

Dynamic ctDNA evaluation of a patient with BRAFV600E metastatic melanoma demonstrates the utility of ctDNA for disease monitoring and tumor clonality analysis

C. Vannas , S. Bjursten , S. Filges , H. Fagman , A. Ståhlberg & M. Levin

To cite this article: C. Vannas , S. Bjursten , S. Filges , H. Fagman , A. Ståhlberg & M. Levin (2020): Dynamic ctDNA evaluation of a patient with BRAFV600E metastatic melanoma demonstrates the utility of ctDNA for disease monitoring and tumor clonality analysis, Acta Oncologica, DOI: [10.1080/0284186X.2020.1802064](https://doi.org/10.1080/0284186X.2020.1802064)

To link to this article: <https://doi.org/10.1080/0284186X.2020.1802064>



© 2020 The Author(s). Published by Informa UK Limited, trading as Taylor & Francis Group.



[View supplementary material](#)



Published online: 08 Aug 2020.



[Submit your article to this journal](#)



Article views: 85



[View related articles](#)



[View Crossmark data](#)

Dynamic ctDNA evaluation of a patient with BRAFV600E metastatic melanoma demonstrates the utility of ctDNA for disease monitoring and tumor clonality analysis

C. Vannas^{a,b}, S. Bjursten^{a,c}, S. Filges^c, H. Fagman^{b,d}, A. Ståhlberg^{b,e,f} and M. Levin^{a,c,g}

^aDepartment of Oncology, Sahlgrenska University Hospital, Gothenburg, Sweden; ^bSahlgrenska Cancer Center for Cancer Research, Department of Laboratory Medicine, Institute of Biomedicine, Sahlgrenska Academy at University of Gothenburg, Gothenburg, Sweden; ^cDepartment of Oncology, Institute of Clinical Sciences, Sahlgrenska Academy, University of Gothenburg, Gothenburg, Sweden; ^dDepartment of Clinical Pathology, Sahlgrenska University Hospital, Gothenburg, Sweden; ^eDepartment of Clinical Genetics and Genomics, Sahlgrenska University Hospital, Gothenburg, Sweden; ^fWallenberg Centre for Molecular and Translational Medicine, University of Gothenburg, Gothenburg, Sweden; ^gWallenberg Laboratory for Cardiovascular Research, Department of Molecular and Clinical Medicine, Sahlgrenska Academy, University of Gothenburg, Gothenburg, Sweden

ARTICLE HISTORY Received 3 June 2020; Accepted 21 July 2020

Introduction

Metastatic melanoma is an aggressive disease with historically poor prognosis [1]. However, during the last decades, treatment of metastatic melanoma has greatly improved with the introduction of immunotherapy and targeted therapy using BRAF/MEK inhibitors [2,3]. Today, immunotherapy is the first line of treatment for patients with metastatic melanoma. Approximately 50% of the patients respond to this treatment, sometimes with long-lasting effects [2]. Patients with activating BRAF V600 mutations can also be treated with BRAF/MEK inhibitors. BRAF/MEK inhibition is effective but development of drug resistance is common [3].

During treatment, patients are routinely followed up with radiological evaluation and by analyzing blood plasma tumor markers, including S-100B and lactate dehydrogenase (LD) [4]. Both radiology and current plasma markers have limited sensitivity and there is a need for improved biomarkers to evaluate treatment response.



Analysis of ctDNA is a novel ultrasensitive approach for patient-specific monitoring of tumor burden and earlier detection of progression and relapse [5]. In metastatic melanoma, patients with detectable levels of ctDNA before starting treatment have a worse prognosis [6,7]. CtDNA analysis correlates to clinical outcome and increased ctDNA has been demonstrated up to 4 months before clinical evidence of progressive disease [8].

Here, we report a case of a patient with a BRAF V600E mutated metastatic melanoma, where ctDNA analysis of BRAF V600E and CTNNB1 S45F using SIMSen-Seq [9] was able to predict recurrence of disease more than seven months before symptomatic and radiological evidence of disease progression.


The allele frequencies of CTNNB1 S45F were at a lower level in both the primary tumor and in ctDNA, indicating a tumor subclone, only detectable during higher tumor burden. This case demonstrates the power of ctDNA for disease monitoring and for the analysis of tumor clonality.

Case

In October 2016, a 69-year-old male was diagnosed with a malignant melanoma above the umbilical region. He displayed a six-year history of a bleeding skin rash that slowly increased in size. Preoperative computer tomography (CT) evaluation of the abdomen and the thorax showed multiple enlarged lymph nodes bilaterally in the axillae (Figure 1(A)). Preoperative blood tests, including the melanoma tumor marker S-100B, were all normal except for a LD value just above the upper limit of normal (ULN). The patient had surgery of the primary tumor, with a split-thickness skin graft, and a bilateral axillary lymph node dissection. Pathoanatomical diagnosis confirmed a malignant melanoma 83 × 70 mm in diameter, with wide excision margin and lymph node metastases bilaterally (Figure 1(D–F)). The patient was staged as pT4aN3aM0. Molecular analysis of the primary tumor showed a BRAF V600E activating mutation with an allele frequency of 51,7% and an activating CTNNB1 S45F mutation with an allele frequency of 7,5%. The fraction of neoplastic cells in the specimen was approximately 50%, indicating a probable copy number gain of the mutant BRAF allele and a subclonal CTNNB1 mutation. This was further verified by FISH, confirming polysomy of chromosome 7 (where the BRAF gene is located) as well as amplification of the BRAF gene in the tumor cells (Figure 1(G–H)).

CONTACT C. Vannas  christoffer.vannas@gu.se  Sahlgrenska cancer center for Cancer Research, Department of Laboratory medicine, University of Gothenburg, Medicinargatan 1G, Gothenburg, SE-413 90, Sweden

This article has been republished with minor changes. These changes do not impact the academic content of the article.

 Supplemental data for this article can be accessed [here](#).

© 2020 The Author(s). Published by Informa UK Limited, trading as Taylor & Francis Group.

This is an Open Access article distributed under the terms of the Creative Commons Attribution License (<http://creativecommons.org/licenses/by/4.0/>), which permits unrestricted use, distribution, and reproduction in any medium, provided the original work is properly cited.

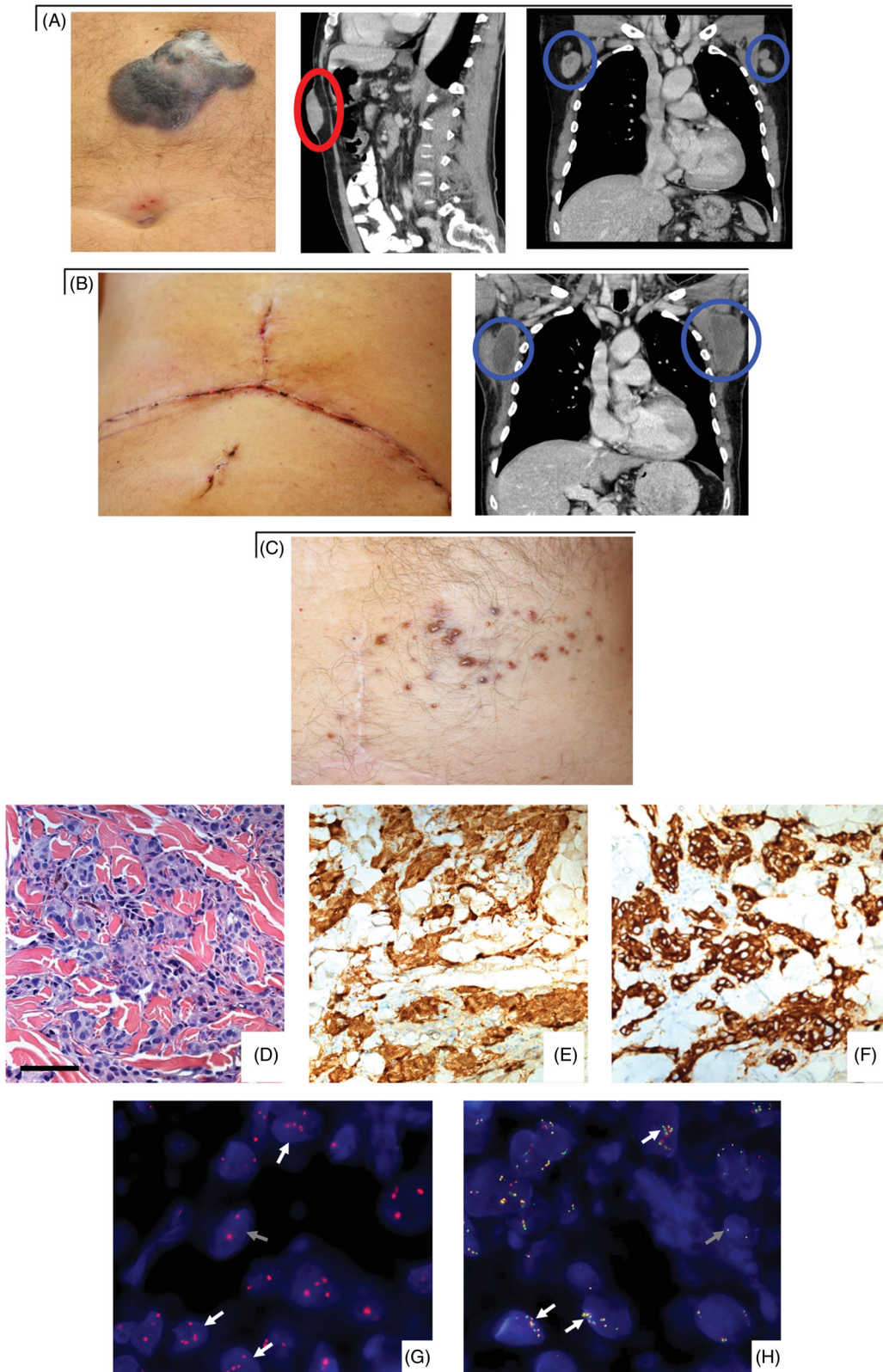


Figure 1. (A) The primary tumor above the umbilical region. Preoperative radiological evaluation with a computer tomography shows the primary tumor (red circles) and the axillary metastases (blue circles). (B) Postoperative images. Postoperative radiological evaluation with a computer tomography shows seromas in the axillae (blue circles), but no sign of tumor recurrence. (C) Disease relapse at the umbilical region 10 months after initiation of palliative treatment. (D–F) Dermal infiltration of malignant melanoma (D) positive for S100 (E) and Melan A (F). Scale bar = 100 μ m. (G) Polysomy of chromosome 7 as evident by CEP7 FISH probe. Gray arrow denotes cell with normal diploid chromosome 7 pattern; white arrows denote cells with chromosome 7 polysomy. (H) Amplification of the BRAF gene as evident by BRAF break apart FISH probe. Gray arrow denotes normal BRAF signal; white arrows denote BRAF cluster amplification ([Supplementary data](#)).

Postoperative CT scan of the abdomen, thorax, neck and brain in December 2016 showed no remaining tumor mass (Figure 1(B)). After a multidisciplinary tumor board, the patient was admitted to the oncological clinic at Sahlgrenska University hospital, Sweden for postoperative radiation therapy.

In mid-December 2016, the patient had his first appointment at the oncological clinic. He was in good performance status (WHO 0) and the surgical wounds were healed (Figure 1(B)). Intriguingly, both S-100B and LD now displayed elevated levels. A new metastasis screening with a positron emission tomography-computed tomography (PET-CT) was performed and indicated multiple skeletal metastases, with metastatic uptake in the right scapula, the sternum, the second lumbar vertebrae and left iliac bone (Figure 2(A)).

Since the tumor had a BRAF V600E activating mutation, palliative treatment was initiated in January 2017 with BRAF/MEK targeted therapy (dabrafenib and trametinib). Blood plasma was collected for subsequent retrospective analysis of ctDNA levels during the course of the disease (Supplementary data).

The patient tolerated the treatment well and after 3 months (day 88) a PET-CT indicated a partial regression of the metastasis in the right scapula and a complete regression of all other metastases. S-100B was now normalized but LD remained slightly above the ULN. CtDNA levels of BRAF V600E and CTNNB1 S45F were elevated at the initiation of targeted treatment (day 0) but decreased rapidly upon initiation of treatment, and were not detectable after 42 days of treatment (Figures 2(A–C)).

In June 2017 (day 149) a new PET-CT showed additional regression of the metastasis in the right scapula and otherwise no sign of metastatic activity. Both S-100B and LD were now below the ULN. To prevent the development of drug resistance, treatment was changed to immunotherapy with Pembrolizumab every third week. In September 2017 (day 235), a new PET-CT showed a complete regression of all metastases and normal tumor markers.

In December 2017 (day 312), the patient started to notice small bumps in the skin at the scar of the primary tumor in the trunk (Figure 1(C)). Fine needle aspiration confirmed a local tumor relapse. The patient also reported progressive symptoms of headache and visual impairment. A metastatic screening with a PET-CT indicated metastatic uptake in abdominal and thoracic lymph nodes and in the left occipital lobe in the brain. An MRI of the brain confirmed a 27 × 30 × 35 mm metastasis (Figure 2(A)). At this stage, both S-100B and LD still remained below ULN (Figure 2(C)). Intriguingly, ctDNA levels of BRAF V600E were detectable since day 91 (Figure 2(C)), i.e., more than 7 months prior to signs of clinical and radiological progression. Over the next months, the ctDNA levels of BRAF V600E were slowly increasing and in November 2017 (day 301) ctDNA levels of CTNNB1 S45F were also detectable.

The patient started corticosteroid treatment and the symptoms gradually decreased. Over the next year, the patient received various palliative regimes, such as reinitiated BRAF/MEK targeted therapy, palliative radiation therapy and

chemotherapy with temozolamide, with mixed response. The disease eventually progressed and in March 2019, the patient passed away due to encephalopathy, related to brain metastases.

Discussion

This case demonstrates the utility of detection of ctDNA dynamics in disease evaluation of metastatic melanoma. In this case, reoccurrence of the BRAF V600E mutation in ctDNA was detected as early as seven months prior to clinical/radiological recurrence, whereas the melanoma markers S-100B and LD remained normal. Our results are consistent with previous reports of ctDNA being a sensitive and early marker for disease progression in metastatic melanoma [6,10–12]. However, the very early increase of BRAF V600E ctDNA is remarkable in the present case. Another interesting point is that the ctDNA levels gradually increased over time whereas radiological evaluation showed continuous tumor regression. This may be due to the occurrence of tumor deposits too small to be detected by radiological evaluation, but where the BRAF copy number gain permitted very early detection in plasma. The additional information generated from ctDNA analysis could possibly have changed the clinical approach, to initiate a more thorough metastasis screening earlier or to initiate second-line therapy.

In addition to disease monitoring, ctDNA analysis opens up the possibility of analyzing tumor clonality and the occurrence of different tumor subclones during disease progression. In this case, it is demonstrated by the possibility to detect a subclonal CTNNB1 S45F mutation upon radiological evidence of metastatic disease. Whether this mutation is subclonally expressed at all the metastatic sites, or ubiquitously expressed in a subset of the metastatic sites is not possible to say. Although less likely, it is also possible that the same CTNNB1 mutation as in the primary tumor has developed de novo at one of the metastatic sites during disease recurrence.

The CTNNB1 S45F mutation occurs in exon three of the β -catenin gene, which is part of the regulatory N-terminal protein domain. Mutations in this domain result in protein stabilization by reduction of phosphorylation-dependent ubiquitylation, causing increased WNT/ β -catenin signaling [13]. Although WNT/ β -catenin signaling in cancer is generally considered an oncogenic event, the role of WNT/ β -catenin signaling in melanomas is not fully elucidated. Elevated levels of nuclear β -catenin in primary tumors and metastases of melanomas are associated with reduced proliferation and improved survival [14]. Conversely, in preclinical models of melanomas, WNT/ β -catenin signaling is linked with a phenotypic switch to a more aggressive and invasive phenotype and to immune suppression [15–18].

It is not possible to draw any conclusion of the biological role of β -catenin signaling in metastatic melanoma from this case. However, it is an interesting observation that this patient with a subclonal CTNNB1 S45F mutation, has a clinical course with a rapid onset of metastatic

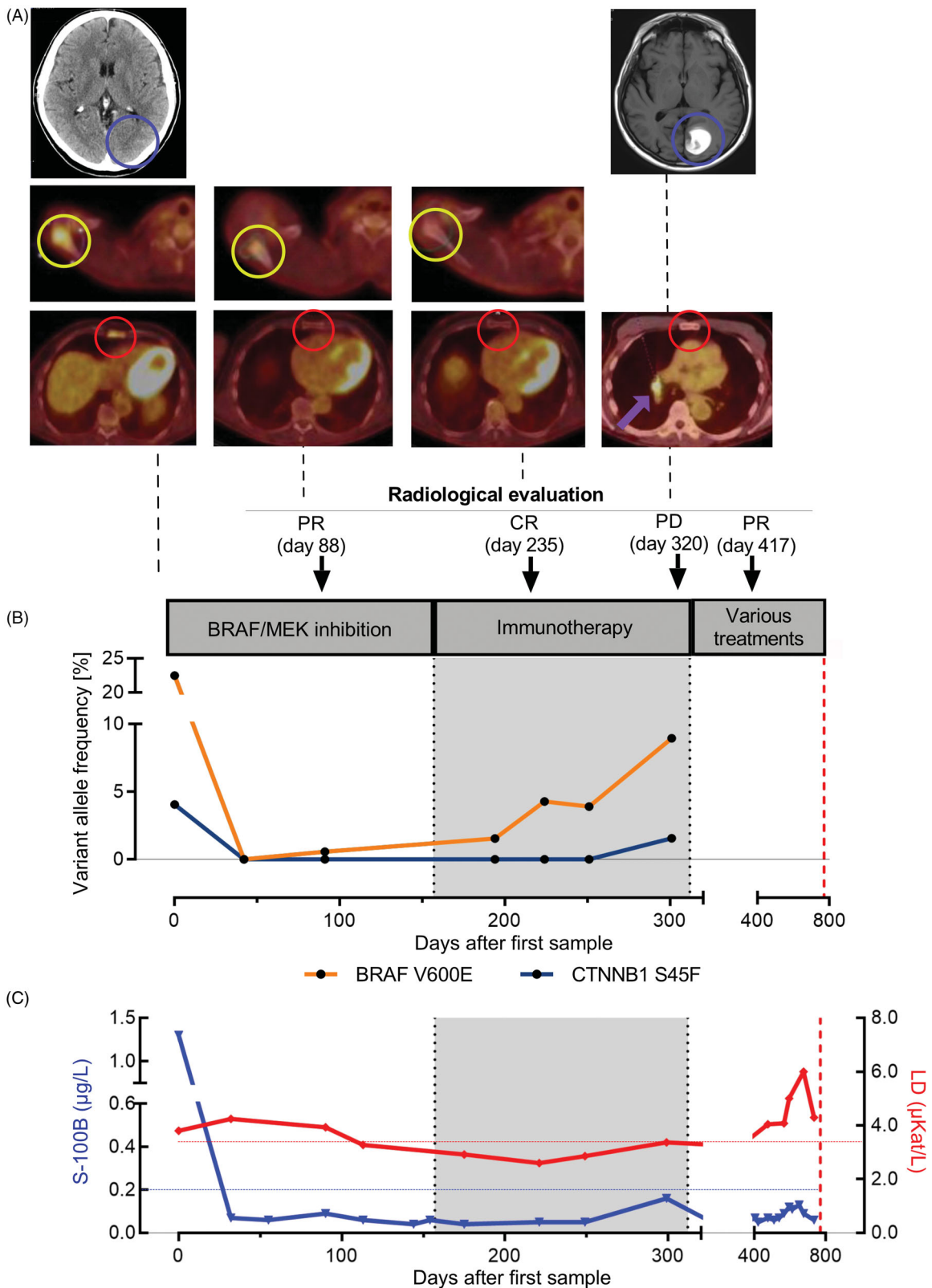


Figure 2. (A) Radiological evaluations during the course of disease. On first row, a computer tomography of the brain prior to initiation of treatment and a Magnetic Resonance Imaging at disease recurrence. Blue circles indicate the anatomical position where the metastasis subsequently occurs. On second and third row, a positron emission tomography-computed tomography of the left scapula and the sternum respectively. Yellow and red circles indicate evaluated lesions. Purple arrow indicates a metastatic lymph glandule that is found at disease recurrence. (B) Variant allele frequency of BRAF V600E mutation (orange) and CTNNB1 S45F mutation (blue). Radiological response is indicated above the figure. CR: Complete response; PR: Partial response; PD: Progressive disease. Red dotted line at the end of the chart indicates time of death. (C) Levels of S-100B and Lactate Dehydrogenase at the same time points as indicated in (B). Blue dotted horizontal line indicates the ULN of S-100B (0,2). Red dotted line indicates the ULN of Lactate Dehydrogenase (3,4 for patients up to 70 years of age).

disease after surgery and disease progression during immunotherapy. The role of β -catenin signaling in the process of invasion, metastasis and immune evasion should be further investigated.

In summary, this case illustrates that ctDNA monitoring provides pivotal clinical information and should be considered as a standard follow-up method in patients with metastatic melanomas.

Acknowledgements

Maria Delin is acknowledged for excellent technical assistance.

Author contributions

All authors have contributed to study design and acquisition of data. CV and ML drafted the manuscript, all coauthors contributed to revising the draft and approved of the submitted manuscript.

Disclosure statement

Max Levin has received lecturing fees from Bristol-Myers Squibb, Novartis and Roche. Anders Ståhlberg is co-inventor of SiMSen-Seq that is patent protected. The other authors claim no disclosure of interest.

Funding

This research was funded by Assar Gabrielssons Research Foundation; Johan Jansson Foundation for Cancer Research; Knut and Alice Wallenberg Foundation, Wallenberg Centre for Molecular and Translational Medicine, University of Gothenburg, Gothenburg, Sweden; Swedish Cancer Society [19-0306]; Swedish Research Council [2017-01392]; the Swedish state under the agreement between the Swedish government and the county councils, the ALF-agreement [716321 to AS and 828121 and 870351 to ML]; Wilhelm and Martina Lundgren Foundation for Scientific Research, Jubileumsklinikens Cancerfond and VINNOVA.

References

- [1] Gladfelter P, Darwish NHE, Mousa SA. Current status and future direction in the management of malignant melanoma. *Melanoma Res.* 2017;27(5):403–410.
- [2] Ascierto PA, Long GV, Robert C, et al. survival outcomes in patients with previously untreated BRAF wild-type advanced melanoma treated with nivolumab therapy: three-year follow-up of a randomized phase 3 trial. *JAMA Oncol.* 2019;5(2):187–194.
- [3] Robert C, Grob JJ, Stroyakovskiy D, et al. Five-year outcomes with dabrafenib plus trametinib in metastatic melanoma. *N Engl J Med.* 2019;381(7):626–636.
- [4] Deckers EA, Wevers KP, Muller Kobold AC, et al. S-100B as an extra selection tool for FDG PET/CT scanning in follow-up of AJCC stage III melanoma patients. *J Surg Oncol.* 2019;120(6):1031–1037.
- [5] Pantel K, Alix-Panabières C. Liquid biopsy and minimal residual disease - latest advances and implications for cure. *Nat Rev Clin Oncol.* 2019;16(7):409–424.
- [6] Schreuer M, Meersseman G, Van Den Herrewegen S, et al. Quantitative assessment of BRAF V600 mutant circulating cell-free tumor DNA as a tool for therapeutic monitoring in metastatic melanoma patients treated with BRAF/MEK inhibitors. *J Transl Med.* 2016;14:95.
- [7] Forthun RB, Hovland R, Schuster C, et al. ctDNA detected by ddPCR reveals changes in tumour load in metastatic malignant melanoma treated with bevacizumab. *Sci Rep.* 2019;9(1):17471.
- [8] McEvoy AC, Pereira MR, Reid A, et al. Monitoring melanoma recurrence with circulating tumor DNA: a proof of concept from three case studies. *Oncotarget.* 2019;10(2):113–122.
- [9] Stahlberg A, Krzyzanowski PM, Jackson JB, et al. Simple, multiplexed, PCR-based barcoding of DNA enables sensitive mutation detection in liquid biopsies using sequencing. *Nucleic Acids Res.* 2016;44(11):e105
- [10] Gray ES, Rizos H, Reid AL, et al. Circulating tumor DNA to monitor treatment response and detect acquired resistance in patients with metastatic melanoma. *Oncotarget.* 2015;6(39):42008–42018.
- [11] Lipson EJ, Velculescu VE, Pritchard TS, et al. Circulating tumor DNA analysis as a real-time method for monitoring tumor burden in melanoma patients undergoing treatment with immune checkpoint blockade. *J Immunotherapy Cancer.* 2014;2:42.
- [12] Seremet T, Jansen Y, Planken S, et al. Undetectable circulating tumor DNA (ctDNA) levels correlate with favorable outcome in metastatic melanoma patients treated with anti-PD1 therapy. *J Transl Med.* 2019;17:303.
- [13] Kim S, Jeong S. Mutation hotspots in the β -catenin gene: lessons from the human cancer genome databases. *Mol Cells.* 2019;42(1):8–16.
- [14] Larue L, Delmas V. The WNT/Beta-catenin pathway in melanoma. *Front Biosci.* 2006;11:733–742.
- [15] Chien AJ, Moore EC, Lonsdorf AS, et al. Activated Wnt/beta-catenin signaling in melanoma is associated with decreased proliferation in patient tumors and a murine melanoma model. *Proc Natl Acad Sci USA.* 2009;106(4):1193–1198.
- [16] Li FZ, Dhillon AM, Anderson RL, et al. Phenotype switching in melanoma: Implications for progression and therapy. *Front Oncol.* 2015;5(Feb):31.
- [17] Damsky WE, Curley DP, Santhanakrishnan M, et al. β -Catenin signaling controls metastasis in Braf-activated Pten-deficient melanoma. *Cancer Cell.* 2011;20(6):741–754.
- [18] Spranger S, Bao R, Gajewski TF. Melanoma-intrinsic β -catenin signalling prevents anti-tumour immunity. *Nature.* 2015;523(7559):231–235.