

## Measurement of stapes footplate thickness in otosclerosis by ultra-high-resolution computed tomography

Yukinori Akazawa , Akira Ganaha , Teruyuki Higa , Shunsuke Kondo , Yoshiaki Oyakawa , Hitoshi Hirakawa , Mikio Suzuki & Tsuneo Yamashiro

To cite this article: Yukinori Akazawa , Akira Ganaha , Teruyuki Higa , Shunsuke Kondo , Yoshiaki Oyakawa , Hitoshi Hirakawa , Mikio Suzuki & Tsuneo Yamashiro (2020): Measurement of stapes footplate thickness in otosclerosis by ultra-high-resolution computed tomography, Acta Oto-Laryngologica, DOI: [10.1080/00016489.2020.1788225](https://doi.org/10.1080/00016489.2020.1788225)

To link to this article: <https://doi.org/10.1080/00016489.2020.1788225>



© 2020 The Author(s). Published by Informa UK Limited, trading as Taylor & Francis Group



Published online: 23 Jul 2020.



Submit your article to this journal [↗](#)



Article views: 221



View related articles [↗](#)



View Crossmark data [↗](#)

## Measurement of stapes footplate thickness in otosclerosis by ultra-high-resolution computed tomography

Yukinori Akazawa<sup>a</sup>, Akira Ganaha<sup>a,b</sup>, Teruyuki Higa<sup>a</sup>, Shunsuke Kondo<sup>a</sup>, Yoshiki Oyakawa<sup>a</sup>, Hitoshi Hirakawa<sup>a</sup>,  
Mikio Suzuki<sup>a</sup> and Tsuneo Yamashiro<sup>c,d</sup>

<sup>a</sup>Department of Otorhinolaryngology, Head and Neck Surgery, Graduate School of Medicine, University of the Ryukyus, Nishihara-cho, Japan; <sup>b</sup>Department of Otorhinolaryngology-Head and Neck Surgery, University of Miyazaki, Miyazaki, Japan; <sup>c</sup>Department of Radiology, Graduate School of Medicine, University of the Ryukyus, Nishihara-cho, Japan; <sup>d</sup>Department of Radiology, Yokohama City University School of Medicine, Yokohama, Japan

### ABSTRACT

**Background:** Ultra-high-resolution computed tomography (U-HRCT) utilizes a  $1024 \times 1024$  matrix with 0.25-mm section thickness, offering better spatial resolution than conventional multi-detector row CT to detect anatomic data for otologic surgery.

**Aims:** We examined stapes footplate thickness using U-HRCT in relation to stapedotomy to predict the difficulty of the surgical procedure.

**Materials and methods:** Subjects were 12 otosclerosis patients and 25 controls who underwent diagnostic U-HRCT. A profile curve (Hounsfield units) was used to measure stapes footplate thickness along a perpendicular line across the stapes footplate in a plane parallel to the lateral semicircular canal.

**Results:** Footplate thickness was smaller at the midpoint than just before the anterior crus and just after the posterior crus. Interobserver variability was lowest at the midpoint, where foot plate thickness was significantly greater in the affected ear in otosclerosis patients compared with controls ( $0.60 \pm 0.09$  mm vs  $0.46 \pm 0.04$  mm;  $p < .001$ ). Otosclerosis patients were detected using U-HRCT with a high area under the curve. Difficulty in the stapes opening procedure correlated with stapes footplate thickness.

**Conclusions:** Footplate thickness on U-HRCT correlated with temporal bone anatomy and corresponded to surgical difficulty.

**Significance:** U-HRCT-derived anatomic data is useful for evaluating the stapes.

### ARTICLE HISTORY

Received 28 May 2020  
Accepted 20 June 2020

### KEYWORDS

Otosclerosis; stapes footplate thickness; ultra-high-resolution computed tomography



## Introduction

Otosclerosis is a multifactorial temporal bone disorder with genetic and environmental causes involving endochondral bone of the otic and labyrinthine capsules. The prevalence of clinical otosclerosis is approximately 0.3–0.4% in the United States, although the prevalence of subclinical histologically confirmed disease is higher [1]. In 1841, Toynbee found stapes fixation in 39 of the 1659 temporal bones (2%) and thus established the link between deafness and stapes fixation [2]. It is important to clarify the fine architectural changes in the temporal bone in order to enable accurate differential diagnosis of several middle and inner ear disorders from otosclerosis [3]. The incidence of otosclerosis is estimated to be much lower in Japanese than in Caucasians [4]. This is considered to be due to the low incidence of involvement of foci anterior to the oval window, low activity, and small lesion size without involvement of the footplate and/or membranous labyrinth of the inner ear [5].

Although otosclerosis is uncommon in the Japanese population, its incidence has been increasing [4].

Stapedectomy and stapedotomy are both standard surgeries for otosclerosis, and stapedotomy provides better improvement in high frequency hearing and has low complication rates [6]. The most important point in stapedotomy is adequate opening of the oval window to avoid damage to the inner ear [7]. Stapes footplate thickness affects the difficulty of the surgical procedure for opening the footplate. Preoperative imaging is thus important for adequately examining the condition of the stapes footplate.

Ultra-high-resolution computed tomography (U-HRCT) scanning with ultra-small detector elements ( $0.25 \times 0.25$  mm) is currently achievable using the 160-row U-HRCT scanner (Aquilion Precision<sup>®</sup>; Canon Medical Systems, Tochigi, Japan) [8]. U-HRCT affords better spatial resolution than multi-detector row CT, and has been successfully introduced into clinical use, for example, for imaging small lung lesions and small vessels in the brain and body [9–11]. While smaller

**CONTACT** Mikio Suzuki  [suzuki@med.u-ryukyu.ac.jp](mailto:suzuki@med.u-ryukyu.ac.jp)  Department of Otorhinolaryngology, Head and Neck Surgery, Graduate School of Medicine, University of the Ryukyus, 207 Uehara, Nishihara-cho, Okinawa 903-0215, Japan

© 2020 The Author(s). Published by Informa UK Limited, trading as Taylor & Francis Group  
This is an Open Access article distributed under the terms of the Creative Commons Attribution-NonCommercial-NoDerivatives License (<http://creativecommons.org/licenses/by-nc-nd/4.0/>), which permits non-commercial re-use, distribution, and reproduction in any medium, provided the original work is properly cited, and is not altered, transformed, or built upon in any way.

detector elements enhance the spatial resolution of CT images by reducing the partial volume effect, the utility of U-HRCT for evaluation of the middle and inner ear structures has not been fully evaluated. In otology, U-HRCT has been beneficial for detecting abnormalities of the ossicular chain and inner ear structures [12,13]. These anatomic data obtained by using U-HRCT may help in surgical planning for ear surgery.

In this study, we measured the thickness of the stapes footplate and bony change around the oval window in patients with otosclerosis. The aim was to examine the stapes footplate thickness detected by U-HRCT in relation to stapedotomy to predict the difficulty of the surgical procedure.

## Subjects and methods

Subjects were 23 affected ears in 12 patients with otosclerosis who were clinically diagnosed based on tympanic membrane findings, audiometric examinations, and temporal bone imaging obtained by using a U-HRCT scanner between August 2017 and February 2020. Of the 12 patients with otosclerosis, eight underwent stapedotomy (unilateral seven and bilateral one) performed by four surgeons (TH, SK, AG, and MS). As controls, temporal bone images of 50 ears in 25 patients with ear drum perforation, sudden deafness, or facial palsy were analysed. These control subjects did not have any lesions around the stapes that would interfere with measurements. Clinical charts including digital recordings of the surgical procedure and operative records were reviewed and compared with U-HRCT findings.

All CT scans were performed with a U-HRCT scanner with 0.25-mm collimation (160 detector rows along the z axis, and 1792 channels with a 0.25-mm detector size in the x-y plane). The U-HRCT scanner settings were as follows: tube voltage = 120 kVp; tube current = 260 mA; collimation = 160 × 0.25 mm (step-and-shoot non-helical scanning); rotation time = 1.5 sec; imaging field of view (FOV) = 80 × 80 mm (matrix size of 512); slice thickness = 0.25 mm, reconstruction kernel = FC30; and image reconstruction = filtered back projection [9].

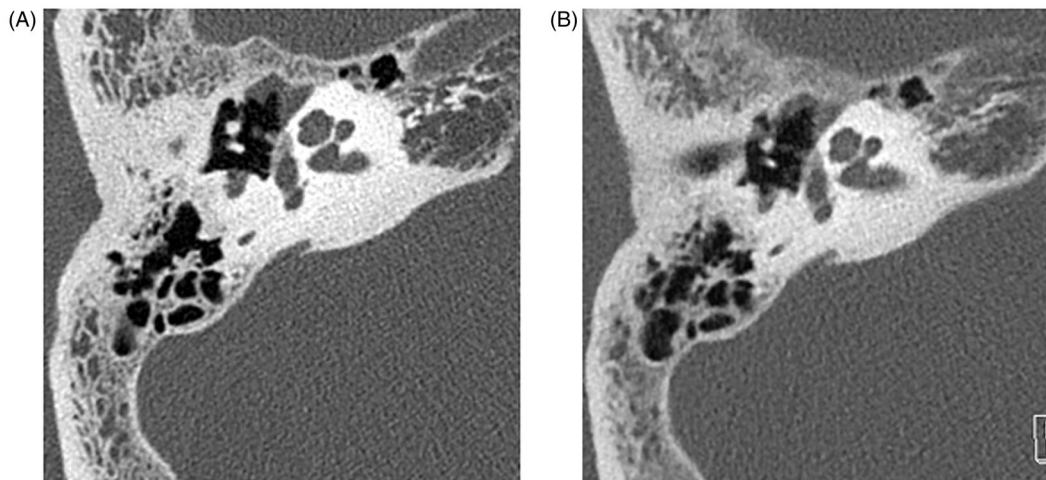
The Hounsfield unit (HU), which is a universally used dimensionless unit, enables quantitative measurement of radio density in the interpretation of CT images. On the HU scale, water is defined as 0 HU, and air is defined as −1000 HU, respectively. Retrospective image analysis was carried out using Ziostation 2 software (Ziosoft Inc., Tokyo, Japan). The HU value was measured along a perpendicular line across the stapes footplate in a plane parallel to the lateral semicircular canal (Figure 1(A,C)). The plane for measurement was selected so that the anterior crus (AC) and posterior crus (PC) in the footplate could be observed simultaneously. Profile curves, which demonstrated the HU value, were automatically created by the software along the perpendicular line. Based on the full width at half maximum (FWHM) method, the thickness of the footplate was semi-automatically measured on the profile curve (Figure 1(B,C)).

Footplate thickness was measured just before the AC, at the midpoint between the AC and PC, and just after the PC by three neuro-otologic surgeons (YA, TH, and SK) who were blinded to the patients' clinical information. Interobserver variability at the three measurements points was investigated. Data were analysed using the SPSS statistical package (SPSS for Windows version 25.0; SPSS Inc., Chicago, IL).

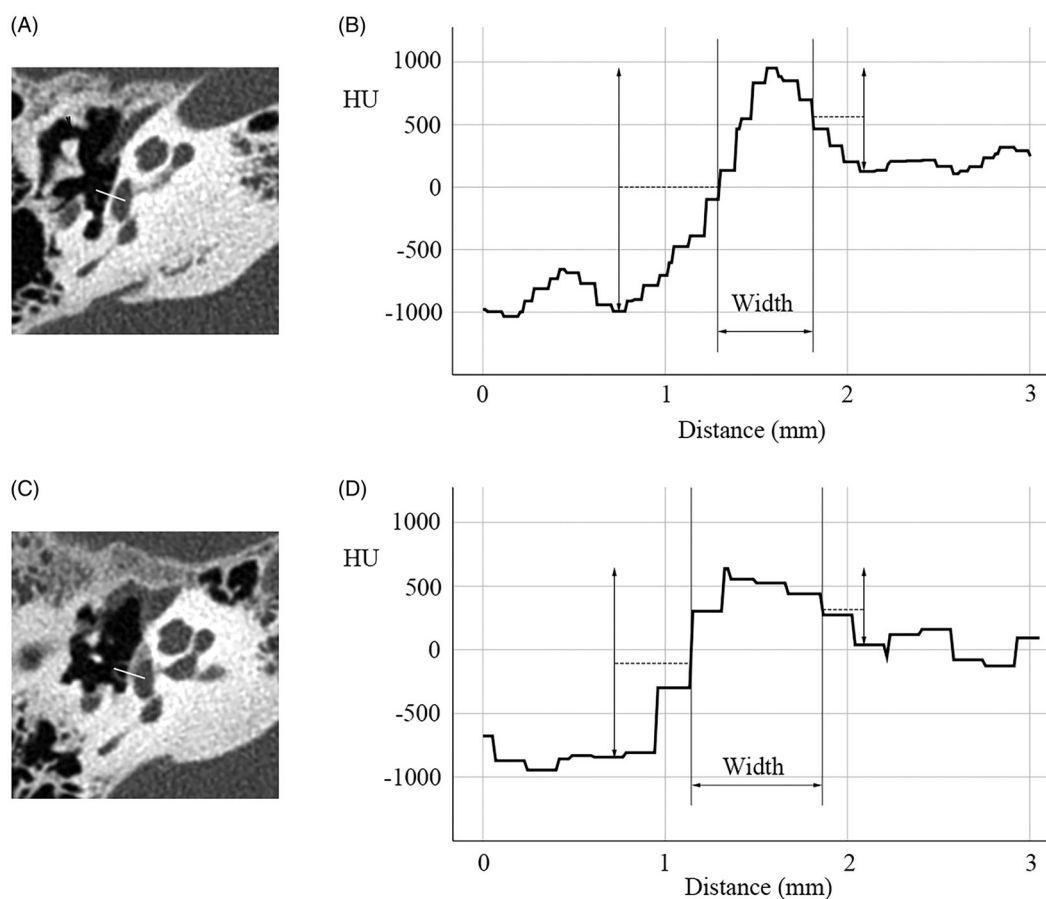
This retrospective study was approved by the Institutional Review Board of University of the Ryukyus and carried out in accordance with the 1975 Declaration of Helsinki, as revised in 2008. Written informed consent from enrolled participants was waived and opt-out opportunities provided to these subjects.

## Results

Mean age of patients (four males and eight females) with otosclerosis was 53 (range, 32–78) years while that of the controls (eight males and 17 females) was 50 (range, 10–78) years. There were no significant differences in age and sex distribution between the otosclerosis patients and controls. Of the 12 patients (23 ears) with otosclerosis, all had fenestral lesions, and one patient (two ears) had retrofenestral involvement in



**Figure 1.** Images from ultra-high-resolution CT (A) and conventional high-resolution CT (B) of the same patient. A. U-HRCT image (0.25-mm slice thickness) in the lateral semicircular canal plane. Decreased HU value in the fissula ante fenestram and stapes was noted. B. HRCT image (1-mm thickness) in the lateral semicircular canal plane. This image was obtained 3 months before A at another hospital. Lesions at the stapes and fissula ante fenestram are not clear on this image.



**Figure 2.** Measurement of stapes footplate thickness. (A) Normal control. Line in A represents a perpendicular line across the stapes footplate at the midpoint between the anterior and posterior crura. (B) Profile curve in A. Longitudinal axis shows HU value along the perpendicular line shown in A. Width was measured as representing stapes footplate thickness using the full width at half maximum (FWHM) method. (C) Otosclerosis patient. Line in C represents a perpendicular line across the stapes footplate at the midpoint between the anterior and posterior crura. (D) Profile curve in C. Longitudinal axis shows HU value along the perpendicular line shown in C. Width was measured using the FWHM method, resulting in much thicker width than in the normal control (B).

addition to fenestral lesion. The fenestral lesion was clearly identified on the U-HRCT image (Figure 2).

### Footplate thickness in the controls

Mean footplate thickness determined by the three neuro-otologists in the control group was 0.61 mm at AC, 0.46 mm at the midpoint, and 0.64 mm at the PC (Table 1). Although there was no significant difference in footplate thickness between the AC and PC, footplate thickness was significantly smaller at the midpoint than at the AC and PC (Friedman test,  $p < .001$ ). There was no significant difference in thickness between the right and left ears.

### Footplate thickness in the otosclerosis patients

Mean footplate thickness in the otosclerosis group was 0.94 mm at the AC, 0.60 mm at the midpoint, and 0.72 mm at the PC (Table 1). Footplate thickness was significantly greater at the AC than at the PC as well as at the midpoint (Wilcoxon's test,  $p < .001$ ). Also, footplate thickness was smaller at the midpoint than at the PC (Wilcoxon's test,  $p < .001$ ). Footplate thickness

**Table 1.** Footplate thickness at three points in controls and otosclerosis patients.

	Anterior crus (mm)		Midpoint (mm)		Posterior crus (mm)	
	Mean	1 SD	Mean	1 SD	Mean	1 SD
Controls (n = 50)	0.61	0.08	0.46	0.04	0.64	0.10
Right ear (n = 25)	0.62	0.08	0.46	0.04	0.64	0.09
Left ear (n = 25)	0.60	0.08	0.45	0.04	0.64	0.11
Otosclerosis (n = 23)	0.94	0.16	0.60	0.09	0.72	0.02

at the AC, midpoint, and PC was significantly greater in patients with otosclerosis than in the control group, respectively (Kruskal-Wallis,  $p < .001$ ;  $p < .001$ ;  $p < .002$ , respectively).

### Interobserver variability at the three measurement points

Interobserver variability for all subjects including controls and otosclerosis patients was 0.306 at the AC, 0.536 at the midpoint, and 0.436 at the PC, which demonstrated fair to

moderate interobserver agreement. Interobserver variability in patients with otosclerosis was 0.043 at the AC, 0.469 at the midpoint, and 0.310 at the PC, respectively. Thus, interobserver agreement was highest at the midpoint among the three-point measurements.

### Receiver operating characteristic (ROC) analysis for stapes footplate thickness in controls and otosclerosis patients

Interobserver agreement was highest at the midpoint between the AC and PC, so stapes footplate thickness was measured at the midpoint for ROC analysis (Figure 3). The ROC curve analysis yielded an area under the curve of 0.953 (95% confidence interval, 0.911–0.996). The maximum sum of specificity and sensitivity was observed at footplate thickness of 0.48. The sensitivity, specificity, positive predictive value, and negative predictive value for detecting otosclerosis were 100%, 74%, 64%, and 100%, respectively.

### U-HRCT findings of stapes footplate thickness and surgical procedure

Of the 12 patients with otosclerosis, eight patients underwent stapedotomy (seven unilateral and one bilateral). No patient required revision surgery. Operators experienced some difficulty with the stapes opening procedure in one of the nine stapedotomy surgeries. This patient had a stapes footplate thickness of 0.81 mm at the midpoint, which was the greatest in this series.

### Discussion

Evaluation of stapes footplate thickness in addition to adequate selection of prosthesis length is crucial in stapedotomy. In this study, stapes footplate thickness was successfully measured and was significantly greater in otosclerosis than in controls on U-HRCT. From the results of interobserver

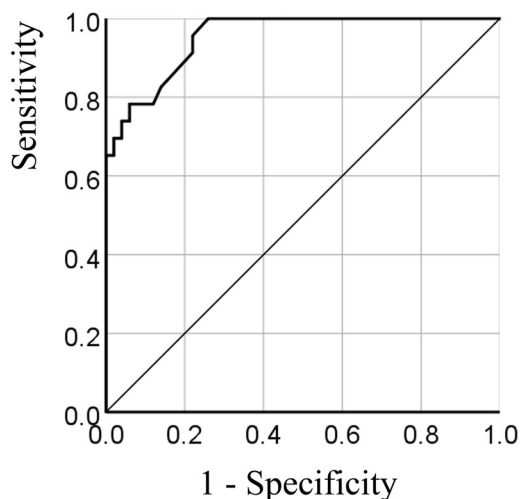
variability, the midpoint was the best point for measuring footplate thickness among the three points. ROC analysis revealed that patients with otosclerosis could be detected using U-HRCT. This is the first report to demonstrate the efficacy of stapes footplate thickness measurement by U-HRCT. Schuknecht and Barber reported on 164 (12.3%) otosclerotic lesions in the 1330 temporal bones in their collection, with and without stapes fixation [14]. Otosclerotic foci were observed in 1.48% of 1011 temporal bones in a Japanese cohort [5]. In our study, fenestral involvement was observed in all patients, but only one patient had retrofenestral involvement and the sample size was limited. Disease severity in patients with otosclerosis in this study was mild and the findings are consistent with previous studies in the Japanese population [4,5].

U-HRCT provides increased spatial resolution because of the halved collimation (0.25 mm) compared with that of conventional HRCT. The shape, thickness, and curvature of the footplate are variable. The medial surface of the footplate is curved and the annular rim has the greatest thickness in the posterior region and the smallest thickness in the anterior region [15]. According to anatomic data of the stapes, the footplate thickness ranges from 0.228 to 0.411 mm [16,17]. Mean footplate thickness at the midpoint in our study was 0.46 mm in the controls. Thickness measured on U-HRCT was consistent with anatomic observations. A previous study using conventional HRCT for normal controls demonstrated that stapes footplate thickness was 0.27 mm on the stapes axial plane and 0.42 mm on the lateral semicircular canal plane [18]. The plane in our study was similar to the semicircular canal plane used in this previous study. Because our data were similar to their footplate thickness data, the stapes axial plane in U-HRCT might be more helpful for determining the exact footplate size. However, stapes footplate thickness was successfully measured in otosclerosis patients as well as controls and differed significantly between the groups. The lateral semicircular canal plane is conventional and easy to use, and the semicircular canal plane in U-HRCT is also available for assessing the condition of the footplate because of the small partial volume effect.

Our findings suggest that stapes footplate thickness detected using U-HRCT corresponded to surgical difficulty, although the number of cases was small and the degree of otosclerosis was relatively mild. Our results also demonstrated that imaging data obtained using U-HRCT is consistent with the anatomy of the temporal bone, because it has smaller collimation, more channels and detector rows, and a smaller focus size than conventional CT. Further research is required to determine the usefulness of U-HRCT in otologic surgery, for example, selection of prosthesis length in stapes surgery and evaluation of postoperative prosthesis status, such as vestibular intrusion.

### Methodological considerations/limitations

The number of patients with otosclerosis was too small to adequately evaluate the surgical procedure. In addition, the semicircular canal plane was examined, not the stapes axial



**Figure 3.** Receiver operating characteristic analysis for stapes footplate thickness in control and otosclerosis patients. Area under the curve, 0.953 (95% confidence interval, 0.911–0.996).

plane, and there was significant difference between patients with otosclerosis and controls.

## Acknowledgements

We thank the Ryukyū Society for the Promotion of Oto-Rhino-Laryngology for writing assistance and technical support.

## Disclosure statement

The authors report no conflict of interest.

## References

- [1] Quesnel AM, Ishai R, McKenna MJ. Otosclerosis: temporal bone pathology. *Otolaryngol Clin North Am.* 2018;51(2):291–303.
- [2] Nazarian R, McElveen JT, Jr., Eshraghi AA. History of otosclerosis and stapes surgery. *Otolaryngol Clin North Am.* 2018;51(2):275–290.
- [3] Revesz P, Liktor B, Liktor B, et al. Comparative analysis of pre-operative diagnostic values of HRCT and CBCT in patients with histologically diagnosed otosclerotic stapes footplates. *Eur Arch Otorhinolaryngol.* 2016;273(1):63–72.
- [4] Yagi T. Incidence and characteristics of otosclerosis in the Japanese population. *Auris Nasus Larynx.* 2002;29(3):257–260.
- [5] Ohtani I, Baba Y, Suzuki T, et al. Why is otosclerosis of low prevalence in Japanese? *Otol Neurotol.* 2003;24(3):377–381.
- [6] Cheng HCS, Agrawal SK, Parnes LS. Stapedectomy versus stapedotomy. *Otolaryngol Clin North Am.* 2018;51(2):375–392.
- [7] Rask-Andersen H, Schart-Moren N, Stromback K, et al. Special anatomic considerations in otosclerosis surgery. *Otolaryngol Clin North Am.* 2018;51(2):357–374.
- [8] Tanaka R, Yoshioka K, Takagi H, et al. Novel developments in non-invasive imaging of peripheral arterial disease with CT: experience with state-of-the-art, ultra-high-resolution CT and subtraction imaging. *Clin Radiol.* 2019;74(1):51–58.
- [9] Xu Y, Yamashiro T, Moriya H, et al. Quantitative emphysema measurement on ultra-high-resolution CT scans. *COPD.* 2019;14:2283–2290.
- [10] Meijer FJA, Schuijf JD, de Vries J, et al. Ultra-high-resolution subtraction CT angiography in the follow-up of treated intracranial aneurysms. *Insights Imaging.* 2019;10(1):2.
- [11] Takagi H, Tanaka R, Nagata K, et al. Diagnostic performance of coronary CT angiography with ultra-high-resolution CT: comparison with invasive coronary angiography. *Eur J Radiol.* 2018;101:30–37.
- [12] Hiraumi H, Obara M, Yoshioka K, et al. Detectability of minute temporal bone structures with ultra-high resolution CT. *Auris Nasus Larynx.* 2019;46(6):830–835.
- [13] Yamashita K, Hiwatashi A, Togao O, et al. Ultrahigh-resolution CT scan of the temporal bone. *Eur Arch Otorhinolaryngol.* 2018;275(11):2797–2803.
- [14] Schuknecht HF, Barber W. Histologic variants in otosclerosis. *Laryngoscope.* 1985;95(11):1307–1317.
- [15] Sim JH, Roosli C, Chatzimichalis M, et al. Characterization of stapes anatomy: investigation of human and guinea pig. *J Assoc Res Otolaryngol.* 2013;14(2):159–173.
- [16] Farahani RM, Nooranipour M. Anatomy and anthropometry of human stapes. *Am J Otolaryngol.* 2008;29(1):42–47.
- [17] Veillon F, Riehm S, Emachescu B, et al. Imaging of the windows of the temporal bone. *Semin Ultrasound CT Mr.* 2001;22(3):271–280.
- [18] Rousset J, Garetier M, Gentric JC, et al. Biometry of the normal stapes using stapes axial plane, high-resolution computed tomography. *J Laryngol Otol.* 2014;128(5):425–430.