

Outcomes of frontolateral vertical partial laryngectomy in T1b glottic carcinomas

Rawad Jadeed & Martin Westhofen

To cite this article: Rawad Jadeed & Martin Westhofen (2020): Outcomes of frontolateral vertical partial laryngectomy in T1b glottic carcinomas, Acta Oto-Laryngologica, DOI: [10.1080/00016489.2020.1816659](https://doi.org/10.1080/00016489.2020.1816659)

To link to this article: <https://doi.org/10.1080/00016489.2020.1816659>



© 2020 The Author(s). Published by Informa UK Limited, trading as Taylor & Francis Group



Published online: 17 Sep 2020.



Submit your article to this journal [↗](#)



Article views: 58



View related articles [↗](#)



View Crossmark data [↗](#)

Outcomes of frontolateral vertical partial laryngectomy in T1b glottic carcinomas

Rawad Jadeed* and Martin Westhofen

Department of Otorhinolaryngology and Plastic Surgery, RWTH Aachen University, Aachen, Germany

ABSTRACT

Background: The treatment of T1b glottic carcinomas with invasion of the anterior commissure (AC) is still a challenge in larynx oncology. The diversity in treatment protocols is due to the difficulty in achieving safety margins of resection, especially in the AC.

Objective: The treatment success rate of frontolateral vertical partial laryngectomy (FVPL) for the treatment of stage T1b squamous cell carcinoma of the glottic larynx infiltrating the AC.

Material and Methods: Clinical data of patients, who were diagnosed with stage T1b squamous cell carcinoma of the glottic larynx and who underwent a FVPL from 01/2003 to 12/2016 in our ENT clinic were retrospectively evaluated. Clinical and oncological outcomes were analyzed.

Results: 39 patients were included in this study. The mean follow-up duration was 79.95 ± 20.59 months. Intraoperative R0 resection was achieved in all patients. In 33.3% patients, documented complications were tissue granulation and synechia formation in the glottic area. The 5-year recurrence-free survival was 82.1%, the 5-year overall survival rate 97.4%, and the 5-year laryngeal preservation rate 94.8%.

Conclusion: Our clinical data demonstrate that T1b glottic carcinomas with invasion of the AC can be effectively treated with FVPL. The outcome is similar to other methods such as transoral laser microsurgery, supracricoidal partial laryngectomy, and radiotherapy.

ARTICLE HISTORY

Received 29 July 2020

Revised 19 August 2020

Accepted 21 August 2020

KEYWORDS

Squamous cell carcinoma; T1b; glottic larynx; anterior commissure AC; frontolateral vertical partial laryngectomy FVPL

Introduction

Laryngeal carcinoma is the second most common malignant disease of the upper aerodigestive tract. Squamous cell carcinomas make up 85% to 95% of laryngeal malignancies [1]. Glottic carcinoma is the most common type of larynx cancer and often affects the anterior two thirds of the vocal folds. The typical symptoms are hoarseness and dysphagia.



Anterior commissure (AC) involvement occurs in approximately 20% of all glottic carcinomas and is generally associated with a poorer prognosis compared to glottic carcinomas without AC involvement [2]. The tumor can directly invade this area of the thyroid cartilage, because the inner perichondrium is absent here [3].

T1b glottic carcinoma can usually be treated with various larynx-preserving strategies such as transoral laser microsurgery (TLM), radiotherapy (RT), and open partial laryngectomy (OPL) such as frontolateral vertical partial laryngectomies (FVPL), supracricoidal partial laryngectomy with cricohyoideopexy (SCPL-CHP) or cricohyoideoepiglotopexy (SCPL-CHEP), and modified supracricoidal laryngectomy (MSCL) [4]. The diversity in treatment protocols is

due to the unique characteristic of this tumor-stage, namely defining the margin of resection, especially in the AC.

All the aforementioned protocols have advantages and disadvantages. TLM has made great progress in recent years in treating larynx carcinoma, especially early stages of glottic carcinoma [5]. However, here the challenge remains determining the adequate resection in the AC with involvement of Broyles' s tendon, especially in a narrow or prominent larynx [6]. Therefore, about 70% of all recurrences of T1b glottic carcinoma occur in the AC [3]. RT provides an ideal option for patients who cannot undergo surgery and anesthesia. In addition, it can be performed without a tracheotomy. However, the disadvantages of RT lie in its many side effects such as mucositis, laryngeal edema, dysphagia, xerostomia, and an increased risk of cartilage necrosis, as well as the difficulty in detecting recurrences [1]. In addition, the cost of RT is much higher, for example four times higher than the cost of TLM [7].

Frontolateral vertical partial laryngectomies (FVPL), a type of OPL, which was first described by Leroux-Robert in 1956 [8] has evolved over time with many modifications. Leroux-Robert describes the resection of the AC and the

CONTACT Rawad Jadeed  rawjad1@yahoo.com  Department of Otolaryngology, Head and Neck Surgery, Klinikum Bielefeld. Ruhr University Bochum, Teutoburger Straße 50, 33604, Bielefeld, Germany.

*Note: This work was carried out in RWTH Aachen University. Present affiliation: Mr. Rawad Jadeed: Department of Otolaryngology, Head and Neck Surgery, Klinikum Bielefeld, Ruhr University Bochum, Teutoburger Straße 50, 33604 Bielefeld, Germany.

Prof. Dr. med. Martin Westhofen: Head of the Department & Chairman Department of Otorhinolaryngology & Plastic Surgery RWTH Aachen University, Aachen, Germany.

© 2020 The Author(s). Published by Informa UK Limited, trading as Taylor & Francis Group

This is an Open Access article distributed under the terms of the Creative Commons Attribution-NonCommercial-NoDerivatives License (<http://creativecommons.org/licenses/by-nc-nd/4.0/>), which permits non-commercial re-use, distribution, and reproduction in any medium, provided the original work is properly cited, and is not altered, transformed, or built upon in any way.

medial triangle of the thyroid cartilage for the treatment of T1b-T2 glottic carcinoma. Tapia and Leroux-Robert introduced the frontal anterior partial resection for the treatment of T1b and T2 with infiltration of both vocal folds [9]. One of the most important advantages of this method is the safe removal of the tumor under direct vision. Disadvantages, which are not exclusive to this method, include the usually longer hospital stay and the need for a temporary tracheotomy, as well as the complications after surgery such as the formation of granulation polyps in the AC and the consequently worsening of the voice quality [6].

In the context of OPL, some centers perform supracricoid partial laryngectomy with cricohyoideopexy (SCPL-CHP) or cricohyoideopiglottopexy (SCPL-CHEP) to treat T1b-T2 glottic carcinoma with very good oncological results [10] and resect the entire thyroid cartilage as well as the paraglottic area. The cricoid cartilage, hyoid bone, most of the epiglottis, and at least one arytenoid cartilage are preserved [11]. The functional results can be improved by MSCL in selected cases [4]. Here, the two sternohyoid muscles are used to reconstruct the neoglottis. However, both arytenoids must be preserved.

In this study, we focus on FVPL. It is the only protocol we use in our center (certified by the German Cancer Society) to treat early stage T1b glottic carcinomas with invasion of the anterior commissure (AC) [12]. During this operation, the tumor can be removed with an adequate safety margin, provided that the cancer has not extended to the ventricle and paraglottic space. Due to the development of laser microsurgery equipment, FVPL has become less frequently used. However, in our experience, this method allows R0 resection in all T1b stage glottic cancer, especially in cases where the endolaryngeal endoscope adjustment is difficult. It is part of the standardized therapy of T1b glottic cancer in our certified head-neck tumor center. Another advantage is that it can be performed even in underdeveloped countries that do not have advanced TLM techniques [13].

This study retrospectively evaluated whether FVPL is a safe treatment to reduce the recurrence rates in patients with T1b N0 stage glottic cancer. The clinical and histological findings, the occurrence of complications, the 5-year recurrence-free survival, the 5-year overall survival, and the 5-year laryngeal preservation rate were investigated over a period of 14 years, and were compared to results in the literature for other methods.

Patients and methods

Patient inclusion criteria and treatment

We retrospectively analyzed the medical records of patients who presented from 01/2003 to 12/2016 in our head-neck tumor center with stage T1b N0 M0 squamous cell carcinoma of the glottic larynx with involvement of the AC. Our center is certified by the German Cancer Society. The patients had no previous treatment for squamous cell carcinoma stage T1b and were treated in our tumor center exclusively by FVPL. Inclusion criteria for the study were patients with confirmed T1b N0 glottic carcinoma with AC

involvement and FVPL treatment. A standard FVPL was performed according to Tapia and Leroux-Robert [8,9].

Preoperative examination and follow-up

As part of the tumor staging, patients underwent panendoscopy with sampling, computed tomography of the neck and thorax, and sonographic examination of the neck and abdomen.

After presenting the cases to our tumor board, we discussed the diagnosis, our recommendation for FVPL, as well as possible alternative therapies such as laser surgical resection and primary radiation in detail with the patients. The disadvantages and advantages of all methods mentioned above were explained. Based on the experience in our tumor center, we recommend FVPL as the therapy of choice for T1b glottic carcinoma. All 39 patients with T1b glottic carcinoma gave informed consent to the FVPL procedure.

Patients' follow-up was performed monthly in the first year after FVPL, then every 2 months in the second year, every 3 months in the third year, every 4 months in the fourth year, every 6 months in the fifth year, and once a year from the sixth year on. Patients had a complete ENT examination including an echographic examination of the neck and a fiberoptic laryngoscopy for tumor follow-up.

Data analysis

The 5-year recurrence-free survival rate, the 5-year overall survival rate, and the 5-year laryngeal preservation rate were analyzed. The Kaplan Meier survival curves were calculated using the function 'Kaplan-Meier' from the 'Survival' package in SPSS 25.0.0.0. Percentages, means, and standard deviations for were calculated using Excel 2010.

Results

During the 14-year inclusion period, 385 new cases of laryngeal carcinoma were diagnosed in our head-neck tumor center. Of these, 39 patients (10.12%) with T1b N0 glottic carcinoma with AC involvement and FVPL treatment were included in this study. In our center certified by the German Cancer Society, FVPL is the standardized treatment for all patients with this indication. No other treatment options for this stage glottic cancer are performed at our head-neck tumor center. Most patients were male, between 61 and 70 years of age, had been or were smokers, and had moderately differentiated squamous cell carcinoma stage T1b N0 M0. The average stay in the hospital was 14 ± 4 days ($n = 39$). The patients' demographics and characteristics are shown in Table 1.

Surgery to close the tracheotomy fistula was required within 2 weeks after FVPL. The tracheostomy fistula was surgically closed in the operating room in all patients. It was performed under local anesthesia in 16 patients and under general anesthesia in the other 23 patients. In most cases (36/39 patients, 92.3%), it was possible to close the fistula within 30 days after tumor resection. In 20 patients

Table 1. Patients' demographics and characteristics.

Demographic or characteristic	Total number (unless stated otherwise)
Patients included:	39
Male	36 (92.3%)
Female	3 (7.7%)
Mean age at diagnosis	66.2 years (range: 51–83 years)
Age range between 61–70 years	46.2%
Age range between 51–60 years	25.6%
Previous or current smokers	35 (89.7%)
Alcoholic	14 (35.9%)
<i>Concomitant diseases</i>	
High blood pressure	16
Insulin-dependent type II diabetes mellitus	6
Hepatitis C	1
<i>Squamous cell carcinoma stage T1b, N0, M0</i>	
Grade 1 (well differentiated)	1
Grade 2 (moderately differentiated)	33
Grade 3 (poorly differentiated)	5

(51.28%), the period was 7 to 14 days after surgery, while the remaining 16 patients (41.02%) had to be readmitted to the hospital to close the tracheotomy fistula. For the remaining 3 patients (7.69%), the operation to close the fistula was not possible until 32–36 days after FVPL. The average time between the surgery and the tracheostoma closure was 17.3 ± 7.0 days ($n = 39$).

The postoperative follow-up period was 54 to 120 months (mean 79.95 ± 20.59 months, $n = 39$). One month postoperative 34 of 39 of the patients (87.2%) had no complications, while 5 (12.8%) had wound healing problems and 4 (10.3%) developed fistula after closing the tracheotomy fistula. Patients with fistula formation had successful intravenous antibiotic treatment and topical antibiotic wound dressing for a week. Within 2 years after FVPL, granulation tissue formation and synechia were seen in 13 of 39 patients (33.3%). A localized granulation tissue in the area of the former AC was found in 9 patients. In 4 patients, the granulation tissues were more extensive with connections between the two vocal folds in the anterior third in the form of a synechia. These diagnoses were made during regular tumor follow-ups in the first 3 months after the operation. As soon as this diagnosis was established, microlaryngoscopy was used to exclude tumor recurrence and to remove the tissue changes using a CO₂ laser a so-called neoglottic plastic i.e. extension. In patients with synechia, this included synechia cutting. The procedure was sufficient the first time in 6 patients. Unfortunately, 7 patients had neoformation of the granulation tissue and it was necessary to repeat the procedure 3 times within 2 years in 3 patients and 4 times in 4 patients.

After FVPL, patients included in the study complained of hoarseness. However, no one indicated difficulty swallowing. None of the patients needed feeding *via* a nasogastric tube. The patients' clinical data are demonstrated in Table 2.

Tumor recurrence was diagnosed in 5 male and 2 female patients (17.9%). The recurrence occurred in one patient (83 years old) in the first year (at 5 months), in 4 patients in the second year (at 13, 18, 20, and 21 months), and in 2 patients after the third year (at 41 and 52 months) following FVPL. The recurrences were treated using different protocols depending on the location and staging of the recurrence.

Patient 2 who had a total laryngectomy and bilateral modified radical neck dissection (MRND) on both sides and then RCT to treat rpT3, rpN1 tumor recurrence, died 2 years later (65 months after FVPL) from distant lung metastases. Patient 16 had a local recurrence rpT4a 5 months after FVPL. Treatment was tumor debulking using TLM and then radiochemotherapy (RCT). This method was chosen, because this patient refused a total laryngectomy. She died at 18 months of respiratory failure with distant lung metastases. Patient 24 died 108 months after FVPL from bleeding esophageal varices after liver cirrhosis due to chronic hepatitis C. The five-year recurrence-free survival was 82.1% (Figure 1).

The 5-year laryngeal preservation rate was 94.8%, and 5-year overall survival rate in our collective was 97.4% (38 of 39 patients; Figure 2).

Discussion

FVPL, SCPL, TLM, and RT have high success rates in treating early stage T1b glottic carcinomas. The choice of the optimal procedure depends on the patient's condition, the depth of the tumor's infiltration, as well as the center's experience in treating these cases. The specific difficulty of T1b glottic cancer is the infiltration of the AC. This is a negative prognostic factor when RT or TLM is performed [12,14,15]. Therefore, in these cases, even if it causes poorer functional results, it is recommended to resect the corresponding cartilaginous framework, to achieve a tumor free margin, and thus reduce the recurrence rate [10].

Table 3 compares the present study, which uses FVPL to studies employing various methods for the treatment of T1b glottic cancer published between 1997 and 2018 [10,16–21].

The overall or actuarial survival rates range from 78.5 to 91.7% in the published trials. In our study, the 5-year overall survival rate was 97.4%. The 5-year recurrence-free survival rate was 82.1% in our study, which was e.g. 72.4% for TLM [18] or 93.5 to 98.2% for SPCL-CHEP [10,21]. The 5-year recurrence-free survival reported by Giovanni et al. who also used FVPL for stage T1 glottic tumor was 100% and thus higher than our collective [16]. This could be due to the fewer patients with AC involvement reported by

Table 2. Study patients' clinical data (patients with complications and tumor recurrences in bold print).

Patient	Gender	Age at first diagnosis (years)	Complication	Time to recurrence (months)	Stage of recurring tumor	Treatment of recurrence	5-year overall survival	Follow-up (months)
1	male	61	none	18	rpN2b	MRND ^b , RCT ^a	yes	120
2	male	75	none	41	rpT3, rpN1	Total laryngectomy, MRND ^b , RCT ^a	yes	65
3	male	68	Granulation polyp	none	none	none	yes	117
4	male	69	Granulation polyp	none	none	none	yes	114
5	male	82	none	none	none	none	yes	110
6	male	67	none	none	none	none	yes	108
7	male	63	Granulation polyp	52	rpT2	Re-FVPL ^c	yes	105
8	male	57	none	none	none	none	yes	103
9	male	71	Granulation polyp	none	none	none	yes	86
10	male	72	none	none	none	none	yes	90
11	male	73	Granulation polyp	none	none	none	yes	85
12	male	65	none	none	none	none	yes	78
13	male	67	none	none	none	none	yes	81
14	male	81	Synechia	none	none	none	yes	85
15	male	66	none	none	none	none	yes	80
16	female	83	none	5	rpT4a	TLM, RCT ^a	no	18
17	male	58	none	none	none	none	yes	75
18	male	52	none	none	none	none	yes	73
19	male	66	Granulation polyp	none	none	none	yes	70
20	male	63	none	none	none	none	yes	68
21	male	67	none	none	none	none	yes	66
22	male	73	none	none	none	none	yes	75
23	male	59	none	none	none	none	yes	71
24	male	59	Wound healing and fistula	none	none	none	yes	108
25	male	81	Wound healing and fistula	none	none	none	yes	70
26	male	71	Synechia	none	none	none	yes	67
27	male	70	none	none	none	none	yes	68
28	male	60	Wound healing	none	none	none	yes	64
29	male	62	Wound healing and fistula	none	none	none	yes	65
30	male	61	none	none	none	none	yes	90
31	female	65	Wound healing and fistula	none	none	none	yes	89
32	male	81	none	13	rpT1a	TLM	yes	87
33	female	52	none	21	rpT1a	TLM	yes	85
34	male	65	Granulation polyp	20	rpT2	Re-FVPL	yes	81
35	male	51	Synechia	none	none	none	yes	77
36	male	65	Granulation polyp	none	none	none	yes	59
37	male	68	none	none	none	none	yes	56
38	male	59	Granulation polyp	none	none	none	yes	55
39	male	54	Synechia	none	none	none	yes	54

^aTLM: transoral CO₂ laser microsurgery.^bRCT: subsequent radiochemotherapy.^cMRND: bilateral modified radical neck dissection.^dFVPL: frontolateral vertical partial laryngectomy.

Giovanni et al. (98/127; 77%). These patients were not differentiated according to T1 and T2, which could mean that the proportion of their stage T1 patients with AC involvement was even lower than 77%. In contrast, all our patients had AC involvement, which results in a poorer prognosis [2]. Recurrence was not mentioned in the other published studies. The 5-year larynx preservation rate was 92.2 to 100% versus 94.8% in our study. This demonstrates that using FVPL is at least comparable to the other methods. This is confirmed by Giovanni et al. who found a 5-year survival rate of 91% in 62 patients with T1 N0 who were treated using FVPL [16].

When comparing methods directly, neither Marcotullio et al. who compared TLM, SCPL-CHP, and SCPL-CHEP nor Gioacchini et al. who compared RT, TLM, and OPL found one method to be better over the others [17,20]. Gioacchini et al. reported that recurrences were less frequent in patients treated with RT. Taylor et al. found no significant difference between primary RT and TLM for the treatment of T1b glottic carcinoma [22]. The 2-year recurrence-free survival after primary

RT was 85.9%, the 2-year overall survival was 94.8%, and the larynx preservation rate in 2 years was 85.9%. For TLM, the 2-year recurrence-free survival was 88.7%, the 2-year overall survival was 94.1%, and the 2-year larynx preservation rate was 100%. The 2-year recurrence-free survival in our study was 87.2% (34/39 patients; Table 2).

Our data show that FVPL delivers similar results for 5-year recurrence-free survival, 5-year overall survival, and 5-year larynx preservation rate to the other methods used for T1b glottic tumors. Determining the adequate resection in the AC with involvement of Broyles' s tendon, especially in a narrow or prominent larynx is a big challenge [6], and most recurrences of T1b glottic carcinoma occur in the AC [3]. The advantage for resection of T1b tumors is that this method allows R0 resection, especially in cases where the endolaryngeal endoscope adjustment is difficult. The tendency of granulation tissue or synechia to form in the former AC (in our study 33.3%) is a disadvantage of FVPL, which has, however, also been reported for the other methods such as TLM [22].

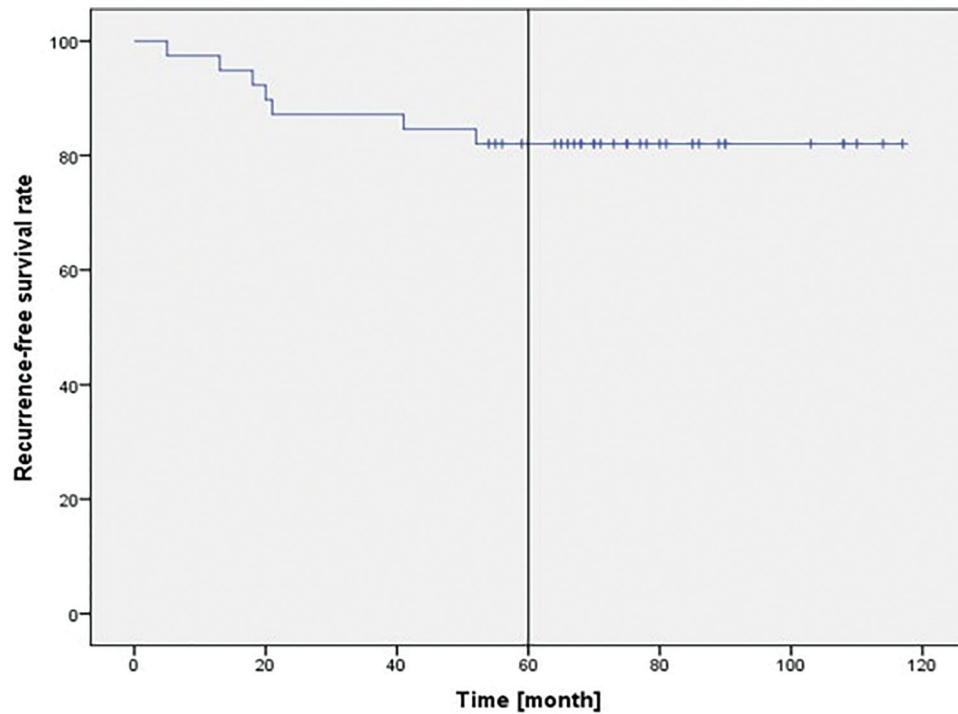


Figure 1. Five-year Kaplan-Meier estimates for recurrence-free survival.

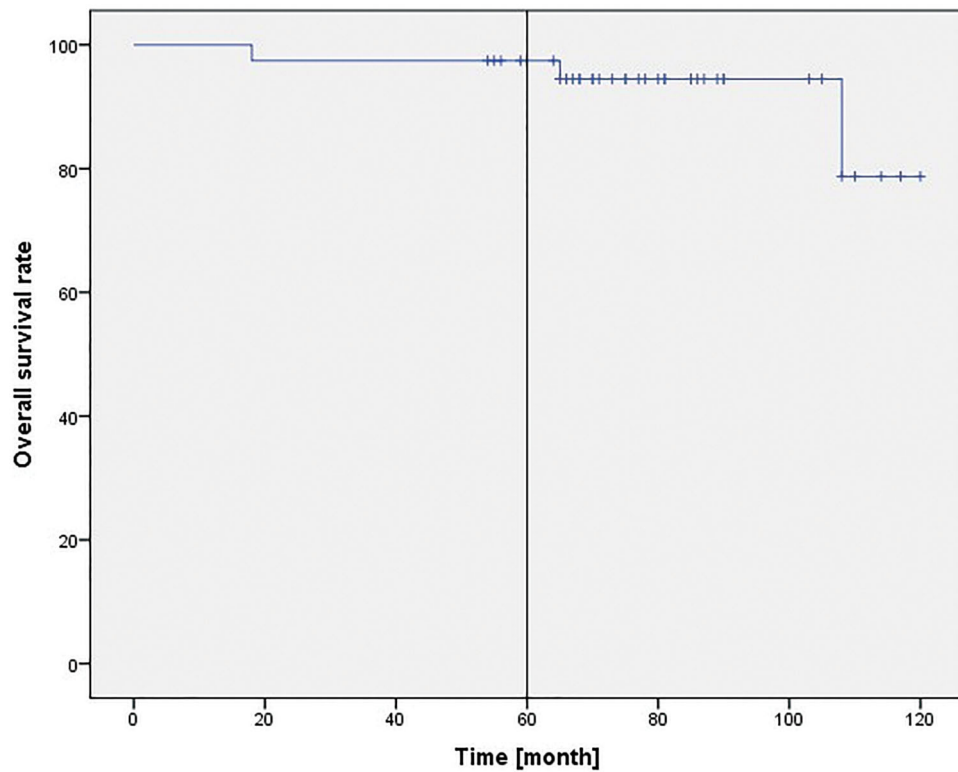


Figure 2. Five-year Kaplan-Meier estimates for overall survival.

Conclusion

The therapy of T1b glottic carcinomas with invasion of the AC is still a big challenge and the treatment method controversial. After analyzing our clinical data, T1b glottic carcinomas can be effectively treated with FVPL resulting in good oncology outcomes comparable to other methods. The

advantages of this surgical procedure are the safety control of the tumor margins, the intraoperative histologically confirmed R0 resection, and the possibility of reconstruction of the glottic larynx. It is also less costly than other methods such as RT. A disadvantage, which is not exclusive to this method, is the need for tracheotomy and the possible

Table 3. Comparison of outcomes of different methods.

Study	Number of patients	Mean age at diagnosis	Method	Inclusion period	TMN Classification	5-year overall survival	5-year recurrence-free survival	5-year larynx preservation rate
Present study retro	39	66.2 years	FVPL	13 years	T1bN0	97.4%	82.1%	94.8%
Laccourreye et al 1997 retro [10]	62	57 years	SPCL-CHEP	10 years	T1-T2N0	86.5%*	98.2%	100%
Giovanni et al 2001 retro [16]	62 65	58 years	FVPL	15 years	T1N0 T2	91% 86%	100% 92.3%	NR
Marcotullio et al 2014 retro [17]	39 14 39	61 years 64 years 62 years	TLM, SCPL-CHP SCPL-CHEP	16 years	T1b	87.2% 78.5% 84.6%	NR	NR
Weiss et al 2017 retro [18]	51	63 years (median)	TLM	20 years	T1b	84.7%	72.4%	92.2%
Song et al 2017 prosp [19]	21	66.8 years	TLM	12 years	T1bN0M0	88%	NR	100%
Gioacchini et al 2017 meta-analysis [20]	387/11 trials 411/6 trials 263/4 trials	NR	RT TLM OPL	Published studies 1988–2016	T1a,T1b	82% 85% 89%	NR	NR
Allegra et al 2018 retro [21]	72 26 AC not involved 46 AC involved	61.5 years	SCPL-CHEP	8 years	T1b-T2	91.7% NR NR	94.4% 96.1% AC not involved 93.5% AC involved	NR 92.2% AC not involved 95.6% AC involved

Retro: retrospective; prosp: prospective; TLM: Transoral laser microsurgery; RT: Radiotherapy; OPL: open partial laryngectomy; SPCL: supracricoid partial laryngectomy; CHP: 14 crico-hyoid-pxy; CHEP: crico-hyoid-epiglottis-pxy; NR: not reported; AC: anterior commissure.

*Actuarial survival instead of overall survival.

formation of synechia and granulation polyps in the reconstruction area of the neoglottis. Further studies are needed to demonstrate which method is best under the individual patient and center conditions.

Acknowledgment

Many thanks and appreciation to Mr. PD Dr. med. Ingo Todt for his participation in reading and evaluating this manuscript.

Disclosure statement

No potential conflict of interest was reported by the author(s).

References

- [1] Dhanisetty S, Johnson J. Tumors of the Larynx. In: Lee KJ, editor. *Essential otolaryngology: head and neck surgery*. New York (NY): The McGraw-Hill Companies; 2012. p. 657–662.
- [2] Rifai M, Khattab H. Anterior commissure carcinoma: I-histopathologic study. *Am J Otolaryngol*. 2000;21(5):294–297.
- [3] Balica NC, Poenaru M, Ștefănescu EH, et al. Anterior commissure laryngeal neoplasm endoscopic management. *Rom J Morphol Embryol*. 2016;57(2 Suppl):715–718.
- [4] Allegra E, Lombardo N, La Boria A, et al. Quality of voice evaluation in patients treated by supracricoid laryngectomy and modified supracricoid laryngectomy. *Otolaryngol Head Neck Surg*. 2011;145(5):789–795.
- [5] Hinni ML, Salassa JR, Grant DG, et al. Transoral laser microsurgery for advanced laryngeal cancer. *Arch Otolaryngol Head Neck Surg*. 2007;133(12):1198–1204.
- [6] Werner JA, Windfuhr JP, et al. Eingriffe an larynx, hypopharynx und trachea [Interventions on the larynx, hypopharynx and trachea]. In: Rettinger A, Hosemann W, Hüttenbrink K B, editors. *HNO-Operationslehre [ENT-Surgery theory]*. Stuttgart (Germany): Thieme; 2018. p. 248–258. German.
- [7] Phillips TJ, Sader C, Brown T, et al. Transoral laser microsurgery versus radiation therapy for early glottic cancer in Canada: cost analysis. *J Otolaryngol Head Neck Surg*. 2009;38(6):619–623.
- [8] Leroux-Robert J. Conservative surgery in cancer of larynx. *Boll Soc Med Chir Cremona*. 1956;10(4):68–76.
- [9] Dietz A. *Kopf-Hals-Tumore; Therapie des Larynx-/Hypopharynxkarzinoms unter besonderer Berücksichtigung des Larynxorganerhalts [Head and neck tumors; therapy of laryngeal/hypopharyngeal carcinoma with special attention to preservation of the larynx organ]*. Bremen (Germany): UNI-MED; 2010. p. 91. German.
- [10] Laccourreye O, Muscatello L, Laccourreye L, et al. Supracricoid partial laryngectomy with cricohyoidoepiglottopexy for "early" glottic carcinoma classified as T1-T2N0 invading the anterior commissure. *Am J Otolaryngol*. 1997;18(6):385–390.
- [11] Laccourreye H, Laccourreye O, Weinstein G, et al. Supracricoid laryngectomy with cricohyoidoepiglottopexy: a partial laryngeal procedure for glottic carcinoma. *Ann Otol Rhinol Laryngol*. 1990;99(6 Pt 1):421–426.
- [12] Yu Y, Lee NY. T1b glottic cancer. In: Dedivitis RA, Peretti G, Haann E, Cernea CR, editors. *Laryngeal cancer: clinical case-based approaches*. New York (NY): Thieme; 2019. p. 20–23.
- [13] André VG, Marco AV. Kulscar. T1b glottic cancer, vertical partial laryngectomy. In: Dedivitis RA, Peretti G, Haann E, Cernea CR. *Laryngeal cancer: clinical case-based approaches*. New York (NY): Thieme; 2019. p. 25–29.
- [14] Maheshwar AA, Gaffney CC. Radiotherapy for T1 glottic carcinoma: impact of anterior commissure involvement. *J Laryngol Otol*. 2001;115:298–301.
- [15] Bradley PJ, Rinaldo A, Suárez C, et al. Primary treatment of the anterior vocal commissure squamous carcinoma. *Eur Arch Otorhinolaryngol*. 2006;263(10):879–888.

- [16] Giovanni A, Guelfucci B, Gras R, et al. Partial frontolateral laryngectomy with epiglottic reconstruction for management of early-stage glottic carcinoma. *Laryngoscope*. 2001;111:663–668.
- [17] Marcotullio D, de Vincentiis M, Iannella G, et al. Surgical treatment of T1b glottic tumor, 10-years follow-up. *Eur Rev Med Pharmacol Sci*. 2014;18(8):1212–1217.
- [18] Weiss BG, Ihler F, Pilavakis Y, et al. Transoral laser microsurgery for T1b glottic cancer: review of 51 cases. *Eur Arch Otorhinolaryngol*. 2017;274(4):1997–2004.
- [19] Song JA, Rigby MH, Trites J, et al. Outcomes of transoral laser microsurgical management of T1b stage glottic cancer. *J Laryngol Otol*. 2017;131(5):433–441.
- [20] Gioacchini FM, Tulli M, Kaleci S, et al. Therapeutic modalities and oncologic outcomes in the treatment of T1b glottic squamous cell carcinoma: a systematic review. *Eur Arch Otorhinolaryngol*. 2017;274(12):4091–4102.
- [21] Allegra E, Saita V, Azzolina A, et al. Impact of the anterior commissure involvement on the survival of early glottic cancer treated with cricohyoidoepiglottopexy: a retrospective study. *Cancer Manag Res*. 2018;10:5553–5558.
- [22] Taylor SM, Kerr P, Fung K, et al. Treatment of T1b glottic SCC: laser vs. radiation- a Canadian multicenter study, Taylor et al. *J Otolaryngol Head Neck Surg*. 2013;42:22.