

## The eye of the takahe, *Porphyrio hochstetteri*

Peter W. Hadden , An E. Pas , Stephanie B. Cassidy & William C. Ober

To cite this article: Peter W. Hadden , An E. Pas , Stephanie B. Cassidy & William C. Ober (2020): The eye of the takahe, *Porphyrio hochstetteri* , New Zealand Journal of Zoology, DOI: [10.1080/03014223.2020.1792945](https://doi.org/10.1080/03014223.2020.1792945)

To link to this article: <https://doi.org/10.1080/03014223.2020.1792945>



© 2020 The Author(s). Published by Informa UK Limited, trading as Taylor & Francis Group



Published online: 09 Aug 2020.



Submit your article to this journal [↗](#)



Article views: 299



View related articles [↗](#)



View Crossmark data [↗](#)

## The eye of the takahe, *Porphyrio hochstetteri*

Peter W. Hadden <sup>a</sup>, An E. Pas<sup>b</sup>, Stephanie B. Cassidy<sup>c</sup> and William C. Ober<sup>d,e</sup>

<sup>a</sup>Department of Ophthalmology, Faculty of Medical and Health Sciences, The University of Auckland, Auckland, New Zealand; <sup>b</sup>Auckland Zoo, Auckland, New Zealand; <sup>c</sup>Cassidy Eye Care, Auckland, New Zealand; <sup>d</sup>Cornell University – Shoals Marine Laboratory, Ithaca, NY, USA; <sup>e</sup>University of New Hampshire – Shoals Marine Laboratory, Durham, NH, USA

### ABSTRACT

We describe the ocular features and normal physiological parameters of the South Island takahe (*Porphyrio hochstetteri*), using three birds. Both eyes face slightly forward such that there is some anatomic possibility of binocular vision but with restriction particularly of the superior and posterior visual fields. The pupil is round under both dim room light and very high illumination and the centre of the pupil is displaced  $\leq 0.5$  mm nasally with regard to the corneal centre. The iris is light brown and has several areas of more prominent vascularity. Their refractive error in the distance by retinoscopy is between 0 and +1 dioptre, although they sometimes accommodate down to -1 dioptre during examination. The average intraocular pressure is  $6.75 \pm 0.88$  mmHg using an iCare tonometer and the average corneal thickness is  $340 \pm 32$   $\mu$ m. The average corneal curvature is  $73.63 \pm 0.82$  dioptres. On B scan the eye appears flattened in its antero-posterior axis; the axial length is  $13.67 \pm 0.61$  mm, the width  $16.36 \pm 0.30$  mm. The distance from the posterior pole of the lens to the retina is  $7.37 \pm 0.26$  mm. The pecten is visible inferiorly but no os opticus can be identified.

### ARTICLE HISTORY

Received 20 April 2020  
Accepted 3 July 2020

### HANDLING EDITOR

James Briskie

### KEYWORDS

South Island takahe;  
*Porphyrio hochstetteri*; eye;  
cornea; ultrasound;  
intraocular pressure; avian;  
refraction; New Zealand; bird

## Introduction

Takahe are a flightless herbivorous rail and, having been presumed extinct in the nineteenth century, were rediscovered in the vicinity of Lake Orbell, Fiordland, New Zealand in 1948. Since then there has been intensive conservation management to rebuild population numbers. Takahe feed on native grasses and ferns in open country (Jamieson 2003) although, prior to human settlement, they were more widespread across New Zealand. Two species have been described, the North Island (*Porphyrio mantelli*) and South Island (*Porphyrio hochstetteri*) takahe, the latter being the only extant species and classified as nationally vulnerable (Robertson et al. 2017). They are also a taonga, a treasured possession, of the Ngāi Tahu iwi.

For most birds, vision would appear to be the 'primary driver of intelligent behaviour' (Martin 2017, p. 27), being particularly required for 'flight, foraging, predator detection, and reproduction' (Martin 2017, p. 187). However, there is significant variability in the

**CONTACT** Peter William Hadden  haddenpeterh211@gmail.com, peterh211@gmail.com

© 2020 The Author(s). Published by Informa UK Limited, trading as Taylor & Francis Group  
This is an Open Access article distributed under the terms of the Creative Commons Attribution License (<http://creativecommons.org/licenses/by/4.0/>), which permits unrestricted use, distribution, and reproduction in any medium, provided the original work is properly cited.

structure and physiology of the vertebrate eye, depending on the characteristics of the animal and its needs. In anurans Huang et al. (2019) found that larger animals generally have larger eyes. This may confer a perceptual advantage because, other things being equal, the larger the entrance pupil, the greater the potential retinal illumination and thus the lower the visual threshold; further, a larger retina allows increased spatial sensitivity (Martin and Osorio 2008). Similarly, compared to other birds the eye of the barn owl *Tyto alba* has a higher proportion of rods versus cones, more forward-facing eyes and a larger cornea to improve its function in a nocturnal environment (Borges et al. 2019). Even two species of the same genus can have significant differences in their sight (Martin 2017, p. 196) and certainly the takahe differs significantly from other extant members of the same genus in non-visual characteristics such as size and flightlessness.

There are large gaps in our knowledge of the visual physiology of individual bird species (Fernández-Juricic et al. 2019), including those of the Order Gruiformes of which takahe are a member, although the visual fields of the blue crane, *Grus paradisea*, were measured by Martin and Shaw (2010). The in vivo anatomy, physiology and optics of the takahe eye has not been previously described.

Given the rarity of the species, which may reduce the opportunity for further study, we wish to report our ocular examination findings in the takahe.

## Materials and methods

We examined the eyes of three live South Island takahe (*Porphyrio hochstetteri*) at Auckland Zoo. One of these birds showed intermittent signs of disorientation and we wished to exclude an ocular cause. The lack of normative data in this species meant that we examined two other apparently normal and healthy birds in order to interpret our findings on the symptomatic bird. On the basis of comparison with the two healthy takahe, ocular examination of the disorientated bird was considered to be within normal limits and we believe that the cause of the disorientation was a previous traumatic brain injury. Therefore we decided to pool the measurements of the three birds for the purposes of this paper.

The eyes were examined as fully as possible while the birds were being restrained and without the use of sedation. External examination was undertaken first and both photographs and video were taken using a smartphone (Samsung S6, South Korea) camera to record the ocular details and to allow ray tracing from the pupil out into visual space to be performed to determine the potential anatomic limits of the visual field. Retinoscopy was performed by an experienced optometrist (SC), the entrance pupil diameter was measured using a ruler held above the eye, in contact with the superior orbital rim, under both relatively low light indoor conditions and then with a bright torch aimed directly at the eye, a permanent record being made by use of the same smartphone. Replay of the video also allowed us to calculate eyelid closure frequency. We then measured the corneal curvature using a KM-500 hand-held keratometer (Nidek, Japan), the intraocular pressure using an iCare ic100 tonometer (iCare, Finland) and the corneal thickness using ultrasound (DGH Pachmate Pachymeter, DGH Technologies, USA). Direct ophthalmoscopy and 15 MHz B-scan ultrasonography (DGH Technologies, USA) using Viscotears Gel (Novartis, Switzerland) as a conductor were then performed by an experienced ophthalmologist (PH).

## Results

The demographic data of the birds examined is presented in Table 1, the disorientated bird being 'Takahe 3'. One was male and the other two female and an exact age was only known in one bird.

We used ray tracing to determine the anatomic constraints on the visual field imposed by the position of the eye within the head (Figure 1). When horizontal, the bill constrains the maximum amount of binocular overlap to  $22.8^\circ$ , although this will vary depending on the posture the bird adopts. We noted that often the takahe adopts a head down posture, which could allow a greater degree of binocular overlap, while at the bill itself the maximum overlap is  $15^\circ$ .

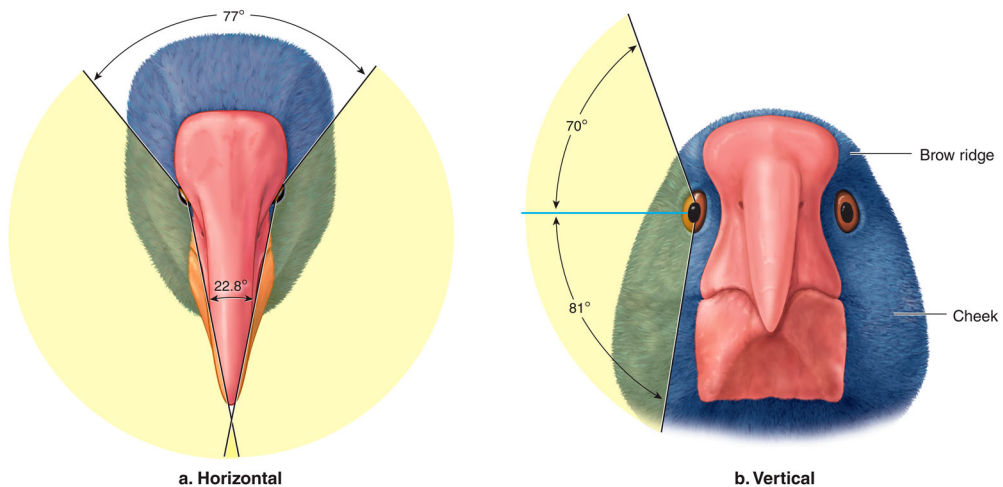
The skull widens behind the eyes such that at angles over  $77^\circ$ , objects behind the bird will not be visible without head movement. There is also a prominent ridge above the eye which will similarly anatomically limit the superior visual field to  $70^\circ$  above the horizon, while the cheek below will limit it to  $81^\circ$  below the horizon.

The membrana nictitans was white but translucent and swept across the eye in a nasal to temporal direction. Reviewing 2 min of video footage, on average it closed once every 2.6 s, varying between 1 per 2 s and 1 per 3.4 s; the nictitans tended to close immediately after a bright light was shone on the eye.

The pupil was round with its centre displaced up to 0.5 mm nasally relative to the centre of the cornea. There was usually a variably delayed (within a few seconds) response

**Table 1.** Demographic data of the study takahe.

	Sex	Age (years)	Weight (kg)
Takahe 1	Male	Approx. 9	2.81
Takahe 2	Female	6.5 years	2.1
Takahe 3	Female	Approx. 8	2.48



**Figure 1.** An artist's rendition of the head of the takahe, based on our observations, images and video as well as images in the public domain. The extent to which the horizontal (Figure 1a) and vertical visual fields (Figure 1b) are constrained by the position of the eye within the head is demonstrated by means of ray tracing.



**Figure 2.** Photograph of the right eye of a takahe, demonstrating the generalised tan colour, round pupil and multiple areas of prominent iris vascularity.

of 1 mm miosis to light exposure with a bright torch from being indoors in a moderately dim room, constricting from approximately 4.5 mm to 3.5 mm. The iris was in all cases a tan brown with several areas of prominent vascularity evenly scattered around the surface (Figure 2).

The fundus had a uniform dull orange colour and only the observer's (PH) approximate refractive error ( $-1D$ ) was required in the direct ophthalmoscopy to clearly visualise the fundus. A darker pecten was just visible inferiorly but a good view of the inferior periphery capable of providing a reliable description was not possible.

The measurements obtained with retinoscopy, keratometry, tonometry, pachymetry and ultrasonography are presented in Table 2.

**Table 2.** Measurements of anatomic and physiological parameters obtained with retinoscopy, keratometry, tonometry, pachymetry and ultrasonography.

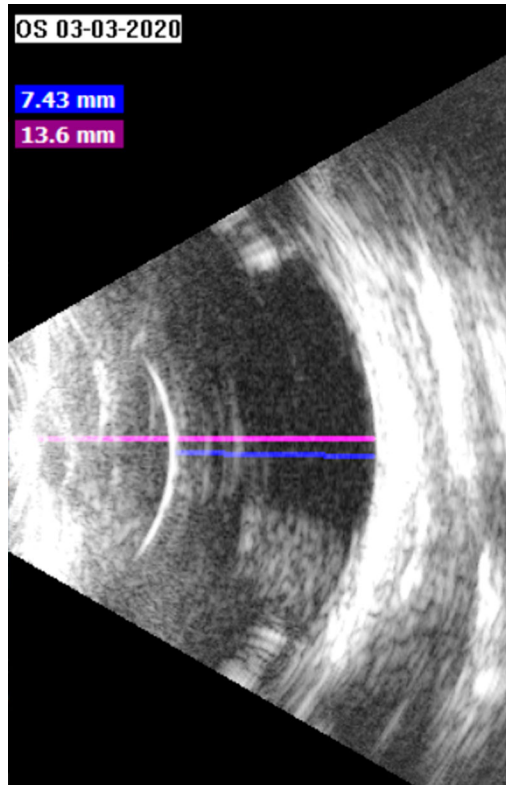
	Retinoscopic refraction (dioptries)	Anterior corneal curvature (dioptries)	IOP (mmHg)	Corneal thickness ( $\mu\text{m}$ )	Axial length (mm)	Posterior lens to retina (mm)	Width of eye (mm)
Takahe 1 RE	+1	N/O	5	335	13.4	7.36	16.7
Takahe 1 LE	+1 to 0	N/O	7.5	344	12.88	7.29	16.36
Takahe 2 RE	0 to $-1$	$74.25 \times 72.75 @12$	7	$448^* / 290$	14.72	6.9	16.25
Takahe 2 LE	0 to $-1$	N/O	7	377	13.87	7.6	15.84
Takahe 3 RE	+1 to 0	$72.0 \times 72.50 @15$	7	$442^*$	13.54	7.62	16.43
Takahe 3 LE	0 to $-0.5$	$72.25 \times 72.50 @94$	7	354	13.6	7.43	16.56
Average		72.63	6.75	340	13.67	7.37	16.36
Standard deviation		0.82	0.88	32	0.61	0.26	0.30

\*These values included the thickness of the nictitating membrane and are not included in the calculation of average and standard deviation.

N/O – not obtainable.

Not all measurements were possible in all eyes of all birds. In two cases, the nictitans was initially unable to be moved away from underneath the corneal pachymeter, although in one case (takahe 2 right eye) a second measurement was possible that then excluded the thickness of the nictitans. However, it was also the thinnest measurement recorded and this may suggest an anomalous result.

On B-scan ultrasonography the eye appeared flattened in its anteroposterior axis such that the width exceeded the axial length (Figure 3). The pecten was visible inferiorly and the largest measurements obtainable of this structure, given that in most slices it was not usually visualised in its entirety, were 4.34 mm in height above the retina and 5.5 mm dorsoventrally, its dorsal end being approximately 3.5 mm ventral to the anatomic posterior pole of the eye. No os opticus as described by Tiemeier (1950) was identifiable on B scan in any bird as there was no specific acoustic shadow despite high echogenicity of the posterior pole generally. 15 MHz B scan ultrasonography is unable to show the details of the anterior segment; at most, in some slices the anterior pole of the lens can be tentatively identified and from this we estimate the lens to be 3.05 mm thick.



**Figure 3.** Screenshot of 15 MHz B scan ultrasound of Takahē 3's left eye. The posterior lenticular surface, retina and pecten are all clearly visible and the anteroposterior flattening of the globe apparent. Note that the anterior segment is poorly visualised, as is normal with a 15 MHz probe. The yellow line indicates an axial length measurement while the purple line is the distance from the posterior lens capsule to the retina. At most, an estimation of the anterior lens surface position is possible in a few images.

## Discussion

The visual fields of many different bird species have been directly measured (Martin 2017), most often with the technique that Martin and Young (1984) described, using a direct ophthalmoscope mounted on a perimeter to observe the angle through which the red reflex is visible, with the head fixed. We were unable to replicate this technique but, given the importance of the visual field to an animal's perception, instead estimated the anatomic limits to the visual field imposed by the position of the eye within the head. Clearly this is likely to exceed the actual visual field when the eye is primary position, given that in all species the retina does not extend around the whole posterior portion of the globe, in the periphery retinal sensitivity decreases and at the edge of the cornea and lens total internal reflection will take place. However, our estimates may be a more reasonable representation of the visual field possible with the addition of eye movement and the maximum degree of overlap that shape of the head allows (22.8° in the horizontal plane) is consistent with Martin's (2007) statement that 'in species that use vision to guide the taking of food or prey items in the bill or with the feet, a frontal binocular field with a maximum width of 20–30° occurs'. It is also of the same order of magnitude as the 23° maximum binocular overlap of the blue crane *Grus paradisea*, another gruiform (Martin and Shaw 2010), although whether birds use this overlap to allow stereoscopic vision is uncertain (Martin 2009). The area of visual awareness may be further increased by head movements (Martin and Osorio 2008).

Almost all birds have been described to have round pupils in all degrees of miosis and mydriasis (Martin 1999) and the takahe is not an exception in this regard. The error in the measurement of the pupil size is likely to be in the order of 0.5 mm, given that the ruler was placed above the eye and against the birds' feathers rather than directly on the eye. Further, in birds the pupil is under voluntary control (Coli et al. 2016) and thus the pupillary responses might be less predictable than in mammals where the iris contains smooth rather than skeletal muscle fibres, although we did find that shining a bright light on the eye caused a repeatable 1 mm of miosis.

Non-cycloplegic retinoscopy, using the red reflex from the retina to objectively determine the refractive state of an eye without the requirement for patient co-operation, can be challenging but SC was convinced that these takahe were most likely mildly hyperopic in the distance, with a refraction between 0 and +1 dioptres, although they often tended to accommodate during retinoscopy to become emmetropic or mildly myopic. Given that accommodation in all described vertebrates makes one more myopic rather than more hyperopic, if we assume that these takahe are representative of their species then these birds should be able to focus clearly on a distant target.

The corneal thickness measurements are likely subject to increased error above that which would be normal for a human, as it was difficult to obtain a directly perpendicular reading at the exact centre of the cornea due to movement of the bird despite being restrained, and in two cases the membrana nictitans was unable to be extricated from beneath the probe.

B scan ultrasound was easy to perform and gave an excellent image of the posterior lens and retina; it was harder to accurately measure the maximum width of the eye because both sides of the eye only just came into the field of view of the probe at the same time, and B scan measurements are not as accurate at the edge of the scan; it is quite

possible that our measurements of width are an underestimate, but certainly the eyes are not spherical but rather flattened front to back.

The axial length measurements are subject to inaccuracy because the anterior segment is difficult to image with a 15 MHz probe and it is not possible to identify the anterior corneal surface. However, when the same ultrasound is used on a human (PH) with an axial length of 25.21 mm right and 24.87 mm left measured using an IOLMaster 700 (Zeiss, Germany), the ultrasound measures an axial length of 25.77 mm right and 24.31 mm left. In both cases the cornea was in direct contact with the probe, with the possible exception of the (very thin) nictitating membrane sometimes sliding under the probe in the takahe. Although there is clearly a measurement error, the axial length measurement is unlikely to be more than 1 mm.

Given an average axial length of 13.67 mm, the anterior focal length of the takahe eye is 8.2 mm, assuming the focal length of the eye is 60% of the axial length as in other vertebrates (Martin 1982). With a maximum pupil diameter of 4.5 mm, the minimum f-number of the eye, a measure of the brightness of an image on the retina, is 1.8. This is similar to the minimum f-number in a variety of species, such as the Humboldt penguin *Spheniscus humboldti* at 2.34 (Martin and Young 1984), the tawny owl *Stix aluco* at 1.3 and *Homo sapiens* at 2.13 (Martin 1982). Hence the takahe eye would appear to be comparable to others in terms of its light gathering capacity.

## Conclusions

Walls (1942) commented that almost all birds have relatively large eyes for their size and, in most birds, the axis is the shortest dimension, such that the eye has a flattened shape. Both these comments are true of the takahe also, when compared with mammals. In particular, the flattened shape of the eye allows a relatively large aperture for the size of the eye, increasing the f-number to a value comparable to other vertebrates and thus increasing retinal sensitivity as well as affording a higher diffraction limit to spatial sensitivity (Martin and Osorio 2008). The approximately emmetropic refraction, typical of most birds but a subject of debate in some aquatic species such as penguins (Martin and Young 1984), will serve to spot predators at distance but the anatomy of the head precludes an 'all-around' visual field in the absence of head movement.

Further work on the anatomy and histology of the takahe eye, as well as behavioural measurements of its visual acuity, colour perception and other visual parameters would no doubt be revealing, as would comparison to the extant, flighted members of the genus *Porphyrio*, in New Zealand represented by the pukeko *Porphyrio melanotus*, which is derived from a later lineage, first appearing in New Zealand after Polynesian settlement, around AD 1500 (Trewick 1997; Garcia-R and Trewick 2015). The latter might help identify features that are changed in birds that lose the ability to fly as some restrictions on ocular anatomy, such as the weight, would be removed once flightlessness became established. Perhaps a larger eye and improved visual performance might be possible by losing the requirement for flight.

## Disclosure statement

No potential conflict of interest was reported by the author(s).



## ORCID

Peter W. Hadden  <http://orcid.org/0000-0003-0352-5286>

## References

- Borges R, Fonseca J, Gomes C, Johnson WE, O'Brien SJ, Zhang G, Gilbert MTP, Jarvis ED, Antunes A. 2019. Avian binocularity and adaptation to nocturnal environments: genomic insights from a highly derived visual phenotype. *Genome Biology and Evolution*. 11:2244–2255.
- Coli A, Stornelli MR, Barsotti G, Ceccherelli R, Giani E, Lenzi C, Giannessi E. 2016. Morphological study of the iris musculature in diurnal and nocturnal raptors. *International Journal of Morphology*. 34:503–509.
- Fernández-Juricic E, Baumhardt PE, Tyrrell LP, Elmore A, DeLiberto ST, Werner SJ. 2019. Vision in an abundant North American bird: the red-winged blackbird. *The Auk: Ornithological Advances*. 20:1–27.
- Garcia-R JC, Trewick SA. 2015. Dispersal and speciation in purple swamphens (Rallidae: *Porphyrio*). *The Auk*. 132:140–155.
- Huang CH, Zhong MJ, Liao WB, Kotrschal A. 2019. Investigating the role of body size, ecology, and behavior in anuran eye size evolution. *Evolutionary Ecology*. 33:585–598.
- Jamieson IG. 2003. No evidence that dietary nutrient deficiency is related to poor reproductive success of translocated takahe. *Biological Conservation*. 115:165–170.
- Martin GR. 1982. An owl's eye: schematic optics and visual performance in *Strix aluco*. *Journal of Comparative Physiology A*. 145:341–349.
- Martin GR. 1999. Eye structure and foraging in king penguins *Aptenodytes patagonicus*. *Ibis*. 144:444–450.
- Martin GR. 2007. Visual fields and their functions in birds. *Journal of Ornithology*. 148(Suppl 2): S547–S562.
- Martin GR. 2009. What is binocular vision for? A bird's eye view. *Journal of Vision*. 9(11):14, 1–19.
- Martin GR. 2017. *The sensory ecology of birds*. Oxford: Oxford University Press.
- Martin GR, Osorio D. 2008. Vision in birds. In: Basbaum AI, Kaneko A, Shepherd GM, Westheimer G, editors. *The senses: a comprehensive reference*. Amsterdam: Academic Press; p. 25–52.
- Martin GR, Shaw JM. 2010. Bird collisions with power lines: failing to see the way ahead? *Biological Conservation*. 143:2695–2702.
- Martin GR, Young SR. 1984. The eye of the humboldt penguin, *Spheniscus humboldti*: visual fields and schematic optics. *Proceedings of the Royal Society B: Biological Sciences*. 223(1231):197–222.
- Robertson HA, Baird K, Dowding JE, Elliott GP, Hitchmough RA, Miskelly CM, McArthur N, O'Donnell CFJ, Sagar PM, Scofield RP, et al. 2017. *Conservation status of New Zealand birds, 2017*. Wellington: Department of Conservation. New Zealand Threat Classification Series 19.
- Tiemeier OW. 1950. The os opticus of birds. *Journal of Morphology*. 86(1):25–46.
- Trewick SA. 1997. Flightlessness and phylogeny amongst endemic rails (Aves: Rallidae) of the New Zealand region. *Philosophical Transactions of the Royal Society B: Biological Sciences*. 352(1352):429–446.
- Walls GL. 1942. *The vertebrate eye and its adaptive radiation*. New York, NY: Hafner Publishing.