

Neurosurgical applications of tractography in the UK

Sebastian M. Toescu , Patrick W. Hales , Martin M. Tisdall , Kristian Aquilina & Christopher A. Clark

To cite this article: Sebastian M. Toescu , Patrick W. Hales , Martin M. Tisdall , Kristian Aquilina & Christopher A. Clark (2020): Neurosurgical applications of tractography in the UK, British Journal of Neurosurgery, DOI: [10.1080/02688697.2020.1849542](https://doi.org/10.1080/02688697.2020.1849542)

To link to this article: <https://doi.org/10.1080/02688697.2020.1849542>



© 2020 The Author(s). Published by Informa UK Limited, trading as Taylor & Francis Group.



[View supplementary material](#)



Published online: 14 Dec 2020.



[Submit your article to this journal](#)



Article views: 286



[View related articles](#)



[View Crossmark data](#)

Neurosurgical applications of tractography in the UK

Sebastian M. Toescu^{a,b} , Patrick W. Hales^b, Martin M. Tisdall^a, Kristian Aquilina^a and Christopher A. Clark^b

^aDepartment of Neurosurgery, Great Ormond Street Hospital, London, UK; ^bDevelopmental Imaging and Biophysics Section, UCL GOS Institute of Child Health, London, UK

ABSTRACT

Introduction: Tractography derived from diffusion MRI can provide important insights into human brain microstructure *in vivo*. Neurosurgeons were quick to adopt the technique at the turn of the century, but it remains plagued by technical fallibilities. This study aims to describe how tractography is deployed clinically in a modern-day, public healthcare system, serving as a snapshot from the 'shop floor' of British neurosurgical practice.

Methods: An 11-question survey was circulated to the mailing lists of the Society of British Neurological Surgeons and British Neurosurgical Trainees' Association, including questions on frequency, indication, tracts reconstructed, specific details of techniques used and personnel by whom it was performed, and a free-text section on the limitations of tractography.

Results: 58 survey responses were received, covering all 40 neurosurgical units in the UK and Ireland. Overall, responses were received from neurosurgeons at 36 units (90.0%) stating tractography was in use at that unit. 74.1% of the responses were from Consultants. The most common indication for tractography was in tumour resection. It was most commonly performed by neuroradiologists or imaging scientists. 75.9% of respondents stated that the model used to process tractography was the diffusion tensor (DTI). Many respondents were unaware of which algorithm (74.1%) or software tools (65.6%) were used by the operator to produce tractography visualisations. The corticospinal tract was the most commonly reconstructed tract. The most commonly cited limitations of the technique were perceived inaccuracy and brain shift.

Conclusions: In this UK-based survey of practising neurosurgeons, we show that 90% of neurosurgical units in the UK and Ireland use tractography regularly; that predominantly DTI-based reconstructions are used; that tumour resection remains the most frequent use of the technique; and that large tracts such as the corticospinal tract are most frequently identified. Many neurosurgeons remain unfamiliar with the underlying methods used to produce tractography visualisations.

ARTICLE HISTORY

Received 18 February 2020
Accepted 6 November 2020

KEYWORDS

MR tractography; diffusion tensor imaging; diffusion weighted imaging; image-guided surgery

Introduction

Tractography derived from diffusion MRI (dMRI) data is a powerful technique enabling non-invasive visualisation of structural brain connections *in vivo*. dMRI uses specialised MRI sequences sensitive to the random motion of water molecules by diffusion. Mathematical models applied to the data on a voxel-wise basis relate the measured dMRI signal to local fibre orientations. The fundamental assumption that the diffusion of water is less hindered along the axis of an axon than across it, gives a directionality (or anisotropy) to the measured signal. The canonical model of dMRI signal is the diffusion tensor,¹ and it is from this that the term diffusion tensor imaging (DTI) stems. However, the inability of the tensor model to resolve crossing fibres within a voxel – a situation which is widespread in white matter² – has motivated the development of more advanced models such as constrained spherical deconvolution (cSD).³ Computer algorithms reconstruct streamlines based on voxel-wise principal directions of diffusion, resulting in tractography reconstructions which approximate the position of white matter pathways from known anatomical priors.


One of the foremost clinical applications of tractography is in neurosurgery where it is used as an adjunct to improve pre-operative planning and intraoperative navigation for neurosurgeons,⁴ with indications ranging from deep brain stimulation⁵ to intrinsic brain tumour resection.⁶ The use of tractography was recently endorsed in the United Kingdom's first NICE Guidelines for Brain Tumours and Metastases in Adults.⁷

The acquisition and processing of dMRI data to generate tractography is complex, and considerations of model choice and algorithm are not traditionally within the purview of neurosurgeons. This study aims to assess how tractography is deployed clinically in a modern-day, public healthcare system, serving as a snapshot from the 'shop floor' of British neurosurgical practice.

Methods

The survey was drafted by the authors and internally piloted. Following this, the survey was approved by the SBNS Academic Committee before being sent to the mailing lists of the Society of British Neurological Surgeons (SBNS) and British Neurosurgical

CONTACT Sebastian M Toescu  sebastian.toescu@ucl.ac.uk  Department of Neurosurgery, Great Ormond Street Hospital, London WC1N 3JH, UK

 Supplemental data for this article can be accessed [here](#).

© 2020 The Author(s). Published by Informa UK Limited, trading as Taylor & Francis Group.

This is an Open Access article distributed under the terms of the Creative Commons Attribution-NonCommercial-NoDerivatives License (<http://creativecommons.org/licenses/by-nc-nd/4.0/>), which permits non-commercial re-use, distribution, and reproduction in any medium, provided the original work is properly cited, and is not altered, transformed, or built upon in any way.

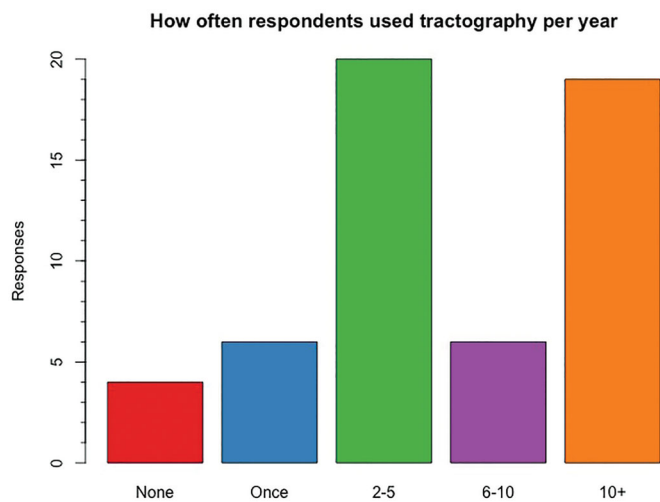


Figure 1. Barplot showing frequency of tractography use amongst neurosurgeons.

Trainees' Association (BNTA) as a Google™ Form and .pdf document. Data collection period was from 15th October 2018 – 31st December 2018. A £50 gift voucher prize draw was used as an incentive. Follow-up emails were sent to Consultants at units from which no response was received to the initial mailout.

The survey consisted of eleven questions regarding the use of tractography: frequency, clinical setting, indication, tracts reconstructed, specific details of techniques used and personnel by whom it was performed, additional neurosurgical intraoperative adjuncts employed were surveyed, as well as a final question with a free-text answer on the limitations of tractography. Additionally, 2 demographic data points were collected on the Grade of respondents and their neurosurgical unit. Descriptive statistical analysis was performed in R.⁸ The survey was designed, and is reported herein, according to published good practice guidelines.⁹ The survey is attached to this paper as [Supplementary File 1](#).

Results

58 survey responses were received, with at least one response from each of the 40 neurosurgical units in the UK and Ireland. Overall, responses were received from neurosurgeons at 36 units (90.0%) stating tractography was in use at that unit. 43 responses (74.1%) were from Consultants, the remainder from Registrars and Fellows. The majority of respondents were from centres undertaking adult neurosurgery only (35/58, 60.3%); 6 respondents (10.3%) were from paediatric centres, whilst the remaining 17 (29.3%) worked in a mixed adult/paediatric setting.

Figure 1 shows data on how often respondents used tractography per year. This shows a bimodal frequency distribution with 32.7% of respondents (19/58) using tractography on a regular basis, at more than ten times per year; and a further 34.5% (20/58) using tractography between two and five times per year. The most common neurosurgical indication for tractography was in tumour resection, with 44/58 respondents (75.9%) deploying tractography in this setting. Other indications for tractography described in the survey are shown in Figure 2. The majority of respondents used tractography for both preoperative planning and intraoperative navigation (32/59, 54.2%); 17/59 (28.8%) used tractography solely for preoperative planning, and a single

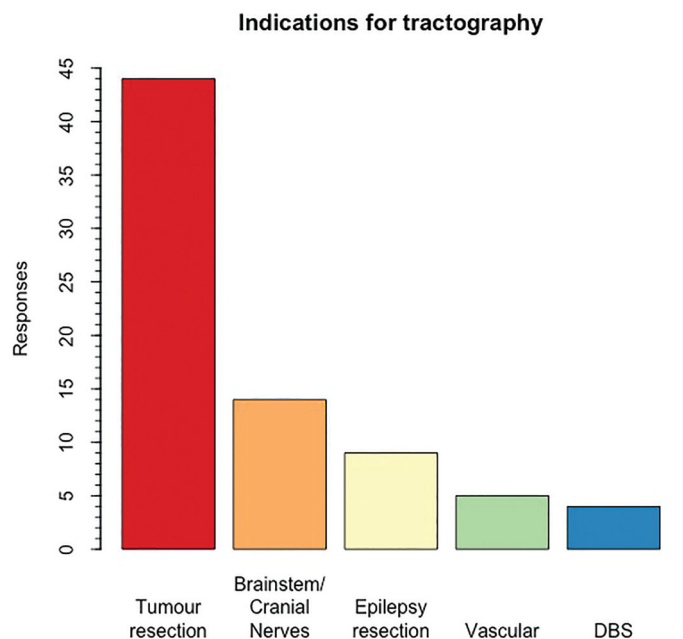


Figure 2. Barplot showing indications for tractography. DBS: deep brain stimulation.

respondent stated they used tractography purely intra-operatively.

The tractography reconstructions were performed by an array of different personnel, as shown in Figure 3. Most commonly, it was undertaken by neuroradiologists (27/58, 46.6%), then imaging scientists/medical physicists (21/58, 36.2%), or by neurosurgeons themselves (19/58, 32.7%); a single respondent stated that tractography was performed by neuroradiography colleagues at their unit.

Tractography methodology

The modelling applied to dMRI data reported by most respondents was the diffusion tensor model (44/58, 75.9%), with a minority using cSD (4/58, 6.90%); the remaining 10 respondents (17.2%) did not know which model of dMRI signal was used in tractography reconstructions at their unit. With regards to the algorithm used to reconstruct tractography streamlines, 74.1% (43/58) of respondents were unaware whether a probabilistic or deterministic algorithm was used at their unit. Similarly, 65.6% (38/58) of respondents were unaware of which software tools were used by the operator to produce tractography results. Other respondents used BrainLab (10/58, 17.2%) or Medtronic (4/58, 6.90%) software systems for tractography; whilst 10.3% (6/58) used alternatives – proprietary (such as Nordic NeuroLab) or open-source (FSL, MRtrix) – solutions.

The tracts most frequently reconstructed are shown in Figure 4. The 'other' category corresponds to one report of using tractography to derive thalamic segmentation for deep brain stimulation.

Limitations of tractography

Tractography is frequently employed as part of a wide array of intraoperative technologies in neurosurgery. Figure 5 shows responses to the question 'Do you use any other adjuncts alongside tractography?'. Neurophysiological monitoring and awake

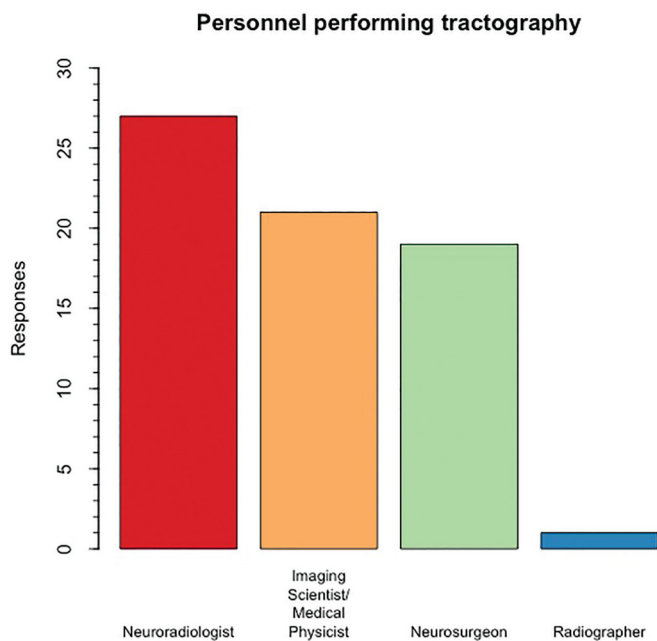


Figure 3. Barplot showing personnel performing tractography across units surveyed.

craniotomy were the most commonly used surgical adjuncts, followed by intraoperative ultrasound and fluorescence guidance. Responses were received from all 6 of the UK centres with a currently active intraoperative MRI (iMRI) suite. 55/58 respondents (94.8%) stated they used more than one adjunct. The 'other' category included fMRI and transcranial magnetic stimulation.

Free-text answers were provided for the section on limitations of tractography. These answers were broadly categorised into ten themes as shown in Figure 6. The most commonly described limitations of the technique were perceived inaccuracy, and brain shift following craniotomy and CSF release. Several respondents raised issues with the nature of tractography being approximate, based on 'statistical' algorithms, leading to deficiencies in reflecting the underlying anatomical structures. One respondent characterised this as 'the fantasy of tractography'. Difficulties were also raised with regards to inter-operator variability, particularly with regard to seed region-of-interest placement. Problems with regards to spatial resolution and 'failure to recognise false positive results' were also mentioned.

Finally, the most numerous category overall seemed to be logistical difficulties in deploying tractography on a routine basis. These included general 'institutional resistance in its acceptance' and a lack of 'time for sequence acquisition'. Shortages in experienced personnel may lead to difficulties in 'getting [tractography] put together by neuroradiology'; tractography, it seems, is 'not part of [a] routine radiology service'.

Discussion

This is the first cross-sectional study of practising neurosurgeons specifically tailored towards the use of diffusion tractography for neurosurgical indications. Using a nationwide survey-based approach to survey all neurosurgical units in the UK and Ireland, we show that while tractography is a tool used in 90% of centres, there is a degree of unfamiliarity with the underlying models and methods used to produce tractography visualisations. In addition, responses to the question on limitations of tractography confirm many long-held criticisms of the technique, but also demonstrate

that some of the biggest barriers to its widespread use are, in fact, logistical.

Since the development of the earliest tractography algorithms around the turn of the century,^{11,12} the majority of the published literature using the technique has been from the neuroscience community, using tractography to probe the microstructure and connectivity patterns of the human brain. In tandem with this, its use has been widely adopted by the neurosurgical community. The earliest reported neurosurgical use of tractography was for pre-operative planning of brain tumour resection.¹³⁻¹⁵ The results of this survey show that tumour resection remains the most common indication for tractography, with 80% of neurosurgeons using it in this context. Level I evidence for the use of tractography in tumour resection is lacking, although a single randomised controlled trial showed that the use of intra-operatively co-registered FA maps to the neuronavigation workstation improved extent of resection, performance status and survival in high-grade gliomas.¹⁶ The development of a gold standard evidence base for tractography in the resection of brain tumours is challenging, as putative RCTs comparing resection with tractography to resection alone will face significant ethical hurdles due to a lack of clinical equipoise.

Epilepsy surgery in adults with refractory temporal lobe epilepsy is another typical indication for intraoperative tractography. Surgical damage to Meyer's loop, and subsequent post-operative visual field deficit, can be reduced using tractography of the optic radiation corrected for brain shift using iMRI.¹⁷ Tractography of the brainstem and cranial nerves is able to depict individual cranial nerves, such as the facial nerve during vestibular schwannoma resection;¹⁸ this was the second most widely-reported indication in this survey. The use of tractography in functional neurosurgery is emerging as a more novel indication. Its utility in fine-tuning pre-operative planning for electrode implantation in Parkinson's disease, for example, is becoming increasingly reported.^{5,19}

The utility of intraoperative adjuncts can be improved by synergistic combinations. This study shows that tractography is often used alongside other adjuncts, most commonly neurophysiological monitoring and awake craniotomy. These adjuncts provide an indication of brain function intra-operatively, and provide a useful compliment to the structural information afforded by diffusion tractography. All but 3 respondents reported using more than one intraoperative adjunct in addition to tractography. Their use is determined by surgeons' (and centres') familiarity with the techniques, and availability of more expensive infrastructure such as iMRI. Brain shift is a commonly reported limitation of tractography. One of the main benefits of iMRI is the ability to correct tractographic reconstructions of relevant white matter pathways for brain shift by updating pre-operative images during surgery.^{20,21} A small number of FDA-approved deterministic DTI methods are able to rapidly reconstruct plausible streamlines 'on the fly' during an operation. Higher-order models such as cSD have been shown to be more accurate than DTI,²² and improve safety margins which are often finely balanced in neurosurgical procedures. However, the refined modelling and streamline estimation using such methods are computationally intensive, often running over several hours on dedicated hardware. Furthermore, the dMRI signal may be impaired by susceptibility artefacts introduced during surgery such as at air-water-brain interfaces. Further work in the areas of pulse sequence development (such as high angular resolution diffusion imaging) and iMRI workflow will need to address these

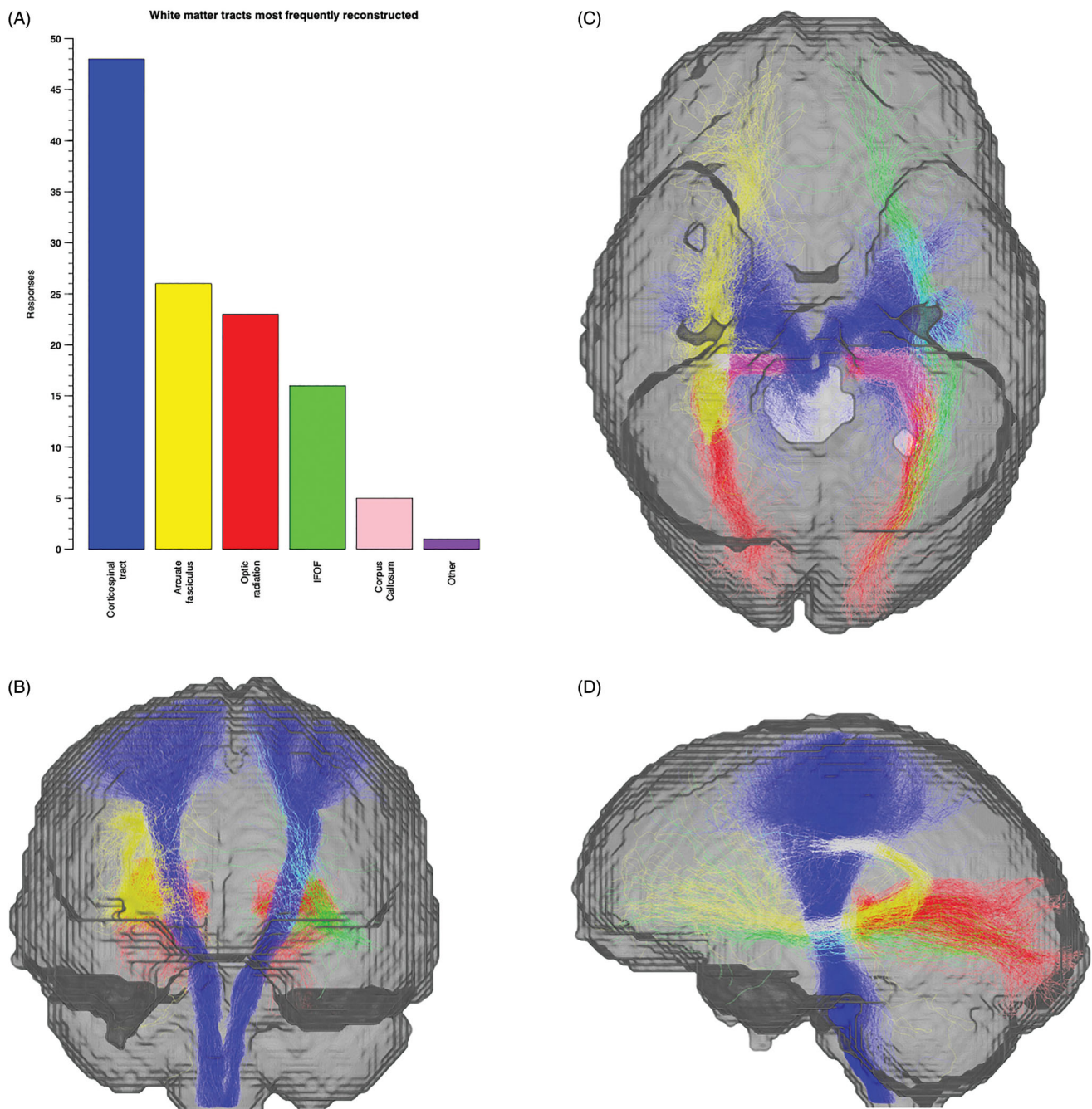


Figure 4. (A) Barplot showing white matter tracts most frequently reconstructed from survey responses. (B) frontal, (C) inferior, and (D) left views of the corticospinal tracts, optic radiations, left inferior fronto-occipital fasciculus and right arcuate fasciculus, coloured according to bars in A (corpus callosum and 'other' tractograms not shown for clarity). Tractography reconstructions performed in a healthy volunteer at our institution using constrained spherical deconvolution modelling of multi-shell diffusion MRI data in *MRTrix*,¹⁰ displayed in a 'glass brain' mask.

constraints to deliver on the promise of flexible yet accurate intra-operative tractography, which has so far proved elusive.²³

A key finding from this survey is the logistical difficulty encountered by many units in deploying tractography. Reconstructions are most commonly performed by neuroradiologists or imaging scientists and medical physicists, usually with an affiliation to an academic centre. Not all neurosurgical units have such an arrangement, leaving busy neurosurgeons to perform tractography alongside clinical duties; one respondent stated they do not have time to do so. Neuroradiology services are instrumental in supporting the deployment of tractography in neurosurgery, although judging from some responses above, extra support is sometimes still needed.

The majority of neurosurgeons surveyed were unaware of the modelling, algorithm and software used to create tractography visualisations. Whilst in itself this is understandable, it is important to be aware that the choice of model used will have a significant impact on the resulting reconstruction of a given tract, and the degree of confidence which can be placed on the results. Equipping neurosurgeons with the tools to perform their own tractography reconstructions may help reduce inter-operator variability, which is perceived as one of the main limitations of tractography. The same tract can be reconstructed using a wide array of user-defined options, from seeding of regions of interest through to thresholding (akin to 'windowing') of the generated tractogram. Concerns over the highly variable results of

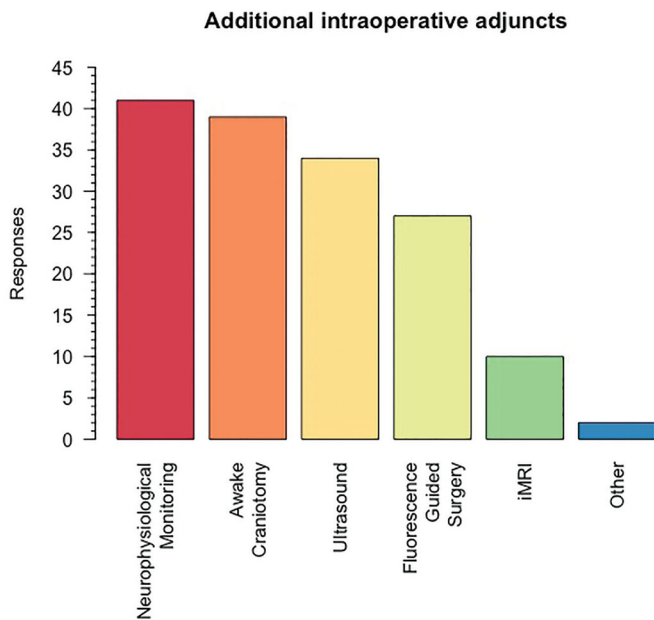


Figure 5. Barplot showing intraoperative adjuncts use across units surveyed.

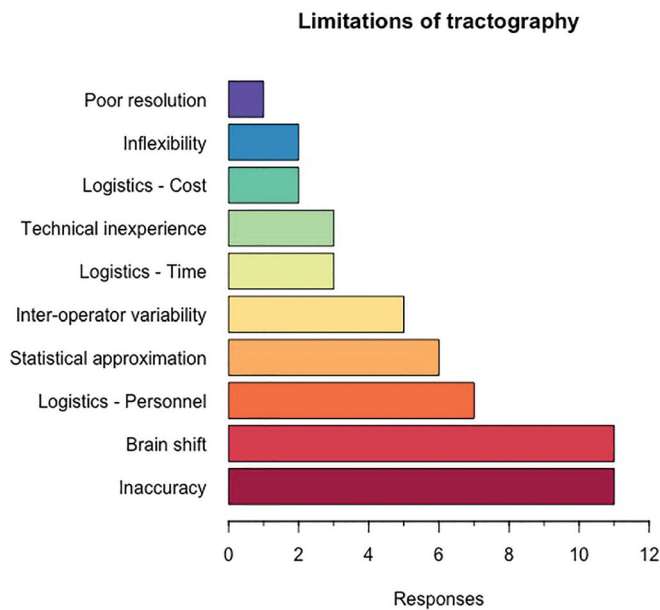


Figure 6. Limitations of tractography described by respondents, categorised based on free-text answers.

tractography and the lack of standardisation in the field have been noted by the tractography community.²⁴ In our unit, we have adopted Standard Operating Procedures as a means of applying a set methodology to reconstruct a given tract, regardless of the surgeon or operative indication.

The authors recognise the limitations inherent in the survey methodology. Responses may have been preferentially elicited from ‘early adopters’ or from surgeons with a vested academic interest in tractography, thus skewing the results. Authors from units that use tractography regularly were more likely to respond. This makes it challenging to estimate the true prevalence of the use of tractography, based on these results. However, every effort was made to acquire survey responses from all neurosurgical units in the UK, representing a desirable response rate.²⁵ Multiple responses were received from 9 units, and whilst

different surgeons may have used tractography for different indications – reflecting its flexibility as a neurosurgical adjunct – concordance was noted in technical and personnel aspects of responses from any given unit.

Conclusions

Tractography derived from diffusion MRI is a useful tool in the arsenal of the modern neurosurgeon. In this UK-based survey of practising neurosurgeons, we show that predominantly DTI-based reconstructions are used, that tumour resection remains the most frequent use of the technique, and that large tracts such as the corticospinal tract are most frequently identified. The results point out a number of limitations with the technique, many of which are inherent, such as inaccuracy in representing underlying anatomy, and intra-operative brain shift. The advent of iMRI and rapid-acquisition high angular resolution imaging may mitigate some of the perceived limitations of tractography described in this report. We urge units using tractography to adopt standardised procedures for tract reconstruction, and hope that broader collaboration in the field can lead to the development of ‘best practice’ in this area.

Acknowledgements

Many thanks to Chloe Li for assistance in preparation of Figure 4. The authors would like to thank all the participants who voluntarily agreed to take part in this survey. Mr Nick Thomas was randomly selected to receive the £50 gift voucher.

Disclosure statement

No potential conflict of interest was reported by the author(s).

Funding

SMT is funded by Great Ormond Street Hospital Children’s Charity and is an Honorary Research Fellow of the Royal College of Surgeons of England. PWH is funded by Children with Cancer UK. All research at Great Ormond Street Hospital NHS Foundation Trust and the UCL Great Ormond Street Institute of Child Health is made possible by the NIHR Great Ormond Street Hospital Biomedical Research Centre.

ORCID

Sebastian M. Toescu  <http://orcid.org/0000-0001-8768-9231>

References

1. Bassar PJ, Mattiello J, LeBihan D. MR diffusion tensor spectroscopy and imaging. *Biophys J* 1994;66:259–67.
2. Behrens TEJ, Berg HJ, Jbabdi S, Rushworth MFS, Woolrich MW. Probabilistic diffusion tractography with multiple fibre orientations: What can we gain? *NeuroImage* 2007;34:144–55.
3. Tournier J-D, Calamante F, Gadian DG, Connelly A. Direct estimation of the fiber orientation density function from diffusion-weighted MRI data using spherical deconvolution. *NeuroImage* 2004;23:1176–85.
4. Essayed WI, Zhang F, Unadkat P, Cosgrove GR, Golby AJ, O’Donnell LJ. White matter tractography for neurosurgical planning: a topography-based review of the current state of the art. *NeuroImage Clin* 2017;15:659–72.
5. Akram H, Dayal V, Mahlknecht P, et al. Connectivity derived thalamic segmentation in deep brain stimulation for tremor. *NeuroImage Clin* 2018;18:130–42.

6. Kuhnt D, Bauer MHA, Becker A, *et al.* Intraoperative visualization of fiber tracking based reconstruction of language pathways in glioma surgery. *Neurosurgery* 2012;70:911–20.
7. National Institute for Health and Care Excellence. 2018. Brain tumours (primary) and brain metastases in adults | Guidance and guidelines | NICE, July. <https://www.nice.org.uk/guidance/ng99>
8. R Core Team. 2019. R: A language and environment for statistical computing. R Foundation for Statistical Computing, Vienna, Austria, url = <https://www.R-project.org/>
9. Kelley K, Clark B, Brown V, Sitzia J. Good practice in the conduct and reporting of survey research. *Int J Qual Health Care* 2003;15:261–6.
10. Tournier J-D, Smith RE, Raffelt DA, *et al.*, 2019. MRtrix3: A fast, flexible and open software framework for medical image processing and visualisation. 202. .doi: [10.1016/j.neuroimage.2019.116137](https://doi.org/10.1016/j.neuroimage.2019.116137)
11. Bassler PJ, Pajevic S, Pierpaoli C, Duda J, Aldroubi A. In vivo fiber tractography using DT-MRI data. *Magn Reson Med* 2000;44:625–32.
12. Mori S, Crain BJ, Chacko VP, van Zijl PC. Three-dimensional tracking of axonal projections in the brain by magnetic resonance imaging. *Ann Neurol* 1999;45:265–9.
13. Clark CA, Barrick TR, Murphy MM, Bell BA. White matter fiber tracking in patients with space-occupying lesions of the brain: a new technique for neurosurgical planning? *NeuroImage* 2003;20:1601–8.
14. Coenen VA, Krings T, Mayfrank L, *et al.* Three-dimensional visualization of the pyramidal tract in a neuronavigation system during brain tumor surgery: first experiences and technical note. *Neurosurgery* 2001; 49:86–93.
15. Mori S, Frederiksen K, van Zijl PCM, *et al.* Brain white matter anatomy of tumor patients evaluated with diffusion tensor imaging. *Ann Neurol* 2002;51:377–80.
16. Wu J-S, Zhou L-F, Tang W-J, *et al.* Clinical evaluation and follow-up outcome of diffusion tensor imaging-based functional neuronavigation. *Neurosurgery* 2007;61:935–49.
17. Winston GP, Daga P, White MJ, *et al.* Preventing visual field deficits from neurosurgery. *Neurology* 2014;83:604–11.
18. Shapely J, Vos SB, Vercauteren T, *et al.* Clinical applications for diffusion mri and tractography of cranial nerves within the posterior fossa: a systematic review. *Front Neurosci* 2019;13:23.
19. Middlebrooks EH, Tuna IS, Almeida L, *et al.* Structural connectivity-based segmentation of the thalamus and prediction of tremor improvement following thalamic deep brain stimulation of the ventral intermediate nucleus. *NeuroImage Clin* 2018;20:1266–73.
20. Nimsky C, Ganslandt O, Merhof D, Sorensen AG, Fahlbusch R. Intraoperative visualization of the pyramidal tract by diffusion-tensor-imaging-based fiber tracking. *NeuroImage* 2006;30:1219–29.
21. Nimsky C, Ganslandt O, Hastreiter P, *et al.* Preoperative and intraoperative diffusion tensor imaging-based fiber tracking in glioma surgery. *Neurosurgery* 2007;61:130–8.
22. Farquharson S, Tournier J-D, Calamante F, *et al.* White matter fiber tractography: why we need to move beyond DTI. *J Neurosurg* 2013; 118:1367–77.
23. Azad TD, Duffau H. Limitations of functional neuroimaging for patient selection and surgical planning in glioma surgery. *Neurosurg Focus* 2020;48:E12.
24. Schilling KG, Daducci A, Maier-Hein K, *et al.* Challenges in diffusion MRI tractography – lessons learned from international benchmark competitions. *Magn Reson Imaging* 2019;57:194–209.
25. Mitchell P. Survey data in neurosurgery. *Br J Neurosurg* 2018;32:465–6.