



## Removing the apocrine sweat glands with nasal endoscope assisted suction cutter: a new technique in the treatment of axillary odor

Zhiqiang Wang , Ruike Cao , Quan Liu , Yan Hu , Qi Zhao , Linlin Liu & Ran Du

To cite this article: Zhiqiang Wang , Ruike Cao , Quan Liu , Yan Hu , Qi Zhao , Linlin Liu & Ran Du (2020): Removing the apocrine sweat glands with nasal endoscope assisted suction cutter: a new technique in the treatment of axillary odor, Journal of Dermatological Treatment, DOI: [10.1080/09546634.2020.1795060](https://doi.org/10.1080/09546634.2020.1795060)

To link to this article: <https://doi.org/10.1080/09546634.2020.1795060>



© 2020 The Author(s). Published with license by Taylor & Francis Group, LLC.



Published online: 23 Jul 2020.



Submit your article to this journal [↗](#)



Article views: 583



View related articles [↗](#)



View Crossmark data [↗](#)

## Removing the apocrine sweat glands with nasal endoscope assisted suction cutter: a new technique in the treatment of axillary odor

Zhiqiang Wang<sup>a\*</sup>, Ruike Cao<sup>a\*</sup>, Quan Liu<sup>a</sup>, Yan Hu<sup>a</sup>, Qi Zhao<sup>b</sup>, Linlin Liu<sup>a</sup> and Ran Du<sup>a</sup>

<sup>a</sup>Department of Plastic and Aesthetic Surgery, Yantai Affiliated Hospital of Binzhou Medical University, Yantai, China; <sup>b</sup>Department of Oncology, Yantai Affiliated Hospital of Binzhou Medical University, Yantai, China

### ABSTRACT

**Objective:** Removing the apocrine sweat glands with nasal endoscope assisted suction cutter is a new technique that we have explored for the treatment of axillary odors. The aim is to introduce this new technique, compare it with traditional treatment and study the efficacy and patients satisfaction it brought about.

**Method:** A total of 82 patients (164 sides) with axillary odor were treated, 49 patients (98 sides) were treated with subcutaneous endoscopic assisted suction cutter, and 33 patients (66 sides) were treated with small-cut trimming. The efficacy of postoperative recovery was evaluated according to Tung grading method, and postoperative complications and satisfaction rate were also included in the comparative evaluation.

**Result:** The combined efficiency of nasal endoscope assisted suction cutter [100% (98/98)] was significantly higher than that of small-cut trimming [89.39% (59/66)]  $\chi^2 = 10.857, p < .01$ . The complications in the nasal endoscope assisted suction cutter group [4.08% (4/98)] were significantly lower than those in the small-cut trimming group [25.76% (17/66)].  $\chi^2 = 16.596, p < .01$ . Patients satisfaction of nasal endoscope assisted cutting aspirator group was higher.

**Conclusion:** Remove the apocrine sweat glands with nasal endoscope assisted suction cutter, as a new feasible technology, is more effective than small-cut trimming method in the treatment of axillary odor.

### ARTICLE HISTORY

Received 29 May 2020  
Accepted 4 July 2020

### KEYWORDS

Endoscope; apocrine sweat glands; satisfaction; small-cut trimming

### Introduction



Axillary odor, commonly known as “body odor,” is one of the common diseases in the department of plastic surgery. Studies suggest that abnormal secretion of the apocrine sweat glands of the axilla is the main cause of axillary odor. Malodor brings negative psychological, social and family effects to patients (1–2). It is often difficult for the conservative treatment to achieve satisfactory effects, while surgical removal of sweat glands has a definite effect (3–11). At present, sweat gland resection surgery mainly includes removal under direct vision and blind pruning and trimming with small incision. It is inevitable to choose a large incision to scrape sweat gland under direct vision and turn over the flap to expose the operation area, which is of great trauma and prone to postoperative hematoma and scar hyperplasia of incision. In order to solve the problem of large trauma, in recent years, more use of small incision blind shaving, this method has the advantages of small incision, rapid postoperative recovery, but limited by the field of vision, the depth and scope of pruning are not up to the requirements, thus sweat glands can not be removed completely, the low cure rate and postoperative recurrence bring great trouble to patients. Dr. Wang Zhiqiang, who is very experienced in nasal endoscope operations in the department of esthetic surgery,

began to explore the application of 70° nasal endoscope as subcutaneous endoscope, to replace the surgical scissors with suction cutter since 2016, at the same time in the operation, under direct observation cutting sweat glands for sake of solving the above-mentioned problems. Here we compare the patients who got the nasal endoscope assisted suction cutter treatment with patients who got small-cut trimming treatment, to observe the curative effects, complications and patients satisfaction of the two methods to prove the practicability of the new technique.

### Patients and methods

#### Patients

The study was approved by the Accreditation Committee of Yantai Affiliated Hospital of Binzhou Medical University. All the patients signed the Informed Consent before surgery. Collection in Among the patients of axillary odor admitted in the department of plastic surgery of Yantai Affiliated Hospital of Binzhou Medical University from May 2013 to October 2019, 33 of them got treatment of small-cut trimming from May 2013 to May 2015 while 49 of them got the treatment of nasal endoscope assisted suction cutter to remove axillary apocrine sweat glands from June 2015 to October 2019.

**CONTACT** Zhiqiang Wang  13853597966@163.com  Department of Plastic and Aesthetic Surgery, Yantai Affiliated Hospital of Binzhou Medical University, No.717, Jinbu street, Yantai, 264100, Shandong, China

\*Zhiqiang Wang and Ruike Cao are co-first authors and contributed equally to this work.

© 2020 The Author(s). Published with license by Taylor & Francis Group, LLC.

This is an Open Access article distributed under the terms of the Creative Commons Attribution-NonCommercial-NoDerivatives License (<http://creativecommons.org/licenses/by-nc-nd/4.0/>), which permits non-commercial re-use, distribution, and reproduction in any medium, provided the original work is properly cited, and is not altered, transformed, or built upon in any way.

According to the diagnostic criteria for Park (12) grade 0: in any environment or under whatever condition, no bad odor sends out from axilla; grade 1: slight bad odor sends out only after heavy manual labor smelt by the patient himself or others within the distance of 20 cm; grade 2: a relatively strong odor sends out after daily activities, which can only be smelt within the distance of 1.5 m; grade 3: strong odor sends out even when the patient is not taking any activity and the odor can be smelt beyond 1.5 m. All the patients we treated were above grade 2, among whom 11 cases of grade 2 and 38 cases of grade 3 were treated by the nasal endoscope assisted suction cutter for the removal of the apocrine sweat glands while 5 patients of grade 2 and 28 patients of grade 3 were treated with small-cut trimming.

### Operation procedure

The preoperative preparation, body position and anesthesia conditions of the two surgical methods were same, and the specific procedures were as follows:

One day before surgery, the patient was shaved off the armpit hair, took the position of lying on his back for external stretching and received a conventional disinfection and draping. The surgical range at 1.0 cm outside the edge of the armpit hair area was marked with methylene blue. The anesthetic solution was prepared with 100 ml normal saline + 10 ml lidocaine + 10 ml ropivacaine + 1 : 100,000 epinephrine, 40–60 ml on each side, and local slight swelling anesthesia was performed.

Patients in the trimming group (control group) were treated with subcutaneous apocrine sweat glands pruning through small incision. A 2.5–4.0 cm incision was made along the axillary striations outside the distribution area of axillary hair. The incision was cut into the subcutaneous fat layer. Tissue clipping and pruning subcutaneous apocrine sweat glands, sweat gland ducts and fat were made, to avoid cutting the skin, and tried to protect the subdermal vascular network. After trimming, rinsed the lacunae with salt water, checked for bleeding, determined no active bleeding, then placed 1 drainage strip on each side, and sutured the incision. After the operation, the elastic bandage was applied to compress the wound, the drainage strip was removed 48 h later, and the suture was removed 7–10 days later. Set a limit of upper limb movement for 1 month, then started rehabilitation exercise.

In the endoscopic group (study group), subcutaneous apocrine sweat glands were excised with the nasal endoscope assisted suction cutter. A 1–1.5 cm incision was made in the middle and posterior axillary hair area (Figure 1), Tissue scissors were combined and separated along the superficial fascia of the upper layer of the axilla, forming a subcutaneous artificial lacuna covering all areas of the apical sweat glands. The flap was suspended with 3-0 silk thread, and the assistant aided in pulling the suture to expose the lacunae (Figure 2). A 70° nasal endoscope (Olympus Corporation) was used to detect whether the space of the cavity reached 1 cm beyond the axillary hair area. During the exploration, enlarged pink apocrine sweat glands could be seen (Figure 3). After adequate hemostasis, the speed of the suction cutter (Stryker, inc) was adjusted to 2000–3000 RPM, and the negative pressure was set to 20–30 mmHg. Under the endoscopic vision, the subdermal fat and apocrine sweat glands were completely absorbed and removed (Figure 4). The end point of suction and cutting was to see the porcelain white dermis and there was sharp

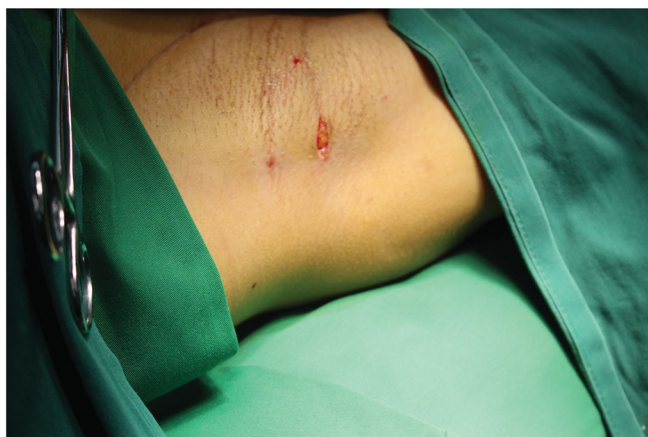


Figure 1. A 1–1.5 cm incision was made in the middle and posterior axillary hair area.

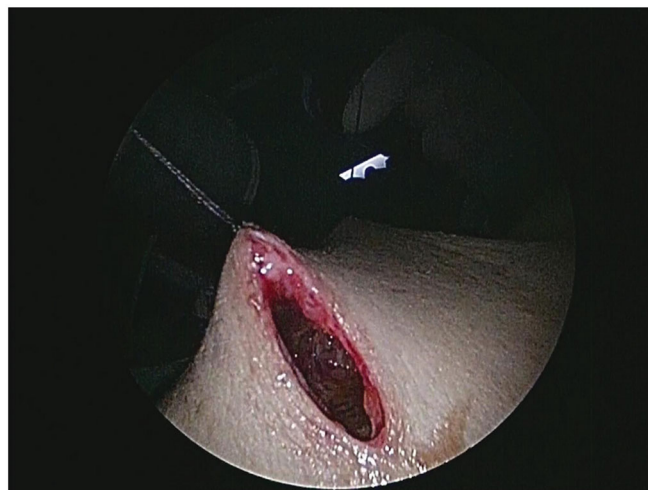

Figure 2. The assistant assisted in pulling the suture to expose the lacunae.

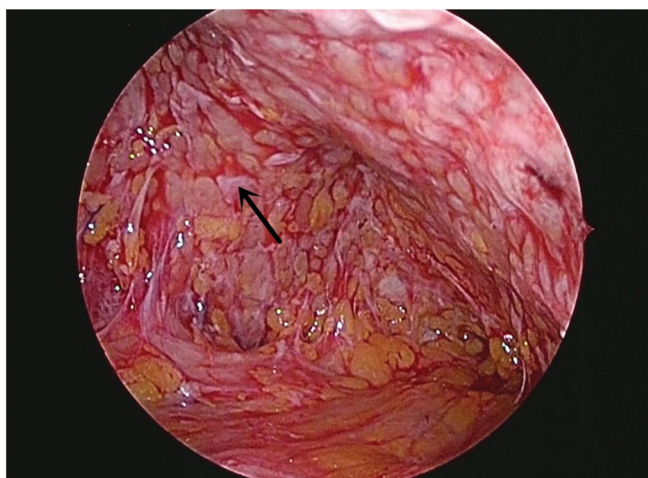
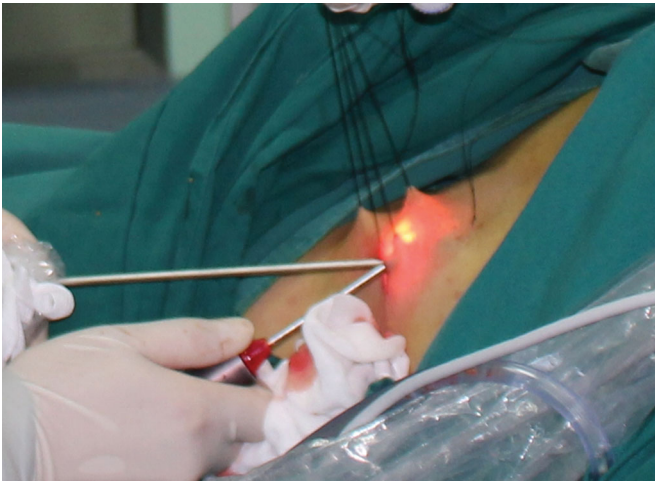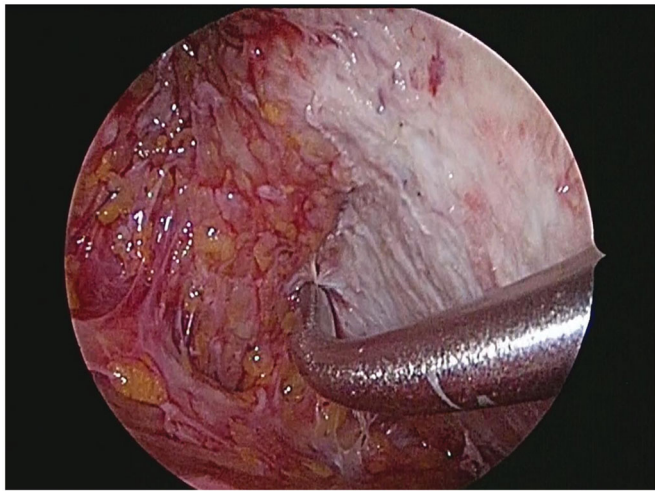


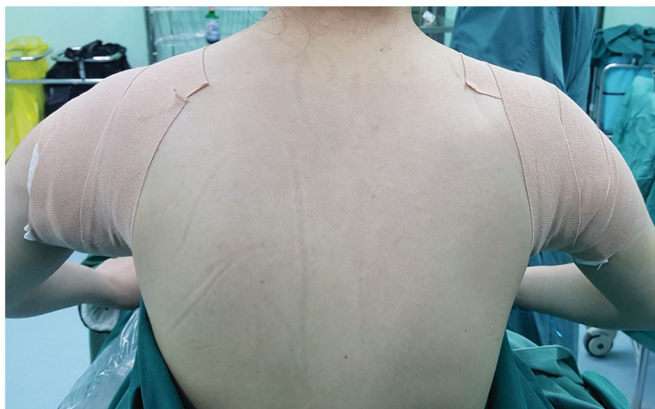Figure 3. Pink apocrine sweat glands could be seen. The black arrows indicate the sweat glands.



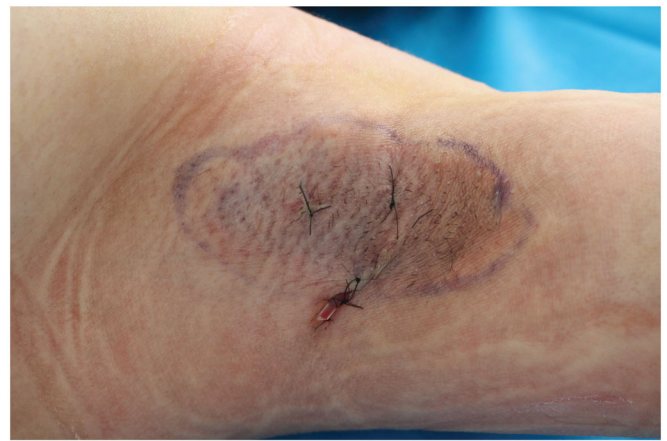**Figure 4.** Remove subdermal fat and apocrine sweat glands.



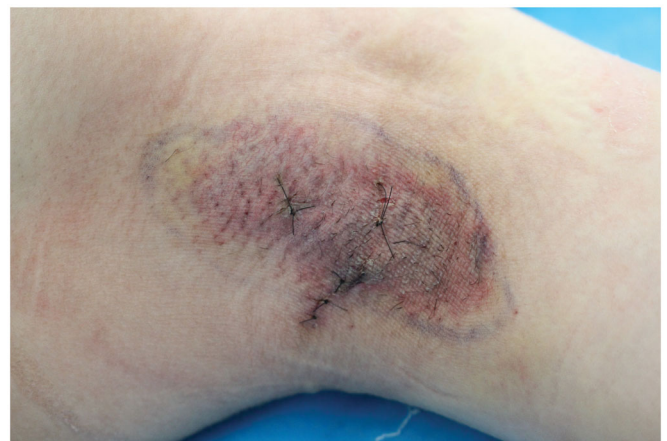**Figure 5.** The end point of suction and cutting was to see the porcelain white dermis.



**Figure 6.** The 3M bandages were pressurized to cover the bilateral axils.



**Figure 7.** The drainage strip was removed 48 h after the operation.

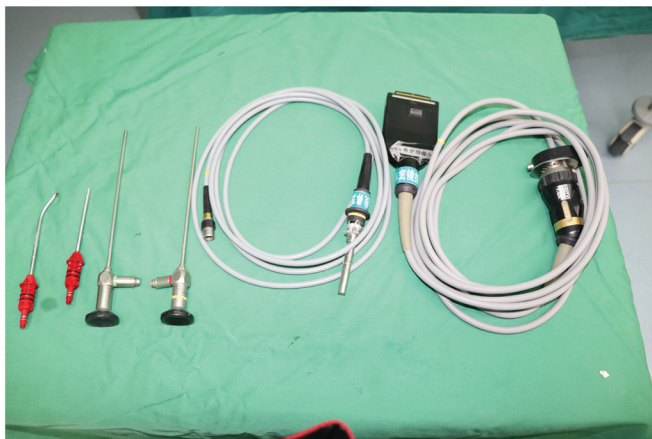

**Figure 8.** After 7 days of postoperatively pressurized wound healing.

difference between the cut part and that not operated (Figure 5). During the resection, attention was paid to the protection of dermal vascular network and skin flap, hair follicles could be removed together, and there was no apocrine sweat gland between the fat and the skin at the end point of cutting and sucking. After the suction and cutting, the smooth flap was clearly observed in the surgical field. After no residual sweat glands or active bleeding, the flap was fixed on the axillary fascia with suture for 3–5 stitches, and the drainage strip was placed to close the surgical incision. The armpits were evenly filled with gauze and the 3M bandages were pressurized to cover the bilateral axils (Figure 6). The drainage strip was removed 48 h after the operation (Figure 7), the axilla was banded under pressure for 5–7 days, and the vigorous activity of the upper limb was restricted for 1 week (Figure 8). The stitches were taken out 7–10 days after the operation, and rehabilitation exercise began 2 weeks after the operation.

#### **Efficacy evaluation**

The clinical efficacy was determined by the Tung (13) grading method. Cure: patients themselves or other people who were very close to the patients can not smell bad odor; Apparent effect: the bad odor decreases obviously, yet the bad odor gave off occasionally after the patients did some sports and sweated; no effect: no significant reduction in odor, patients or others



**Figure 9.** Nasal endoscopic system and suction cutter commonly used in surgery.

who were very close can smell the odor. Apparent efficiency = (cure + apparent effect)/samples number of this group  $\times 100\%$ .

### Statistical method

SPSS 23.0 software was used, and  $\chi^2$  test and Student's *t* test was used for data statistics.  $p < .01$  was considered statistically significant.

### Result

All the 82 patients were able to cooperate and eventually completed the treatment. Forty-nine patients (98 sides) were operated with nasal endoscope assisted suction cutter, including 20 males and 29 females, aged from 16 to 45 years, with an average age of 23 years and a course of disease ranging from 1 to 15 years (Figure 9). Thirty-three patients (66 sides) underwent small-cut trimming, including 9 males and 24 females, aged from 18 to 42 years, with an average age of 25 years. The course of the disease ranged from 1 to 17 years. The operations were done by the attending doctors or the level above and matched the operation specifications.

### Clinical efficacy

The cure rate of the endoscopic group (92.86%) was significantly higher than that of the trimming group (43.94%). Endoscopic apparent efficiency (including cure) was 100%, significantly higher than that of the trimming group (89.39%), as shown in Table 1. The efficiency was significantly different ( $\chi^2 = 10.857$ ,  $p < .01$ ).

### Postoperative complications

Complications occurred in 4 patients (4.08%) in the endoscopic group, and 17 patients (25.76%) in the trimming group, as shown in Table 2. The complication rate of the trimming group was significantly higher than that of the endoscopic group ( $p < .01$ ). After the late dressing change, treatment and rehabilitation exercise, the complications of the two groups of patients could recover well without serious sequelae.

**Table 1.** Comparison of efficacy between endoscopic group and small-cut trimming in treatment of axillary odors (side).

Group	Number of cases	Cure	Apparent effect	Invalid
Endoscopic group	98	91	7	0
Trimming group	66	29	30	7

**Table 2.** Comparison of postoperative complications.

Complications	Endoscopic group	Trimming group	$\chi^2$	<i>p</i>
Hematocous	2	5	2.957	.086
Infection	0	2	3.006	.083
Skin flap necrosis	0	1	1.494	.222
Delayed wound healing	2	5	2.957	.086
Obvious scar	1	10	12.586	<.01
Local contracture	1	6	6.287	.012
Upper brachial nerve injury	0	0	–	–
Total	6	29	–	–
Side number of complications	4	17	16.596	<.01
Complication rate	4.08%	25.76%	–	–

### Treatment time comparison

Patients in the process of receiving treatment will have psychological pressure on any operation, the shorter the time was, the less pressure it would cause and the higher the acceptance and satisfaction degree it would bring to the patients. There was no significant difference in operation time between the endoscopic group ( $53.22 \pm 5.76$ ) and the trimming group ( $54.58 \pm 4.55$ ). However, as the time of binding, suture removal and rehabilitation exercise of the endoscopic group (Table 3) were all significantly shorter than those of the trimming group, patients in this group felt more satisfied and returned to normal life earlier.

### Follow-up of effects and satisfaction


The patients were followed up for at least 6 months after the operations, 2 years at most. Follow-up methods included telephone calls, WeChat and outpatient reviews, etc. We believe that patients' satisfaction was subjective rather than objective. To assess satisfaction, we used the subjective scale in Figure 10. Satisfaction increased gradually from 0 to 3, 0 indicated unsatisfied, 3 indicated very satisfied. It mainly covered the following aspects: curative effect, decreased sweat secretion, hair loss and scar hyperplasia. Patients assessed their own cases and scored according to their own conditions (e.g. 100% perspiration before surgery. Excellent: reduced sweat secretion by 76–100%; Good: decrease sweat secretion by 51–75%; General: reduction of sweat secretion by 26–50%; Poor: reduced sweat secretion by 0–25%. We believe that a score of 2 or above indicates a patients satisfaction). Tables 4–6 showed the statistical analysis of the patients' satisfaction survey.

### Discussion

As for the treatment of axillary odor, there are many methods (4–13), including local deodorant, ultrasound, laser, botox, negative pressure aspiration, surgical curettage, subcutaneous pruning, etc., among which the surgical effect is the most significant. At present, the technique of small-cut trimming is mostly used by clinicians, and it is also easy to get with regard to technology and equipment. The method of small-cut trimming pursuits

**Table 3.** Treatment time comparison.

Group	Operation time (min)	Compression binding time (days)	Suture removal time (days)	Rehabilitation exercise time (days)
Endoscopic group	53.22 ± 5.76	7.45 ± 1.46	7.61 ± 1.15	14.35 ± 1.36
Trimming group	54.58 ± 4.55	14.91 ± 2.04	11.15 ± 2.33	30.52 ± 2.02
<i>t</i>	-1.131	-19.335	-9.114	-43.360
<i>p</i>	0.262	<0.01	<0.01	<0.01

**Figure 10.** Subjective scale of satisfaction.**Table 4.** Endoscope group satisfaction.

Scores	0	1	2	3
Efficacy	0	0	8	90
Hyperhidrosis improvement	0	0	3	95
Hair loss	0	14	40	44
Scar	0	2	16	80

**Table 5.** Trimming group satisfaction.

Scores	0	1	2	3
Efficacy	9	11	17	30
Hyperhidrosis improvement	7	6	34	19
Hair loss	2	10	34	20
Scar	2	12	40	12

**Table 6.** Satisfaction rate comparison.

Group	Endoscopic group (%)	Trimming group (%)	$\chi^2$	<i>p</i>
Efficacy	100	71.2	31.909	<.01
Hyperhidrosis improvement	100	80.3	20.965	<.01
Hair loss	85.7	81.8	0.449	.503
Scar	98.0	78.8	14.530	<.01

of small incision, however, if the armpit hair part is large and the incision size is not enough to expose the edge of the flap, the flap would be forced to flip and squeezed repeatedly, the cutting depth would be inconsistent and cause skin flap thinning, some parts would be excessive to make the skin flap blood supply get worse, which would lead to the formation of a hematoma, delayed healing, skin flap necrosis, scar hyperplasia, and even scar contracture. All of these would bring certain psychological burden to the patient. In nasal surgery, we often use the nasal speculum system and the suction cutter to operate accurately in a limited operating space. Inspired by this, we applied this technology to the treatment of axillary odor and achieved amazing results.

The method of nasal endoscope assisted suction cutter treatment can avoid the above-mentioned problems, though the incision is smaller, under a broader vision and direct observation, the skin flap can be separated apart wider. So the deep layer of apocrine sweat glands is thoroughly absorbed, and the flap will not be squeezed and turned over, to preserve the dermal vascular network and reduce unnecessary tissue damage. Moreover, negative pressure absorption takes in relatively soft apocrine sweat gland tissue rather than tough fibrous tissue,

thus reduces the subcutaneous fibrous tissue injury, avoids the formation of thinning skin flap and greatly reduces the formation of the postoperative complications, particularly, the postoperative scar is very small, which shall not affect the nice-looking surface of armpit.

During the operation, it is necessary to select the appropriate Angle endoscope and suction cutter. The 70° nasal endoscope is suitable for the space under the armpit, and the exploration space is wider due to its Angle advantage, making the operation more convenient for the surgeon. The extent of gland resection is confirmed through direct visualization. The operation takes about 40–60 min, during which the patient is allowed to properly move the arm on which the operation has been completed or the side that has not yet been operated on. In this way, the patient feels better.

In comparing the treatment time between the two groups, we found that the operation time became shorter and shorter as the surgical methods matured. According to the current comprehensive statistics, there is no significant difference in the duration of surgery between the two groups. In the future, with the improvement of the operation process or techniques, the duration of surgery in the endoscopic group may be shorter than that in the trimming group, and the statistical data will be changed accordingly. Moreover, the time for binding, suture removal and rehabilitation exercise of the endoscopic group were significantly shorter than that of the trimming group, and the comfort and psychological adaptation of patients in the former group were significantly better. The method was operated under local anesthesia, and all patients could choose this method except those with severe underlying diseases which were not suitable for surgical treatment.

In terms of postoperative satisfaction, we adopted the subdivision method to evaluate not only the satisfaction of efficacy, but also the major complications. Although this criterion is not necessarily objective, it can still reflect the gap between preoperative psychological expectation and postoperative reality. The satisfaction rate of patients in the endoscopic group for surgical effect, control of sweat secretion and control of scar was higher than that in the trimming group. As for the problem of postoperative hair loss, since part of the underarm hair follicles will be scraped during the surgical operation, the postoperative axillary hair loss should be explained to the patient before the operation, and the consent form should be signed. All women wanted to lose armpit hair, most men didn't care about hair loss, and a few wanted to keep it. The operation can achieve the double effects of both treatment and depilation; The majority of patients were satisfied with the subjective evaluation of depilation.

The new surgical technique has some drawbacks, such as the higher medical costs for patients. The reason is that patients have to pay for equipment in addition to the cost of surgery. In addition, the use of nasal endoscope assisted suction cutter device requires endoscopic equipment and surgeons with endoscopic operation experience, technical requirements are high, thus it is still difficult to popularize the method.

In conclusion, we describe a new technique for axillary odor, using subcutaneous endoscopic assisted suction cutter is more minimally invasive, with better visual field, more thorough resection, more obvious curative effect and fewer complications, making patients more comfortable, less psychological pressed, bringing faster postoperative recovery, which is worthy of further clinical promotion and application.

### Disclosure statement

The authors have no financial interest in any of the companies and/or equipment used or referenced in this article.

### References

1. Strutton DR, Kowalski JW, Glaser DA, et al. US prevalence of hyperhidrosis and impact on individuals with axillary hyperhidrosis: results from a national survey. *J Am Acad Dermatol*. 2004;51(2):241–248.
2. Atkins JL, Butler PEM. Hyperhidrosis: a review of current management. *Plast Reconstr Surg*. 2002;110(1):222–228.
3. Shi Z, Yan X, Ye X. Modified tumescent superficial suction with curettage treatment for axillary bromidrosis: clinical experience of 280 cases. *Aesthetic Plast Surg*. 2014;38(1):151–155.
4. Kim HG. A new osmidrosis procedure, the scrape and suction technique: review of 4,322 patients. *Aesthetic Plast Surg*. 2014;38(2):282–287.
5. Wang C, Wu H, Du F, et al. Axillary osmidrosis treatment using an aggressive suction-curettage technique: a clinical study on paired control. *Aesth Plast Surg*. 2015;39(4):608–615.
6. Yang H-H, Miao Y, Chen Y-T, et al. Minimally invasive approaches to axillary osmidrosis treatment: a comparison between superficial liposuction with automatic shaver curettage, subcutaneous laser treatment, and microwave-based therapy with a modified technique. *J Cosmet Dermatol*. 2019;18(2):594–598.
7. Huang YH, Yang CH, Chen YH, et al. Reduction in osmidrosis using a suction-assisted cartilage shaver improves the quality of life. *Dermatol Surg*. 2010;36(10):1573–1577.
8. Li ZR, Sun CW, Zhang JY, et al. Excision of apocrine glands with preservation of axillary superficial fascia for the treatment of axillary bromhidrosis. *Dermatol Surg*. 2015;41(5):640–644.
9. Fan YM, Wu ZH, Li SF, et al. Axillary osmidrosis treated by partial removal of the skin and subcutaneous tissue en bloc and apocrine gland subcision. *Int J Dermatol*. 2001;40(11):714–716.
10. Chang YY, Chen CH, Rosaline Hui CY, et al. A prospective clinical and histologic study of axillary osmidrosis treated with the microwave-based device. *Dermatol Sin*. 2015;33(3):134–141.
11. Arneja JS, Hayakawa TE, Singh GB, et al. Axillary hyperhidrosis: a 5-year review of treatment efficacy and recurrence rates using a new arthroscopic shaver technique. *Plast Reconstr Surg*. 2007;119(2):562–567.
12. Park YJ, Skin MS. What is the best method for treating bromidrosis. *Ann Plast Surge*. 2001;47(3):303–309.
13. Tung TC. Endoscopic shaver with liposuction for treatment of axillary osmidrosis. *Ann Plast Surg*. 2001;46(4):400–404.