

Personalized irradiation therapy for NMSC by rhenium-188 skin cancer therapy: a long-term retrospective study

Cesidio Cipriani , Maria Desantis , Gerhard Dahlhoff , Shannon D. Brown III , Thomas Wendler , Mar Olmeda , Gunilla Pietsch & Bernadette Eberlein

To cite this article: Cesidio Cipriani , Maria Desantis , Gerhard Dahlhoff , Shannon D. Brown III , Thomas Wendler , Mar Olmeda , Gunilla Pietsch & Bernadette Eberlein (2020): Personalized irradiation therapy for NMSC by rhenium-188 skin cancer therapy: a long-term retrospective study, Journal of Dermatological Treatment, DOI: [10.1080/09546634.2020.1793890](https://doi.org/10.1080/09546634.2020.1793890)

To link to this article: <https://doi.org/10.1080/09546634.2020.1793890>



© 2020 The Author(s). Published with license by Taylor & Francis Group, LLC



Published online: 22 Jul 2020.



Submit your article to this journal [↗](#)



Article views: 938



View related articles [↗](#)





View Crossmark data [↗](#)



Citing articles: 1 View citing articles [↗](#)

Personalized irradiation therapy for NMSC by rhenium-188 skin cancer therapy: a long-term retrospective study

Cesidio Cipriani^{a*}, Maria Desantis^a, Gerhard Dahlhoff^b, Shannon D. Brown III^b, Thomas Wendler^{b†} , Mar Olmeda^b, Gunilla Pietsch^{c#} and Bernadette Eberlein^c 

^aNuclear Medicine Division, ALGa Institute, Celano, Italy; ^bOncoBeta GmbH, Munich, Germany; ^cDepartment of Dermatology and Allergy Biederstein, School of Medicine, Technical University of Munich, Munich, Germany

ABSTRACT

Objectives: This study aimed to provide long-term clinical data about an innovative epidermal radioisotope therapy called Rhenium-SCT[®] (Skin Cancer Therapy) for non-melanoma skin cancer (NMSC), based on the use of the non-sealed beta emitter rhenium-188.

Material and methods: 52 NMSC patients with a mean age of 71.7 years were treated with rhenium-188 skin cancer therapy between the years 2005 and 2014. An acrylic matrix containing rhenium-188 was applied on a plastic foil covering the tumor. The treatment time for reaching a radiation dose of 50 Gy was calculated by a software program. Patients' characteristics and clinical follow-up data were collected and retrospectively analyzed.

Results: Overall 55 lesions (32 BCC, 19 SCC, 2 M. Bowen and 2 extramammary Paget's disease (EMPD)) mainly in the head and neck region (72.3%) were treated. The average size of the irradiation area was 9.79 cm² and the mean treatment time 46.35 min. All lesions showed a complete remission after a follow-up period between 3 and more than 12 months. No complications or other post-interventional problems were reported.

Conclusions: Rhenium-SCT[®] is considered as an effective, rapid, safe, painless treatment mostly performed in a single therapeutic session, regardless of the shape complexity, anatomical site and number of lesions.

ARTICLE HISTORY

Received 23 June 2020
Accepted 5 July 2020

KEYWORDS

BCC (basal cell carcinoma); brachytherapy; NMSC (non-melanoma skin cancer); rhenium-188; SCC (squamous cell carcinoma)

Introduction



During the last decades the number of non-melanoma skin cancer (NMSC) diseases has increased worldwide, being the most frequent malignancy (30% of total cancers) among European population. NMSC occurrence increases with age and its peak is found around the sixth to seventh decade and more frequently in men than in women (1,2). In Germany, a continuous long-term increase of NMSC incidence with no tendency for leveling off is expected (3). Tumors appear very often on sun-exposed areas of the body, such as the face, neck, bald scalp, hands, shoulders, arms and back; the rim of the ear and the lower lip are especially vulnerable to these cancers.

There are several kinds of treatment available for both types of skin cancer, basal cell carcinomas (BCC) and squamous cell carcinomas (SCC). The surgical intervention is the most common way of treatment, followed by cauterization, cryosurgery, photodynamic therapies and several other methods. For the treatment of selected cases, such as tumors located in critical, or inoperable patients, owing to systemic underlying diseases (cardiomyopathy, pulmonary insufficiency) irradiation therapy with low energy X-ray or electron beams as well as the interstitial

brachytherapy using sealed radioisotope iridium-192 can be reliable alternatives (4,5).

Rhenium-188 is a high energy beta emitting therapeutic radioisotope; beta particles have a maximum energy of 2.12 MeV and a mean energy of 764 KeV, and it also presents an additional 155 keV (15%) gamma emission. It has a half-life of about 16.98 h, which means that it decays continuously while mainly emitting beta-radiation. The therapeutic effect of rhenium-188's beta-radiation is very shallow in human tissue, up to 3 mm in depth, which makes it ideal for targeted treatment of superficial skin cancer types, like most non-melanoma skin cancers. Different to iridium-192, rhenium-188 has a flatter dose distribution in depth providing thus a more homogeneous dose to the tumor. The rapid drop of dose after 3 mm spares underlying layers of tissue, of particular importance for mucous tissues like lips and genitals (5–7).

This epidermal radioisotope therapy using rhenium-188 is commercially known as Rhenium-SCT[®]. The medical working principle of the Rhenium-SCT[®], or epidermal radioisotope therapy, is based on the local direct cell-killing effect of the beta-radiation, which triggers both the local death of cells and local

CONTACT Bernadette Eberlein  bernadette.eberlein@tum.de  Department of Dermatology and Allergy Biederstein, Technische Universität München, Biedersteiner Str. 29, München 80802, Germany

*Cesidio Cipriani was formerly part of the S. Eugenio Hospital, Rome, Italy.

†Thomas Wendler is now affiliated with Technical University of Munich, Faculty of Computer Science, Computer Aided Medical Procedures.

#Gunilla Pietsch is now affiliated with State Hospital Klagenfurt, Klagenfurt am Wörthersee, Austria.

© 2020 The Author(s). Published with license by Taylor & Francis Group, LLC

This is an Open Access article distributed under the terms of the Creative Commons Attribution-NonCommercial-NoDerivatives License (<http://creativecommons.org/licenses/by-nc-nd/4.0/>), which permits non-commercial re-use, distribution, and reproduction in any medium, provided the original work is properly cited, and is not altered, transformed, or built upon in any way.

reactions of the immune system of the body to repair itself. This radioisotope therapy to treat NMSC with non-sealed rhenium-188 offers a personalized solution for NMSC patients and is already available in specialized centers in Italy, South Africa, Australia, and Germany.

The present study retrospectively analyses 52 patients with a confirmed diagnosis of NMSC treated with the rhenium-188 skin cancer therapy between the years 2005 and 2014. The aim of the study is to collect clinical data to prove the effectiveness of the treatments performed with rhenium-188. Additionally, information about the size of the tumors, their location and the treatment time was collected, including reports of potential side effects of the mentioned therapy.

Materials and methods

Patients

52 patients, 34 males and 18 females, were considered in the present retrospective study performed in the Nuclear Medicine Department of S. Eugenio Hospital, Rome, Italy from May 2005 to May 2014. Patients with multiple lesions were also included in the study and the total number of lesions treated was 55. The following information was documented: general patient data such as age at treatment time, gender, anatomic site and histological type of the lesion, individual dosimetry files as well as treatment and diagnostic confirmation dates. Clinical photographs before, during and after the intervention were recorded. Recurrent tumors from previous treatment options were also included and 28 patients of the 52 had been previously treated with surgery or other methods. Patients whose available personal or clinical information was incomplete or undetailed were excluded from the study.

The selected cases were all histologically confirmed and grouped into the following 4 morphological categories: (1) basal cell carcinoma (BCC), (2) squamous cell carcinoma (SCC), (3) Bowen's disease and (4) extramammary Paget's disease (EMPD). Cancers whose histological type was other or unspecified were not considered. Regarding the anatomical sites of the tumors, the following classification was selected: head and neck, trunk, limbs and genitalia. The head and neck area were subdivided into smaller regions: forehead, scalp, cheek, nose, ear and peri-orbital and perioral regions.

All procedures performed in this study involving human participants were in accordance with the 1964 Helsinki declaration and its later amendments or comparable ethical standards. Informed consent was obtained from all individual participants included in this study.

Treatments

The carrier-free rhenium-188 (perrhenate) was obtained from a $^{188}\text{W}/^{188}\text{Re}$ generator (Oak Ridge National Laboratory, Oak Ridge, TN, USA; ITG GmbH, Garching, Germany) by elution with saline. A sterile nanocolloid (200–800 nm) of rhenium-188 results from a reaction of perrhenate with hydrogen sulfide. This nanocolloid is then thoroughly mixed with a synthetic acrylic resin (Max Meyer, Milan, Italy) to obtain a compound with a homogeneous distribution of the radioactive nanocolloid.

To proceed with the treatment, the lesion needed to be outlined with a dermatographic pen using accurate visual examination and dermoscopy, including a safety margin of

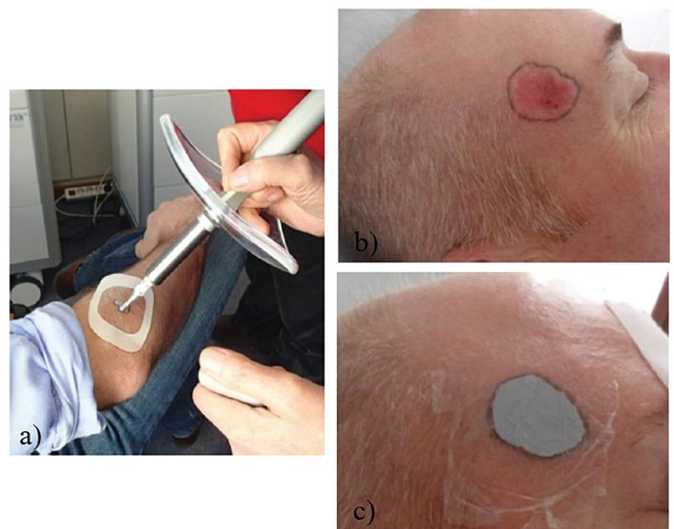

Figure 1. Application of the radioactive compound (a). Lesion before (b) and after (c) the application of the paste.

approximately 5 mm around it. This safety margin was selected to match the common one used in a standard surgery. Right before the treatment starts, the skin to be treated was covered first by a thin layer of a protective cream (Tueor; SOFAR, Milan, Italy) and/or a special foil (Aero Healthcare Ltd, Horsham, United Kingdom). The radioactive resin was then evenly applied on top of the protective cream or on top of the protective foil covering the previously mentioned outlined area, to prevent any direct contact of the radioactive compound with the epidermis (Figure 1).

Once the compound was applied, it was left over the lesion for a defined period of time in order to enable delivery of the targeted dose at the desired depth (see *Dosimetry* section for more information). Once the treatment time was over, the cream and/or the foil was easily removed together with the compound and properly disposed of. At the end, a contamination test needed to be carried out on the treated lesion(s) to confirm the absence of radioactivity. During the application physicians and patients needed to be properly protected from radioactive sources to which they may be subjected, as a result of the therapy.

The Rhenium-SCT[®] includes several ready-to-use, CE certified medical devices. The rhenium-188 compound is filled in the so-called carpoules, which include a specially designed brush for precise application within the marked lesion area. The carpoules are operated with a specially designed shielded ergonomic applicator holding the carpoule with the radioactive compound inside. Three additional devices are also part of this ready-to-use kit: a base station to safely handle both the applicator and the carpoules, a measurement station to record the measurement of the activity and a waste station, for the management of the radioactive waste once already disposed of (Figure 2).

Dosimetry

With the Rhenium-SCT[®], the administered dose for each patient depended on the initial activity of the isotope, the isotope emission energy, the application area, the depth of the lesion and the contact time of the radioactive source. The application area, also called irradiation area, included both the lesion area and

the 5 mm security margin around it. For each patient, the applied radioactivity was measured using a dose calibrator, and the treatment time was calculated using a multi-point source, real-time integration software program (VARSKIN 3.0; US Nuclear Regulatory Commission), which had already been validated as a proper method by comparison with the results with an independent Monte Carlo calculation (8).

For these calculations, a cylinder model was selected, and the application area was used as the irradiation field. The choice of including healthy tissue within the irradiation area was an

important parameter because a lethal dose must be administered to the potentially infiltrating cells in the external border. The acrylic matrix was assumed to be constant of a density of 1.2g/cm^3 , a thickness of $100\text{ }\mu\text{m}$ and average atomic number of 15. The plastic foil was assumed to have a density of 1.0g/cm^3 and a thickness of $10\text{ }\mu\text{m}$. The applied activity completed the input data for the calculation.

The resulting time needed to treat a tumor was calculated based on the assumption that a dose of 50Gy at a depth of $300\text{--}600\text{ }\mu\text{m}$ from the epidermis is sufficient to be lethal to any skin tumor of that thickness, as already clinically demonstrated (9).

Results

Age, gender and clinical type distribution

Of the 52 participants of the study treated between 2005 and 2014, 34 (65.38%) were male and 18 (34.62%) were female. A total number of 55 lesions were treated, 35 in male patients and 20 in female patients. The age distribution ranged from 48 to 96 years (Figure 3). The average age of the patients was 71.65 years at the time of treatment. The peak of the age frequency distribution was the seventh decade.

Of the 55 lesions registered, 32 were histologically diagnosed as BCC, 19 as SCC, 2 as M. Bowen and 2 as EMPD. BCC was the most common clinical type (58.18%).

Anatomical site distribution

Head and neck regions were by far the most affected areas (72.73%), being the nose the commonest site of incidence (27.5%), followed by the cheek (20%) and the perioral region (15%). High incidence rates were also found in the genitalia, with 8 cases (Table 1).

Irradiation area and times

Irradiation areas, which included the area of the lesions and the security margin, ranged from 0.3 to 60.5 cm^2 , with an average size of 9.79 cm^2 . Most of the areas treated were registered between 2 and 10 cm^2 (57%) (Figure 4). In these calculations, 2




Figure 2. Rhenium-SCT[®] equipment: carpoules filled with the radioactive compound (a); applicator (b); set of devices required to perform the therapy: base station, measurement station and waste station (c).

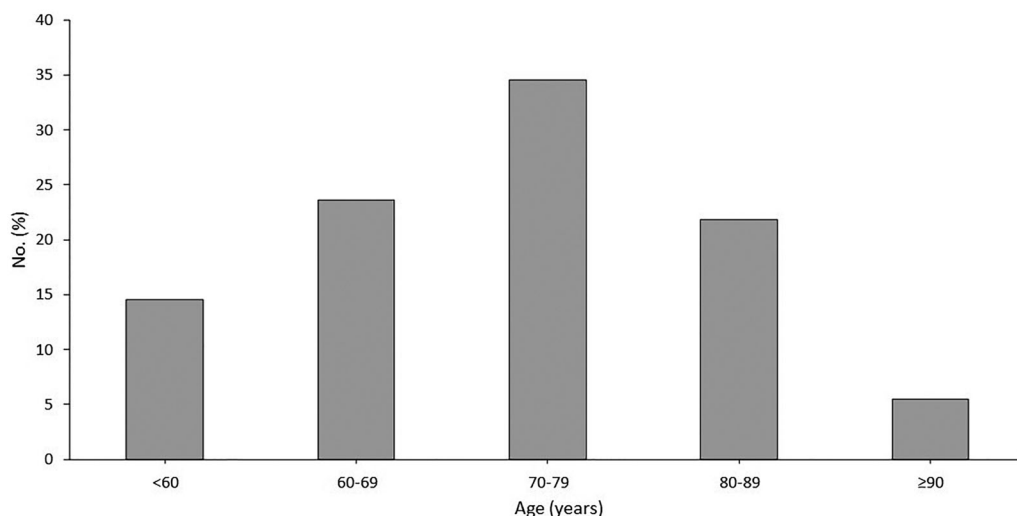


Figure 3. Age distribution of non-melanoma skin cancer patients treated with Rhenium-SCT[®].

of the 55 cases were excluded since the information regarding the total irradiation area was not clearly documented.

The treatment times with the Rhenium-SCT[®] for all the 55 registered lesions varied from 8 to 151 min, with an exceptional case of 240 min where unusually little radioactivity was applied. This particular case did not correspond to the usually performed Rhenium-SCT[®] applications and it was therefore excluded for the average time calculations. The determination of the mean time provided a value of 46.35 min.

Applied dose

A dose of 50 Gy at the deepest point of the lesion was used for all patients. The different lesion depths ranged from 300 to 600 μm , being therefore the mentioned dose an adequate one as clinical practice has already demonstrated. The calculated dose for each patient was dependent on the irradiation time, the depth of the lesion, the irradiation area and the activity applied to each of them (Figure 5).

Table 1. Anatomical site distribution of non-melanoma skin cancer lesions treated with Rhenium-SCT[®].

	Non-Melanoma Skin Cancer		
	Male, <i>n</i> = 35 No. (%)	Female, <i>n</i> = 20 No. (%)	Total, <i>n</i> = 55 No. (%)
Head and neck			
Periorbital	4 (17.39)	0 (0)	4 (10)
Forehead	1 (4.35)	2 (11.77)	3 (7.5)
Scalp	3 (13.04)	0 (0)	3 (7.5)
Cheek	4 (17.39)	4 (23.53)	8 (20)
Nose	5 (21.74)	6 (35.29)	11 (27.5)
Ear	4 (17.39)	1 (5.88)	5 (12.5)
Perioral	2 (8.7)	4 (23.53)	6 (15)
Subtotal	23	17	40 (72.73)
Trunk			
Back	1 (100)	0 (0)	1 (100)
Subtotal	1	0	1 (1.82)
Limbs			
Upper limbs	3 (60)	1 (100)	4 (66.67)
Lower limbs	2 (40)	0 (0)	2 (33.33)
Subtotal	5	1	6 (10.91)
Genitalia	6	2	8 (14.54)

The treatment time, which is defined as the irradiation time of a lesion with the radioactive source, decreased with increasing activity applied per area, especially with small doses in the range of 20 to 100 MBq/cm². For deeper lesions, slightly longer irradiation times were needed when applying the same dose.

Follow-up

All 52 patients showed complete remission shortly after the treatment with only one session. Clinical evaluations were carried out during follow-up visits to confirm complete remission of the tumor (Figure 6). The average follow-up time was 414 days, and the median was 296 days. 36 cases completed the documentation with at least 6 months clinical follow-up pictures. 19 cases had documentation for more than 12 months and 45 patients had only documentation for more than 3 months; 5 patients who did not have complete documentation died after the first post-interventional year. For 14 patients no reason for the missing follow-up is known.

No complications or other post-interventional problems were reported, as well as no contaminations of the patients, staff, or equipment.

Discussion

The use of radioisotopes as an alternative to surgical treatment of skin cancer is known since the 1960s and started with iridium-192 (10–12). Now there is an alternative to iridium-192, which is rhenium-188, an isotope with strong therapeutic properties, conferring therefore the Rhenium-SCT[®] some benefits.

Use of rhenium-188 as a dermatological high-dose-rate brachytherapy for the treatment of basal and squamous cell carcinoma was first described in 2008 (13). It has already been used in a large variety of BCC and SCC forms, from tumors of very large sizes to relapsing or recurrent forms, to multifocal lesions (14). This technique was later employed to treat patients with a histologically confirmed diagnosis of squamous cell carcinoma of the penis (SCCP) with irradiation times that ranged between 30 and 60 min, resulting in the spare of the anatomical integrity of the organ (6). Brachytherapy with rhenium-188 was

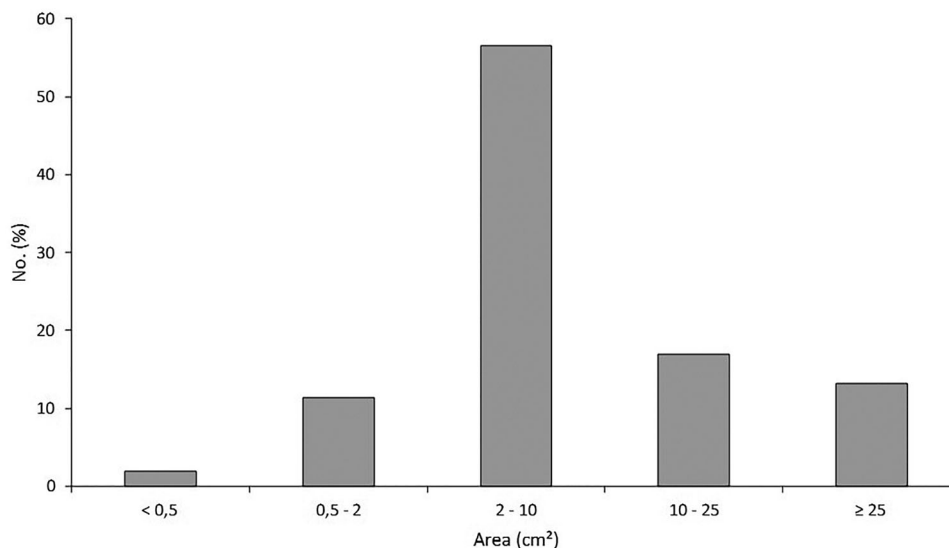


Figure 4. Size distribution of non-melanoma skin cancer lesions treated with Rhenium-SCT[®], including the 5 mm security margin around them.

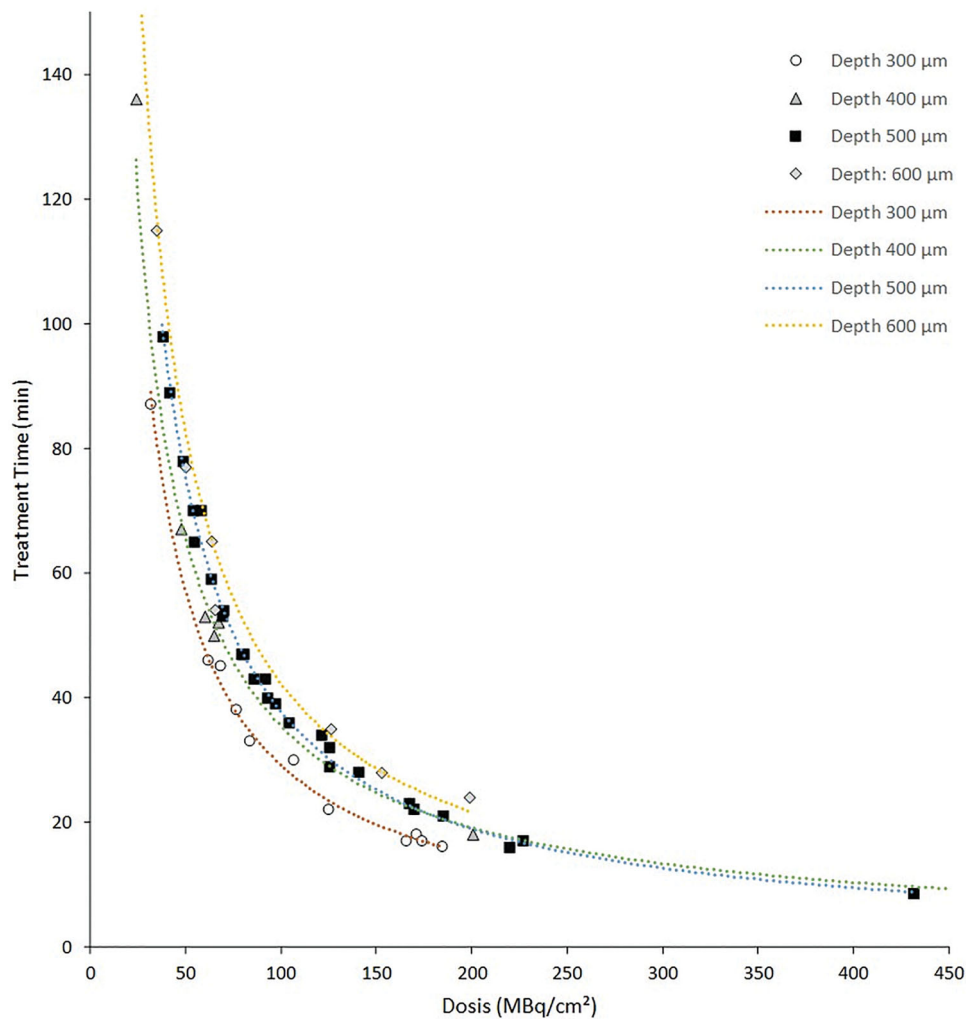


Figure 5. Correlation between the activity applied to a patient and the resulting treatment time for a Rhenium-SCT[®] therapy.

also selected to treat extramammary Paget's disease (EMPD) in 15 patients, with a consequent complete healing process (15). Overall, more than 460 patients, with a total of approximately 1300 histologically or clinically confirmed lesions of BCCs and SCCs have been successfully treated to date with the referred epidermal radioisotope therapy. This study provided some clinical data acquired with a long-term follow-up that proves its medical efficiency.

The main advantage of the described technique lies in the usefulness in all types of BCCs and SCCs, without restriction of anatomical location, dimension, number of lesions, clinical or histological type, and patient clinical situation.

A superiority of the proposed treatment with respect to surgery is evident for all tumors located in high-risk areas or difficult sites on which surgery would be difficult (nose, ears, eyelids), for patients with a high number of lesions or with tumor relapses, patients for which surgery would produce functional mutilations (penis, vulva, eyelids lesions), and, generally, in elderly, infirm, or otherwise inoperable patients.

By binding the radionuclide to a matrix and applying it over the foil that sits right on top of the lesion, the exact shape and size of the lesion can be covered, without direct contact of the radionuclide to the skin itself. As a result, healthy tissue can be spared, and no contamination is derived.

The rapid drop of the dose after 3 mm also spares underlying layers of tissue, of particular importance for mucous tissues like lips and genitals. Of great importance are the ears in order to spare the cartilage and for the eye lids due to radiation sensitive eye lenses. Thereby, the application field spreads and offers new opportunities to areas where the conventional treatment is inefficient. The technique proposed by the Rhenium-SCT[®] offers the ability to treat almost every anatomical location, as well as the possibility to treat several lesions at once, leading to a great advantage if compared with conventional treatments.

Likewise, in contrast to conventional radiation therapy and brachytherapy with sealed sources, in the proposed method generally only a single treatment is needed and no anesthesia (local or otherwise) is required. The role of the dermatologist is crucial when defining the safety margin around the lesion to ensure the treatment of the entire tumor and avoid thus a second or even a third treatment. A mean time of 46.53 min for a session of the Rhenium-SCT[®] treatment has been reported in the present study.

The use of natural or artificial radioactive substances in medicine requires special protective measures to prevent radiation from causing damage to the human organism. In addition to the need for appropriate protection against external irradiation, which may originate from open end enclosed preparations,

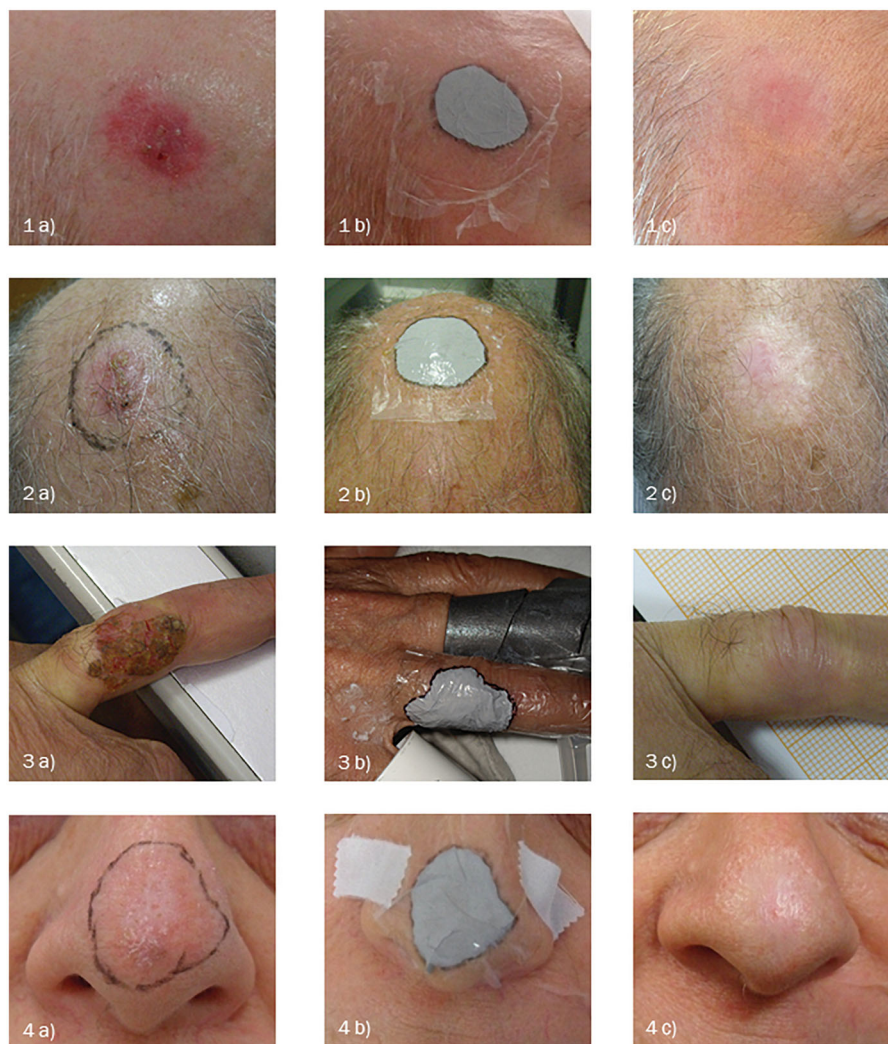

Figure 6. NMSC lesions before (a), during (b) and after (c) a treatment with rhenium-188 in 4 cases (case 1: BCC at the forehead; case 2: M. Bowen at the scalp; case 3: BCC at the finger; case 4: BCC at the nose).

appropriate measures were taken to avoid the constant risk of damage to radioactive preparations. External contamination was prevented by appropriate measures from transport to discharge. Internal contamination was also prevented by various measures, such as the use of a foil, the covering of hazardous areas and continuous training of the user. No contaminations or radiation damage were observed in any application.

Special care needs to be paid to the working protocols involving radiation therapies with non-sealed sources. The level of radiation exposure for the patient and medical staff could also be increased if the necessary measures are not taken. For this reason, special protective clothing was used by the medical personnel, which reduced the exposure of the staff below 0.7 μSv per application. Additionally, the Rhenium-SCT[®] have been provided with the right amount of shielding to minimize the dose received by the physician. The radiation exposure for the patient during a Rhenium-SCT[®] therapy is mainly due to the gamma levels of rhenium-188 and it varies depending on where the tumor is located. It is usually no more than 50 – 100 μSv , with a maximum value of 170 μSv , whereas in comparison, the average natural radiation exposure per year in Germany is 2,100 μSv .

Given that the Rhenium-SCT[®] is an epidermal radioisotope therapy, several complications can be conceived. However, no indication of radiation damage could be observed during the treatment of the 52 patients and the subsequent follow-ups with the patients. Some of the areas treated showed a slight depigmentation of the skin compared to the surrounding layers. Besides that, no further complications were reported or could be directly correlated to the Rhenium-SCT[®] treatment.

Disclosure statement

SDB and MO are current employees of OncoBeta, GD works as a medical consultant for OncoBeta and TW is a former employee of OncoBeta. The rest of the authors have no conflict of interest.

Funding

OncoBeta received a grant from the 'Medical technology Bavarian research program' [grant number: PBN-MED-1604-0003] for the publication of the manuscript as one of the work packages.

ORCID

Thomas Wendler  <http://orcid.org/0000-0002-0915-0510>
 Bernadette Eberlein  <http://orcid.org/0000-0003-4509-6491>

References

1. Lomas A, Leonardi-Bee J, Bath-Hextall F. A systematic review of worldwide incidence of nonmelanoma skin cancer. *Br J Dermatol.* 2012;166(5):1069–1080.
2. Zink A. [Non-melanoma skin cancer: Pathogenesis, prevalence and prevention]. *Hautarzt.* 2017;68(11):919–928.
3. Leiter U, Keim U, Eigentler T, et al. Incidence, mortality, and trends of nonmelanoma skin cancer in Germany. *J Invest Dermatol.* 2017;137(9):1860–1867.
4. Leitlinienprogramm Onkologie (Deutsche Krebsgesellschaft, Deutsche Krebshilfe, AWMF): S3-Leitlinie Aktinische Keratose und Plattenepithelkarzinom der Haut, Haut, Langversion 1.1.2020, AWMF Registernummer 032/022OL; [cited 2020 July 10]. Available from: <https://www.leitlinienprogramm.onkologie.de/leitlinien/aktinische-keratosenundplattenepithelkarzinom-der-haut/>.
5. Szeimies RM, Hauschild A, Garbe C, et al. *Tumoren der Haut: Grundlagen – Diagnostik – Therapie.* Stuttgart: Thieme Verlag 2010.
6. Carrozzo A, Sedda A, Muscardin L, et al. Dermo beta brachytherapy with 188-Re in squamous cell carcinoma of the penis: a new therapy. *Eur J Dermatol.* 2013; 23(2): 183–188.
7. Pillai MR, Dash A, Knapp FF. Jr. Rhenium-188: availability from the (188)W/(188) Re generator and status of current applications. *Curr Radiopharm.* 2012;5(3):271–287.
8. Sherbini S, DeCicco J, Gray AT, et al. Verification of the VARSKIN beta skin dose calculation computer code. *Health Phys.* 2008;94(6):527–538.
9. Baum RP. *Therapeutic nuclear medicine.* Berlin, Heidelberg: Springer-Verlag; 2014.
10. Guix B, Finestres F, Tello J, et al. Treatment of skin carcinomas of the face by high-dose-rate brachytherapy and custom-made surface molds. *Int J Radiat Oncol Biol Phys.* 2000;47(1):95–102.
11. Tormo A, Celada F, Rodriguez S, et al. Non-melanoma skin cancer treated with HDR Valencia applicator: clinical outcomes. *J Contemp Brachytherapy.* 2014;6(2):167–172.
12. Delishaj D, Laliscia C, Manfredi B, et al. Non-melanoma skin cancer treated with high-dose-rate brachytherapy and Valencia applicator in elderly patients: a retrospective case series. *J Contemp Brachytherapy.* 2015;7(6):437–444.
13. Sedda AF, Rossi G, Cipriani C, et al. Dermatological high-dose-rate brachytherapy for the treatment of basal and squamous cell carcinoma. *Clin Exp Dermatol.* 2008;33(6): 745–749.
14. Sedda AF, Rossi G, Cipriani C, et al. Beta emitter multilayer for the dermatological brachytherapy of cutaneous tumours. *Eur J Nucl Med Mol Imag.* 2003;2(Suppl):S343.
15. Carrozzo AM, Cipriani C, Donati P, et al. Dermo beta brachytherapy with 188Re in extramammary Paget's disease. *G Ital Dermatol Venereol.* 2014;149(1):115–121.