



Hepatitis C virus infection in nephrology patients

Lionel Rostaing & Nassim Kamar

To cite this article: Lionel Rostaing & Nassim Kamar (2011) Hepatitis C virus infection in nephrology patients, Alexandria Journal of Medicine, 47:2, 87-95, DOI: [10.1016/j.ajme.2011.06.001](https://doi.org/10.1016/j.ajme.2011.06.001)

To link to this article: <https://doi.org/10.1016/j.ajme.2011.06.001>



© 2011 Alexandria University Faculty of Medicine. Production and hosting by Elsevier B.V. All rights reserved.



Published online: 17 May 2019.



Submit your article to this journal [↗](#)



Article views: 37



View related articles [↗](#)



Review Article

Hepatitis C virus infection in nephrology patients

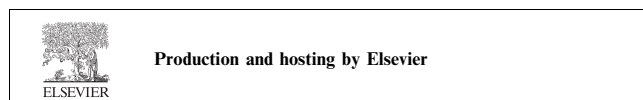
Lionel Rostaing *, Nassim Kamar

Department of Nephrology, Dialysis and Organ Transplantation, CHU Rangueil, Toulouse University Hospital, France

Contents

1. Introduction	87
2. Membranoproliferative glomerulonephritis	88
3. Membranous glomerulonephritis	88
4. HCV-related renal disease in cases of comorbid conditions	88
4.1. Human immunodeficiency virus (HIV) infection	88
4.2. Diabetic nephropathy	88
5. Diagnosis	89
6. Treatment	89
6.1. Symptomatic therapy	89
6.2. Anti-HCV therapy	89
6.2.1. Interferon-alpha	89
6.2.2. Interferon alpha and ribavirin	89
6.2.3. Ribavirin monotherapy	90
6.3. Immunosuppressive therapy	90
6.3.1. Rituximab	90
6.3.2. Immunosuppressive therapy in the case of acute and severe disease	91
6.4. Recommendations (Table 1)	91
References	93

* Corresponding author. Tel.: +33 5 61 32 25 84.
E-mail address: rostaing.l@chu-toulouse.fr (L. Rostaing).



1. Introduction

Hepatitis C virus (HCV) infection leads to chronic liver disease, but also to extra-hepatic manifestations.¹ These include mixed cryoglobulinemia, lymphoproliferative disorders, and renal disease. HCV infection has been reported in association with distinct histological patterns of glomerulonephritis in native kidneys.² Membranoproliferative glomerulonephritis (MPGN) associated with type II cryoglobulinemia is the predominant type of HCV-related glomerulonephritis.³ Less common glomerulonephritis diseases have also been reported in HCV-infected patients: these include MPGN without

cryoglobulinemia,⁴ membranous glomerulonephritis (MGN),⁴ focal segmental glomerular sclerosis,⁵⁻⁷ proliferative glomerulonephritis,^{4,8,9} and fibrillary^{10,11} and immunotactoid glomerulopathies.¹¹ Other anecdotal case reports have been also published: HCV-related IgA nephropathy,¹² rapidly progressive glomerulonephritis,¹³ and thrombotic microangiopathy associated with cryoglobulinemic MPGN.¹⁴ However, whether a causative effect between these glomerular diseases and HCV infection exists is still unknown.

Kidney biopsies were performed in HCV-positive patients before liver transplantation and in autopsy cases of patients infected by HCV. Different patterns of HCV-related glomerulonephritis were found in the majority of patients.^{15,16}

Following renal transplantation, some glomerulonephritis can recur on the graft¹⁷ and several occurrences of *de novo* glomerulonephritis associated with HCV infection have been reported. In addition to the HCV-related glomerulopathy described above in native kidneys, acute transplant glomerulopathy,⁵ chronic transplant glomerulopathy,^{5,18} and renal thrombotic microangiopathy associated with anticardiolipin antibodies¹⁹ have been also previously described. In order to avoid HCV infection recurrence on the kidney allograft, it is advisable to treat with antiviral therapy, i.e. alpha-interferon (α IFN) with or without ribavirin (RBV), those HCV (+)/RNA (+) dialysis patients who are candidates for kidney transplantation.

Herein, we provide an overview of renal diseases related to HCV and their therapies, as well as the treatment options available for HCV (+)/RNA (+) dialysis patients. We will not mention, however, HCV infection-related complications in the post-kidney transplantation setting.

2. Membranoproliferative glomerulonephritis

More than 80% of patients with mixed cryoglobulinemia are infected by HCV, and cryoglobulinemia is found in all patients with HCV-related MPGN.³ Cryoglobulins of types I, II, and III are immunoglobulins that precipitate at cold temperature. HCV-associated cryoglobulinemic glomerulonephritis, often with type II cryoglobulinemia, is related to the deposition in the glomerulus of immune complexes made by the HCV antigen, anti-HCV immunoglobulin (Ig) G antibodies, and a rheumatoid factor, which in most cases is an IgM kappa. Clinically, patients present with proteinuria and microscopic hematuria. Nephrotic syndrome and acute nephritic syndrome, with rapid deterioration of renal function, are observed in, respectively, 20% and 25% of patients.^{3,20} Fifty percent of patients have moderate renal insufficiency,³ and hypertension is present in 80% of patients.²⁰ HCV-related cryoglobulinemic renal disease is often associated with extra-renal manifestations. The most frequently observed are purpura, arthralgia, and peripheral neuropathy.²¹

Laboratory parameters reveal the presence of circulating cryoglobulins, which are most commonly type II cryoglobulins in which the rheumatoid factor is an IgM kappa. The complement components, C4 and C1q, are usually low. Serum C3 level is also moderately decreased. Serum anti-HCV antibodies and HCV RNA are detected in both the serum and the cryoprecipitate. HCV RNA concentrates in cryoprecipitate are ~1000 fold higher than in the serum. Histological examination of kidney biopsies usually reveals the presence of glomerular infiltration by activated macrophages. The glomerular basement

membrane shows double contours, which are caused by the interposition of monocytes between the basement membrane and the endothelium. Immunofluorescence exhibits subendothelial deposits of IgM, IgG, and the complement components. On electron microscopy, large subendothelial deposits are present. Vasculitis of small renal arteries is present in 30% of cases. A Japanese group demonstrated the glomerular deposition of HCV core antigen in patients with MPGN.²² In general, the renal prognosis is good²⁰; however, renal disease is the first cause of morbid-mortality in patients with mixed cryoglobulinemia.²⁰

Some authors have reported many cases of MPGN without cryoglobulinemia.^{23,24} However, the majority of patients who presented with this renal disease had rheumatoid factor in the sera, and some of them developed cryoglobulinemia on follow-up. This suggests that cryoglobulins were already present in the sera, possibly at very low levels, and so were not detected initially. Several later studies failed to find any association between MPGN and HCV in the absence of cryoglobulinemia.^{3,5,25}

HCV-related MPGN associated with type III mixed cryoglobulinemia has also been reported.²⁶

3. Membranous glomerulonephritis

Several cases of MGN have been described in HCV-infected patients.^{6,27,28} The clinical presentation and the histological findings are similar to idiopathic MGN. Biologically, they are characterized by normal complement levels, and the absence of cryoglobulins and rheumatoid factors in the serum. A Japanese group detected HCV core protein in the glomeruli of two patients with MGN, suggesting that immune complexes containing HCV proteins might be deposited in the glomeruli.²⁹ In one study from Japan, 8.3% of patients with MGN were anti-HCV (+)/HCV RNA positive compared with fewer than 1% in patients with other glomerulonephritis patterns (excluding MPGN). Finally, the prevalence of MGN was found to be significantly higher in HCV-positive compared to HCV-negative renal-transplant patients.³⁰ These findings support a possible pathogenic role of HCV in the development of MGN.

4. HCV-related renal disease in cases of comorbid conditions

4.1. Human immunodeficiency virus (HIV) infection

Few data regarding glomerular lesions in patients with coexisting HIV and HCV infections have been published. Renal biopsies performed in HIV-HCV co-infected patients presenting with hematuria, nephrotic range proteinuria, renal insufficiency, and hypertension have revealed the presence of type I or type III MPGN, MGN, or mesangial proliferative glomerulonephritis.^{31,32,12,33} Cryoglobulinemia was detected in some of patients with MPGN, and hypocomplementemia was found in the majority of them. The clinical course of HCV-related renal disease in patients co-infected by HIV is characterized by a rapid progression to renal failure.³² The optimal treatment of these patients is unknown. Anti-HCV therapy might be the treatment of choice.

4.2. Diabetic nephropathy

A high prevalence of HCV infection was found in patients with type II diabetic-related nephropathy.³⁴ The slope of reciprocal

serum creatinine was significantly greater in the HCV-positive than in HCV-negative patients with type II diabetic-related glomerulosclerosis. HCV infection was an independent factor associated with the slope of reciprocal serum creatinine.³⁴ The authors concluded that HCV infection might alter the progression of diabetic-related nephropathy.³⁴ HCV was also found to be a predictor factor of poorer renal survival in diabetic patients.³⁵ The mechanism of this observation is unknown.

5. Diagnosis

Patients infected by HCV should be routinely screened for microalbuminuria, microscopic hematuria, hypertension, and renal function, as well as for cryoglobulinemia, complement factors, and rheumatoid factor. A kidney biopsy should be performed in cases of proteinuria, impairment of renal function, or cryoglobulinemia. This strategy will allow us to detect silent glomerular disease that is related to HCV at an early stage.

Similarly, patients with MPGN or MGN should be screened for HCV infection. This includes: liver-enzyme levels, HCV serology with a 3D-generation enzyme-linked immunosorbent assay, HCV RNA in the serum and in the cryoprecipitate, if available. A normal liver-enzyme level does not exclude the diagnosis of HCV infection.

6. Treatment

Cryoglobulinemic membranoproliferative glomeronephritis is the most frequent HCV-related renal injury. Renal disease is the first cause of morbid-mortality in mixed cryoglobulinemia patients.²⁰ Hence, even if the HCV-related liver injury is not an indication for anti-viral therapy, HCV-related renal disease requires a specific treatment. This treatment relies on either anti-HCV therapy alone in cases of moderate renal disease, or on combined anti-viral and immunosuppressive therapies in cases of severe renal disease, i.e., nephrotic syndrome and/or progressive renal failure, or diseases that are refractory to anti-HCV therapy alone.

6.1. Symptomatic therapy

Blood-pressure control, diuretics, the blockade of the rennin-angiotensin system using either angiotensin-converting enzyme inhibitors (ACEIs) alone or combined with an angiotensin receptor blockers (ARBs), as well as the treatment of hyperlipidemia, are of proven benefit.³⁶

6.2. Anti-HCV therapy

Because a link has been established between HCV infection and the occurrence of cryoglobulinemic MPGN, anti-viral therapies have been used in HCV-positive patients presenting with glomerulonephritis in order to achieve clearance of HCV from the serum and, consequently, to have a beneficial effect on renal injury.

6.2.1. Interferon-alpha

In the early 1990s, standard alpha-interferon (α -IFN) was used alone at different doses, i.e. 3–10 MU three times a week: unfortunately, the results were disappointing. In 15 patients

who had a complete clearance of HCV RNA after α -IFN therapy, an improvement in renal function was observed.³⁷ However, there was no effect on proteinuria and all patients relapsed after α -IFN therapy was stopped. Later, in a prospective uncontrolled study, 14 patients experiencing an HCV-related glomerulonephritis were treated with α -IFN for 6 to 12 months.⁹ Overall, proteinuria significantly decreased, while renal function remained stable. In 11 patients, sera were tested for HCV RNA while on this therapy. Patients who became cleared of HCV RNA ($n = 6$) had a better outcome compared to those who remained HCV RNA positive ($n = 5$). However, virological and renal relapses were observed after completing the therapy. In this study, in five patients, the use of oral prednisone, in addition to α -IFN, had no effect on renal function. In contrast, steroid pulses had a beneficial effect in two patients. Finally, the use of cytotoxic agents, with or without plasma exchange, was associated with a high rate of death and a flare-up in HCV viremia.⁹

6.2.2. Interferon alpha and ribavirin

During the last few years, a combined therapy of α -IFN, especially pegylated IFN, with ribavirin, has become the gold standard of HCV treatment because it has been found to be more effective than α -IFN alone (See “Treatment of chronic hepatitis C virus infection: Recommendations for adults-I”). This has prompted physicians to treat HCV-related glomerulonephritis with this combination. However, published case reports and uncontrolled studies have only included small numbers of patients so far.

In a prospective uncontrolled study, 20 patients presenting with MPGN ($n = 17$), membranous glomerulonephritis ($n = 2$), and mesangioproliferative glomerulonephritis ($n = 1$) were treated with α -IFN and either with or without ribavirin.³⁸ All patients were given α -IFN 3 MU three times weekly. In cases of persistent HCV RNA at three months, ribavirin was added at the daily dose of 15 mg/kg: treatment was continued for 12 months. Four out of the 20 patients became HCV RNA negative within the first three months and, consequently, did not receive ribavirin therapy. Only one out of the 16 remaining patients who additionally received ribavirin became cleared of HCV RNA within the serum. Seven patients underwent a ribavirin dose reduction due to adverse events, mainly hemolytic anemia. Overall, both HCV RNA concentration and proteinuria decreased significantly. Serum-albumin level, as well as both C3 and C4 complement-component levels, increased significantly. Renal function remained stable. In this study, no data are provided regarding the outcome of renal disease after cessation of anti-HCV therapy.

In order to reduce ribavirin-induced hemolytic anemia, some authors have developed a high-performance liquid chromatography method to monitor the plasma ribavirin level, and have reported on their first treatment with concentration-controlled ribavirin plus α -IFN therapy in HCV-related glomerular disease.³⁹ The intended trough ribavirin plasma concentration was 10–15 mmol/L. Four patients received standard α -IFN, two received pegylated α -IFN and ribavirin, and one patient received ribavirin monotherapy because of poor tolerance to α -IFN. Five of the patients had a sustained virological response 6–32 months after antiviral therapy was stopped. One patient relapsed three months after completing therapy, whereas one patient who was receiving ribavirin monotherapy did not have a virological response. Serum-albu-

min level normalized in all patients, and proteinuria decreased in all patients. Glomerular filtration rate improved in three patients and remained stable in four other patients. Despite monitoring ribavirin plasma concentration, the main side-effect observed was ribavirin-induced hemolytic anemia, which required a ribavirin-dose reduction, low-dose iron, and systematic erythropoietin support. An improvement in renal histology has been also reported in a small number of patients.⁴⁰

More recently, 18 patients who had HCV-related cryoglobulinemic MPGN were treated with a combined therapy of standard or pegylated interferon and ribavirin.⁴¹ After a symptomatic treatment of nephrotic-range proteinuria by furosemide, with or without ACEIs, and with or without plasma exchange that was or was not associated with steroids, 18 patients received anti-HCV therapy, while seven other patients did not receive any anti-viral therapy. Fourteen out of the 18 were treated with standard α -IFN at 3 MU, three times weekly, plus ribavirin at 600–1000 mg/d, and the four other patients received pegylated IFN at 1.5 μ g/kg weekly with the same dose of ribavirin. The mean duration of anti-HCV therapy was 18 ± 10 months (range 6–24 months). The mean duration of follow-up after completing anti-HCV treatment was 16.7 ± 17.7 months (range 6–30 months). A sustained virological response was observed in 67% of patients. Pegylated IFN was given in three virological responders and one non-responder. After anti-HCV treatment, proteinuria and cryoglobulin levels decreased. In addition, serum-albumin level increased significantly in virological responders compared to both the non-responders, who were receiving the combination therapy, and to the control patients, who were receiving any anti-viral treatment. In contrast, serum-creatinine level remained stable in all three groups. These data suggest that anti-viral therapy should be given for a long period.

The major side effects of α -IFN can be flu-like symptoms, malaise, myalgia, asthenia, loss of weight, cardiovascular disorders, hematological abnormalities, neurological disorders... The side effects of α -IFN are enhanced in patients with impaired renal function compared to those with normal renal function. This might be related to differences in α -IFN pharmacokinetics. To date, two molecularly different pegylated interferons are available, i.e., pegylated interferon alfa-2a (Pegasys, Hoffmann-La Roche, Basel, Switzerland) and pegylated interferon alpha-2b (Peg-Intron, Schering-Plough, Berlin Germany). The pegylation of α -IFN results in an increase of its half life. For both pegylated interferon formulations, renal clearance accounts for a relatively smaller proportion of its total clearance than for non-pegylated interferons, i.e., 30%.^{42,43} However, pegylated IFN should be used with caution.

6.2.3. Ribavirin monotherapy

Despite the absence of a complete and sustained virological response, ribavirin monotherapy has been shown to have a beneficial effect on HCV-related glomerulopathy in immunocompetent patients,⁴⁴ as well as in renal-⁴⁵ and liver-transplant patients.⁴⁶

Ribavirin, when given alone or in association with α -IFN, is responsible for hemolytic anemia, especially in cases of renal-function impairment. Thus, it is widely admitted that ribavirin dosage should be adapted to creatinine clearance rather than to body weight,^{47–49} as has been previously recommended. Ribavirin plasma concentration predicts ribavirin-in-

duced anemia.⁵⁰ Hence, in patients with impaired renal function, ribavirin should be given with caution. The accumulation of ribavirin induces hemolytic anemia. Severe chronic hemolysis is responsible for iron overload, liver iron deposition, and an acceleration in liver fibrosis progression.⁵¹

6.3. Immunosuppressive therapy

In the past, patients with mixed cryoglobulinemia, with or without renal involvement, were treated by plasma exchange to remove circulating cryoglobulins from the plasma and, consequently, to diminish the deposition of immune complexes in the kidney.²¹ Cyclophosphamide was also used to improve renal disease by suppressing B lymphocyte stimulation and cryoglobulin production.²¹ Steroid pulses were administered to treat glomerular infiltration abnormalities.²¹ Low doses of oral steroids were also given to some patients.²¹ Previous uncontrolled studies that included a small number of patients treated with these therapies showed that this regime often controlled the acute phase of the disease, but was often poorly tolerated. The flare-up of HCV RNA concentration observed during immunosuppressive therapy may be harmful to HCV related-liver disease.

6.3.1. Rituximab

Recently, rituximab, a human-mouse chimeric monoclonal antibody that reacts with the CD20 antigen and, thus, directly and selectively targets the B cells, has proved effective and very well tolerated in patients with B-cell non-Hodgkin lymphomas. Hence, it is used to treat mixed cryoglobulinemia and HCV-related cryoglobulinemic MPGN.

Two patients, with HCV-related cryoglobulinemic MPGN, were treated with rituximab at four weekly doses of 375 mg/m².⁵² They were unresponsive to conventional treatments, including α -IFN, plasmapheresis, steroids, and either cyclophosphamide or 2-chlorodeoxyadenosine. A rapid response, and the disappearance of proteinuria and inactive urinary sediment, was observed in one patient who had a recent onset of nephritis. No improvement was noticed in the second patient when rituximab was interrupted after two infusions due to a thrombosis of the retinal artery. In the patient who completed rituximab therapy, HCV RNA concentration showed minimal fluctuations.⁵²

Later, six patients who had HCV-related cryoglobulinemic glomerulonephritis were treated with rituximab.⁵³ One patient received the standard four weekly doses, and the five other patients were treated by the standard protocol, plus two additional infusions at one and two months later. Proteinuria was decreased in all patients. Serum-creatinine level decreased in two patients, increased in one patient, and remained stable in the three other patients. Interestingly, HCV viral load decreased or remained stable in all patients. Rituximab has been also found to be effective for the treatment of HCV-related type II cryoglobulinemic MPGN when used as a first-line therapy.⁵⁴

A renal-transplant patient who was experiencing a *de novo* HCV-related type III cryoglobulinemic MPGN was treated with rituximab therapy: he had a clearance of cryoglobulinemia, a decrease in proteinuria, and no change in serum creatinine or HCV RNA.⁵⁵ Rituximab was efficient in treating *de novo* cryoglobulinemic MPGN in HCV-positive or -negative renal-transplant patients, but is associated with a high rate

of infectious complications, which might be related to the impairment of T- and B-cell functions that these patients experience.⁵⁵ Further controlled randomized studies are required to define the exact indications of rituximab, the dose of rituximab required, as well as its long-term effect on HCV liver disease.

6.3.2. Immunosuppressive therapy in the case of acute and severe disease

During the acute phase, plasmapheresis and steroid pulses might be used to remove circulating cryoglobulins from the plasma and to treat the glomerular infiltration abnormalities, respectively. Even in the absence of controlled randomized studies that compared the use of anti-CD20 monoclonal antibodies, i.e. rituximab (RTX) to IV cyclophosphamide, rituximab therapy should be preferred to cyclophosphamide. This is supported by two very recent publications. In the first, Saadoun et al.⁵⁶ examined whether treatment of HCV-mixed cryoglobulinemia (MC) may target either the viral trigger (HCV) or the downstream B-cell clonal expansion. In a prospective cohort study they included 38 HCV-MC patients who received (i) a combination of RTX (375 mg/m²) once a week for one month followed by Peg-interferon-alpha (Peg-IFN-alpha; 2a, 180 microg or 2b, 1.5 microg/kg) weekly plus RBV (600–1200 mg) daily for 48 weeks or (ii) Peg-IFN-alpha/ribavirin with the same modalities ($n = 55$). In the whole population of HCV-MC patients ($n = 93$), a complete clinical response was achieved in 73.1% (68 of 93), cryoglobulin clearance in 52.7% (49 of 93), and a sustained virologic response in 59.1% (55 of 93). Compared with Peg-IFN-alpha/ribavirin, rituximab plus Peg-IFN-alpha/ribavirin-treated patients had a shorter time to clinical remission (5.4 ± 4 vs. 8.4 ± 4.7 months, $P = .004$), better renal response rates (80.9% vs. 40% of complete response, $P = .040$), and higher rates of cryoglobulin clearance (68.4% vs. 43.6%, $P = .001$) and clonal VH1-69(+) B-cell suppression ($P < .01$). Treatment was well tolerated with 11% of discontinuation resulting from antiviral therapy and no worsening of HCV RNA under rituximab. The second study included fewer patients, i.e. 37 which presented with HCV-related MC.⁵⁷ The patients were given a combination of Peg-IFN-alpha (2a: 180 mug or 2b: 1.5 mug/kg) weekly plus RBV (1000 or 1200 mg) daily for 48 weeks, with ($n = 22$) or without ($n = 15$) RTX (375 mg/m²) once a week for one month followed by two 5-monthly infusions (PIRR). Complete response was achieved in 54.5% (12/22) and in 33.3% (5/15) of patients who received PIRR

and Peg-IFN-alpha/RBV, respectively ($P < .05$). Clearance of HCV RNA and conversion of B-cell populations from oligoclonal to polyclonal in liver, bone marrow, and peripheral blood was maintained for up to three years in 10 of 12 (83.3%) and in 2 of 5 (40%) patients receiving PIRR and Peg-IFN-alpha/RBV, respectively ($P < .01$). Cryoproteins in 22.7% (5/22) of patients with PIRR and in 33.3% (5/15) with Peg-IFN-alpha/RBV persisted despite sustained HCV RNA clearance. No response occurred in remaining five patients of both groups. PIRR therapy is well tolerated and more effective than Peg-IFN-alpha/RBV combination in HCV-related MC. Its effect may last for more than three years. The findings of these two studies indicate that rituximab combined with Peg-IFN-alpha/ribavirin is well tolerated, is more effective than Peg-IFN-alpha/ribavirin, and has long-lasting effects on HCV-MC.

6.4. Recommendations (Table 1)

All patients should be treated with ACEIs in association or not with ARBs, as well as with anti-HCV therapy. The latter relies on a combined anti-viral therapy of standard or pegylated IFN and ribavirin. We recommend the treatment of patients for at least 48 weeks, and the continuation of anti-viral therapy, even in the absence of a decrease in HCV RNA concentration of 2-log at week 12. Clinicians should be aware that after HCV RNA clearance, cryoglobulinemia persists for a long period. Ribavirin doses should be adapted according to creatinine clearance in order to avoid its main side effect, i.e., hemolytic anemia. Combined anti-viral and immunosuppressive therapies may be the treatment of choice for patients with severe renal disease, i.e., nephrotic syndrome and/or progressive renal failure, or diseases that are refractory to anti-HCV therapy alone.

HCV treatment in the chronic kidney disease (CKD) CKD population: The AASLD (American Association for the Study of Liver Diseases) has published guidelines for the CKD population stating that “when HCV infection is identified in persons with CKD, interferon-based antiviral treatment must be considered, but the regimen will vary depending on the kidney disease. . . The decision to treat must take into account the competing severities of the CKD and the chronic liver disease, the risks of the treatment itself, and whether there are comorbid conditions that may affect morbidity and mortality, such as cardiovascular disease”.⁵⁸

Table 1 Treatment of HCV-related glomerulonephritis.

Patients with moderate proteinuria and non-rapid but progressive renal failure:

Symptomatic treatment: Anti-HCV therapy for at least 12 months

Standard α -interferon 3 MU three times/week or pegylated α -IFN 1.5 μ g/kg/week

Ribavirin: dose adapted to the creatinine clearance or to a trough plasma concentration of 10–15 mmol/L with or without erythropoietin support

Patients with nephrotic-range proteinuria and/or progressive renal failure:

Symptomatic therapy: Furosemide, angiotensin-converting enzyme inhibitor (ACEIs) alone or combined with an angiotensin receptor antagonist (ARBs)

Plasma exchange: 3 L of plasma three times/week for 2 or 3 weeks

Rituximab: 375 mg/m² week for 4 weeks* or cyclophosphamide: 2 mg/kg/d for 2–4 months

Methylprednisolone pulses: 0.5–1 g/d for three consecutive days

Anti-HCV therapy (see above).

* Additional infusions of rituximab might be given in cases of early relapse after conventional therapy.

The kidneys play a major role in the catabolism and filtration of both interferon and ribavirin; thus, their clearances may be affected in subjects with CKD.^{59,60} The clearance of pegylated interferon is affected in those with CKD, although hemodialysis does not affect its clearance.⁶¹ Hence, the AASLD guidelines recommend subcutaneous weekly doses of 1 µg/kg of peginterferon alpha-2b and of 135 µg of peginterferon alpha-2a⁵⁸ to patients with stage 3–5 CKD. Because ribavirin is eliminated by the kidney, and if overdosed might result in dramatic anemia,⁶² ribavirin therapy is contraindicated when creatinine clearance is < 50 mL/min. Hence, most data regarding HCV treatment in the CKD population deal with the use of either standard α -interferon or α -pegylated interferon.

With regards to end-stage kidney-disease (ESKD) patients who are chronically treated by dialysis, Casanovas-Taltavull et al. reviewed two meta-analyses (Meta-1 and Meta-2) published in 2008. From these they analyzed the SVRs, any adverse effects, and the reasons for discontinuing α IFN treatment in dialysis patients.⁶³ The Meta-1 study analyzed results obtained from 645 patients; the Meta-2 study used data from 459 patients (19 studies were duplicated). Overall, the SVR was 40%; SVR in genotype 1 was 33%, with pegylated interferon providing few additional benefits over conventional alpha-interferon. Adverse events, such as typical flu-like syndrome occurred in 41% of patients, requiring withdrawal of antiviral treatment in 11% of them. A high rate of anemia was also documented, although the use of recombinant erythropoietin, intravenous iron administration, or transfusions was not generally reported. A typical flu-like syndrome occurred in 41% of patients, which required withdrawal of antiviral treatment in 11%. Severe adverse events were divided into the following groups: hormonal (thyroid), bone pain, cytopenia, gastrointestinal, immunological (prior graft rejection), central nervous system, cardiovascular, and infectious problems. The reviewers of these meta-analyses pointed out any bias in the selection criteria of candidates for treatment, limitations related to the number and type of adverse effects (as well as their clinical evaluation), and discrepancies in cases of discontinuation of treatment or loss to follow-up.

With regards to Meta-1, the primary outcome was a SVR (as a measure of efficacy); the secondary outcome was the drop-out rate (as a measure of tolerability).⁶⁴ They identified 13 prospective studies, which were controlled clinical trials that included 539 unique patients, of whom 10 (76.9%) patients were receiving maintenance dialysis. Pooling of these studies' results showed a significant increase in viral response of patients treated with antiviral therapy compared to patients who did not receive any therapy (controls). The pooled odds ratio (OR) of failure to obtain a SVR was 0.081 [95% confidence intervals (CI), 0.029–0.230], $p = 0.0001$. The pooled OR of drop-out rate was significantly increased in treated versus control patients, OR = 0.389 (95% CI, 0.155–0.957), $p = 0.04$. The studies were heterogeneous with regard to viral response and drop-out rate. In the subset of clinical trials ($n = 6$) involving only dialysis patients receiving α -IFN monotherapy for chronic HCV, there was a significant difference in the risk of failure to obtain a SVR (study vs. control patients), OR = 0.054 (95% CI, 0.019; 0.150), $p = 0.0001$. No difference in the drop-out rate between study and control patients was shown [OR = 0.920 (95% CI, 0.367; 2.311), NS]. Meta-1 showed that viral response was greater in patients with chronic kidney disease who received antiviral

therapy than in controls. No differences in the drop-out rates between study and control patients occurred in the subgroup of dialysis patients on α -IFN monotherapy.⁶⁴

With regards to Meta-2, the authors took into account those chronic dialysis patients with chronic HCV infection who were either treated with α IFN or peg α IFN, with or without ribavirin.⁶⁵ They searched on MEDLINE for indexed studies since 1966, and only selected studies with a sample size greater than 10. They looked for the following parameters: SVR at six months after treatment, rate of treatment discontinuation caused by adverse events, and factors associated with these outcomes. They analyzed 20 studies that contained 459 α IFN-treated patients, three studies that contained 38 peg α IFN-treated patients, and two studies that contained 49 peg α IFN and ribavirin-treated patients. The overall SVR rate was 41% (95% confidence interval [CI], 33–49) for α IFN and 37% (95% CI, 9–77) for peg α IFN. Treatment-discontinuation rates were 26% (95% CI, 20–34) for α IFN and 28% (95% CI, 12–53) for peg α IFN. SVR was higher, with three million units (MU) or higher of α IFN at three times weekly, with lower mean amounts of HCV RNA, lower rates of cirrhosis, a HCV genotype 1, or elevated transaminase, though these findings were not statistically significant.

Treatment-discontinuation rates were greater in studies using larger doses. Hence, side-effects from alpha-interferon were numerous, particularly in the ESKD population. The main side effects were fatigue/weakness and loss of appetite, which may lead to weight loss and, thus, fluid overload if dry weight is not adapted accordingly. Many patients also developed anemia, which often requires commencement or increased treatment with erythropoietin-stimulating agents; in addition, seizures can occur if there is fluid overload and hypertension. The limitations of these meta-analyses were publication bias, there were few randomized controlled trials, and there were limitations in generalizability of all hemodialysis patients. In conclusion, alpha-IFN treatment of hemodialysis patients resulted in an SVR rate of 41%. Thus, a higher weekly dose of α IFN, a lower mean level of pre-treatment HCV RNA, a lower rate of cirrhosis, an HCV genotype different from 1, and/or decreased transaminase levels may all be associated with greater SVR rates.⁶⁵

A more recent meta-analysis has been published on a group of 770 hemodialysis patients with chronic HCV infection, in which the authors evaluated factors that were associated to SVR after α -pegylated or standard α -IFN monotherapy. Twenty-one studies on α -IFN-alfa2a or α -IFN-alfa2b (491 patients), and 12 on pegylated-IFN-alfa2a or PEG-IFN-alfa2b (279 patients), were evaluated. The pooled SVRs for standard and pegylated α -IFN monotherapy in random-effect models were 39.1% (95% CI, 32.1–46.1) and 39.3% (95% CI, 26.5–52.1), respectively. Pooled dropout rates were 22.6% (95% CI, 10.4–34.8) and 29.7% (95% CI, 21.7–37.7), respectively. Female gender, HCV-RNA copies per mL, HCV genotype, alanine transaminase pattern, duration of infection, stage of liver fibrosis, and treatment duration were not associated with SVR. Only an age less than 40 years was significantly associated with SVR (odds ratio, 2.17; 95% CI, 1.03–4.50).⁶⁶

There are only few limited reports that describe the combined use of (peg) alpha-interferon and ribavirin in dialysis patients. With regard to this combined therapy, the AASLD guidelines state that “Ribavirin can be used in combination with interferon with a markedly reduced daily dose with care-

ful monitoring for anemia and other adverse effects".⁵⁸ The largest series published so far on the combined use of peginterferon alpha-2a plus ribavirin in hemodialysis patients obtained a SVR rate of 97% (34/35) in the treated patients (peginterferon alpha-2a plus ribavirin) vs. 0% (0/35) in untreated controls.⁶⁷ These findings have not been confirmed in further reports where the SVR rate ranges between 7% and 71%.⁶⁸

Treatment of acute HCV infection in CKD patients: In the general population, with regard to the treatment of acute HCV infection, the AASLD guidelines state that "Treatment can be delayed for 8–12 weeks after acute onset of hepatitis to allow spontaneous resolution.

Although excellent results were achieved using standard interferon monotherapy, it is appropriate to consider the use of peginterferon. Until more information becomes available, no definitive recommendation can be made about the optimal duration needed for treatment of acute hepatitis C; however, it is reasonable to treat for at least 12 weeks and 24 weeks may be considered".⁵⁸

In dialysis patients, Liu et al. have very recently published their experience regarding the treatment of acute HCV infection. They included 35 dialysis patients that had no spontaneous clearance of HCV at 16 weeks after acute HCV infection. They were thus then given a course of peginterferon alpha 2a at 135 µg weekly for 24 weeks.⁶⁹ They compared the results with those from a historical series of 36 hemodialysis patients who had acute hepatitis C, but had not received treatment. The rate of SVR in their treatment group was significantly higher than the rate of spontaneous HCV clearance in the control historical series group (88.6% vs. 16.7%). All but one patient had a rapid virologic response (undetectable HCV RNA levels at four weeks of therapy), and all patients who received more than 12 weeks of therapy had early and end-of-treatment virologic responses. All patients who had clearance of HCV by 16 weeks had undetectable HCV RNA levels during and at the end of follow-up. Liu et al. conclude that "Pegylated IFN alfa-2a monotherapy is safe and efficacious for hemodialysis patients with acute hepatitis C. It is suggested that patients without spontaneous clearance of HCV by week 16 should receive this therapy".⁶⁹

In addition, dialysis patients who were cleared of the HCV virus after antiviral therapy, and received kidney transplantation, did not present with HCV reactivation, despite heavy immunosuppression.⁷⁰ Hence, 16 HCV seropositive/HCV RNA-positive hemodialysis patients who were treated with IFN-alpha (9 MU/wk during 6 or 12 months) underwent kidney transplantation 38 months (range, 2–57) after alpha-IFN therapy. At kidney transplantation, HCV viremia was negative in all patients. Immunosuppression relied on anticalcineurin agents with or without steroids and/or antimetabolites; in addition, 12 of them received induction therapy with antithymocyte globulins; at the last follow-up after kidney transplantation, i.e. 22.5 months (range, 2–88), HCV viremia remained negative in all patients.⁷⁰ Recently, we have assessed the persistence of HCV infection in 26 HCV seropositive kidney-transplant patients currently receiving immunosuppressants, and who were formerly infected with HCV, i.e., they had eliminated HCV either spontaneously or after interferon-α therapy while on hemodialysis.⁷¹ No biochemical or virological relapse was seen during the median posttransplant follow-up of 10.5 years (range: 2–16) in those patients who received

immunosuppressive therapy that included calcineurin inhibitors (100%), and/or steroids (62%), and/or antimetabolites (94%). At the last follow-up, all had undetectable HCV RNA according to the conventional tests that were repeated, on average, five times (range, 1–15). We also looked for residual HCV RNA in their plasma and peripheral blood-mononuclear cells (PBMCs) (stimulated or not in culture) with an ultrasensitive RT-PCR assay, followed by Southern blotting for PBMCs: no HCV genomic RNA was detected in the plasma samples or in the unstimulated and stimulated PBMCs. Thus, an absence of a relapse of HCV in formerly HCV-infected immunocompromised patients suggests complete eradication of HCV after its elimination while on dialysis.⁷¹ These findings highlight the fact that HCV-positive dialysis patients who have a SVR after completion of alpha-(peg) interferon therapy are really cured of HCV.

References

1. Cacoub P, Costedoat-Chalumeau N, Lidove O, Alric L. Cryoglobulinemia vasculitis. *Curr Opin Rheumatol* 2002;**14**:29.
2. Sabry AA, Sobh MA, Irving WL, et al. A comprehensive study of the association between hepatitis C virus, glomerulopathy. *Nephrol Dial Transplant* 2002;**17**:239.
3. D'Amico G. Renal involvement in hepatitis C infection: cryoglobulinemic glomerulonephritis. *Kidney Int* 1998;**54**:650.
4. Morales J, Morales E, Andrés A, Praga M. Glomerulonephritis associated with hepatitis C virus infection. *Curr Opin Nephrol Hypertens* 1999;**8**:205.
5. Cosio FG, Roche Z, Agarwal A, et al. Prevalence of hepatitis C in patients with idiopathic glomerulopathies in native, transplant kidneys. *Am J Kidney Dis* 1996;**28**:752.
6. Altraif IH, Abdulla AS, al Sebayel MI, et al. Hepatitis C associated glomerulonephritis. *Am J Nephrol* 1995;**15**:407.
7. Stehman-Breen C, Alpers CE, Fleet WP, Johnson RJ. Focal segmental glomerular sclerosis among patients infected with hepatitis C virus. *Nephron* 1999;**81**:37.
8. Horikoshi S, Okada T, Shirato I, et al. Diffuse proliferative glomerulonephritis with hepatitis C virus-like particles in paramesangial dense deposits in a patient with chronic hepatitis C virus hepatitis. *Nephron* 1993;**64**:462.
9. Johnson RJ, Gretch DR, Couser WG, et al. Hepatitis C virus-associated glomerulonephritis. Effect of alpha-interferon therapy. *Kidney Int* 1994;**46**:1700.
10. Coroneos E, Truong L, Olivero J. Fibrillary glomerulonephritis associated with hepatitis C viral infection. *Am J Kidney Dis* 1997;**29**:132.
11. Markowitz GS, Cheng JT, Colvin RB, et al. Hepatitis C viral infection is associated with fibrillary glomerulonephritis, immunotactoid glomerulopathy. *J Am Soc Nephrol* 1998;**9**:2244.
12. Gonzalo A, Navarro J, Barcena R, et al. IgA nephropathy associated with hepatitis C virus infection. *Nephron* 1995;**69**:354.
13. Usalan C, Erdem Y, Altun B, et al. Rapidly progressive glomerulonephritis associated with hepatitis C virus infection. *Clin Nephrol* 1998;**49**:129.
14. Herzenberg AM, Telford JJ, De Luca LG, et al. Thrombotic microangiopathy associated with cryoglobulinemic membranoproliferative glomerulonephritis, hepatitis C. *Am J Kidney Dis* 1998;**31**:521.
15. Arase Y, Ikeda K, Murashima N, et al. Glomerulonephritis in autopsy cases with hepatitis C virus infection. *Intern Med* 1998;**37**:836.
16. McGuire BM, Julian BA, Bynon JSJ, et al. Glomerulonephritis in patients with hepatitis C virus cirrhosis undergoing liver transplantation. *Ann Intern Med* 2006;**144**:735.

17. Cruzado JM, Torras J, Gil-Vernet S, Grinyo JM. Glomerulonephritis associated with hepatitis C virus infection after renal transplantation. *Nephrol Dial Transplant* 2000;**15**:65.
18. Gallay BJ, Alpers CE, Davis CL, et al. Glomerulonephritis in renal allografts associated with hepatitis C infection: a possible relationship with transplant glomerulopathy in two cases. *Am J Kidney Dis* 1995;**26**:662.
19. Baid S, Pascual M, Williams Jr WW, et al. Renal thrombotic microangiopathy associated with anticardiolipin antibodies in hepatitis C-positive renal allograft recipients. *J Am Soc Nephrol* 1999;**10**:146.
20. Tarantino A, Campise M, Banfi G, et al. Long-term predictors of survival in essential mixed cryoglobulinemic glomerulonephritis. *Kidney Int* 1995;**47**:618.
21. Fabrizi F, Colucci P, Ponticelli C, Locatelli F. Kidney and liver involvement in cryoglobulinemia. *Semin Nephrol* 2002;**22**:309.
22. Yamabe H, Inuma H, Osawa H, et al. Glomerular deposition of hepatitis C virus in membranoproliferative glomerulonephritis. *Nephron* 1996;**72**:741.
23. Johnson RJ, Gretch DR, Yamabe H, et al. Membranoproliferative glomerulonephritis associated with hepatitis C virus infection. *N Engl J Med* 1993;**328**:465.
24. Johnson RJ, Willson R, Yamabe H, et al. Renal manifestations of hepatitis C virus infection. *Kidney Int* 1994;**46**:1255.
25. Yamabe H, Johnson RJ, Gretch DR, et al. Hepatitis C virus infection, membranoproliferative glomerulonephritis in Japan. *J Am Soc Nephrol* 1995;**6**:220.
26. Agnello V, Chung C, Kaplan LM. A role of hepatitis C virus infection in type II cryoglobulinemia. *N Engl J Med* 1992;**327**:1490.
27. Rollino C, Roccatello D, Giachino O, et al. Hepatitis C virus infection, membranous glomerulonephritis. *Nephron* 1991;**59**:319.
28. Davda R, Peterson J, Weiner R, et al. Membranous glomerulonephritis in association with hepatitis C virus infection. *Am J Kidney Dis* 1993;**22**:452.
29. Okada K, Takishita Y, Shimomura H, et al. Detection of hepatitis C virus core protein in the glomeruli of patients with membranous glomerulonephritis. *Clin Nephrol* 1996;**45**:71.
30. Morales JM, Pascual-Capdevila J, Campistol JM, et al. Membranous glomerulonephritis associated with hepatitis C virus infection in renal transplant patients. *Transplantation* 1997;**63**:1634.
31. Morales E, Alegre R, Herrero JC, et al. Hepatitis-C-virus-associated cryoglobulinaemic membranoproliferative glomerulonephritis in patients infected by HIV. *Nephrol Dial Transplant* 1997;**12**:1980.
32. Cheng JT, Anderson HLJ, Markowitz GS, et al. Hepatitis C virus-associated glomerular disease in patients with human immunodeficiency virus coinfection. *J Am Soc Nephrol* 1999;**10**:1566.
33. Stokes MB, Chawla H, Brody RI, et al. Immune complex glomerulonephritis in patients coinfecting with human immunodeficiency virus, hepatitis C virus. *Am J Kidney Dis* 1997;**29**:514.
34. Soma J, Saito T, Taguma Y, et al. High prevalence, adverse effect of hepatitis C virus infection in type II diabetic-related nephropathy. *J Am Soc Nephrol* 2000;**11**:690.
35. Crook ED, Penumalee S, Gavini B, Filippova K. Hepatitis C is a predictor of poorer renal survival in diabetic patients. *Diabetes Care* 2005;**28**:2187.
36. Chadban SJ, Atkins RC. Glomerulonephritis. *Lancet* 2005;**365**:1797.
37. Misiani R, Bellavita P, Fenili D, et al. Interferon alfa-2a therapy in cryoglobulinemia associated with hepatitis C virus. *N Engl J Med* 1994;**330**:751.
38. Sabry AA, Sobh MA, Sheashaa HA, et al. Effect of combination therapy (ribavirin, interferon) in HCV-related glomerulopathy. *Nephrol Dial Transplant* 2002;**17**:1924.
39. Bruchfeld A, Lindahl K, Stahle L, et al. Interferon, ribavirin treatment in patients with hepatitis C-associated renal disease, renal insufficiency. *Nephrol Dial Transplant* 2003;**18**:1573.
40. Rossi P, Bertani T, Baio P, et al. Hepatitis C virus-related cryoglobulinemic glomerulonephritis: long-term remission after antiviral therapy. *Kidney Int* 2003;**63**:2236.
41. Alric L, Plaisier E, Thebault S, et al. Influence of antiviral therapy in hepatitis C virus-associated cryoglobulinemic MPGN. *Am J Kidney Dis* 2004;**43**:617.
42. Lamb M, Marks I, Wynohradnyk L, et al. Forty kilodalton peginterferon alfa-2a (Pegasys) can be administered safely in patients with end-stage renal disease. *Hepatology* 2001;**34**:326A.
43. Gupta SK, Pittenger AL, Swan SK, et al. Single-dose pharmacokinetics, safety of pegylated interferon-alpha2b in patients with chronic renal dysfunction. *J Clin Pharmacol* 2002;**42**:1109.
44. Hu SL, Jaber BL. Ribavirin monotherapy for hepatitis C virus-associated membranous nephropathy. *Clin Nephrol* 2005;**63**:41.
45. Kamar N, Sandres-Saune K, Selves J, et al. Long-term ribavirin therapy in hepatitis C virus-positive renal transplant patients: effects on renal function, liver histology. *Am J Kidney Dis* 2003;**42**:184.
46. Pham HP, Feray C, Samuel D, et al. Effects of ribavirin on hepatitis C-associated nephrotic syndrome in four liver transplant recipients. *Kidney Int* 1998;**54**:1311.
47. Kamar N, Chatelut E, Manolis E, et al. Ribavirin pharmacokinetics in renal, liver transplant patients: evidence that it depends on renal function. *Am J Kidney Dis* 2004;**43**:140.
48. Bruchfeld A, Lindahl K, Schvarcz R, Stahle L. Dosage of ribavirin in patients with hepatitis C should be based on renal function: a population pharmacokinetic analysis. *Ther Drug Monit* 2002;**24**:701.
49. Lin CC, Philips L, Xu C, Yeh LT. Pharmacokinetics and safety of viramidine, a prodrug of ribavirin, in healthy volunteers. *J Clin Pharmacol* 2004;**44**:265.
50. Lindahl K, Schvarcz R, Bruchfeld A, Stahle L. Evidence that plasma concentration rather than dose per kilogram body weight predicts ribavirin-induced anaemia. *J Viral Hepat* 2004;**11**:84.
51. Kamar N, Boulestin A, Selves J, et al. Factors accelerating liver fibrosis progression in renal transplant patients receiving ribavirin monotherapy for chronic hepatitis C. *J Med Virol* 2005;**76**:61.
52. Zaja F, De Vita S, Mazzaro C, et al. Efficacy, safety of rituximab in type II mixed cryoglobulinemia. *Blood* 2003;**101**:3827.
53. Roccatello D, Baldovino S, Rossi D, et al. Long-term effects of anti-CD20 monoclonal antibody treatment of cryoglobulinaemic glomerulonephritis. *Nephrol Dial Transplant* 2004;**19**:3054.
54. Quartuccio L, Soardo G, Romano G, et al. Rituximab treatment for glomerulonephritis in HCV-associated mixed cryoglobulinemia: efficacy, safety in the absence of steroids. *Rheumatology* 2006;**45**:842.
55. Basse G, Ribes D, Kamar N, et al. Rituximab therapy for de novo mixed cryoglobulinemia in renal-transplant patients. *Transplantation* 2005;**80**:1560.
56. Saadoun D, Resche Rigon M, Sene D, et al. Rituximab plus Peg-interferon-alpha/ribavirin compared with Peg-interferon-alpha/ribavirin in hepatitis C-related mixed cryoglobulinemia. *Blood* 2010;**116**:326–34.
57. Dammacco F, Tucci FA, Lauletta G, et al. Pegylated interferon-alpha, ribavirin, and rituximab combined therapy of hepatitis C virus-related mixed cryoglobulinemia: a long-term study. *Blood* 2010;**116**:343–53.
58. Ghany MG, Strader DB, Thomas DL, Seef LB. AASLD practice guidelines. Diagnosis, management, and treatment of hepatitis C: an update. *Hepatology* 2009;**49**:1335–74.
59. Bocci V, Pacini A, Muscettola M, et al. Renal filtration, absorption, and catabolism of human alpha interferon. *J Interferon Res* 1981;**1**:347–52.
60. Glue P. The clinical pharmacology of ribavirin. *Semin Liver Dis* 1999;**19**(Suppl 1):17–24.
61. Gupta SK, Pittenger AL, Swan SK, et al. Single-dose pharmacokinetics and safety of pegylated interferon-alpha 2b in patients with chronic renal dysfunction. *J Clin Pharmacol* 2002;**42**:1109–15.

62. Brochot E, Castelain J, Duverlie G, et al. Ribavirin monitoring in chronic hepatitis C therapy: anemia versus efficacy. *Antivir Ther* 2010;**15**:687–95.
63. Casanovas Taltavull T, Baliellas Comellas C, Cruzado Garrirt JM. Results of hepatitis C virus treatment in patients on hemodialysis: data from published meta-analyses in 2008. *Transplant Proc* 2009;**41**:2082–4.
64. Fabrizi F, Ganeshan SV, Lunghi G, Messa P, Martin P. Antiviral therapy of hepatitis C in chronic kidney diseases: meta-analysis of controlled clinical trials. *J Viral Hepat* 2008;**15**:600–6.
65. Gordon CE, Uhlig K, Lau J, Levey AS, Wong JB. Interferon treatment in hemodialysis patients with chronic hepatitis C virus infection: a systematic review of the literature and meta-analysis of treatment efficacy and harms. *Am J Kidney Dis* 2008;**51**:263–7.
66. Alavian SM, Tabatabaei SV. Meta-analysis of factors associated with sustained viral response in patients on hemodialysis treated with standard or pegylated interferon for hepatitis C infection. *Iran J Kidney Dis* 2010;**4**:181–94.
67. Rendina M, Schena A, Castellaneta NM, et al. The treatment of chronic hepatitis C with peginterferon alpha-2a (40 kDa) plus ribavirin in hemodialysed patients awaiting renal transplant. *J Hepatol* 2007;**46**:768–74.
68. Fabrizi F, Messa P, Basile C, Martin P. Hepatic disorders in chronic kidney disease. *Nat Rev Nephrol* 2010;**6**:721–6.
69. Liu CH, Liang CC, Liu CJ, et al. Pegylated interferon alfa-2a monotherapy for hemodialysis patients with acute hepatitis C. *Clin Infect Dis* 2010;**51**:541–9.
70. Kamar N, Toupance O, Buchler M, Sandres-Saune K, Izopet J, Durand D, et al. Evidence that clearance of hepatitis C virus RNA after alpha-interferon therapy in dialysis patients is sustained after renal transplantation. *J Am Soc Nephrol* 2003;**14**:2092–8.
71. Nicot F, Kamar N, Mariamé B, et al. No evidence of occult hepatitis C virus (HCV) infection in serum of HCV antibody-positive HCV RNA-negative kidney-transplant patients. *Transplant Int* 2010;**23**:594–601.