



Multidetector CT evaluation of potential right lobe living donors for liver transplantation

Mohamed Saied Abdelgawad & Osama L. El-Abd

To cite this article: Mohamed Saied Abdelgawad & Osama L. El-Abd (2011) Multidetector CT evaluation of potential right lobe living donors for liver transplantation, Alexandria Journal of Medicine, 47:4, 309-315, DOI: [10.1016/j.ajme.2011.06.004](https://doi.org/10.1016/j.ajme.2011.06.004)

To link to this article: <https://doi.org/10.1016/j.ajme.2011.06.004>



© 2011 Alexandria University Faculty of Medicine. Production and hosting by Elsevier B.V. All rights reserved.



Published online: 17 May 2019.



Submit your article to this journal [↗](#)



Article views: 51



View related articles [↗](#)



ORIGINAL ARTICLE

Multidetector CT evaluation of potential right lobe living donors for liver transplantation

Mohamed Saied Abdelgawad *, Osama L. El-Abd

National Liver Institute, El-Menoufiya University, Shebein El-Koom, Alexandria, Egypt

Received 4 June 2011; accepted 18 June 2011

KEYWORDS

Liver transplantation;
Multidetector CT;
Living donors

Abstract *Introduction:* Living donor liver transplantation is increasingly being used to help compensate for the increasing shortage of cadaveric liver grafts. However, the extreme variability of the hepatic vascular systems can impede this surgical procedure.

Aim of the work: The aim of the study was to demonstrate the role of multidetector CT (MDCT) in evaluation of potential right lobe living donors for liver transplantation.

Methods: The study included twenty-five liver donors in pre-operative assessment before liver transplantation. Triphasic abdominal MDCT. Post-processing techniques including multiplanner reformation (MPR), maximum intensity projection (MIP) and volume rendering (VR).

Results: Twenty donors had Michels type I variant, one donor with type Michels type II, while the remaining four had Michels type III. Sixteen donors had dominant right hepatic vein, five had late confluence of the middle hepatic vein; while remaining four donors had dominant middle hepatic vein. Twenty donors had type A portal vein branching, while the remaining five had type B portal vein branching. The percentage of right hepatic lobe for the whole liver volume ranging from 40% to 55%.

Conclusion: Multidetector CT provides important information in evaluation of potential living donors for liver transplantation.

© 2011 Alexandria University Faculty of Medicine. Production and hosting by Elsevier B.V. All rights reserved.

* Corresponding author.

E-mail address: mselgawad@yahoo.com (M.S. Abdelgawad).



1. Introduction

To meet the needs of an increasing number of potential liver transplant recipients, alternative approaches rather than cadaveric liver transplantation have been developed, including living donor liver transplantation (LDLT). However, LDLT may cause morbidity in an otherwise healthy donor who generously takes such an important risk for a loved one. Therefore, donor safety is a primary concern, and selection protocols are of paramount importance to preserve donor health by excluding unsuitable candidates for either medical

or anatomic reasons. With the development of the new multi-detector computed tomographic (CT) techniques, the radiologist plays a relevant role, providing, with a minimally invasive procedure, valuable information that will be useful in choosing the most suitable candidate and in identifying anatomic variants that may alter the surgical approach.¹

The liver has three major vascular systems upon which hepatic segmental anatomy nomenclature is based: two hepatopetal systems (arterial and portal venous systems) and the hepatic venous system for drainage. The segmental division of the liver, first described by the French surgeon Couinaud, has functional implications because each segment has its own vascular supply and may be resected without affecting the rest of the liver parenchyma. This nomenclature should be helpful in establishing clear communication with the transplantation surgeon.²

In normal arterial anatomy, the common hepatic artery arises from the celiac trunk, from which the left gastric, gastroduodenal, and proper hepatic arteries arise, the latter dividing distally at the hilus into right and left branches.³ The artery to segment IV is usually considered a small branch from the LHA.¹

In normal portal anatomy, the portal vein bifurcates at the hilus into right and left pedicles. The right pedicle in turn bifurcates into anterior and posterior branches, both of which further bifurcate into ascending and descending branches. Each of these four branches supplies a segment of the right lobe. The left pedicle divides into three branches, one for each segment of the left lobe.¹

The hepatic venous anatomy is extremely variable, the most common pattern consisting of three main hepatic veins. The right hepatic vein (RHV) is often the largest of the three and drains the greatest part of the right lobe.⁴

The middle hepatic vein (MHV) drains the central sector of the liver (segments IV, V, and VIII), and its branching and confluence pattern is quite variable.⁵

The MHV usually joins the left hepatic vein (LHV), which drains the LLS (segments II and III), to form a common trunk that empties into the inferior vena cava (IVC).¹

Vascular variations affecting arterial, portal venous, and hepatic venous supply are quite common. Arterial variants are present in approximately 42% of cases.³

In his classic report, Michels first described a basic classification system for common and rare hepatic arterial variants, the most common of which were a replaced or accessory RHA arising from the superior mesenteric artery (SMA) and a replaced or accessory LHA arising from the left gastric artery^{3,6,7} (Table 1).

Variants of the artery to segment IV are seen in nearly 47% of cases, a fact that may have relevant implications in that segment IV may be supplied by one or more branches arising from the LHA, the RHA, or both.^{8,9}

Portal venous variants appear in approximately 10% of cases. These variants mainly affect the right portal vein (RPV) and may be classified into five types of branching as defined by the origin of the branch of the anterior segments. Type A, normal anatomy; type B, early bifurcation or trifurcation; type C, extra-parenchymal branching of the anterior branch from the LPV; type D, intraparenchymal branching of the anterior branch from the LPV; and type E, an undivided main portal trunk. Types B and C result in two venous openings that should be surgically reconstructed in cases of right lobe dona-

Table 1 Michel classification of the hepatic arterial anatomy.¹

Type	Description
I	Hepatic trunk arising from CHA
II	Replaced LHA arising from LGA
III	Replaced RHA arising from SMA
IV	Replaced LHA and replaced RHA
V	Accessory LHA arising from LGA
VI	Accessory RHA arising from SMA
VII	Accessory LHA and RHA
VIII	Replaced RHA and accessory LHA
IX	Replaced LHA and accessory RHA
X	Entire hepatic trunk arising from SMA

tion. The chosen technique for reconstruction depends on the distance between the right anterior and posterior branches. Types D and E represent absolute contraindications for right lobe donation.^{9,10}

LDLT first became an important treatment choice in children with end-stage liver diseases, and mainly left lobe lateral segment (LLS) grafts were used. As experience accumulated in these cases, the practice was extended to right lobe grafts. There are many other types of grafts (monosegmental, left lobar with or without the MHV, left lobar with the MHV plus the caudate lobe, right lateral sector, dual, whole liver); nevertheless, right lobe and LLS grafts represent the two ends of a wide spectrum, with quite different technical considerations.¹²

During harvest of the LLS, parenchymal transection is performed along the falciform ligament, whereas during harvest of the right lobe it is performed approximately 1 cm to the right of the MHV and parallel to the Cantlie line, which runs from the gallbladder fossa to the IVC, following the MHV.^{13,14}

Total liver volume has been reported to have relatively constant relation to body weight; however, lobar volumes are quite variable.¹⁵

The ratio between graft weight and recipient body weight or between graft volume and the estimated standard liver volume of the recipient has been used to determine the ideal liver volume for recipients. It is considered acceptable when these parameters are at least 0.8% and 40%, respectively, provided that the liver parenchyma is normal, with no fatty infiltration. The accepted remaining volume for the donors is between 35% and 40% of the total liver volume.¹⁶

When the graft volume is insufficient, mainly in right lobe donation, there is a risk of "small-for-size" syndrome. Grafts are prone to dysfunction, not only because of insufficient liver volume, but also because the graft may sustain injury related to excessive portal perfusion.¹⁷ In LLS transplantation, grafts tend to be large for size, which may cause vascular compression and difficulty in abdominal closure.¹ Detection of biliary anatomical variant is crucial before, transplantation and this is better assessed by Magnetic resonance cholangiopancreatography (MRCP).¹⁰

The aim of the study was to demonstrate the role of multi-detector CT (MDCT) in evaluation of potential right lobe living donors for liver transplantation.

2. Methods

This study included the twenty-five donors who underwent right lobe donation for liver transplantation.

The objectives of multidetector CT in the evaluation of potential donors are (a) to depict the arterial, portal venous, and hepatic venous anatomy, (b) to help identify important vascular variants, (c) to help identify the origin and course of the dominant arteries to segment IV, (d) to allow volumetric measurements of the graft, whole liver, and remnant liver, and (e) to help detect unexpected focal or diffuse liver lesions.¹

The equipments used were:

Siemens Somatom sensation 20 slices unit kV/effective mAs/rotation time (sec): 120 kV/225 effective mAs/0.75 s; slice thickness, 0.6 mm (12 donors).

Toshiba Aquillon 16-MDCT unit; kV/effective mAs/rotation time (sec): 120 kV/225 effective mAs/0.5 s; slice thickness 1 mm (eight donors).

Some cases on Toshiba Aquillon 128-MDCT unit kV/effective mAs/rotation time (sec): 120 kV/225 effective mAs/0.35 s; slice thickness 0.5 mm (five donors).

The CT examination was performed first, with a plain scan of the liver, followed by a triphasic contrast-enhanced CT at 25 s, 45 s, and 70 s after an injection of 120 mL of nonionic contrast medium (Opray 350 "ivoversol") (350 mg I/mL) given at a peripheral vein at a rate of 3 mL/s, to catch the early arterial phase, late arterial–early portal venous phase, and hepatic venous phase, respectively.

The data acquired were transferred to a workstation either Siemens CT workstation, Vitrea or Osirix for reconstruction of the 3D images of the portal venous system, and hepatic veins and arteries. The data were processed with the techniques of volumetric reconstruction, multiplanar reconstruction, and maximum intensity projection.

Total liver and graft volumes were measured with a paintbrush method after hand tracing of axial liver margins, the frequency of selection depending on changes in liver contour. Particular care was taken to exclude the IVC, extrahepatic portal vein, and major fissures.¹⁸

The virtual hepatectomy plane was chosen as follows: for right lobe harvest, a relatively avascular plane to the right of the MHV.¹

Analysis of the image data was based on source images as well as two-dimensional multiplanar reformatted images and three-dimensional (3D) MIP and VR post processed images created on the available workstation.

Overlapping thin-slab axial MIP images were used to depict the arteries to segment IV, whereas thin- and thick-slab axial and coronal MIP images were used to depict the hepatic venous anatomy. This technique offers excellent contrast between the liver parenchyma and the enhanced vessels, which is useful for evaluating hepatic veins and arteries supplying segment IV. On the other hand, the origin or course of contrast material enhanced arteries reconstructed with VR techniques and overlapping the hepatic parenchyma may be sometimes misinterpreted.¹⁹

3. Results

The demographic data of the donors; they were 22 males and three females; ranging in age from 28 to 45 years.

The arterial anatomical variant was as: 20 donors (80%) had Michels type I variant, one donor (4%) with type Michels type II, while the remaining four (16%) had Michels type III. (Figs. 1 and 2)

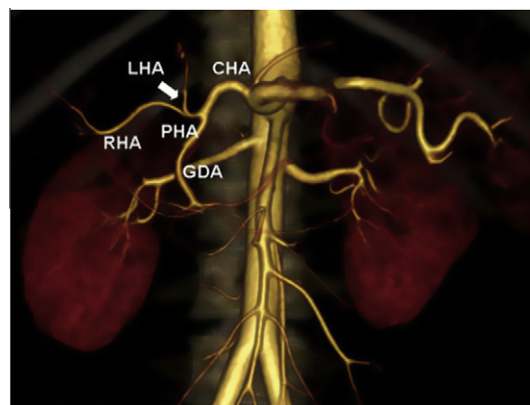


Figure 1 Three-dimensional volume-rendered (VR) image shows the normal hepatic arterial anatomy. CHA (common hepatic artery), GDA (gastroduodenal artery), LHA (left hepatic artery), PHA (proper hepatic artery) and its bifurcation (arrow), RHA (right hepatic artery). Michel type I.

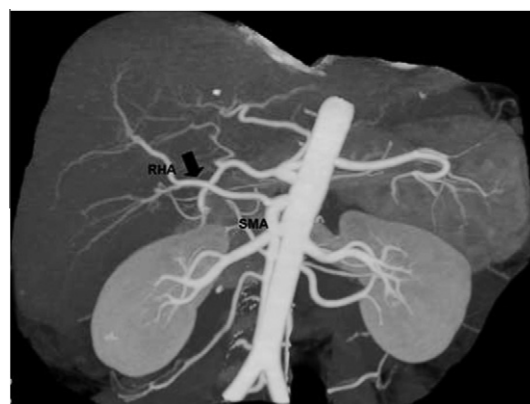


Figure 2 (MIP) image from CT data shows a replaced right hepatic artery RHA (arrow) arising from the superior mesenteric artery (SMA). Michel type III.

Twenty donors (80%) had type A portal vein branching, while the remaining five (20%) had type B portal vein branching. (Figs. 3 and 4)

Regarding the hepatic venous anatomical variant; 16 donors (64%) had dominant right hepatic vein, five had late (20%) confluence of the middle hepatic vein; while remaining four donors (16%) had dominant middle hepatic vein. (Figs. 5–8). Three cases had right inferior accessory hepatic vein; yet the distance from the confluence of the IVC was less than 40 mm.

The percentage of right hepatic lobe for the whole liver volume ranged from 40% to 55%. (Fig. 9)

4. Discussion

It should be emphasized that the evaluation of the donor must be individualized and should never be performed apart from evaluation of the recipient; it is the combination of characteristics of both the donor and the recipient that helps determine whether the two are suitable for consideration for LDLT.

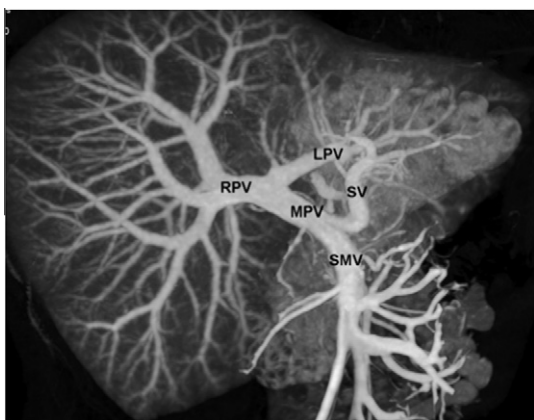


Figure 3 Normal portal venous anatomy. The left (LPV), main (MPV), and right portal (RPV) vein are well visualized. Superior mesenteric vein (SMV) and splenic vein (SV). Type A.

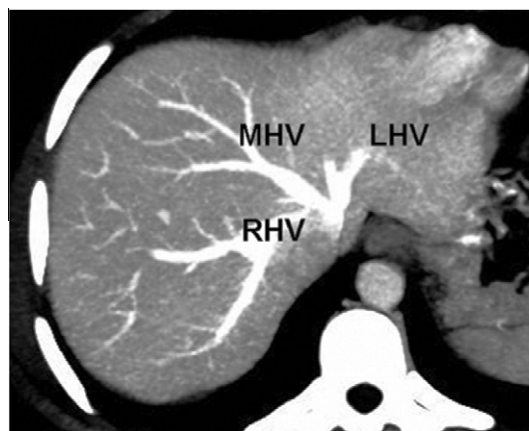


Figure 5 Axial MIP, showing normal hepatic venous anatomy with the left hepatic vein (LHV) forms a common trunk with the middle hepatic vein (MHV), whereas a large right hepatic vein (RHV) drains the right lobe independently.

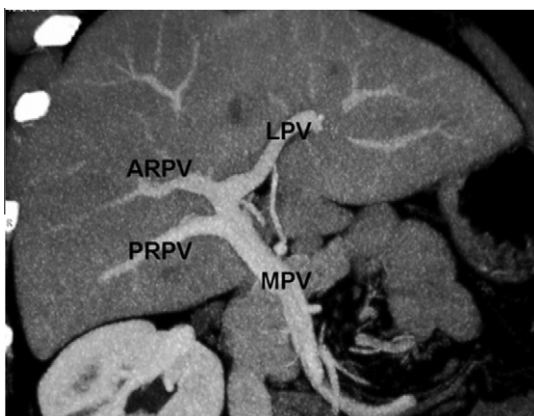


Figure 4 Coronal MIP image shows a trifurcation of the main portal vein (Type B), into the anterior right (ARPV), posterior right (PRPV), and left portal vein (LPV). In cases of right lobe donation, this variant would lead to the creation of two venous openings that should be reconstructed.

Hence, close cooperation between radiologists and surgeons is mandatory to achieve optimal results.²⁰

Multidetector CT is an excellent tool for mapping out the hepatic vascular anatomy; it is essential that the radiologist be familiar with the normal liver anatomy and be able to recognize the presence of variants, especially those considered relative or absolute contraindications for donation, those requiring reconstruction or multiple anastomoses, and those that may alter the surgical approach.^{21,22}

Although virtually none of the known arterial variants is considered a contraindication for surgery, the hepatic artery is subject to many anatomic variations that may alter the surgical approach.²³

In this study 20 donors (80%) had Michels type I variant, one donor (4%) with Michels type II, while the remaining 4 (16%) had Michels type III.

When normal arterial anatomy is found, a hepatic artery with sufficient length for reconstruction is difficult to obtain because only a part of the liver is harvested. Thus, it is important to recognize the proper hepatic artery bifurcation and to measure the length of the RHA (in cases of right lobe dona-

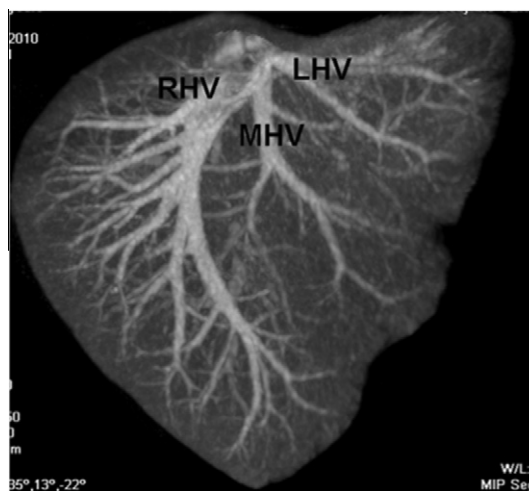


Figure 6 Coronal MIP, showing normal hepatic venous anatomy of the same patient with the left hepatic vein (LHV) forms a common trunk with the middle hepatic vein (MHV), whereas a large right hepatic vein (RHV) drains the right lobe independently.

tion) or LHA (in cases of LLS donation) before the next bifurcation. Even so, findings such as filiform or redundant arteries may impede arterial reconstruction.¹⁸

Some variants are suitable for the transplantation surgeon, whereas others are not. A replaced RHA or LHA enables the surgeon to perform safer anastomoses because these arteries are usually longer. In contrast, the presence of an accessory RHA or LHA would theoretically lead to the creation of a dual anastomosis because hepatic arteries are, as a rule, considered end arteries. However, there are sometimes intrahepatic anastomoses, which allow the ligation of the smaller artery.¹⁰

Arterial variants may consist of the substitution of a single branch, such as the RHA or LHA, for two or more branches. Such a variant is more common and usually more complex in the LHA than in the RHA. The radiologist should measure the distance between these two or more branches; if they are close

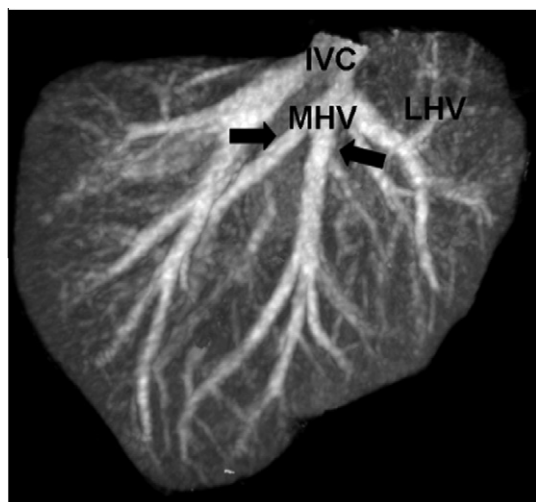


Figure 7 Coronal MIP showing late confluence of two branches (arrows) to form the middle hepatic vein (MHV) very close to the inferior vena cava (IVC).

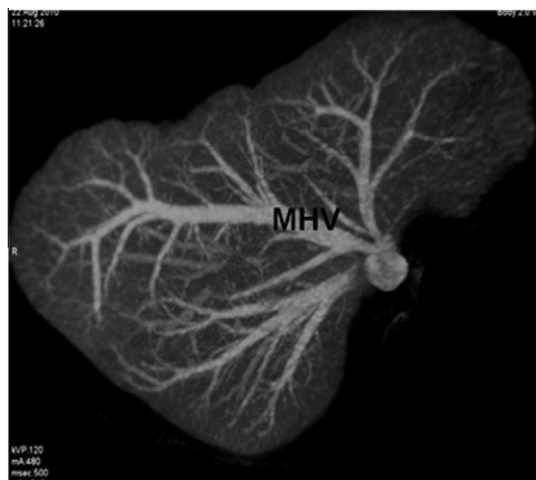


Figure 8 Axial MIP shows a large middle hepatic vein (MHV) that drains the anterior segments of the right hepatic lobe.

together, a single anastomosis can be performed; otherwise, multiple arterial reconstruction may be necessary.¹⁶

After right lobe resection, the remnant liver volume approaches the critical limit; thus, undisturbed inflow to segment IV, which accounts for up to 40% of post surgical liver volume, is crucial to prevent liver failure. However, as mentioned earlier, the arterial supply to segment IV may be quite variable. To preserve the branches to segment IV, the radiologist should carefully identify their precise origin as well as the distance to the bifurcation of the proper hepatic artery. Because the branches will traverse the transection plane, one should be especially aware of when they arise from the RHA in cases of right lobe donation.¹⁰

When normal portal venous anatomy is found, in cases of right lobe donation, the length of the RPV from the main trunk bifurcation to the next bifurcation should be measured.¹⁶

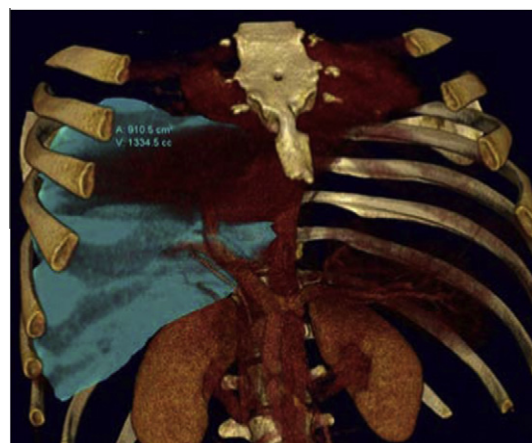


Figure 9 Shows the calculated volume of the right lobe graft (1334 cc [cm³]).

In this study 20 patient (80%) had type A portal vein branching, while the remaining five had type B (20%) portal vein branching.

Portal venous variants mostly affect right lobe donation. Particular attention should be paid to variants resulting in two venous openings, namely, trifurcation or extra-parenchymal branching of the anterior branch from the LPV. If the branches are close together, they can be joined together to make a single orifice (venoplasty). If they are not, they can be anastomosed separately one to the RPV and one to the LPV in the recipient or connected to a Y-shaped vascular graft for a single anastomosis. Therefore, the distance between the two branches must be carefully measured. Intra-parenchymal branching of the anterior branch from the LPV and an undivided MPV are considered absolute contraindications for right lobe donation.¹⁶

Images of the hepatic venous anatomy, even when this anatomy is considered normal, should be used to guide the surgeon during the retrieval procedure. Large venous branches that cross the transection planes may cause unexpected bleeding during retrieval and should be preserved when they are of significant size (i.e., 5 mm in diameter). If these significant branches are transected, the drained sectors may also develop congestion and late ischemia, compromising the functional volume of the graft. During harvesting of the right lobe, significant accessory RHVs that drain a wide area of the posterior sector should be preserved and implanted separately on the recipient IVC. When such veins are identified, their distance to the RHV should be measured in the coronal plane. If this distance exceeds 4 cm, it may be difficult to surgically implant both veins with a single partially occluding clamp.¹⁷

MHV anatomy is actually the key to right lobe donation, and variations in the confluence pattern of the MHV may be of paramount importance. Usually, during right-sided hepatectomy, one or more significant branches of the MHV will need to be transected.²⁴

This situation is more common in cases of either (a) late confluence of branches forming the MHV or (b) dominance of the MHV over the RHV, in which case the MHV can provide drainage for a large portion of the right lobe. However, reconstruction of the MHV is necessary if the resection plane contains significant segment V or VIII veins.¹³

In this study 16 donors (64%) had dominant right hepatic vein, five (20%) had late confluence of the middle hepatic vein; while remaining four donors (16%) had dominant middle hepatic vein.

Some authors believe that including the MHV in the graft (extended right lobe donation), which is a more compromising procedure for the donor, is a simpler and more straight forward approach, provided the liver remnant is adequate.⁴

In all such cases, 3D models are helpful for depicting the precise relationship between hepatic veins. During harvesting of the LLS, unexpected bleeding may occur when a large tributary to the LHV, draining part of segment IV, traverses the falciform ligament.¹¹

An LHV draining independently into the IVC is a suitable variation; on the contrary, variations resulting in two venous openings, namely, veins of segments II and III draining independently, should be reconstructed.²⁵

Different studies have reported excellent agreement between real graft volumes and measured CT volumes. Obtaining accurate estimates of the graft and whole liver volumes is critical to ensure that the graft and remnant liver contain sufficient volume to (a) guarantee liver regeneration and (b) sustain function in the immediate postoperative period. Therefore, the virtual hepatectomy plane should be carefully evaluated, especially in right lobe donors with no clear anatomic landmarks to indicate the limits between the right and left lobes.¹⁹

In this study the percentage of right hepatic lobe for the whole liver volume ranged from 40% to 55%.

It has been reported that liver regeneration terminates after the liver has achieved 75–95% of its original size, approximately 6–8 weeks after harvest. The regeneration ratio is proportional to the amount of resection, being significantly higher after right lobe donation than after LLS donation, since the remnant liver has to regenerate more liver volume to meet functional demands.²⁶

5. Conclusion

Multidetector CT provides important information in evaluation of potential living donors for liver transplantation. It plays a relevant role, providing, with a minimally invasive procedure, valuable information that will be useful in choosing the most suitable candidate and in identifying anatomic variants that may alter the surgical approach.

References

- Alonso-Torres A, Fernandez-Cuadrado J, Pinilla I, Parron M, de Vicente E, Lopez-Santamaria M. Multidetector CT in the evaluation of potential living donors for liver transplantation. *Radiographics* 2005;**25**(4):1017–30.
- Soyer P, Bluemke DA, Bliss DF, Woodhouse CE, Fishman EK. Surgical segmental anatomy of the liver: demonstration with spiral CT during arterial portography and multiplanar reconstruction. *AJR Am J Roentgenol* 1994;**163**(1):99–103.
- Gruttadauria S, Foglieni CS, Doria C, Luca A, Lauro A, Marino IR. The hepatic artery in liver transplantation and surgery: vascular anomalies in 701 cases. *Clin Transplant* 2001;**15**(5):359–63.
- Fan ST, De Villa VH, Kiuchi T, Lee SG, Makuuchi M. Right anterior sector drainage in right-lobe live-donor liver transplantation. *Transplantation* 2003;**75**(Suppl. 3):S25–7.
- Marcos A, Orloff M, Miele L, Olzinski AT, Renz JF, Sitzmann JV. Functional venous anatomy for right-lobe grafting and techniques to optimize outflow. *Liver Transpl* 2001;**7**(10):845–52.
- Michels NA. Newer anatomy of the liver and its variant blood supply and collateral circulation. *Am J Surg* 1966;**112**(3):337–47.
- Hiatt JR, Gabbay J, Busuttill RW. Surgical anatomy of the hepatic arteries in 1000 cases. *Ann Surg* 1994;**220**(1):50–2.
- Lee SS, Kim TK, Byun JH, Ha HK, Kim PN, Kim AY, et al. Hepatic arteries in potential donors for living related liver transplantation: evaluation with multi-detector row CT angiography. *Radiology* 2003;**227**(2):391–9.
- Pannu HK, Maley WR, Fishman EK. Liver transplantation: preoperative CT evaluation. *Radiographics*, 2001;21 Spec No:S133–46.
- Nakamura T, Tanaka K, Kiuchi T, Kasahara M, Oike F, Ueda M, et al. Anatomical variations and surgical strategies in right lobe living donor liver transplantation: lessons from 120 cases. *Transplantation* 2002;**73**(12):1896–903.
- Deshpande RR, Heaton ND, Rela M. Surgical anatomy of segmental liver transplantation. *Br J Surg* 2002;**89**(9):1078–88.
- Chen CL, Fan ST, Lee SG, Makuuchi M, Tanaka K. Living-donor liver transplantation: 12 years of experience in Asia. *Transplantation* 2003;**75**(Suppl. 3):S6–11.
- Broering DC, Sterneck M, Rogiers X. Living donor liver transplantation. *J Hepatol* 2003;**38**(Suppl. 1):S119–35.
- Williams RS, Alisa AA, Karani JB, Muiesan P, Rela SM, Heaton ND. Adult-to-adult living donor liver transplant: UK experience. *Eur J Gastroenterol Hepatol* 2003 Jan;**15**(1):7–14.
- Kamel IR, Kruskal JB, Warmbrand G, Goldberg SN, Pomfret V, Raptopoulos V. Accuracy of volumetric measurements after virtual right hepatectomy in potential donors undergoing living adult liver transplantation. *AJR Am J Roentgenol* 2001;**176**(2):483–7.
- Chen YS, Cheng YF, De Villa VH, Wang CC, Lin CC, Huang TL, et al. Evaluation of living liver donors. *Transplantation* 2003;**75**(Suppl. 3):S16–19.
- Kamel IR, Kruskal JB, Pomfret EA, Keogan MT, Warmbrand G, Raptopoulos V. Impact of multidetector CT on donor selection and surgical planning before living adult right lobe liver transplantation. *AJR Am J Roentgenol* 2001;**176**(1):193–200.
- Kruskal JB, Raptopoulos V. How I do it: pre-operative CT scanning for adult living right lobe liver transplantation. *Eur Radiol* 2002;**12**(6):1423–31.
- Ishifuro M, Horiguchi J, Nakashige A, Tamura A, Marukawa K, Fukuda H, et al. Use of multidetector row CT with volume renderings in right lobe living liver transplantation. *Eur Radiol* 2002;**12**(10):2477–83.
- Byun JH, Kim TK, Lee SS, Lee JK, Ha HK, Kim AY, et al. Evaluation of the hepatic artery in potential donors for living donor liver transplantation by computed tomography angiography using multidetector-row computed tomography: comparison of volume rendering and maximum intensity projection techniques. *J Comput Assist Tomogr* 2003;**27**(2):125–31.
- Limanond P, Raman SS, Ghobrial RM, Busuttill RW, Saab S, Lu DS. Preoperative imaging in adult-to-adult living related liver transplant donors: what surgeons want to know. *J Comput Assist Tomogr* 2004;**28**(2):149–57.
- Sahani D, D'Souza R, Kadavigere R, Hertl M, McGowan J, Saini S, et al. Evaluation of living liver transplant donors: method for precise anatomic definition by using a dedicated contrast-enhanced MR imaging protocol. *Radiographics* 2004;**24**(4):957–67.

23. Erbay N, Raptopoulos V, Pomfret EA, Kamel IR, Kruskal JB. Living donor liver transplantation in adults: vascular variants important in surgical planning for donors and recipients. *AJR Am J Roentgenol* 2003;**181**(1):109–14.
24. Kamel IR, Lawler LP, Fishman EK. Variations in anatomy of the middle hepatic vein and their impact on formal right hepatectomy. *Abdom Imaging* 2003;**28**(5):668–74.
25. Egawa H, Inomata Y, Uemoto S, Asonuma K, Kiuchi T, Okajima H, et al. Hepatic vein reconstruction in 152 living-related donor liver transplantation patients. *Surgery* 1997;**121**(3):250–7.
26. Kwon KH, Kim YW, Kim SI, Kim KS, Lee WJ, Choi JS. Postoperative liver regeneration and complication in live liver donor after partial hepatectomy for living donor liver transplantation. *Yonsei Med J* 2003;**44**(6):1069–77.