

No Evidence for Circulating Retina Specific Autoreactive T-cells in Latent Tuberculosis-associated Uveitis and Sarcoid Uveitis

Benjamin Schrijver, Hannah Hardjosantoso, Josianne C. E. M Ten Berge, Marco W. J. Schreurs, P. Martin Van Hagen, Rik A. Brooimans, Aniki Rothova & Willem A. Dik

To cite this article: Benjamin Schrijver, Hannah Hardjosantoso, Josianne C. E. M Ten Berge, Marco W. J. Schreurs, P. Martin Van Hagen, Rik A. Brooimans, Aniki Rothova & Willem A. Dik (2020): No Evidence for Circulating Retina Specific Autoreactive T-cells in Latent Tuberculosis-associated Uveitis and Sarcoid Uveitis, Ocular Immunology and Inflammation, DOI: [10.1080/09273948.2019.1698752](https://doi.org/10.1080/09273948.2019.1698752)

To link to this article: <https://doi.org/10.1080/09273948.2019.1698752>



© 2019 The Author(s). Published with license by Taylor & Francis Group, LLC.



[View supplementary material](#)



Published online: 08 Jan 2020.



[Submit your article to this journal](#)



Article views: 561



[View related articles](#)



[View Crossmark data](#)



[Citing articles: 3](#) [View citing articles](#)

No Evidence for Circulating Retina Specific Autoreactive T-cells in Latent Tuberculosis-associated Uveitis and Sarcoid Uveitis

Benjamin Schrijver, BSc^{a,b}, Hannah Hardjosantoso, MD^{b,c}, Josianne C. E. M Ten Berge, MD, PhD^{b,c}, Marco W. J. Schreurs, PhD^{a,b}, P. Martin Van Hagen, MD PhD^{a,b,d}, Rik A. Brooimans, PhD^{a,b}, Aniki Rothova, MD, PhD^{b,c}, and Willem A. Dik, PhD^{a,b}

^aDepartment of Immunology, Laboratory Medical Immunology, Erasmus MC University Medical Center Rotterdam, Rotterdam, the Netherlands; ^bRare Immune Diseases Center, Erasmus MC Medical Center, Rotterdam, the Netherlands; ^cDepartment of Ophthalmology, Erasmus MC University Medical Center Rotterdam, Rotterdam, the Netherlands; ^dDepartment of Internal Medicine, Section Clinical Immunology, Erasmus MC University Medical Center Rotterdam, Rotterdam, the Netherlands

ABSTRACT

Purpose: To detect circulating retina-specific autoreactive CD4⁺ T-cells and antiretinal antibodies (ARA) in latent tuberculosis (TB)-associated uveitis or sarcoid uveitis patients.

Methods: The presence of crude retinal extract (RE) autoreactive CD4⁺ T-cells was determined by a highly sensitive flowcytometric-based technique examining co-expression of CD25 and CD134 (OX40) on RE stimulated PBMC. The presence of ARA in available matched serum samples was assessed by indirect immunofluorescence.

Results: No autoreactive CD4⁺ T-cells against RE could be detected in either latent TB-associated uveitis or sarcoid uveitis patients, while ARA were detected in the serum of the majority (5/6) of latent TB-associated uveitis and all (3/3) sarcoid uveitis patients.

Conclusion: Even with the use of this highly sensitive flowcytometric technique circulating retina-specific autoreactive CD4⁺ T-cells could not be detected. In contrast, ARA were detected in the majority of patients indicating an adaptive humoral immune response toward retinal antigens had occurred.

ARTICLE HISTORY

Received 27 June 2019
Revised 13 November 2019
Accepted 25 November 2019

KEYWORDS



Tuberculosis; sarcoidosis; OX40; uveitis; autoantibodies; retina; CD25; ANA; ARA; autoimmunity

Tuberculosis (TB)-associated uveitis represents a major cause of uveitis, particularly in TB endemic countries. The pathophysiology of TB-associated uveitis is still incompletely understood. Ocular infection with *Mycobacterium tuberculosis* (*Mtb*) is a very rare condition that may cause uveitis when *Mtb*-bacilli invade the eye and consequently elicit local granulomatous inflammation.¹⁻³ In support of local ocular infection by *Mtb*, anti-tuberculosis therapy (ATT) can be very effective in TB-associated uveitis patients without systemic signs of TB, higher response rates have been witnessed in patients with a high QuantiFERON-TB Gold test (QFT) score.⁴ However, the results were often inconclusive, better responses to ATT in combination with corticosteroids have been shown and a significant number of patients still need corticosteroid treatment after ATT, which may point to the involvement of other pathophysiological mechanisms as well. Several lines of evidence suggest that autoimmune reactions against retinal antigens might constitute part of the pathophysiology of uveitis, which may especially be relevant in the setting of latent TB-associated uveitis.⁴⁻⁸


Autoreactive T-cells toward crude retinal extract (RE) have been found in vitreous samples from patients with TB-associated uveitis.⁹ Yet, this study failed to identify RE autoreactive T-cells in paired peripheral blood samples, which was attributed to a presumed low-frequency of RE-specific T-cells

in peripheral blood.⁹ Alternatively, the sensitivity of the experimental approach (intracellular cytokine staining) might impede detection in this study.⁹ Detection of peripheral T-cells with auto-reactivity toward retinal antigens is, however, necessary for a good understanding of the immunopathogenesis of TB-associated uveitis and subsequent treatment and thus warrants further study.⁹

To detect retina-specific autoreactive T-cells in peripheral blood, we retrospectively examined induction of the activation markers CD25 (IL-2 Receptor- α) and CD134 (OX40) on the cell surface of CD4⁺ T-cells of patients with latent TB-associated uveitis upon stimulation with RE. This approach displays higher sensitivity than other techniques used to detect antigen-specific T-cell activation, including intracellular cytokine detection.^{10,11} The potential of this test has been shown for detecting latent TB infections by measuring specific T-cell recall responses to *Mtb*-specific peptides.¹² Therefore, stimulation experiments with *Mtb* purified protein derivative (PPD) served as a control in our study. Antiretinal autoantibodies (ARA) were previously found in TB-associated uveitis.¹³ As the initiation of a humoral immune response may depend on T-cell help, we measured ARA in available paired serum samples. Outcomes of latent TB-associated uveitis patients were compared to those from patients with sarcoid uveitis as this disease shares multiple immunopathological

CONTACT Willem A. Dik  w.dik@erasmusmc.nl  Department of Immunology, Laboratory Medical Immunology, Erasmus MC University Medical Center, PO Box 2040, Rotterdam, CA 3000, The Netherlands

Color versions of one or more of the figures in the article can be found online at www.tandfonline.com/oi/i

 Supplemental data for this article can be accessed on the [publisher's website](http://www.tandfonline.com/oi/i).

© 2019 The Author(s). Published with license by Taylor & Francis Group, LLC.

This is an Open Access article distributed under the terms of the Creative Commons Attribution-NonCommercial-NoDerivatives License (<http://creativecommons.org/licenses/by-nc-nd/4.0/>), which permits non-commercial re-use, distribution, and reproduction in any medium, provided the original work is properly cited, and is not altered, transformed, or built upon in any way.

features with TB and is sometimes clinically hard to distinguish from latent TB-associated uveitis.^{8,14,15}

Material and Methods

Patients and Sample Collection

In this study, patients with latent TB-associated uveitis ($n = 7$) and sarcoid uveitis ($n = 4$) who visited the outpatient clinic of the department of Ophthalmology and Clinical Immunology of the Erasmus MC, University Medical Center, Rotterdam were included. All patients underwent a standardized uveitis work-up and full ophthalmological examination.¹⁶ In patients with anterior uveitis and panuveitis, the human leukocyte antigen (HLA) B27 was determined. Patient characteristics are given in supplementary Table 1.

Diagnosis of latent TB-associated uveitis was assigned after the exclusion of underlying systemic diseases and other causes of uveitis, a positive score ($>0,35$ IU/ml) in the QFT, and the absence of any signs suggesting active TB. The diagnosis of definite sarcoid uveitis was given after excluding other causes of uveitis and confirmation by biopsy of an accessible inflammation site. Sarcoidosis patients included were QFT negative.

Blood samples were collected and peripheral blood mononuclear cells (PBMC) were isolated using a Ficoll (GE healthcare, Chicago, IL, USA) based density separation technique. Subsequently, PBMC were frozen until further analysis. Demographic data were collected at the time of sampling.

All subjects provided their written informed consent. The study was approved by the medical ethical committee of the Erasmus MC, University Medical Center, Rotterdam (protocol number MEC-2016-606) and in coherence with the tenets of the Declaration of Helsinki.

Retinal Extracts

Retina extract was prepared as described previously by Kuiper *et al.*¹⁷ In brief, retina tissue was obtained from a postmortem eye without a history of intraocular inflammation or vitreoretinal disease. The retina was carefully dissected from the underlying pigment epithelium, homogenized in 500 μ L phosphate-buffered saline (PBS) and subsequently centrifuged (10000 relative centrifugal force (RCF), 4°C, 30 min). The supernatant was carefully collected and heat-inactivated at 100°C for 7 min to neutralize endogenous tissue protease activity. Protein yield was assessed by colorimetric Bradford assay and the extract was aliquoted and stored at -80°C until further use.

Human Umbilical Vein Endothelial Cell Extracts

The human umbilical vein endothelial cell line (HUVEC) was cultured in the EBMTM-2 basal medium supplemented with EGMTM-2 SingleQuatsTM (Lonza, Basel, Switzerland) and penicillin and streptomycin (100 IU/ml; BioWhittaker, Verviers, Belgium). Cells were harvested by scraping, homogenized in 500 μ L PBS containing the protease inhibitors prefabloc (Roche, Basel, Switzerland), α -prot (Roche), and sodium orthovanadate (Sigma-Aldrich, St. Louis, MO, USA),

followed by three cycles of freeze-thawing and subsequently centrifuged (10000 RCF, 4°C, 30 min). The supernatant was carefully collected, protein yield was assessed by colorimetric Bradford assay and the extract was aliquoted and stored at -80°C until further use.

Detection of Antigen-Specific CD4⁺ T-Cells by Measurement of CD25/CD134 Co-Expression

Cryopreserved PBMC were thawed and suspended in RPMI-1640 (Gibco, Paisley, UK) culture medium supplemented with 10% fetal calf serum (Gibco), L-glutamine 2 mM (BioWhittaker), and penicillin and streptomycin (100 IU/ml; BioWhittaker). Cells were seeded onto 24-well plates, at 0.5×10^6 cells per well. For each assay, the following conditions were used: no exogenous stimulation (negative control), stimulation with 2,5 μ g/ml phytohemagglutinin (PHA; positive control), RE or HUVEC protein lysate (irrelevant protein control) at final concentrations of 100-, 10-, or 1 μ g/ml. As an antigen-specific positive control for the latent TB-associated uveitis patients, PBMC were stimulated with mycobacterium tuberculosis PPD (Statens Serum Institute, Copenhagen, Denmark) at a concentration of 4 μ g/ml. Cells were stimulated for 48 h in a humidified 5% CO₂ incubator. Subsequently, 100 μ L of cell suspension of each culture was stained for 15 min at room temperature (RT) with 20 μ L of the antibody mixture provided in the Act-T4 CellTM kit (CD3-PerCP-Cy5.5, CD4-FITC, CD25-APC, and CD134-PE; Cytognos, Salamanca, Spain), for better selection of the leukocyte population, 5 μ L CD45-PO (Invitrogen Corporation, Carlsbad, CA, USA) was added to the antibody mix. Thereafter, erythrocytes were lysed with erythrocyte lyse-non-wash solution provided in the Act-T4 CellTM kit following the manufactures instructions. Cells were measured using a BD FACSCantoTM (BD Biosciences, San Jose, CA, USA) cell analyzer. Flow-cytometric data were analyzed using the Infinicyt software (Cytognos).

Leukocytes were selected by CD45 vs side scatter, after which T-lymphocytes were identified using a CD3 vs side scatter gate, followed by a selection of CD3⁺CD4⁺ T-cells, which were then analyzed for CD25 and CD134 co-expression. Gates for CD25⁺ and CD134⁺ were based upon a comparison of negative control (unstimulated) and positive control (PHA) stimulation. Results for induction of CD3⁺CD4⁺CD25⁺CD134⁺ T-cells obtained upon stimulation with RE, HUVEC lysate or mycobacterium tuberculosis PPD were calculated as a stimulation index relative to maximal induction obtained with PHA (specific stimulus/PHA stimulus).

Detection of Antiretinal Antibodies by Indirect Immunofluorescence (IIF)

Serum ARA were determined as described previously.¹⁶ In short, primate retinal tissue (EuroImmun, Lubeck, Germany) was incubated with patients' serum (1:100 dilution) for 30 min at RT. After washing with PBS 0.2% Tween, sections were incubated with goat anti-human IgA/G/M conjugated with fluorescein isothiocyanate

(EuroImmun) for 30 min at RT. Sections were washed with PBS 0.2% Tween, embedded in glycerol and covered with a coverslip. Slides were analyzed using an AXIO Lab.A1 fluorescence microscope (Zeiss, Thornwood, NY, USA) and photographed at 200x and 400x magnification using a Nikon DS-Fi1 camera (Minato, Tokyo, Japan). Retinal tissue incubated with PBS or 1:100 diluted serum from a person negative for anti-nuclear antibodies (ANA) and ARA were used as negative controls. As positive controls, retinal tissue was incubated with either 1:100 diluted serum from an ANA positive person or 1:100 diluted serum from an ARA positive person. Sera from the included patients (1:80 dilution) were also analyzed for the presence of ANA by IIF using HEp-2 cells (Inova, San Diego, CA, USA) according to routine diagnostic protocols used in the laboratory medical immunology of the department of immunology within Erasmus MC. A positive staining of nuclei within the retinal tissue was scored as undetermined in case of a positive ANA result.

Statistics

All data analyses were performed in GraphPad Prism 5.0. Comparison between two groups was performed by an unpaired, two-tailed student's t-test. Correlations were calculated by pearson's correlation coefficient. A p -value $< .05$ was considered significant.

Results

Patients' Characteristics

The mean age of the latent TB-associated uveitis patients at the moment of blood sampling was 47 years (range 29–66 years) and 40 (range 29–51) for the sarcoid uveitis patients. The mean duration of uveitis was 5.5 years for the latent TB-associated uveitis group and 1.5 years for the sarcoid uveitis group. None of the latent TB-associated uveitis patients received immune suppressive therapy (IST) nor ATT within 3 months before study inclusion. From the ocular sarcoidosis patients, three did not receive IST within 3 months before study inclusion, while in one of the patients, IST (methotrexate) was started 1 month before blood drawing. For a detailed overview of all assessed individual patient characteristics, see supplementary Table 1.

Detection of Antigen-Specific CD4⁺ T-Cells

In all patients tested, stimulation of PBMC with PHA resulted in clear activation of the CD4⁺ T-lymphocytes as evidenced by an increase of the CD4⁺CD25⁺CD134⁺ T-lymphocyte fraction. Yet, the increase in CD4⁺CD25⁺CD134⁺ T-lymphocytes was significantly ($p < 0,05$) lower in the latent TB-associated uveitis group than the sarcoid uveitis group (Figures 1 and 2a). Moreover, in the latent TB-associated uveitis group the responsiveness of CD4⁺ T-lymphocytes to PHA correlated significantly

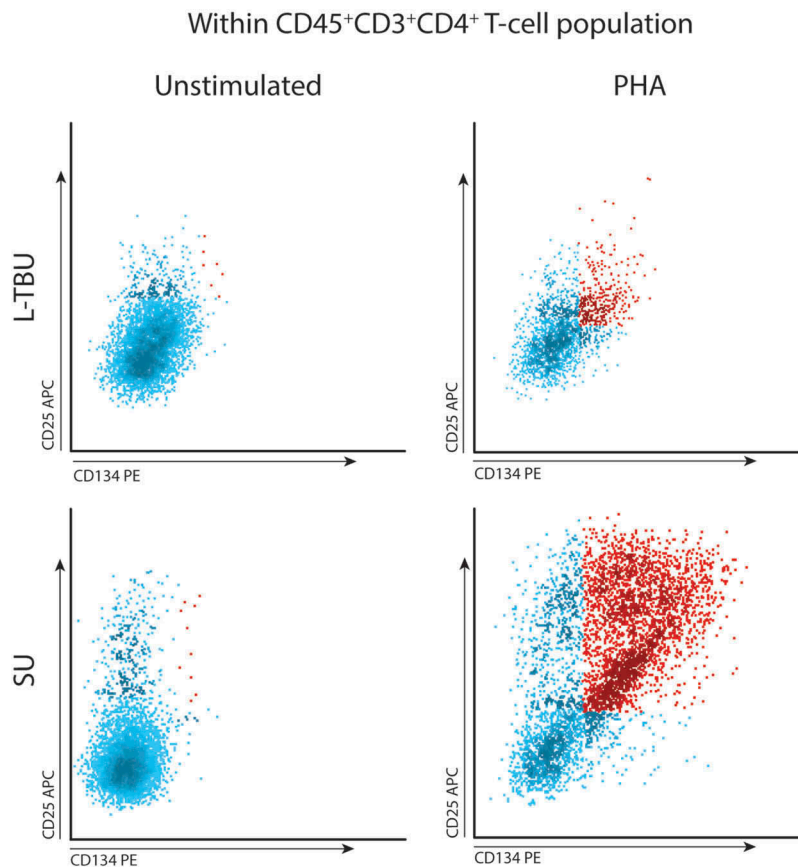


Figure 1. Representative flowcytometric analysis of peripheral blood mononuclear cells (PBMC) from a latent tuberculosis-associated uveitis (L-TBU) and sarcoid uveitis (SU) patient, unstimulated (left column) and stimulated with 2.5µg/ml phytohemagglutinin (PHA; right column).

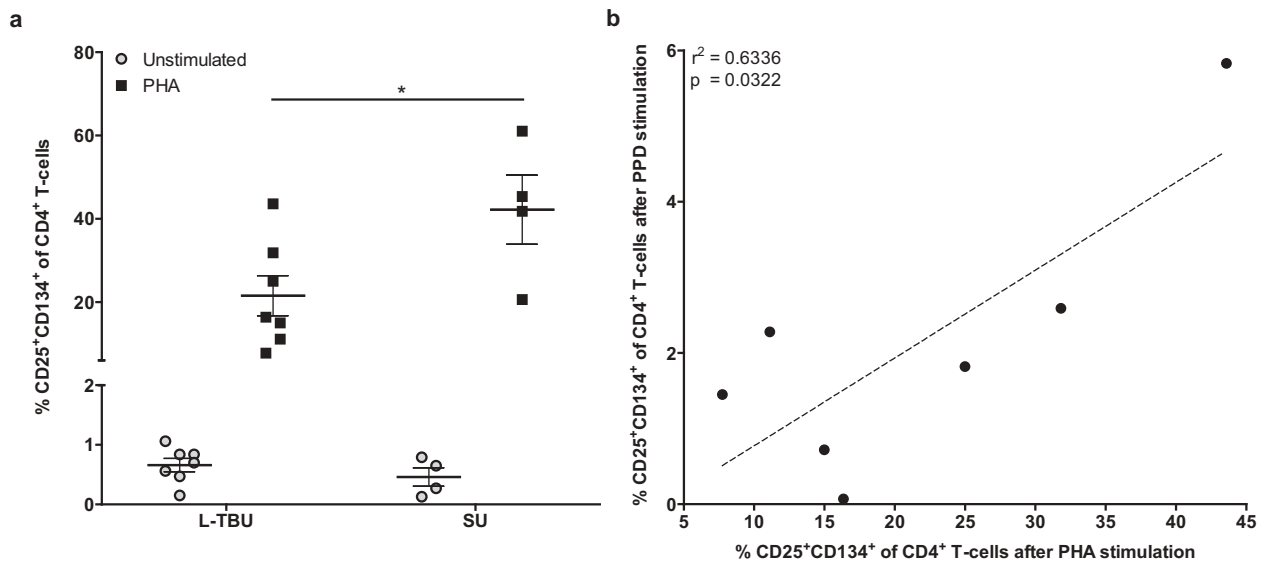


Figure 2. (a) Percentage CD25⁺ CD134⁺ of CD4⁺ T-cells after PBMC from L-TBU (n = 7) or SU (n = 4) were cultured for 48 h in the presence (black squares) or absence (gray circles) of 2.5 µg/ml PHA. Each circle and related square represent an individual patient. Horizontal lines indicate the mean values. Statistical analysis was done using the unpaired, two-tailed student's t-test. * = $P < .05$. (b) Correlation between the percentages of CD25⁺ CD134⁺ CD4⁺ T-cells observed in L-TBU patients after PBMC stimulation with either 4 µg/ml mycobacterium tuberculosis purified protein derivative (PPD) or 2.5 µg/ml PHA. Statistical analysis was done using the spearman's rank correlation test.

($p < .05$, $r^2 = 0.63$) with the observed response upon mycobacterium tuberculosis PPD stimulation (Figure 2b). Six out of seven latent TB-associated uveitis patients responded to mycobacterium tuberculosis PPD stimulation with an induction of CD4⁺CD25⁺CD134⁺ population with a stimulation index of at least 0.05. This mycobacterium tuberculosis PPD stimulation index did not exceed 0.03 in the sarcoid uveitis group (Figure 3). Stimulation with the different RE concentrations seemed to have a slight stimulatory effect on T-cells from 3 out of 7 latent TB-associated uveitis patients (Figure 4a). Yet the same patients also responded to stimulation with HUVEC protein lysate, which served as irrelevant protein control (Figure 4b). Therefore, the T-cell responses observed to RE in these patients were considered a-specific.

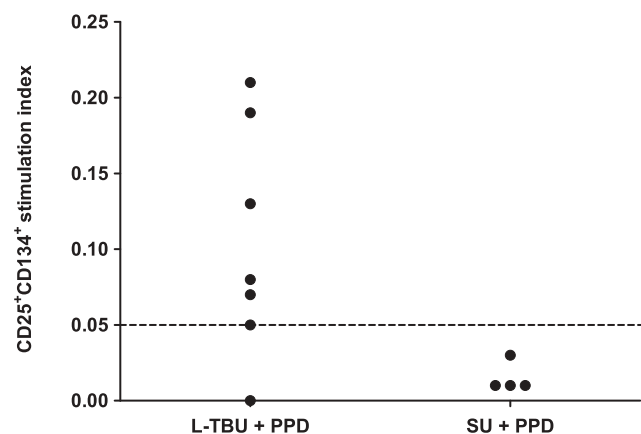


Figure 3. T-cell response to mycobacterium tuberculosis PPD stimulation. Each circle represents an individual patient (L-TBU n = 7, SU n = 4). Data are represented as a CD25⁺ CD134⁺ stimulation index (effect specific stimulus/effect PHA stimulus).

Detection of Serum ARA

Serum for detection of ARA was available from six of the latent TB-associated uveitis patients and from three of the sarcoid uveitis patients. Five of the six latent TB-associated uveitis patients' sera revealed reactivity against retinal tissue. In one of these cases, positivity against retinal cell nuclei was observed in combination with ANA positivity and was therefore scored as undetermined. The other four positive latent TB-associated uveitis cases displayed reactivity of varying intensity (weak to strong) against retinal cell nuclei and/or the photoreceptor layer and the outer limiting membrane (OLM; Figure 5) and were ANA negative. Sera of all three sarcoid uveitis patients were ANA negative but did display reactivity against retinal cell nuclei with two sera also displaying reactivity against the photoreceptor layer and one also against the OLM. Retinal staining patterns are summarized in Table 1.

Discussion

In this study, we used a sensitive flowcytometry-based assay to detect retina-autoreactive CD4⁺ T-cell responses. Yet, no retina-autoreactive CD4⁺ T-cells were found in peripheral blood of patients with latent TB-associated uveitis or sarcoid uveitis. In contrast, specific ARA were detected in the majority of latent TB-associated uveitis and sarcoid uveitis patients.

Retinal autoimmunity has been proposed in TB-associated uveitis for a while.^{18,19} Moreover, the development of anterior granulomatous uveitis has been described following *Bacille-Calmette-Guérin* (BCG) therapy for bladder carcinoma. This was associated with the presence of peripheral T-cells that proliferated and produced cytokines (a.o. T-helper 1 (Th1) cytokines like IFN- γ and TNF- α) upon exposure to mycobacterium tuberculosis PPD as well as specific retinal antigens.⁷

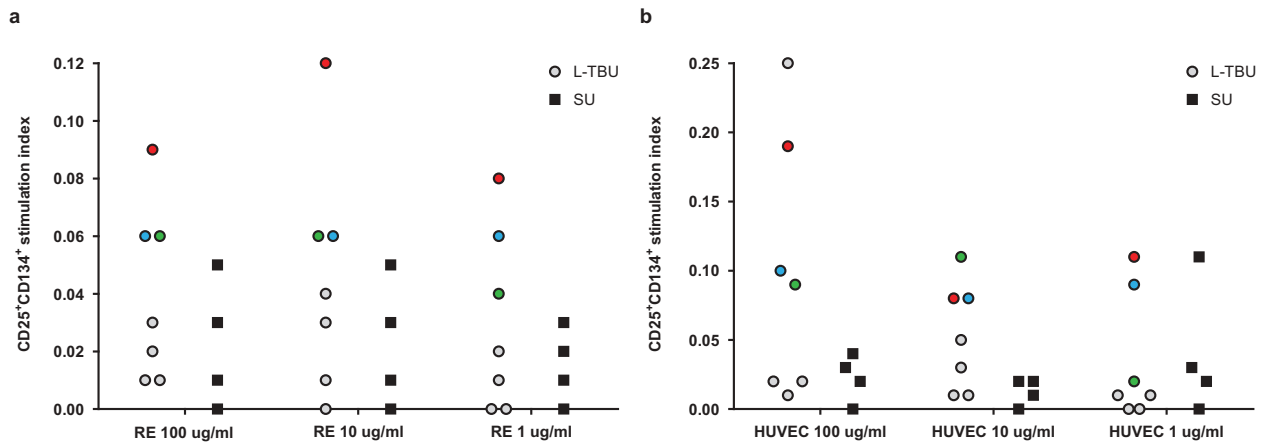


Figure 4. T-cell response upon stimulation with (a) retinal extract (RE; 100-, 10-, 1 ug/ml) or (b) human umbilical vein endothelial cell (HUVEC) protein lysate (100-, 10-, 1 ug/ml) in L-TBU patients (n = 7, circles) or SU patients (n = 4, black squares). Each circle or square represents an individual patient. Data are represented as a CD25⁺CD134⁺ stimulation index. The three L-TBU patients displaying a T-cell response to RE and HUVEC protein lysate are individually represented by either the red, green or blue circles.

The fact that retina-specific CD4⁺ T-cells could not be detected in our study is unlikely to be related to a generalized state of unresponsiveness, as PBMC from all patients responded to PHA stimulation and PBMC from 6 out of 7 latent TB-associated uveitis cases also responded to mycobacterium tuberculosis PPD stimulation. In addition, IFN- γ was detected in the culture supernatant of 3 out of 7 latent TB-associated uveitis cases after stimulation with PPD (data not shown). We can however not exclude the possibility that our RE isolation procedure resulted in the generation of heat-denatured proteins that might not be easily processed by antigen-presenting cells and subsequently presented to T-lymphocytes. The PHA response was however significantly lower in the latent TB-associated uveitis group, suggesting a certain level of T-cell unresponsiveness or exhaustion in comparison to sarcoid uveitis patients, even though a-specific and pathogen specific recall responses have been shown to be reduced in sarcoidosis patients.²⁰ This is further supported by the positive correlation between the mycobacterium tuberculosis PPD induced response and the PHA induced response observed in the latent TB-associated uveitis group.

There are several possibilities why retina-autoreactive CD4⁺ T-cells were not detected in the patient's blood samples. First, the number of circulating retina-autoreactive CD4⁺ T-cells might be extremely low in the blood of latent TB-associated uveitis patients and therefore too low for detection. This was also suggested by Tagirasa *et al.* who did find autoreactive T-cells toward RE in vitreous samples from TB-associated uveitis patients but not in matched peripheral blood samples.⁹ Second, uveitis activity and limited patient inclusion might have contributed to our findings. In this study, only three out of the seven latent TB-associated uveitis and two out of the four sarcoid uveitis patients had active uveitis at the time of sampling. In contrast, previous studies that did find circulating autoreactive T-cells to specific retinal antigens or RE in patients with uveitis (e.g. sarcoidosis, Behçet disease, Vogt-Koyanagi-Harada syndrome, and birdshot chorioretinopathy) mostly included patients with active uveitis.^{17,21,22} Moreover, the studies that did find circulating retina-autoreactive T-cells enrolled higher

patient numbers but detected autoreactive T-cells only in part of the included patients.^{17,21,22} Lastly, for this study, we used cryopreserved cells which might lead to suboptimal responses to certain stimuli in comparison to freshly isolated blood mononuclear cells.²³

Although autoreactive CD4⁺ T-cells against RE were not detected in peripheral blood of the latent TB-associated uveitis patients, we did detect serum ARA in 5/6 (83%) of these cases. This is at a higher prevalence than our group previously described in presumably healthy blood donors from the Netherlands (17%),¹⁶ but also in Indonesian patients with uveitis in the setting of active TB (44%) or latent TB (37%).¹³ The three sarcoid uveitis sera analyzed were all ARA positive (100%), indicative of an autoimmune component in these cases as well, yet without detectable retina-autoreactive T-cells in the peripheral blood. Serum antibodies to retinal antigens have been previously described in ~44% of sarcoid uveitis patients.²⁴

Although there is no evidence that these ARA are pathogenic and may just reflect retinal damage their presence might support the occurrence of a T-cell dependent anti-retinal immune response in cases of TB-associated as well as sarcoid uveitis. Yet, we cannot exclude the possibility of a T-cell independent humoral immune response against retina antigens nor potential molecular mimicry as has been demonstrated to exist for mycobacterial heat-shock protein-65 and medium molecular weight neurofilament (NF-M).^{25,26} Discrepancies between autoantibody positivity and the absence of detectable circulating autoreactive T-cells have been observed in other disease entities as well, for instance in anti-Hu antibody-associated paraneoplastic neurological syndromes.²⁷ The high ARA prevalence observed in our current study might be an overestimation as the number of patients per uveitis group was small.

In conclusion, we were unable to demonstrate circulating autoreactive T-cells to RE in peripheral blood samples from patients with latent TB-associated uveitis or sarcoid uveitis. Although the absence of circulating retina-specific autoreactive T-cells cannot be ruled out, we propose that the number of such

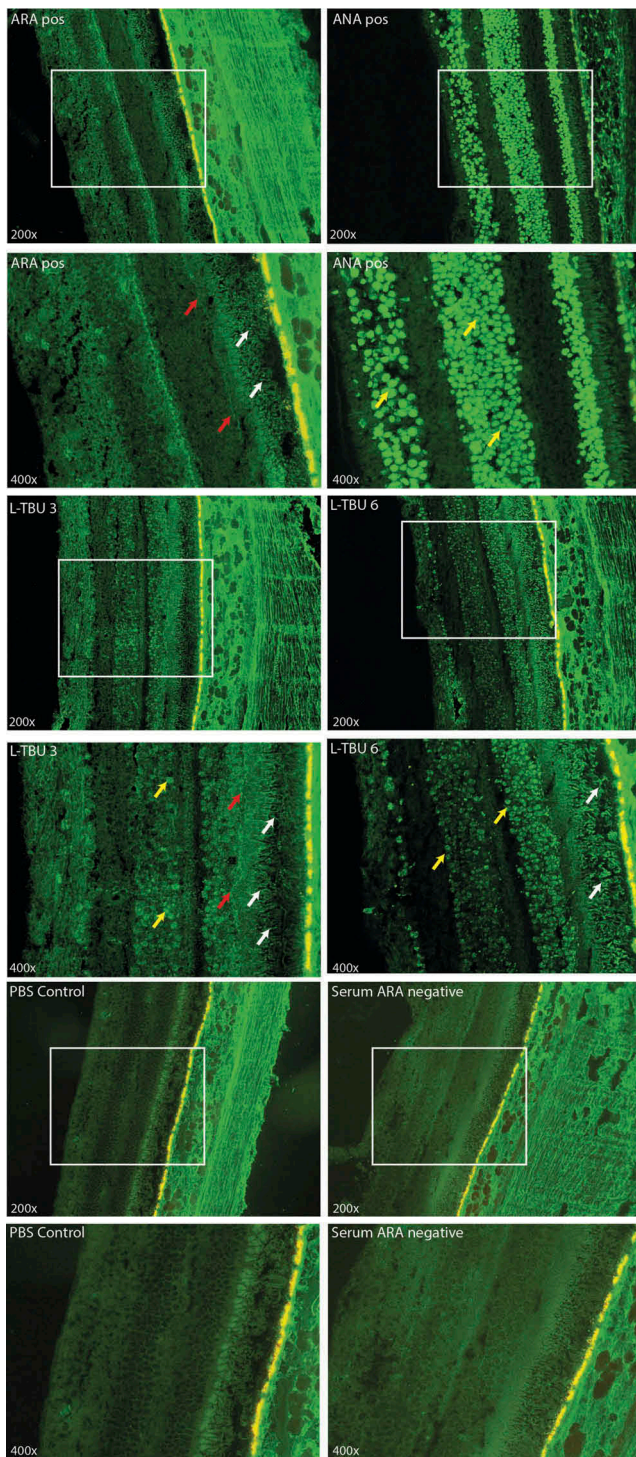


Figure 5. Representative indirect immunofluorescence microscopy images for antiretinal antibodies (ARA) on primate retinal tissue incubated with serum from two different L-TBU patients and negative and positive controls (ARA positive serum control first column, first and second row, anti-nuclear antibodies (ANA) positive serum control second column, first and second row, patient no. 3 first column, third and fourth row; patient no. 6 second column, third and fourth row; PBS control first column fifth and sixth row; ARA and ANA negative serum second column, fifth and sixth row). Images were visualized at 200x magnification (first, third and fifth row) with the indicated square shown at 400x magnification (second, fourth and sixth row). The arrows depict positive staining for antiretinal antibodies (ARA) of the photoreceptor layer (white arrows), outer limiting membrane (red arrows), and nuclear antigens (yellow arrows).

Table 1. Antiretinal antibodies (ARA).

Patient	ARA		
	Nuclear	Photoreceptor Layer	OLM
L-TBU 1	-	±	-
L-TBU 2	+	-	-
L-TBU 3	++	++	+
L-TBU 4	UD	-	-
L-TBU 5	-	+	-
L-TBU 6	++	++	-
SU 1	+	+	+
SU 2	+	+	-
SU 3	+	-	-

L-TBU = latent tuberculosis-associated uveitis, SU = sarcoid uveitis, OLM = outer limiting membrane, UD = undetermined

cells is far too low for reliable detection, even here with the use of highly sensitive flowcytometric approach. To determine the presumed pathophysiological role of autoimmune reactions in active and inactive TB-associated uveitis, as well as sarcoid uveitis, intraocular fluid samples should be examined.

Declaration of interest

The authors report no conflicts of interest. The authors alone are responsible for the content and writing of the paper.

References

1. La Distia Nora R, Walburg KV, van Hagen PM, *et al.* Retinal pigment epithelial cells control early mycobacterium tuberculosis infection via interferon signaling. *Invest Ophthalmol Vis Sci.* 2018;59:1384–1395. doi:10.1167/iovs.17-23246.
2. Mack U, Migliori GB, Sester M, *et al.* LTBI: latent tuberculosis infection or lasting immune responses to *M. tuberculosis*? A TBNET consensus statement. *Eur Respir J.* 2009;33:956–973. doi:10.1183/09031936.00120908.
3. La Distia Nora R, Sitompul R, Bakker M, *et al.* Tuberculosis and other causes of uveitis in Indonesia. *Eye (Lond).* 2018;32:546–554. doi:10.1038/eye.2017.231.
4. Gineys R, Bodaghi B, Carcelain G, *et al.* QuantiFERON-TB gold cut-off value: implications for the management of tuberculosis-related ocular inflammation. *Am J Ophthalmol.* 2011;152(3):e431. doi:10.1016/j.ajo.2011.02.006.
5. Vos AG, Wassenberg MW, de Hoog J, Oosterheert JJ. Diagnosis and treatment of tuberculous uveitis in a low endemic setting. *Int J Infect Dis.* 2013;17:e993–999. doi:10.1016/j.ijid.2013.03.019.
6. Spratt A, Key T, Vivian AJ. Chronic anterior uveitis following bacille Calmette-Guerin vaccination: molecular mimicry in action? *J Pediatr Ophthalmol Strabismus.* 2008;45:252–253. doi:10.3928/01913913-20080701-15.
7. Garip A, Diedrichs-Mohring M, Thureau SR, Deeg CA, Wildner G. Uveitis in a patient treated with bacille-calmette-guerin: possible antigenic mimicry of mycobacterial and retinal antigens. *Ophthalmology.* 2009;116(2457–2462):e2451–2452. doi:10.1016/j.optha.2009.05.021.
8. Elkington P, Tebruegge M, Mansour S. Tuberculosis: an infection-initiated autoimmune disease? *Trends Immunol.* 2016;37:815–818. doi:10.1016/j.it.2016.09.007.
9. Tagirasa R, Parmar S, Barik MR, Devadas S, Basu S. Autoreactive T cells in immunopathogenesis of TB-associated uveitis. *Invest Ophthalmol Vis Sci.* 2017;58:5682–5691. doi:10.1167/iovs.17-22462.
10. Zaunders JJ, Munier ML, Seddiki N, *et al.* High levels of human antigen-specific CD4+ T cells in peripheral blood revealed by stimu-

- lated coexpression of CD25 and CD134 (OX40). *J Immunol.* 2009;183:2827–2836. doi:10.4049/jimmunol.0803548.
11. Sadler R, Bateman EA, Heath V, et al. Establishment of a healthy human range for the whole blood “OX40” assay for the detection of antigen-specific CD4+ T cells by flow cytometry. *Cytometry B Clin Cytom.* 2014;86:350–361. doi:10.1002/cytob.21165.
 12. Hsu DC, Zaunders JJ, Plit M, et al. A novel assay detecting recall response to Mycobacterium tuberculosis: comparison with existing assays. *Tuberculosis (Edinb).* 2012;92:321–327. doi:10.1016/j.tube.2012.03.008.
 13. La Distia Nora R, Ten Berge JC, Rothova A, Schreurs MW. Antinuclear and antiretinal antibodies in uveitis associated with active and latent tuberculosis. *Acta Ophthalmol.* 2018;96:e659–e660.
 14. Koth LL, Solberg OD, Peng JC, et al. Sarcoidosis blood transcriptome reflects lung inflammation and overlaps with tuberculosis. *Am J Respir Crit Care Med.* 2011;184:1153–1163. doi:10.1164/rccm.201106-1143OC.
 15. Maertzdorf J, Weiner J, Mollenkopf H-J, et al. Common patterns and disease-related signatures in tuberculosis and sarcoidosis. *Proc Natl Acad Sci USA.* 2012;109:7853–7858. doi:10.1073/pnas.1121072109.
 16. Ten Berge JC, Schreurs MW, Vermeer J, Meester-Smoor MA, Rothova A. Prevalence and clinical impact of antiretinal antibodies in uveitis. *Acta Ophthalmol.* 2016;94:282–288. doi:10.1111/aos.12939.
 17. Kuiper JJ, Emmelot ME, Rothova A, Mutis T. Interleukin-17 production and T helper 17 cells in peripheral blood mononuclear cells in response to ocular lysate in patients with birdshot chorioretinopathy. *Mol Vis.* 2013;19:2606–2614.
 18. Forrester JV, Kuffova L, Dick AD. Autoimmunity, autoinflammation, and infection in uveitis. *Am J Ophthalmol.* 2018;189:77–85. doi:10.1016/j.ajo.2018.02.019.
 19. Ang M, Cheung G, Vania M, et al. Aqueous cytokine and chemokine analysis in uveitis associated with tuberculosis. *Mol Vis.* 2012;18:565–573.
 20. Ahmadzai H, Cameron B, Chui JJ, Maertzdorf J, Weiner J, Mollenkopf HJ. Peripheral blood responses to specific antigens and CD28 in sarcoidosis. *Respir Med.* 2012;106:701–709. doi:10.1016/j.rmed.2012.01.012.
 21. de Smet MD, Bitar G, Mainigi S, Nussenblatt RB. Human S-antigen determinant recognition in uveitis. *Invest Ophthalmol Vis Sci.* 2001;42:3233–3238.
 22. de Smet MD, Yamamoto JH, Mochizuki M, et al. Cellular immune responses of patients with uveitis to retinal antigens and their fragments. *Am J Ophthalmol.* 1990;110:135–142. doi:10.1016/S0002-9394(14)76981-8.
 23. Jeurink PV, Vissers YM, Rappard B, Savelkoul HF. T cell responses in fresh and cryopreserved peripheral blood mononuclear cells: kinetics of cell viability, cellular subsets, proliferation, and cytokine production. *Cryobiology.* 2008;57:91–103. doi:10.1016/j.cryobiol.2008.06.002.
 24. Jankowska R, Witkowska D, Porębska I, et al. Serum antibodies to retinal antigens in lung cancer and sarcoidosis. *Pathobiology.* 2004;71:323–328. doi:10.1159/000081728.
 25. Machado Ribeiro F, Goldenberg T. Mycobacteria and autoimmunity. *Lupus.* 2015;24:374–381. doi:10.1177/0961203314559634.
 26. Lule S, Colpak AI, Balci-Peynircioglu B, et al. Behcet disease serum is immunoreactive to neurofilament medium which share common epitopes to bacterial HSP-65, a putative trigger. *J Autoimmun.* 2017;84:87–96. doi:10.1016/j.jaut.2017.08.002.
 27. de Jongste AH, de Graaf MT, Martinuzzi E, et al. Three sensitive assays do not provide evidence for circulating HuD-specific T cells in the blood of patients with paraneoplastic neurological syndromes with anti-Hu antibodies. *Neuro Oncol.* 2012;14:841–848. doi:10.1093/neuonc/nos118.