



Surgical management of spasmodic torticollis

Wael Fouad

To cite this article: Wael Fouad (2011) Surgical management of spasmodic torticollis, Alexandria Journal of Medicine, 47:4, 317-323, DOI: [10.1016/j.ajme.2011.07.010](https://doi.org/10.1016/j.ajme.2011.07.010)

To link to this article: <https://doi.org/10.1016/j.ajme.2011.07.010>



© 2011 Alexandria University Faculty of Medicine. Production and hosting by Elsevier B.V. All rights reserved.



Published online: 17 May 2019.



Submit your article to this journal [↗](#)



Article views: 157



View related articles [↗](#)



ORIGINAL ARTICLE

Surgical management of spasmodic torticollis

Wael Fouad

Alexandria Faculty of Medicine, Neurosurgery Department, Sultan Hussein Street, Azarita, Alexandria, Egypt

Received 23 June 2011; accepted 17 July 2011

Available online 23 August 2011

KEYWORDS

Focal dystonia;
Spasmodic torticollis;
Anterior rhizotomy;
Selective denervation

Abstract *Introduction:* Spasmodic torticollis (ST) is a neuromuscular disorder characterized by uncontrolled clonic and intermittently tonic spasm of the neck muscles.

Objective: This retrospective study was done to study clinical picture and to evaluate the surgical results of different surgical procedures in 11 patients who had spasmodic torticollis.

Methods: The male to female ratio was 1–2 (4 males and 7 females) and their ages ranged from 18 to 65 years. The X-ray of the cervical spine was performed before the operation to exclude cervical disorders that can cause symptoms similar to spasmodic torticollis. MRI of the head and neck was performed in all patients, without finding significant brain lesions. Electromyography of the cervical muscles was performed preoperatively and postoperatively. All cases underwent surgery in the form of variable combinations of ventral rhizotomy of C1, C2 + selective peripheral denervation of neck muscles involved according to the type of torticollis. Mean postoperative follow up period was 24 months.

Results: There was no operative mortality. As regards the morbidity, one patient had deficiency of shoulder elevation that was transient and improved after 3 months; one patient had wound infection that responded well to antibiotics after culture and sensitivity. Postoperative dysphagia was found in two cases that improved in one of them after two months. At the last follow up examination period, excellent results were obtained in 55% of patients, good results in 18% of patients, fair results in 18% of patients, and poor results in 9% of cases.

Conclusion: There is no standard surgical procedure for treatment of ST; this is adapted to each patient according to type of torticollis. Better results were obtained in simple torticollis (excellent results in 100%), than in complex type (excellent and good results in 33.3%).

© 2011 Alexandria University Faculty of Medicine. Production and hosting by Elsevier B.V. All rights reserved.

E-mail address: waelfouad_67@hotmail.com

2090-5068 © 2011 Alexandria University Faculty of Medicine.
Production and hosting by Elsevier B.V. All rights reserved.

Peer review under responsibility of Alexandria University Faculty of Medicine.

doi:10.1016/j.ajme.2011.07.010



Production and hosting by Elsevier

1. Introduction

Spasmodic torticollis (ST) is a neuromuscular disorder characterized by uncontrolled clonic and intermittently tonic spasm of the neck muscles.¹ It causes abnormal posture of the head, usually with an involuntary deviation from the normal position. The abnormal position of the head may represent rotation, tilting, or extension of the neck. If the shoulders or trunk are involved, the disease should more properly be labeled dystonia.² The condition may begin at any adult age,

with a peak incidence between the ages of 30 and 40. The first manifestation may be a feeling of tightness of the neck muscles, and the patient may develop a tic like movement in hopes of obtaining comfort. Symptom may progress either rapidly or gradually, but usually a plateau is reached within a few years.^{1,3} To explain its etiology and pathophysiology, several hypotheses have been proposed: disorder of the reflex arcs maintaining cervical muscle tone, dysfunction of basal ganglion and their connections, psychogenic factors, and vascular compression.^{4,5} Many surgical treatments have been tried, such as myotomy, neurectomy or rhizotomy of the involved muscles or nerves spinal cord stimulation, botulinum toxin injection, selective peripheral denervation (SPD), and microvascular decompression (MVD).^{6,7}

ST can be classified as a simple movement disorder or a complex movement disorder. This former refers to rotation, lateral tilting, extension, and flexion of the head and neck. The latter comprises a combination of more than one movement, with some being predominant and other relatively secondary.⁸

The aim of this work was to study clinical picture and to evaluate the surgical results of 11 patients who had spasmodic torticollis, also to compare these results with the results of the other authors reported in literature.

2. Methods

This retrospective study was carried out on 11 patients who had spasmodic torticollis. This study was done in Alexandria hospitals over a period of 8 years starting from January 2002 to December 2009. The male to female ratio was 1 to 2 (4 males and 7 females) and their ages ranged from 18 to 65 years with mean age of 39 years. Four patients suffered from simple movement disorder, while the other seven suffered from complex movement disorder (Table 1). All of them had been treated with multiple therapies without significant benefit before they were treated surgically.

The X-ray of the cervical spine was performed before the operation to exclude cervical disorders that can cause symptoms similar to spasmodic torticollis. A magnetic resonance (MR) scan of the head and neck was performed in all patients, without finding significant brain lesions. Electromyography (EMG) of the cervical muscles was performed preoperatively and postoperatively. The indications for surgery of spasmodic torticollis were as follows:

1. Patients were examined carefully before the operation to exclude the deformity of cervical spondylosis, hysterical torticollis, and systemic dystonic or dyskinetic movement disorders such as Huntington's chorea, systemic torsion dystonia, Parkinson's disease.

2. The spasmodic muscles were confined mainly to the neck.
3. The symptoms were stable and have lasted for at least 24 months.

The surgical procedures were done on two settings usually separated by one to two months.

The first surgical setting was performed in the prone position. Under general anesthesia, the head is fixed in a slightly flexed position. The upper half of the body is elevated about 30 degrees. Muscle relaxant is not used except at the induction of anesthesia. A short straight skin incision from theinion to the C5 level was used. The midline nuchal ligament was cut and the inferior oblique muscle and the posterior arch of C1 were exposed. The suboccipital rectus muscles were cut unilaterally at their insertion, with the preservation of the inferior oblique muscle. C1 and C2 laminectomy was performed and the dura was opened. After dissection of the arachnoid membrane and the dentate ligament, C1 and C2 ventral rootlets were exposed and sectioned. The small vessels running with the rootlets must be preserved. For intradural procedure, very fine microsurgical instruments were required. After dural closure with 5-0 silk continuous suture, the space between semispinalis capitis and semispinalis cervicis was dissected to expose the posterior rami from C3 to C5. These branches were cut completely and complete denervation was confirmed with electrical stimulation. By tilting the microscope the procedure was performed through a much smaller incision than in the traditional Bertrand procedure.

The second surgical setting {denervation of Sternocleidomastoid (SCM) and/or levator scapulae (LS)} was performed operated under general anesthesia in the supine position with the head rotated to the opposite side. The microscope was used from the skin incision which was straight and about 8 cm along the posterior border of SCM; to avoid damage to the great auricular nerve. After identification of the main trunk of the accessory nerve, the nerve was followed in both distal and proximal directions and all the branches to SCM were cut and coagulated. At the anterior border of LS, the nerve to LS muscle was identified by electrostimulation and cut, the distal part of the nerve was pulled out from the muscle to prevent reinnervation.

Mean postoperative follow up examination period was 24 months (range from 15 to 34 months).

3. Results

All patients were scheduled to be assessed at 1 week, 3 months, 6 months, 12 months postoperatively.

Postoperative mortality and morbidity: There was no perioperative mortality. As regards the morbidity, one patient had deficiency of shoulder elevation that was transient and im-

Table 1 Correlation between the type of torticollis and the surgical outcome.

Type of torticollis	No	Percentage (%)	Outcome		
Simple	Laterocollis	1	36	Excellent results in all 4 cases	
	Rotational torticollis	3			27
Complex	Rotational + retrocollis	5	64	1 Excellent, 2 good, 2 fair	
	Laterocollis + retrocollis	1			9
	Rotational + laterocollis	1			9
Total	11	100	6 Excellent, 2 good, 2 fair, 1 poor		

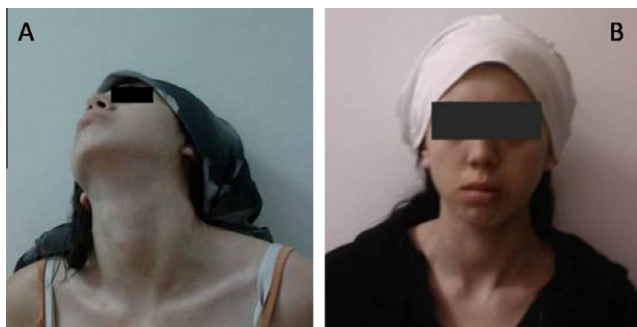


Figure 1 Patient with right rotation and retrocollis. Before (A) and after (B) operation.

proved after 3 months; one patient had wound infection that responded well to antibiotics after culture and sensitivity. Post-operative dysphagia was found in two cases that improved in one of them after two months. No operation-related complications, such as death, infection, leakage of cerebrospinal fluid, respiratory complications were observed during the follow-up period, which ranged from 15 to 34 months.

Assessment of outcome after surgery was based upon Jho and Jannetta's⁷ criteria of treatment, the operative results were categorized into four groups: Group 1 = excellent results (Cure): The patient has no cervical muscle spasms. There may be a minimal head tilt in the neutral position or a subjective sensation of stiffness due to soft tissue contracture. The full range of neck motion is maintained. Group 2 = good results (Improvement with minimal spasm): Patients may have mild restriction of neck motion and mild head tilt in the neutral position. Group 3 = fair results (Improvement with moderate spasm): Patients may have a moderate degree of restriction of neck motion and head tilt in the neutral position. Group 4 = poor results (Minimal improvement or unchanged): The patient has significant restriction of neck motion and head tilt in the neutral position.

At the last follow up period, six patients were cured (55%), two patients (18%) had improved with minimal spasms, another two patients (18%) had improved with moderate spasms and one patient did not improve (9%).

Abnormal neck posture that was present in all cases improved in patients (91%) postoperatively, while pain that was present in 44% of cases improved in all these cases as measured by visual analogue scale. Figs. 1–4 demonstrate the photos before the operation and 6 month postoperatively. Summary data and outcome of these 11 patients are listed in Table 2.



Figure 2 Patient with right rotational torticollis. Before (A) and after (B) operation.

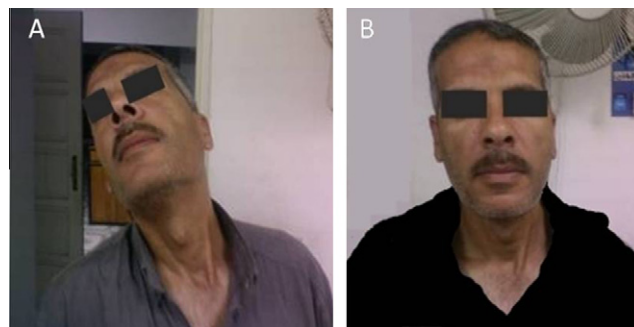

Figure 3 Patient with right laterocollis and retrocollis. Before (A) and after (B) operation.

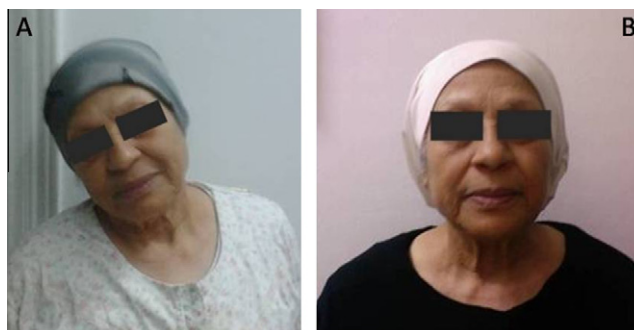

Figure 4 Patient with right laterocollis. Before (A) and after (B) operation.

4. Discussion

The etiology and pathophysiology of ST are still unknown. Several hypotheses have been proposed. The therapeutic effects of stereotactic ventrolateral thalamotomy and subthalamotomy led to the hypothesis that ST is the manifestation of a basal ganglia disorder.^{9,10} The observation that patients suffering from ST sometimes manifest tremors and dystonic symptoms of the hand and head, which often occur in patients with basal ganglia lesions, further supports this theory.¹¹ Some investigators believe that ST is a brainstem disorder of the reflex arcs that maintain cervical muscle tone; particularly the spinoolivary and vestibular systems have been considered to be important in the development of synergistic contraction of the cervical muscles.¹² The abnormal exteroceptive reflex of the sternocleidomastoid muscle produced by electrical stimulation of the supraorbital nerve has been observed in patients with ST.¹ Therefore, Nakashima et al.¹³ believed that the abnormal function of inhibitory interneuronal networks between the trigeminal nerve and the motor neurons of the accessory and upper cervical nerves may mediate abnormal exteroceptive suppression of the sternocleidomastoid muscles and contribute to the pathogenesis of ST. Some investigators considered that psychogenic factors, such as neurotic personality, psychological instability, irritability, impulsiveness, and defensive attitude, may participate in the pathogenesis of ST. The symptoms of ST can also worsen the patient's emotional control, which creates a vicious cycle.¹⁴ As the evidence suggests that several hyperactive cranial nerve dysfunction syndromes, such as trigeminal neuralgia, hemifacial spasm, and neurogenic hypertension, are caused by neurovascular

Table 2 Summary data of 11 patients with spasmodic torticollis.

No.	Age	Sex	Duration of symptoms	Type of torticollis	Operative procedure	Outcome	Follow up period months
1	65	F	8	Right lateral tilting	Right ventral rhizotomy C1,C2+ right posterior ramisectomy C3,C4,C5 and denervation of levator scapulae and SCM on right side.	Cured	34
2	31	F	3	Right rotation	Right ventral rhizotomy C1,C2+ right posterior ramisectomy C3,C4,C5+ denervation of left SCM	Cured	20
3	38	F	2	Right rotation + retrocollis	Right ventral rhizotomy C1,C2+ partial left ventral rhizotomy C1,C2,C3+ right posterior ramisectomy C3,C4,C5+ denervation of left SCM	Improved with minimal spasm	28
4	34	M	4	Left rotation + retrocollis	Left ventral rhizotomy C1,C2+ partial right ventral rhizotomy C1,C2,C3+ left posterior ramisectomy C3-C5+ denervation of right SCM	Improved with moderate spasm	23
5	42	M	5	Right lateral tilting + retrocollis	Right ventral rhizotomy C1,C2+ partial left ventral rhizotomy C1,C2+ right posterior ramisectomy C3-C5+ denervation of right SCM and levator scapulae	Unchanged	19
6	36	F	4	Left rotation	Left ventral rhizotomy C1,C2+ left posterior ramisectomy C3,C4,C5+ denervation of right SCM	Cured	30
7	41	M	4	Right rotation	Right ventral rhizotomy C1,C2+ right posterior ramisectomy C3,C4,C5+ denervation of left SCM	Cured	23
8	35	F	3	Left rotation + retrocollis	Left ventral rhizotomy C1,C2+ partial right ventral rhizotomy C1,C2+ left posterior ramisectomy C3,C4,C5+ denervation of right SCM	Improved with minimal spasm	19
9	18	M	4,5	Right rotation + retrocollis	Right ventral rhizotomy C1,C2+ partial left ventral rhizotomy C1,C2,C3+ right posterior ramisectomy C3,C4,C5+ denervation of left SCM	Cured	15
10	42	F	2,5	Left rotation + retrocollis	Left ventral rhizotomy C1,C2+ partial right ventral rhizotomy C1,C2,C3+ left posterior ramisectomy C3,C4,C5+ denervation of right SCM	Improved with moderate spasm	28
11	48	F	6	Left rotation + contralateral tilting	Left ventral rhizotomy C1,C2+ partial right ventral rhizotomy C1,C2,C3+ left posterior ramisectomy C3,C4,C5+ denervation of SCM and levator scapulae on right side	Cured	25

compression, some authors reported that neurovascular compression could be a possible cause of ST and that patients can benefit from MVD.¹⁵⁻¹⁷ One possible mechanism involved in the pathogenesis of ST caused by vascular compression could be an ectopic discharge of the accessory and upper cervical nerve that dominates the cervical muscles. Demyelination of the axons subsequent to the compression of the nerve by the artery might induce ectopic discharge between the axons of the reflex arcs that maintain cervical muscle tone. It is possible that the neurovascular compression is reversible; once the axons have been liberated from compressing factors, the ectopic discharge might disappear, and normal function could be recovered. Such hypotheses need to be supported by more experimental evidence.^{18,19}

In this study, the most common form of ST was rotational + retrocollis that was found in 46% of cases. The sec-

ond most common form of ST was rotational torticollis that was found in 27% of cases. These findings were the same as reported by previous studies.^{3,16,17}

Various forms of surgical treatment for ST were used including anterior rhizotomy, posterior ramisectomy and combined technique.³

The general principle of the posterior cervical ramisectomy had been described by Bertrand et al.²⁰ The procedure is carried out under light general anesthesia, without curare, with both invasive and non-invasive monitoring. SPD cannot be carried out without neurostimulation. The latter is essential for the precise identification of the spinal accessory nerve and its branches destined to the SCM and trapezius, as well as to identify all posterior rami, from C3 to C5. With this procedure, some patients complained of numbness in the occipital area and a few showed deafferentation pain. This is obviously

because of the sensory components of the C2 nerve is sacrificed. Sensory deficit in the C2 region may not be very trouble some for daily life, but some patients in many series had an uneasy feeling of C2 sensory loss that makes them emotionally unstable.²¹

To decrease venous bleeding to preserve occipital sensory function, and to decrease total invasiveness, the technique of denervation was modified by Taira et al.²² that consists of the sectioning of intradural ventral roots of C1 and C2 through a limited C1 hemilaminectomy then the denervation was completed with the section of the posterior rami from C3 to C6 and the SCM denervation as in the original Bertrand procedure. This can be regarded as a combination of Dandy's²³ anterior rhizotomy and Bertrand's²⁰ ramisectomy. Thus it is no longer a peripheral technique. The anterior branches of C1 and C2 have important function for swallowing, and bilateral sectioning of these branches results in swallowing difficulties. Therefore, this combined approach is only indicated for unilateral denervation and not suitable in case of retrocollis that requires bilateral denervation.²⁰

The combined technique used in this study consists of intradural sectioning of the ventral roots of C1, C2 and may be C3 intradurally after C1, C2, and C3 laminectomy, but also due to the use of a shorter incision and the use of a surgical microscope. It allows patients to avoid postoperative sensibility disorder of the C2 cutaneous region. Since the C1 and C2 motor roots play a major role in swallowing, when carried out bilaterally, complete resection were done on one side while only partial resection were done on the opposite side.

Denervation of the SCM and LS muscle anteriorly, but through an incision on the posterior edge of the SCM muscle, gives access to the anterior nerve bundles which innervate these muscles and allows their selective section.²⁴ Disadvantage of this method is that it requires C1 and C2 laminectomy and dural opening.

The selective denervation of the majority of muscle involved in dystonia, gives good results for head posture, but leads to limited neck movement for some sufferers.^{16,17} Better determination the involvement of each muscle group is important that allowed the surgery to be performed in stages, initially dealing with the muscles in the dominant abnormal posture, with the possibility of later denervating the synergistic muscles. This strategy avoids unnecessary denervation for certain patients, thus allowing better post-operative function. The persistence of certain abnormal movements related to muscles that were not denervated should not lead one to consider the surgical operation a failure. The SPD and ventral rhizotomy do not cure dystonia. It may eventually evolve in a new form of muscular impairment.²⁵ During the immediate post-operative period, there may be present a series of new abnormal movements which are generally temporary and reversible. To limit this risk, preoperative medications should be maintained for few months, before considering weaning. Certain abnormal movements may appear after a short period of time. This may be due to reactivation of the muscles that had been denervated. In this study, SPD and ventral rhizotomy results are considered to be stabilized after a period of six months, while previous reports showed that the best treatment effects was observed over one to two years after operation.²⁰

In this study, at the last follow up period, six patients were cured (55%), two patients (18%) had improved with minimal spasms, another two patients (18%) had improved with moder-

Table 3 Summary of results for main surgical series.

Series	No	Duration of symptoms (years)	Average age	Complications	No of reoperated cases	Assessment criteria	Good to excellent results	Last follow up period (months)
Bertrand ²⁰	260	Not stated	Not stated	Infection (1)		Not stated	88%	Not stated
Ford et al. ²⁵	16	6.8	52.6	Not stated	7	Global satisfaction scale	69%	62.4
Meyer ²⁶	30	8	55	Not stated	19	TWSTERS	100%	26
Munchau et al. ²⁷	40	11	50	Infection (1), Shoulder deficiency (2), Dysphagia (12), Aggravation of oromandibular dystonia (2)	2	TWSTERS	67%	18
Braun and Richter ²⁸	155	8.5	48.2	Haematoma (3), Dysphagia (4), Laryngeal stenosis (1), Occipital neuralgia (3), Shoulder deficiency (1)	15	TWSTERS	73%	33
Chen et al. ²⁹	362	3.9	39	0	Not stated	Global satisfaction scale	87.9%	2-29 years
Taria et al. ²²	31	4.4	41	0	0	Tsu ³⁰ torticollis rating scale	100%	6
Gohen-Gadol et al. ³¹	168	8.6	53.4	Infection (1), Myocardial infarction (1), DVT (1), shoulder deficiency (3), Hypoxia (1)	17	Global satisfaction scale	70%	41

TWSTERS = Toronto Western Spasmodic Torticollis rating Scale. DVT = deep vein thrombosis.

ate spasms and one patient did not improve (9%). Abnormal neck posture that was present in all cases improved in patients (91%) postoperatively, while pain that was present in 44% of cases improved in all these cases as measured by visual analogue scale. Contrary to previous authors who reported that the type of deformation presented by ST does not seem to lead to significant differences in surgical results; better results were obtained in simple torticollis (excellent results in 100%), than in complex type (excellent and good results in 33.3%) in this study.²⁵⁻²⁷ Like the other series, age and gender were not studied as factors determining good or bad surgical results.²⁵⁻³⁰ Summary of results for main surgical series of ST are shown in Table 3.

Previous studies showed that the poor results are notably due to poorly selected targets. Therefore patients should be excluded who present with cervical dystonia less than two years, and have been stable for less than one year.²⁷⁻³² But many other causes of poor results could be incriminated like the appropriate muscles targeted by the operation, correct surgical technique proper postoperative physiotherapy and the progress of dystonia.²⁰

However, primary resistance to botulinum toxin is a significantly more controversial prognostic factor. Ford et al.²⁵ and Munchau et al.²⁷ did not observe any significant improvement in dystonia after surgery in their patients presenting primary toxin resistance. Conversely, 62% of Braun's et al.²⁸ patients who had never seen improvement with the toxin were satisfied by the results of surgery. Certain toxin resistance diagnoses had been made, although electromyographic screening had not been performed. Following EMG analysis of such patients, significant improvements were sometimes observed by changing injection sites. These elements leave the debate on this issue open.²⁷ Finally, according to Molina-Negro and Bouvier,³³ although patients presenting a good initial response to the toxin are the best candidates for SPD, primary toxin resistance is by no means a contraindication to surgery. In this study, all patients received previous repeated toxin injections, primary resistance to toxin was observed in two cases (18%); after surgery one of them had good result but the other had poor result.

5. Conclusion

There is no standard surgical procedure for treatment of ST; this is adapted to each patient according to type of torticollis. Better results were obtained in simple torticollis (excellent results in 100%), than in complex type (excellent and good results in 33.3%). SPD and ventral rhizotomy results are considered to be stabilized after a period of six months.

To obtain good results, careful selection of the patients (focal cervical dystonia for at least 2 years preoperatively), identification of appropriate muscles targeted by the operation, correct surgical technique and proper postoperative physiotherapy must be done.

References

- Gildenberg PL. Comprehensive management of spasmodic torticollis. *Appl Neurophysiol* 1981;**44**:233-3.
- Gildenberg PL, Tasker RR. Spasmodic torticollis. *Contemp Neurosurg* 1982;**4**(6):1-7.
- Hamby WB, Schiffer S. Spasmodic torticollis: results after cervical rhizotomy in 50 cases. *J Neurosurg* 1969;**31**:323-6.
- Hassler R, Dieckmann G. Stereotaxic treatment for spasmodic torticollis. In: Schaltenbrand G, Walker AE, editors. *Stereotaxy of the human brain: anatomical, physiological, and clinical applications*. 2nd ed. New York: Thieme-Stratton; 1982. p. 522-31.
- Wycis HT, Gildenberg PL. Long-range evaluation of the treatment of spasmodic torticollis. *Excerpta Med, Int Congr Ser* 1969;**193**:7.
- Friedman AH, Nashold BS, Sharp R, et al Treatment of spasmodic torticollis with intradural selective rhizotomies. *J Neurosurg* 1993;**78**:46-56.
- Jho HD, Jannetta PJ. Microvascular decompression for spasmodic torticollis. *Acta Neurochir (Wien)* 1995;**135**:21-6.
- Taira T. Spasmodic torticollis (letter). *J Neurosurg* 2004;**100**:171-2.
- Mundinger F, Riechert T, Disselhoff J. Long-term results of stereotactic treatment of spasmodic torticollis. *Confin Neurol* 1972;**34**:41-50.
- Colbassani Jr HJ, Wood JH. Management of spasmodic torticollis. *Surg Neurol* 1986;**25**:153-8.
- Herz E, Glaser GH. Spasmodic torticollis; clinical evaluation. *Arch Neurol Psychiatry* 1949;**61**:227-39.
- Duane DD. Spasmodic torticollis. *Adv Neurol* 1988;**49**:135-50.
- Nakashima K, Thompson PD, Rothwell JC, Day BL, Stell R, Marsden CD. An exteroceptive reflex in the sternocleidomastoid muscle produced by electrical stimulation of the supraorbital nerve in normal subjects and patients with spasmodic torticollis. *Neurology* 1989;**39**:1354-8.
- Choppy-Jacolin M, Ferrey G, Demaria C. A psychometric study of 34 patients afflicted with spasmodic torticollis. *Acta Neurol Scand* 1977;**55**:483-92.
- Adams CB. Microvascular compression: an alternative view and hypothesis. *J Neurosurg* 1989;**70**:1-12.
- Shima F, Fukui M, Kitamura K, et al. Diagnosis and surgical treatment of spasmodic torticollis of 11th nerve origin. *Neurosurgery* 1988;**22**:358-63.
- Freckmann N, Hagenah R, Herrmann HD, et al Bilateral microsurgical lysis of the spinal accessory nerve roots for treatment of spasmodic torticollis. Follow-up of 33 cases. *Acta Neurochir (Wien)* 1986;**83**:47-53.
- Nagata K, Matsui T, Joshita H, et al Surgical treatment of spasmodic torticollis: effectiveness of microvascular decompression. *No To Shinkei* 1989;**41**:97-102.
- Sun K, Lu Y, Hu G, et al. Microvascular decompression of the accessory nerve for treatment of spasmodic torticollis: early results in 12 cases. *Acta Neurochir* 2009;**151**:1251-7.
- Bertrand C, Molina-Negro P, Martinez SN. Combined stereotactic and peripheral surgical approach for spasmodic torticollis. *Appl Neurophysiol* 1978;**41**:122-33.
- Bertrand CM. Selective peripheral denervation for spasmodic torticollis: Surgical technique, results, and observation in 260 cases. *Surg Neurol* 1993;**40**:96-103.
- Taira T, Kobayashi T, Takahashi K, et al A new denervation procedure for idiopathic cervical dystonia. *J Neurosurg (Spine 2)* 2002;**97**:201-6.
- Dandy WE. An operation for treatment of spasmodic torticollis. *Arch Neurol* 1930;**20**:1021-32.
- Taira T, Kobayashi T, Takahashi K, et al Selective peripheral denervation of the levator scapulae muscle for laterocollis cervical dystonia. *Neuroscience* 2003;**10**:449-52.
- Ford B, Louis ED, Greene P, Fahn S. Outcome of selective ramisectomy for botulinum toxin resistant torticollis. *J Neurol Neurosurg Psychiatry* 1998;**65**:472-8.
- Meyer CHA. Outcome of selective peripheral denervation for cervical dystonia. *Stereotact Funct Neurosurg* 2001;**77**:44-7.
- Munchau A, Palmer JD, Dressler D, et al Prospective study of selective peripheral denervation for botulinum-toxin resistant patients with cervical dystonia. *Brain* 2001;**124**:769-83.

28. Braun V, Richter HP. Selective peripheral denervation for spasmodic torticollis: 13-year experience with 155 patients. *J Neurosurg (Spine 2)* 2002;**97**:207–12.
29. Chen X, Ma A, Liang J, et al. Selective denervation and resection of cervical muscles in treatment of spasmodic torticollis: Long-term follow-up results in 207 cases. *Stereotact Funct Neurosurg* 2000;**75**:96–102.
30. Tsui JKC, Eisen A, Stoessl AJ, et al. Double blinded study of botulinum toxin in spasmodic torticollis. *Lancet* 1986;**2**:245–7.
31. Cohen-Gadol AA, Ahlskog JE, Matsumoto JY, et al. Selective peripheral denervation for the treatment of intractable spasmodic torticollis: experience with 168 patients at the Mayo Clinic. *J Neurosurg* 2003;**98**:1247–54.
32. Motomochi M, Makita Y, Nabeshima S, et al. Surgical treatment and long-term result of spasmodic torticollis. *Neurol Med Chir (Tokyo)* 1983;**23**:741–6.
33. Molina-Negro P, Bouvier G. Surgical treatment of spasmodic torticollis by peripheral denervation. In: Tarsy D, Vitek J, Lozano AM, editors. *Surgical treatment of Parkinson's disease and other movement disorders*. Humana Press; 2004. p. 172–85.