



## Brown–Violetto–Van Laere syndrome: Egyptian case report

Hayam Moustafa, Tarek Omar & Yaser Sami

To cite this article: Hayam Moustafa, Tarek Omar & Yaser Sami (2012) Brown–Violetto–Van Laere syndrome: Egyptian case report, Alexandria Journal of Medicine, 48:1, 43-46, DOI: [10.1016/j.ajme.2011.08.007](https://doi.org/10.1016/j.ajme.2011.08.007)

To link to this article: <https://doi.org/10.1016/j.ajme.2011.08.007>



© 2011 Alexandria University Faculty of Medicine. Production and hosting by Elsevier B.V. All rights reserved.



Published online: 17 May 2019.



Submit your article to this journal [↗](#)



Article views: 81



View related articles [↗](#)



## CASE REPORT

# Brown–Vialletto–Van Laere syndrome: Egyptian case report

Hayam Moustafa <sup>a,\*</sup>, Tarek Omar <sup>b</sup>, Yaser Sami <sup>b</sup>

<sup>a</sup> Department of Physical Medicine, Rheumatology and Rehabilitation, Alexandria Faculty of Medicine, Alexandria University, Egypt

<sup>b</sup> Department of Pediatrics, Alexandria Faculty of Medicine, Alexandria University, Egypt

Received 13 June 2011; accepted 26 August 2011

Available online 3 December 2011

### KEYWORDS

Brown–Vialletto–Van Laere syndrome;  
Hearing impairment;  
Progressive bulbar palsy

**Abstract** We report an Egyptian case with Brown–Vialletto–Van Laere syndrome. A five-year-old girl with progressive hearing loss was documented by brainstem auditory evoked potentials (BAEP) as sensorineural deafness, bilateral facial palsy and bilateral partial vocal cord paralysis in the paramedian position. There was no evidence of involvement of the upper motor neurons or spinal motor nerves. There is no similar case in the family.

© 2011 Alexandria University Faculty of Medicine. Production and hosting by Elsevier B.V. All rights reserved.

## 1. Introduction

The Brown–Vialletto–Van Laere syndrome (BVVL) is a rare disorder characterized by sensorineural deafness followed or

*Abbreviations:* BVVL, Brown–Vialletto–Van Laere syndrome; BAEP, brain stem auditory evoked potential; MRI, magnetic resonance image; MMND, the Madras motor neuron disease.

\* Corresponding author. Present/permanent address: Faculty of Medicine, Department of Physical Medicine, Rheumatology and Rehabilitation, Alexandria University, Egypt.

E-mail address: hayam\_mstf@yahoo.com (H. Moustafa).

2090-5068 © 2011 Alexandria University Faculty of Medicine. Production and hosting by Elsevier B.V. All rights reserved.

Peer review under responsibility of Alexandria University Faculty of Medicine.

doi:10.1016/j.ajme.2011.08.007



Production and hosting by Elsevier

accompanied by cranial nerve disorders, usually involving the motor components of the facial and glossopharyngeal to hypoglossal nerves.<sup>1,2</sup> It was first described by Brown in 1894,<sup>3</sup> and later by Vialletto in 1936<sup>4</sup> and Van Laere in 1966.<sup>5,6</sup> The age of onset of the first symptoms varies ranging from infancy to the third decade<sup>6,7</sup>. Fifty-eight cases of BVVL have been reported in just over a century. Around half of all cases are sporadic.<sup>8</sup>

The majority of familial cases demonstrate autosomal recessive inheritance, although autosomal dominant<sup>1,9</sup> and X-linked inheritance<sup>1</sup> have been suggested in a few families. The female to male ratio is approximately 3:1 in reported cases.<sup>7</sup> Recently Green et al. identified a candidate gene, C20orf54, by studying a consanguineous family with multiple affected individuals and subsequently demonstrated that mutations in this gene were the cause of disease in other, unrelated families.

We reported the clinical and neurophysiological features of a patient with deafness, with cranial nerve involvement, and respiratory difficulties. This clinical picture and neurosensorial deafness suggest the diagnosis of pontobulbar palsy with sensorineural deafness or Brown–Vialletto–Van Laere syndrome.

## 2. Case report

A five-year-old girl was brought up by her parents who noticed progressive hearing loss. This was associated with dysphonia. Video laryngoscope was done and revealed bilateral partial vocal cord paralysis in the paramedian position. Subsequently, she suffered from severe respiratory distress and admitted to a hospital where a permanent tracheostomy was done. Two months later the mother noticed that her girl developed mask face (unable to smile), inability to close both eyes, excessive salivation with food accumulation at vestibules. Bilateral facial nerve paralysis was documented. The patient was referred to our hospital.

On admission, there were no motor or sensory complaints in both upper and lower limbs, and no sphincter disturbances. Prenatal, perinatal, and postnatal histories were free.

Her psychomotor development was normal. Vaccinations were given as scheduled.

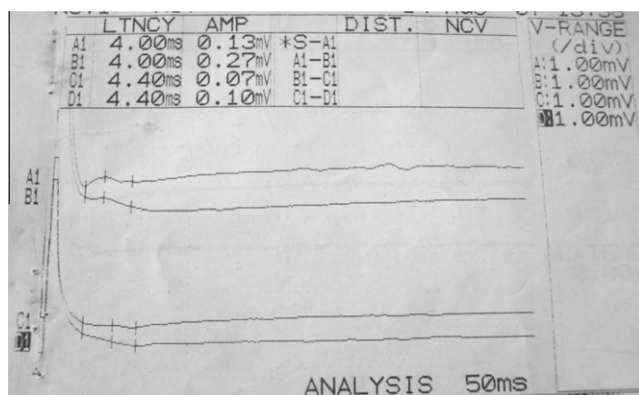
Family history revealed positive consanguinity of first degree but there was no family history of similar condition.

By physical examination, the child was conscious, alert not distressed but uncooperative due to hearing loss. Tracheostomy tube was present. She had masked face, opened mouth, excessive salivation, mild deviation of the mouth angle to the left, unable to smile, cannot blow or purse mouth, cannot firmly close the eyes and cannot raise her eye brows. There were wasting and weakness of side to side tongue movement and fasciculations. Muscle tone and power as well as tendon reflexes were normal. There were no signs of wasting or sensory abnormalities in both upper and lower limbs.

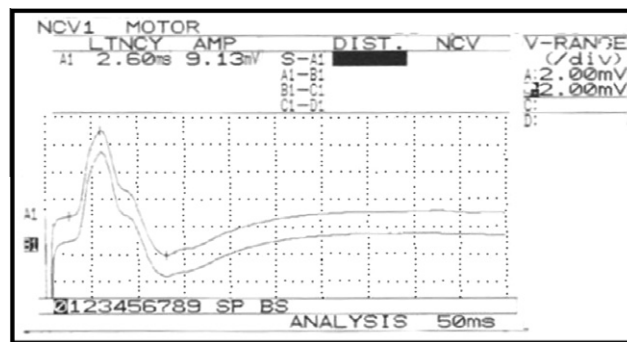
Electrophysiological study revealed: normal motor and sensory conduction studies of the peripheral nerves. Facial nerve conduction study to orbicularis oculi muscles showed low amplitude (left 0.27 mV and right 0.1 mV) and delayed latency (left 4 ms and right 4.4 ms) (Fig. 1). Normal facial conduction study to orbicularis oculi muscle (Fig. 2).

Poor response of the blink reflex (Fig. 3). Needle electromyography to orbicularis oculi and oris muscles showed motor unit drop out and polyphasicity. While muscles of the upper and lower limbs were normal. This was consistent with severe axonal degeneration of the facial nerve bilaterally.

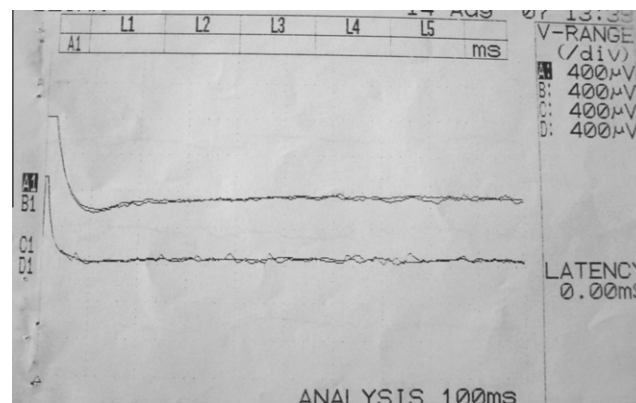
Video laryngoscope revealed; 'bilateral partial vocal cord paralysis in the paramedian position.



**Figure 1** Facial nerve conduction study to orbicularis oculi muscles (delayed latencies and low amplitude on both sides).



**Figure 2** Normal facial conduction study to orbicularis oculi muscle.



**Figure 3** Poor response of the blink reflex.

Brain stem auditory evoked potential (BAEP) revealed; bilateral severe sensory neural hearing loss at high frequency. Magnetic resonance image (MRI), blood chemistry, electrocardiogram and echocardiography, were unremarkable.

## 3. Discussion

The Brown-Vialetto-Van Laere syndrome (BVVL) is a rare neurological disorder of unknown etiology, characterized by progressive pontobulbar palsy associated with sensorineural deafness.<sup>6</sup>

In our patient sensorineural deafness is the first symptom of the disease. Hearing loss has been consistently described at the onset of the disease both in familiar and non-familiar cases.<sup>10</sup>

The sensorineural deafness was accompanied by multiple cranial nerve palsies involving the motor components of the 7th, 9th and 12th cranial nerves, but there was no evidence of involvement of the upper motor neurons or spinal motor nerves in our case. Together, the clinical findings suggested a diagnosis of progressive pontobulbar palsy with sensorineural deafness, or BVVL syndrome.

There are several conditions that closely resemble BVVL and that should always be considered in the differential diagnosis. It would be difficult to diagnose BVVL in a patient who initially presents with just sensorineural deafness. The development of other cranial nerve in conjunction with sensorineural deafness is likely to be needed to secure the diagnosis with any degree of confidence. The most closely related

condition is the progressive bulbar paralysis of Fazio-Londe,<sup>11</sup> where the only distinguishing feature from BVVL is the absence of deafness. Another differential of BVVL is the Nathalie syndrome, which is a rare condition characterized by deafness in conjunction with spinal muscular atrophy, cataract, cardiac conduction defects and hypogonadism.<sup>12</sup> The Boltshauser syndrome, which is characterized by distal muscular atrophy with vocal cord paralysis and sensorineural hearing loss, is also very similar to BVVL.<sup>13</sup> However, in the former, the brainstem signs are restricted to vocal cord paralysis and the inheritance is likely to be autosomal dominant. Autosomal dominant inheritance is very uncommon in BVVL, with only two families reported.<sup>1,9</sup> The Madras motor neuron disease (MMND) is another condition closely related to BVVL.<sup>14</sup> MMND is characterized by wasting and weakness of limb muscles, sensorineural deafness and multiple cranial nerve palsies usually affecting cranial nerves VII, IX and XII. Dysfunction of cranial nerves III and VI has not been reported in MMND.<sup>15</sup> Interestingly, one reported case of BVVL had a partial right bundle branch block on electrocardiography<sup>8</sup> but our patient had normal echocardiography.

The etiopathogenesis of BVVL syndrome is still unknown and genetic transmission is quite variable; autosomal recessive, autosomal dominant, and X-linked inheritance, as well as autoimmune origin have been considered.<sup>1,9,16</sup> Recently, Green et al.<sup>17</sup> reported the identification of mutations in the C20orf54 gene as the cause of BVVL syndrome. Also, Bosch et al.<sup>18</sup> demonstrated that BVVL syndrome is associated with the riboflavin deficiency that resulted from a defect in the riboflavin transporter, encoded by the C20orf54 gene. As regards our patient there is no family history of similar condition even of hearing loss although there is a positive consanguinity between the parents.

Laryngeal dyspnea and stridor due to paralysis of the vocal cords, which may lead to acute hospital admission with the mistaken diagnosis of croup, as was observed in our case, are early and striking manifestations in BVVL syndrome.<sup>19</sup>

In our patient hearing loss has been reported as the first presentation; however, in case 2 of Gallai et al.<sup>19</sup> bulbar weakness at 20 months was the first evident symptom and hearing loss was never documented during life time but only at autopsy. Konstantinos et al.<sup>16</sup> reported a male infant with late onset hearing loss, Necropsy in this case revealed severe loss of axons and of myelin of the 8th nerve roots and heavy gliosis in the ventral cochlear nuclei. In our case, however, the deafness was documented by performing BAEP. The recognition of the onset of deafness without performing BAEP may be missed in infants and young children, especially those with simultaneous severe neurological problems.

The protracted cases may show a steady progression or a streaking irregular course with relapsing phases followed by periods of arrest and even partial improvement. Piccolo and co-workers<sup>20</sup> described the case of a sporadic BVVL with recovery from respiratory muscle failure. Gallai and coworkers<sup>19</sup> reported two cases characterized by improvement of dysphagia and motor performances. De Grandis and coworkers<sup>9</sup> described a case with clinical and neurophysiological improvement as well. The case we described showed a stationary course.

Investigations are usually done to exclude other causes or confirm the clinical signs of the patients. Neurophysiological studies demonstrate changes consistent with chronic<sup>21-24</sup> or

active<sup>7,8,25</sup> denervation in muscles. Motor nerve conduction velocities are usually normal.

Sensory action potentials are rarely reduced.<sup>7,9</sup> The electrophysiological study of our patient showed poor response of the blink reflex with low amplitude of facial nerve conduction study and delayed latency that indicate severe loss of axons and myelin in the roots of the 7th cranial nerves. Normal peripheral conduction study with normal needle electromyography to muscles of the upper and lower limbs are going with the absence of spinal nerve involvement.

Brainstem auditory evoked potentials were abnormal when performed in 17 cases,<sup>7,1,23,26-32</sup> as in our patient.

There are no MRI changes in our patient, although others reported changes in MRI in the form of atrophy of the brainstem<sup>30,31</sup> and cerebellum,<sup>30-32</sup> or hyperintensity in the brainstem nuclei.<sup>26,32</sup>

There is no specific treatment for BVVL. Supportive care and symptomatic treatment are the mainstays of management for this child. Steroids and immunoglobulins have been tried in several cases.<sup>6,33</sup>

## References

- Hawkins SA, Nevin NC, Harding AE. Pontobulbar palsy and neurosensory deafness (Brown-Vialetto-Van Laere syndrome) with possible autosomal dominant inheritance. *J Med Genet* 1990;**27**:176.
- Prabhu HV, Brown MJS. Brown-Vialetto-Van Laere syndrome: a rare syndrome in otology. *J Laryngol Otol* 2005;**119**(6):470-2.
- Brown CH. Infantile amyotrophic lateral sclerosis of the family type. *J Nerv Ment Dis* 1894;**21**:707-16, Quoted from Ref. [6].
- Vialetto E. Contributo alla forma ereditaria della paralisi bulbare progressive. *Riv Sper Freniat* 1936;**40**:1-24, Quoted from Ref. [6].
- Van Laere J. Paralyse bulbo-pontine chronique progressive familiale avec surdit . Un cas de syndrome de Klippel. *Rev Neurol* 1966;**115**:289-95, Quoted in Ref. [6].
- Sathasivam S. Brown-Vialetto-Van Laere syndrome review. *Orphanet J Rare Dis* 2008;**3**:9.
- Voudris KA, Skardoutsou A, Vagiakou A. Infantile progressive bulbar palsy with deafness. *Brain Dev* 2002;**24**:732-5.
- M egarban  A, Desguerres I, Rizkallah E, Delague V, Nabbout R, Barois A, et al. Brown-Vialetto-Van Laere syndrome in a large inbred Lebanese family: confirmation of autosomal recessive inheritance? *Am J Med Genet* 2000;**92**:117-21.
- De Grandis D, Passadore P, Chinaglia M, Brazzo F, Ravenni R, Cudia P. Clinical features and neurophysiological follow-up in a case of Brown-Vialetto-Van Laere syndrome. *Neuromusc Disord* 2005;**15**:565-8.
- Malheiros Jos  Augusto, Camargos Sarah Teixeira, de Oliveira Jos  Teotonio, Cardoso Francisco EC. Brazilian family with Brown Vialetto Van Laere syndrome with autosomal recessive inheritance. *Arq Neuropsiquiatr* 2007;**65**(1):32-5.
- McShane MA, Boyd S, Harding B, Brett EM, Wilson J. Progressive bulbar paralysis of childhood. A reappraisal of Fazio-Londe disease. *Brain* 1992;**115**:1889-900.
- Cremers CW, Ter Haar BG, Van Rens TJ. The Nathalie syndrome. A new hereditary syndrome. *Clin Genet* 1975;**8**:330-40.
- Boltshauser E, Lang W, Spillman T, Hof E. Hereditary distal muscular atrophy with vocal cord paralysis and sensorineural hearing loss: a dominant form of spinal muscular atrophy. *J Med Genet* 1989;**26**:105-8.
- Meenakshisundaram E, Jagannathan K, Ramamurthy B. Clinical pattern of motor neuron disease seen in younger age groups in Madras. *Neurol India* 1970;**18**(Suppl 3):109-12.

15. Nalini A, Yamini BK, Gayatri N, Thenmarasu K, Gope R. Familial Madras motor neuron disease (FMMND): study of 15 families from southern India. *J Neurol Sci* 2006;**250**:140–6.
16. Voudris Konstantinos A, Skardoutsou Angeliki, Vagiakou Eleni A. Infantile progressive bulbar palsy with deafness case report. *Brain Dev* 2002;**24**:732–5.
17. Green P, Wiseman M, Crow YJ, Houlden H, Riphagen S, Lin JP, et al. Brown–Violetto–Van Laere Syndrome, a ponto-bulbar palsy with deafness, is caused by mutations in C20orf54. *Am J Hum Genet* 2010;**86**:485–9.
18. Bosch AM, Abeling NG, IJlst L, Knoester H, Pol WL, Stroomer AE, et al. Brown–Violetto–Van Laere and Fazio Londe syndrome is associated with a riboflavin transporter defect mimicking mild MADD: a new inborn error of metabolism with potential treatment. *J Inherit Metab Dis* 2011;**34**:159–64.
19. Gallai V, Hockaday JM, Hughes JT, Lane DJ, Oppenheimer DR, Rushworth G. Ponto-bulbar palsy with deafness (Brown–Violetto–Van Laere syndrome). A report on three cases. *J Neurol Sci* 1981;**50**:259–75.
20. Piccolo G, Marchioni E, Maurelli M, Simonetti F, Bizzetti F, Savoldi F. Recovery from respiratory muscle failure in a sporadic case of Brown–Violetto–Van Laere syndrome with unusually late onset. *J Neurol* 1992;**239**:355–6.
21. Dipti S, Childs A-M, Livingston JH, Aggarwal AK, Miller M, Williams C, et al. Brown–Violetto–Van Laere syndrome: variability in age at onset and disease progression highlighting the phenotypic overlap with Fazio-Londe disease. *Brain Dev* 2005;**27**:443–6.
22. Aydın ÖF, Özcelikel D, Senbil N, Gürer YKY. Brown–Violetto–Van Laere syndrome; the first Turkish case. *Acta Neurol Belg* 2004;**104**:111–3.
23. Sathasivam S, O’Sullivan S, Nicolson A, Tilley PJ, Shaw PJ. Brown–Violetto–Van Laere syndrome: case report and literature review. *Amyotroph Lateral Scler Other Motor Neuron Disord* 2000;**1**(4):277–81.
24. Davenport RJ, Mumford CJ. The Brown–Violetto–Van Laere syndrome: a case report and literature review. *Eur J Neurol* 1994;**1**:51–4.
25. RamachandranNair R, Parameswaran M, Girija AS. Violetto–Van Laere syndrome in two sisters born to consanguineous parents. *Pediatr Neurol* 2004;**30**:354–5.
26. Koul R, Jain R, Chacko A, Alfutaisi A, Hashim J, Chacko J. Pontobulbar palsy and neurosensory deafness (Brown–Violetto–Van Laere syndrome) with hyperintense brainstem nuclei on magnetic resonance imaging: new finding in three siblings. *J Child Neurol* 2006;**21**:523–5.
27. Abarbanel JM, Ashby P, Marquez-Julio A, Chapman KR. Bulbo-pontine paralysis with deafness: the Violetto–Van Laere syndrome. *Can J Neurol Sci* 1991;**18**:349–51.
28. Nemoto H, Konno S, Nomoto N, Wakata N, Kurihara T. A case of Brown–Violetto–Van Laere (BVVL) syndrome in Japan. *Clin Neurol* 2005;**45**:357–61.
29. Miao J, Li H, Lin H, Su C, Liu Y, Lei G, et al. Severe sleep disordered breathing in a patient with Brown–Violetto–Van Laere syndrome: polysomnographic findings. *J Neurol Sci* 2007;**263**:214–7.
30. Francis DA, Ponsford JR, Wiles CM, Thomas PK, Duchon LW. Case report. Brown–Violetto–Van Laere syndrome. *Neuropathol Appl Neurobiol* 1993;**19**:91–4.
31. Koc AF, Bozdemir H, Sarica Y. Mental retardation associated with Brown–Violetto–Van Laere syndrome. *Amyotroph Lateral Scler Other Motor Neuron Disord* 2003;**4**(1):52–3.
32. Malheiros JA, Camargos ST, de Oliveira JT, Cardoso FEC. A Brazilian family with Brown–Violetto–Van Laere syndrome with autosomal recessive inheritance. *Arq Neuropsiquiatr* 2007;**65**:32–5.
33. Gallai V, Hockaday JM, Hughes JT, Lane DJ, Oppenheimer DR, Rushworth G. Ponto-bulbar palsy with deafness (Brown–Violetto–Van Laere syndrome). *J Neurol Sci* 1981;**50**:259–75.