



Human immunodeficiency virus and the anorectum

Elroy Patrick Weledji

To cite this article: Elroy Patrick Weledji (2013) Human immunodeficiency virus and the anorectum, Alexandria Journal of Medicine, 49:2, 163-167, DOI: [10.1016/j.ajme.2012.12.001](https://doi.org/10.1016/j.ajme.2012.12.001)

To link to this article: <https://doi.org/10.1016/j.ajme.2012.12.001>



© 2013 Alexandria University Faculty of Medicine. Production and hosting by Elsevier B.V. All rights reserved



Published online: 17 May 2019.



Submit your article to this journal [↗](#)



Article views: 70



View related articles [↗](#)



Citing articles: 1 View citing articles [↗](#)



REVIEW

Human immunodeficiency virus and the anorectum

Elroy Patrick Weledji

Faculty of Health Sciences, University of Buea, Buea, South West Region, Cameroon

Received 21 August 2012; accepted 20 December 2012

Available online 5 March 2013

KEYWORDS

Human immunodeficiency virus (HIV);
Acquired immune deficiency syndrome (AIDS);
Anorectal disorders;
Surgical management;
Prognosis

Abstract An understanding of HIV/AIDS is important to the practice of colon and rectal surgery as these patients frequently present with proctological diseases. Operations for anorectal pathology represent one of the most common indications for surgery in HIV-positive patients. It appears that anorectal pathology in HIV/AIDS infected patients has not been impacted by highly active anti retroviral therapy. The general approach to the HIV- infected patient and management of the anorectal diseases are discussed. Surgical procedures can be safe and effective therapeutic modalities. Symptomatic improvement of the underlying anorectal pathology may make delayed wound healing an acceptable complication in many AIDS patients. Part of the complete treatment includes education, treatment and counselling of sexual partners.

© 2013 Alexandria University Faculty of Medicine. Production and hosting by Elsevier B.V. All rights reserved.

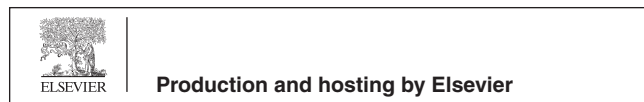
Contents

1. Introduction	163
2. Method	164
3. Anorectal problems in AIDS patients	164
4. Proctological diseases.	165
5. Conclusions	166
References	166

1. Introduction

Human immunodeficiency virus (HIV) is an RNA retrovirus that infects human T lymphocytes. It is transmitted by contaminated body fluids and, after a variable latent period of 5–10 years, it produces diminished immunological function which manifests as the acquired immunodeficiency syndrome (AIDS). The suppressed cellular immunity allows the development of malignancies (Kaposi's sarcoma, lymphoma) and opportunistic infections (Pneumocystis carinii pneumonia,

E-mail address: elroypat@yahoo.co.uk
Peer review under responsibility of Alexandria University Faculty of Medicine.



cryptosporidium, cytomegalovirus (CMV), herpes simplex virus (HSV), varicella zoster virus (VZV) and fungi (candida)).¹ There is no cure but the highly active antiretroviral treatment (HAART) prolongs survival in some patients. Since its discovery in 1981,¹ AIDS has rivalled the worse epidemics in history with the highest prevalence in sub-Saharan Africa. As of 2004 an estimated 25 million people have died, and 40 million are living with AIDS.² The incidence of HIV infection has apparently leveled in the USA and Western Europe and the mortality from these infections has decreased as HAART has become widely available.² Surgical presentation is with anorectal complaints (40%), requests for venous access (20%), cutaneous manifestations (20%), abdominal pain, requests for biopsy and others (20%).³

HIV is one of the sexually transmitted organisms that affect the anorectum. Other viral organisms include cytomegalovirus, herpes simplex virus (HSV), human papilloma virus (condylomata acuminatum), and molluscum contagiosum. Bacterial organisms include *Campylobacter jejuni*, *Chlamydia trachomatis*, *Lymphogranuloma venereum*, *Haemophilus ducreyi* (chancroid), *Neisseria gonorrhoeae* (gonorrhoea), *Donovania granulomatis* (granuloma inguinale) and *Treponema pallidum* (syphilis). The presence of more than one offending organism is common and the presenting symptoms may range from gastrointestinal (diarrhoea, rectal bleeding) to visible lesions in the anus and perineum.⁴ The diarrhoea associated with the opportunistic colonic infections (CMV and bacterial colitis), is severe and encourages anal ulceration. The more typically regarded organisms that cause sexually transmitted diseases (STDs) including HIV involving the anorectum present with two main symptom complexes; proctitis or perianal ulceration.⁴ For the malignancies, Kaposi's sarcoma may resemble an ulcerated haemorrhoid, non-Hodgkin's lymphoma may resemble a perianal abscess and squamous cell carcinoma may be mistaken for a small benign ulcer.

The increased prevalence and variety of STDs seen in the Western world have been attributed to greater promiscuity, homosexuality and the use of the anorectum for sexual gratification.⁵ Unprotected anoreceptive sex and multiple partners are two common behaviours among homosexual males that put them at increased risk for anorectal STDs. Females are also affected by anorectal STDs, with more than 10% of American women and their male consorts engaging in anorectal sexual activity.⁵ Paramount to the diagnosis of these diseases is a thorough history about sexual practices. These discussions may be uncomfortable for the patient and practitioner, but without them the proper diagnosis is likely to be missed. The aim of this review is to present and assess the proctological diseases related to HIV/AIDS and the implications on surgical management.

2. Method

Electronic searches of the Medline (PubMed) database, Cochrane library, and science citation index were performed to identify original published studies on HIV/AIDS and anorectal disorders. Relevant articles were searched from relevant chapters in specialized texts and all included.

The general approach to the HIV-infected patient with proctological complaints start with a thorough history, which includes presenting symptoms, bowel and sphincter function,

sexual practices, the number and gender of sexual partners from the past 12 months, use of protection, past history of STDs, past HIV testing and prior anorectal surgery. Part of the complete treatment of STDs including HIV includes educating the patient as to the mode of transmission and ways to avoid subsequent reinfection. This frequently includes treatment and counselling of sexual partners.^{4,5} The current anti retroviral treatment the patient is taking as well as CD4 counts and viral load are determined. The decision to undertake surgery is aided by staging patients according to their level of general immunity (CDC stages I-IV) The CD4 T-lymphocyte categories are, category 1 (> 500 cells/ μ l), category 2 (200-499 cells/ μ l), and category 3 (< 200 cells/ μ l). A CD4 level of greater than 500 indicates mild disease and implies that appropriate operative treatment should not be withheld. A CD4 level of less than 500 indicates advanced disease and an exceedingly poor outcome.^{7,25} The pathophysiological consequences of advanced disease (e.g. immunosuppression, malnutrition, infections and neoplasms) could dictate the scaling down of the magnitude of surgery to an acceptable and safe level.

However, CD4 studies of the value of viral loads and CD4 counts (alone or in combination) in predicting operative morbidity and mortality did not produce conclusive results and these tests are not ideal for every day practical use.^{8,11}

The four factors that have been found to increase operative morbidity and mortality in HIV/AIDS patients are: a compromised physiological state (a poor American Society of Anaesthesiology-ASA or Korkoroff's performance score), physiologically demanding surgery, emergency surgery, and operations in contaminated fields, e.g. anorectum or oral cavity.⁸ In the current HAART era, patients have an improved general resistance to infection and are nutritionally better.³⁰ Postponing elective operations with the aim of starting the patient on antiretroviral medication to improve the CD4 count should be encouraged.⁸ Special protective procedures, for example the use of prophylactic antibiotics is essential when dealing with these patients.³

3. Anorectal problems in AIDS patients

Operations for anorectal pathology represent one of the most common indications for surgery in HIV-positive patients.^{3,4} The improved surgical outcomes together with the preventive measures against occupational HIV transmission have resulted in the treatment of HIV/AIDS patients becoming an accepted part of routine surgical practice.^{8,11,30} With increasing survival of HIV/AIDS patients on HAART the other non-AIDS related anorectal disorders requiring treatment predominate. Two-thirds of AIDS patients needing surgical treatment for anorectal disease such as symptomatic haemorrhoids, perianal sepsis were rendered symptom-free. So treatment is well worth doing as the survival is close to the survival of patients with AIDS who did not have anorectal disease.^{4,11} One concern in taking care of these patients is how their disease affects wound healing. It appears that patients who are HIV positive without AIDS have no increased risk of wound problems, while those with AIDS are more likely to have delayed wound healing.^{8-10,26} There are minimal problems with wound healing if wound care for HIV-AIDS patients incorporate the WHO suggestions or the UK NICE guidelines for reduction of wound infection.⁹ Sphincter preservation is of utmost importance during all anal

operations because male homosexuals have a tendency towards incontinence and the diarrhoea associated with opportunistic colonic infections is often severe. The HIV also has a predilection for the external anal sphincter predisposing urge (active) incontinence.^{4,18}

4. Proctological diseases

HIV/AIDS patients frequently present with proctological diseases divided into three categories⁴: (1) Proctological complaints common to the population at large (e.g. haemorrhoids, fissures, pruritis) are frequently seen in HIV/AIDS patients and in the absence of routine screening may be the primary reason for seeking medical help. (2) Diseases associated with high-risk behaviours such as anoreceptive intercourse. Included in this group are the STDs which cause proctitis and anogenital ulcerations. (3) Those illnesses associated with HIV infection such as HIV anal ulceration, unusual opportunistic infections, Kaposi's sarcoma and lymphoma.

The distribution of the most common anorectal pathologies reported in HIV patients include anal ulcer (29–32%), anal condyloma (32–43%), anal fissure (6–33%), anal fistula (6–33%), perirectal abscess (3–25%) and haemorrhoids (4–14%).⁶ AIDS-associated ulcers are most commonly associated with patients with clinical AIDS and lower CD4 counts and it appears that since the introduction of HAART it is a less common clinical problem.²⁷ However, one published series has reported no change in the prevalence and distribution of anal pathology (including AIDS ulcers) since the introduction of HAART.⁶

Internal haemorrhoids most commonly presents with symptoms of bleeding or prolapse. HIV-positive patients are treated along the same treatment schedule as HIV-negative patients. Initial management is with increased dietary fibre, bulking agents and topical preparations. Those that remain symptomatic are treated with local measures such as rubber band ligation, infrared coagulation or sclerotherapy.⁴ There were no complications related to banding and 91% of patients had at least some improvement of their presenting symptoms.¹² Haemorrhoidectomy is indicated in patients who fail conservative treatments. The results of haemorrhoidectomy in HIV-positive patients have been conflicting, most likely because of difference in the severity of AIDS. Hewitt et al.¹³ found no difference in wound healing times in HIV-negative vs. HIV positive, HIV positive vs. HIV/AIDS, or CD4⁺ > 200 vs. CD4⁺ < 200. However, Morandi et al.¹⁰ found 50% of patients with AIDS failed to heal in 32 weeks after haemorrhoidectomy. The two factors most associated with poor wound healing were AIDS and Karnofsky's performance score. Taking these studies into account haemorrhoidectomy should be offered to HIV-positive patients without AIDS based on standard indications just as for HIV-negative patients. AIDS patients with more advanced disease, low CD4⁺ counts (< 100) or poor performance status are at increased risk. The benefits of resolution of symptoms must be balanced against this risk.

Acute anorectal abscesses are treated by incision and drainage of the abscess and mushroom catheter (malecot) placed for 5–7 days. Broad spectrum antibiotics are prescribed especially if there is any associated cellulitis.⁴ Fistula treatment in patients with AIDS and decreased CD4⁺ or leucocytes is similar to those of Crohn's patients with draining setons placed to

control sepsis. Fistulas in HIV/AIDS with normal counts are treated with the same treatment algorithm as HIV-negative patients.^{3,4,18}

Idiopathic anal fissures in HIV-positive patients must be distinguished from HIV-associated ulcers and STDs that cause anogenital ulcers.¹⁴ Treatment is similar to that of the HIV-negative population starting with conservative measures such as warm soaks, stool softeners and topical ointments. Anoreceptive intercourse is discouraged. Two percent diltiazem ointment applied two to three times daily to the anus or botulinum toxin injected into the internal anal sphincter is alternative treatments to surgery in patients who do not respond to initial conservative measures. Lateral internal anal sphincterotomy is appropriate for patients who fail conservative measures but do not have chronic diarrhoea or pre-existing incontinence. Alternatively a cutaneous advancement flap is preferred in those with a contraindication to sphincterotomy.⁴

AIDS-associated anal ulcers are a distinct disease process from typical anal fissures. Clinically they both result in pain with defaecation, but AIDS ulcers are more likely to result in disabling pain unrelated to bowel movements.¹⁵ Diarrhoea encourages anal ulceration and stool cultures for salmonella, shigella, campylobacter and cryptosporidium with microscopy for giardia, ova cysts and amoebae are mandatory.⁴ On examination AIDS ulcers are differentiated by their location proximal to the dentate line with a broad-based ulcer which may dissect between tissue planes. The presence of a cavity contributes to stool and pus trapping which may explain the severity of pain. Biopsy identifies treatable aetiologies of these ulcers, including HSV, CMV, *Treponema pallidum*, mycobacterium, cryptococcus, *Haemophilus ducreyi*, *Chlamydia trachomatis* and cancer.⁴ Long term cultures from an ulcer base may reveal mycobacterium avium intracellulare. Viral cultures can detect CMV or acyclovir-resistant strains of HSV which can both cause extensive anal ulceration. CMV can also be detected on rectal biopsy. Isolated CMV proctitis is uncommon and presents with non-specific symptoms like tenesmus, diarrhoea and haematochezia. Medical treatment of CMV requires either intravenous ganciclovir or intravenous foscarnet, lasting 3–6 weeks depending on clinical response.¹⁶ As ulcer healing is not common the goal of surgical treatment is pain relief effected by debridement, unroofing cavities (to eliminate trapping) and repeat intralesional steroid injection for recurrent pain.¹⁵

Anal warts Human Papilloma virus (HPV) is a DNA virus that is the cause of viral warts on the skin and the genitalia. HPV infection is spread by direct contact with infected skin or fluid and is frequently silent in 70% of sexually active people. It becomes more clinically apparent as anal warts in the immunosuppressed HIV/AIDS patient.¹⁷ Anal intercourse is not required for anal infection to occur. Low-risk (non-oncogenic) HPV serotypes such as HPV 6 and 11 account for the majority of anogenital warts. Anal warts in AIDS patients tend to be aggressive, dysplastic and harder to eradicate. As with other viral infections, it is impossible to eradicate the causative human papilloma virus (HPV) infection by surgical excision. For this reason the surgical excision of condylomas is effectively performed more for relief of symptoms and cosmesis.¹⁸ Excision may have the benefit of providing tissue for histopathology in recurrent or atypical appearing lesions or in HIV-positive patients. Electrocautery is satisfactory for isolated warts but precise scissor excision on a bleb of raised skin is preferable for extensive warts to preserve the intervening

skin bridges and subsequent stenosis.⁴ A risk of using the laser is the problem of aerosolised active viral particles in the laser plume and cases of medical providers developing condylomata in the respiratory tract have been reported. Transmission of viral particles appears to be less of a problem with the larger-particle smoke from electrocautery.⁴ Topical podophyllin or 5% 5-fluorouracil cream applied through a proctoscope is time consuming, tedious and often of little benefit with high recurrence rates.¹⁹ Excision has produced the best results for anal condylomata but topical 5% imiquimod cream has shown promise. By acting as a local immunomodulator that induces α -interferon, tumour necrosis factor- α and other cytokines it has the potential to eradicate HPV from the mucocutaneous surfaces adjacent to gross lesions, which could decrease recurrences and treatment failures. Complete resolution of lesions occurs in >50% of cases and additional patients experience a substantial reduction of wart volume.²⁰ Recurrences occur in 10–20%. Imiquimod can be used as solitary therapy, 'debulking' large condylomata in order to minimise pain and fibrosis caused by fulguration/excision, treating early recurrences after surgical treatment or as 'adjuvant' treatment after surgical treatment. Females should undergo regular cervical colposcopic screening because of the associated risk of cervical cancer.²¹ There is good evidence that severe dysplasia may progress to Ca-in situ and thence to squamous cell cancer. A quadrivalent HPV vaccine against the high risk (oncogenic) serotypes HPV 6, 11, 16 and 18 is now available but its use is prophylactic. Current recommendations are to vaccinate females before exposure to HPV. No data are available on the efficacy of this vaccine for preventing anogenital HPV in males.²²

Neoplasia Malignant neoplasia is remarkably of high incidence for young people with HIV/AIDS.^{3,4,25} This includes *non-Hodgkin's lymphoma* in the perianal area.²⁵ When this presents in the ischio-rectal fossa, it can look exactly like a tense ischio-rectal abscess. It is tense, hot and tender, but solid. The temptation in the middle of the night is for the junior doctor to plunge a knife into and let all the pus out. The diagnosis can be made by a needle biopsy via the perineum. A biopsy should not be taken inside the anal canal as the patient will develop a fistula in the lymphomatous tissue.⁴ *Kaposi's sarcoma* may resemble an ulcerated haemorrhoid and is treated by radiotherapy. Excision usually leaves a painful unhealed ulcer.²⁶

HPV and anal cancer The anal canal and cervix are similar in histology in that each case has a squamous-columnar transition zone and has led to the suggestion that anal HPV may progress through grades of dysplasia to invasive cancer and is the basis for screening and treatment strategies aimed at identifying these premalignant changes.^{23,28} Anal Pap smears are one screening test that has been suggested for homosexual men, especially those that are HIV-positive.¹⁸ Squamous cell carcinoma may be mistaken for a small benign ulcer and so biopsy is mandatory.²⁷ The annual incidence of anal cancer in the USA is estimated at about 4000. The incidence in HIV-negative homosexuals is roughly 35 times that rate and further doubled in HIV-positive males.²⁷ It appears that in the HAART era this rate has not been decreased.²⁴ Even so, it is a rare condition perhaps because the rate of progression is slower than the natural history of the HIV disease. The pre-malignant anal carcinoma in situ lesion may be rapidly progressive in immunocompromised patients (transplant recipients and HIV patients), but as the rate of progression is slower than the natural history of HIV disease there is a need

for caution when considering treatment.⁴ Radiotherapy may be helpful for symptomatic cases. A less aggressive approach so as to prevent anal stenosis is to excise or biopsy/destroy only gross lesions and submit the remainder to close observation. Chemo-irradiation is the treatment of choice for most invasive anal cancers.²⁸ Salvage abdominoperineal resection (APR) can be useful if the CD4 count is >200, otherwise the perineal wound will not heal.^{4,29,30}

Traumatic anal fissures may also result from changes in bowel habit, colitis, proctitis or the trauma of ano-rectal intercourse. Anal ulcers can be iatrogenic occurring in the region of a previous lateral sphincterotomy initially performed for an ulcer which was mistaken for a fissure. Inappropriate anal instrumentation or 'fisting' injuries can result in the most horrendous sphincter injuries which usually require permanent faecal diversion. American proctologists see very massive and erosive ulcers, which actually erode their way through the anal canal. Setons are recommended for most fistulae.^{4,5}

5. Conclusions

Sexually transmitted diseases including HIV affecting the anorectum are common and increasing in frequency. A high index of suspicion and knowledge of the anorectal lesions is required for diagnosis and treatment. An appropriate sexual history is important in diagnosing these conditions. It appears that HAART has not decreased the incidence of anorectal pathology in HIV infected patients but may have decreased the progression and complications pre-and postoperatively. Operations for anorectal pathology still represent one of the most common indications for surgery in HIV-positive patients. The best predictor of perioperative morbidity and mortality is ASA/Korsakoff's performance scores that measure general health. Aggressive surgical intervention must be undertaken with caution in patients with AIDS. Symptomatic improvement of the underlying pathology may make delayed wound healing an acceptable complication in many instances. Education and sexual health promotion are necessary for the prevention of HIV and its anorectal disorders.

References

1. Barré-Sinoussi F, Chermann JC, Rey F, Nugeyre MT, Chamaret J, Gruest J, et al. Isolation T-lymphotropic retrovirus from a patient at risk of AIDS. *Science* 1983;**220**:867–70.
2. Jayasarhya A, Robertson C, Allan PS. Twenty five years of HIV management. *J R Soc Med* 2007;**100**:363–6.
3. Miles AJG, Wastell C. AIDS and the general surgeon. *Recent advances in Surg* 1991;**14**:85–98.
4. Beck DE, Wexner SD. AIDS and the Colorectal Surgeon. Part II: anorectal diseases. *Postgrad Adv Colorectal Surg* 1990;**0**:1–13.
5. Voeller B. AIDS and heterosexual anal intercourse. *Arch Sex Behav* 1991;**20**:233–76.
6. Gonzalez Ruth C, Heartfield W, Briggs B, et al. Anorectal Pathology in HIV/AIDS infected patients has not been impacted by highly active anti retroviral therapy. *Dis Colon Rectum* 2004;**47**:1483–6.
7. CDC, Centre for Disease Control. Morbidity and Mortality weekly report. 1993 revised classification system for HIV infection and expanded surveillance case definition for AIDS among adolescents and adults. *MMWR* 1992;**48**(RR-A):1–19.
8. Samuel Smit. Guidelines for surgery in the HIV patients. *Continous Medical Education (CME)* 2010; 28(8).

9. Weledji EP, Kamga HLF, Assob JL, Nsagha DS. A critical review on HIV/AIDS and wound care. *Afr J Clin Exp Microbiol* 2012;**3**(2):66–73.
10. Morandi E, Merlini D, Savaggio A. Prospective study of healing time haemorrhoidectomy. *Dis Colon Rectum* 1999;**42**(11):40–4.
11. Kazatchkie M, Dybul M, Lob-Leryt J. AIDS: lessons learned and myths dispelled. *The Lancet* 2005;**374**(9685):260–3, 18/7/2005.
12. Moore BA, Fleshner PR. Rubber band ligation for haemorrhoidal disease can be safely performed in selected HIV-positive patients. *Dis Colon Rectum* 2001;**2001**(44):1079–82.
13. Hewitt WR, Sokol JP, Fleshner PR. Should HIV status alter indications for Haemorrhoidectomy? *Dis Colon Rectum* 1996;**39**:615–8.
14. Brar HS, Goblesman L, Surawicz C. Anorectal pathology in AIDS. *Gastrointest Endosc Clin N Am* 1998;**8**:913–31.
15. Modesto VI, Goblesman L. Surgical debridement and intralesional steroid injection in the treatment of idiopathic AIDS-related anal ulceration. *Am J Surg* 1997;**174**:439–41.
16. Whitley RJ, Jacobson MA, Freidberg DN, et al. Guidelines for the treatment of cytomegalovirus diseases in patients with AIDS in the era of potent antiretroviral therapy: recommendations of an international panel. *Arch Intern Med* 1998;**158**:957–69.
17. Nelson CM, Harris RB, Dunne FF, et al. Risk factors for anogenital human papilloma virus infection in men. *J infect Dis* 2007;**196**:1137–45.
18. Scholfield JH, Northover JMA, Carr ND. Male homosexuality, HIV infection and Colorectal surgery. *Br J Surg* 1990;**71**:493–6.
19. Von Krogh G, Longstaff E. Podophyllin office therapy against condyloma should be abandoned. *Sex Transm Infect* 2001;**77**:409–12.
20. Maitland JE, Maw R. An audit of patients who have received imiquimod cream 5% for the treatment of anogenital warts. *Int J STD AIDS* 2009;**11**:268–70.
21. Hernandez BY, MacDuffe K, Zhux. Anal human papilloma virus infection in women and its relationship with cervical cancer. *Cancer Epidemic Biomarker Prev* 2005;**14**:2550–6.
22. Palefsky J. Human papillomavirus in HIV-infected persons. *Top HIV Med* 2007;**15**:130–3.
23. Scholefield J, Hickson W, Smith J. Intraepithelial neoplasia: part of a multifocal disease process. *Lancet* 1992;**340**:121–3.
24. Palefsky JM, Holly EA, Efirde JT, et al. Anal intraepithelial neoplasia in the highly active antiretroviral therapy era among HIV-positive men who have sex with men. *AIDS* 2005;**19**:1407–14.
25. Kaplan LD. AIDS-associated lymphomas. *Infect Dis Clin N Am* 1988;**2**(2):525–32.
26. Lorenz HP, Wilson W, Leigh B, Scheater WP. Kaposi's sarcoma of the rectum in patients with the acquired immunodeficiency syndrome. *Am J Surg* 1990;**160**:681–3.
27. Daling J, Weiss N, Hulop T. Sexual practices, sexually transmitted diseases and the incidence of anal cancer. *N Eng J Med* 1987;**317**:973–7.
28. Nigro N, Vaitkevicius V, Considine Jr B. Combined therapy for cancer of the anal canal. A preliminary report. *Dis Colon Rectum* 2009;**27**:354–6.
29. Albaran RG, Webber J, Staffes C. CD4 Cell counts as a prognostic factor of major abdominal surgery in patients infected with the Human immunodeficiency virus. *Arch Surg* 1988;**113**:626–63.
30. Horberg AM, Hurley LB, Klein DB, et al. Surgical outcomes in HIV-infected patients in the era of highly active antiretroviral therapy. *Arch Surg* 2006;**141**:1238–45.