



Foam treatment for varicose veins; efficacy and safety

Mamdouh Mohamed Kotb, Hosny Kotb Shakiban & Ahmed Fathi Sawaby

To cite this article: Mamdouh Mohamed Kotb, Hosny Kotb Shakiban & Ahmed Fathi Sawaby (2013) Foam treatment for varicose veins; efficacy and safety, Alexandria Journal of Medicine, 49:3, 249-253, DOI: [10.1016/j.ajme.2012.11.003](https://doi.org/10.1016/j.ajme.2012.11.003)

To link to this article: <https://doi.org/10.1016/j.ajme.2012.11.003>



© 2013 Alexandria University Faculty of Medicine. Production and hosting by Elsevier B.V. All rights reserved



Published online: 17 May 2019.



Submit your article to this journal [↗](#)



Article views: 75



View related articles [↗](#)



Citing articles: 1 View citing articles [↗](#)



ORIGINAL ARTICLE

Foam treatment for varicose veins; efficacy and safety

Mamdouh Mohamed Kotb, Hosny Kotb Shakiban, Ahmed Fathi Sawaby *

Vascular Surgery Department, Alexandria Faculty of Medicine, Alexandria University, Alexandria, Egypt

Received 23 August 2012; accepted 23 November 2012

Available online 8 April 2013

KEYWORDS

Varicose veins;
Foam sclerotherapy;
Duplex ultrasound imaging;
Treatment outcome;
Complications

Abstract Introduction: Lower extremity varicose vein is a common disease. Sclerotherapy can be used to treat truncal varices of the superficial venous system. This involves injecting a sclerosant intraluminally in order to cause fibrosis and eventual obliteration of the vein.

Objective: To demonstrate the efficacy and safety of foam sclerotherapy in the treatment of great saphenous reflux measured against patient clinical examination and duplex scanning.

Materials and methods: Fifty legs with varicose veins due to incompetent great saphenous vein were treated with ultrasound guided sclerosing foam prepared according to the Tessari method by mixing 3% polidocanol solution (Aethoxysclerol) with air using 2 disposable syringes and a three way tap producing high-quality micro-foam. Clinical examination and duplex scanning before and after the treatment with a mean follow up of 6 months were done to every patient.

Results: An average of 10 ml of foam was required to close incompetent Great saphenous veins as defined by a reflux of more than 0.5 s documented by duplex scan. At the 6th month of follow up, patients felt that their legs were treated successfully with resolution of symptoms and complete resolution in 96%.

Conclusion: Foam sclerotherapy is a safe and effective therapy in treating varicose veins with high patient satisfaction and improvement in quality of life.

© 2012 Production and hosting by Elsevier B.V. on behalf of Alexandria University Faculty of Medicine.

1. Introduction

The definition of sclerosing foam (SF) is a mixture of gas and liquid sclerosing solution (detergent type). The gas must be

* Corresponding author. Present address: Vascular Surgery Department, Faculty of Medicine, Alexandria University, Egypt.

E-mail addresses: Dr_mamdouhkotb@yahoo.com (M.M. Kotb), hosnykotb@yahoo.com (H.K. Shakiban), Ahmad791977@hotmail.com (A.F. Sawaby).

Peer review under responsibility of Alexandria University Faculty of Medicine.

well tolerated or physiologic and the bubble size less than 100. The behavior of sclerosing foam is different when injected compared to the action of a liquid solution.¹

The use of air and a sclerosing drug in combination was described in 1944 by Orbach²: the air-block technique. The sclerosing solution was added to air, by simply shaking the syringe or the vial to produce large bubbles which had a high air: liquid ratio and with increased efficacy only for smaller veins, this method is not suitable for larger veins such as saphenous trunks or larger tributaries because after injection of foam, the air positioned itself along the upper side of the vein, impending contact with the endothelium.

Further advancement came then from subsequent innovation: Cabrera et al.^{3,4} published an article about the production of a complex foam with CO₂. Monfreux⁵ described the



Production and hosting by Elsevier

MUS method that generated a simple foam with air by means of a glass syringe. Mingo-Garcia⁶ developed a special device to produce foam with compressed air, and Tessari⁷ presented an original method of foam formation with two disposable syringes and a three way-tap. Frullini⁸ published a different method to produce foam in a vial of sclerosing solution, provided that the vial has a rubber cap, the method utilizes the turbulence effect that a disposable syringe and a relatively large connector can create into the vial with a fast push on the piston.

2. Materials and methods

Fifty randomly selected legs of 50 patients suffering from varicosities of the great saphenous vein reflux were enrolled in this study.

All patients were examined clinically and by duplex scanning to assess both superficial and deep venous systems. The exclusion criteria were: Pregnancy, breast feeding, DVT, known allergy to polidocanol solution (Aethoxysclerol) and lack of mobility. Inclusion criteria for the study were truncal incompetence in the great saphenous veins as defined by a reflux of more than 0.5 s documented by duplex scan.

A Tessari micro-foam technique was done using Aethoxysclerol 3% in a ratio of 1 ml sclerosing solution to 4 ml air Fig. 1.

The foam was generated according to Tessari by using two disposable syringes and a three-way tap. Up to 10 ml the foam was produced from 2 ml of Aethoxysclerol 3% and 7.5 ml of air with 20 passages through the tap. Patients are treated at the operating room which is equipped with a color duplex ultrasound and an adjustable examination board, which can be tilted to 45°. Firstly, the sapheno-femoral disconnection is done by local infiltration. Then, the patient is placed in a tilted position to facilitate puncture of the GSV. The planned puncture site of the GSV is normally 3–5 cm below the knee. The vein is punctured under ultrasound guidance with an 18G standard vascular access needle. A standard guide wire is inserted into the GSV using the standard Seldinger technique.

A 5Fr. introducer sheath is advanced over the guide wire. The dilator and guide wire are removed. The patient is tipped back to a horizontal position and the leg is elevated by 30°. We placed the introducer tip 2 cm distally to the sapheno-femoral

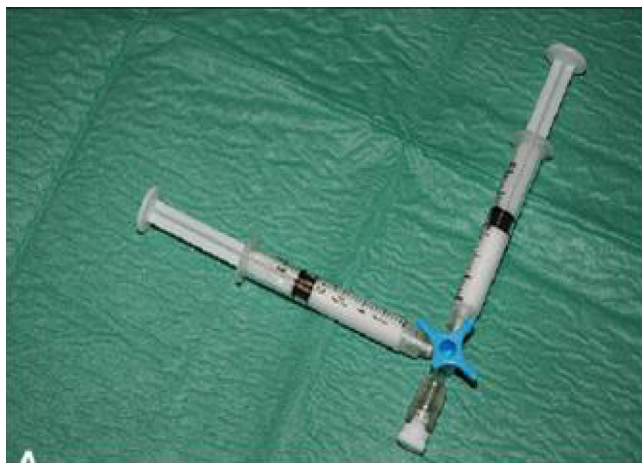

Figure 1 A Tessari micro-foam technique using two disposable syringes and a three way tap.

junction. This catheterization procedure aimed to induce a significant vasospasm in the vein in order to reduce the blood volume present in the vessel and thereby increase concentration and vessel-wall contact of the sclerosing agent.

Sclerosant foam is now prepared and injected in the catheter. When the foam has reached the introducer-tip the sheath is slowly withdrawn with one hand, while injecting 5–10 ml of sclerosing foam depending on the length of the treated vein segment. After application of a sterile dressing at the puncture site, compression stockings are applied up to the thigh. The patient was then instantly mobilized and asked to walk for five minutes.

All legs are placed in (class 2) 30–40 mmHg graduated elastic stocking for 2 weeks (1 week all the time and 1 week during the day only).

Every patient is advised to:

- [1] Avoid straining, strenuous physical activity or Valsalva maneuver for the first month because they may contribute to early recanalization.
- [2] Avoid prolonged car or plane travel of more than 4 h during the first month after treatment to decrease the incidence of the thromboembolic events.

All patients were reviewed for occurrence of complication: the complications were classified as systemic (drug reaction-transient confusion status and visual disturbance) and local (DVT, phlebitis, skin pigmentation, skin necrosis). Follow-up was provided for every patient: every patient was reviewed at 1 week, 1 month, 3 months and 6 months by duplex and clinical examinations as well as patient satisfaction.

3. Results

3.1. Safety

In 50 patients with GSV reflux, 50 limbs were studied (Table 1). Subjects' age ranged from 25 to 41 years with a mean of 33 years. Fifty-six percent were women and 44% were men.

Compared with the classic liquid sclerotherapy, foam sclerotherapy is more likely to induce post-inflammatory hyperpigmentation but less likely to induce skin necrosis because it has a much higher sclerosing power at a 3- to 4-fold dilution. A few weeks following therapy, patients may experience a string-like induration of the injected vein due to venous obliteration.

Adverse outcomes were infrequent with no serious complications reported. Any erythema was meticulously reported as superficial thrombophlebitis (STP) (2%) Fig. 2. Other adverse effects reported or observed included pain along the course of the great saphenous vein (6%), staining and hyperpigmentation (36%) reflecting the aggressive treatment approach to complete the closure of all branch varicosities and any demonstrated venous channels Fig. 3. There was no documented incidence of anaphylaxis, stroke, sepsis, arterial injection, and nerve damage. Because of ligation of SFJ, the sclerosing foam does not enter the systemic circulation after administration, and neither deep vein thromboses (DVTs) nor emboli have been reported.

3.2. Efficacy

An average total volume of 7.3 mL foam (equivalent to 1.7 mL of 3% polidocanol solution) was injected to achieve venous

Table 1 Anatomical CEAP classification of cases studied ($n = 50$).

C0	No visible or palpable signs of venous insufficiency	0%
C1	Telangiectasia and/ or reticular varicosities	6%
C2	Varicose veins (VVs)	90%
C3	VVs with leg edema, or corona phlebectatica	0%
C4	Venous eczema, pigmentation, lipodermatosclerosis, atrophie blanche	0%
C5	Healed varicose ulcers	4%
C6	Active venous ulceration	0%

CEAP, clinical, etiological, anatomical and pathological elements.

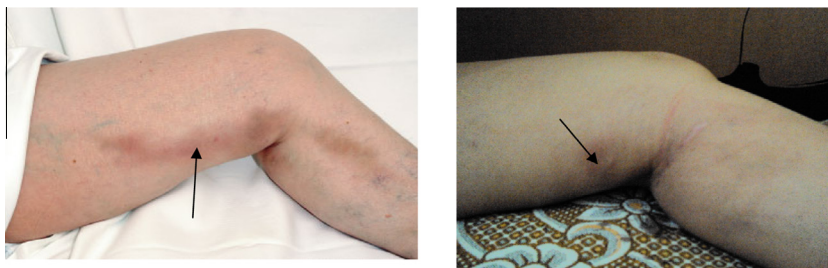


Figure 2 Two cases of STP 1 month after treatment of incompetent great saphenous vein with 10 ml of 3% polidocanol foam.

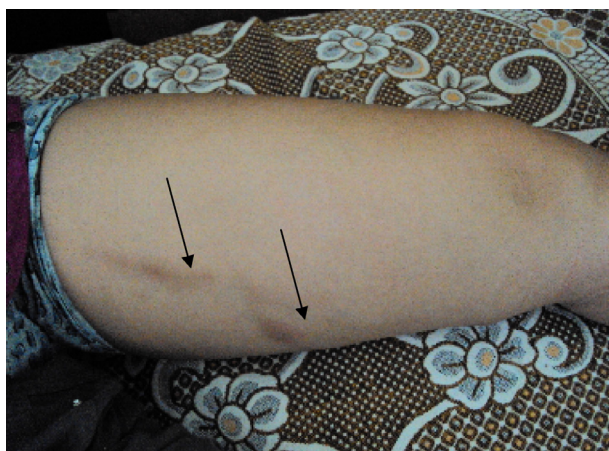

Figure 3 Staining and hyper pigmentation after foam sclerotherapy.

closure in the first 6 months **Figs. 4 and 5**. In the first 3 months, 18% required additional UGFS treatment, and 6% between 3 and 6 months (**Table 2**). Symptoms (92%) such as aching limb pain and cramps resolved on the first month of treatment.

4. Discussion

4.1. Safety

In the 50 legs treated with sclerosing foam we had no serious complications (in particular, no pulmonary embolism, no DVT or nerve injury). Phlebitis which was a sequela of excessive inflammatory reaction of the sclerosing foam had-occurred in 2% of legs (two different patients), while Frullini and Cavezzi⁹ and Rabee et al.¹⁰ reported only 1% of phlebitis.

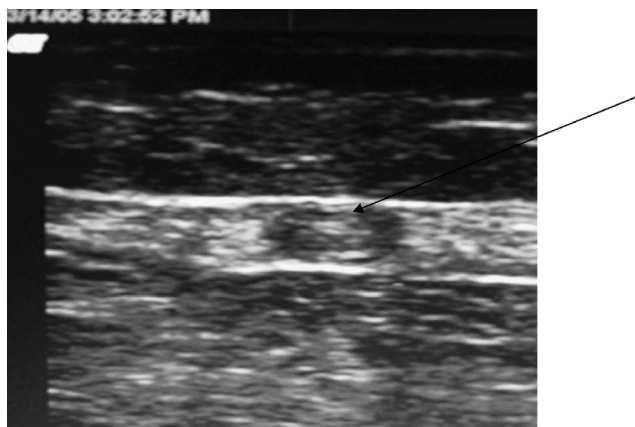


Figure 4 Closed great saphenous vein one week after treatment.

No skin necrosis, sclerosant induced ulcer, wound infection or nerve injury was reported.

This study demonstrated a high patient satisfaction with improvement of the quality of life and a high rate of closure of the saphenous trunks and visible varicosities with foam therapy.

Results achieved in this study were comparable with other studies.^{11–14} But in the VEDICO trial comparing the treatment of varicose veins using several techniques including sclerotherapy, surgery and foam sclerotherapy, the study demonstrated the elimination of reflux in all patients with 10 year follow up.¹⁵

The incidence of passage of the foam to the deep system is eliminated by ligation of the saphenofemoral junction. In January and November 2004, a study conducted by Barrett et al.¹⁶ showed similar results to our study. They used the same technique to obtain high success with low incidence of complication.

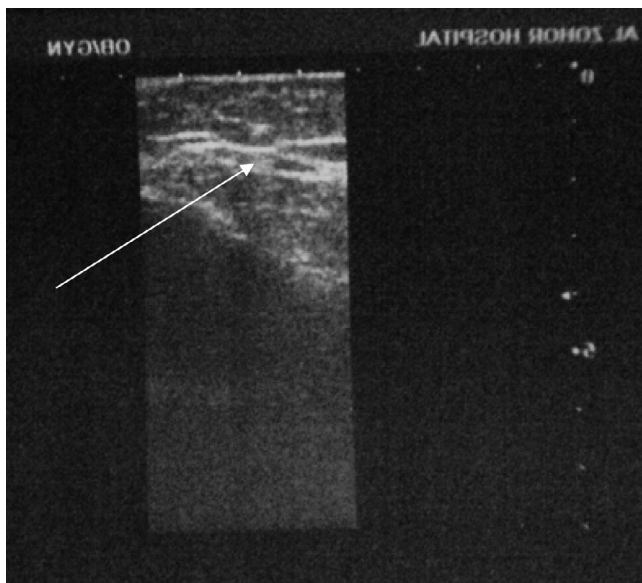


Figure 5 Fibrotic great saphenous vein six months after treatment.

Table 2 Duplex follow-up data after 6 months.

Location	Success/occluded	Partial success/occluded	No success/recanalized
GSV ($n = 50$)	47 (94%)	1 (2%)	2 (4%)

Table 3 Subgroup SFJ diameters over time ($n = 50$).

	Initial diameter (mm)	Month 1	Month 3	Month 6
CEAP 1 (6%)	4.6	3.3	2.9	1.5
CEAP2 (90%)	5.0	4.1	2.6	1.6
CEAP 5 (4%)	3	2.6	2.0	1.2

SFJ, saphenofemoral junction; CEAP, clinical, etiological, anatomical and pathological elements.

4.2. Efficacy

Compared with classic liquid sclerotherapy, foam sclerotherapy was about four times more effective because of increased contact time with the venous wall, increased surface area of the venous wall, and venous spasm.¹ After one UGFS session, more than two thirds of the truncal varicosities were occluded and more than 90% of treatments were successful after two or three sessions.¹⁷ Several large case series and one multicenter study have been published. UGFS in 1411 limbs showed occlusion in 88% of GSVs after a mean follow-up of 11 months.^{17–19} Few studies showed 69% complete sclerosis in 99 limbs after 24 months of follow-up,¹² 44% occlusion in 211 limbs after 5 years of follow-up,¹³ and 88% occlusion in 143 limbs after 6 weeks of follow-up.¹⁴ A small prospective randomized trial suggested that SFJ ligation and one session of UGFS was less effective in the short term, but significantly less costly and time-consuming than stripping, and multiple avulsions.¹⁵

All sizes of GSVs over all CEAP classes were shown to be safely and effectively treated (Table 3). Patients enjoyed an immediate return to activity, avoiding the cost of time off work. The technique of UGFS was well accepted by all patients, who felt strongly that UGFS was effective in treating their varicose veins, would recommend it to a friend, and would have UGFS repeated in the future if required. A statistically significant reduction in the diameter of the GSV was demonstrated in all cases of GSV reflux.

Although most of the patients who needed further treatment were during the first 3 months of follow up, we believed that the 6 month follow up provides a sufficient time to assess the development of early recanalization.²⁰ Barrett et al.¹⁶ had reported that, a 3 month follow up was enough but others^{11,16} did not accept that because this period was too short for establishment of alternative venous pathway.

Surgery carries a risk of general anesthesia and the time of work off. Surgery is not more effective than foam sclero-therapy for primary truncal saphenous vein treatment.¹⁸ So we believed that, it was difficult to justify a procedure that has increased patient morbidity and mortality and no increase in safety.

5. Conclusion

We believed that foam sclerotherapy is a safe and effective treatment for varicose veins without serious side effects. It can be used for varicosities due to saphenous trunk reflux. Patient safety is a prime indication for foam therapy (no general anesthesia and low risk of DVT). Foam has added the benefit of high patient satisfaction, less hospital stay and early return to the daily work.

References

- Frullini Alessandro. Foam sclerotherapy a review. *Phlebo Lymphogr* 2003;**40**:125–9.
- Orbach EJ. Sclerotherapy of varicose veins: utilization of intravenous air block. *Am J Surg* 1944;**36**:2–6.
- Cabrera Garrido JR, Garciaolmedo Cabrera, Olmedo Garcia. *Sclerosants Phlebologie* 1997;**50**:181–8.
- Cabrera Cabrera, Garcia-Olmedo, Ominguez MA. Treatment of varicose vein with sclerosant in microfoam form: long term outcomes. *Phlebologie* 2000;**15**:19–23.
- Monfreux A. Traitement sclerosant des troncs sapheneis et leurs collaterales e gros caliber par la methode. *MUS Phlebologie* 1997;**50**:352–3.
- Mingo- Garacia J. Esclerosis venosa con espuma: foam medical system. *Rev Esp Med Ciruga Cosmetica* 1999;**50**:29–31.
- Tessari L. Nouvelle technique de obtention de la sclero- mousse. *Phlebologie* 2000;**53**:129.
- Frullini A. New technique in producing sclerosing foam in a disposable syringe. *Dermatol Surg* 2000;**26**:705–6.
- Frullini A, Cavezzi A. Sclerosing foam in the treatment of varicose veins and telangiectasia. *Dermatol Surg* 2002;**28**:11–5.
- Rabee E, Fisher Pannier, Gerlach, et al. Guidelines for sclerotherapy of varicose veins. *Dermatol Surg* 2004;**30**:687–93.
- Barrett LM, Frazegp, Allen Bruce, et al. Guidelines of sclerotherapy. *Dermatol Surg* November 2004;**82**:1291–301.
- Rybak Z. Foam obliteration of insufficient perforating veins in patients suffering from leg ulcers. *Phlebology* 2003;**42**:20.
- Wright D. Safety of intra venous foamed sclerosants. *Phlebology* 2006;**44**:155–9.
- Hamel- Desnos, Philippe D, Jan CW, et al. Evaluation of the efficacy of Polidocanol in the form of foam compared with liquid

- form in sclerotherapy of the greater saphenous vein. *Dermatol Surg* 2003;**29**:1170–5.
15. Belcaro G, Cesatrone MR, Di Renzo A, et al. Foam-sclerotherapy surgery, sclerotherapy and combined for varicose: 10-year, prospective study, randomised, control, trial (VEDICO trial). *Angiology* 2003;**54**:307–15.
 16. Barrett LM, Frazcgp, Allen Bruce, et al. Microfoam ultrasound-guided sclerotherapy treatment for varicose veins in a subgroup with diameter of 10 mm or greater versus a subgroup of less than 10 mm. *Dermatol Surg* January 2004;**30**:1386–90.
 17. Benigni JP, Sadoun S, Thirion V, et al. Telangiectasies et varices reticularires. Traitement par la mousse d Aetoxisclerol a 0.25% presentation dune etude pilote. *Phlebologie* 1999;**52**:283–90.
 18. Geroulakos G. Foam therapy for those with varicose vein. *Dermatol Surg* 2005;**50**:89–94.
 19. Breu FX, Guggenbichler S. European consensus meeting on foam sclerotherapy. *Dermatol Surg* 2004;**30**:709–17.
 20. Teruya Thand Ballard JL. New approaches for the treatment of varicose veins. *Surg Clin N Am* 2004;**84**:1397–417.