



Periapical abscess of the maxillary teeth and its fistulizations: Multi-detector CT study

Sherif A. Shama

To cite this article: Sherif A. Shama (2013) Periapical abscess of the maxillary teeth and its fistulizations: Multi-detector CT study, Alexandria Journal of Medicine, 49:3, 273-279, DOI: [10.1016/j.ajme.2012.10.005](https://doi.org/10.1016/j.ajme.2012.10.005)

To link to this article: <https://doi.org/10.1016/j.ajme.2012.10.005>



© 2013 Alexandria University Faculty of Medicine. Production and hosting by Elsevier B.V. All rights reserved



Published online: 17 May 2019.



Submit your article to this journal [↗](#)



Article views: 275



View related articles [↗](#)



ORIGINAL ARTICLE

Periapical abscess of the maxillary teeth and its fistulizations: Multi-detector CT study[☆]

Sherif A. Shama *

Alexandria University, Department of Radio-Diagnosis, Faculty of Medicine, Azarita, Alexandria, Egypt

Received 31 August 2012; accepted 24 October 2012

Available online 14 December 2012

KEYWORDS

Periapical abscess;
MDCT;
Oro-antral fistula;
Oro-nasal fistula

Abstract *Aim:* The aim of this study was to assess the role of MDCT and the dedicated dental software in assessment of the periapical abscesses of the maxillary teeth and in detection of abnormal fistula as well as post intervention complications.

Materials and methods: This study was conducted on 20 patients with periapical abscess of the maxillary teeth. MDCT machines were used in examination of all patients. Workstation was used for manipulation of data. Dedicated dental software was used in the evaluation of all diseased teeth.

Results: Fourteen patients had their abscesses involving the maxillary molar and premolar teeth, six of them showed associated oro-antral fistula (42.8%). Four patients had their abscesses surrounding the apices of the incisors, two of them showed associated oro-nasal fistula (50%). None of the patients with periapical abscesses surrounding the roots of the canine teeth ($n = 2$) showed abnormal fistulization. Nine cases (45%) showed missing crowns and retained roots due to previous trials of extractions. Two cases (10%) of fracture of the maxillary alveolar process complicating trials of previous extraction were also encountered.

Conclusion: The MDCT with its outstanding image quality of the bony structures supported by its 3-D and VR capabilities can detect the periapical dental abscess in a 3-D fashion, accurately define its location, size and extent and is excellent in evaluation of possible fistula. As compared to panorama X-ray, MDCT was more accurate in diagnosis of abnormal fistula and associated fracture of the alveolar process of the maxillary bone.

© 2012 Production and hosting by Elsevier B.V. on behalf of Alexandria University Faculty of Medicine.

* Tel.: +20 1282012330/+20 34838483; fax: +20 34838480.

E-mail address: sh_shama@yahoo.com.

[☆] *Presentation:* Poster presentation in scientific exhibit of 44th annual meeting of the American Society of Head and Neck radiology (ASHNR), Houston, TX, USA, October, 2010.

Peer review under responsibility of Alexandria University Faculty of Medicine.



Production and hosting by Elsevier

1. Introduction

Tooth decay is the most common chronic illness in the pediatric population, affecting 50% of children aged 9 years or less and 80% of those aged 17 years or less.¹ In addition, the emergency room often serves as a site of primary dental care for many pediatric patients.² Periodontal abscesses are a common manifestation of dental disease and are associated with multiple potentially life-threatening complications.

Odontogenic infection may spread in two ways. The first pathway is provided by the formation of dental caries, which

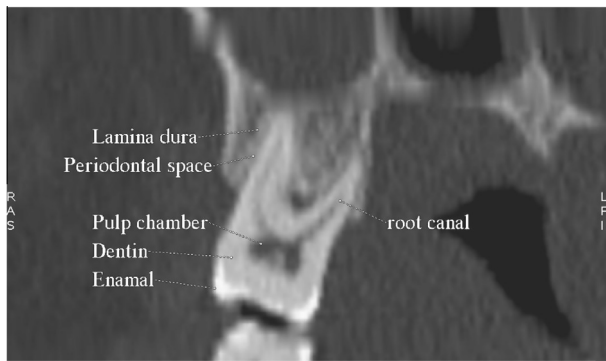


Figure 1 Normal CT anatomy of a maxillary molar tooth. Diseased maxillary sinus is seen.

allow bacteria to enter the tooth and spread to its apex (root), with resultant apical periodontitis, granuloma, abscess, and finally, radicular cyst formation. The second involves bacterial overgrowth and inflammation in the space between the tooth and the gum, which eventually lead to the destruction of the periodontal ligaments and erosion of the bone. A focal abscess also may form at the root of the tooth.³ Normal CT anatomy of a maxillary molar tooth is presented in Fig. 1.

The periapical abscess results from an infection of the pulpal tissue causing the pulp to become necrotic. It is formed when pus escapes from walls of the pulp chamber and the root canal(s) through the apical foramen. An area of pus and fluid accumulation forms in the bone surrounding the apex of the tooth. As the pressure builds up, the abscess may perforate into the oral cavity, the maxillary sinus or even the nasal cavity; extend into nearby bone, causing osteomyelitis; or, more often, spread to soft tissues, causing cellulitis and a swollen face.

Other complications of an odontogenic abscess include the spread of infection into the deep spaces of the neck and the orbit, airway compromise, internal jugular vein thrombosis, and intracranial extension of infection.⁴

Patients with odontogenic abscesses present with fever, tooth pain, facial swelling, dysphagia, trismus, and possibly dyspnea. Treatment includes antibiotics with possible abscess drainage and definitive management (root canal or extraction) of the offending tooth.

The panorama X-ray remains the standard radiological technique in evaluation of these abscesses. It is a simple, cheap and familiar technique. The recent imaging technology now offers Cone-beam CT⁵ and Multi-detector CT (MDCT) for evaluation of these lesions. Both techniques offer multi-planar

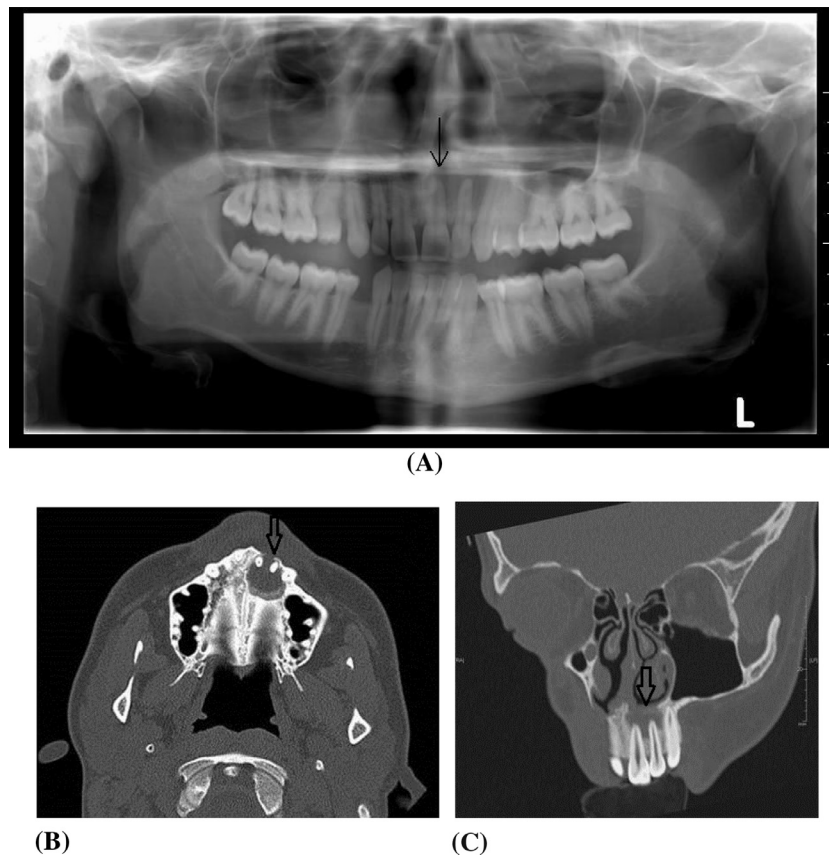


Figure 2 A case of periapical abscess surrounding the roots of the left maxillary medial and lateral incisors with focal bony destruction involving the left incisive bone (premaxilla) as well as the palatine process of the left maxilla resulting in oro-nasal fistula. The incisive canal is still intact. (A) Digital Panorama X-ray view: the lesion is hardly noted as faint lucency surrounding the diseased roots (arrow). (B and C) Axial and reconstructed coronal oblique MDCT images in bone windows. (D–J) The abscess and fistula are demonstrated in 3-D VR images using different angles and software. (I and J) Views from the nasal side of the fistula.

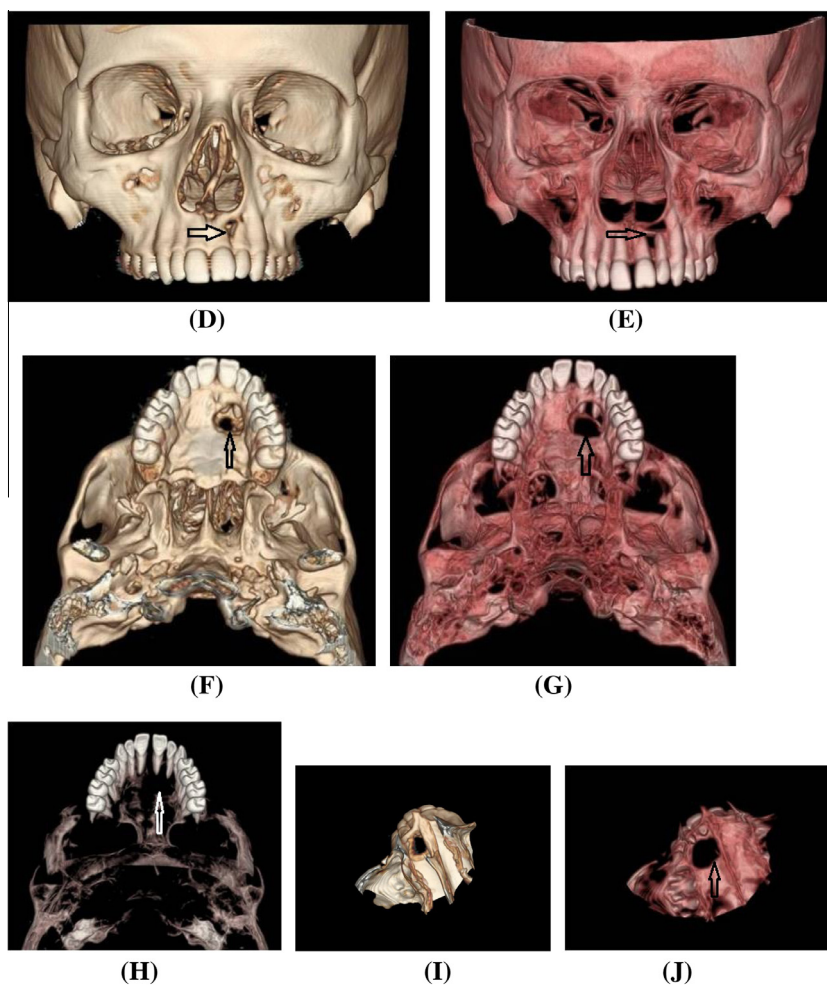


Figure 2 (continued)

reconstruction, in addition to the 2 and 3 dimension models. MDCT with its outstanding capabilities for evaluation of bony structures supported with recent dedicated dental software can now provide an accurate assessment of the periapical abscesses and possible associated complications.

The aim of this study was to assess the rule of MDCT and the dedicated dental software in assessment of the periapical abscesses of the maxillary teeth and in detection of the abnormal fistula as well as post intervention complications.

2. Materials and methods

This work was conducted on 20 patients including thirteen females and seven males. The patient's age ranged between 28 and 63 years. The mean age was 43.22 years. All of them were selected on the basis of the presence of periapical abscess involving one or more of the maxillary teeth that could be seen on the basis of MDCT.

An eight slice multi-detector CT machine (Bright speed S, GE, USA) was used in assessment of all patients. Before imaging, the patient was informed about the investigation and instructed not to move during scanning. The patients were in supine position. A lateral scout view was taken and used for planning the axial images. Axial images were taken without any angulations (Tilt 0). The protocol was 120 mA, 130 kV,

0.6 mm slice thickness and head field of view (FOV). The scanning covered all components of the maxillary bone.

All images were prospectively reconstructed at 0.6 mm with 0.4 mm overlap; using a soft tissue and high-resolution bone filter. The reconstructed axial images were transferred to Advantage 4.4 GE, USA workstation for manipulation of data. Multi-planar reformation (MPR), curved reconstruction of the maxillary teeth as well as average and maximum intensity projection (Average IP and Max. IP) was generated in different planes. Using the dedicated reconstructive dental software, volume rendering images (VR) of the maxillary bone and the teeth were generated (Figs. 2–4). Virtual endoscopy of the maxillary sinus was also obtained for selected cases (Fig. 3). All of the medical ethics were respected.

3. Results

Twenty patients with periapical abscess of the maxillary teeth were included in this study. Thirteen were females (65%) and seven were males (35%). The patient's age ranged between 28 and 63 years. The mean age was 43.22 years.

Four patients (20%) had periapical abscesses of the central and/or lateral incisors (Fig. 2). Two patients (10%) had their abscesses surrounding the root of the canine teeth. Fourteen

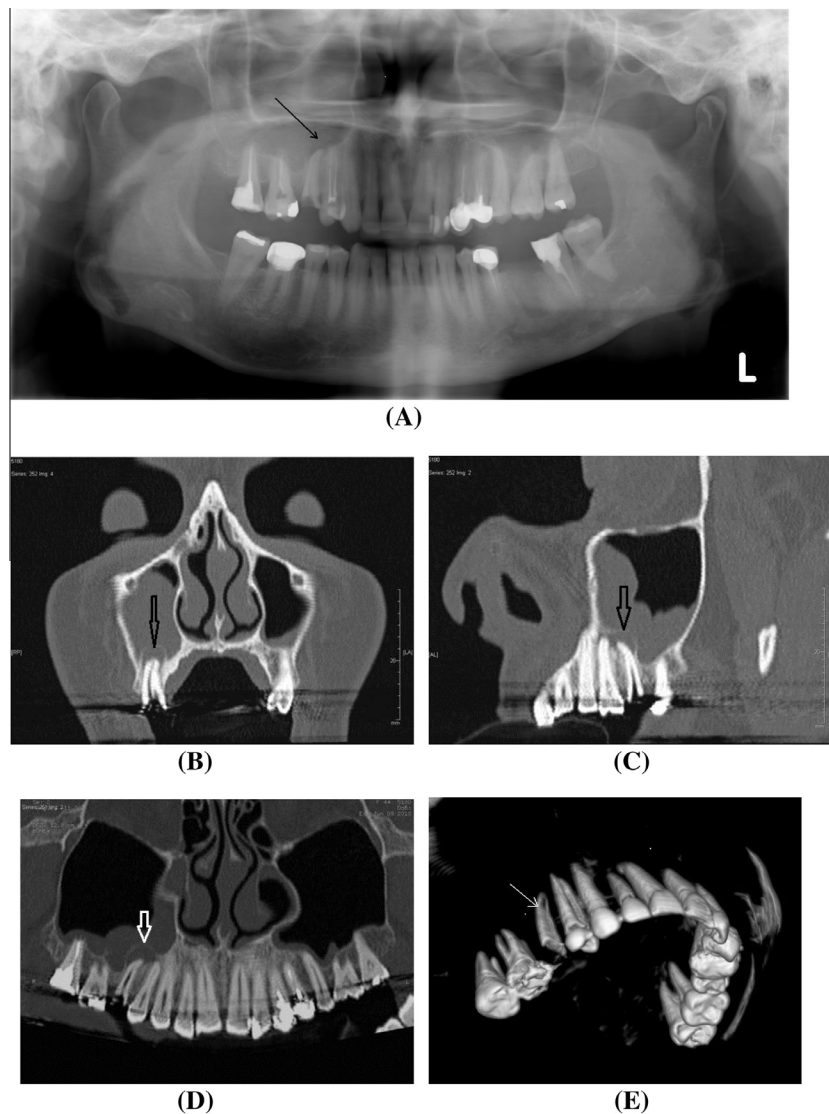


Figure 3 A case of broken right maxillary second premolar tooth with missing crown. Periapical abscess is seen surrounding the residual roots and showing fistulization into the maxillary antrum. (A) Digital Panorama X-ray view: the periapical abscess is adequately noted as lucency surrounding the diseased retained roots. This view failed to adequately demonstrate the bony destruction and the oro-nasal fistula. (B–D) Reconstructed MDCT images in bone windows. Coronal oblique, sagittal oblique and curved reconstruction respectively. (E and F) The retained roots are demonstrated in 3-D VR images using different angles and software. (G and H) The abscess and fistula are demonstrated in 3-D VR images using different angles. Views from inside maxillary antrum. In G the roof of the antrum was removed while the lateral wall was removed in H. (I) Virtual endoscopy, view from inside the antrum showing the abscess and fistula.

patients (70%) had their abscesses involving the maxillary molar and premolar teeth (Table 1).

Fourteen patients had their abscesses involving the maxillary molar and premolar teeth, six of them showed associated oro-antral fistula (42.8%). Four patients had their abscesses surrounding the apices of the incisors, two of them showed associated oro-nasal fistula (50%). None of the patients with periapical abscesses surrounding the roots of the canine teeth ($n = 2$) showed abnormal fistulization (Table 2).

Two cases of oro-nasal fistula were encountered. One patient showed oro-nasal fistula complicating periapical abscess surrounding the roots of the left maxillary medial and lateral incisors (Fig. 2). Another patient showed oro-nasal fistula complicating periapical abscess surrounding the root of the left maxillary lateral incisor.

Six cases of associated oro-antral fistula were detected. Four of them were complicating periapical abscesses of the premolar teeth and two were complicating the periapical abscesses of the molars (Figs. 3 and 4).

Periapical lucency could be seen in panorama X-ray in 17 out of the 20 patients (85%). This lucency could be detected in the remaining three cases only after confirmation of the presence of periapical abscess with MDCT. Panorama X-ray alone could suggest the presence of the fistula in less than half of the cases with fistulae (three out of eight cases, 37.5%). However, the confirmed radiological diagnosis of the fistula was done on MDCT basis in all cases (Table 3).

Nine cases (45%) showed missing crowns and retained roots due to previous trials of extractions (Figs. 3 and 4). Two cases (10%) of fracture of the maxillary alveolar process

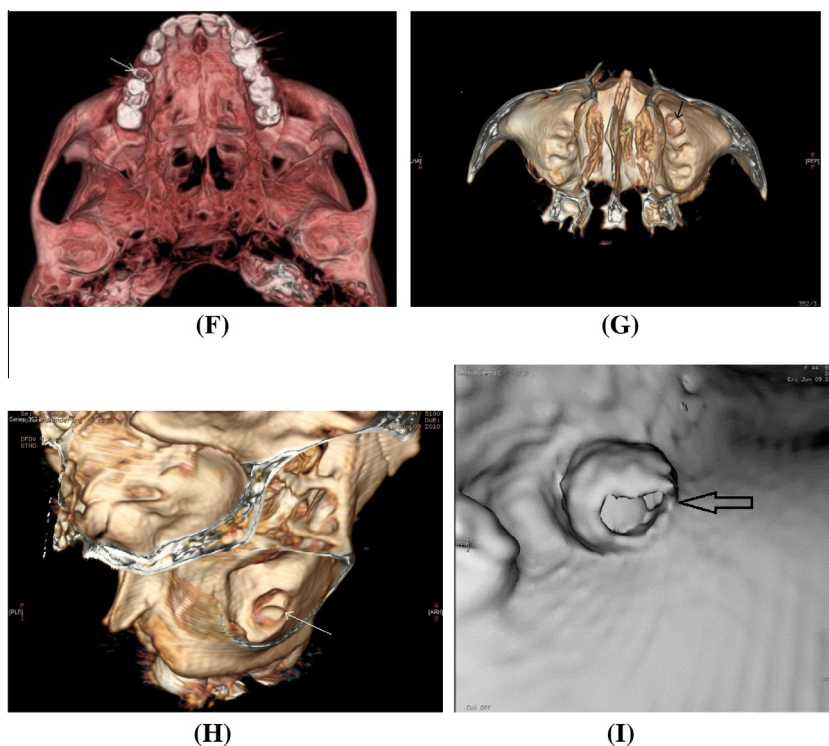


Figure 3 (continued)

complicating trials of previous extraction were also encountered (Table 4; Fig. 4). All missed crowns and retained roots were diagnosed with panorama X-ray. Fractures of the alveolar process were only diagnosed with MDCT.

4. Discussion

The alveolar process of the maxillary bone harboring the upper jaw teeth is anatomically located under the maxillary air sinuses posteriorly and the hard palate that forms the floor of the nasal cavity more anteriorly. So, abnormal fistulization could occur into the maxillary antrum (oro-antral fistula). However the periapical abscess of the diseased anterior maxillary teeth can result into oro-nasal fistula.

Dentists are used to use the panorama X-ray view to evaluate the periapical disease. The panorama X-ray stills are the gold standard radiological technique in evaluation of the teeth and their periapical abscesses. It is not expensive but maintains good sensitivity. Panorama X-ray was maintaining relative good sensitivity in diagnosing periapical abscess of the maxillary teeth (85% of cases). Only 37.5% of cases of fistula could be diagnosed with panorama X-ray. All the cases of missing crowns and retained roots were diagnosed with panorama X-ray. None of the fractures of the alveolar process of the maxillary bone were seen in panorama X-ray.

The cone beam CT (CBCT) is a small machine that is practical for use in a dental office. In a comparative study, more than a third of lesions detected with CBCT were missed with periapical radiography (PA) in the maxillary premolars and molars. The probability of detecting lesions with PA alone was limited to teeth with apices in close contact with the floor of the maxillary sinus and when bone thickness between lesion

and sinus (measured with CBCT) was 1 mm or less. Additional findings such as lesion expansion into the sinus, sinus membrane thickening, missed canals, and the presence of apico-marginal defects were also more frequently seen with CBT than PA.⁶

However, the CBCT is limited by their small field of view and relative limited resolution, 3-D and VR capabilities as compared to the multi-detector CT (MDCT). MDCT now offer itself as a non invasive tool not only for diagnosis of the periapical abscess but also for accurate detection of the extent of the infective process and possible fistula formation.

Many complications of previous interventions could be detected using MDCT high capabilities in the evaluation of bony structures in 3-D. Missing crowns and retained roots are the most common that were encountered in this study (45%). Tiny fractures of the maxillary alveolar process were encountered in 2 cases (10%).

The recent MDCT technology now offer newly developing era of 2 and 3 dimension reconstructive techniques as well as dedicated dental software that provide an excellent 3 dimension models of the teeth. They significantly help both radiologist and dentist in accurate detection of the periapical abscesses as well as evaluation of any complication such as fistulization or sequelae of previous interventions. In this study, as compared to panorama X-ray, MDCT was more accurate in the diagnosis of abnormal fistula and associated fracture of the alveolar process of the maxillary bone as complication of previous trial of extraction.

Suspected odontogenic abscesses are best evaluated with CT, which demonstrates a periodontal lucency that extends into adjacent soft tissues through a focal cortical break or fistula, with an extra-osseous fluid collection.⁷

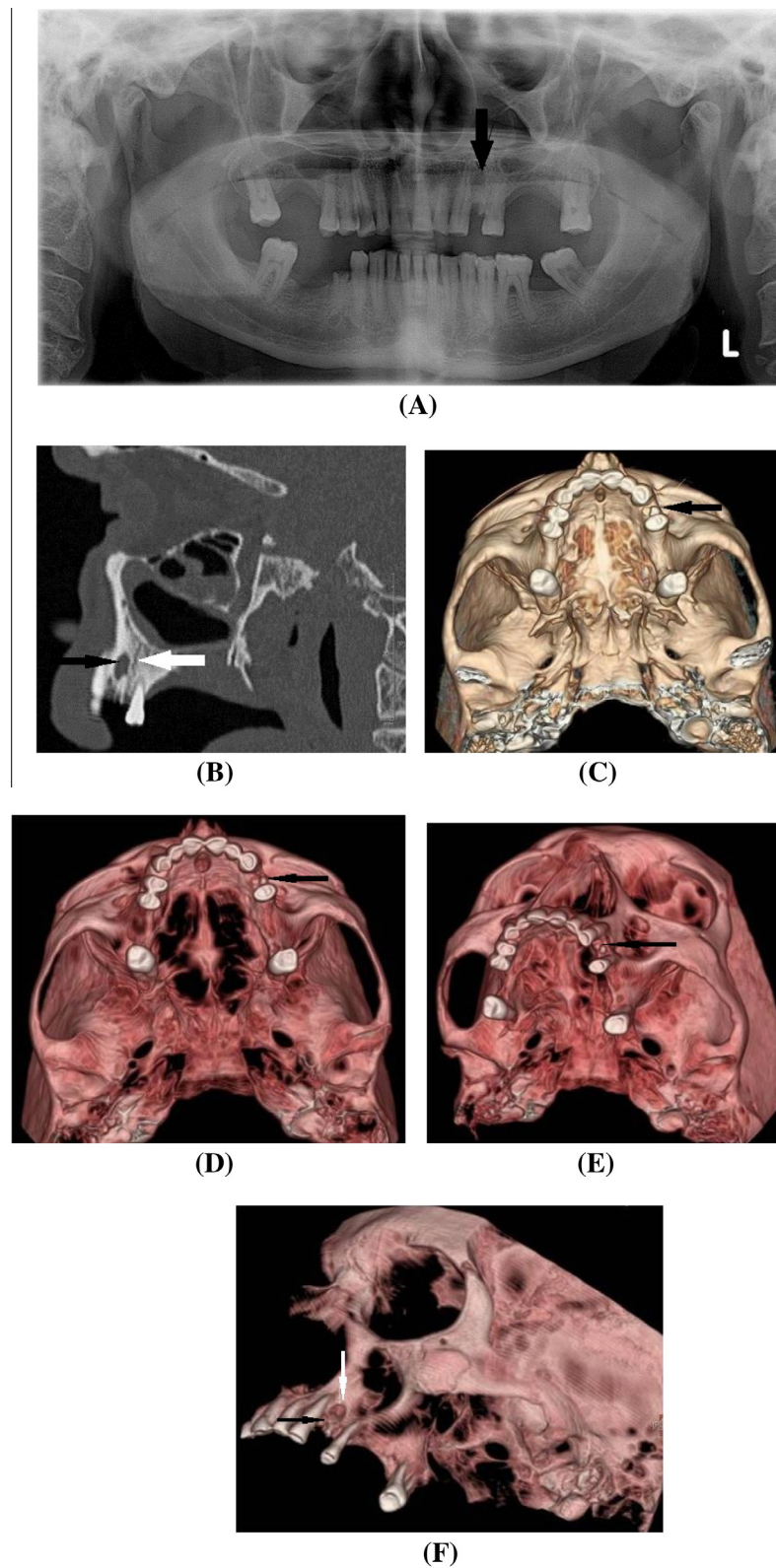


Figure 4 A case of periapical abscess surrounding the retained root of the left maxillary first premolar tooth. The tooth is broken and the crown is lost. Fissure fracture is noted crossing the alveolar process of the maxilla just posterior (distal) to the abscess, the fracture line did not violate to the bony plate forming the floor of the maxillary antrum. No oro-antral fistula is noted. (A) Digital Panorama X-ray view: the periapical abscess is adequately noted. This view failed to adequately demonstrate the fracture. (B) Reconstructed sagittal oblique MDCT image in bone window, showing the periapical abscess (black arrow) and fracture line (white arrow). (C–F) The retained roots (black arrows) and the abscess (white arrow) are demonstrated in 3-D VR images using different angles and software.

Table 1 Distribution of the involved maxillary teeth showing periapical abscesses.

Involved teeth	Number of patients	Percent (%)
Incisors	4	20
Canines	2	10
Molar and premolars	14	70
Total	20	100

Table 2 Distribution of the involved maxillary teeth showing periapical abscesses and abnormal fistula.

Involved teeth	Number of periapical abscesses	Number of associated fistula	Percent (%)
Incisors	4	2	50
Canines	2	0	0
Molar and premolars	14	6	42.8

Table 3 Numbers of periapical abscess of maxillary teeth and fistula as diagnosed with Panorama X-ray compared to MDCT.

	Panorama X-ray	MDCT	Percent (%)
Periapical abscess	17	20	85
Fistula	3	8	37.5

Table 4 Distribution of complications of previous trials of tooth extraction as diagnosed with panorama X-ray and MDCT.

Complications	Panorama X-ray	MDCT
Missing crowns and retained roots	9	9
Fracture of the maxillary alveolar process	0	2

In addition the unrecognized peri-apical abscess is a cause of failed endoscopic sinus surgery. Dentists are unable to recognize periapical abscesses reliably with dental X-rays and

exam. In patients with maxillary sinus disease, the teeth should be specifically examined as part of the radiological workup.⁸

5. Conclusion

The MDCT with its outstanding image quality of the bony structures supported by its 3-D and VR capabilities can detect the periapical dental abscess in a 3-D fashion, accurately define its location, size and extent and is excellent in the evaluation of possible fistula. As compared to panorama X-ray, MDCT was more accurate in the diagnosis of abnormal fistula and associated fracture of the alveolar process of the maxillary bone.

The abscesses around the apices of the maxillary pre-molar and molar teeth can result in oro-antral fistula. On the other hand periapical abscesses involving the anteriorly located teeth notably the incisors can result in oro-nasal fistulae.

References

1. Department of Health and Human Services. Guide to children's dental care in Medicaid. Available from <http://www.cms.hhs.gov/medicaiddentalcoverage/downloads/dentalguide.pdf>. Published October 2004. accessed February 26, 2010.
2. Ladrillo TE, Hobdell MH, Caviness AC. Increasing prevalence of emergency department visits for pediatric dental care, 1997–2001. *J Am Dent Assoc* 2006;**137**(3):379–85.
3. Ludwig BJ, Foster BR, Saito N, Nadgir RN, Castro-Aragon I, Sakai O. Diagnostic imaging in nontraumatic pediatric head and neck emergencies. *Radiographics* 2010;**30**(3):781–99.
4. Vieira F, Allen SM, Stocks RM, Thompson JW. Deep neck infection. *Otolaryngol Clin North Am* 2008;**41**(3):459–83.
5. Lofthag-Hansen S, Huuonen S, Gröndahl K, Gröndahl HG. Limited cone-beam CT and intraoral radiography for the diagnosis of periapical pathology. *Oral Surg Oral Med Oral Pathol Oral Radiol Endod* 2007;**103**(1):114–9.
6. Low KMT, Dula K, Bürgin W, Von Arx T. Comparison of periapical radiography and limited cone-beam tomography in posterior maxillary teeth. Referred for apical surgery. *J Endod* 2008;**34**:557–62.
7. Dunfee BL, Sakai O, Pistey R, Gohel A. Radiologic and pathologic characteristics of benign and malignant lesions of the mandible. *Radiographics* 2006;**26**(6):1751–68.
8. Longhini AB, Branstetter BF, Ferguson BJ. Unrecognized odontogenic maxillary sinusitis: a cause of endoscopic sinus surgery failure. *Am J Rhinol Allergy* 2010;**24**(4):296–300.