

Electronic Theses and Dissertations, 2004-2019

2016

Evaluation of Echogenicity Within and Between Ultrasonographic Images of the Vastus Lateralis

Alyssa Varanoske
University of Central Florida

 Part of the [Physiology Commons](#), and the [Sports Sciences Commons](#)
Find similar works at: <https://stars.library.ucf.edu/etd>
University of Central Florida Libraries <http://library.ucf.edu>

This Masters Thesis (Open Access) is brought to you for free and open access by STARS. It has been accepted for inclusion in Electronic Theses and Dissertations, 2004-2019 by an authorized administrator of STARS. For more information, please contact STARS@ucf.edu.

STARS Citation

Varanoske, Alyssa, "Evaluation of Echogenicity Within and Between Ultrasonographic Images of the Vastus Lateralis" (2016). *Electronic Theses and Dissertations, 2004-2019*. 4900.
<https://stars.library.ucf.edu/etd/4900>

EVALUATION OF ECHOGENICITY WITHIN AND BETWEEN
ULTRASONOGRAPHIC IMAGES OF THE VASTUS LATERALIS

by

ALYSSA N. VARANOSKE
B.S. University of Connecticut, 2014

A thesis submitted in partial fulfillment of the requirements
for the degree of Master of Science
in the Department of Educational and Human Sciences
in the College of Education and Human Performance
at the University of Central Florida
Orlando, Florida

Spring Term
2016

Major Professor: David H. Fukuda

© 2016 Alyssa N. Varanoske

ABSTRACT

PURPOSE: The purpose of this study was to examine the echo intensity (EI) values of different ultrasound (US) images of the vastus lateralis (VL) using panoramic imaging in the transverse plane (PTI) and still imaging in the longitudinal plane (SLI). Secondary purposes of this study were to examine VL homogeneity and to determine relationships between subcutaneous adipose tissue thickness (SubQ) adjacent to the muscle and EI. **METHODS:** Twenty-four recreationally-trained collegiate males (20.2 ± 1.6 years; height: 178.1 ± 6.6 cm; weight: 82.2 ± 13.4 kg) participated in this investigation. EI, cross-sectional area (CSA), muscle thickness (MT), and SubQ of the VL were assessed in the dominant limb (DOM) via three PTI and SLI. The best PTI was divided into three compartments of equal horizontal length (tertiles) to examine EI homogeneity. **RESULTS:** A repeated-measures ANOVA revealed a significant main effect for image/tertile between measures of EI ($p < 0.001$). The EI of PTI (57.976 ± 8.806 AU) was significantly lower than EI of SLI (65.453 ± 11.023 AU) ($p = 0.002$), however significant positive correlations existed between the two ($r = 0.681$; $p < 0.001$). Additionally, the EI of the SLI was significantly greater than the EI of the lateral tertile (58.717 ± 9.877 AU) ($p = 0.001$) and the EI of the posterior tertile (56.354 ± 9.887 AU) ($p = 0.002$). Although there was no significant difference between EI of the SLI and EI of the anterior tertile (59.065 ± 9.126 AU), a trend towards a significant difference was shown ($p = 0.051$). No significant differences in EI values between tertiles were identified. Significant differences in MT existed between PTI and SLI (PTI: 2.178 ± 0.367 cm; SLI: 2.015 ± 0.397 cm; $p = 0.003$), however MT values from PTI and SLI were significantly positively correlated with one another ($r = 0.809$, $p < 0.001$). Significant differences in SubQ existed between PTI and SLI (PTI: 0.217 ± 0.167 cm; SLI: 0.316

± 0.225 cm; $p < 0.001$), however SubQ values from PTI and SLI were significantly positively correlated with one another ($r = 0.915$, $p < 0.001$). No relationship between EI and SubQ from either image was found (PTI and SubQ: $r = -0.067$, $p = 0.754$; SLI and SubQ: $r = -0.114$, $p = 0.597$). SLI yielded slightly lower standard errors of measurement (SEM) and coefficients of variation (CV), indicating better precision compared to PTI. **CONCLUSIONS:** EI of the VL appears to be homogeneous as assessed in a PTI in recreationally-trained collegiate males. Additionally, PTI and SLI yield different EI, CSA, MT, and SubQ values, but these values are highly correlated. The use of SLI requires less time, equipment, and technical expertise, and therefore may be advantageous for use in future studies.

TABLE OF CONTENTS

LIST OF FIGURES	viii
LIST OF TABLES	xiii
LIST OF ACRONYMS/ABBREVIATIONS	xiv
CHAPTER ONE: INTRODUCTION.....	1
Purpose of the Study	5
Research Questions	6
Hypotheses	6
Delimitations	7
Limitations	7
Assumptions.....	8
Operational Definitions.....	9
CHAPTER TWO: REVIEW OF LITERATURE.....	10
The Use of Ultrasonography in Skeletal Muscle Assessment	10
Validity and Reliability of Ultrasonography in Assessment of Skeletal Muscle Morphology. 17	
Validity and Reliability of Ultrasonography Compared to Magnetic Resonance Imaging .. 17	
Validity and Reliability of Ultrasonography Compared to Computerized Tomography: 28	
Validity and Reliability of Ultrasonography in Assessment of Subcutaneous Adipose Tissue Thickness	33

Effects of Intramuscular and Subcutaneous Fat on Skeletal Muscle Echo Intensity.....	34
Skeletal Muscle Echogenicity May Be Related to Skeletal Muscle Quality	41
Echo Intensity and its Effects on Muscular Strength and Cardiovascular Performance	44
Skeletal Muscle Echo Intensity May be Related to Anaerobic Sports Performance	62
Inter- and Intra-muscular Adaptations to Resistance Exercise are Heterogeneous	70
Inter- and Intra-muscular Echo Intensity Values May Be Heterogeneous	87
Single Versus Panoramic Ultrasound Imaging Techniques in Skeletal Muscle Echo Intensity Quantification	94
CHAPTER THREE: RESEARCH DESIGN AND METHODOLOGY	98
Participants.....	98
Research Design.....	98
Variables	99
Instrumentation	99
Procedures.....	100
Ultrasonography.....	100
Image Analysis.....	102
Compartmentalization of the Vastus Lateralis.....	108
Data Analysis	110
CHAPTER FOUR: RESULTS	113
CHAPTER FIVE: DISCUSSION.....	117

Conclusions.....	136
APPENDIX A: FIGURES	137
APPENDIX B: TABLES	157
APPENDIX C: REQUIREMENTS FOR SELECTING THE BEST PANORAMIC IMAGE..	163
APPENDIX D: REQUIREMENTS FOR SELECTING THE BEST SINGLE STILL LONGITUDINAL IMAGE	165
APPENDIX E: INTERNATIONAL REVIEW BOARD (IRB) APPROVAL FORM	167
APPENDIX F: LETTER TO UNIVERSITY OF CENTRAL FLORIDA’S CLUB RUGBY COACH.....	169
APPENDIX G: DATA COLLECTION SHEET FOR ULTRASOUND PROCEDURE RELIABILITY	171
APPENDIX H: DATA COLLECTION SHEETS FOR ULTRASOUND PRECISION VALUES	173
APPENDIX I: BEST IMAGE SELECTION CHECKBOX.....	176
APPENDIX J: DATA COLLECTION SHEETS FOR VARIABLES OF BEST ULTRASOUND IMAGES	178
REFERENCES	181

LIST OF FIGURES

- Figure 1: A sample participant laying down for panoramic transverse image (PTI) analysis. PTI were taken at 50% of the straight-line distance from the greater trochanter and the lateral epicondyle of the femur. Image capture location was demarcated using a permanent marker on the surface of the skin. PTI were captured in the transverse plane, perpendicular to the force-generating axis of the muscle, using extended-field-of-view ultrasonography (LogiqView™). The yellow box represents the probe head orientation, and the solid yellow line represents the direction of probe manipulation along the leg during image capture. .. 138
- Figure 2: A sample participant laying down for single longitudinal image (SLI) analysis. Still images were taken at 50% of the straight-line distance from the greater trochanter and the lateral epicondyle of the femur. Image capture location was demarcated using a permanent marker on the surface of the skin. SLI were captured in the longitudinal plane, parallel to the force-generating axis of the muscle, using a still image. The yellow box represents the probe head orientation and image capture location. 139
- Figure 3: A sample panoramic transverse image (PTI) of the vastus lateralis (VL) used for cross-sectional area (CSA) analysis. The outline of the VL muscle was located in the image and traced using the polygon function tool in ImageJ, which included as much lean mass as possible without including any surrounding bone or fascia. The CSA value is highlighted in red and recorded in centimeters²..... 140
- Figure 4: A sample panoramic transverse image (PTI) of the vastus lateralis (VL) used for echo intensity (EI) analysis. The same region of interest used for cross-sectional area (CSA)

analysis is again used for EI analysis. The EI value is highlighted in red and recorded in arbitrary units. 141

Figure 5: A sample histogram plot generated in ImageJ for echo intensity (EI) determination.

This plot quantifies the grayscale of each individual pixel within the region of interest previously demarcated for cross-sectional area (CSA) and represents them as values from 0-255..... 142

Figure 6: A sample panoramic transverse image (PTI) with muscle thickness (MT) measurement

highlighted in blue. MT was quantified using the line tool at the midpoint of the horizontal distance between the anterior and posterior sides of the vastus lateralis (VL). MT is defined as the distance between the inferior border of the superficial aponeurosis and the superior border of the deep aponeurosis. The MT value is highlighted in red and recorded in centimeters. 143

Figure 7: A sample panoramic transverse image (PTI) with subcutaneous adipose tissue

thickness (SubQ) measurement highlighted in blue. SubQ was quantified using the line tool at the midpoint of the horizontal distance between the anterior and posterior sides of the vastus lateralis (VL). SubQ is defined as the distance between the inferior border of the epitelium and the superior border of the superficial aponeurosis. The SubQ value is highlighted in red and reported in centimeters..... 144

Figure 8: A sample single longitudinal image (SLI) of the vastus lateralis (VL) used for cross-

sectional area (CSA) analysis. The outline of the VL muscle was located in the image and traced using the polygon function tool in ImageJ, which included as much lean mass as possible without including any surrounding bone or fascia. The right and left sides of the traced polygon consisted of perfectly vertical lines, parallel to each other and parallel to the

edges of the image, whereas the superficial and deep lines of the ImageJ polygon corresponded to the muscle-aponeurosis interface. The CSA value is highlighted in red and reported in centimeters². 145

Figure 9: A sample single longitudinal image (SLI) with muscle thickness (MT) measurement highlighted in yellow. MT was quantified using the line tool at the midpoint of the horizontal distance between the left and right sides of the vastus lateralis (VL). MT is defined as the distance between the inferior border of the superficial aponeurosis and the superior border of the deep aponeurosis. The MT value is highlighted in red and reported in centimeters. 146

Figure 10: A sample single longitudinal image (SLI) with subcutaneous adipose tissue (SubQ) measurement highlighted in yellow. SubQ was quantified using the line tool at the midpoint of the horizontal distance between the left and right sides of vastus lateralis (VL). SubQ is defined as the distance between the inferior border of the epithelium and the superior border of the superficial aponeurosis. The SubQ value is highlighted in red and reported in centimeters. 147

Figure 11: A sample panoramic transverse image (PTI) divided into three tertiles of equal horizontal length. The anterior tertile (AT) denotes the compartment of the vastus lateralis (VL) that is situated in the anterior side of the body, the lateral tertile (LT) denotes the compartment of the VL that is situated on the lateral side of the body, and the posterior tertile (PT) denotes the compartment of the VL that is situated on the posterior side of the body..... 148

Figure 12: Cross-sectional area (CSA) values obtained from panoramic transverse images (PTI) and single still longitudinal images (SLI) with corresponding trendline and correlation coefficient. 149

Figure 13: Echo intensity (EI) and cross-sectional area (CSA) values obtained from panoramic transverse images (PTI) and still longitudinal images (SLI). Open circles represent measures obtained from PTI. Closed circles represent measures obtained from SLI. 150

Figure 14: Echo intensity (EI) values of panoramic transverse images (PTI), still longitudinal images (SLI), anterior tertiles (AT), lateral tertiles (LT), and posterior tertiles (PT). Open circles represent individual data points. Closed circles represent sample means, and 95% confidence intervals are denoted by error bars. 151

Figure 15: Echo intensity (EI) values obtained from still longitudinal images (SLI) compared to EI of panoramic transverse images (PTI), anterior tertiles (AT), lateral tertiles (LT), and posterior tertiles (PT). Open circles represent measures obtained from PTI. Open squares represent measures obtained from AT. Closed squares represent measures obtained from LT. Closed triangles represent measured obtained from PT..... 152

Figure 16: Muscle thickness (MT) values obtained from panoramic transverse images (PTI) and single still longitudinal images (SLI) with corresponding trendline and correlation coefficient. 153

Figure 17: Subcutaneous adipose tissue thickness (SubQ) values obtained from panoramic transverse images (PTI) and single still longitudinal images (SLI) with corresponding trendline and correlation coefficient. 154

Figure 18: Echo intensity (EI) and muscle thickness (MT) values obtained from panoramic transverse images (PTI) and still longitudinal images (SLI). Open circles represent measures obtained from PTI. Closed circles represent measures obtained from SLI. 155

Figure 19: Echo intensity (EI) and subcutaneous adipose tissue thickness (SubQ) values obtained from panoramic transverse images (PTI) and still longitudinal images (SLI). Open circles represent measures obtained from PTI. Closed circles represent measures obtained from SLI..... 156

LIST OF TABLES

Table 1: Participant characteristics (n = 24).	158
Table 2: Precision measurements between three consecutive panoramic transverse images (PTI) or still longitudinal images (SLI) for cross-sectional area (CSA), echo intensity (EI), muscle thickness (MT), and subcutaneous adipose tissue thickness (SubQ).....	159
Table 3: Echo intensity (EI; measured in AU), cross-sectional area (CSA; measured in cm ²), muscle thickness (MT; measured in cm), and subcutaneous adipose tissue thickness (SubQ; measured in cm) values of the selected panoramic transverse images (PTI), still longitudinal images (SLI), anterior (AT), lateral (LT), and posterior (PT) tertiles. Results are reported as mean ± standard deviation.	160
Table 4: Pearson product-moment correlation coefficients between echo intensity (EI) measures in panoramic transverse images (PTI), still longitudinal images (SLI), anterior (AT), lateral (LT), and posterior (PT) tertiles. P-values are reported below correlation coefficients in parentheses.....	161
Table 5: Pearson product-moment correlation coefficients between body mass index (BMI), muscle thickness (MT), cross-sectional area (CSA), and echo intensity (EI) values in panoramic transverse images (PTI) and still longitudinal images (SLI). Correlation coefficients reported with subcutaneous adipose tissue thickness (SubQ) were evaluated using Spearman's rho. P-values are reported below correlation coefficients in parentheses.	162

LIST OF ACRONYMS/ABBREVIATIONS

ANOVA	Analysis of Variance
AT	Anterior Tertile
AU	Arbitrary Units
BMI	Body Mass Index
Cm	Centimeters
CSA	Cross-Sectional Area
CSA _{AT}	Cross-Sectional Area of the Anterior Tertile
CSA _{LT}	Cross-Sectional Area of the Lateral Tertile
CSA _{PT}	Cross-Sectional Area of the Posterior Tertile
CSA _{PTI}	Cross-Sectional Area of a Panoramic Transverse Image
CSA _{SLI}	Cross-Sectional Area of a Single Longitudinal Image
CV	Coefficient of Variation
dB	Decibels
DOM	Dominant leg
EI	Echo Intensity
EI _{AT}	Echo Intensity of the Anterior Tertile

EI _{LT}	Echo Intensity of the Lateral Tertile
EI _{PT}	Echo Intensity of the Posterior Tertile
EI _{PTI}	Echo Intensity of a Panoramic Transverse Image
EI _{SLI}	Echo Intensity of a Single Longitudinal Image
ICC	Intra-Class Correlation
LT	Lateral Tertile
MD	Minimal Difference
MHz	Megahertz
MT	Muscle Thickness
MT _{PTI}	Muscle Thickness of a Panoramic Transverse Image
MT _{SLI}	Muscle Thickness of a Single Longitudinal Image
PTI	Panoramic Transverse Image
PT	Posterior Tertile
SLI	Still Longitudinal Image
SEM	Standard Error of Measurement
SubQ	Subcutaneous Adipose Tissue Thickness
SubQ _{PTI}	Subcutaneous Adipose Tissue Thickness in a Panoramic Transverse Image

SubQ _{SLI}	Subcutaneous Adipose Tissue Thickness in a Single Longitudinal Image
US	Ultrasound
VL	Vastus Lateralis

CHAPTER ONE: INTRODUCTION

Numerous studies have used ultrasonography as a way to assess skeletal muscle morphology (Caresio, Molinari, Emanuel, & Minetto, 2014; Fukumoto et al., 2012; Jajtner et al., 2014; Mangine et al., 2014a; Mangine et al., 2014b; Melvin et al., 2014; Scanlon et al., 2014; Wells et al., 2014; Young, Jenkins, Zhao, & McCully, 2015). The echogenicity (or echo intensity) of skeletal muscle obtained via ultrasonography can provide crucial information regarding muscle composition and possibly muscle quality (Mangine et al., 2014a; Mangine et al., 2014b; Pillen, 2010; Pillen and van Alfen, 2011; Scanlon et al., 2014; Wells et al., 2014). Echogenicity refers to the degree of reflectance of ultrasound waves off of a body tissue, where different body tissues possess different degrees of reflectivity (Pillen, 2010). Lower values of skeletal muscle echo intensity may be indicative of lower amounts of intramuscular fat and/or fibrous tissue which would be beneficial for many populations, including individuals who resistance train (Mangine et al., 2014a; Mangine et al., 2014b; Pillen et al., 2009; Scanlon et al., 2014; Strasser, Draskovits, Praschak, Quittan, & Graf, 2013; Watanabe et al., 2012; Wells et al., 2014; Wilhelm et al., 2014; Young, Jenkins, Zhao, & McCully, 2015). It has been demonstrated that with resistance training, echo intensity values within the muscle may decrease (Jajtner et al., 2014; Ivey et al., 2000; Scanlon et al., 2014). Additionally, significant negative correlations have been discovered between muscle echo intensity and strength and performance measures in various populations (Cadore et al., 2012; Fukumoto et al., 2012; Mangine et al., 2014a; Mangine et al., 2014b; Mangine et al., 2014c; Scanlon et al., 2014; Watanabe et al., 2013; Young, Jenkins, Zhao, & McCully, 2015). Previous research has shown that with training, inhomogeneous adaptations with regard to muscle size may occur within the same muscle (Ema, Wakahara,

Miyamoto, Kanehisa, & Kawakami, 2013; Seynnes, de Boer, & Narici, 2007; Wakahara et al., 2012; Wells et al., 2014). Further studies have shown that the echogenicity within individual skeletal muscles may lack homogeneity as well (Caresio, Molinari, Emanuel, & Minetto, 2014; Young, Jenkins, Zhao, & McCully, 2015). To the best of our knowledge, no existing research has examined the heterogeneity of echo intensity values within the vastus lateralis muscle or in a recreationally-trained population.

Ultrasound analysis of select muscles do not always permit the entire muscle to be viewed in a single still image, so panoramic imaging has been developed. Panoramic ultrasound imaging utilizes the overlapping of one image onto another as the probe is moved along the surface of the skin, to produce one comprehensive image (Ihnatsenka and Boezaart, 2010). Previous research has shown that panoramic imaging is a valid and reliable way to assess skeletal muscle morphology (Athiainen et al., 2010; Jajtner et al., 2014; Jajtner et al., 2015; Jenkins et al., 2015; Mangine et al., 2014a; Mangine et al., 2014b; Mangine et al., 2014c; Noorkoiv, Nosaka, & Blazevich, 2010; Scanlon et al., 2014; Scott et al., 2012; Wells et al., 2014). However, Noorkoiv and colleagues (2010) suggested that panoramic imaging may increase the likelihood of error due to the overlapping of one image onto another. Caresio and colleagues (2014) found that the region of interest affects reliability values of echo intensity obtained from a single still ultrasound image, where a larger region of interest generally results in a greater intra-class correlation coefficients between multiple measurements. These results offer the proposition that a panoramic image may result in a more accurate representation of muscle echogenicity if the entire muscle area cannot fit in a single still image. An investigation conducted by Jenkins et al. (2015) compared the echo intensities of single transverse ultrasound images of the biceps brachii to panoramic images of the same muscle. These researchers

discovered similar intra-class correlation coefficients, coefficients of variation, and minimal differences between the two different types of images. However, no previous research has investigated the heterogeneity of skeletal muscle echogenicity within an individual transverse panoramic image by breaking it up into anterior, lateral, and posterior compartments. Wells and colleagues (2014) discovered that resistance training can induce greater increases in vastus lateralis muscle thickness medially compared to laterally. Likewise, Ema et al. (2013) discovered significantly greater increases in the medial region of the vastus intermedius compared to the lateral region after resistance training. These inhomogeneous adaptations may affect echo intensity values of different areas within the muscle, however compartmental echo intensity was not examined in either study. Furthermore, Caresio et al. (2014) discovered significantly different echo intensity values in the rectus femoris muscle in a still ultrasound image at medial locations compared to lateral locations. Based on these results, one may expect to see different echo intensities among different compartments of a panoramic ultrasound image of the vastus lateralis.

Research up to this point has failed to examine the correlation between the echogenicity of single longitudinal images and transverse panoramic images of the same skeletal muscle. Most investigations have used only type of image to quantify muscle echo intensity, whether it be still images in the longitudinal or transverse plane or panoramic images in the transverse plane (Caresio, Molinari, Emanuel, & Minetto, 2014; Jajtner et al., 2014; Lixandrão et al., 2014; Mangine et al., 2014a; Mangine et al., 2014b; Mangine et al., 2014c; Melvin et al., 2014; Scanlon et al., 2014; Strasser, Draskovits, Praschak, Quittan, & Graf, 2013; Watanabe et al., 2012; Wells et al., 2014; Wilhelm et al., 2014; Young, Jenkins, Zhao, & McCully, 2015). Due to differences in fiber orientation and muscle architecture, an ultrasound image captured in the

longitudinal plane will produce an image that is vastly different from that captured in the transverse plane (Pillen, 2010). A longitudinal scan, taken parallel to the body of the muscle, will produce an image with visible striations due to fascia and connective tissue between individual muscle fibers. In contrast, a transverse scan will produce an image that is speckled in appearance due to the cross-sectioning of individual fascicles, connective tissue, and fascia (Pillen, 2010). It is likely that both types of images may produce different echo intensity values, however if both images are captured from the same area of the same muscle, one would expect correlation coefficients between the echogenicity of the two images types to be high.

Muscle echogenicity is thought to be related to muscle quality, where a muscle with lower echo intensity values may contain lower amounts of intramuscular fat (Pillen et al. 2009; Strasser et al. 2013; Watanabe et al. 2012; Wilhelm et al. 2014; Young et al. 2015). However, upon examination of subcutaneous adipose tissue and its potential effect on echo intensity, research has exhibited conflicting results. Some researchers have demonstrated that echo intensity values are positively correlated with subcutaneous adipose tissue thickness (Caresio, Molinari, Emanuel, & Minetto, 2014; Nijboer-Oosterveld, van Alfren, & Pillen, 2011; Watanabe et al., 2013; Young, Jenkins, Zhao, & McCully, 2015), whereas other research has found no correlation between echo intensity and subcutaneous adipose tissue thickness (Fukumoto et al., 2012; Melvin et al., 2014; Scholten, Pillen, Verrips, & Zwarts, 2003; Wu, Darras, & Rutkove, 2010). Melvin and colleagues (2014) were one of the few to investigate the relationship between subcutaneous adipose tissue thickness and echo intensity in a resistance-trained population. These researchers discovered no correlation between subcutaneous adipose tissue thickness and echo intensity in Division I football players. Perhaps the thickness of subcutaneous adipose tissue adjacent to the muscle does not have an effect on a trained population, whereas a thicker

layer of subcutaneous fat may actually infiltrate the muscle in an untrained population (Miljkovic and Zmuda, 2010). Further research is necessary to determine the effect of subcutaneous adipose tissue on echo intensity in a recreationally-trained population.

Therefore, this study aimed to examine the relationship between echo intensity values obtained from different image types and scanning planes within the same muscle, to examine the heterogeneity of echo intensity values within the same image, and to determine if the amount of subcutaneous adipose tissue is related to skeletal muscle echogenicity in a recreationally-trained population.

Purpose of the Study

The purpose of this study is to determine if there is a relationship between the echo intensity of a transverse panoramic ultrasound image and a longitudinal still ultrasound image of the vastus lateralis in the dominant leg of collegiate recreationally-trained males. The secondary purpose of this investigation is to determine if the echo intensity of the anterior, lateral, and posterior compartments of the vastus lateralis muscle in the dominant leg of collegiate recreationally-trained males is homogeneous as assessed in a transverse panoramic ultrasound image. Lastly, this study aims to determine if there is a relationship between subcutaneous adipose tissue thickness adjacent to the muscle and echo intensity of the vastus lateralis muscle in collegiate recreationally-trained males.

Research Questions

The research questions for this investigation were as follows:

1. Is there a relationship and/or a significant difference between the echo intensity of a panoramic ultrasound image captured in the transverse plane and a still ultrasound image captured in the longitudinal plane of the vastus lateralis?
2. Do the anterior, lateral, and posterior sub-compartments of the vastus lateralis muscle have the same echo intensity values?
3. Is there a relationship between the subcutaneous adipose tissue thickness adjacent to the muscle and echo intensity of the vastus lateralis?

Hypotheses

The hypotheses for this investigation were as follows:

1. There is a positive correlation but a significant difference between the echo intensity values of an ultrasonographic transverse panoramic image and an ultrasonographic longitudinal still image of the vastus lateralis.
2. The anterior, lateral, and posterior sub-compartments of the vastus lateralis muscle differ in echo intensity.
3. There is no correlation between the subcutaneous adipose tissue thickness adjacent to the muscle and echo intensity of the vastus lateralis.

Delimitations

1. Each participant was a member of the University of Central Florida's Rugby Club team.
2. Each participant was not affiliated with the University of Central Florida's Athletic Association.
3. Participants visited the Human Performance Laboratory at the University of Central Florida on one occasion.
4. Participants will lay supine on an examination table for ultrasound assessment of the vastus lateralis muscle of the dominant leg.

Limitations

1. Each participant was recruited from one collegiate club-level rugby team, and therefore may not be representative of all recreationally-trained collegiate males.
2. No requirement for resistance training experience or years playing rugby for participation was enforced so some subjects tested may have joined the team without prior rugby experience.
3. No age range criteria was enforced for participation, although all subjects were college-aged.
4. There was no inclusion criteria for body composition, so echo intensity values obtained from participants with larger amounts of fat mass may have inaccurately resulted in lower echo intensity values due to non-systematic reflection of ultrasound waves with

increasing amounts of adipose tissue (Nijboer-Oosterveld, van Alfen, & Pillen, 2011; Young, Jenkins, Zhao, & McCully, 2015).

5. Participants did not receive compensation for participation, which may have restricted incentive to participate.
6. No medical history clearance or questionnaire was completed by any participant. Subjects with musculoskeletal injuries currently or previously were not excluded from the study, which may have affected echo intensity values due to increased pathological or neurological fibrous tissue.
7. There was no distinction of player positions prior to testing. Different positions have different demands, which may affect muscle architecture and composition as well as fat mass in a non-homogeneous way.

Assumptions

1. Participants did not partake in vigorous exercise for at least 24 hours prior to testing.
2. Proper calibration of ultrasound and consistency of ultrasound settings between and within participants (frequency, gain, depth, dynamic range, etc.).
3. A skilled, experienced, and reliable technician completed all ultrasound imaging and ensured proper pressure and placement of the ultrasound probe upon the muscle of interest.

Operational Definitions

1. *Cross-Sectional Area*: The total area of a two-dimensional image of a body tissue.
2. *Dominant Leg*: Limb dominance was determined by self-reported kicking preference.
3. *Echo intensity/ Echogenicity*: The degree of reflectance of ultrasound waves off of a body tissue, measured via ultrasound (Pillen, 2010).
4. *Muscle Thickness*: The perpendicular distance from the deep border of the superficial aponeurosis of a muscle to the superficial border of the deep aponeurosis of the same muscle (Mangine et al., 2014a; Mangine et al., 2014b; Mangine et al., 2014c; Radaelli et al., 2013; Scanlon et al., 2014; Wells et al., 2014).
5. *Subcutaneous Adipose Tissue Thickness/ Subcutaneous Fat Thickness*: The perpendicular distance from the superficial border of the superficial aponeurosis of a muscle to the deep border of the epithelium.
6. *Tertile*: Once a panoramic transverse image of the vastus lateralis has been divided into equal thirds based on length, one tertile represents one of the three compartments of the muscle.
 - a. *Anterior Tertile*: The compartment of the vastus lateralis in a divided panoramic transverse image that is situated near the front of the body.
 - b. *Posterior Tertile*: The compartment of the vastus lateralis in a divided panoramic transverse image that is situated near the rear of the body.
 - c. *Lateral Tertile*: The compartment of the vastus lateralis in a divided panoramic transverse image that is situated away from the midline of the body.

CHAPTER TWO: REVIEW OF LITERATURE

The Use of Ultrasonography in Skeletal Muscle Assessment

The use of ultrasonography in assessment of skeletal muscle has grown vastly over the past 20 years (Mourtzakis & Wischmeyer, 2014). Ultrasonography is a quick, portable, relatively inexpensive, and non-invasive way to measure skeletal muscle morphological characteristics, including attributes such as muscle thickness, cross-sectional area, fiber architecture, and echo intensity (Pillen, 2010; Pillen and van Alfen, 2011). The following review articles explain how ultrasonography is utilized in relation to assessment of skeletal muscle morphology.

Ihnatsenka, B. and Boezaart, A.P., 2010.

Ultrasound: Basic Understanding and Learning the Language.

The purpose of this article was to familiarize the reader with various terms, techniques, and settings regarding the use of a standard ultrasound. Ultrasonography of skeletal muscle typically utilizes a brightness-mode (B-mode) ultrasound, which creates black-and-white images of different body tissues and muscles on the ultrasound screen. Each tissue contains varying degrees of grayscale contrast, which enables the distinction of one tissue from another. Skeletal muscle ultrasonography incorporates the use of a straight probe, which produces an image onscreen that is equal to the width of the transducer. When placed on the surface of the skin, the probe transmits sound waves that pass into the body and reflect off of each body tissue with a different amplitude. The reflected 'echoes' are transmitted back to the probe, which then create

pixelated images based on the degree of tissue reflectance and the time it took for the echo to return back to the probe.

Ultrasound probes can emit waves of high frequency, midrange frequency, or low frequency, where each frequency serves a specific function. High-frequency probes emit waves ranging from 10-15-Megahertz and are preferred when examining superficial tissues at a maximum distance of 4 centimeters from the surface of the skin. Midrange-frequency probes emit waves ranging from 5-10-Megahertz and are used to view deeper structures that lie 5-6 centimeters from the surface of the skin. Low-frequency probes emit waves ranging from 2-5-Megahertz and are beneficial when viewing much deeper images, 10+ centimeters from the surface of the skin. High-frequency probes and midrange-frequency probes provide better image resolution than low-frequency probes, however low-frequency probes permit a greater image depth. It is essential to use the probe that provides the best resolution for the corresponding depth of the tissue of interest. Additionally, the depth setting on the ultrasound should be set deep enough so that the image encompasses the entire tissue of interest, however increasing the depth after this point will decrease image quality. In addition, changing the gain of the ultrasound will adjust the brightness of the image. Modifying the gain will cause a change in the echogenicity of the image and may allow easier discrimination of separate muscles and body tissues, but it is crucial to keep this constant during the examination of multiple subjects.

Probe manipulation is another aspect of ultrasonography that is crucial for acceptable image quality. Altering the probe will change the direction of the ultrasound wave beams, which will affect each image. The mnemonic 'PART' can be useful when discussing probe manipulation, which stands for pressure, alignment, rotation, and tilt. Modifications in any one of

these maneuvers will change the way a body structure appears on an image. For example, modifying the pressure application of the probe on the skin surface can improve image quality, but can also affect the thickness and brightness of the structure of interest. Typically, probe pressure should be applied evenly so that all sides of the tissue are compressed to an equal and even extent. In some scenarios however, it may be beneficial to apply more pressure on one side of the probe than on the other in order to direct the beam perpendicularly to the structure of interest so that the underlying structures are properly aligned. In addition, applying too much pressure to the probe may disfigure the body tissues and lead to an inaccurate representation of muscle morphology.

Alignment, also referred to as sliding, is also a vital aspect of probe manipulation, especially when performing panoramic ultrasound scans. Panoramic scans are a relatively new development in ultrasonography, which permit two-dimensional cross-sectional images of larger muscles to be viewed in a single image (Ahtiainen et al., 2010; Henrich, Schmider, Kjos, Tutschek, & Dudenhausen, 2002). Panoramic scans are especially beneficial for use when the structure of interest will not fit entirely in a still image. These types of scans have been proven effective for measuring spatial arrangement, locating anatomical reference points, and accurately measuring muscle and organ volume (Henrich, Schmider, Kjos, Tutschek, & Dudenhausen, 2002; Kim, Choi, Kim, Lee, & Han, 2003). Panoramic scans utilize the compilation of multiple still images, overlapped upon one another to produce one comprehensive image. When performing an ultrasonographic panoramic scan, the ultrasound probe is moved along the skin adjacent to the structure of interest. It is essential that constant pressure and sliding speed of the probe are maintained throughout the entire sweep to ensure that possible alterations in muscle characteristics within the image are not due to improper probe alignment or pressure.

Rotation and tilt are other characteristics of probe manipulation that can be altered to change an ultrasound image. Rotation refers to the clockwise/counter-clockwise shift of the probe, which can affect the orientation of muscle fibers and measurement of cross-sectional area if the probe is rotated erroneously. Tilt refers to the backward/forward movement of the probe, which can affect the direction of the wave beam that is reflected off the tissue of interest. In all, it is imperative that correct probe manipulation is performed to produce a high-quality and accurate depiction of underlying body tissues (Ihnatsenka and Boezaart, 2010).

Pillen, S., 2010.

Skeletal Muscle Ultrasound.

The purpose of this article was to compare the use of an ultrasound in assessment of normal muscle tissue to that of neurological or pathological muscle tissue. Normal muscle tissue can be easily distinguished from surrounding structures such as bone, subcutaneous fat, nerves, and blood vessels due to the varying degrees of echogenicity that each tissue possesses.

Echogenicity, or echo intensity, refers to the degree of reflectance of ultrasound waves off of a body tissue. When a difference in reflectivity between different body structures or different parts of the same structure exists, contrasting colors will appear on the ultrasound image. All body tissues can be characterized by some degree of echogenicity, ranging from tissues that are hyperechoic, or those that appear completely white on the screen, to those that are anechoic, or those that appear completely black on the screen. Tissues that are hyperechoic possess greater reflectivity than those that are anechoic. For example, in a given ultrasound image, bone appears anechoic with a hyperechoic rim due to the inability of the ultrasound beam to penetrate past the outer surface of the bone. Arteries, veins, and fat also appear anechoic on an

ultrasound image. On the other hand, muscles appear hypoechoic, a degree of reflectance between hyperechoic and anechoic that appears a shade of gray on screen.

Muscles have a striate structure, which is primarily due to intramuscular fascia, individual fibers, and connective tissue surrounding each individual fascicle. Fascia and connective tissue appear as lines or streaks throughout muscle and are hyperechoic in nature (Ihnatsenka and Boezaart, 2010). Normal skeletal muscle appears hypoechoic, but the degree of echogenicity can be influenced by various factors. For example, a healthy muscle will appear relatively uniform throughout, with a lower reflectance and lower echogenicity due to the decreased presence of intramuscular fat or fibrous tissue. In contrast, neurological or pathological disorders can cause skeletal muscle architecture to become distorted, leading to the infiltration of fat and fibrous tissue (Caresio, Molinari, Emanuel, & Minetto, 2004; Miljkovic and Zmuda, 2010). The increased presence of intramuscular fat or fibrous tissue produces an image that is brighter in color. A brighter ultrasound image is typically indicative of “poorer” muscle quality due to the increased levels of intramuscular fat and fibrous tissue. However, muscle quality is a very subjective measurement and can differ depending on the goals of the individual (Fukumoto et al., 2012; Pillen et al., 2009; Pillen and van Alfen, 2011).

Additionally, attenuation of the ultrasound beam can further affect the echogenicity of a skeletal muscle (Pillen, 2010). The inconsistencies in impedance as the ultrasound waves travel through underlying body structures inherently cause the superficial part of the a tissue of interest to appear more hyperechoic than the hypoechoic deeper part, which could result in an inaccurate measure of muscle echogenicity (Pillen, 2010).

Ultrasonography can be beneficial for use in all anatomical planes of the body.

Ultrasound scanning or imaging planes are similar to anatomical planes and consist of the transverse (axial) plane, the longitudinal (sagittal) plane, and the frontal (coronal) plane.

Utilization of different imaging planes will have a profound effect on the ultrasound image as well as the body tissues that can be seen. For example, a transverse scan, captured perpendicularly to the long axis of the muscle, will produce an image with a speckled appearance due to the perpendicular division of individual muscle fibers in this plane. In contrast, a longitudinal scan, taken parallel to the long axis of the muscle, will produce an image with visible striations, which are visible fascia and connective tissue between individual muscle fibers. Differences in muscle architecture on a macroscopic level (fusiform muscles, unipennate muscles, bipennate muscles, convergent muscles, etc.) will result in variations in muscle fiber arrangement and therefore will change what can be viewed on an ultrasound image.

The ability to classify muscle architecture correctly and distinguish one structure from another is imperative when analyzing ultrasound images. The fibrous epimysium surrounding skeletal muscle is very hyperechoic and clearly visible on ultrasound images. In addition, variations in echo intensity values can exist between different skeletal muscles due to disparities in the amount of fibrous tissue, muscle architecture, and possible imbalances throughout the body (Seynnes, de Boer, Narici, 2007). It is vital to take this into account when comparing the echogenicity of one muscle to that of another.

Quantification of the echo intensity of an individual muscle is typically performed through gray scale analysis. Utilization of an image analysis software, such as ImageJ (National Institutes of Health, Bethesda, Maryland, USA) or Adobe Photoshop (Adobe Systems Inc., San

Jose, California, USA) allows a subjective selection of a region of interest within an ultrasound image. After selecting a region of interest that entirely encompasses only the desired skeletal muscle but does not include the surrounding fascia, a histogram plot of the brightness of each individual pixel within the region of interest can be created. The values on the histogram range from 0-255, where a value of 0 represents a pixel that is completely black, and a value of 255 represents a pixel that is completely white (Nielsen, Jensen, Darvann, Jorgensen, & Bakke, 2006; Pillen, 2010; Pillen and van Alfreu, 2011). The mean grayscale value from the region of interest can then be generated via the histogram, which describes the overall echogenicity of the region of interest. Lower mean levels of echo intensity are indicative of a darker muscle and usually contain less intramuscular fat or fibrous tissue. Higher mean levels of echo intensity are indicative of a brighter muscle and usually contain greater amounts of intramuscular fat, fibrous tissue, some degree of neuromuscular or pathological disorders, or the infiltration of inflammatory markers as an indication of muscle damage (Jajtner et al., 2015). However, the echo intensity of a muscle can also be affected by the gain or depth of the ultrasound probe transducer and can also vary depending on the pressure, tilt, rotation, and alignment of the probe on the skin itself (Pillen, 2010). It is very essential to keep these consistent between each individual when performing a research study. An alteration in one variable can lead to extreme changes in echogenicity that are not actually due to the muscle itself, but due instead to application of the ultrasound (Pillen, 2010).

Validity and Reliability of Ultrasonography in Assessment of Skeletal Muscle Morphology

Previous research has shown that ultrasonography is a valid and reliable tool for the assessment of skeletal muscle morphological characteristics, such as muscle cross-sectional area and muscle thickness. Cross-sectional area is defined as the area of a cross-sectional image of a muscle and is a valid and reliable measure of muscle size (Mangine et al., 2014a; Mangine et al., 2014b; Mangine et al., 2014c; Scanlon et al., 2014; Wells et al., 2014). Muscle thickness, defined as the perpendicular distance from the superficial aponeurosis to the deep aponeurosis of the muscle, has also been reported to be a valid and reliable way to assess muscle size (Mangine et al., 2014a; Mangine et al., 2014b; Mangine et al., 2014c; Radaelli et al., 2013; Scanlon et al., 2014; Wells et al., 2014). However, many studies have used alternative techniques to assess skeletal muscle and tissue, which include but are not limited to, magnetic resonance imaging and computerized tomography. The following studies have aimed to examine the validity and reliability of assessing skeletal muscle and body tissue through ultrasonography in comparison to other muscle imaging techniques.

Validity and Reliability of Ultrasonography Compared to Magnetic Resonance Imaging

Magnetic resonance imaging, or MRI, has been often been considered the gold standard for assessing skeletal muscle size and cross-sectional area, especially in the evaluation of exercise training programs, disease, or sarcopenia (Ahtiainen et al., 2010; Reeves, Maganaris, & Narici, 2003). Magnetic resonance imaging enables a high level of contrast between different body tissues as well as visualization of both superficial and deep muscles, making the assessment

of each tissue relatively easy (Ahtiainen et al., 2010; Pillen, 2010; Pillen and van Alfen, 2011; Reeves, Maganaris, & Narici, 2003). However, magnetic resonance imaging devices are not easily accessible for use in research due to their high cost of operation and high demand in clinical settings, which is why ultrasonography is often used for skeletal muscle assessment instead (Reeves, Maganaris, & Narici, 2003). The following studies aim to examine the validity and reliability of the use of ultrasonography compared to magnetic resonance imaging.

Esformes, J.I., Narici, M.V., & Maganaris, C.N., 2002.

Measurement of Human Muscle Volume Using Ultrasonography.

The purposes of this study were to use ultrasonography to measure the volume of the tibialis anterior muscle, to determine the reproducibility of using ultrasonography as a technique to assess muscle volume, and to examine the validity of ultrasonography compared to magnetic resonance imaging. Six healthy and physically active males and females (age: 23 ± 3 years) volunteered to participate. On day one of the study, participants were instructed to lay in a supine position for 20-30 minutes prior to testing to allow for interstitial or intracellular fluid shifts to occur. A 7.5-Megahertz, brightness-mode ultrasound was used to obtain 11 different transverse scans of the tibialis anterior muscle of the left leg in each subject. The length of the tibialis anterior muscle varied between subjects, but the distance between each of the 11 scans was kept constant within each subject. Measurement of the tibialis anterior was performed through ultrasonographic identification of the myotendinous and osteotendinous junctions at the proximal and distal ends of the muscle, respectively. Each ultrasound image was recorded twice, five minutes apart. On the next visit, which occurred 1-3 days later, magnetic resonance imaging scans were captured at the same locations that the ultrasound scans had previously been taken at.

All image analysis was performed by the same investigator three separate times using NIH Image software (NIH Image, National Institute of Health, Bethesda, USA).

The results of this study revealed that there was a very high intra-class correlation (ICC = 0.99) between the two ultrasound measurements taken at each of the 11 intervals, indicating that ultrasound assessment of tibialis anterior volume is highly reproducible. There was also a very strong correlation between the tibialis anterior volume assessed via magnetic resonance imaging and ultrasonography ($r^2 = 0.978$). However, the researchers noted that compared to the magnetic resonance imaging method, ultrasonography tended to slightly overestimate muscle volumes smaller than 120 centimeters³ and underestimate muscle volumes larger than 120 centimeters³. Overall, ultrasonography is a reliable, accurate, and reproducible method of measuring muscle volume as compared to magnetic resonance imaging (Esformes, Narici, & Maganaris, 2002).

Reeves, N.D., Maganaris, C.N., & Narici, M.V., 2004.

Ultrasonographic Assessment of Human Skeletal Muscle Size.

Reeves and colleagues (2004) aimed to test the reproducibility and validity of ultrasonography compared to magnetic resonance imaging in assessment of the cross-sectional area of the vastus lateralis muscle. This study was one of the first to use image fitting ultrasonography to assess a large muscle involved in locomotion. Ultrasonography had previously been restricted to measurement of small muscles due to the limited size of the ultrasound image. Six healthy males and females (age: 76.8 ± 3.2 years) volunteered to participate in this study. On the day of testing, subjects were instructed to lay in a supine position for 20 minutes prior to examination to allow for fluid shifts to occur. A 7.5-Megahertz,

brightness-mode ultrasound was used to obtain 10 transverse scans of the vastus lateralis muscle of the right leg in each subject. The proximal insertion of the vastus lateralis was identified on each subject and 10 transverse sections were then marked every 30 millimeters (mm) from this point. Ultrasound images of each section were recorded twice, with an average of three days in between scans. Magnetic resonance imaging measurements were performed on the same days that the ultrasound measurements were taken, about one hour after the ultrasound scans.

Magnetic resonance imaging scans attempted to capture images at the same locations that the ultrasound scans had previously been taken at, however it was only possible to obtain images of the lower vastus lateralis due to size constraints with magnetic resonance imaging. All magnetic resonance imaging and ultrasound measurements were performed by the same investigator.

Ultrasonographic still images of the vastus lateralis were sequentially opened in Microsoft PowerPoint (Microsoft, Redmond, WA, USA) and were rotated upon each other until the entire cross-section of the muscle could be seen. Cross-sectional area image analysis of the magnetic resonance images and ultrasound scans were then performed by six different experimenters to examine inter-experimenter reliability.

The results of this study showed that there was a very strong intra-class correlation (ICCs ranged from 0.997 to 0.999) between the two ultrasound measurements taken at each of the 10 intervals, and typical error for ultrasound reliability was averaged 0.29 centimeters² (2.6%). This indicates that ultrasound assessment of vastus lateralis cross-sectional area is highly reproducible. Validity of the magnetic resonance imaging method compared to the ultrasound method produced intra-class correlations ranging from 0.988 to 0.999, with a mean typical error of 0.15 centimeters² (1.7%). Coefficient of variation values for cross-sectional area analysis by different experimenters equalled 2.1% for ultrasound images and 0.8% for magnetic resonance

images. Although coefficients of variation were slightly greater for ultrasonography assessment compared to magnetic resonance imaging assessment, this indicates that ultrasonography is a valid and reliable tool to assess the cross-sectional area of large muscles compared to magnetic resonance imaging. However, due to the small sample size and homogeneous population, the results of this study may not generalize to other populations. For example, the typically lower muscle mass and cross-sectional area that is often seen in older individuals would require fewer images to construct the overlay of the muscle (Janssen, Heymsfiels, & Ross, 2002). In younger individuals who possess greater muscle mass, more images of the vastus lateralis would be required, possibly increasing the chance of error. In addition, differences in subcutaneous fat and tendon architecture exist between younger and older individuals, which may also affect image fitting (Kubo, Kanehisa, Miyatani, Tachi, & Fukunaga, 2003). This study shows the validity and reliability of the use of ultrasonography in a specific population, but whether or not the validity and reliability of its use also applies to other populations will be further discussed (Reeves, Maganaris, & Narici, 2004).

Lixandrão, M.E., Ugrinowitsch, C., Bottaro, M., Chacon-Mikahil, M.P.T., Cavaglieri, C.R., Min, L.L., de Souza, E.O., Laurentino, G.C., & Libardi, C.A., 2014.

Vastus Lateralis Muscle Cross-Sectional Area Ultrasonography Validity for Image Fitting in Humans.

To test a more heterogeneous sample of subjects, Lixandrão and colleagues (2010) examined the validity of magnetic resonance imaging compared to ultrasonography in assessment of the cross-sectional area of the vastus lateralis muscle. In this experiment, 31 subjects (age: 52.44 ± 16.37 years; n = 21 males, n = 10 females) who were healthy and had not

participated in an exercise training program for at least six months were recruited. Each subject was instructed to refrain from exercise for 72 hours prior to the first day of the study. Upon arrival, all subjects were instructed to lay in a supine position 20 minutes prior to examination to allow for fluid shifts to occur. Their legs were then strapped with Velcro to prevent movement. Magnetic resonance images and ultrasound images were captured in duplicate of the participants' right vastus lateralis muscle at 50% of the perpendicular distance from the greater trochanter to the inferior border of the lateral epicondyle of the femur. Sequential ultrasonographic still images were captured using a 7.5-Megahertz brightness-mode ultrasound, which were then imported into an image overlaying software that was previously described by Reeves and colleagues (2004). Cross-sectional area for each image was measured using an image analysis software.

The results of this experiment demonstrated that there was a very strong positive correlation ($r = 0.99$, $p < 0.001$) between the cross-sectional area values obtained from the magnetic resonance images and the ultrasound images. The total error between the two imaging techniques was 0.37 centimeters² (1.75%), which was similar to the total error between magnetic resonance images and ultrasound images reported by Reeves et al. (2004). High intra-measurement reliability of both the magnetic resonance imaging and ultrasound methods were reported; the typical error was equal to 0.36 centimeters² (1.69%) and 0.35 centimeters² (1.68%), respectively. These results suggest that there is high validity and reliability of using ultrasonography to assess the cross-sectional area of the vastus lateralis muscle in a heterogeneous sample of participants. The authors note that the ultrasound method of measuring cross-sectional area does not produce an over- or underestimation of the actual measurements, as previously proposed by Reeves Maganaris, & Narici (2004) because the values of cross-sectional

area obtained by both magnetic resonance imaging and ultrasonography were very similar (Lixandrão et al., 2014).

Ahtiainen, J.P., Hoffren, M., Hulmi, J.J., Pietikäinen, M., Mero, A.A., Avela, J., & Häkkinen, K., 2010.

Panoramic Ultrasonography is a Valid Method to Measure Changes in Skeletal Muscle Cross-Sectional Area.

A relatively recent and increasingly popular technique in ultrasonography is the use of panoramic imaging. Often times, single still ultrasound images do not permit the entire area of large muscles to be viewed in a single frame. Panoramic ultrasound imaging is a process that involves the overlapping of multiple still images upon one another to create one cohesive image on the ultrasound screen. Panoramic images are composed of multiple small snapshots of the muscle, which are aligned upon one another to create a larger image that contains the entire region of interest. Prior to this point, the reliability and validity of this method of ultrasonography have not been evaluated in muscles with a large cross-sectional area. This study was the first to examine the validity and reliability of panoramic ultrasonography in the assessment of vastus lateralis cross-sectional area compared to magnetic resonance imaging.

Twenty-seven untrained, healthy men were placed in either a total-body resistance-training group ($n = 20$; age: 26.0 ± 4.2 years) or control group ($n = 7$; age 24.3 ± 3.0 years) for 21 weeks. Vastus lateralis cross-sectional area was measured via ultrasonography and magnetic resonance imaging taken on the same days at the beginning and end of the study, preceded by at least three days of inactivity. Subjects were instructed to lay supine for 20 minutes prior to

examination to allow for fluid shifts to occur. Upon examination, each participants' legs were placed 15 centimeters apart and were held in place with sculptured supports between and under their legs to prevent movement. The ultrasound and magnetic resonance imaging scans were performed at three different locations along the vastus lateralis muscle; one at the midpoint of the lateral knee joint surface and the spina iliaca anterior superior, one located 2 centimeters distally, and one located 4 centimeters distally from the aforementioned point. A 10-Megahertz brightness-mode ultrasound and LogicView™ software was used to generate panoramic images of the vastus lateralis muscle. A probe support, angled perpendicularly to the leg, was used to ensure that constant pressure and compression was applied against the leg throughout the entire scan. The probe was manually moved along the leg in transverse plane, which had been marked previously with an ink line along the skin. As the transducer was moved, the LogicView™ software created a panoramic image on the screen. The quick frame rate of this software allowed for greater than 10 images to be taken per second, resulting in considerable overlap of images. Based on the rotation and orientation of the images in the sequence, the software was able to create one comprehensive image on the screen to display to the user. Three panoramic ultrasonographic images were taken at each location for every subject before and after the 21-week period. Magnetic resonance images were taken at the same sites that the ultrasound images were obtained from. The same investigator performed all of the ultrasound and magnetic resonance imaging measurements in this experiment. After all of the measurements were obtained, an image analysis software (ImageJ, National Institutes of Health, Bethesda, MD, USA) was used to determine vastus lateralis cross-sectional area from both the ultrasound and magnetic resonance imaging images.

The results of this study showed that subjects participating in the resistance training program experienced significantly greater increases in cross-sectional area of the vastus lateralis compared to the control group, which was observed in both the magnetic resonance imaging and ultrasound imaging techniques ($p < 0.001$). There was no statistically significant difference in muscle cross-sectional area between either group at the beginning of the study, so both groups were combined to assess the reliability of the ultrasound method in measuring cross-sectional area. The intra-day repeatability of the ultrasound measurements was very strong, with a high intra-class correlation (ICC = 0.997) and low standard errors of measurement (SEM = 0.38 centimeters²).

The validity of the ultrasound method compared to the magnetic resonance imaging method in measurement of cross-sectional area was also assessed. The magnetic resonance imaging method yielded cross-sectional area values that were systematically larger than those obtained using the ultrasound method (31.28 ± 5.09 centimeters² vs 28.32 ± 4.96 centimeters², respectively), however intra-class correlations between the two were still very strong, and the standard error of measurement was low (ICC = 0.905, SEM = 0.87 centimeters²). The mean difference between the cross-sectional area values obtained from magnetic resonance imaging and ultrasound was $10 \pm 4\%$. When examining the validity of the ultrasound method compared to magnetic resonance imaging method in the assessment of changes in cross-sectional area after the training period, the intra-class correlation between the two types of measurement and the standard error of measurement both increased (ICC = 0.929, SEM = 0.94 centimeters²).

Overall, the results of this study show that panoramic ultrasonography is a valid and reliable tool in the assessment of vastus lateralis cross-sectional area. The ability of the

ultrasound to detect changes in muscle cross-sectional area after a training program was very similar to that measured via magnetic resonance imaging. The use of panoramic imaging reduces the time necessary for construction of the cross-sectional area of large muscles. However, cross-sectional area values assessed in the training group at the start of the study via ultrasonography were systematically lower than the values obtained via magnetic resonance imaging. The authors suggest that this may be due to the measurement plane of the ultrasound in comparison to that of magnetic resonance imaging. The magnetic resonance scans captured images in a plane along a perfectly vertical axis, perpendicular to the measurement table and not to the participant. In contrast, the ultrasound captured images perpendicularly to the participant's leg and not perpendicularly to the table. This could have resulted in an overestimation of the vastus lateralis cross-sectional area in the magnetic resonance images compared to the ultrasound images due to the angle at which the magnetic resonance imaging beam was oriented upon the leg. The experimenters reported that a difference in the perpendicular axis of measurement between the two methods of only 5-10° would result in a difference in cross-sectional area of approximately 1-3%. This may indicate that the use of the ultrasound is a more accurate way to assess vastus lateralis cross-sectional area than the use of magnetic resonance imaging. In summary, panoramic ultrasonography is a valid and reliable tool for measuring vastus lateralis cross-sectional area compared to magnetic resonance imaging (Ahtiainen et al., 2010).

Scott, J.M., Martin, D.S., Ploutz-Snyder, R., Caine, T., Matz, T., Arzeno, N.M., Buxton, R., & Ploutz-Snyder, L., 2012.

Reliability and Validity of Panoramic Ultrasound for Muscle Quantification.

This study aimed to examine the validity and reliability of panoramic ultrasonography compared to magnetic resonance imaging in the assessment of quadriceps and gastrocnemius cross-sectional area and volume. Researchers in this study used the same type of panoramic imaging previously described by Ahtiainen and colleagues (2010). Nine healthy people (n = 8 males, n = 1 female; age: 34.5 ± 8.2 years) with no recent history of thigh injury or inflammation volunteered to participate. Cross-sectional area of the vastus lateralis, rectus femoris, and medial and lateral gastrocnemius were measured using magnetic resonance imaging as well as a 9-Megahertz brightness-mode ultrasound with panoramic capabilities. During imaging, the investigators used a customized template on the right leg of each participant to ensure consistent measurement. Once images were obtained, two different researchers analyzed the cross-sectional area of the ultrasound and magnetic resonance images via different image analysis softwares (ultrasound: MATLAB; Mathworks, Natick, MA, USA; magnetic resonance imaging: ImageJ, v. 1.42, National Institutes of Health, Bethesda, MD, USA).

The researchers determined that there was high inter-rater reliability between both the ultrasound images and magnetic resonance images. The cross-sectional area determined from the ultrasound images had strong intra-class correlations (ICC = 0.963 – 0.991) and low coefficients of variation (CV = 2.4% – 4.1%). The cross-sectional area determined from the magnetic resonance images also had strong intra-class correlations (ICC = 0.946 – 0.986) and low coefficients of variation (CV = 2.8% – 3.8%). These findings align with other research investigating panoramic ultrasonography as a valid and reliable technique to measure cross-sectional area in large muscles such as the vastus lateralis (Thomaes et al., 2012; Noorkoiv, Nosaka, & Blazevich, 2010).

The absolute differences in cross-sectional area between the two images ranged from 0.3 to 1.0 centimeters², and mean differences in the cross-sectional area determined by ultrasonography were within 14% of the magnetic resonance imaging values for the rectus femoris and gastrocnemius, but greater than 14% for the vastus lateralis. The authors note that the disparities in cross-sectional area values between imaging techniques seen in the vastus lateralis may be due to the great curvature of the distal thigh compared and the large volume of the vastus lateralis muscle in general. With a large region of interest (in this case, muscle area), the ultrasound may systematically omit small sections of the image when processing it panoramically, which would produce a smaller image overall. Other researchers, including Ahtiainen and colleagues (2010), also found consistently smaller values of cross-sectional area with use of the ultrasound compared to magnetic resonance imaging. Ahtiainen et al. (2010) attributed this discrepancy to the differences in axes of analysis with ultrasonography and magnetic resonance imaging and determined that ultrasonography may actually produce values of cross-sectional area that are more accurate than those determined by magnetic resonance imaging (Scott et al., 2012).

Validity and Reliability of Ultrasonography Compared to Computerized Tomography:

Computerized tomography (CT) is another technique that is often used to assess skeletal muscle and is especially used in a clinical populations (Pillen, 2010; Pillen and van Alfren, 2011). Computerized tomography has often be used in emergency scenarios to examine bone injuries or detect the presence of disease (Pillen, 2010; Pillen and van Alfren, 2011; Thomaes et al., 2012). However, one disadvantage of computerized tomography is that, unlike

ultrasonography or magnetic resonance imaging, it emits radiation, and therefore may be deterred for use in certain populations or scenarios (Pillen, 2010; Pillen and van Alflen, 2011; Thomaes et al., 2012). For example, research studies requiring more than one computerized tomography scan (i.e. pre- to post- studies) may discourage people from participating due to the potentially harmful consequences. In addition, computerized tomography is capable of examining the infiltration of fat in muscles, but it is not capable of viewing fibrosis. The inability to distinguish fibrosis from normal muscle tissue in computerized tomography diminishes the ability for computerized tomography to assess muscle quality, but computerized tomography can still be used to assess muscle size. Regardless, the validity and reliability of computerized tomography compared to ultrasonography in the assessment of skeletal muscle will be discussed.

Thomaes, T., Thomis, M., Onkelinx, S., Coudyzer, W., Cornelissen, V., & Vanhees, L., 2012.

Reliability and Validity of the Ultrasound Technique to Measure the Rectus Femoris Muscle Diameter in Older CAD-Patients.

Thomaes and colleagues (2012) examined the reliability and validity of using ultrasonography compared to computerized tomography to measure the diameter of the rectus femoris muscle in elderly individuals. Forty-five males and females with coronary artery disease (age: 68.4 ± 6.2 years) who were participating in a sports maintenance program volunteered for this study. Twenty of the 45 subjects were assessed with both ultrasonography and computerized tomography, whereas the remaining subjects were assessed twice with ultrasonography to examine both the validity and reliability of ultrasonography. A sequence of five still-images of the right rectus femoris was obtained in every subject using a brightness-mode 12-Megahertz

ultrasound at the midpoint between the lateral epicondyle and major trochanter of the femur. Subjects who received computerized tomography scans did so at the same location as the ultrasound scans, however four of the five images were located either below or above the aforementioned point. All ultrasound and computerized tomography scans were measured by the same researcher.

The results of this study showed that the average difference between the rectus femoris diameter assessed via ultrasonography and computerized tomography was very small and insignificant (0.01 ± 0.12 centimeters, $p = 0.66$), and the intra-class correlation between the two types of measurement was high (ICC = 0.92). In addition, there was high test-retest reliability between the two ultrasound measurements, where the average difference between the two was small and insignificant (0.02 ± 0.10 centimeters, $p = 0.40$), and the intra-class correlation was high (ICC = 0.97). This study shows that ultrasound is a valid and reliable tool to assess rectus femoris muscle diameter in an older, diseased population as compared to computerized tomography. Ultrasonography may actually be beneficial for use in this population due to the evasion of radiation emission, which is one major consequence of using computerized tomography (Thomaes et al., 2012).

Noorkoiv, M., Nosaka, K., & Blazevich, A.J., 2010.

Assessment of Quadriceps Muscle Cross-Sectional Area by Ultrasound Extended-Field-of-View Imaging.

The purpose of this study was to examine the inter- and intra-experimenter reliability and validity of the cross-sectional area of the vastus lateralis muscle measured using ultrasonography

and computerized tomography. Another aim of the study was to examine whether the reliability of panoramic ultrasonographic imaging was dependent on the proximo-distal location from which the image was obtained. In this study, researchers used extended-field-of-view panoramic ultrasonography to assess the vastus lateralis muscle of six males (age: 28.7 ± 4.6 years) (Ahtiainen et al., 2010). Prior to testing, each subject rested in a supine position for 20 minutes. Cross-sectional area was assessed at 10%, 20%, 30%, 40%, and 50% of the distance from the superior border of the patella to the anterior superior iliac spine in both limbs of each participant. The researchers used a 10-Megahertz brightness-mode ultrasound to obtain five consecutive transverse scans at each site and on each leg of the subjects. A custom-made device was used to ensure that the probe was guided perpendicularly to the leg. Computerized tomography images were taken at the same sites previously marked, two hours after the ultrasound images were captured. Vastus lateralis cross-sectional area was then assessed using an image analysis software (1.41, Wayne Rasband, National Institutes of Health, USA).

The results of this study revealed that there was a high intra-class correlation between the two imaging techniques captured at each location, which ranged from 0.951 to 0.998 ($p < 0.001$). However, the 95% confidence interval was only in the acceptable range for images taken at 30%, 40%, and 50% of the distance from the superior border of the patella to the anterior superior iliac spine. The smallest difference between the cross-sectional areas measured using each technique was at the 50% mark, and the difference in cross-sectional area values obtained from each technique increased in the images taken distally from this point. At the 20% mark, the ultrasound images produced cross-sectional area values that were, on average, 8.9% smaller than those measured by computerized tomography. One major limitation of the study was that at the 10% mark, the vastus lateralis could not be visualized in most subjects.

The coefficient of variation examining the intra and inter-experimenter reliability of the ultrasound imaging technique ranged from 0.6 to 2.7%. The intra-class correlation values for inter-day reliability of the ultrasound imaging technique ranged from 0.982 to 0.998. The cross-sectional areas of the vastus lateralis assessed at each location were all significantly different from one another, regardless of the method used. This shows that the vastus lateralis muscle varies in muscle size at different locations. Based on these results, the experimenters concluded that ultrasonography is a valid and reliable tool to assess large muscle cross-sectional area, but that the validity and reliability are dependent on location. Images taken at mid-thigh and proximal sections of the vastus lateralis were the most accurate and repeatable, whereas images taken more distally had poorer reliability. At distal regions of the thigh, a lower reliability was most likely observed because of the smaller thigh diameter and tightly curved surface, which may have made the probe more difficult to control. However, as the diameter of the vastus lateralis decreases, the most appropriate scanning plane for measurement of cross-sectional area changes due to the differences in the structure of the muscle. At a more distal point on the muscle, the superficial and deep aponeuroses of the vastus lateralis no longer exhibit a near-parallel formation, as they do at a more central point. In computerized tomography, each image is taken perpendicularly to the table, which is an accurate method for measuring cross-sectional area when the aponeuroses of the muscle are parallel to each other. As the distance from the mid-thigh area increases, the cross-sectional area of the muscle may not be obtained in the correct plane when assessed by computerized tomography. On the other hand, ultrasonography captures an image that is perpendicular to the skin, which may provide a more accurate measurement of distally-located cross-sectional area than computerized tomography. In the present study, a smaller cross-sectional area was observed with the ultrasound technique as compared to the

computerized tomography technique in all distal images, which may provide evidence that ultrasonography is a better method to assess cross-sectional area at distal locations than computerized tomography (Noorkoiv, Nosaka, & Blazevich, 2010).

Validity and Reliability of Ultrasonography in Assessment of Subcutaneous Adipose Tissue

Thickness

In addition to the assessment of skeletal muscle morphological characteristics, ultrasonography has also been used as a tool to measure subcutaneous body adipose tissue thickness (Pineau, Filliard, & Bocquet, 2009; Selkow, Pietrosimone, & Saliba, 2011). Subcutaneous adipose tissue is defined as the layer of fat that lies beneath the skin, superficial to the muscle (Selkow, Pietrosimone, & Saliba, 2011). Correct and accurate measurement of subcutaneous adipose tissue thickness is an essential tool in the examination of an individual's body composition or percent body fat. Body composition can be used as an indication of health, where a lower body fat percentage is generally associated with lower risk of disease (Wagner, 2013). The evaluation of subcutaneous adipose tissue thickness in previous studies has been assessed in various ways, including the use of skinfold measurements, dual x-ray absorptiometry, hydrostatic weighing, and ultrasonography (Fanelli & Kuczmarski, 1984; Pineau, Filliard, & Bocquet, 2009; Selkow, Pietrosimone, & Saliba, 2011).

The use of ultrasonography as a way to assess subcutaneous adipose tissue thickness has been proven to be valid and reliable in comparison to magnetic resonance imaging, computerized tomography, bioelectrical impedance analysis, arm circumference, and skinfolds. For example, Fanelli and Kuczmarski (1984) examined the correlation between subcutaneous adipose tissue

thickness measured via skinfold calipers and brightness-mode ultrasound. The researchers discovered correlation coefficients ranging from $r = 0.677 - 0.871$ between the two methods of assessing subcutaneous adipose tissue thickness at areas adjacent to the triceps, biceps, subscapula, waist, suprailiac, thigh, and calf in 124 men (age: 18-30 years). In another study assessing the correlation of subcutaneous adipose tissue measured by skinfold calipers and ultrasonography, Selkow and colleagues (2011) found strong correlations between the two methods in the vastus medialis obliquus ($r = 0.90, p < 0.001$), distal and proximal rectus femoris ($r = 0.93, p < 0.001$ and $r = 0.93, p < 0.001$, respectively), and vastus lateralis ($r = 0.91, p < 0.001$) in 20 healthy adults ($n = 13$ men, $n = 7$ women; age: 26.9 ± 5.4 years). Fukumoto and colleagues (2012) discovered that subcutaneous fat thickness assessed via ultrasonography was significantly positively correlated with body mass index and percent body fat as assessed by bioelectric impedance analysis ($r = 0.61, p < 0.001$ and $r = 0.51, p < 0.001$, respectively). Furthermore, Jenkins et al. (2015) discovered significant correlations between fat thickness adjacent to the biceps brachii assessed via ultrasonography and skinfold thickness and arm circumference ($r = 0.98; p < 0.001; r = 0.75; p < 0.01$, respectively). These studies provide evidence that ultrasonography is a valid and reliable tool in the assessment of subcutaneous adipose tissue thickness.

Effects of Intramuscular and Subcutaneous Fat on Skeletal Muscle Echo Intensity

Skeletal muscle echo intensity has been shown to be related to levels of intramuscular fat and possibly subcutaneous adipose tissue (Caresio, Molinari, Emanuel, & Minetto, 2014; Fukumoto et al., 2012; Nijboer-Oosterveld, van Alflen, & Pillen, 2011; Scholten, Pillen, Verrips,

& Zwarts, 2003; Pillen, 2010; Pillen and van Alflen, 2011; Watanabe et al., 2013; Young, Jenkins, Zhao, & McCully, 2015). Pillen and colleagues (2009) discovered significant positive correlations between muscle echo intensity and the amount of intramuscular fibrous tissue obtained via muscle biopsies. Furthermore, Young et al. (2015) discovered significant positive correlations between intramuscular fat assessed via magnetic resonance imaging and echo intensity. Studies regarding whether or not subcutaneous adipose tissue thickness is related to echo intensity have discovered conflicting results. Some researchers have shown that echo intensity values are positively correlated with subcutaneous fat thickness (Caresio, Molinari, Emanuel, & Minetto, 2014; Nijboer-Oosterveld, van Alflen, & Pillen, 2011; Watanabe et al., 2013; Young, Jenkins, Zhao, & McCully, 2015). However, additional research has found no correlation between echo intensity and subcutaneous fat thickness (Fukumoto et al., 2012; Jenkins et al., 2015; Melvin et al, 2014; Scholten, Pillen, Verrips, & Zwarts, 2003; Wu, Darras, & Rutkove, 2010). Jenkins et al. (2015) discovered significant correlations between fat thickness adjacent to the biceps brachii assessed via ultrasonography with skinfold thickness and arm circumference ($r = 0.98$; $p < 0.001$; $r = 0.75$; $p < 0.01$, respectively), but found no significant correlation between fat thickness and skeletal muscle echo intensity. Similarly, Caresio et al. (2014) discovered no correlation between fat thickness and echo intensity in the biceps brachii, however significant positive correlations existed between subcutaneous adipose tissue thickness and echo intensity of the vastus lateralis, tibialis anterior, and medial gastrocnemius. Perhaps the subcutaneous adipose tissue thickness adjacent to the biceps brachii does not have an effect on the echo intensity of that muscle, but the subcutaneous adipose tissue thickness adjacent to the other muscle groups has an effect on the echo intensity of that muscle group (Caresio et al., 2014; Jenkins et al., 2015). Melvin and colleagues (2014) discovered no significant correlations

between vastus lateralis echo intensity assessed via ultrasonography and percent body fat, fat mass, lean mass, or leg lean mass in NCAA Division I football players assessed by dual x-ray absorptiometry. Overall, conflicting results exist as to whether or not subcutaneous adipose tissue has an effect on skeletal muscle echo intensity. The following study aims to discuss the effects of intramuscular and subcutaneous adipose tissue on skeletal muscle echo intensity.

Although the previously discussed studies provide conflicting results, it is important to note that a greater amount of subcutaneous fat adjacent to the muscle may provide larger variability in echo intensity values (Pillen, 2010; Pillen and van Alfen, 2011). Pillen (2010) noted that there may be attenuation or non-systematic reflection of the ultrasound beam when it encounters different tissues, which may affect echo intensity values. Young and colleagues (2015) proposed that an underestimation of echo intensity may occur when the amount of intramuscular fat reaches about 15% due to the non-systematic reflection of the ultrasound waves. If there is an underestimation of intramuscular fat, the echo intensity of the muscle would most likely decrease, which would lead to an inaccurate measure of echogenicity and muscle quality.

Additional research hypothesized that increased levels of intermuscular fat, or fat within fascia, may be due to the overflow of subcutaneous fat into the intermuscular compartment due to the inability to store excess amounts of fat (Gan et al., 2002). With an increase in intermuscular fat and accompanying preservation of subcutaneous fat, one may seem to have lower levels of subcutaneous fat, when in reality, the fat has just been deposited intermuscularly instead. The following study aimed to examine the effect of intramuscular fat on echo intensity in healthy individuals.

Young, H., Jenkins, N.T., Zhao, Q., & McCully, K.K., 2015.

Measurement of Intramuscular Fat by Muscle Echo Intensity.

The purpose of this study was to compare the echo intensity values derived from ultrasound images to the percent intramuscular fat values obtained through magnetic resonance imaging of the rectus femoris, biceps femoris, tibialis anterior, and medial gastrocnemius muscles. Thirty-one males and females (ages: 20-61 years) with diverse body mass indices and physical activity levels completed either two testing sessions (one using ultrasound and one using magnetic resonance imaging) or three testing sessions (two using ultrasound and one using magnetic resonance imaging). Images of the dominant leg were captured while the participant was lying in a supine position using an 8-12-Megahertz brightness-mode ultrasound. The gain was set at 58 decibels, the frequency was set at 8-Megahertz, and the depth was set at 4 centimeters. The scanning depth was kept constant from participant to participant unless the thickness of the layer of subcutaneous fat did not allow the entire muscle area to fit in the ultrasound image. Both the magnetic resonance images and ultrasound images were obtained from the same location on each muscle. This allowed for intramuscular fat comparisons between the two imaging techniques and within-muscle analysis of echo intensity and percent intramuscular fat variability. Two images of each imaging type were captured from the muscles of interest. However, one major limitation that the authors noted was that the entire areas of the biceps femoris, tibialis anterior, and medial gastrocnemius did not fit in the single ultrasound image. This may have resulted in measures of muscle echo intensity that were not representative of the entire muscle because the full muscle area was not included. The ultrasound and magnetic resonance images were then used to quantify echo intensity, muscle thickness, subcutaneous fat

thickness, and cross-sectional area of each muscle using an image analysis software (ImageJ, National Institutes of Health, Bethesda, MD, version 1.45s).

The results of this study revealed that there were moderate to strong positive correlations between the echo intensity values and the percent intramuscular fat measured by magnetic resonance imaging for each muscle (tibialis anterior: $r = 0.66$; rectus femoris: $r = 0.79$; biceps femoris: $r = 0.45$; medial gastrocnemius: $r = 0.54$). This data shows that a higher echo intensity assessed by ultrasonography was associated with higher levels of intramuscular fat assessed by magnetic resonance imaging. The investigators also observed an independent influence of subcutaneous fat thickness on muscle echo intensity. After correction for subcutaneous fat thickness, stronger correlations between muscle echo intensity and percent intramuscular fat were observed for each muscle (tibialis anterior: $r = 0.80$; rectus femoris: $r = 0.91$; biceps femoris: $r = 0.80$; medial gastrocnemius: $r = 0.76$). Further correlation analyses were then performed, separating the participants by gender. Higher correlations were found in men compared to women in every muscle (males: tibialis anterior: $r = 0.77$; rectus femoris: $r = 0.96$; biceps femoris: $r = 0.86$; medial gastrocnemius: $r = 0.86$; females: tibialis anterior: $r = 0.59$; rectus femoris: $r = 0.84$; biceps femoris: $r = 0.84$; medial gastrocnemius: $r = 0.81$). After combining the data from all muscles, an overall moderate to strong correlation was found between echo intensity and percent intramuscular fat ($r = 0.61$). In addition, a multiple-regression analysis was performed with echo intensity and subcutaneous fat thickness as independent variables and percent intramuscular fat as the dependent variable. This provided correlation coefficients that were similar to those found with the simple linear correlation with the subcutaneous fat correction factor applied (tibialis anterior: $r = 0.76$; rectus femoris: $r = 0.90$; biceps femoris: $r = 0.80$; medial gastrocnemius: $r = 0.76$).

The reproducibility of the testing procedure on two separate days across all muscle groups were high, as indicated intra-class correlations and coefficients of variation for echo intensity values: rectus femoris: ICC = 0.91, CV = 3.3%; biceps femoris: ICC = 0.72, CV = 13.1%; tibialis anterior: ICC = 0.92, CV = 2.6%; medial gastrocnemius: ICC = 0.71, CV = 5.6%. In addition, the inter-tester reliability of the ultrasound image analysis was examined and shown to be high in all muscle groups: rectus femoris: ICC = 0.93, CV = 4.3%; biceps femoris: ICC = 0.96, CV = 4.5%; tibialis anterior: ICC = 0.98, CV = 3.5%; medial gastrocnemius: ICC = 0.95, CV = 3.7%.

The results of this study show that moderate to strong correlations existed between echo intensity and percent intramuscular fat in four different muscles of the lower extremity. In addition, the investigators found an influence of subcutaneous fat thickness on the echo intensity of the muscle that was independent from the amount of intramuscular fat present. Previous studies have discovered that the thickness of subcutaneous fat adjacent to the muscle can distort the reflection and/or absorption of ultrasound waves upon the tissue of interest, which can increase the difficulty of visualizing deeper tissues (Pillen & van Alfren, 2011; Nijboer-Oosterveld, van Alfren, & Pillen, 2011; Wattjes, Kley, & Fischer, 2010). Pillen and van Alfren (2011) stated that an ultrasound wave can be attenuated when the beam encounters different types of tissues. Young and colleagues (2015) hypothesized that participants with greater than approximately 15% intramuscular fat may experience a reflection and absorption of the ultrasound beam that is affected in a non-systematic way. Therefore, the use of ultrasonography may be limited to more superficial tissues of interest.

The correlation between echo intensity values obtained from the ultrasound and percent intramuscular fat obtained from the magnetic resonance images improved when a correction factor for subcutaneous adipose tissue thickness was applied, further demonstrating that subcutaneous fat may distort image quality. The investigators also noted that higher correlations were found when examining the corrected echo intensity and percent intramuscular fat for each muscle individually, as compared to examining all muscle groups as a whole. This shows that there is great variability in the echo intensity values obtained from different muscle groups, which is consistent with prior research (Caresio, Molinari, Emanuel, & Minetto, 2014; Pillen et al., 2009; Pillen & van Alfen, 2011). In addition, the differences in the correlation coefficients within the different types of imaging and between genders was consistent with previous research conducted by Arts and colleagues (2010). These researchers discovered that the mean echo intensity values obtained from the sternocleidomastoid, biceps brachialis, forearm flexor group, quadriceps femoris, and tibialis anterior muscles were all greater in all female age groups compared to their male counterparts in participants ranging from 15 – 80+ years old. In this study, echo intensity was also found to be significantly positively correlated with age, showing that echo intensity increases with increasing age (Arts et al., 2010).

In the present study, there was high reproducibility and reliability of the ultrasound technique and analysis performed on two different days and by different experimenters. However, limitations in the size of the ultrasound window may have accounted for measurement error, especially when the entire muscle could not be viewed in a single frame. There were also limitations in determining the exact amounts of adipose tissue within magnetic resonance images of the muscles because the identification of pure muscle, pure fat, and pure connective tissue was based on an investigator's subjective measures. Overall, the amount of intramuscular fat assessed

via magnetic resonance imaging was related to the echo intensity of the rectus femoris, biceps femoris, tibialis anterior, and medial gastrocnemius in healthy males and females (Young, Jenkins, Zhao, & McCully, 2015).

Skeletal Muscle Echogenicity May Be Related to Skeletal Muscle Quality

Muscle echo intensity is assessed by averaging the brightness of each pixel of a defined region of interest on an ultrasound image (Jenkins et al., 2015; Pillen, 2010; Pillen and van Alfren, 2011; Scanlon et al., 2014). Recent interest has been brought to the use of echo intensity as a way to assess skeletal muscle quality, where a darker image with lower echogenicity may be indicative of better muscle quality due to lower amounts of intramuscular fibrous tissue and/or triglycerides (Fukumoto et al., 2012; Pillen, 2010; Pillen and van Alfren, 2011). However, muscle quality is a very subjective measure. For example, lower amounts of intramuscular fibrous tissue and triglycerides would probably be most beneficial for the general population as well as for strength and power athletes. In many strength and power sports, the main objective is to exert maximal force as quickly as possible. Skeletal muscle architecture greatly influences its function (Burkholder, Fingado, Baron, & Lieber, 1994). A greater muscle mass and greater physiological cross-sectional area is generally indicative of greater strength, force-producing capabilities, and faster speed of contraction (Burkholder, Fingado, Baron, & Lieber, 1994; Fukunaga et al., 2001; Mayhew, Piper, & Ware, 1993; Moreau, Simpson, Teefey, & Damiano, 2010; Young, Stokes, & Crowe, 1985). Possessing a greater muscle mass would be advantageous for strength and power sport athletes because these sports emphasize short bouts of extremely high-intensity exercise, requiring greater muscle mass and force (Kraemer, 1997; Mayhew,

Piper, & Ware, 1993). Echo intensity has been used in a limited number of training studies to assess muscle quality before and after a training program. Studies done on various populations have demonstrated that prolonged resistance training results in an increase in muscle thickness and cross-sectional area which is primarily due to muscle hypertrophy (Charette et al., 1991; Ikai and Fukunaga, 1970; McCall, Byrnes, Dickinson, Pattany, & Fleck, 1996; Narici, Roi, Landoni, Minettu, & Cerretelli, 1989; Scanlon et al., 2014; Seynnes, de Boer, & Narici, 2007). Further studies examining the echo intensity of skeletal muscle and performance have shown that echogenicity is negatively correlated with strength and other performance measures, and that higher echo intensity values are related to poorer performance (Cadore et al., 2012; Fukumoto et al., 2012; Mangine et al., 2014a; Mangine et al., 2014b; Mangine et al., 2014c; Scanlon et al., 2014; Watanbe et al., 2013; Young, Jenkins, Zhao, & McCully, 2015). However, most research examining skeletal muscle echo intensity and performance have been restricted to the examination of clinical and elderly populations who have an increased levels of fibrosis. Few studies have been performed specifically on strength and power athletes that investigate the relationship between muscle echo intensity and performance (Mangine et al., 2014a; Mangine et al., 2014b; Mangine et al., 2014c). Nonetheless, a lower skeletal muscle echo intensity would presumably be advantageous for strength and power athletes.

On the other hand, it is also apparent that certain populations may actually benefit from greater amounts of intramuscular or fat fibrous tissue within certain muscles. Previous research has shown that stores of intramuscular triglycerides increase after prolonged aerobic training due to an increased reliance on fat oxidation for energy during endurance exercise (Morgan, Short, & Cobb, 1969; Schrauwen-Hinderling et al., 2003; van Loon & Goodpaster, 2005). In endurance athletes, a higher level of intramuscular fat would most likely result in a higher intramuscular

echo intensity, and therefore a 'lower' muscle quality. However, the adaptation of increased storage of intramuscular fat in response to chronic endurance exercise is actually beneficial for these athletes and would instead represent a 'higher' muscle quality. In contrast, recent research has found that many trained cyclists possess a lower muscle echo intensity in the rectus femoris muscle, which was highly correlated with intramuscular glycogen content quantified via muscle biopsy (Hill and Millan, 2015). Maximizing intramuscular glycogen content is essential for exercise performance, especially for athletes who compete in high-intensity activities for a long duration. Decreased levels of intramuscular glycogen has been associated with fatigue, hypoglycemia, decreased performance, decreased muscle contractility, and decreased calcium release (Bangsbo, Graham, Kiens, & Saltin; 1992; Chin and Allen; 1997; Hargreaves, Meredith, & Jennings, 1992). It has also been widely accepted that a greater intramuscular glycogen content is associated with increased water retention (MacKay & Bergman, 1931; Olsson & Saltin, 1970). In muscles that have greater glycogen and accompanying water content, echo intensity values of the muscle will likely be decreased (Hill and Millan, 2015). This occurs because sound waves emitted by an ultrasound probe travel easily through water, so few waves are reflected back to the transducer, producing a darker image (Pillen, 2010). Therefore, in endurance-trained athletes who possess greater glycogen content than their sedentary counterparts, one may expect to see lower values of echo intensity (Hill and Millan, 2015). However, immediately after an exhaustive exercise bout that depletes intramuscular glycogen stores, intramuscular echo intensity may be increased due to decreased glycogen and decreased water within the muscle. Jajtner and colleagues (2015) demonstrated an increased echo intensity in the rectus femoris and vastus lateralis muscles from pre-to post-exercise following a lower-body resistance training protocol in resistance-trained men. These researchers also observed

significant increases in cross-sectional area in the rectus femoris and vastus lateralis muscles immediately after exercise, which was probably the result of local swelling and other factors (Jajtner et al., 2015). After a period of 30 minutes, the cross-sectional area and echo intensity of both the rectus femoris and vastus lateralis muscles began to decrease towards pre-values, which could be indicative of glycogen replenishment after exercise (Jajtner et al., 2015). Hill and Millan (2015) demonstrated similar findings, i.e., increased echo intensity compared to pre-values in trained cyclists following a bout of exhaustive endurance exercise. These results indicate that glycogen storage may have a profound effect on skeletal muscle echogenicity.

The balance between increased intramuscular triglycerides and increased intramuscular glycogen that occurs with endurance training will alter the way that muscles look on an ultrasound by producing either a brighter image or a darker image, respectively (Abernethy, Thayer, & Taylor, 1990). However, most endurance athletes experience both of these skeletal muscle adaptations simultaneously. Research examining which adaptation predominates and has the greatest effect on muscle echogenicity is non-existent up to this point. Regardless, the following studies examine the use of echo intensity via ultrasonography as a way to assess muscle quality.

Echo Intensity and its Effects on Muscular Strength and Cardiovascular Performance

Skeletal muscle echo intensity has been shown to be related to strength and cardiovascular performance, where lower echo intensity values have been correlated with increased muscular strength and cardiovascular performance, particularly in the elderly (Cadore et al., 2012; Fukumoto et al., 2012; Mangine et al., 2014a; Mangine et al., 2014b; Mangine et al.,

2014c; Scanlon et al., 2014; Strasser, Draskovits, Praschak, Quittan, & Graf, 2013; Watanbe et al., 2013; Wilhelm et al., 2014). The following studies assess the relationships between echo intensity, muscular strength, and cardiovascular performance.

Cadore, E.L., Izquierdo, M., Conceição, M., Radelli, R., Pinto, R.S., Baroni, B.M., Vaz, M.A., Alberton, C.L., Pinto, S.S., Cunha, G., Bottaro, M., & Kruel, L.F.M., 2012.

Echo Intensity is Associated with Skeletal Muscle Power and Cardiovascular Performance in Elderly Men.

Cadore and colleagues (2012) examined the relationship between the echo intensity of the rectus femoris muscle and skeletal muscle strength and power in 31 elderly males (age: 64.7 ± 4.1 years). Researchers used a 7.5-Megahertz brightness-mode ultrasound to assess the echo intensity of a transverse still image of the rectus femoris as well as the muscle thickness of the rectus femoris, vastus lateralis, vastus intermedius, and vastus medialis. Each participant was instructed to abstain from exercise for at least 72 hours prior to the study. The echo intensity of the rectus femoris was assessed after 15 minutes of resting in a supine position and was determined using the standard histogram function in an image analysis software (ImageJ, National Institutes of Health, USA, version 1.37). Subjects then performed an incremental test on a cycle ergometer to measure VO_2 max, first and second ventilatory thresholds, and workloads performed at each threshold. The subjects also performed isometric and isokinetic knee extensions on an isokinetic dynamometer to obtain isometric peak torque and isokinetic peak torque at different velocities.

The results of the study indicated that the echo intensity of the rectus femoris muscle was significantly negatively correlated with isometric peak torque and isokinetic peak torque at $60^\circ/s$,

180°/s, and 360°/s (correlation values ranged from $r = -0.48$ to $r = -0.64$; $p < 0.05$). In addition, there were significant negative correlations between the echo intensity of the rectus femoris and the workloads at the first and second ventilatory thresholds ($r = -0.46$; $p = 0.013$, and $r = -0.50$; $p = 0.009$, respectively). Significant positive correlations were found between muscle thickness values of the rectus femoris, vastus intermedius, and vastus medialis, muscles and the values for isometric and isokinetic peak torque at all speeds (correlation values ranged from $r = 0.42$ to $r = 0.63$; all $p < 0.05$), however correlation coefficients were greatest at higher velocities (180°/s and 360°/s). These results indicate that individuals in this study that possessed larger amounts of muscle mass and lower echo intensity values tended to produce greater force than those with smaller muscle mass and greater echo intensity values. In addition, individuals with ‘better’ muscle quality, i.e., lower echo intensity, were able to perform more work at ventilatory threshold than those who had ‘lower’ muscle quality, indicating that muscle quality and muscle size both contribute to muscle strength. The authors suggest that a lower amount of connective tissue and intramuscular fat may actually increase cardiorespiratory capacity in older populations. This hypothesis is thought to occur because with aging, the number of capillaries within skeletal muscle decreases and the number of capillaries in isolation increases. Sufficient capillarization is essential for cardiovascular performance, and a greater amount of intramuscular adipose and connective tissue may impair cardiovascular function by restricting blood flow. In contrast, prolonged endurance training results in an increase in intramuscular fat, but also an increase in capillarization (Blomqvist & Saltin, 1983; Kraemer, 1997; Morgan, Short, & Cobb, 1969; Schaible & Schever, 1981; Schrauwen-Hinderling et al., 2003; van Loon & Goodpaster, 2005). This increase in capillarization maintains endurance capacity by allowing sufficient blood flow throughout the muscle. Overall, this study shows how echo intensity is a useful tool in the

assessment of muscle quality, muscle strength, and cardiovascular performance in older individuals (Cadore et al., 2012).

Fukumoto, Y., Ikezoe, T., Yamada, Y., Tuskagoshi, R., Nakamura, M., Mori, N., Kimura, M., & Ichihashi, N., 2012.

Skeletal Muscle Quality Assessed from Echo Intensity is Associated with Muscle Strength of Middle-Aged and Elderly Persons.

The purpose of this study was to examine if skeletal muscle echo intensity is associated with muscle strength independently of muscle thickness. A secondary purpose was to determine the relationship between echo intensity and body composition. Ninety-two healthy women (age: 70.4 ± 6.6 years; 51-87 years). The researchers used an 8-Megahertz brightness-mode ultrasound to obtain transverse still images of the quadriceps femoris of the right leg. Muscle thickness of the quadriceps femoris was defined as the distance between the upper boundary of the femur and the lower boundary of the fascia surrounding the rectus femoris. This measurement included both the rectus femoris and vastus intermedius muscles. Echo intensity was evaluated using a standard histogram function in an image analysis software (Adobe Photoshop Elements, Adobe Systems Inc., San Jose, CA, USA), but only included the rectus femoris muscle and did not include the vastus intermedius. Subcutaneous fat thickness was also assessed in each individual using an ultrasound, and was defined as the distance between the upper boundary of the fascia surrounding the rectus femoris and the line separating the dermis from the subcutaneous fat. Body fat percentage was assessed via bioelectrical impedance analysis. In addition, maximal isometric strength of the lower extremity was measured at 60° knee flexion using an isometric dynamometer.

To assess test-retest reliability, two separate images from seven female subjects (age: 60.3 ± 6.9 years) were taken on two different days. A high intra-class correlation existed between each of the two images captured for muscle thickness ($ICC_{1,1} = 0.90$), subcutaneous fat thickness ($ICC_{1,1} = 0.96$) and echo intensity ($ICC_{1,1} = 0.91$), showing that the reliability of each of these measurements was high.

Additionally, there was a significant positive correlation between muscle thickness and muscle strength in the subjects ($r = 0.47, p < 0.001$), revealing that a thicker muscle was associated with greater amounts of strength. There was also a significant negative correlation between muscle thickness and age ($r = -0.40, p < 0.001$), which may have been a result of sarcopenia. There was no correlation between muscle thickness and fat thickness. In addition, there was a significant negative correlation between the echo intensity of the rectus femoris and muscle thickness ($r = -0.33, p < 0.001$) and muscle strength ($r = -0.40, p < 0.001$), showing that a 'better' quality muscle was associated with a thicker and stronger muscle. Echo intensity was positively correlated with age ($r = 0.34, p < 0.001$), which was probably due to the infiltration of fat and fibrous tissue that is associated with aging (Arts et al., 2010). However, echo intensity was not correlated with subcutaneous fat thickness.

The researchers then performed further partial correlation analyses on echo intensity using age and muscle thickness as covariates. When this was performed, echo intensity was still significantly negatively correlated with muscle strength, showing that both muscle size and muscle quality contribute independently to muscle strength. However, the echo intensity values of the quadriceps femoris were not correlated to subcutaneous adipose tissue thickness, body mass index, or percent body fat. These results suggest that measurements of subcutaneous and

visceral fat may not be related to the degree of fat within certain muscles, and that one cannot assume a lower muscle quality with increased amounts of subcutaneous fat. In addition, because the values of fat thickness, body mass index, and percent body fat were not correlated with muscle strength, it is evident that echo intensity, representing the amount of fat that exists within a muscle, is a more accurate indicator of muscle strength than overall body fat (Fukumoto et al., 2012).

Watanabe, Y., Yamada, Y., Fukumoto, Y., Ishihara, T., Yokoyama, K., Yoshida, T., Miyake, M., Yamagata, E., & Kimura, M., 2012.

Echo Intensity Obtained from Ultrasonography Images Reflecting Muscle Strength in Elderly Men.

Watanabe and colleagues (2012) aimed to determine whether muscle quality, as assessed by measuring muscle echo intensity, or muscle size, as assessed by measuring muscle thickness, corresponded to strength in elderly men. In this study, 184 healthy, elderly men (aged: 65 – 91 years) were subjected to a 5-10-Megahertz, brightness-mode ultrasound, which was used to examine the muscle thickness and echo intensity of the right thigh via transverse still images. One major limitation of this study was that each of the participants were standing upright when the ultrasound images were captured, so the legs were not completely relaxed and fluid shifts were not permitted (Ahtiainen et al., 2010; Esformes, Narici, & Maganaris, 2002; Fukumoto et al., 2012; Lixandrão et al., 2014; Reeves, Maganaris, & Narici, 2004; Scanlon et al., 2014; Wells et al., 2014). The researchers defined the muscle thickness of the anterior compartment of the thigh as the sum of the thicknesses of the vastus intermedius and rectus femoris muscles, as previously defined by Fukumoto and colleagues (2012). Echo intensity was evaluated using a

standard histogram function in an image analysis software (Adobe Photoshop Elements, Adobe Systems Inc., San Jose, CA, USA), and included as much of the rectus femoris muscle as possible, without including the surrounding fascia. The researchers also examined subcutaneous adipose tissue thickness, defined as the distance between the fascia of the rectus femoris muscle and the dermis, as previously defined by Fukumoto and colleagues (2012). In addition, muscle strength was assessed by evaluating maximum isometric knee extension torque at an angle of 90° on a custom dynamometer chair.

To assess test-retest reliability of the echo intensity measurements, two separate images from 12 subjects (age: 74.2 ± 4.7 years) were taken on two different days. The intra-class correlation between each of the two images captured for echo intensity was $ICC = 0.9635$, and the coefficient of variation was $CV = 4.2\%$, showing that the reliability of each of these measurements were high.

The investigators discovered that there was a significant positive correlation between muscle thickness and muscle strength ($r = 0.411, p < 0.001$), revealing that a thicker muscle was related to greater strength. In addition, there was a significant negative correlation between muscle thickness and age ($r = -0.326, p < 0.001$) and significant positive correlations between echo intensity and age ($r = 0.280, p < 0.001$), which could be a result of decreased muscle mass via sarcopenia. No significant correlation existed between muscle thickness and subcutaneous adipose tissue thickness, however there was a significant positive correlation between echo intensity and subcutaneous adipose tissue thickness ($r = 0.240, p = 0.001$), showing that lower quality muscle was associated with greater subcutaneous fat. Fukumoto et al. (2012) found

conflicting results regarding echo intensity and fat thickness in a similar population, where no correlation existed between echo intensity and fat thickness in older adults.

Muscle thickness and echo intensity were shown to contribute independently to muscle strength, as demonstrated through multivariate regression analysis. The researchers then performed further partial correlation analyses on echo intensity and muscle thickness using age, fat thickness, height, and weight as covariates. Echo intensity was still significantly negatively correlated with muscle strength ($p < 0.001$), and muscle thickness was still positively correlated with muscle strength ($p = 0.004$). The results of this study show that echo intensity was related to muscle strength independently of muscle thickness and that echo intensity is safe and easy way to assess muscle quality in older individuals (Watanabe et al., 2012).

Strasser, E.M., Draskovits, T., Praschak, M., Quittan, M., & Graf, A., 2013.

Association Between Ultrasound Measurements of Muscle Thickness, Pennation Angle, and Skeletal Muscle Strength in the Elderly.

Strasser and colleagues (2012) aimed to examine the relationship between muscle thickness and echo intensity of the quadriceps femoris muscles and maximum voluntary isometric contraction force in younger and older subjects. With aging, decreases in muscle strength and performance occur due to decreases in muscle mass and infiltration of fibrous and adipose tissue (Cruz-Jentoft et al., 2010). This change in muscle strength and performance likely has an effect on muscle architecture. In this study, 26 healthy young men and women (age: 24.2 ± 3.7 years; 18-35 years) and 26 healthy elderly men and women (age: 67.8 ± 4.8 ; 60-80 years) volunteered to participate. One leg of each participant was randomly assigned for investigation,

which was performed on two separate days. A 7.25-Megahertz brightness-mode ultrasound was used to capture both longitudinal and transverse still-images of each of the four quadriceps femoris muscles. All images were taken at the midpoint between the greater trochanter and the lateral knee joint space while the participants were lying in a supine position. However, the authors do not mention if the participants were able to rest prior to ultrasound examination to allow for fluid shifts to occur. Muscle thickness, defined as the widest distance between the superficial and deep fascia, of each individual muscle in the transverse plane was analyzed using ImageJ (National Institutes of Health, USA). Echo intensity of each individual muscle was also determined using ImageJ, however longitudinal images of each individual muscle were used. Single-leg maximum voluntary isometric contraction force during knee extension was also measured on each of the testing days, using the same leg that was used for ultrasound analysis.

The results of this investigation revealed that there were no significant differences in the amount of time spent participating in physical activity each week between the older and younger subjects. Despite this, the subjects in the older group had significantly weaker maximum voluntary isometric contraction force than those in the younger group (352.1 ± 114.2 Newtons (N) versus 510.8 ± 178.4 N, respectively, $p < 0.001$). Intra-class correlations between muscle thickness values for both groups examining each muscle between different days, different experimenters, different images, and within the same subject were all calculated to be high (ICCs ranged from 0.86 to 0.97). On the other hand, intra-class correlations between echo intensity values revealed differences between each group. The echo intensity values of the younger group had higher intra-class correlations (ranging from ICC = 0.57 to 0.65), whereas the echo intensity values of the older group had lower intra-class correlations (ranging from ICC = 0.20 to 0.31), indicating less reliability in older subjects. Systematic differences in echo intensity values were

found in the vastus intermedius in both the elderly and younger groups and in the vastus medialis in the elderly group. Additionally, the thickness of each of the quadriceps femoris muscles were significantly smaller in older individuals compared to younger individuals ($p < 0.05$), with the greatest difference occurring in the rectus femoris. The muscle thickness of each muscle was significantly positively correlated with maximal voluntary isometric contraction force in both groups ($p < 0.00001$). The echo intensities of each of the quadriceps femoris muscles were significantly greater in the older group compared to the younger group ($p < 0.01$), with the greatest difference in values between testing days occurring in the rectus femoris and vastus intermedius muscles. The vastus intermedius had the lowest echogenicity in both groups, whereas the rectus femoris had the highest echogenicity in both groups. However, the correlation between muscle echo intensity and maximal voluntary isometric contraction force revealed that there were no significant correlations between the two in the older group. In contrast, the younger group displayed significant moderate negative correlations (ranging from $r = -0.47$ to -0.64 , $p < 0.05$) between all muscles of the quadriceps femoris and maximal voluntary isometric contraction force, showing that lower echo intensity was related to increased muscle strength, but only in younger individuals.

The results of this study demonstrate that there were systematic differences in echo intensity values obtained in younger and older individuals. The discrepancies between these values may exist because the participants did not lay supine for a period of time prior to ultrasound examination. The correlation coefficients between echogenicity of the rectus femoris and maximal voluntary isometric contraction force in older individuals gathered in this investigation were lower than those in obtained other investigations (Cadore et al., 2012; Fukumoto et al., 2012). Discrepancies between the correlation coefficients found in these studies

may be due to the ultrasound scanning plane that was used in the investigation. Cadore et al. (2012) and Fukumoto et al. (2012) used transverse scans of the rectus femoris to determine echo intensity, whereas the current study used longitudinal scans. The echogenicity of skeletal muscle is highly affected by ultrasound positioning, so differences in scanning planes may affect echo intensity values due to differences in muscle architecture when viewing the muscle in a different plane (Pillen, 2010). In the longitudinal plane of the quadriceps femoris muscles, each individual muscle fascicle and surrounding perimysium can be visualized (Pillen, 2010). In the transverse plane, the individual fascicles of the quadriceps femoris cannot be viewed, but cross-sections of connective and adipose tissue can be seen. Ultrasound probe orientation would therefore probably have a profound effect on the echo intensity of the underlying muscle. Additional research should be investigated on this topic, which will be discussed further in this review of literature (Strasser, Draskovits, Praschak, Quittan, & Graf, 2013).

Wilhelm, E.N., Rech, A., Minozzo, F., Radaelli, R., Botton, C.E., Pinto, R.S., 2014.

Relationship Between Quadriceps Femoris Echo Intensity, Muscle Power, and Functional Capacity of Older Men.

The purpose of this study was to determine the relationship between the echo intensity of the quadriceps femoris muscles and muscle strength and power in elderly males. Fifty healthy, older men (age: 66.1 ± 4.5 years) participated in this study. Testing was completed on three separate days, with a least 72 hours between each testing day. Four transverse ultrasound still-images of each of the right quadriceps femoris muscles were obtained using a 9-Megahertz, brightness-mode ultrasound, taken at a depth of 70 millimeters and set at a gain of 90 decibels. Images of the vastus lateralis, rectus femoris, and vastus intermedius muscles were captured at

the midpoint of the distance between the lateral condyle of the femur and the greater trochanter. Images of the vastus medialis were captured at 30% of the aforementioned length. Echo intensity of each muscle was calculated using the standard histogram function on an image analysis software (ImageJ, National Institute of Health, USA, version 1.42q). The thickness of each muscle was also calculated. The echo intensity of all four quadriceps femoris muscles were analyzed and quantified as the mean of the four individual muscles. The whole quadriceps femoris muscle thickness was also measured, which equaled the sum of the muscle thickness values for all four individual muscles. In addition, unilateral knee extension one-repetition maximum, vertical jump power, isometric peak torque, rate of torque development, knee extension power, and a 30-second sit-to-stand test were assessed on each participant as well.

The results of this investigation revealed that significant negative correlations existed between the echo intensities of each individual muscle and all power variables, however the correlations ranged from weak to moderate ($r = -0.285$ to -0.725 , $p \leq 0.05$). There were also significant negative correlations between the echo intensity of all of the quadriceps femoris muscles and all power variables, but these correlations ranged from moderate to strong ($r = -0.411$ to -0.746 , $p \leq 0.05$). Total quadriceps femoris muscle thickness was significantly positively correlated with all power measurements ($p < 0.05$). Additionally, moderate negative correlations existed between all echo intensity measurements, isometric peak torque, and knee extension one-repetition maximum (correlation coefficients ranged from $r = -0.460$ to -0.657 , $p \leq 0.05$). Echo intensity of the vastus lateralis, vastus medialis, and quadriceps femoris had moderate to strong significant negative correlations with rate of torque development, whereas the correlation between the echo intensities of the vastus intermedius and rectus femoris with rate of torque development only reached significance after longer periods of time. Furthermore,

significant negative correlations existed between the maximal number of repetitions completed in the 30-second sit to stand and the echo intensity of the quadriceps femoris and each individual muscle ($p \leq 0.05$). Quadriceps femoris muscle thickness was significantly positively correlated with the maximal number of repetitions completed in the 30-second sit to stand ($p < 0.05$).

These results demonstrate that individuals who possessed better muscle quality, i.e., had lower echo intensity values tended to have greater strength and power values. The echo intensities of the four quadriceps femoris muscles, the vastus lateralis, and vastus medialis had the strongest negative correlations with all strength and power variables. This could indicate that echo intensity of these specific muscles may be most accurate when predicting lower body strength and power performance in elderly males. These findings align with the data collected by other researchers examining echo intensity and performance in an older population (Cadore et al., 2012; Fukumoto et al., 2012). However, these findings contradict the results that Strasser et al. (2013) discovered in an elderly population, which could be due to the differences in ultrasound probe alignment. Overall, these researchers discovered that lower echo intensity values were indicative of greater muscle strength and power in elderly males (Wilhelm et al., 2014).

Scanlon, T.C., Fragala, M.S., Stout, J.R., Emerson, N.S., Beyer, K.S., Oliveira, L.P., & Hoffman, J.R., 2014.

Muscle Architecture and Strength: Adaptations to Short-Term Resistance Training in Older Adults.

Scanlon and colleagues (2014) examined the changes in muscle morphology and muscle architecture after six weeks of resistance training in elderly individuals. Twenty-six healthy elderly males and females (age: > 60 years) were assigned to either a resistance training group or control group. The resistance training group completed a six-week total-body resistance training program consisting of two workouts per week, with progression and manipulation of acute program variables throughout the duration of the study. The control group maintained their normal daily activities. In general, subjects in the resistance training group experienced workouts that consisted of 2-4 sets of 8-12 repetitions of about 6-10 exercises at an estimated 70-85% of their maximal intensity. At the start of the study, each subject was instructed to refrain from physical activity for at least 72 hours prior to each testing session. After resting in a supine position for 15 minutes, a 12-Megahertz, brightness-mode ultrasound was used to capture measurements of muscle thickness, cross-sectional area, and echo intensity of the vastus lateralis and rectus femoris in the dominant leg of all subjects. The gain of the ultrasound was set to 50 decibels and the image depth was set to 5 centimeters. Extended field-of view panoramic ultrasonography was used to capture three images of each muscle in the transverse plane. Images of the vastus lateralis were taken at 50% of the distance between the prominent point of the greater trochanter and the lateral condyle. Images of the rectus femoris were taken at 50% of the distance between the anteroinferior iliac spine and the proximal border of the patella. Three images were also captured in the same location as those previously mentioned but in the longitudinal plane. Cross-sectional area and echo intensity for were analyzed on each panoramic image using the polygon tracing tool on an image analysis software (ImageJ, National Institutes of Health, Bethesda, MD, version 1.45s) and included as much of the muscle as possible, without including the surrounding fascia. Muscle thickness was defined as the distance from the deep

aponeurosis to the superficial aponeurosis surrounding each muscle of interest and was also measured using the image analysis software. Intra-class correlations and standard errors of measurement were calculated for the rectus femoris cross-sectional area, muscle thickness, and echo intensity (ICC = 0.99, SEM = 0.46 centimeters²; ICC = 0.96, SEM = 0.11 centimeters; ICC = 0.91, SEM = 3.47 arbitrary units, respectively) and for the vastus lateralis cross-sectional area, muscle thickness, and echo intensity (ICC = 0.99, SEM = 1.26 centimeters; ICC = 0.89, SEM = 0.12 centimeters; ICC = 0.93, SEM = 5.1 arbitrary units, respectively), all of which were found to be high. In addition, knee extensor strength was assessed via maximal voluntary isotonic contraction of 10 repetitions or less.

The results of the study showed that there were significant improvements in muscle strength in the resistance training group throughout the duration of the study as measured by a one-repetition maximum knee extension ($p \leq 0.01$). No improvements in strength existed in the control group ($p > 0.05$). In addition, there was an increase in muscle quality, which was represented as relative strength, in the resistance training group. This was assessed by dividing the one-repetition maximum on the knee extension by lean thigh mass assessed via dual x-ray absorptiometry. There was also an increase in muscle quality, which was represented as strength relative to echo intensity, in the resistance training group. This was assessed by dividing the one-repetition maximum on the knee extension by the echo intensity of the vastus lateralis and the rectus femoris. There were no differences in cross-sectional area or muscle thickness of the rectus femoris from the beginning to the end of the study in either group ($p > 0.05$). Additionally, there were no changes in muscle thickness in the vastus lateralis for either the resistance training or the control group, and there were no significant changes in the echo intensity of the vastus lateralis in the resistance training group. However, there was a significant group by time

interaction for the resistance training group in the cross-sectional area of the vastus lateralis ($p < 0.05$). The cross-sectional area of the vastus lateralis significantly increased by an average of 7.4% in the resistance training group, which was not seen in the control group ($p < 0.05$). In addition, at baseline, the echo intensities of the rectus femoris in females were significantly higher than those seen in males (87.6 ± 5.8 arbitrary units in women; 78.4 ± 12.9 arbitrary units in men). A *post hoc* analysis revealed a gender interaction, where the echo intensity of the vastus lateralis decreased in females after training ($p = 0.014$), but this was not seen in males. The authors suggest that this may be due to gender differences in body composition or due to the influence of hormones on physiological changes with training. There was a main effect for time observed in the echo intensity of the rectus femoris in the control group, which corresponded to a significant decrease in echo intensity of 4.4% ($p < 0.05$), which could not be explained.

These results show that six weeks of resistance training may be sufficient to increase muscle size but may not be sufficient enough to change muscle quality. Also, increases in cross-sectional area of the vastus lateralis in the resistance training group were detected via ultrasonography but were not detected by dual x-ray absorptiometry, which may indicate that the use of ultrasonography is a more sensitive way to assess changes in muscle architecture than the use of dual x-ray absorptiometry. In addition, since increases in cross-sectional area were seen only in the vastus lateralis, it is possible that it takes longer than six weeks to see structural adaptations in the rectus femoris, or that the rectus femoris was not a key contributor to knee extension and was not activated to a great enough extent to adapt to the training. There were no changes in muscle thickness observed in either group, which may indicate that it takes longer than six weeks to induce changes in muscle diameter (Bemben, 2002). The results of this study show that six weeks of resistance training was sufficient enough to induce changes in muscle

architecture, muscle strength, and relative strength in elderly individuals, however it was insufficient at inducing changes in echo intensity in males (Scanlon et al., 2014).

Mangine, G.T., Fukuda, D.H., La Monica, M.B., Gonzalez, A.M., Wells, A.J., Townsend, J.R., Jajtner, A.R., Fragala, M.S., Stout, J.R., & Hoffman, J.R., 2014.

Influence of Gender and Muscle Architecture Asymmetry on Jump and Sprint Performance.

The purpose of this investigation was to determine the effect of gender and muscle architecture on jump and sprint performance in 28 healthy males ($n = 14$, age: 24.3 ± 2.2 years) and females ($n = 14$, age: 21.5 ± 1.7 years). Measures of muscle architecture were obtained using a 12-Megahertz brightness-mode ultrasound set at a depth of 5 centimeters and a gain of 50 decibels. Cross-sectional area, echo intensity, and muscle thickness of the rectus femoris and vastus lateralis in both limbs of each subject were assessed after laying supine for a period of 15 minutes. Cross-sectional area and echo intensity measurements were assessed in the transverse plane using panoramic imaging at 50% of the distance between the anterior-inferior iliac to the proximal border of the patella and at 50% of the distance between the lateral condyle and the most prominent point of the greater trochanter, respectively. Measures of muscle thickness for both muscles were assessed in the longitudinal plane via single still-images. Three images of each type were captured to assess reliability. All image analysis was completed using ImageJ (National Institutes of Health, Bethesda, MD, version 1.45s). Additionally, vertical jump height and peak and mean vertical jump power were assessed in each individual using a Tendo™ Weightlifting Analyzer (Tendo Sports Machines, Trencin, Slovakia). Thirty-meter sprint time from a three-point stance was also measured in each subject.

The results of the study show that there were significant gender differences between measures of rectus femoris muscle thickness in both legs, cross-sectional area in both legs, and echo intensity in the non-dominant leg between men and women ($p < 0.05$). In the vastus lateralis, significant gender differences existed between measures of cross-sectional area and echo intensity in both limbs. There were also significant bilateral differences between cross-sectional area of the vastus lateralis in men. No significant correlations existed between muscle thickness, cross-sectional area, or echo intensity of either the rectus femoris or vastus lateralis in either leg in males or females. However, peak vertical jump power was significantly correlated with non-dominant leg muscle thickness of the rectus femoris in men ($r = 0.66, p < 0.01$), cross-sectional area of the vastus lateralis in the dominant limb in men ($r = 0.64, p < 0.01$), and muscle thickness in the vastus lateralis in the non-dominant limb in men ($r = 0.55, p = 0.04$). Peak vertical jump power was also significantly correlated with muscle thickness of the non-dominant vastus lateralis muscle in women ($r = 0.81, p < 0.001$) and the bilateral difference between muscle thickness in the vastus lateralis in women ($r = -0.73, p < 0.001$). Mean vertical jump power was significantly correlated with muscle thickness in the non-dominant rectus femoris muscle in males ($r = 0.48, p = 0.04$), cross-sectional area of the non-dominant rectus femoris muscle in females ($r = 0.59, p = 0.03$), bilateral differences between muscle thickness in the vastus lateralis in women ($r = -0.76, p < 0.001$), cross-sectional area of the non-dominant rectus femoris in women ($r = 0.59, p = 0.03$), and the bilateral differences between both the vastus lateralis and rectus femoris echo intensities in women ($r = 0.54, p = 0.05$; $r = 0.55, p = 0.04$, respectively).

These results show that males possess significantly greater muscle mass and lower echo intensity values than females, which is known to affect the ability to generate force (Cadore et

al., 2012). In males, muscle architecture was shown to be a primary determinant of performance. In women, asymmetry in muscle size between opposing limbs was shown to negatively affect jumping performance, whereas asymmetry in muscle echo intensity (i.e. muscle quality) was shown to positively affect jumping performance. In conclusion, bilateral differences in muscle architecture and muscle quality may help some populations, while hindering others (Mangine et al., 2014a).

Skeletal Muscle Echo Intensity May be Related to Anaerobic Sports Performance

The previous studies have discussed the relationship between skeletal muscle echo intensity and strength measures, particularly in an elderly population. Examination of the echo intensity of skeletal muscle in athletes is sparse due to the use of echogenicity as a way to assess pathological conditions and muscle quality in older populations. However, some recent studies have been conducted investigating the echogenicity of skeletal muscles in an athletic population, which will be discussed in the following section (Jajtner et al., 2014; Mangine et al., 2014c; Melvin et al., 2014). In addition to these studies, an investigation conducted by Ivey and colleagues (2000) discovered significant decreases in echo intensity in young women following a unilateral resistance training program for 9 weeks. The following studies aim to investigate the relationship between echo intensity and performance in athletes.

Mangine, G.T., Hoffman, J.R., Gonzalez, A.M., Jajtner, A.R., Scanlon, T., Rogowski, J.P., Wells, A.J., Fragala, M.S., & Stout, J.R., 2014.

Bilateral Differences in Muscle Architecture and Increased Rate of Injury in National Basketball Association Players.

An investigation by Mangine et al. (2014c) explored the relationship between bilateral differences in echo intensity within the rectus femoris and vastus lateralis muscles and injury rate in nine professional National Basketball Association players (age: 23.5 ± 2.6 years). In this study, a 12-Megahertz, brightness-mode ultrasound, set at a depth of 5 centimeters and a gain of 50 decibels, was used to measure cross-sectional area, echo intensity, and muscle thickness of the rectus femoris and vastus lateralis in both limbs. After laying in a supine position for a period of 15 minutes, measures of cross-sectional area and echo intensity of the rectus femoris were assessed in the transverse plane via panoramic imaging captured in Logiqview™. Images were captured at 50% of the distance between the anterior-inferior iliac spine to the proximal border of the patella. Measures of cross-sectional area and echo intensity for the vastus lateralis were assessed in the transverse plane via panoramic imaging at 50% of the distance between the lateral condyle and the most prominent point of the greater trochanter. Measures of muscle thickness for both muscles were assessed in the longitudinal plane via single still-images. Three images of each type were captured to assess intra-experimenter reliability. All images were analyzed using ImageJ (National Institutes of Health, Bethesda, MD, version 1.45s). Bilateral and unilateral vertical jump power of each subject were also assessed using a power output unit (Tendo Sports Machines, Trencin, Slovak Republic).

Intra-class correlations between cross-sectional area measurements for the vastus lateralis and rectus femoris were reported to be high (ICC = 0.99 and 0.99, respectively). Intra-class correlations between muscle thickness measurements for the vastus lateralis and rectus femoris were also reported to be high (ICC = 0.89 and 0.96, respectively). Intra-class correlations

between echo intensity measurements for the vastus lateralis and rectus femoris were reported to be high as well (ICC = 0.93 and 0.91, respectively). The amount of games that the players missed per season was moderately correlated to the bilateral difference in the cross-sectional area of the rectus femoris ($7.8\% \pm 6.4$ difference, $r = 0.657$, $p = 0.05$) and weakly correlated to the bilateral difference in the cross-sectional area of the vastus lateralis ($6.2\% \pm 4.8$ difference, $r = 0.521$, $p = 0.15$). The mean difference in muscle thickness between each leg in the rectus femoris and vastus lateralis were $6.2\% \pm 5.1$ and $7.9\% \pm 8.9$, respectively. The mean difference in echo intensity between each leg in the rectus femoris and vastus lateralis were $7.9\% \pm 4.0$ and $5.4\% \pm 3.5$, respectively. Players who were healthy (i.e. not injured) had smaller bilateral differences in muscle thickness, cross-sectional area, and echo intensity in the vastus lateralis and smaller bilateral differences in cross-sectional area and echo intensity in the rectus femoris compared to injured players, however these did not reach statistical significance ($p > 0.05$). In addition, there were smaller discrepancies between bilateral differences in vertical jump peak and average power in the uninjured group, however these measures also did not reach statistical significance ($p > 0.05$).

These results show that greater bilateral differences in muscle architecture and vertical jump power were associated with a greater rate of injury. Bilateral differences in muscle architecture and strength may result in unequal forces distributed upon the lower extremities, which can be caused by preferential use of one leg over the other or the demands of the specific sport (Mangine et al., 2014c).

Jajtner, A.R., Hoffman, J.R., Scanlon, T.C., Wells, A.J., Townsend, J.R., Beyer, K.S., Mangine, G.T., McCormack, W.P., Bohner, J.D., Fragala, M.S., & Stout, J.R., 2014.

Performance and Muscle Architecture Comparisons Between Starters and Nonstarters in National Collegiate Athletic Association Division I Women's Soccer.

The aim of this study was to determine if changes in muscle architecture of the vastus lateralis in women's collegiate Division I soccer players occur over a three-month competitive season. An additional purpose of the study was to assess muscle morphological characteristics in relation to speed, power, reaction time, and playing time, all of which are specific to the sport of soccer. In this study, 28 female collegiate Division I soccer players (age: 19.9 ± 1.1 years) completed a resistance training program during the in-season, twice weekly. Measurements of vastus lateralis and rectus femoris cross-sectional area and echo intensity were obtained using panoramic imaging in the transverse plane with a 12-Megahertz, brightness-mode ultrasound, set at a depth of 5 centimeters, a gain of 50, and dynamic range of 72. Muscle thickness measurements of the vastus lateralis and rectus femoris were obtained with the ultrasound probe oriented in the longitudinal plane, using a single still-image. Three images were captured at the each of the same locations previously described by Mangine and colleagues (2014c) and were analyzed using the same image analysis software. Additionally, a line drill measured for time and lower-body power were also assessed.

The results of this study revealed that there was high test-retest reliability between the three images of the rectus femoris with respect to muscle thickness, cross-sectional area, and echo intensity, as indicated by intra-class correlations and standard errors of measurement (muscle thickness: ICC = 0.96, SEM = 0.11 centimeters; cross-sectional area: ICC = 0.99, SEM = 0.46 centimeters²; echo intensity: ICC = 0.91, SEM = 3.47, respectively). Additionally, there was high test-retest reliability between the three images of the vastus lateralis with respect to muscle thickness, cross-sectional area, and echo intensity (muscle thickness: ICC = 0.89, SEM =

0.12 centimeters; cross-sectional area: ICC = 0.99, SEM = 1.26 centimeters²; echo intensity: ICC = 0.93, SEM = 5.10, respectively). Significant differences in playing time and age existed between starters and non-starters ($p > 0.001$ and $p = 0.028$, respectively). No significant interactions were discovered between vertical jump peak or mean power or line drill time between starters and non-starters during the season. Additionally, there were no significant changes in vertical jump peak or mean power or line drill time in either groups from the beginning to the end of the season, however magnitude-based inferences suggested that the starting players' fastest line drill time was likely negative, meaning that they became faster throughout the course of the season. An analysis of variance and pairwise comparisons revealed significant main effects for time with regard to the echo intensity of the rectus femoris ($p = 0.005$) and the cross-sectional area of the vastus lateralis ($p = 0.022$) throughout the course of the season in both groups. A decrease in echo intensity of the rectus femoris was found from the beginning (65.57 ± 1.50 arbitrary units) to the end (61.26 ± 1.59 arbitrary units) of the season, indicating likely improved muscle quality at the end of the season, however there was no significant difference between groups. The authors suggest that this decrease may be a result of the high utilization of the rectus femoris muscle during explosive knee extensions in the sport of soccer, which are especially important for kicking the ball. Also, an increase in cross-sectional area of the vastus lateralis was discovered from pre- (20.84 ± 3.58 centimeters²) to post-season (21.46 ± 3.66 centimeters²), which was likely due to increases in muscle size and strength. Furthermore, a likely negative difference was found in the muscle thickness of the vastus lateralis of the starting players, which the authors stated may not have large practical significance due to the simultaneous improvement in echo intensity. In conclusion, it is evident that muscle

quality may and size may change over the course of a competitive season in collegiate female soccer players (Jajtner et al., 2014).

Melvin, M.N., Smith-Ryan, A.E., Wingfield, H.L., Ryan, E.D., Trexler, E.T., & Roelofs, E.J., 2014.

Muscle Characteristics and Body Composition of NCAA Division I Football Players.

The aim of this investigation was to examine characteristics of muscle architecture and body composition in NCAA Division I football athletes. In this study, 69 football players (age: 20.0 ± 1.1 years) were investigated were separated into groups by position, race, grade level, and starter status. A 26-Hz, brightness-mode ultrasound set at a depth of 4.5 centimeters and a gain of 68 decibels was used to capture a panoramic image of the vastus lateralis muscle in each participant. If the depth of 4.5 centimeters was insufficient to capture the entire area of the vastus lateralis in one image, the depth was adjusted according to the individual's needs. Prior to examination, each subject was instructed to refrain from physical activity for at least two hours. Upon arrival, each participant was instructed to lay in a supine position for 3-5 minutes before ultrasound assessment. A recent study by Jajtner and colleagues (2015) revealed a significant increase in cross-sectional area vastus lateralis and rectus femoris may occur for up to 48 hours after a resistance exercise bout. Jajtner and colleagues (2015) also discovered a significant increase in echo intensity of the vastus lateralis immediately after exercise compared to pre-exercise values and that these values continued to decrease to below baseline levels after a period of 48 hours. The results from this study show that it may require more than 48 hours after a resistance exercise bout to assess muscle architecture accurately (Jajtner et al., 2015).

Unfortunately, this may have been a major limitation of the present study because subjects were

only required to refrain from exercise for a period of two hours. Another limitation that existed in this study was that the participants were not laying down for a sufficient enough time to allow for fluid shifts to occur. Previous research has required participants to lay in a supine position for at least 15 minutes prior to examination (Ema, Wakahara, Miyamoto, Kanehisa, & Kawakami, 2013; Esformes, Narici, & Maganaris, 2002; Jajtner et al., 2014; Lixandrão et al., 2014; Mangine et al., 2014a; Mangine et al., 2014b; Mangine et al., 2014c; Reeves, Maganaris, & Narici, 2004; Scanlon et al., 2014; Strasser, Draskovits, Praschak, Quittan, & Graf, 2013; Wakahara et al., 2012; Wells et al., 2014). Allowing only 3-5 minutes for fluid shifts may have affected intramuscular water content and therefore echo intensity.

Echo intensity and cross-sectional area of the vastus lateralis were assessed from the same image using an image analysis software (ImageJ, National Institutes of Health, version 1.37). In addition, each participant completed a full-body dual x-ray absorptiometry scan to determine body composition.

The results of this study showed that there were significant differences between player positions with respect to vastus lateralis cross-sectional area ($p \leq 0.05$), however there were no significant differences between positions with respect to echo intensity. Additionally, there were significant differences in percent body fat, lean body mass, lean leg mass, and fat mass between positions ($p \leq 0.05$). There were no significant differences in cross-sectional area, echo intensity, percent body fat, lean body mass, lean leg mass, and fat mass between races. Significant positive correlations were discovered between vastus lateralis cross sectional area and lean mass, fat mass, leg lean mass, and percent body fat ($p \leq 0.05$). A significant negative correlation was discovered between vastus lateralis cross-sectional area and echo intensity ($r = -0.455, p < 0.01$),

showing that individuals possessing a larger muscle area tended to have a darker muscle. No correlations were discovered between echo intensity and percent body fat, fat mass, lean mass, or leg lean mass. Similar results were discovered by Fukumoto and colleagues (2012) who found no correlation between echo intensity and percent body fat but significant negative correlations between echo intensity and cross-sectional area.

There were no performance variables measured in this study, however one can assume that each athlete was physically fit and strong due to standard requirements of Division I football. Direct assessments of strength and power were not measured in this study, so conclusions on how echo intensity or cross-sectional area may affect performance cannot be made. One may hypothesize that this athletic population of football players may have lower values of echo intensity and greater values of cross-sectional area compared to an elderly or untrained population due to lower levels of intramuscular fat or fibrous tissue and increased muscle mass. Vastus lateralis cross-sectional area was found to be correlated with all measures of body composition, which could indicate that the sport of football requires players with large statures and greater body fat along with increased muscle mass. The fact that measures of body fat significantly differed among player positions but echo intensity values did not may indicate that players with greater amounts of fat mass are able to maintain muscle quality, despite the hypothesis that an infiltration from the subcutaneous fat may lead to increased adipose tissue deposits into the muscle (Caresio, Molinari, Emanuel, & Minetto, 2004; Miljkovic and Zmuda, 2010). Values of cross-sectional area in this study (38.7 ± 6.6 centimeters²) were considerably greater than those found in other studies examining the cross-sectional area of the vastus lateralis in untrained young males in other studies (26.7 ± 4.5 centimeters² and 19.8 ± 1.9 centimeters²) (Ahtiainen et al., 2010; Scott et al., 2012). These findings are anticipated because Division I

football players undergo high-volume resistance training which is shown to increase hypertrophy in Type II muscle fibers, leading to increases muscle size and cross-sectional area (Charette et al., 1991; Ikai and Fukunaga, 1970; McCall, Byrnes, Dickinson, Pattany, & Fleck, 1996; Narici, Roi, Landoni, Minettu, & Cerretelli, 1989; Scanlon et al., 2014; Seynnes, de Boer, & Narici, 2007). Resistance training has also been shown to decrease values of echo intensity, which may explain why values of echo intensity in this study were lower than those seen in other studies examining untrained or elderly males (Jajtner et al., 2014; Scanlon et al., 2014). The results of this study show that values of echo intensity may not necessarily be correlated with percent body fat in a trained, athletic population. In addition, the cross-sectional area of the vastus lateralis in Division I football players is greater than that in an untrained or elderly population, whereas the opposite is true for echo intensity (Melvin et al., 2014).

Inter- and Intra-muscular Adaptations to Resistance Exercise are Heterogeneous

Previous research has shown that the architecture of skeletal muscle is heterogeneous throughout individual muscles as well as between different muscle groups (Lexell & Taylor, 1991; Zajac, 1992). Studies on cadavers have discovered that the mean cross-sectional area of Type I and Type II muscle fibers varied significantly within the vastus lateralis muscle and that the distribution of these muscle fibers within the muscle vary (Arbanas et al., 2012; Lexell & Taylor, 1991; Mahon, Toman, Willan, & Bagnall, 1984; Nygaard & Sanchez, 1982). For example, disparities in muscle fiber distribution and size have been found superficially compared to deep, proximally compared to distally, or between contralateral limbs (Arbanas et al., 2012; Lexell & Taylor, 1991; Mahon, Toman, Willan, & Bagnall, 1984; Nygaard & Sanchez, 1982).

Furthermore, Narici and colleagues (1988) observed that the cross-sectional area of the quadriceps femoris muscles are not uniform throughout the entire length of the muscles. The cross-sectional area of each of the knee extensor muscles reaches a maximum near the mid-point of the femur and then decreases both proximally and distally from this point (Narici, Roi, & Landoni, 1988). Because of this reason, research investigating the effects of strength training on different regions of the muscle has been conducted. Investigators have discovered that chronic periods of resistance training cause an increase in muscle hypertrophy, but that this increase is not homogeneous throughout different muscle groups or within individual portions of muscles (Blazevich, Cannavan, Coleman, & Horne, 2007; Ema, Wakahara, Miyamoto, Kanehisa, & Kawakami, 2013; Häkkinen et al., 2001; Housh, Housh, Johnson, & Chu, 1985; Melnyk, Rogers, & Hurley, 2009; Narici et al., 1996; Noorikoiv, Nosaka, & Blazevich, 2010; Wells et al., 2014). Housh and colleagues (1985) investigated the effects of eight weeks of unilateral concentric isokinetic training in untrained male college students (age: 25.1 ± 6.1 years). They discovered that the cross-sectional areas of multiple muscles within the forearm and legs increased in only the side of the body that had been trained and that there was preferential hypertrophy of specific muscles within a muscle group. Additionally, the researchers observed that the increases in hypertrophy differed along the length of the muscle, and that the increases in hypertrophy also differed between individual muscles (Housh, Housh, Johnson, & Chu, 1985). A further investigation by Melnyk et al. (2009) examined the effects of nine weeks of unilateral strength training on quadriceps femoris cross-sectional area in the proximal, distal, and middle regions of the muscles of 43 individuals of varying age. The investigators reported that the greatest increases in cross-sectional area were seen at the middle region of the quadriceps femoris (Melnyk, Rogers, & Hurley, 2009). Similar results were found by Häkkinen and colleagues

(2001) who observed selective changes in muscle hypertrophy of the quadriceps femoris after 21 weeks of resistance training in older women (age: 64 ± 3 years). In this study, increases in cross-sectional area were greatest at the region of greatest cross-sectional area, which corresponded to the most proximal portion of the vastus lateralis measured and the most distal portion of the vastus medialis measured (Häkkinen et al., 2001).

Conflicting research by Narici et al. (1996) demonstrated that six months of strength training in males resulted in greater increases in cross-sectional area of the quadriceps femoris at distal (increase from baseline by $18.8 \pm 7.2\%$, $p < 0.001$) and proximal (increase from baseline by $19.3 \pm 6.7\%$, $p < 0.001$) ends of the muscles compared to the central region (increase from baseline by $13.0 \pm 7.2\%$, $p < 0.001$). Furthermore, previous research has suggested the evidence of neuromuscular compartments and myonuclear domains within individual muscles based on differences in muscle architecture, nervous innervation, and histological analysis within the muscle (Allen, Roy, & Edgerton, 1999; Segal, Wolf, DeCamp, Chopp, & English, 1991; Segal, 1992). If this compartmentalization within muscles exists, it may explain why different adaptations are observed within the same muscle. The following studies highlight a few of the more recent studies examining the inhomogeneous muscle architectural adaptations to periods of resistance training.

Seynnes, O.R., de Boer, M., & Narici, M.V., 2007.

Early Skeletal Muscle Hypertrophy and Architectural Changes in Response to High-Intensity Resistance Training.

The purpose of this study was to examine the adaptations to high-intensity resistance training in the muscle architecture of the lower extremity. Thirteen healthy, recreationally active males and females participated in this 35-day long investigation. Seven participants (n = 5 males, n = 2 females) (age: 20 ± 2 years) were assigned to a resistance training group, and six males (age: 22 ± 3 years) were assigned to a control group. The resistance training program was conducted three times weekly and consisted of leg extension and leg curl exercises. Maximal voluntary contraction and electromyographic activity during knee extension were tested at baseline, after 10 days, after 20 days, and at the end of the training program. Muscle cross-sectional area of the quadriceps femoris was also evaluated at each of these timepoints using magnetic resonance imaging. Three transverse scans were captured at 25% and 50% of femur bone length, corresponding to the distal and proximal regions of the quadriceps, respectively.

The main findings from this study showed that there was a significant increase in maximal voluntary contraction after only 10 days of resistance training ($p < 0.01$). By the end of the 35-day training period, subjects in the training group significantly increased maximum voluntary contraction by $38.9 \pm 5.7\%$ compared to baseline values ($p < 0.001$). There was also a progressive increase in electromyographic activity within the quadriceps femoris during maximal knee extension throughout the training period, which was significantly greater than baseline after 20 days ($29.8 \pm 7.0\%$, $p < 0.01$) and after 30 days ($34.8 \pm 4.7\%$, $p < 0.01$) of training.

Additionally, the cross-sectional area of the quadriceps femoris muscles significantly increased from baseline values after only 20 days of training, both distally ($p < 0.01$) and proximally ($p < 0.001$). By the end of the 35-day period, the cross-sectional area of the quadriceps femoris significantly increased $6.5 \pm 1.1\%$ distally ($p < 0.001$) and $7.4 \pm 0.8\%$ proximally ($p < 0.001$), however these changes were not significantly different from each other. With closer examination

of each individual muscle of the quadriceps femoris, the cross-sectional area of the distal part of the vastus lateralis muscle increased to a greater extent than the distal parts of the vastus intermedius, vastus medialis, and rectus femoris from baseline values at all timepoints. After only 20 days of training, the distal part of the vastus lateralis significantly increased from baseline values by $9.0 \pm 3.7\%$ ($p < 0.05$). After 35 days, the distal region of the vastus lateralis significantly increased from baseline values by $13.8 \pm 3.1\%$ ($p < 0.01$). In comparison, the cross-sectional areas of the vastus medialis and vastus intermedius only significantly increased after the entire training period had completed, by $5.5 \pm 1.9\%$ ($p < 0.01$) and $6.0 \pm 1.9\%$ ($p < 0.001$), respectively. The cross-sectional area of the distal part of rectus femoris was not observed due to its anatomical structure. However, when examined at the proximal sites, the cross-sectional area of the rectus femoris muscle significantly increased by $7.4 \pm 2.7\%$ ($p < 0.001$) after 20 days of training, and significantly increased by $11.4 \pm 5.0\%$ ($p < 0.001$) after 35 days of training. The cross-sectional area of the vastus lateralis and vastus medialis also significantly increased proximally by $4.5 \pm 1.0\%$ ($p < 0.05$) and $6.3 \pm 2.8\%$ ($p < 0.05$) after 20 days, and by $7.8 \pm 2.0\%$ ($p < 0.01$) and $8.6 \pm 3.0\%$ ($p < 0.01$) at the end of the 35-day period, respectively. However, there were no significant differences between the extent of the increase in cross-sectional area observed distally and proximally of any of the quadriceps femoris muscles.

The findings from this investigation show that muscle hypertrophy from resistance training occurs in all of the quadriceps femoris muscles, but in a non-homogeneous way. The percent increase in maximal voluntary contraction and electromyographic activity greatly outweighed the increase in cross-sectional area for any of the muscles of the quadriceps femoris, indicating that neural factors probably contributed the most to the increase in strength, with secondary aid from changes in muscle architecture (Sale, 1988). The authors note that the

mechanical stimuli upon each muscle is the primary determinant for muscle growth, and that the disparities in cross-sectional area increases may be due to different demands on each part of the muscle. The forces generated through muscle contraction are transferred both longitudinally and transversely throughout the muscle, and any change in muscle architecture or tendinous structures throughout the muscle may affect its ability to adapt (Segal, 1992; Street, 1983).

Perhaps, in this investigation, the distal portion the vastus lateralis was stimulated more so than the proximal part, whereas in the vastus medialis, the opposite may have occurred. This may explain why inhomogeneous increases in muscle hypertrophy were observed between muscles and at varying locations along each muscle (Seynnes, de Boer, & Narici, 2007).

Ema, R., Wakahara, T., Miyamoto, N., Kanehisa, H., & Kawakami, Y., 2013.

Inhomogeneous Architectural Changes of the Quadriceps Femoris Induced by Resistance Training.

The objective of this study was to determine if lower extremity muscle architecture adapts to resistance training in a homogeneous way within the same muscle and between different muscles. Twenty-one healthy men were assigned to either a control (n = 10; age: 26 ± 4 years) or resistance training group (n = 11; age: 27 ± 2 years). The resistance training group consisted of unilateral knee extension exercises for a period of 12 weeks with both concentric and eccentric actions for five sets of eight repetitions. The training load for each participant in the training group was standardized at 80% of their one-repetition maximum, however the authors do not state how many times per week the exercises were performed. Before and after the training program, muscle thickness measurements of the vastus lateralis, vastus medialis, rectus femoris, and vastus intermedius were captured using a 7.5-Megahertz, brightness-mode

ultrasound. Measures of cross-sectional area of the quadriceps femoris were completed using magnetic resonance imaging. Participants waited at least three days after completing the last training session to be examined via ultrasound. Measurements were completed at distal and proximal regions of each muscle of the quadriceps femoris. Additionally, previous research performed by Blazevich and colleagues (2006) discovered that the muscle architecture of the vastus intermedius is inhomogeneous laterally and medially, so further ultrasound measurements of the vastus intermedius were captured at these locations. Longitudinal, single still-images of each muscle were captured from the right leg of each subject after they had been laying in a supine position for 20 minutes. Muscle thickness was defined as the mean of the distances between the superficial and deep aponeuroses (or bone in place of the superficial aponeurosis for the vastus intermedius). Magnetic resonance imaging scans were captured at the same locations as the ultrasound measurements to determine cross-sectional area of each muscle. Muscle thickness and cross-sectional area were determined using an image analysis software (ImageJ, National Institute of Health, USA). In addition, the maximal voluntary isometric knee extension torque of each participant was measured before and after the training program, at least three days after the last day of the protocol.

Intra-class correlations between muscle thickness measurements taken on two separate days were reported to be high (ICC = 0.860), and the coefficient of variation was determined to be less than 3.4%. The intra-class correlations for magnetic resonance imaging images were also reported to be high (ICC = 0.999) and the coefficient of variation was $0.6 \pm 0.7\%$. After the training period, the training group significantly increased knee extension one-repetition maximum and maximal voluntary isometric knee extension torque (69 ± 9 kilograms (kg) vs. 86 ± 9 kg; $p < 0.001$ and 257 ± 51 Newton meters (Nm) vs. 318 ± 51 Nm; $p < 0.001$, respectively),

whereas there were no significant changes in the control group in either variable. A three-way multivariate analysis of variance revealed a significant group by time interaction for muscle cross-sectional area ($p < 0.01$) and muscle thickness ($p < 0.05$) in each muscle. Significant increases in muscle cross-sectional area ($p < 0.05$) and muscle thickness ($p < 0.05$) were observed for each muscle at each measurement site, except for muscle thickness in the lateral region of the vastus intermedius. Furthermore, a three-way analysis of variance revealed a significant group by muscle by region interaction on muscle cross-sectional area ($p < 0.05$) and a significant group by muscle interaction on muscle thickness ($p < 0.01$). Follow-up analysis of variances demonstrated that the increases in cross-sectional area and muscle thickness of the rectus femoris in the training group were significantly greater than those of the other muscles measured ($p < 0.01$, $p < 0.05$, respectively). The increase in cross-sectional areas of the rectus femoris and vastus lateralis were greater in the distal region of the muscles compared to the proximal region ($p < 0.01$, $p < 0.05$, respectively), whereas there were no differences between the increases in the proximal and distal regions in the vastus intermedius and vastus medialis. However, the increase in muscle thickness in the medial region of the vastus intermedius was greater than the increase in the lateral region ($p < 0.05$).

The results of this study show that there are inhomogeneous adaptations to resistance exercise in the quadriceps femoris muscles. The increase in cross-sectional area and muscle thickness were greater in the rectus femoris than in any of the other muscles, possibly demonstrating greater utilization of this muscle when performing knee extension exercises. Previous research has demonstrated that muscle activation in the rectus femoris was greater than that in any of the vasti during a knee extension exercise, which may be responsible for the disparities in inter-muscle hypertrophy seen in the current study (Narici et al., 1996; Richardson,

Frankm & Haseler, 1998). Furthermore, research has shown that there are a greater proportion of Type II muscle fibers in the rectus femoris than in the other muscles of the quadriceps femoris (Johnson, Sideri, Weightman, & Appleton, 1973). Type II muscle fibers are known to experience hypertrophy to a greater extent than Type I muscle fibers, which could be another explanation for the greater increase in muscle thickness and cross-sectional area in the rectus femoris compared to the vasti (Aagaard et al., 2001).

Differences in muscle cross-sectional area between the distal and proximal parts of the muscle were seen in the rectus femoris and the vastus lateralis. These results support the findings of Wakahara and colleagues (2012), who suggested that the regional differences in increased muscle cross-sectional area after resistance training were due to regional differences in within-muscle activation during exercise. Studies have shown disproportionate amounts of muscle activation in the proximal versus distal regions of the rectus femoris (Akima et al., 1999; Akima et al., 2004). Akima and colleagues (2004) discovered that during isokinetic knee extension, muscle activation was greater in the distal region of the rectus femoris than the proximal region, which could account for differences in hypertrophy between distal and proximal regions of the muscle in the current study. In addition, the vastus intermedius muscle demonstrated differences in the increase in muscle thickness medially compared to laterally. Previous research has shown that a two-week knee extension training regimen increased muscle activation in the anterior/medial regions of the vastus intermedius compared to the lateral regions (Akima et al., 1999). These findings parallel the greater increase in muscle thickness in the medial regions of the vastus intermedius compared to the lateral regions in the current study. This study shows that the inter- and intra-muscular adaptations of the quadriceps femoris to resistance training occur in an inhomogenous way (Ema, Wakahara, Miyamoto, Kanehisa, Kawakami, 2013).

Wakahara, T., Naokazu, M., Sugisaki, N., Murata, K., Kanehisa, Y., Fukunaga, T., & Yanai, T, 2012.

Association Between Regional Differences in Muscle Activation in One Session of Resistance Exercise and in Muscle Hypertrophy After Resistance Training.

The purpose of this investigation was to determine if regional muscle activation is related to regional increases in muscle hypertrophy after resistance training. Twelve healthy men (age: 25.2 ± 3.0 years) participated an experiment investigating the acute effects of resistance training on muscle activation and hypertrophy in the upper arms. Nineteen healthy men participated in a secondary experiment investigating the chronic effects of resistance training on muscle activation and hypertrophy in the upper arms. When assessing the acute effects of resistance training, investigators instructed the participants to lay in a supine position and perform five sets of eight repetitions of a lying triceps extension exercise at 80% of their one-repetition maximum, which had been analyzed two days prior. Magnetic resonance images of the upper arms were captured before and after the exercise bout. Magnetic resonance images have been used previously to quantify the regional differences in muscle activation through determination of the brightness of the image. High-intensity exercise causes an increase in the brightness of the magnetic resonance images (Adams, Duvoisin, & Dudley, 1992; Fleckenstein, Bertocci, Nunnally, Parkey, & Peshock, 1989). The brightness of the images can be quantified by transverse relaxation time, which is related to the exercise intensity, the number of repetitions completed, and the electrical activity within the muscle (Adams, Duvoisin, & Dudley, 1992; Fisher, Meyer, Adams, Foley, & Potchen, 1990; Yue, 1994). Previous studies have shown distal-proximal disparities in transverse relaxation time on a magnetic resonance image within the gastrocnemius muscle while performing a calf raise (Kinugasa, Kawakami, & Fukunaga, 2005).

The distal region of the gastrocnemius was found to have a greater increase in transverse relaxation time compared to the proximal region, indicating higher activation in the distal region of the muscle (Kinugasa, Kawakami, & Fukunaga, 2005).

In the present study, a total of 13 magnetic resonance images were captured along the upper arm, however the authors do not state which arm the images were taken from. The cross-sectional area of the triceps brachii and mean transverse relaxation were analyzed using an image analysis software (ImageJ, National Institute of Health, USA). The mean transverse relaxation time for each pixel within the triceps brachii was calculated in order to determine the percentage of the muscle area that was activated. The intra-class correlations between two analyses of each magnetic resonance imaging slice were reported to be high (ICC = 0.999), and the coefficient of variation was $0.3 \pm 0.3\%$.

In the second part of the study investigating the chronic effects of resistance training, twelve participants were assigned to a training group (age: 26.3 ± 3.7 years), while seven subjects were assigned to a control group (age: 26.9 ± 3.9 years). Subjects in the training group endured a 12-week resistance training protocol that they performed three times weekly, however the researchers do not mention what kinds of exercises were included in this regimen. Thirteen magnetic resonance images of the upper extremity were captured before and after the training period. The cross-sectional area of the triceps brachii was analyzed using an image analysis software (ImageJ, National Institute of Health, USA). The intra-class correlations between two analyses of the magnetic resonance imaging slices for three participants were reported to be high (ICC = 0.998), and the coefficient of variation was $1.2 \pm 1.2\%$.

The results from this study revealed that there was a significant main effect for region for the percent activated area of the muscle immediately after an acute bout of exercise as determined by an analysis of variance. The proximal and middle regions of the long and medial heads of the triceps brachii had a significantly greater percent of activated area than the distal regions. In addition, the percentage of activated area in the lateral head of the triceps brachii was significantly lower than that in the medial or long head at lower at locations ranging from 12-16 centimeters from the elbow.

After 12 weeks of resistance training, there was a significant increase in one-repetition maximum of the lying triceps extension exercise from 11.0 ± 2.0 kg to 17.3 ± 2.9 kg ($p < 0.05$). A two-way analysis of variance showed main significant main effects of time and region on the cross-sectional area of the triceps brachii in trained individuals. The cross-sectional area of the triceps brachii increased significantly throughout all parts of the muscle, however the change in cross-sectional area was significantly greater in the proximal and middle regions compared to the distal regions ($p < 0.05$). No differences in cross-sectional area were observed for individuals in the control groups in any region of the muscle.

The findings of this study indicate that the percentage of activated area of the triceps brachii during one resistance exercise bout and the increase in cross-sectional area after chronic resistance training occur in a non-homogeneous way. The percentage of activated area after resistance exercise and the increase in cross-sectional area after training were both greater in the middle and proximal regions of the triceps brachii than the distal regions. The differences in relative increases in cross-sectional area support the hypothesis that hypertrophy may occur to a greater extent in the areas of the muscle that are activated to the greatest extent during exercise

(Adams, Duvoisin, & Dudley, 1992; Fisher, Meyer, Adams, Foley, & Potchen, 1990; Narici et al., 1996; Yue, 1994). The non-uniform increase in percent activated area after a resistance training bout may be due to the direction at which the exercise is performed, which is the result of differences in muscle recruitment for different exercises (Buchanan, Almdale, Lewis, & Rymer, 1986). In addition, previous research has suggested that the existence of neuromuscular compartments within a muscle may affect the way each muscle adapts individually to a stimulus (Segal, Wolf, DeCamp, Chopp, & English, 1991). Another possible explanation for the varied increase in cross-sectional area is muscle fiber composition of the triceps brachii. The long and lateral heads contain about 60% Type II muscle fibers, whereas the medial head contains about 40% Type II muscle fibers (Elder Bradbury, & Roberts, 1982). The greater increase in cross-sectional area in the proximal region of the triceps brachii may be due to the greater proportion of Type II fibers in the long head, whereas the smaller increase in the cross-sectional area in the distal region may be due to the lesser proportion of Type II fibers in the medial head (Elder, Bradbury, & Roberts, 1982). The main findings from this study show that the regional differences in muscle activation during one resistance exercise bout paralleled the increases in cross-sectional area of the triceps brachii after chronic resistance training, suggesting that hypertrophy within a muscle occurs in a non-homogeneous way (Wakahara et al., 2012).

Wells, A.J., Fukuda, D.H., Hoffman, J.R., Gonzalez, A.M., Jajtner, A.R., Townsend, J.R., Mangine, G.T., Fragala, M.S., & Stout, J.R., 2014.

Vastus Lateralis Exhibits Non-Homogeneous Adaptation to Resistance Training.

In this study, the investigators aimed to examine the changes in muscle architecture at two different points on the vastus lateralis muscle after a period of resistance training. A

secondary purpose of the study was to determine if the changes in muscle architecture at each point of the muscle was related to maximal strength. This study is unique because it looked to examine the adaptations to resistance training at different locations within the same muscle in the transverse plane, whereas most previous research has compared muscular adaptations to resistance training in the longitudinal plane, i.e., proximally and distally. Twenty-three Division I female soccer players (age: 19.7 ± 1.0 years) completed a 15-week resistance training protocol in the off-season as instructed by the team strength and conditioning coach. Players exercised four times per week and did not engage in any other structured exercise protocol throughout the course of the study. At the beginning and end of the 15-week period, a 12-Megahertz, brightness-mode ultrasound was used to assess muscle thickness, cross-sectional area, and echo intensity of vastus lateralis muscle in the self-reported dominant leg of each participant. The ultrasound settings were standardized at a gain of 50 decibels, a dynamic range of 72, and a depth of 5 centimeters for each subject. Prior to testing, each participant was instructed to lay in a supine position for 15 minutes to allow for fluid shifts to occur. Ultrasound measurements of muscle thickness were taken in the longitudinal plane, parallel to the length of the leg. Measurements were captured at two separate locations along the vastus lateralis muscle while the participant was laying on their non-dominant side; one at 50% of the linear distance from the greater trochanter to the lateral epicondyle of the femur (which was termed V0) and the other at a point located 5 centimeters medially from the previously mentioned site, toward the anterior side of the body (which was termed V5). Three still images were taken at each location in the longitudinal plane. Panoramic ultrasound measurements of the cross-sectional area of the vastus lateralis were captured in the transverse plane, perpendicularly to the length of the muscle at 50% of the linear distance from the greater trochanter to the lateral epicondyle of the femur. These

panoramic images were also used for echo intensity analysis. Three images were captured at this location in the transverse plane.

Muscle thickness, cross-sectional area, and echo intensity were quantified via an image analysis software (ImageJ, National Institutes of Health, USA, version 1.45s). Muscle thickness was defined as the distance between the inferior border of the superficial aponeurosis to the superior border of the deep aponeurosis. Cross-sectional area of the panoramic images were calculated using the polygon tool in ImageJ by tracing the outline of the muscle, attempting to include as much lean mass as possible while avoiding the surrounding bone and fascia. Echo intensity was also calculated from the panoramic images by using the standard histogram function in ImageJ. In addition to ultrasound measures, one-repetition maximum testing in the barbell back squat was performed at the beginning and end of the 15-week period in 14 of the 23 subjects to evaluate muscle strength.

Reliability data for the muscle thickness and cross-sectional area measures were reported as intra-class correlations, and were shown to be very high (ICC = 0.99). The investigators discovered that there was a significant increase in one-repetition maximum squat strength throughout the course of the study (change from pre to post = 3.7 ± 2.4 kg, $p = 0.004$). Additionally, the post values showed increases in muscle thicknesses at both V0 and V5 along the vastus lateralis compared to pre-values. However, the change in muscle thickness was significantly greater at V5 (change from pre to post = 0.18 ± 0.18 centimeters) compared to V0 (change from pre to post = 0.04 ± 0.16 centimeters) ($p = 0.006$). Furthermore, the changes in one-repetition maximum squat strength correlated significantly with the changes in muscle thickness at V0, but did not correlate with the changes in muscle thickness at V5. Also, there was

a significant increase in cross-sectional area of the vastus lateralis from pre to post (change from pre to post = 0.58 ± 0.39 centimeters², $p = 0.016$), but the magnitude-based inferences suggest that this change was trivial. No significant change in the echo intensity values from pre to post was observed.

The primary findings from this study show that the vastus lateralis adapts to resistance training in a non-homogeneous manner because the changes in muscle thickness were significantly greater at V5 compared to V0. The vastus lateralis muscle is unique in its morphology in comparison to other knee extensor muscles such as the rectus femoris because it has an asymmetrical shape in the transverse plane. The anteromedial side of the vastus lateralis is inherently thicker than the posterolateral part of the muscle (Blazevich, Gill, & Zhou, 2006). Additionally, studies have shown that muscle thickness and cross-sectional area vary along the length of the vastus lateralis muscle (Ema, Wakahara, Miyamoto, Kanehisa, & Kawakami, 2013). Research has also shown that adaptations in muscle architecture may be dependent on the specific region of the muscle due to differences in neuromuscular compartments (Ema, Wakahara, Miyamoto, Kanehisa, & Kawakami, 2013; English, Wolf, & Segal, 1993; Segal, 1991; Segal, Wolf, DeCamp, Chopp, & English, 1991). As a result, the vastus lateralis may experience non-homogeneous adaptations to training due to the nature of the muscle architecture, which is consistent with the findings of this study. The changes in muscle thickness at V0 were significantly correlated with improvements in barbell back squat strength, whereas there were no correlations found between the changes in muscle thickness at V5 and barbell back squat strength, indicating that improvements in strength may be mediated only by architectural changes at V0. Additionally, because the differences in cross-sectional area from pre to post were trivial, it is likely that the increases in barbell back squat strength may be due to the

increases in muscle thickness and not increases in cross-sectional area. These results also show that significant increases in muscle thickness do not necessarily result in concomitant increases in muscle cross-sectional area. The results from this study conflict with those seen in other studies, which have observed significant increases in cross-sectional area of the vastus lateralis following resistance exercise in men (Narici et al., 1996; Seynnes, de Boer, & Narici, 2007). However, the results from this study align with Nimphius and colleagues (2012), who discovered no change in muscle cross-sectional area despite an increase in squat strength after a competitive season in female softball players. In contrast to the findings of the current study, Nimphius and colleagues (2012) did not see significant increases in muscle thickness, but there was a high correlation between the changes in one-repetition maximum squat strength and muscle thickness ($r = 0.57, p < 0.05$).

Furthermore, there were no significant differences in echo intensity of the vastus lateralis throughout the course of the study, whereas other researchers have found conflicting results. Scanlon and colleagues (2014) observed a significant decrease in echo intensity in the vastus lateralis in elderly women after a resistance training program, which correlated to an increase in knee extensor strength. In addition, Ivey and colleagues (2000) discovered an increase in muscle quality defined as muscle strength per unit volume assessed by magnetic resonance imaging in young women following unilateral resistance training. Furthermore, Jajtner and colleagues (2014) discovered decreased echo intensity in Division I women's soccer players from the beginning to the end of a competitive season. These results show that muscle strength relative to muscle volume may be a more sensitive measure of muscle quality compared to echo intensity, or that changes in echo intensity require a longer training period. Overall, adaptations of the

vastus lateralis muscle to resistance training may occur in a non-homogeneous way (Wells et al., 2014).

Inter- and Intra-muscular Echo Intensity Values May Be Heterogeneous

The above studies have validated that skeletal muscle architecture is inhomogeneous and that the within- and between-muscle adaptations to resistance training occur in an inhomogeneous manner. For this reason, the echo intensity within and between muscles may vary as well. The following studies aim to examine the echo intensity between muscle groups and within individual muscles.

Young, H., Jenkins, N.T., Zhao, Q., & McCully, K.K., 2015.

Measurement of Intramuscular Fat by Muscle Echo Intensity.

Although this study has been discussed previously, a secondary purpose of the study was to examine the variability of echo intensity within the same muscle. Thirty-one males and females (age: 20 – 61 years) with diverse body mass indices and physical activity levels were involved in this investigation. The upper and lower leg lengths of each participant were measured and recorded. Marks were made on the upper legs of each participant at distances of one-third and one-fourth the length of the upper leg from the superior lateral aspect of the patella to the anterior superior iliac spine. Marks were also made on the lower legs of each participant at distances of one-third and one-fourth the length of the lower leg from the inferior lateral aspect of the patella to the calcaneus. Ultrasound and magnetic resonance images of the rectus femoris,

medial gastrocnemius, tibialis anterior, and biceps femoris were captured at the marks previously mentioned.

The results of this investigation revealed that the echo intensities of the different muscles examined varied considerably (rectus femoris: 55.1 ± 7.4 arbitrary units; biceps femoris: 42.6 ± 7.3 arbitrary units; tibialis anterior: 56.1 ± 8.0 arbitrary units; medial gastrocnemius: 51.5 ± 8.5 arbitrary units). Additionally, the mean echo intensities of the images taken at different locations within the same muscle revealed significant differences. Coefficients of variation for echo intensities between the two imaging locations within each muscle were fairly high, indicating disparities in intra-muscle echo intensity (CV = 5.6% in the rectus femoris; CV = 6.3% in the biceps femoris; CV = 5.0% in the tibialis anterior; CV = 4.8% in the medial gastrocnemius). When a correction factor for subcutaneous fat thickness was applied, the coefficient of variation for echo intensity between different locations within the same muscle changed (CV = 5.7% in the rectus femoris; CV = 8.7% in the biceps femoris; CV = 4.9% in the tibialis anterior; CV = 5.2% in the medial gastrocnemius). Coefficients of variation for the percent intramuscular fat between magnetic resonance images taken at each location revealed that differences in the amounts of intramuscular fat existed at different locations within the same muscle (CV = 11.0% in the rectus femoris; CV = 7.6% in the biceps femoris; CV = 5.6% in the tibialis anterior; CV = 5.1% in the medial gastrocnemius).

The investigators noted that higher correlations between the echogenicity of the images taken at each location were found when examining the corrected echo intensity and percent intramuscular fat for each muscle individually compared to examining all muscle groups as a whole. This research also shows that variability in echo intensity exists in different locations

within the same muscle. Investigators discovered different amounts of intramuscular fat at each location within the muscle, which could significantly impact the echo intensity at those specific locations. In addition, the authors discovered variability in the echo intensity between different muscle groups, which was consistent with prior research (Caresio, Molinari, Emanuel, & Minetto, 2014; Pillen, 2010; Pillen et al., 2009; Pillen & van Alfen, 2011). Pillen and colleagues (2009) suggested that differences in muscle fiber orientation and fibrous tissue distribution within each muscle can contribute to the disparities in echo intensity between different muscles. Arts and colleagues (2010) also reported that the relationship between age and echo intensity dependent on the muscle of interest, and that some muscles did not show a change in echo intensity with age. In addition, the variability in echo intensity values discovered between different muscles in the present study may have been partially due to the size limitation of the ultrasound image. The investigators noted that a single ultrasound image was sufficiently large enough to capture the entire area of the rectus femoris muscle, but was not large enough to capture the entire area of the biceps femoris, tibialis anterior, and medial gastrocnemius, which may have affected echo intensity values. Overall, it is apparent that echo intensity is inhomogeneous throughout an individual muscle and among muscle groups (Young, Jenkins, Zhao, & McCully, 2015).

Caresio, C., Molinari, F., Emanuel, G., & Minetto, M.A., 2014.

Muscle Echo Intensity: Reliability and Conditioning Factors.

The purpose of this study was to assess the reliability of skeletal muscle echo intensity depending on the size, shape, and location of the region of interest within an individual muscle. Some muscles contain internal fascia that separates one component of the muscle from another,

depending on the function and architecture of the specific muscle. In addition, some muscles have an inhomogeneous distribution of intramuscular fat or fibrous tissue due to neurological or pathological conditions or as a result of normal muscle architecture. In this study, three consecutive transverse ultrasound images of the biceps brachii, rectus femoris, vastus lateralis, tibialis anterior, and medial gastrocnemius were assessed in opposite limbs of 20 healthy participants (n = 10 females, age: 26.0 ± 2.3 years; n = 10 males, age: 30.2 ± 5.6 years). A brightness-mode ultrasound, set at a gain of 50% of the total range was used to capture still images of each muscle in all participants. The depth setting on the ultrasound varied between participants and between muscles in order to include the entire muscle area in one image. However, altering depth settings between individuals and muscle groups may have affected image quality and echo intensity because this changes how deep the ultrasound beams penetrate the structure of interest (Pillen, 2010).

Muscle thickness and subcutaneous fat thickness of each muscle were quantified using ImageJ (National Institutes of Health, Bethesda, MD, USA). The echo intensity of each muscle was assessed using the standard histogram function on MATLAB (The MathWorks, Inc., Natick, MA, USA). To do this, the maximal region of interest within an individual muscle was selected by including as much of the muscle as possible without including any surrounding fascia. Additionally, multiple other regions of interest within each muscle were assessed to examine the effect of the size and location of the region of interest on echo intensity. For example, a maximal rectangular region of interest was also created within each muscle, which was defined as the maximal rectangular area within the muscle that did not include any surrounding bone or fascia. Within the maximal rectangular region of interest, a total of nine other regions of interest were examined, each decreasing in size from the previous region of interest by 10%. Two additional

regions of interest examined in the tibialis anterior, a rectangular region in the superficial portion and a square region in the deep portion. In the rectus femoris, two additional regions of interest were also examined, a square region in the lateral portion and a square region in the medial portion.

The findings of this study indicate that the muscle thickness values were higher in males than females for all muscles except the medial gastrocnemius ($p < 0.01$). Subcutaneous adipose tissue thickness was greater in females than in males for all muscles except the biceps brachii ($p < 0.001$). Intra-class correlations and coefficients of variation were calculated across the different regions of interest within each muscle to assess intra-image reliability. Intra-class correlations ranged from moderate to high for each muscle (ICC = 0.54 to 0.86) and coefficients of variation ranged from 6.7% to 11.5%. Inter-image reliability was also calculated to determine the consistency of three images captured at each location and with each size of the region of interest in both the right and left limbs. In general, a non-linear relationship existed between the intra-class correlations of the three consecutive images captured at each location and the region of interest size, where lower intra-class correlations were discovered when examining smaller regions of interest in both the right and left limbs. The authors concluded that a region of interest with a dimension of 9.6% the total size of the maximum region of interest was sufficient enough to obtain high reliability (where the intra-class correlation was greater than 0.70) in all muscles examined. No significant differences in echo intensity were found between the dominant and non-dominant muscles or the maximum regions of interest and maximum rectangular regions of interest in any muscle. Significantly greater echo intensity values were discovered in females compared to males in the rectus femoris, tibialis anterior, and medial gastrocnemius, however no significant differences were seen in the vastus lateralis and biceps brachii. When the data was

pooled for gender, the echo intensities of the biceps brachii and tibialis anterior were significantly higher than those of the medial gastrocnemius, rectus femoris, and vastus lateralis.

Upon examination of the additional regions of interest in the tibialis anterior and rectus femoris, differences in echo intensity between regions were discovered. In the tibialis anterior, the echo intensity was significantly lower for the rectangular-shaped superficial portion compared to the square-shaped deep portion or the maximal region of interest and the maximal rectangular region of interest ($p < 0.05$). Also, the echo intensity of the rectus femoris was significantly greater in the medial portion compared to the lateral portion or the maximal region of interest and the maximal rectangular region of interest ($p < 0.05$). No significant correlations were found between muscle thickness and echo intensity in any muscle, however significant positive correlations were discovered for subcutaneous adipose tissue thickness and echo intensity in the vastus lateralis, tibialis anterior, and medial gastrocnemius (correlation coefficients ranged from $r = 0.44$ to 0.77 ; $p < 0.05$).

The findings of this study show that echo intensity values may differ depending on the size, shape, and location of the region of interest. Quantifying the echo intensities of smaller regions of interest within muscles with were associated with lower intra-class correlations between images taken at the same location. This may indicate that it is important to include the entire area of a muscle when examining its echo intensity. A small section of the muscle may not be representative of the entire muscle and may result in inaccurate measures of muscle echogenicity. Additionally, the present study discovered that echo intensity values vary among different muscle groups and within individual muscles. This may be due to differences in muscle architecture and fascicle distribution throughout the muscle.

The positive correlation between subcutaneous adipose tissue thickness and echo intensity in the vastus lateralis, tibialis anterior, and medial gastrocnemius may imply that greater amounts of fat adjacent to the muscle cause higher echo intensity values. Perhaps the intramuscular adipose and fibrous tissue content is dependent on the amount of subcutaneous fat adjacent to the muscle. Miljkovic and Zmuda (2010) hypothesized that a greater amount of intramuscular adipose tissue may result from the infiltration of fat from the subcutaneous layer, so a greater amount of subcutaneous fat may increase the amount of intramuscular fat. In the current study, discrepancies between the correlations of subcutaneous fat and echo intensity existed depending on the observed muscle. Different muscles may have specific cellular adaptations to lipid storage and utilization depending on one's level of activity, which may affect the amount of fat storage within a muscle and therefore may affect muscle echo intensity.

The authors also hypothesized that the measurement of echo intensity is, in nature, an average value, so it does not represent extremely high or extremely low values of echogenicity within a muscle well. The distribution of fat and fibrous tissue within a muscle are lost with the central measure of echo intensity, so varying measures of echogenicity may occur within a muscle but cannot be seen when looking at overall muscle echo intensity. Further research should be done examining echo intensity values within individual muscles. Overall, it is apparent that the size, shape, and location of the region of interest within a muscle has a profound effect on its echo intensity value (Caresio, Molinari, Emanuel, & Minetto, 2014).

Single Versus Panoramic Ultrasound Imaging Techniques in Skeletal Muscle Echo Intensity Quantification

A single transverse ultrasound image often does not permit the entire skeletal muscle area to fit in a single ultrasound image, so panoramic imaging has been developed to allow for visualization of larger muscles within one frame (Athaiainen et al., 2010; Henrich, Schmider, Kjos, Tutschek, & Dudenhausen, 2002; Thomaes et al., 2012; Noorkoiv, Nosaka, & Blazeovich, 2010). However, panoramic imaging increases the likelihood of error due to the overlapping of images upon one another (Noorkoiv, Nosaka, & Blazeovich, 2010). Noorkoiv and colleagues (2010) suggested that the curvature of the body of interest affects the reliability of panoramic ultrasound images, where tightly curved regions will probably result in lower reliability values. The results from an investigation previously discussed by Caresio et al. (2014) proposed that the reliability of echo intensity measurements may increase when the region of interest increases. These results offer the suggestion that a panoramic image may result in a more accurate representation of muscle echo intensity than a still image, especially in larger muscles that cannot fit in a single frame. The following study compares the utilization of panoramic ultrasound imaging with single ultrasound imaging in quantification of skeletal muscle echo intensity.

Jenkins, N.D.M., Miller, J.M., Buckner, S.L., Cochrane, K.C., Bergstrom, H.C., Hill, E.C., Smith, C.M., Housh, T.J., & Cramer, J.T., 2015.

Test-Retest Reliability of Single Transverse Versus Panoramic Ultrasound Imaging For Muscle Size and Echo Intensity of the Biceps Brachii.

The aim of the current study was to examine the reliability of echo intensity values of the biceps brachii obtained via panoramic ultrasound scans compared to single transverse still images. Fourteen healthy males (age: 21.8 ± 2.5 years) who had not engaged in resistance training within the past six months and had no indication of musculoskeletal injury were examined on two days, separated by a period of about 48 hours. Participants were instructed to refrain from any physical activity for at least 24 hours prior to testing. During each visit, a 10-Megahertz, brightness-mode ultrasound with a gain of 58 decibels was used to capture three panoramic transverse and three single transverse images of the biceps brachii on the right arm of all subjects. A padded guide was constructed and placed upon the arm of each subject to ensure that the probe moved perpendicularly to the length of the arm. An experienced investigator selected the best panoramic image and best transverse image taken from each participant during each visit. These images were then used for further analysis. Echo intensity, cross-sectional area, muscle thickness, and fat thickness for each of the best images were calculated using an image analysis software (ImageJ, National Institutes of Health, Bethesda, MD, USA, version 1.47v). Additionally, skinfold measurements and arm circumference measurements were obtained.

The findings of this investigation revealed no significant differences in any measurements obtained on the first visit compared to the second visit ($p > 0.05$). A significant correlation existed between muscle thickness and cross sectional area ($r = 0.93$; $p < 0.001$). Significant correlations also existed between subcutaneous adipose tissue thickness assessed via ultrasonography and skinfold thickness and arm circumference ($r = 0.98$; $p < 0.001$; $r = 0.75$; $p < 0.01$, respectively). However, no significant correlation existed between echo intensity of either the panoramic or still image and subcutaneous adipose tissue thickness. These findings are in conjunction with Caresio et al. (2014) who discovered no correlation between fat thickness

and echo intensity of the biceps brachii muscle, but found significant correlations between fat thickness and echo intensity in the vastus lateralis, tibialis anterior, and medial gastrocnemius. Therefore, the relationship between echo intensity and subcutaneous adipose tissue thickness may be dependent on the muscle of interest and/or the population studied. Test-retest reliability for the echo intensity of the panoramic images was moderate (intra-class correlation = 0.78), whereas test-retest reliability for cross-sectional area, muscle thickness, fat thickness, and the echo intensity of single images were high (intra-class correlations ranged from 0.82 to 0.99). All coefficients of variation between measurements on different testing days ranged from 2.26% to 7.27%. These results show that there was only slightly lower reliability in echo intensity values in panoramic images compared to single still images. These findings are in conjunction with those discovered by Rosenberg et al. (2014), who reported intra-class correlations of 0.72 in the echo intensity of panoramic images taken of the medial gastrocnemius. The echo intensity reliability values obtained from both panoramic and single images in this study were both lower than the reliability values obtained from all other ultrasound measures, including muscle thickness, subcutaneous adipose tissue thickness, and muscle cross-sectional area. Additionally, there were no significant differences ($p = 0.13$) between the echo intensity values calculated via panoramic images and single images, and the echo intensities of each image type of image were strongly correlated with one another ($r = 0.89$). These findings indicate that future studies may wish to use echo intensity obtained through single transverse images rather than panoramic transverse images due to the similar reliabilities and high correlations between the two. However, Caresio et al. (2014) discovered lower reliability values when the region of interest within a muscle decreases, so this may provide evidence of the contrary. Panoramic ultrasound imaging requires a greater amount of time and expertise to perform in comparison to single still-

images, which may provide further reason for the use of still images. Overall, the results of this study show that echo intensity values calculated via transverse panoramic ultrasound images are comparable to those of single transverse images in the biceps brachii, so single transverse images may be more beneficial to use if time constraints exist (Jenkins et al., 2015).

CHAPTER THREE: RESEARCH DESIGN AND METHODOLOGY

Participants

Twenty-five collegiate recreationally-trained males participated in this investigation. One participant was removed from the final analysis due to inconsistencies in ultrasound (US) probe pressure and discrepancies during imaging. Therefore, data from 24 subjects (age: 20.2 ± 1.6 years; height: 178.1 ± 6.6 cm; weight: 82.2 ± 13.4 kg) was included in the final analysis. Participants were purposively sampled from the University of Central Florida's rugby club team through contact with the team coach.

Each subject was required to provide a verbal form of consent in order to participate, following a description of the procedures, benefits, and risks of the study. Subjects were excluded from the study if they had participated in vigorous exercise for at least 24 hours prior to testing (Cadore et al 2012; Jajtner et al., 2014). The investigation was approved by the University of Central Florida's Institutional Review Board for human subjects, and a waiver of consent was granted for the Institutional Review Board for participation in the study.

Research Design

Each participant reported to the Human Performance Laboratory at the University of Central Florida on one occasion for non-invasive US examination of the vastus lateralis (VL) muscle in the dominant (DOM) leg. Subjects were required to abstain from vigorous exercise for

at least 24 hours prior to examination (Cadore et al., 2012; Jajtner et al., 2014). During this visit, three panoramic, extended-field-of-view images of the VL were captured in the transverse plane (PTI). Additionally, three still images of the VL were captured in the longitudinal plane (SLI). US image analysis was then completed using an image analysis software to determine specific muscle morphological characteristics.

Variables

The independent variables included in this investigation were: (a) Tertile [Posterior (PT) vs. Lateral (LT) vs. Anterior (AT)] and (b) Image Type (PTI vs. SLI). The dependent variables included in this investigation were: (a) Echo Intensity (EI), (b) Muscle Cross-Sectional Area (CSA), (c) Muscle Thickness (MT), and (d) Subcutaneous Adipose Tissue Thickness (SubQ).

Instrumentation

- A scale (Health-O-Meter Professional Scale, Patient Weighing Scale, Model 500 KL, Pelstar, Alsip, IL, USA) was used to obtain measurements of height and weight of each participant.
- A 12-Megahertz (MHz), brightness-mode US (General Electric LOGIQ P5, Wauwatosa, WI, USA) was used to capture images of the VL muscle in the DOM limb.

- An image analysis software (ImageJ, National Institutes of Health, USA, version 1.45s) was used to quantify muscle morphological characteristics, including EI, CSA, MT, and SubQ.
- A data analysis computer program (SPSS for Windows, version 21.0, SPSS Inc., Chicago, Illinois, United States) was used to perform statistical analyses.
- A computer software (Calculation for the test of the difference between two dependent correlations with one variable in common, Vanderbilt University, Nashville, TN, USA) was used to determine the difference between two dependent correlations.

Procedures

Ultrasonography

Prior to testing, all participants were instructed to wear shorts on testing day to avoid compression of the upper leg musculature and to expose the upper portion of the thigh. Participants were also required to abstain from vigorous exercise for at least 24 hours prior to examination (Cadore et al. 2012; Jajtner et al. 2014). Upon arrival to the Human Performance Laboratory, the subjects' height and weight were recorded prior to US examination. US procedures have been previously described by Jajtner et al. (2014), Mangine et al. (2014a), Mangine et al. (2014b), Mangine et al. (2014c), and Scanlon et al. (2014). Briefly, subjects were required to lay supine on an examination table with both legs fully extended for a minimum of 15 minutes to allow for fluid shifts to occur (Ahtiainen et al., 2010; Esformes, Narici, & Maganaris, 2002; Lixandrão et al., 2014; Reeves, Maganaris, & Narici, 2004; Scanlon et al.,

2014; Watanabe et al., 2012; Wells et al., 2014). Then, each participant was instructed to lay on their non-dominant side in order to obtain skeletal muscle US images of the VL muscle in the DOM leg. Subjects were positioned with their legs on top of one another and slightly bent at the knee (Wells et al., 2014).

US images of the VL were captured at 50% of the straight-line distance from the greater trochanter and the lateral epicondyle of the femur by an experienced researcher (C.H.B.) (Scanlon et al., 2014; Wells et al., 2014). To ensure proper probe placement and consistent image capture location, a dotted line was drawn transversely and longitudinally along the surface of the skin from the aforementioned location. All measures of muscle morphology were obtained using a B-mode, 12-MHz linear probe US (General Electric LOGIQ P5, Wauwatosa, WI, USA), coated with transmission gel (Aquasonic® 100, Parker Laboratories, Inc., Fairfield, NJ, USA) to provide acoustic contact without depressing the dermal layer of the skin (Scanlon et al., 2014; Wells et al., 2014). US settings remained fixed for examination of each participant to minimize instrumentation bias, to optimize spatial resolution, and to ensure EI consistency (Scanlon et al., 2014; Wells et al., 2014). Image gain was set at 50 decibels (dB), dynamic range was set at 72, and image depth was set at 5 cm (Scanlon et al., 2014; Wells et al., 2014). Three PTI were captured in the transverse plane, perpendicular to the long axis of the muscle. These images utilized extended-field-of-view ultrasonography (LogiqView™) in order to include entire area of the VL in a single panoramic image. Additionally, three SLI were captured in the longitudinal plane, parallel to the long axis of the muscle. All measures were performed by the same examiner and captured from the same anatomical locations. Anatomical landmarks and probe orientation for US analysis in the PTI and SLI of a sample participant are depicted in Figure 1 and Figure 2, respectively.

Image Analysis

All US images were analyzed offline by an experienced researcher (A.N.V.) using an image analysis software (ImageJ, National Institutes of Health, USA, version 1.45s) to quantify muscle morphological characteristics. A known distance shown in each ultrasound image was used to calibrate the image analysis software.

Analysis of Panoramic Transverse Images

Cross-Sectional Area of the Vastus Lateralis in Panoramic Transverse Images

CSA of the VL was quantified using images taken in the transverse plane utilizing extended-field-of-view ultrasonography (LogiView™). PTI utilized a sweep of the probe along the VL from the anterior portion of the muscle to the posterior portion of the muscle in order to capture the entire area of the muscle in a single image. Three consecutive images were captured at the same anatomical location by the same investigator to determine within-day precision.

Out of the three panoramic images captured from each participant, two experienced researchers (A.N.V. and C.H.B.) individually selected the best image for subsequent analysis (Jenkins et al., 2015). If the researchers did not agree on which image was best, a third experienced researcher (D.H.F.) selected the best image of the two chosen by A.N.V. and C.H.B. Requirements for best panoramic image selection can be found in Appendix C.

CSA of the PTI (CSA_{PTI}) was quantified offline using ImageJ. The outline of the VL muscle was located in the image and traced using the polygon function tool, which included as much lean mass as possible without including any surrounding bone or fascia (Wells et al.,

2014). The total area of the traced polygon was then calculated and reported in centimeters² (cm²). A sample image for CSA_{PTI} analysis is presented in Figure 3.

Inter-day reliability for CSA_{PTI} was completed on a separate sample of participants, with at least 24 hours between examinations. C.H.B. completed ultrasound image capture, and A.N.V. completed image analysis. A.N.V. and C.H.B. individually selected the best image for subsequent analysis (Jenkins et al., 2015). If these researchers did not agree on which image was best, a third experienced researcher (D.H.F.) selected the best image of the two. Intra-class correlation coefficients using model “3,1” (ICC_{3,1}), standard error of measurements (SEM), minimal differences (MD), and coefficients of variation (CV) between the CSA of the best PTI taken on two separate days were determined to be: ICC_{3,1} = 0.984; SEM = 1.073 cm²; MD = 2.974 cm²; CV = 2.105%.

Echo Intensity of the Vastus Lateralis in Panoramic Transverse Images

EI of the PTI (EI_{PTI}) was quantified within the region of interest previously demarcated for CSA_{PTI} determination. EI of the traced polygon was determined using the standard histogram function in ImageJ. Quantification of the grayscale of each individual pixel in the region of interest was expressed as a value between 0-255 arbitrary units (AU) (0: black; 255: white) (Pillen, 2010; Scanlon et al., 2014; Wells et al., 2014). The grayscale of each individual pixel was then projected on a histogram plot (Pillen, 2010; Scanlon et al., 2014; Wells et al., 2014). EI_{PTI} was quantified as the mean grayscale of the entire region of interest. A sample image for EI_{PTI} analysis is presented in Figure 4. A sample histogram plot of EI_{PTI} is presented in Figure 5.

Inter-day reliability for EI_{PTI} was completed on a separate sample of participants. The same methods described previously for inter-day reliability were used. $ICC_{3,1}$, SEM, MD, and CV between the EI of best PTI taken on two separate days were determined to be: $ICC_{3,1} = 0.718$; SEM = 3.117 AU; MD = 8.641 AU; CV = 4.589%.

Muscle Thickness of the Vastus Lateralis in Panoramic Transverse Images

MT from PTI (MT_{PTI}) was determined by identifying the outline of the VL in the PTI. The line tool and overlay options in ImageJ were then used to draw vertical lines on the most-anterior and most-posterior borders of the muscle. The horizontal distance between the anterior and posterior borders of the muscle was measured, and this distance was divided into equal halves. The line tool and overlay options were used to mark the location of midline on the image at a location away from the muscle. One vertical line was then drawn through the muscle at the midpoint using the line tool and overlay option. MT, which is defined as the distance between the inferior border of the superficial aponeurosis and the superior border of the deep aponeurosis, was then measured using the line tool at the aforementioned midpoint of the muscle (Wells et al., 2014). A sample MT_{PTI} quantification is represented in Figure 6.

Inter-day reliability for MT_{PTI} was completed on a separate sample of participants. The same methods described previously for inter-day reliability were used. $ICC_{3,1}$, SEM, MD, and CV between the MT of the best PTI taken on two separate days were determined to be: $ICC_{3,1} = 0.914$; SEM = 0.083 cm; MD = 0.230 cm; CV = 2.905%.

Subcutaneous Adipose Tissue Thickness Adjacent to the Vastus Lateralis in Panoramic Transverse Images

SubQ from PTI (SubQ_{PTI}) was assessed using the same US images that were previously used to quantify CSA_{PTI} , EI_{PTI} , and MT_{PTI} in ImageJ. SubQ is defined as the distance between the inferior border of the epithelium and the superior border of the superficial aponeurosis (Young, Jenkins, Zhao, & McCully, 2015). To quantify SubQ_{PTI} , the same midpoint that was previously used for MT_{PTI} was subsequently used for further analysis. The vertical line through the midpoint of the VL was extended throughout the image to include the subcutaneous fat layer. The line tool in ImageJ was then used to measure the distance between the inferior border of the epithelium and the superior border of the superficial aponeurosis. A sample SubQ_{PTI} quantification is represented in Figure 7.

Inter-day reliability for SubQ_{PTI} was completed on a separate sample of participants. The same methods described previously for inter-day reliability were used. $\text{ICC}_{3,1}$, SEM, MD, and CV between the SubQ of the best PTI taken each on two separate days were determined to be: $\text{ICC}_{3,1} = 0.987$; SEM = 0.063 cm; MD = 0.175 cm; CV = 8.243%.

Analysis of Single Still Longitudinal Images

Cross-Sectional Area of the Vastus Lateralis in Still Longitudinal Images

CSA of the VL was also assessed using US images taken in the longitudinal plane, parallel to the long axis of the muscle. SLI were captured at 50% of the distance from the greater trochanter and the lateral epicondyle of the femur (Scanlon et al., 2014; Wells et al., 2014).

Three consecutive still-images were captured at the same anatomical location by the same investigator to determine within-day precision.

Out of the three SLI captured from each participant, two experienced researchers (A.N.V. and C.H.B.) individually selected the best image for subsequent analysis (Jenkins et al., 2015). If the researchers did not agree on which image was best, a third experienced researcher (D.H.F.) selected the best image of the two chosen by A.N.V. and C.H.B. Requirements for best still image selection can be found in Appendix D.

In ImageJ, the outline of the VL was located and traced using the polygon function tool to obtain as much lean mass as possible without including any surrounding bone, fascia, or image outline (Wells et al., 2014). Because the entire area of the muscle was not included in a single image, CSA of the SLI (CSA_{SLI}) was limited to the size of the frame. The right and left sides of the traced polygon consisted of perfectly vertical lines that aligned with the edges of the image, whereas the superficial and deep lines of the ImageJ polygon corresponded to the muscle-aponeurosis interface. The total area of the traced polygon was then calculated and reported in cm^2 . A sample CSA_{SLI} quantification is presented in Figure 8.

Inter-day reliability for CSA_{SLI} was completed on a separate sample of participants. The same methods described previously for inter-day reliability were used. $ICC_{3,1}$, SEM, MD, and CV between the CSA of the best SLI taken on two separate days were determined to be: $ICC_{3,1} = 0.871$; $SEM = 0.351 \text{ cm}^2$; $MD = 0.973 \text{ cm}^2$; $CV = 4.513\%$.

Echo Intensity of the Vastus Lateralis in Still Longitudinal Images

The EI of the SLI (EI_{SLI}) was quantified using the same images and outlines that were used to simultaneously quantify CSA_{SLI} using ImageJ. EI of the traced polygon was determined using the standard histogram function in ImageJ as the mean grayscale of the region of interest.

Inter-day reliability for EI_{SLI} was completed on a separate sample of participants. The same methods described previously for inter-day reliability were used. $ICC_{3,1}$, SEM, MD, and CV between the EI of the best SLI taken on two separate days were determined to be: $ICC_{3,1} = 0.776$; SEM = 4.264 AU; MD = 11.818 AU; CV = 5.564%.

Muscle Thickness of the Vastus Lateralis in Still Longitudinal Images

MT from SLI (MT_{SLI}) was quantified using the straight line tool in ImageJ at 50% of the horizontal distance of the image length. A sample MT_{SLI} quantification is presented in Figure 9.

Inter-day reliability for MT_{SLI} was completed on a separate sample of participants. The same methods described previously for inter-day reliability were used. $ICC_{3,1}$, SEM, MD, and CV between the MT of the best SLI taken on two separate days were determined to be: $ICC_{3,1} = 0.889$; SEM = 0.082 cm; MD = 0.226 cm; CV = 4.613%.

Subcutaneous Adipose Tissue Thickness Adjacent to the Vastus Lateralis in Still Longitudinal Images

SubQ from SLI (SubQ_{SLI}) was quantified using the straight line tool in ImageJ at 50% of the horizontal distance of the image length. A sample SubQ_{SLI} quantification is presented in Figure 10.

Inter-day reliability for SubQ_{SLI} was completed on a separate sample of participants. The same methods described previously for inter-day reliability were used. $\text{ICC}_{3,1}$, SEM, MD, and CV between the CSA of the best SLI taken on two separate days were determined to be: $\text{ICC}_{3,1} = 0.993$; SEM = 0.057 cm; MD = 0.158 cm; CV = 9.186%.

Compartmentalization of the Vastus Lateralis

To examine the heterogeneity of EI, the best PTI that were previously used for CSA_{PTI} , EI_{PTI} , MT_{PTI} , and SubQ_{PTI} quantification were further analyzed. Each image was divided into three compartments using ImageJ. To do this, the outline of the VL was identified and vertical lines were drawn on the most-anterior and most-posterior borders of the muscle using the line tool and overlay options. The horizontal distance between the anterior and posterior borders of the muscle was then measured, and this distance was divided into equal thirds. The line tool and overlay option was used to mark the location of each tertile on the image at a location away from the muscle. Two vertical lines were then drawn through the muscle at the tertile marks to break the VL into three compartments using the line tool and overlay option. The three compartments of the VL were classified as the anterior tertile (AT), lateral tertile (LT), and posterior tertile (PT)

tertiles depending on anatomical location. A sample PTI broken up into 3 compartments (AT, LT, and PT) is depicted in Figure 11.

Cross-Sectional Area of Individual Tertiles

The CSA of each of the three tertiles was quantified using the best PTI which had been subsequently broken up into three compartments of equal length. The AT of the VL was located on the right-hand side of the US image, the LT of the VL was located in the center of the US image, and the PT of the VL was located on the left-hand side of the US image as a result of the probe placement and manipulation during scanning. Individual tertiles were easily identified as a result of the anatomically asymmetrical shape of the VL in the transverse plane. The anterior part of the VL is inherently thicker than the posterior part of the muscle, making anatomical identification of different sub-compartments fairly easy (Blazevich, Gill, & Zhou, 2006). The CSA of each compartment was quantified offline using ImageJ. To quantify CSA of the AT (CSA_{AT}), the outline of the AT was located in the image and was traced using the polygon function tool to obtain as much lean mass as possible without including any surrounding bone, fascia, or image outline (Wells et al., 2014). The total area of the traced polygon was then calculated and reported in cm^2 . To quantify CSA of the LT (CSA_{LT}), the outline of the LT was located in the image and was traced using the polygon function tool to obtain as much lean mass as possible without including any surrounding bone, fascia, or image outline (Wells et al., 2014). The total area of the traced polygon was then calculated and reported in cm^2 . Finally, to quantify CSA of the PT (CSA_{PT}), the outline of the PT was located in the image and was traced using the polygon function tool to obtain as much lean mass as possible without including any surrounding

bone, fascia, or image outline (Wells et al., 2014). The total area of the traced polygon was then calculated and reported in cm².

Echo Intensity of Individual Tertiles

The EI of each of the three compartments of the VL was quantified using the same US images and outlines used to quantify individual tertile CSA. EI of the AT (EI_{AT}), EI of the LT (EI_{LT}), and EI of the PT (EI_{PT}) were determined using the standard histogram function in ImageJ as the mean grayscale of the selected region of interest.

Statistical Analysis

Intra-examiner precision between three consecutive PTI and three consecutive SLI captured from each subject was analyzed using SEM for CSA, EI, MT, and SubQ. The following equation was used to calculate SEM (Vincent and Weir, 2012; Weir, 2005):

$$SEM = \sqrt{MS_E}$$

The SEM indicates how precise a measurement is compared to its true value and it is not sensitive to within- or between-subject variability (Vincent and Weir, 2012; Weir, 2005).

Additionally, the coefficient of variation (CV) for each variable was calculated, which normalized the standard deviations of each measurement to the mean. The equation for CV is as follows (Vincent and Weir, 2012):

$$CV = \frac{SD_x}{\bar{x}} \times 100$$

In this equation, SD_x represents the standard deviation of the sample, and \bar{x} represents the sample mean. Lower CVs indicate greater reproducibility between measurements.

A data analysis software was used to complete further statistical analysis (SPSS for Windows, version 21.0, SPSS Inc., Chicago, Illinois, United States). Shapiro-Wilk tests were used to determine normality for each variable. In the case of a non-normally distributed variable, equivalent non-parametric statistics were used. EI_{PTI} , EI_{SLI} , EI_{AT} , EI_{LT} , and EI_{PT} , as well as CSA_{PTI} , CSA_{SLI} , CSA_{AT} , CSA_{LT} , and CSA_{PT} data obtained from the best images and tertiles of the VL were analyzed using a one-way repeated measures analysis of variance (ANOVA). In the event of a significant main effect, a Bonferroni-adjusted *post hoc* comparison was performed between groups. A dependent *t*-test was used to examine the null hypothesis that MT_{PTI} and MT_{SLI} were not statistically different. Because $SubQ_{PTI}$ and $SubQ_{SLI}$ were not normally distributed, a Wilcoxon *t*-test was used to examine the null hypothesis that $SubQ_{PTI}$ and $SubQ_{SLI}$ were not statistically different. Additionally, Pearson product-moment correlation coefficients were used to evaluate relationships between various dependent variables using the best PTI and SLI. In the event of a non-normally distributed variable, Spearman's rho rank correlation coefficients were used instead of Pearson product-moment correlations (Caresio et al., 2014; Fredricks and Nelsen, 2007; O'Donoghue, 2013). Interpretation of the correlation coefficients were as follows: 0.00 – 0.30: little to no correlation; 0.30 – 0.50: low/weak correlation; 0.50 – 0.70: moderate correlation; 0.70 – 0.90: high/strong correlation; 0.90 – 1.00: very high/very strong correlation (Hinkle, Wiersma, & Jurs, 2003).

All data are reported as mean \pm standard deviation unless otherwise noted. Results

were considered significant at an alpha-level of $p \leq 0.05$. All data analysis was performed using SPSS version 21.0 (SPSS Inc., Chicago, Illinois, United States).

Differences between two dependent correlation coefficients with one variable in common were tested using a method proposed by Steiger (1980). This method was used to determine if one correlation was significantly different than another correlation with one common variable. First, each correlation coefficient of interest was converted into a z -score using Fisher's r -to- z transformation (Mudholkar, 1983). Then, differences between correlation coefficients were computed using equations previously described by Steiger (1980). The two correlation coefficients to be compared (i.e., r_{xy} and r_{yz}), along with the correlation coefficient between the two unshared variables (i.e., r_{xz}), and the sample size were inputted into a computer software (Calculation for the test of the difference between two dependent correlations with one variable in common, Vanderbilt University, Nashville, TN, USA). The p -value associated with a two-tailed test of significance was then computed. Results were considered significant at an alpha-level of $p \leq 0.0083$ after a Bonferroni correction factor was applied:

$$\text{Bonferroni – corrected alpha – level} = \frac{\text{significance level of Pearson's correlation}}{\text{number of total correlation comparisons}}$$

When substituting the appropriate values in this equation, the results are as follows:

$$\frac{0.05}{6} = 0.0083$$

An alpha level of $p \leq 0.0083$ was used to determine if one correlation was significantly different from another.

CHAPTER FOUR: RESULTS

Twenty-four individuals were included in the final analysis out of 25 participants initially recruited. Participant characteristics and anthropometric data are expressed in Table 1.

The SEM and CV for each variable indicated high inter-image precision between all images and variables measured, however SLI yielded slightly better precision values. Precision measures are reported in Table 2.

Shapiro-Wilk tests for normality indicated that all measures of VL muscle morphological characteristics were normally distributed except for SubQ_{PTI} and SubQ_{SLI}. Table 3 lists results for measures of EI, CSA, MT, and SubQ between images and tertiles.

A repeated-measures ANOVA revealed a significant main effect for image/tertile between measures of CSA ($F_{4,92} = 347.852$, $p < 0.001$, $\eta^2 = 0.938$). A Bonferroni-adjusted *post hoc* analysis revealed that the CSA_{PTI} was significantly greater than CSA_{SLI} ($p < 0.001$), CSA_{AT} ($p < 0.001$), CSA_{LT} ($p < 0.001$), and CSA_{PT} ($p < 0.001$). Additionally, the CSA_{SLI} was significantly less than the CSA_{AT} ($p < 0.001$), CSA_{LT} ($p < 0.001$), and CSA_{PT} ($p = 0.041$). The CSA_{AT} was significantly greater than CSA_{LT} ($p < 0.001$) and CSA_{PT} ($p < 0.001$), whereas the CSA_{LT} was significantly greater than CSA_{PT} ($p < 0.001$). CSA_{PTI} and CSA_{SLI} values are displayed in Figure 12.

All CSA measures were significantly positively correlated with one another. Moderate to very strong correlations existed between CSA_{PTI} and all other measures of CSA (CSA_{PTI} and CSA_{AT}: $r = 0.934$; $p < 0.001$; CSA_{PTI} and CSA_{LT}: $r = 0.926$; $p < 0.001$; CSA_{PTI} and CSA_{PT}: $r = 0.876$; $p < 0.001$). Moderate to strong correlations existed between CSA_{SLI} and all other

measures of CSA (CSA_{SLI} and CSA_{AT} : $r = 0.564$; $p = 0.004$; CSA_{SLI} and CSA_{LT} : $r = 0.810$; $p < 0.001$; CSA_{SLI} and CSA_{PT} : $r = 0.687$; $p < 0.001$). Additionally, moderate to strong correlations existed between CSA_{AT} and other measures of CSA (CSA_{AT} and CSA_{LT} : $r = 0.796$; $p < 0.001$; CSA_{AT} and CSA_{PT} : $r = 0.703$; $p < 0.001$). Strong to very strong correlations existed between measures of CSA_{LT} and all other measures of CSA (CSA_{LT} and CSA_{PT} : $r = 0.879$; $p < 0.001$). CSA_{PTI} and CSA_{SLI} were significantly negatively correlated with both EI_{PTI} and EI_{SLI} . CSA_{PTI} , CSA_{SLI} , EI_{PTI} , and EI_{SLI} are represented in Figure 13.

A repeated-measures ANOVA revealed a significant main effect for image/tertile between measures of EI ($F_{4,92} = 11.517$, $p < 0.001$, $\eta^2 = 0.334$). A Bonferroni-adjusted *post hoc* analysis revealed that EI_{PTI} was significantly lower than EI_{SLI} ($p = 0.002$). Additionally, EI_{SLI} was significantly greater than EI_{LT} ($p = 0.001$) and EI_{PT} ($p = 0.002$). Although there was no significant difference between EI_{SLI} and EI_{AT} , a trend towards a significant difference was revealed ($p = 0.051$). However, no significant differences existed between EI_{AT} and any other measures of EI (EI_{AT} and EI_{PTI} : $p = 1.000$; EI_{AT} and EI_{LT} : $p = 1.000$; EI_{AT} and EI_{PT} : $p = 1.000$). Additionally, no significant differences were noted between EI_{PTI} and EI of any of the tertiles (EI_{PTI} and EI_{LT} : $p = 1.000$; EI_{PTI} and EI_{PT} : $p = 1.000$), or between EI_{LT} and EI_{PT} ($p = 0.881$). Individual data for EI are reported as open circles in Figure 14.

Table 4 lists the Pearson product-moment correlations among EI variables measured in different images and tertiles. Correlation coefficients between all measures of EI ranged from moderate to very high. EI_{PTI} was significantly positively correlated with all other measures of EI ($p < 0.001$). EI_{SLI} was also significantly positively correlated with all measures of EI ($p < 0.011$).

EI_{AT}, EI_{LT}, and EI_{PT} were all significantly positively correlated with all other measures of EI ($p < 0.011$). EI_{SLI} compared to EI_{PTI}, EI_{AT}, EI_{LT}, and EI_{PT} is represented in Figure 15.

Steiger's Z-test revealed that there were significant differences between correlation coefficients for measures of EI. The correlation between EI_{SLI} and EI_{PTI} was significantly greater than the correlation between EI_{SLI} and EI_{AT} ($p = 0.0067$). However, the correlation between EI_{SLI} and EI_{PTI} was significantly lower than the correlation between EI_{SLI} and EI_{LT} ($p = 0.0036$). No significant differences in correlation coefficients were found between EI_{SLI} and EI_{PTI} or between EI_{SLI} and EI_{PT} ($p = 0.0725$).

Upon examination of the correlation coefficients of EI of individual tertiles compared to EI_{SLI}, the correlation between EI_{SLI} and EI_{AT} was significantly lower than the correlation between EI_{SLI} and EI_{LT} ($p = 0.0006$). Furthermore, the correlation between EI_{SLI} and EI_{PT} was significantly lower than the correlation between EI_{SLI} and EI_{LT} ($p = 0.0027$). However, no significant differences in correlation coefficients were found between EI_{SLI} and EI_{AT} or between EI_{SLI} and EI_{PT} ($p = 0.9411$).

A dependent *t*-test between MT_{PTI} and MT_{SLI} revealed that MT_{PTI} was significantly greater than MT_{SLI} ($p = 0.003$), however MT_{PTI} and MT_{SLI} were significantly positively correlated. MT_{PTI} and MT_{SLI} values are displayed in Figure 16.

A Wilcoxon *t*-test between SubQ_{PTI} and SubQ_{SLI} revealed that SubQ_{SLI} was greater than SubQ_{PTI} ($p < 0.001$), however SubQ_{SLI} and SubQ_{PTI} were significantly positively correlated. SubQ_{PTI} and SubQ_{SLI} values are displayed in Figure 17.

Table 5 lists the Pearson product-moment correlations or Spearman's rho correlations among selected variables. Non-significant weak correlations were discovered between MT_{PTI} and

MT_{SLI} with $SubQ_{PTI}$ and $SubQ_{SLI}$. Moderate to very strong significant positive correlations were found between MT_{PTI} and MT_{SLI} with all measures of CSA. Additionally, significant weak to moderate negative correlations were found between MT_{PTI} and MT_{SLI} and measures of EI. MT and EI values measured from different images are displayed in Figure 18. $SubQ_{PTI}$ and $SubQ_{SLI}$ were significantly positively correlated with CSA_{PTI} , but were not significantly correlated with CSA_{SLI} . Neither measure of SubQ was correlated with EI_{SLI} or EI_{PTI} . SubQ and EI measures from different images are represented in Figure 19.

CHAPTER FIVE: DISCUSSION

Several studies have utilized ultrasonography to examine skeletal muscle EI and its relationship to muscular strength, cardiovascular endurance, and anaerobic sports performance (Cadore et al., 2012; Fukumoto et al., 2012; Jajtner et al., 2014; Mangine et al., 2014a; Mangine et al., 2014b; Mangine et al., 2014c; Melvin et al., 2014; Scanlon et al., 2014; Strasser, Draskovits, Praschak, Quittan, & Graf, 2013; Watanbe et al., 2013; Wells et al., 2014; Wilhelm et al., 2014). Additionally, previous research has discovered that inter- and intra-muscular adaptations to resistance exercise may alter muscle morphology in a heterogeneous way (Ema, Wakahara, Miyamoto, Kanehisa, & Kawakami, 2013; Seynnes, de Boer, & Narici, 2007; Wakahara et al., 2012; Wells et al., 2014). However, few studies have examined the variability of EI within and between muscle groups (Caresio, Molinari, Emanuel, & Minetto, 2014; Jenkins et al., 2015; Young, Jenkins, Zhao, & McCully, 2015). To our knowledge, this is the first study to compare EI of different compartments and different images of the VL in the DOM limb. The main findings of this study suggest that EI_{SLI} is significantly greater than EI_{PTI} taken within the same muscle, but significant positive correlations existed between EI values obtained from the two different types of images. Additionally, the use of the SLI yielded slightly lower CVs and SEM for all measurements (CSA_{SLI} , EI_{SLI} , MT_{SLI} , and $SubQ_{SLI}$) compared to PTI (CSA_{PTI} , EI_{PTI} , MT_{PTI} , and $SubQ_{PTI}$), indicating better precision compared to PTI. Also, after dividing the PTI of the VL into three compartments of equal length, EI_{SLI} was significantly greater than EI of two of the compartments (EI_{LT} and EI_{PT}), and a trend towards significance was seen in the third compartment (EI_{AT}). However, no significant differences in EI values existed between any of the three compartments. Other main findings of this study are that significant differences in

correlations coefficients existed between EI of different images of the VL and EI of individual tertiles. Furthermore, no significant correlations were discovered between SubQ_{PTI} and SubQ_{SLI} with EI_{PTI} or EI_{SLI}.

EI_{SLI} provided significantly greater values than EI_{PTI} (65.453 ± 11.023 AU vs. 57.976 ± 8.806 AU, respectively). Despite these values being significantly positively correlated with each other, the discrepancies between values are most likely a result of the scanning plane. The SLI was captured in the longitudinal plane, parallel to the long axis of the VL. This produced a US image with visible striations throughout the entire image area, which was primarily a result of fascia and connective tissue between individual fascicles (Pillen, 2010). The fascia and connective tissue appear hyperechoic in nature in a US image, whereas the muscle fibers themselves appear relatively hypoechoic due to a difference in the impedance of sound waves through certain tissues (Ihnatsenka and Boezaart, 2010). In SLI, the length of the fascia or connective tissue can be visualized throughout the entire thickness of the muscle. Because EI in itself is an average measure of brightness in a defined region of interest, the lightly-colored striations in the SLI likely caused the brightness of the region of interest to increase, therefore increasing EI (Nielsen, Jensen, Darvann, Jorgensen, & Bakke, 2006; Pillen, 2010; Pillen and van Alfren, 2011). In contrast, the PTI produced a US image with a speckled appearance due to the cross-sectioning of individual fascicles, connective tissue, and fascia in the transverse plane (Pillen, 2010). Since these images did not contain visible striations of hyperechoic tissue similar to what was displayed in the SLI, it is likely that this alone may have caused EI_{PTI} to be lower than EI_{SLI}. Another potential reason for the differences in EI values between images may be a result of the probe placement during PTI and SLI examination. During SLI examination of the VL, the probe is physically placed in a different anatomical location along the muscle compared

to that during PTI assessment. The SLI encompasses portions of the muscle in slightly proximal and distal locations from 50% of the straight-line distance from the greater trochanter to the lateral epicondyle of the femur in the longitudinal plane, whereas the PTI encompasses portions of the muscle in the anteromedial and posterolateral directions. Previous research has shown that EI differs between distal and proximal locations within an individual muscle and that EI is dependent on scanning location (Young, Jenkins, Zhao, & McCully, 2015). For example, Young and colleagues (2015) discovered significant differences in muscle EI between still images taken at proximal and distal locations of the rectus femoris, biceps femoris, and medial gastrocnemius. EI was significantly greater in the proximal portion of the rectus femoris and the medial gastrocnemius compared to the distal portion, but was significantly lower in the proximal portion of the biceps femoris compared to the distal portion (Young, Jenkins, Zhao, & McCully, 2015). In the present study, the SLI was captured in the longitudinal plane and encompassed small portions of the muscle in slightly proximal and slightly distal locations. In contrast, the PTI was captured at 50% of the straight-line distance from the greater trochanter to the lateral epicondyle of the femur and did not include any portion of the VL in the longitudinal plane. It is possible that, because the SLI contained proximal and distal portions of the VL, some of the muscle included may have had a greater EI compared to that contained in the PTI.

Upon division of the PTI into individual tertiles, EI_{AT} , EI_{LT} , and EI_{PT} were not significantly different from one another ($p > 0.8$). In addition, EI_{AT} , EI_{LT} , and EI_{PT} were not significantly different from EI_{PTI} ($p = 1.000$). This contradicts the findings of Caresio and colleagues (2014), who discovered significant differences in muscle EI within still transverse images of the rectus femoris and tibialis anterior. In this study, the EI of a square-shaped region of interest in both the lateral and medial regions of the rectus femoris within the same US image

were examined. EI was significantly greater in the medial region of the muscle compared to the lateral region ($p < 0.05$). In our study, no significant differences in EI were discovered between anteromedial or posterolateral compartments of the VL, as the EI_{AT} , EI_{LT} , and EI_{PT} were not significantly different from one another. A possible explanation for this may be that while the rectus femoris and vastus lateralis both assist in leg extension, they have considerably different fiber architecture arrangements. The rectus femoris is a bipennate muscle, meaning that fibers within the muscle are oriented in two different directions on opposite sides of the tendon on the force-generating axis (Moreau, Teefey, & Damiano, 2009). In contrast, the vastus lateralis is a unipennate muscle, and the fascicles are oriented in only one direction on one side of the tendon of the force-generating axis (Moreau, Teefey, & Damiano, 2009). Differences in muscle fiber architecture have a profound effect on skeletal muscle EI (Arts et al., 2012; Caresio, Molinari, Emanuel, & Minetto, 2014; Jajtner et al., 2014; Mangine et al., 2014c; Pillen, 2010; Reimers et al., 1993; Scanlon et al., 2014; Strasser, Draskovits, Praschak, Quittan, & Graf, 2013; Young, Jenkins, Zhao, & McCully, 2015). Previous research has discovered significantly different EI values between muscle groups in healthy males and females (Caresio et al., 2014; Strasser et al., 2013; Young, Jenkins, Zhao, & McCully, 2015). Jajtner et al. (2014), Mangine et al. (2014c), and Scanlon et al. (2014) discovered significant differences in EI with respect to different muscles of the leg, including the rectus femoris and VL. Differences in EI values between muscles are probably a result of the amount of connective or fibrous tissue within the muscle, fiber type distribution, intramuscular triglyceride arrangement, and architectural features of fascicles and their orientation within the muscle (Caresio, Molinari, Emanuel, & Minetto, 2014). The findings of the present study may have contradicted those of Caresio et al. (2014) due to the differences in fiber distribution and orientation between the VL and rectus femoris. The

bipennate structure of the rectus femoris may have resulted in EI values that differed between medial and lateral regions of the muscle due to differences in fascicle architecture and distribution (Caresio, Molinari, Emanuel, & Minetto, 2014; Moreau, Teefey, & Damiano, 2009). Unlike the rectus femoris, the VL has a uniform pennation arrangement of fascicles throughout the entire muscle, which may provide reason for why no significant differences in EI between tertiles were seen in the present study (Moreau, Teefey, & Damiano, 2009).

Despite finding no significant differences in EI between tertiles, there was a significant difference between in EI between SLI and both LT and PT ($p < 0.002$). However, a trend toward significance a trend toward significance discovered between EI_{SLI} and EI_{AT} ($p = 0.051$). A possible explanation for this may be the differing depths of the VL captured in each tertile. Although each tertile was the same width horizontally, the inherent muscle architecture of the VL likely caused the CSA of each tertile to be significantly different due to the inconsistent depths of the muscle contained in each compartment. The VL is asymmetrical in the transverse plane, where the anteromedial portion of the muscle is thicker than the posterolateral portion (Blazevich, Gill, & Zhou, 2006; Wells et al., 2014). The anteromedial portion of the VL corresponded with the AT in the present study, which was associated with a significantly larger CSA compared to in the LT and PT. In the AT, the VL protrudes deeper within the US image compared to the LT or the PT. This difference in muscle depth may non-systematically affect image quality and resolution due to the different reflectance of sound waves off of the tissue of interest. Ihnatsenka and Boezaart (2010) stated that high-frequency probes, similar to the one used in the present study, are preferred when examining superficial tissues at a maximum of 4-5 cm from the surface of the skin. While this type of probe may be appropriate for examination of the PT and the LT in the present study, examination of the AT with a high-frequency probe may

result in compromised image resolution, especially in a trained population (Ihnatsenka and Boezaart, 2010). Resistance-trained athletes often have thicker muscles with increased cross-sectional areas compared to those in an untrained population, which is primarily due to hypertrophy of individual muscle fibers (Charette, et al. 1991; Ikai and Fukunaga, 1970; McCall, Byrnes, Dickinson, Pattany, & Fleck, 1996; Narici, Roi, Landoni, Minettu, & Cerretelli, 1989; Scanlon et al., 2014; Seynnes, de Boer, & Narici, 2007). In a trained population, possessing a large muscle thickness may not permit the entire muscle area to be viewed using a US depth of 5 cm or less. Increasing the image depth of the US may allow for visualization of the entire muscle, but would further decrease image resolution. Additionally, possessing greater amounts of SubQ may restrict the amount of muscle area that can fit in a US image. This may decrease image resolution if the depth of the image were to be increased to include the entire muscle area. Furthermore, previous research has shown that increasing amounts of SubQ may non-systematically affect the reflectance of an ultrasound beam off of a tissue of interest (Pillen and van Alfen, 2011). It is possible that, upon examination of the AT, a midrange-frequency probe may be more appropriate to use if the tissue of interest does not fit into a US image with a depth of 5 cm. This may be especially important in a resistance-trained population if the size of the muscle is large due to an increased muscle thickness and hypertrophy (Ihnatsenka and Boezaart, 2010; Ikai and Fukunaga, 1970; McCall, Byrnes, Dickinson, Pattany, & Fleck, 1996). However, the depth of the ultrasound beam in the current study was maintained at 5 cm to ensure consistent image quality between subjects. Although subjects were excluded from the study if the entire area of the VL was unable to fit in a PTI, possessing a thicker VL may have resulted in a decreased image resolution especially in the deeper portion of the AT. A decreased image

resolution in the AT may have resulted in EI values that were not significantly different from those of the SLI, which may provide possible evidence for the trend towards significance.

Another possible explanation for the non-significant difference discovered between EI_{AT} and EI_{SLI} may be due to the differences in EI between deep and superficial tissues. Research conducted by Caresio and colleagues (2014) discovered that there were significant differences in EI values between superficial and deep portions of the tibialis anterior muscle on a transverse still US image. In this study, the EI of a square-shaped region of interest in the deep region of the tibialis anterior was significantly greater than the EI of a rectangular-shaped region of interest in the superficial region. In the present study, there was no significant difference between EI_{AT} and EI_{SLI} ($p = 0.051$), although the EI_{SLI} had significantly greater values than EI_{PTI} , EI_{LT} , and EI_{PT} . One explanation for this may be that the AT encompasses more of the VL in the deep portion of the US image compared to the PT and AT. If EI within the deep portion of the VL was greater than EI within the superficial portion of the VL, similar to the findings of Caresio and colleagues (2014), this may have resulted in a slightly greater EI values for the AT compared to those of the other tertiles. Although the present study did not measure differences in EI between superficial and deep compartments of the VL, perhaps the fact that the AT encompassed more of the muscle in a deeper location resulted in a slightly higher EI.

Pearson product-moment correlation coefficients calculated between measures of EI for all images and tertiles revealed that all measures of EI were significantly positively correlated with one another ($p > 0.011$). However, the correlation between EI_{SLI} and EI_{PTI} was significantly greater than the correlation between EI_{SLI} and EI_{AT} , significantly lower than the correlation between EI_{SLI} and EI_{LT} , and was not significantly different from the correlation between EI_{SLI}

and EI_{PT} . Additionally, the correlation between EI_{SLI} and EI_{LT} was significantly greater than the correlation between EI_{SLI} and either of the other tertiles. These results may provide further evidence that muscle depth has a large effect on EI. For example, the SLI was captured at 50% of the straight-line distance from the greater trochanter to the lateral epicondyle of the femur in the longitudinal plane. If, instead, this still image had been taken in the transverse plane but at the same location, the resulting image may have looked similar to a still image of the LT. This is because the LT encompasses a transverse image of the VL at the midpoint of the straight-line distance from the greater trochanter to the lateral epicondyle of the femur which corresponds to the center of the muscle, whereas the PT and AT capture transverse images of the VL in the posterolateral and anteromedial directions from this point, respectively. Image capture of the SLI is completed on the lateral side of the leg in the muscle belly of the VL. Therefore, the midpoint of the LT is also located on lateral side of the leg, in the muscle belly of the VL. Although the posterolateral location of the SLI in the transverse plane is not directly measured, MT_{SLI} and MT_{LT} may be related to one another because they are captured in approximately the same location from the same muscle. Therefore, image resolution should be affected to approximately the same extent in both of these types of pictures due to similar MT and SubQ values (Ihnatsenka and Boezaart, 2010). This may explain why significantly greater correlations were discovered between EI_{SLI} and EI_{LT} compared to the correlation between EI_{SLI} and EI_{PT} , EI_{SLI} and EI_{AT} , and EI_{SLI} and EI_{PTI} . In addition, the significantly greater correlation between EI_{SLI} and EI_{PTI} compared to that of EI_{SLI} and EI_{AT} was likely a result of the amount of deep muscle that the AT encompassed. Ihnatsenka and Boezaart (2010) proposed that a greater MT may increase the likelihood of non-systematic error in resolution of the structure of interest. Since the AT

encompasses the VL in deeper locations compared to the LT or PT, the thickness of the muscle in the AT may have affected its resolution in a US image.

Although the measurements of CSA_{SLI} and CSA_{PTI} were significantly positively correlated ($r = 0.752$, $p < 0.001$), CSA_{PTI} was significantly greater than CSA_{SLI} ($p < 0.001$). Additionally, CSA_{PTI} and CSA_{SLI} were significantly positively correlated with MT_{SLI} and MT_{PTI} , indicating that both CSA and MT may be used interchangeably for quantification of muscle size. Furthermore, CSA_{SLI} was significantly less than CSA_{AT} , CSA_{LT} , or CSA_{PT} , while CSA_{PTI} was significantly greater than CSA_{AT} , CSA_{LT} , or CSA_{PT} . This is intuitive because the SLI and each of the tertiles encompass a much smaller muscle area compared to the PTI. Although the PTI of the VL was divided into three compartments of equal length, the CSA of each compartment was significantly different from one another. Differences between CSA_{AT} , CSA_{LT} , and CSA_{PT} were due to reasons discussed previously regarding the morphology of the VL in the transverse plane. However, previous research has also demonstrated that resistance training may cause non-homogeneous muscle architectural adaptations in the transverse plane occur, which may be dependent on the regional activation of the muscle (Ema, Wakahara, Miyamoto, Kanehisa, & Kawakami, 2013; Wells et al., 2014). For example, one of the first studies to measure the mediolateral changes in muscle architecture with resistance training was completed by Ema and colleagues (2013), who discovered that a 12-week knee-extensor resistance training program elicited significantly greater increases in the MT of the vastus intermedius medially compared to laterally in 11 healthy males. Although these researchers did not directly measure muscle activation, they attributed their findings to the possibility of disproportionate amounts of muscle activation in the anterior compared to posterior regions of the muscle (Akima et al., 1999; Akima et al., 2004). Akima and colleagues (1999) discovered that isokinetic knee extensor training

muscle activation was greater in the anteromedial portion of the vastus intermedius compared to the posterolateral portion, which could account for differences in hypertrophy between medial and lateral parts of the muscle. Another study examining the mediolateral changes in muscle architecture was conducted by Wells and colleagues (2014), demonstrating that a 15-week off-season resistance training program in female soccer players elicited significantly greater increases in MT of the VL medially compared to laterally. However, there were no significant differences in CSA of the VL after the training program, despite a significant increase in barbell back squat strength (Wells et al., 2014). In the present study, subjects had experienced an off-season training regimen and were examined during the transition from the pre-season to the competition season. These subjects may have experienced increases in VL MT similar to those described by Wells et al. (2014), where the MT of the medial portion of the muscle may have increased to a greater extent than the lateral portion. With greater increases in MT in one portion of the muscle compared to another, this may affect the CSA of individual tertiles to an even greater extent and may contribute to greater discrepancies in CSA between the compartments. However, one limitation in the present study is that the off-season and in-season training programs were not structured or recorded, and actual changes in VL MT or CSA throughout the training period could not be determined. Future research should look to examine the changes in CSA of compartments of the VL along with MT over the course of a training season.

Measurements of $SubQ_{SLI}$ and $SubQ_{PTI}$ were significantly positively correlated with one another, and measurements of MT_{SLI} and MT_{PTI} were significantly positively correlated with one another. However, $SubQ_{SLI}$ was significantly greater than $SubQ_{PTI}$, whereas MT_{PTI} was significantly greater than MT_{SLI} . A potential explanation for this is the anatomical location of the US probe placement during SLI examination compared to the anatomical location of the probe

placement during PTI examination. The PTI encompasses the entire area of the VL in the transverse plane, so making direct horizontal measurement and demarcation of the midpoint of the muscle for SubQ_{PTI} and MT_{PTI} analysis is fairly simple on an image analysis software. In contrast, the placement of the SLI in the transverse plane is dependent only on the straight-line distance from the greater trochanter to the lateral epicondyle of the femur and is not dependent on the actual location of the VL. While the placement of the SLI is certainly on the lateral side of the leg, it cannot be assured that this positioning was aligned perfectly with the midpoint of the PTI. This possible inconsistency between SLI placement and the location of the LT may account for the differences between measurements of MT_{PTI} , MT_{SLI} , SubQ_{PTI} , and SubQ_{SLI} . Due to the morphology of the VL previously discussed, the anteromedial portion of the VL is thicker than the posterolateral part (Blazevich, Gill, & Zhou, 2006; Wells et al., 2014). Additionally, SubQ located adjacent to the muscle on the anteromedial portion of the limb is often smaller than SubQ located adjacent to the muscle on the posterolateral portion (Levine et al., 2000). In the present study, if the SLI was captured at a more posterolateral location compared to the midpoint of the PTI, the SLI would most likely possess greater SubQ_{SLI} and lower MT_{SLI} values. In contrast, if the SLI was captured at a more anterolateral location compared to the midpoint of the PTI, the SLI would include lower SubQ_{SLI} and greater MT_{SLI} values. Nonetheless, the effects of probe placement, with respect to the midpoint of the PTI, during SLI examination should be evaluated in future investigations.

The current findings align with those of other researchers who have discovered no significant correlations between either measure of SubQ and EI_{SLI} or EI_{PTI} in the VL but significant negative correlations between measures of EI and CSA (Fukumoto et al., 2012; Melvin et al., 2014). In the present study, EI measurements and CSA measurements are obtained

simultaneously, where each is derived from the same outline within a US image. Melvin and colleagues (2014) examined EI and CSA of the VL in Division I football athletes and discovered that EI was negatively correlated with CSA but EI was not correlated with fat mass.

Additionally, CSA of the VL was significantly positively correlated with fat mass (Melvin et al., 2014). These results indicate that in football players, the accumulation of body fat is associated with muscle size but not EI, a potential proxy of muscle quality (Melvin et al., 2014). In our study, we examined recreationally-trained club sport athletes, who would likely benefit from increased muscle mass and lower EI with moderate amounts of fat mass. Our results show that individuals with greater CSA tended to have greater amounts of SubQ, which may provide evidence that possessing both are crucial for this population. Additionally, despite the previous hypothesis proposed by Miljkovic and Zmuda (2010) that an infiltration of fat from the subcutaneous layer may lead to increased adipose tissue deposits in the muscle, muscle EI was maintained even with increasing amounts of SubQ. Furthermore, our results show that EI may not be influenced by SubQ in an athletic population.

Previous research has required subjects to lay in a supine position for a period of 15 minutes prior to US analysis to allow for fluid shifts to occur (Ema, Wakahara, Miyamoto, Kanehisa, & Kawakami, 2013; Esformes, Narici, & Maganaris, 2002; Jajtner et al., 2014; Lixandrão et al., 2014; Mangine et al., 2014a; Mangine et al., 2014b; Mangine et al., 2014c; Reeves, Maganaris, & Narici, 2004; Scanlon et al., 2014; Strasser, Draskovits, Praschak, Quittan, & Graf, 2013; Wakahara et al., 2012; Wells et al., 2014). The aforementioned study conducted by Melvin and colleagues (2014) required subjects to lay down in a supine position for only 3-5 minutes. This may have not been enough time for fluid shifts to occur, which may have affected intramuscular water content and therefore EI. Additionally, by examining EI and CSA of the VL

at as little as two hours after exercise, Melvin and colleagues (2014) may have seen higher EI and CSA values that could have been a result of local swelling, infiltration of inflammatory markers, glycogen depletion, and edema that were not a result of muscle composition (Jajtner et al., 2015; Hill and Millan, 2015). Jajtner and colleagues (2015) found an increased EI and CSA of the VL following a lower-body resistance training protocol in resistance-trained men that did not return until baseline levels until about 24 hours post-exercise. Likewise, Hill and Millan (2015) discovered higher EI values in the rectus femoris of trained cyclists after an exhaustive endurance exercise bout as compared to before, which was highly correlated with the amount of glycogen depletion in the muscle. Participants in our study were required to lay in a supine position for at least 15 minutes and refrain from exercise for at least 24 hours prior to US examination. Therefore, the results from our study may not be the result of post-exercise glycogen depletion, edema, or inflammation, and instead may be more accurate representations of muscle EI. Future research may be necessary to determine if there are differences in skeletal muscle EI when participants are only required to lay supine for a short period of time prior to US examination.

Our results regarding SubQ and its relationship to EI conflict with those of Caresio and colleagues (2014), Nijboer-Oosterveld and colleagues (2011), and Watanabe and colleagues (2013), who discovered significant positive correlations between EI and SubQ in various muscles throughout the body. Possible reasons for the disagreement are the training statuses of individuals examined, the age of the participants, the muscles examined, and the ultrasound probe orientation and settings. For example, Caresio et al. (2014) discovered significant positive correlations between SubQ and EI in the VL, tibialis anterior, and medial gastrocnemius in 20 healthy subjects. However, these researchers also discovered no significant correlations between

SubQ and EI in the biceps brachii. These findings align with those of Jenkins and colleagues (2015) who found also no significant correlations between SubQ and EI of the biceps brachii. Taken together, these results show that the amount of SubQ adjacent to a muscle may have a greater effect on EI for specific muscle groups (Caresio et al., 2014; Jenkins et al., 2015). However, the fact that Caresio et al. (2014) found a significant correlation between SubQ and EI of the VL may have to do with training status and gender of the population studied. In this study, men and women with unknown training statuses were examined and pooled for data analysis. It has been demonstrated that females tend to have greater EI values in the quadriceps femoris muscles compared to males, which is probably due to the influence of hormones and greater amounts of essential fat in women (Scanlon et al., 2014). If these individuals were untrained, perhaps the amount of SubQ adjacent to the muscle has a greater effect on EI than in a recreationally-trained population. Previous research has discovered that a greater amount of SubQ adjacent to the muscle may provide larger variability in EI values (Pillen, 2010; Pillen and van Alfren, 2011). Likewise, an untrained population may possess greater amounts of intramuscular fat, which has been found to be positively correlated with increasing EI values (Pillen et al., 2009; Young, Jenkins, Zhao, & McCully, 2015). Young and colleagues (2015) proposed that an underestimation of EI may actually occur when the amount of intramuscular fat reaches about 15%, which is primarily due to the non-systematic reflection of US waves. In populations with increasing amounts of intramuscular fat, skeletal muscle EI of the muscle would most likely decrease, which would lead to an inaccurate measure of echogenicity.

Research examining muscle architecture of the VL has reported substantially different values for CSA_{PTI}, MT_{SLI}, SubQ_{SLI}, and EI compared to those obtained in the current study. CSA_{PTI} values obtained in our study ($34.735 \pm 8.051 \text{ cm}^2$) are considerably greater than those

reported in untrained, healthy males ($29.7 \pm 5.1 \text{ cm}^2$; Ahtiainen et al., 2010), untrained, healthy males and females ($21.25 \pm 6.85 \text{ cm}^2$; Lixandrão et al., 2014) ($19.8 \pm 1.9 \text{ cm}^2$; Scott et al., 2012), and untrained elderly males and females ($14.99 \pm 4.36 \text{ cm}^2$; Scanlon et al., 2014). Studies investigating CSA_{PTI} of the VL in recreationally-trained males as well as physically active males and females have reported values similar compared to the ones in the present study ($39.8 \pm 7.3 \text{ cm}^2$; Mangine et al., 2014a) ($31.9 \pm 8.8 \text{ cm}^2$; Mangine et al., 2014b). Likewise, CSA_{PTI} of the VL in resistance-trained males in previous studies are comparable to those seen in our study ($33.4 \pm 5.7 \text{ cm}^2$; Ahtiainen et al., 2010) ($33.56 \pm 5.39 \text{ cm}^2$; Jajtner et al., 2015). Research investigating CSA_{PTI} of the VL in trained, Division I collegiate football players discovered slightly larger CSA_{PTI} values than those in our study ($38.7 \pm 6.6 \text{ cm}^2$; Melvin et al., 2014), however research examining CSA_{PTI} of the VL in professional NBA players revealed slightly lower values ($33.6 \pm 3.4 \text{ cm}^2$; Mangine et al., 2014c).

In addition, MT_{SLI} values obtained in our study ($2.015 \pm 0.397 \text{ cm}$) were considerably greater than those reported in the VL in untrained elderly males and females ($1.51 \pm 0.34 \text{ cm}$; Scanlon et al., 2014) and greater than those reported in Division I collegiate female soccer players at the end of an off-season training program ($1.43 \pm 0.2 \text{ cm}$; Wells et al., 2014). However, our results for MT_{SLI} were lower than those discovered in professional National Basketball Association players ($2.26 \pm 0.46 \text{ cm}$; Mangine et al., 2014c). MT_{SLI} measurements obtained in our study were greater than those reported in physically active males and females by Mangine and colleagues (2014b) ($1.87 \pm 0.36 \text{ cm}$, pooled for gender), but lower than those reported in other physically active males and females by Caresio and colleagues (2014) ($2.39 \pm 0.46 \text{ cm}$ and $2.10 \pm 0.19 \text{ cm}$, respectively). Furthermore, our values for SubQ_{SLI} (0.316 ± 0.225

cm) were considerably lower than those discovered in physically active males and females (0.57 ± 0.23 cm and 1.28 ± 5.5 cm, respectively; Caresio et al., 2014).

Previous studies have reported a wide range of EI values of the VL in untrained young males and females, elderly individuals, resistance-trained males and females, physically active males and females, individuals before and after resistance training programs, players in the National Basketball Association, and Division I collegiate football and women's soccer players (Caresio et al., 2014; Jajtner et al., 2014; Jajtner et al., 2015; Mangine et al., 2014a; Mangine et al., 2014b; Mangine et al., 2014c; Melvin et al., 2014; Scanlon et al., 2014; Strasser, Draskovits, Praschak, Quittan, & Graf, 2013; Wells et al., 2014; Wilhelm et al., 2014). However, direct associations between EI values obtained from different studies may not be practical due to differences in US settings (i.e. gain, depth, dynamic range, US make and model), techniques, probe orientation, and types of images (Melvin et al., 2014). Previous research from our laboratory has investigated EI using a 12-MHz B-mode US, set at a gain of 50 dB, a depth of 5 cm, and a dynamic range of 72 to capture a panoramic image of the VL in the transverse plane (Jajtner et al., 2014; Jajtner et al., 2015; Mangine et al., 2014a; Mangine et al., 2014b; Mangine et al., 2014c; Scanlon et al., 2014; Wells et al., 2014). These US settings align with those used in the current study. The results from the present study report EI_{PTI} values of the VL (57.976 ± 8.806 AU) that are considerably less than EI_{PTI} values reported from our laboratory in untrained elderly males and females (91.80 ± 10.79 AU, pooled for gender; Scanlon et al., 2014), physically active men and women (60.4 ± 12.6 AU and 71.2 ± 12.8 AU, respectively; Mangine et al., 2014a; 65.9 ± 11.8 AU, pooled for gender; Mangine et al., 2014b), Division I collegiate female soccer players after a resistance-training program and in the pre-and post-season (68.27 ± 8.05 AU; Wells et al., 2014; 69.08 ± 7.19 AU and 68.32 ± 6.80 AU, respectively; Jajtner et al.,

2014), resistance-trained males (63.27 ± 6.67 AU; Jajtner et al., 2015), and professional National Basketball Association players (62.1 ± 10.6 AU; Mangine et al., 2014c).

The muscle morphological characteristics examined in the present study are probably a result of the training status of the subjects evaluated. The participants included in this study were collegiate male club-sport athletes, who possessed a higher activity level than physically active college students, but a lower training status compared to Division I athletes. Resistance training, along with anaerobic sports training, promotes increases in contractile proteins, which results in muscle and myofiber hypertrophy, occurring primarily in Type IIa muscle fibers (Charette et al., 1991; Deschenes and Kraemer, 2002; Ikai and Fukunaga, 1970; McCall, Byrnes, Dickinson, Pattany, & Fleck, 1996; Melvin et al., 2014; Narici, Roi, Landoni, Minettu, & Cerretelli, 1989; Scanlon et al., 2014; Seynnes, de Boer, & Narici, 2007). Therefore, because our subjects were recreationally resistance-trained and participated in club sports, a greater CSA and MT with a lower SubQ may be expected. Furthermore, resistance training has been shown to elicit significant decreases in EI values in various populations (Jajtner et al., 2014; Scanlon et al., 2014). It is likely that in our subjects, a lower EI may be a result of the training that their respective sport required. Jajtner et al. (2014) discovered significant decreases in EI of the rectus femoris from pre-season to post-season in Division I collegiate women's soccer players. Likewise, Scanlon and colleagues (2014) discovered significant decreases in EI of the VL after a six-week resistance training program in elderly women. However, Wells et al. (2014) discovered no significant changes in EI of the VL after a 15-week off-season resistance training program in Division I collegiate women's soccer players. The discrepancies in findings may indicate that each muscle of the lower body adapts to resistance training in a non-homogeneous way and that changes in muscle EI may be more than just a result of training. Future studies should look to

examine EI before and after a resistance training program or sport season in male club sport athletes to determine the effectiveness of the program on muscle quality.

CSA_{SLI}, EI_{SLI}, MT_{SLI}, and SubQ_{SLI} yielded greater precision values compared to CSA_{PTI}, EI_{PTI}, MT_{PTI}, and SubQ_{PTI}, as determined by within-session SEM and CV. Noorkoiv and colleagues (2010) suggested that lower reliability values seen with panoramic imaging may be due to the extent of curvature and area of the region of interest, where a more tightly curved region with a larger area of interest may result in lower reliability values. This may occur because panoramic imaging utilizes the overlapping of one image onto another, which increases the likelihood of error (Noorkoiv, Nosaka, & Blazevich, 2010). While still images may provide better reliability values, in many situations, the use of panoramic imaging is necessary to get an accurate representation of the entire muscle, as is the case in the present study. The measurement of CSA_{PTI} represented the total CSA of the entire muscle, whereas CSA_{SLI} represented the total area of muscle contained within the single frame and was not representative of the entire CSA of the VL. CSA_{SLI} was limited to the size of the frame, which consisted of perfectly vertical lines on both the left and right sides of the image as well as deep and superficial lines that corresponded to actual muscle-aponeurosis interfaces. Caresio and colleagues (2014) suggested that a non-linear relationship exists between EI reliability and the size of the region of interest in the VL, where the highest ICCs corresponded with the greatest area encompassed within the region of interest. Despite the largest regions of interest within the muscle displaying the highest ICC values for EI, the researchers concluded that a region of interest within the muscle the size of only about 10-15% of the maximum region of interest was necessary to elicit reliable EI values. This indicates that analyzing the entire area of the muscle for EI reliability assessment (i.e. panoramic imaging) may not be necessary. This may provide evidence that the use of EI_{SLI}

and CSA_{SLI} assessment may be beneficial if time constraints exist, if the structure of interest is located in a tightly-curved region, or if panoramic imaging is not feasible.

One limitation to the present study is that medical history questionnaires were not required for participants to complete prior to participation. Therefore, subjects with musculoskeletal injuries prior to the study were not excluded, which may have affected EI values. Previous research has discovered higher EI values due to increased fibrous tissue, which may be a result of increased scar tissue or pathological or neurological conditions (Caresio, Molinari, Emanuel, & Minetto, 2004; Jajtner et al., 2014; Miljkovic and Zmuda, 2010; Pillen, 2010). Another limitation to the present study was that there was no inclusion requirement for body composition. Thus, as described earlier, EI values obtained from participants with larger amounts of subcutaneous adipose tissue or intramuscular fat may have inaccurately resulted in false measures of lower EI (Young, Jenkins, Zhao, & McCully, 2015). Additionally, there was no requirement for resistance training experience for inclusion in our study. Some participants may have joined a club sport team without prior training experience, which would have affected muscle morphological characteristics and would not have been representative of a recreationally resistance-trained population. Finally, there was no distinction of player positions/specialties prior to testing. Melvin et al. (2014) discovered significantly different amounts of fat mass, lean mass, and VL CSA between different positions in Division I football players, however there were no significant differences in EI between positions. Different positions/specialties have different demands, which may affect muscle architecture and composition as well as fat mass in a non-homogeneous way. Future research should look to examine EI in club-sport athletes with completion of medical history questionnaires, body fat inclusion requirements, resistance-training experience, and distinction of player positions/specialties.

Conclusions

In conclusion, the current study provides evidence that EI_{PTI} of the VL appears to be homogeneous amongst the examined tertiles. Furthermore, despite differences in measurements of EI, MT, SubQ, and CSA between the PTI and SLI, these ultrasound-derived variables are highly correlated. The use of the SLI yields better precision with respect to each variable compared to the PTI. Therefore, utilization of the SLI may be advantageous for quantification of MT, SubQ, CSA, and EI for examination of the VL in a recreationally-trained population in future studies, especially if time constraints exist and only one image type can be measured, a highly-experienced technician in panoramic ultrasonography is not present, or if the thickness of the muscle is large enough to possibly affect reflectivity of an ultrasound beam

APPENDIX A: FIGURES

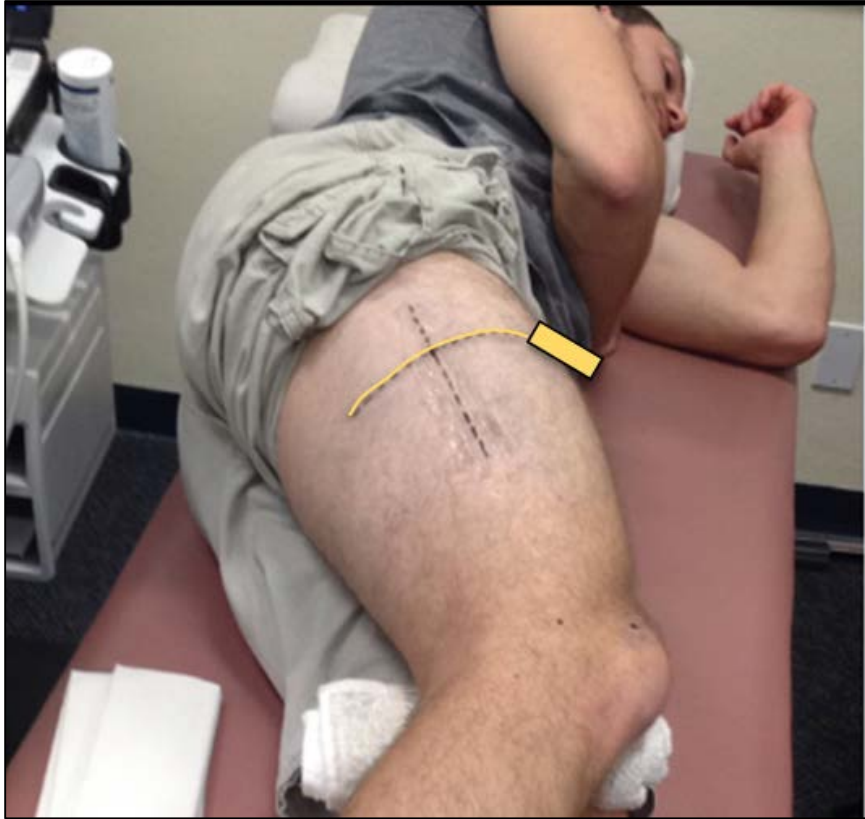

Figure 1: A sample participant laying down for panoramic transverse image (PTI) analysis. PTI were taken at 50% of the straight-line distance from the greater trochanter and the lateral epicondyle of the femur. Image capture location was demarcated using a permanent marker on the surface of the skin. PTI were captured in the transverse plane, perpendicular to the force-generating axis of the muscle, using extended-field-of-view ultrasonography (LogiqView™). The yellow box represents the probe head orientation, and the solid yellow line represents the direction of probe manipulation along the leg during image capture.

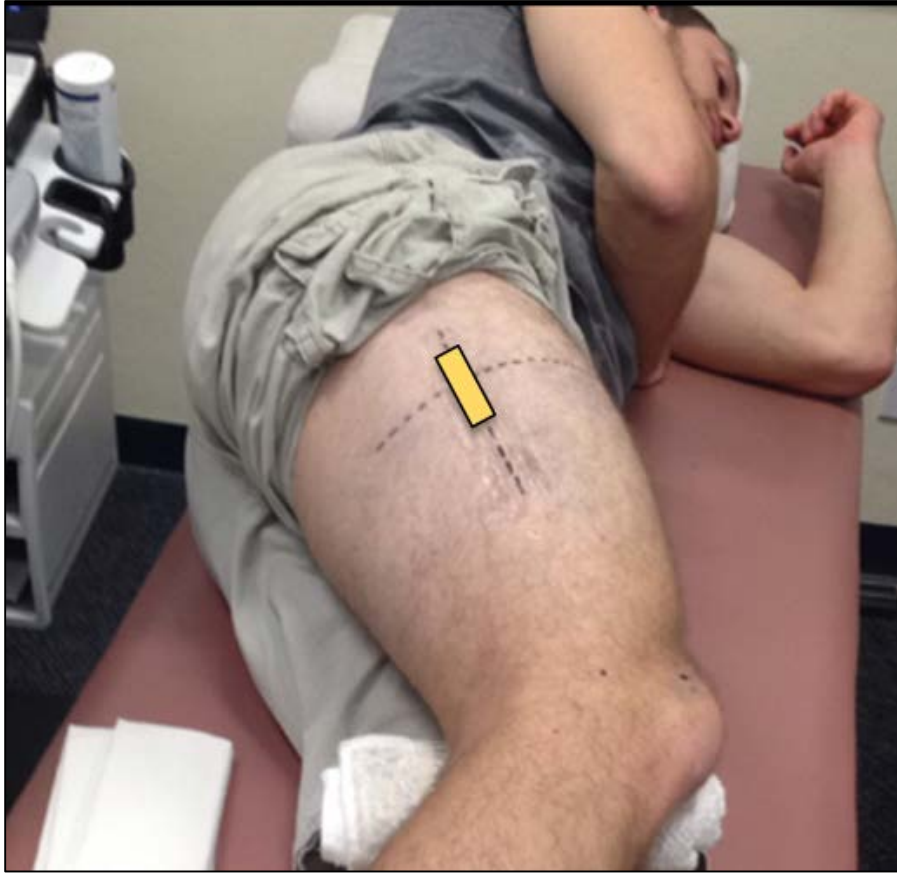

Figure 2: A sample participant laying down for single longitudinal image (SLI) analysis. Still images were taken at 50% of the straight-line distance from the greater trochanter and the lateral epicondyle of the femur. Image capture location was demarcated using a permanent marker on the surface of the skin. SLI were captured in the longitudinal plane, parallel to the force-generating axis of the muscle, using a still image. The yellow box represents the probe head orientation and image capture location.

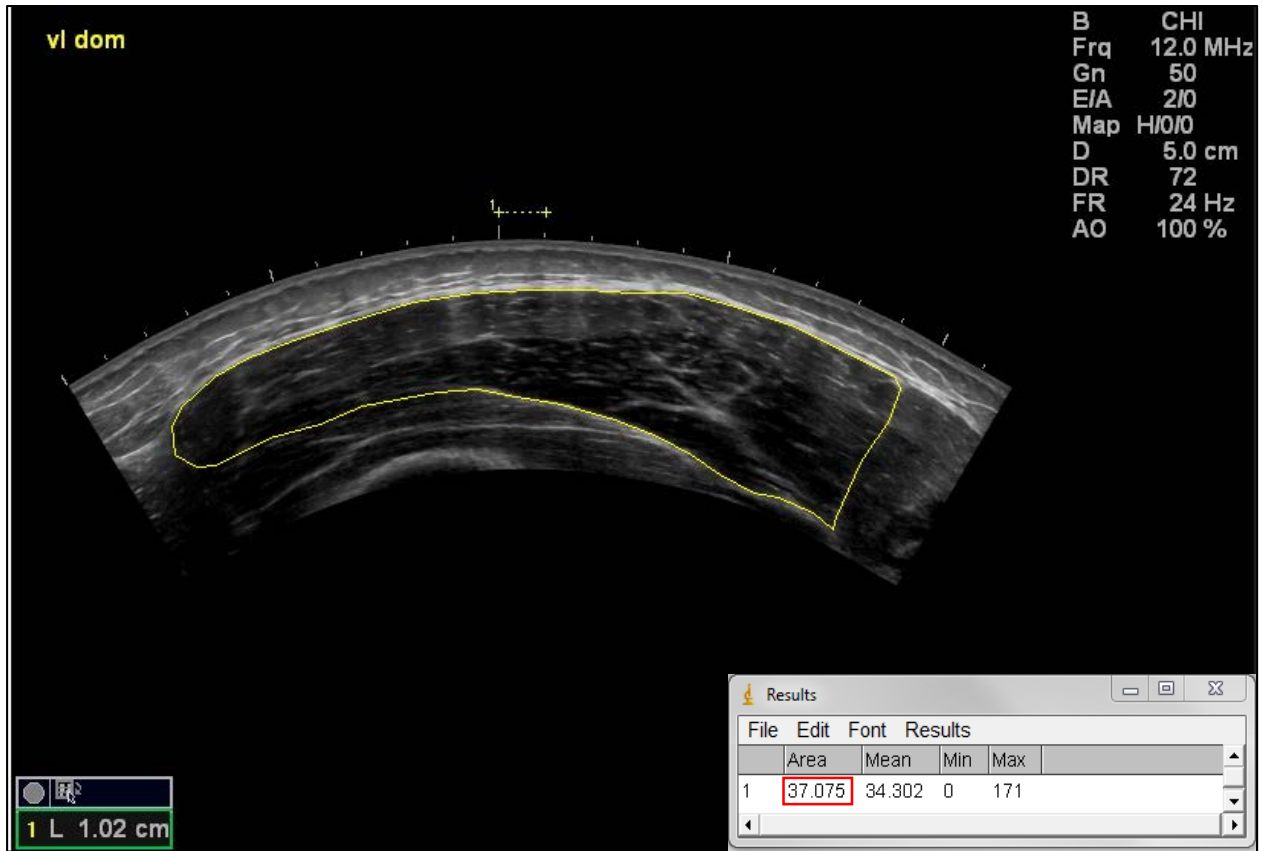


Figure 3: A sample panoramic transverse image (PTI) of the vastus lateralis (VL) used for cross-sectional area (CSA) analysis. The outline of the VL muscle was located in the image and traced using the polygon function tool in ImageJ, which included as much lean mass as possible without including any surrounding bone or fascia. The CSA value is highlighted in red and recorded in centimeters².

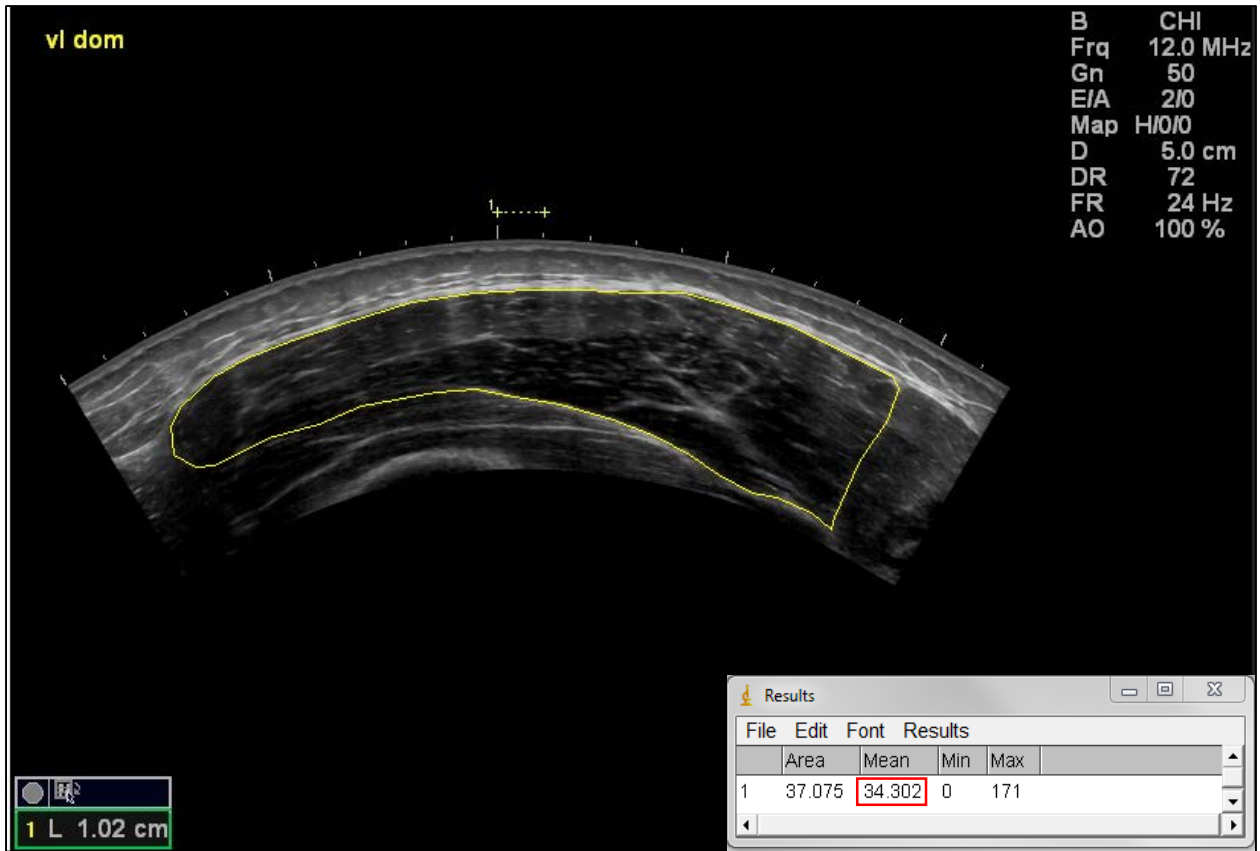


Figure 4: A sample panoramic transverse image (PTI) of the vastus lateralis (VL) used for echo intensity (EI) analysis. The same region of interest used for cross-sectional area (CSA) analysis is again used for EI analysis. The EI value is highlighted in red and recorded in arbitrary units.

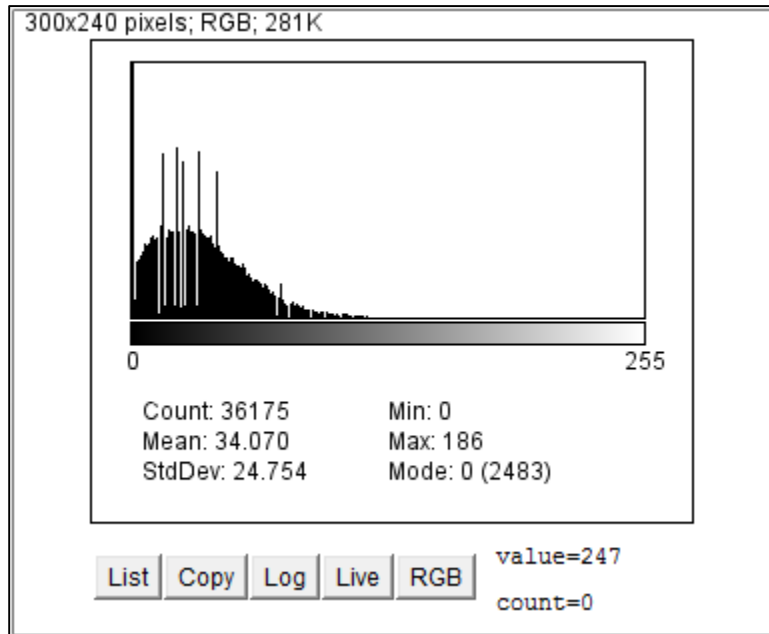


Figure 5: A sample histogram plot generated in ImageJ for echo intensity (EI) determination. This plot quantifies the grayscale of each individual pixel within the region of interest previously demarcated for cross-sectional area (CSA) and represents them as values from 0-255.

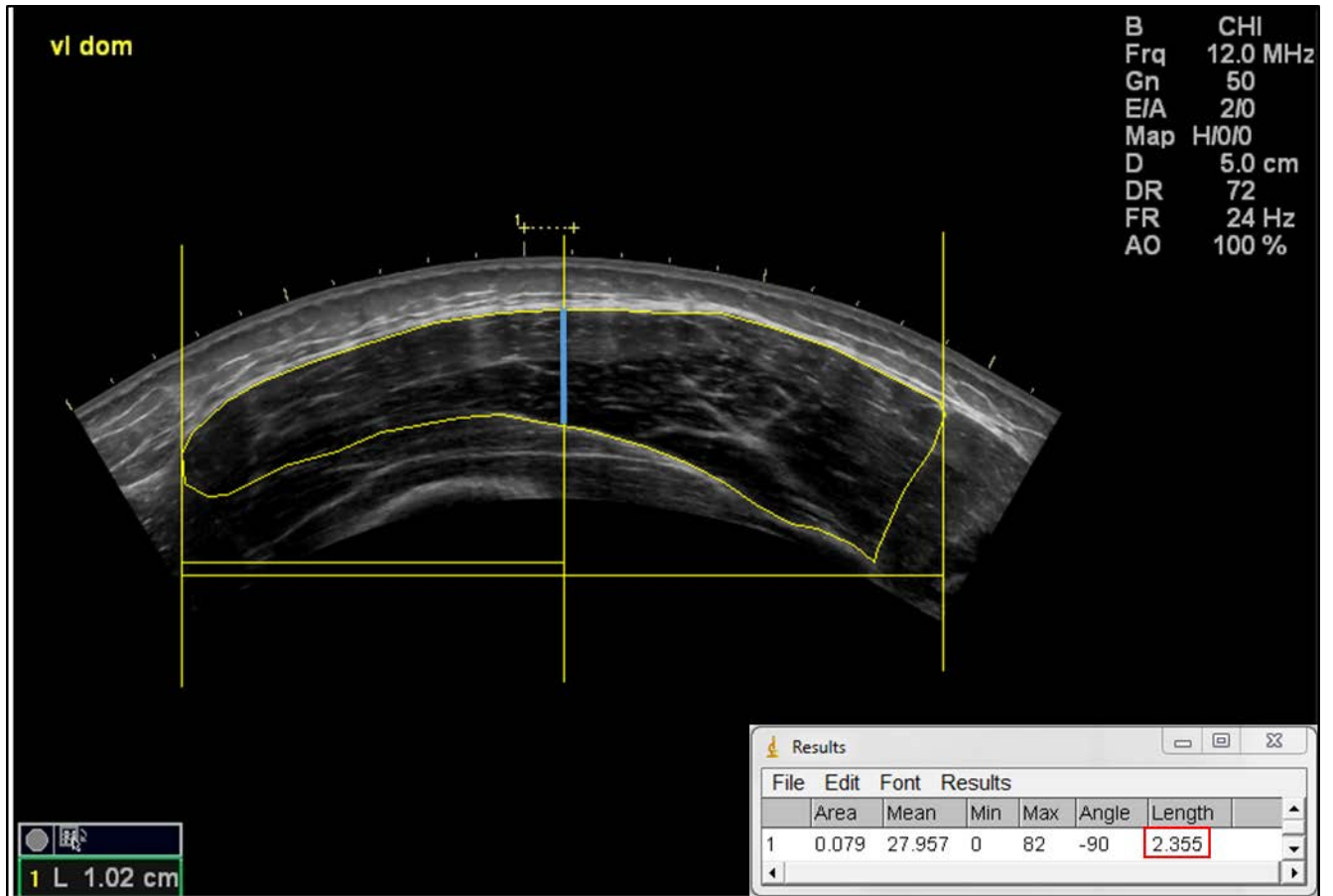


Figure 6: A sample panoramic transverse image (PTI) with muscle thickness (MT) measurement highlighted in blue. MT was quantified using the line tool at the midpoint of the horizontal distance between the anterior and posterior sides of the vastus lateralis (VL). MT is defined as the distance between the inferior border of the superficial aponeurosis and the superior border of the deep aponeurosis. The MT value is highlighted in red and recorded in centimeters.

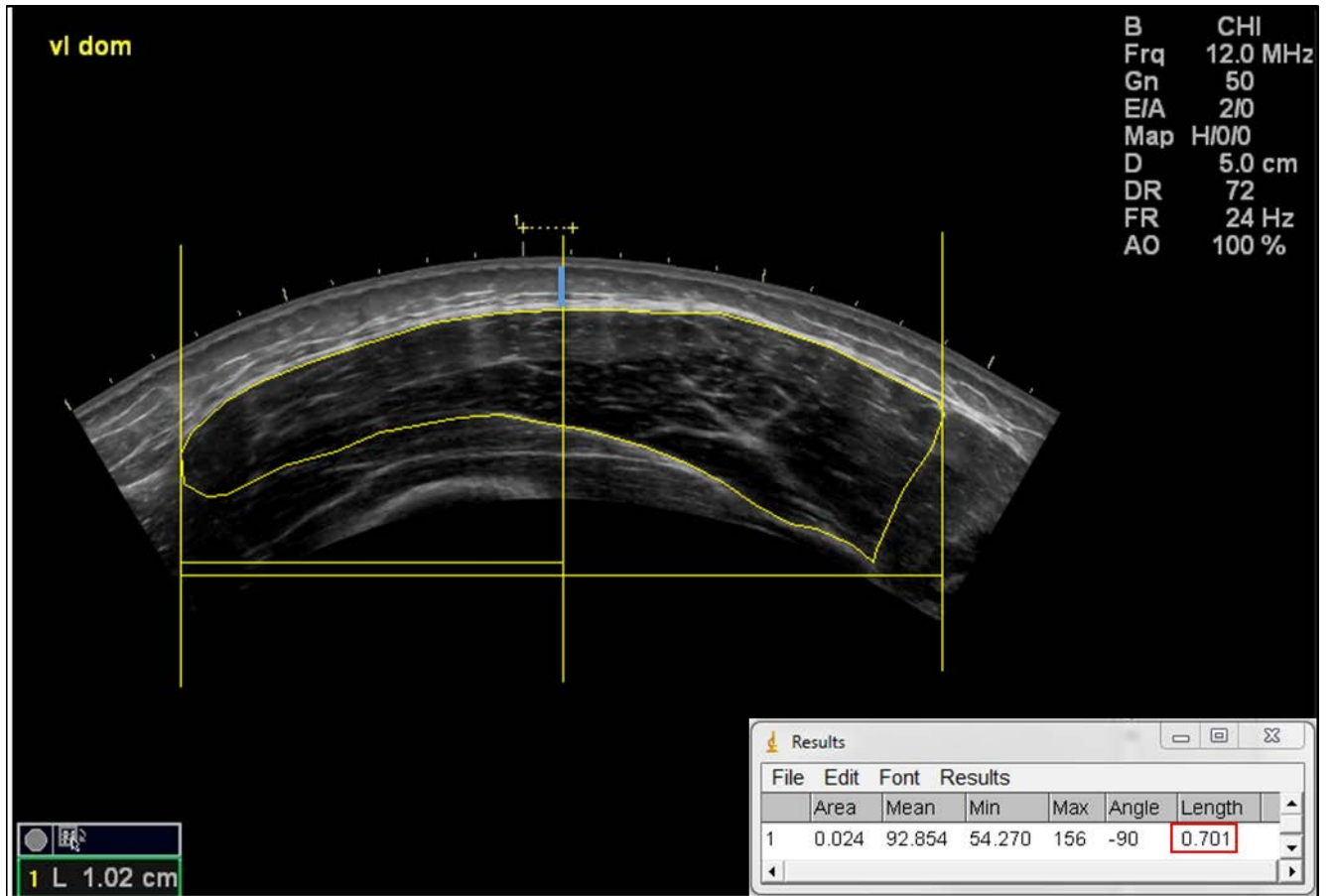


Figure 7: A sample panoramic transverse image (PTI) with subcutaneous adipose tissue thickness (SubQ) measurement highlighted in blue. SubQ was quantified using the line tool at the midpoint of the horizontal distance between the anterior and posterior sides of the vastus lateralis (VL). SubQ is defined as the distance between the inferior border of the epidermis and the superior border of the superficial aponeurosis. The SubQ value is highlighted in red and reported in centimeters.

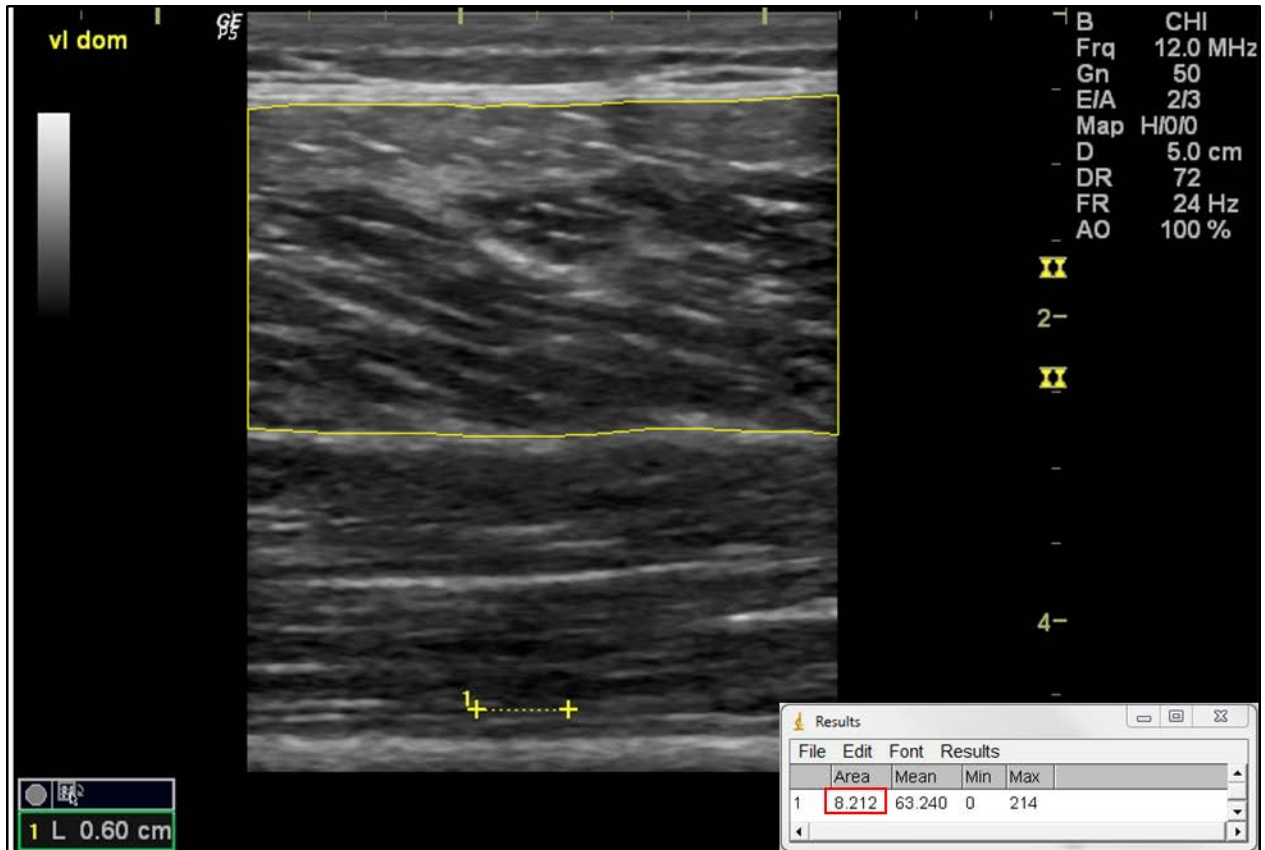


Figure 8: A sample single longitudinal image (SLI) of the vastus lateralis (VL) used for cross-sectional area (CSA) analysis. The outline of the VL muscle was located in the image and traced using the polygon function tool in ImageJ, which included as much lean mass as possible without including any surrounding bone or fascia. The right and left sides of the traced polygon consisted of perfectly vertical lines, parallel to each other and parallel to the edges of the image, whereas the superficial and deep lines of the ImageJ polygon corresponded to the muscle-aponeurosis interface. The CSA value is highlighted in red and reported in centimeters².

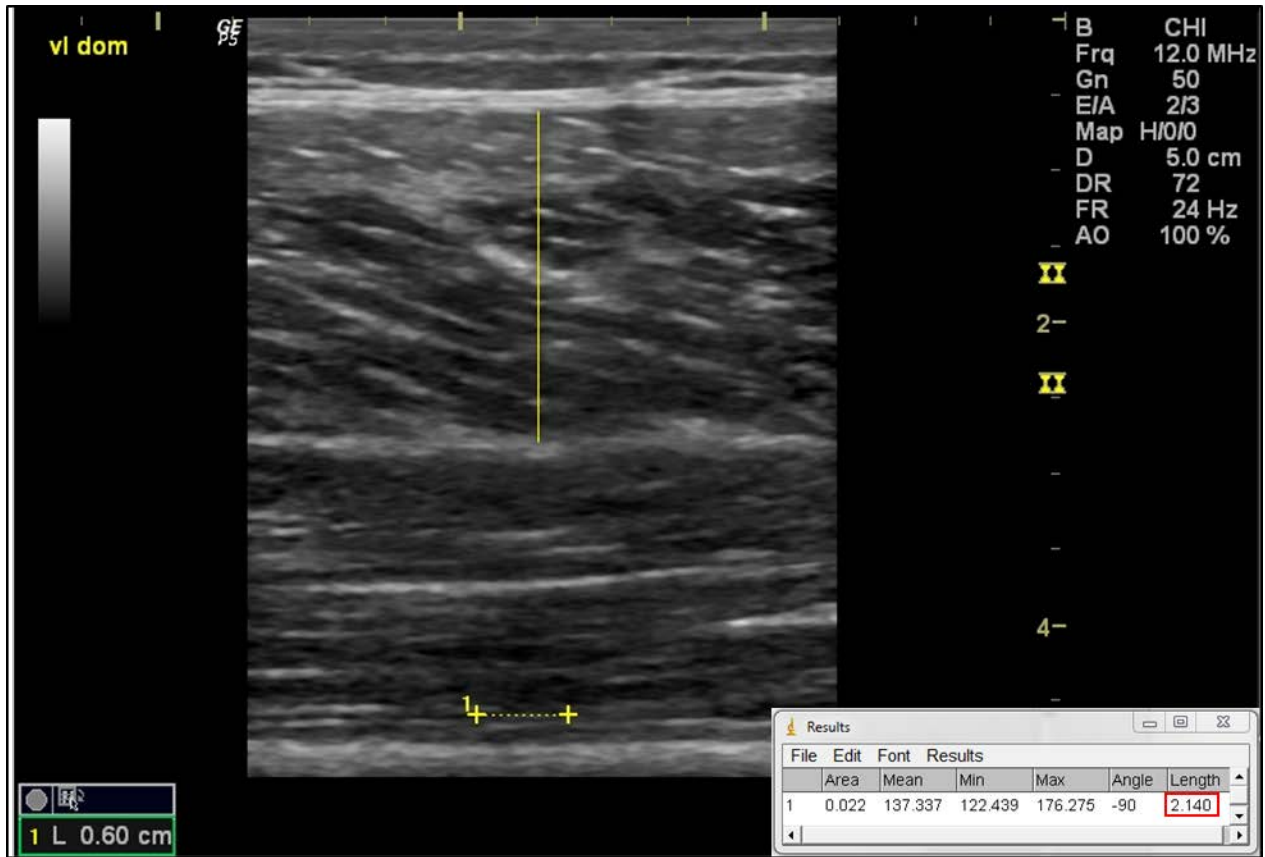


Figure 9: A sample single longitudinal image (SLI) with muscle thickness (MT) measurement highlighted in yellow. MT was quantified using the line tool at the midpoint of the horizontal distance between the left and right sides of the vastus lateralis (VL). MT is defined as the distance between the inferior border of the superficial aponeurosis and the superior border of the deep aponeurosis. The MT value is highlighted in red and reported in centimeters.

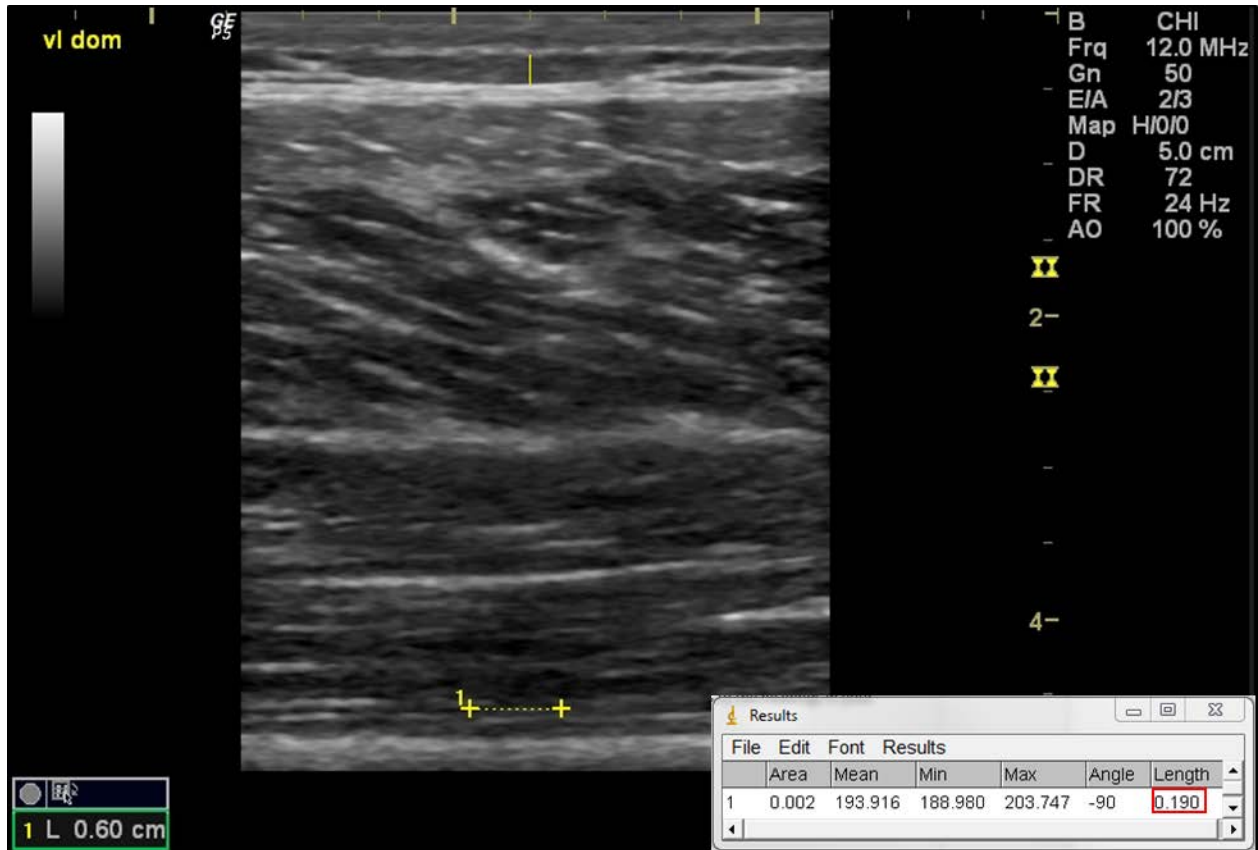


Figure 10: A sample single longitudinal image (SLI) with subcutaneous adipose tissue (SubQ) measurement highlighted in yellow. SubQ was quantified using the line tool at the midpoint of the horizontal distance between the left and right sides of vastus lateralis (VL). SubQ is defined as the distance between the inferior border of the epithelium and the superior border of the superficial aponeurosis. The SubQ value is highlighted in red and reported in centimeters.

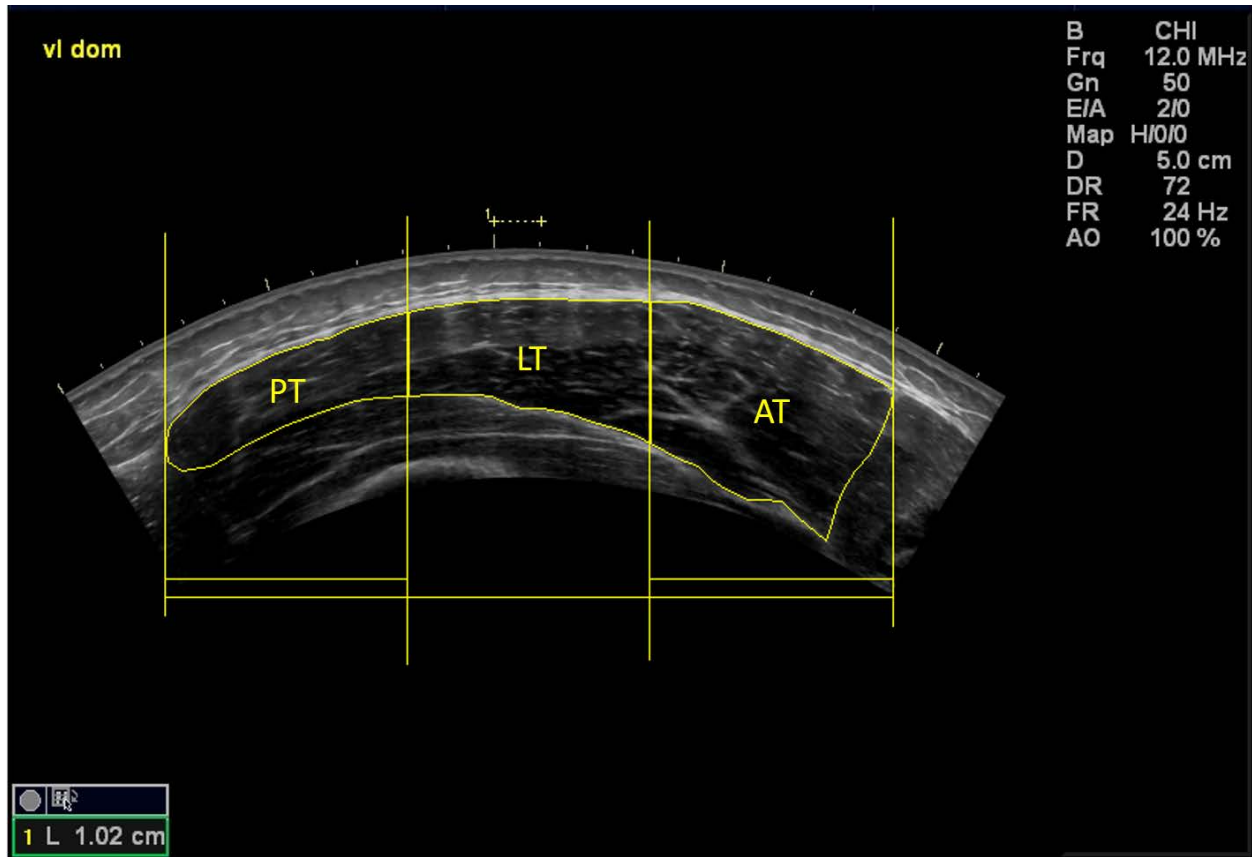


Figure 11: A sample panoramic transverse image (PTI) divided into three tertiles of equal horizontal length. The anterior tertile (AT) denotes the compartment of the vastus lateralis (VL) that is situated in the anterior side of the body, the lateral tertile (LT) denotes the compartment of the VL that is situated on the lateral side of the body, and the posterior tertile (PT) denotes the compartment of the VL that is situated on the posterior side of the body.

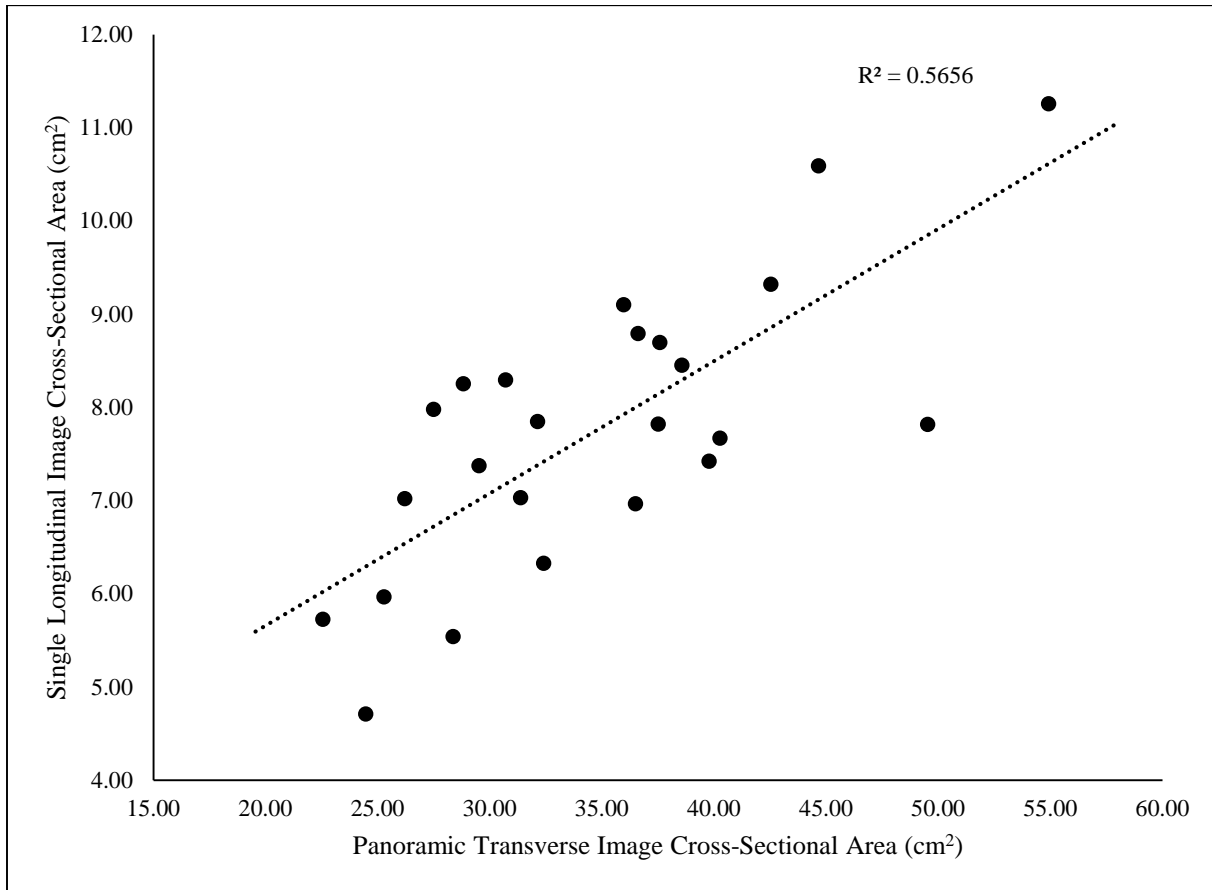


Figure 12: Cross-sectional area (CSA) values obtained from panoramic transverse images (PTI) and single still longitudinal images (SLI) with corresponding trendline and correlation coefficient.

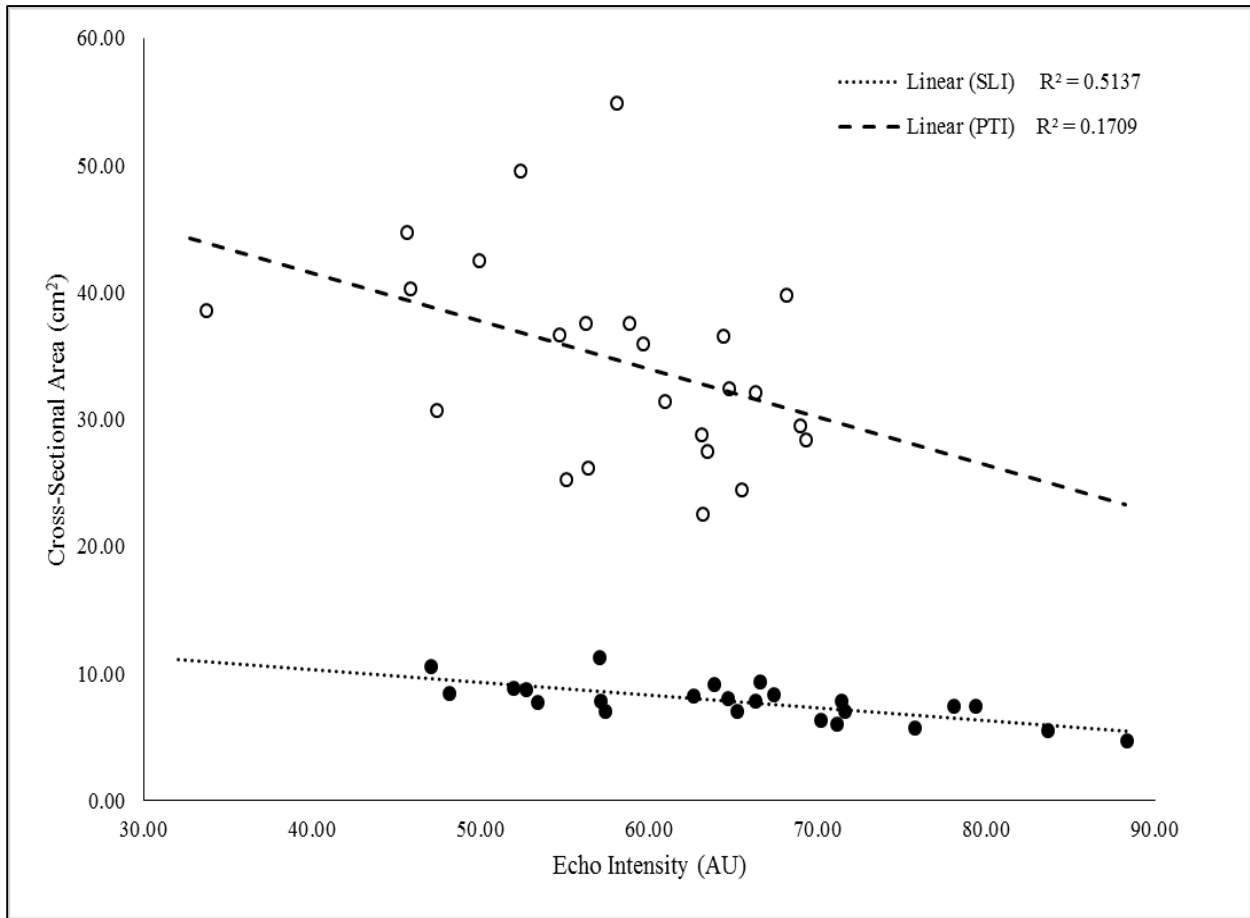


Figure 13: Echo intensity (EI) and cross-sectional area (CSA) values obtained from panoramic transverse images (PTI) and still longitudinal images (SLI). Open circles represent measures obtained from PTI. Closed circles represent measures obtained from SLI.

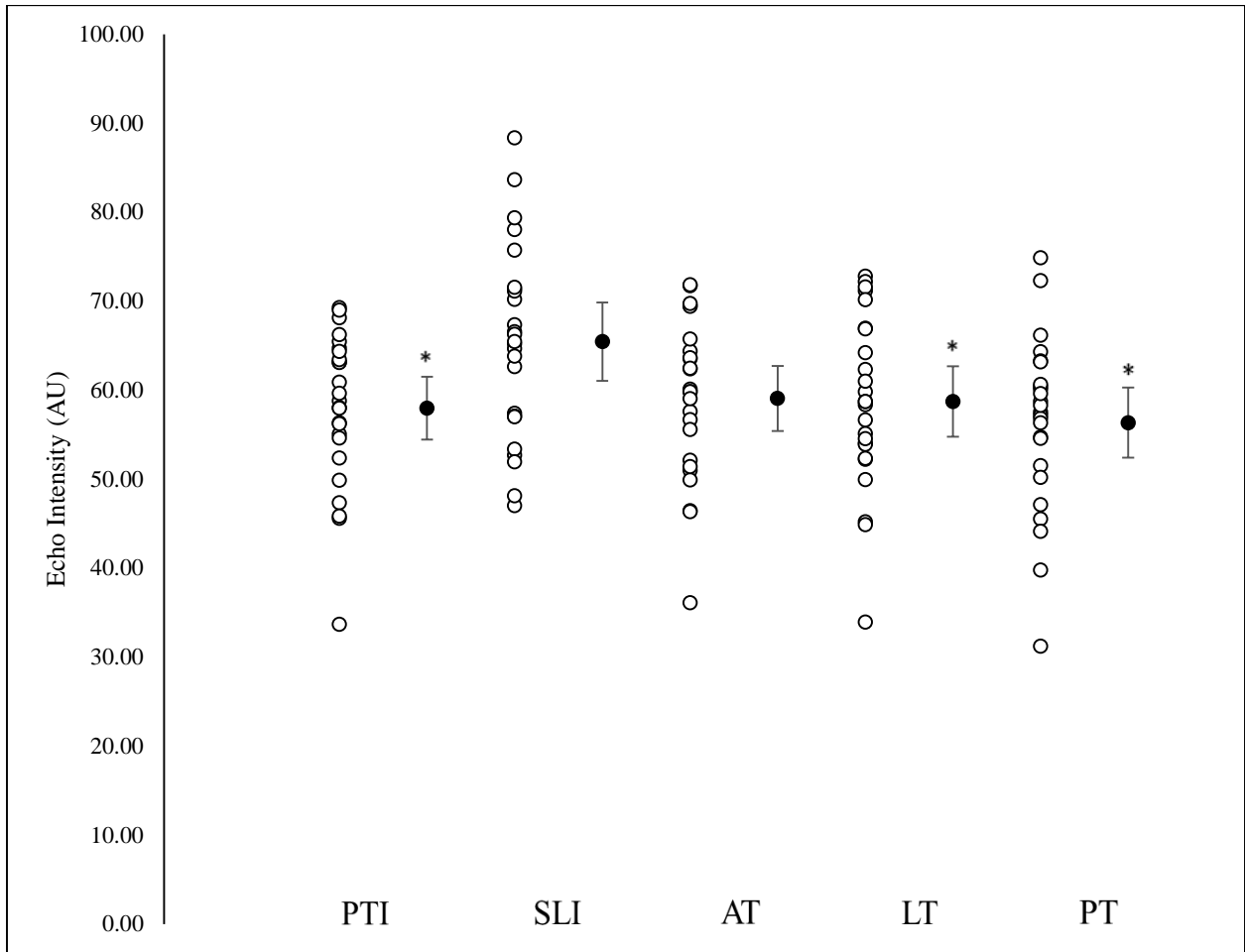


Figure 14: Echo intensity (EI) values of panoramic transverse images (PTI), still longitudinal images (SLI), anterior tertiles (AT), lateral tertiles (LT), and posterior tertiles (PT). Open circles represent individual data points. Closed circles represent sample means, and 95% confidence intervals are denoted by error bars.

*Denotes statistically significant difference ($p < 0.01$) from single still longitudinal images.

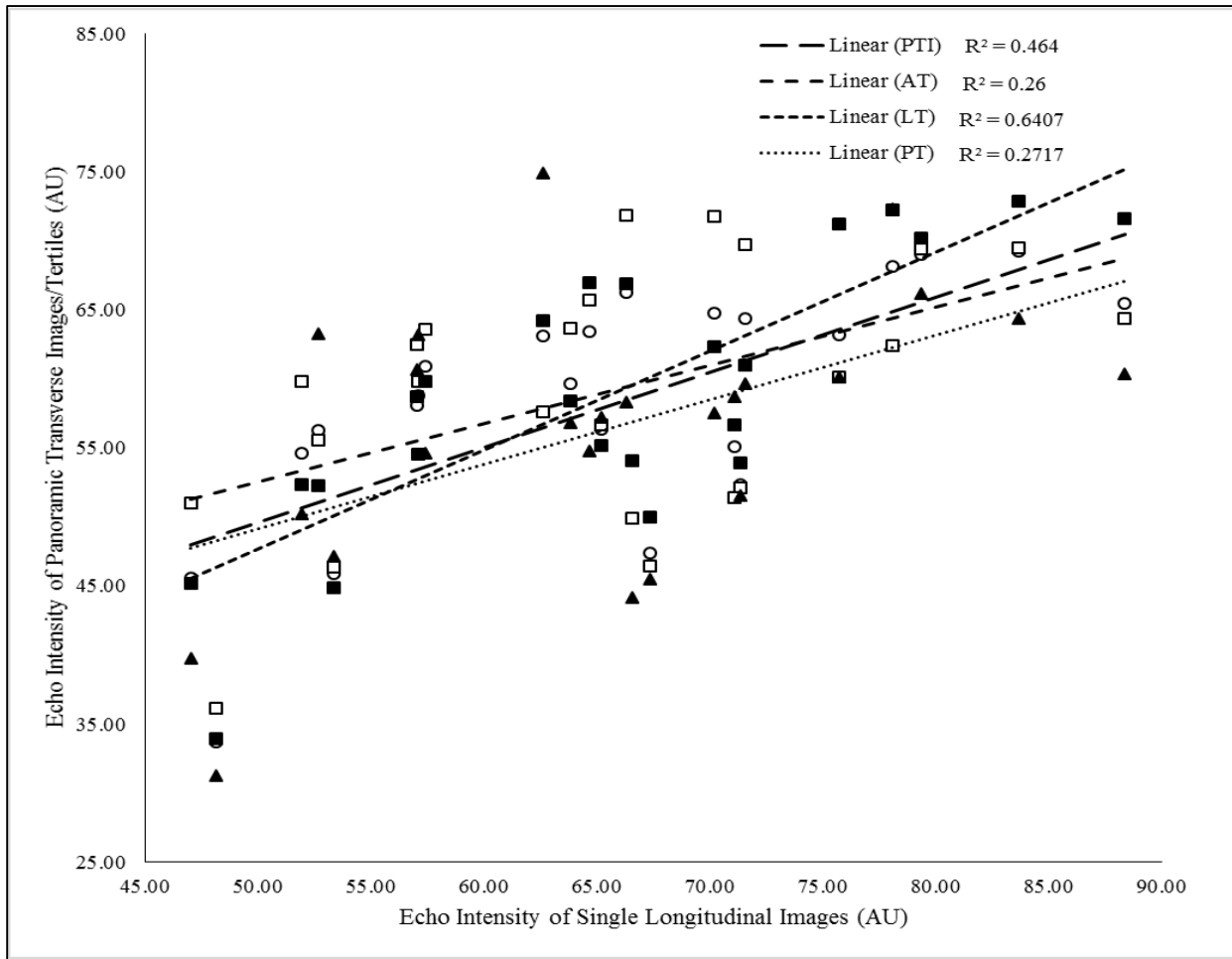


Figure 15: Echo intensity (EI) values obtained from still longitudinal images (SLI) compared to EI of panoramic transverse images (PTI), anterior tertiles (AT), lateral tertiles (LT), and posterior tertiles (PT). Open circles represent measures obtained from PTI. Open squares represent measures obtained from AT. Closed squares represent measures obtained from LT. Closed triangles represent measured obtained from PT.

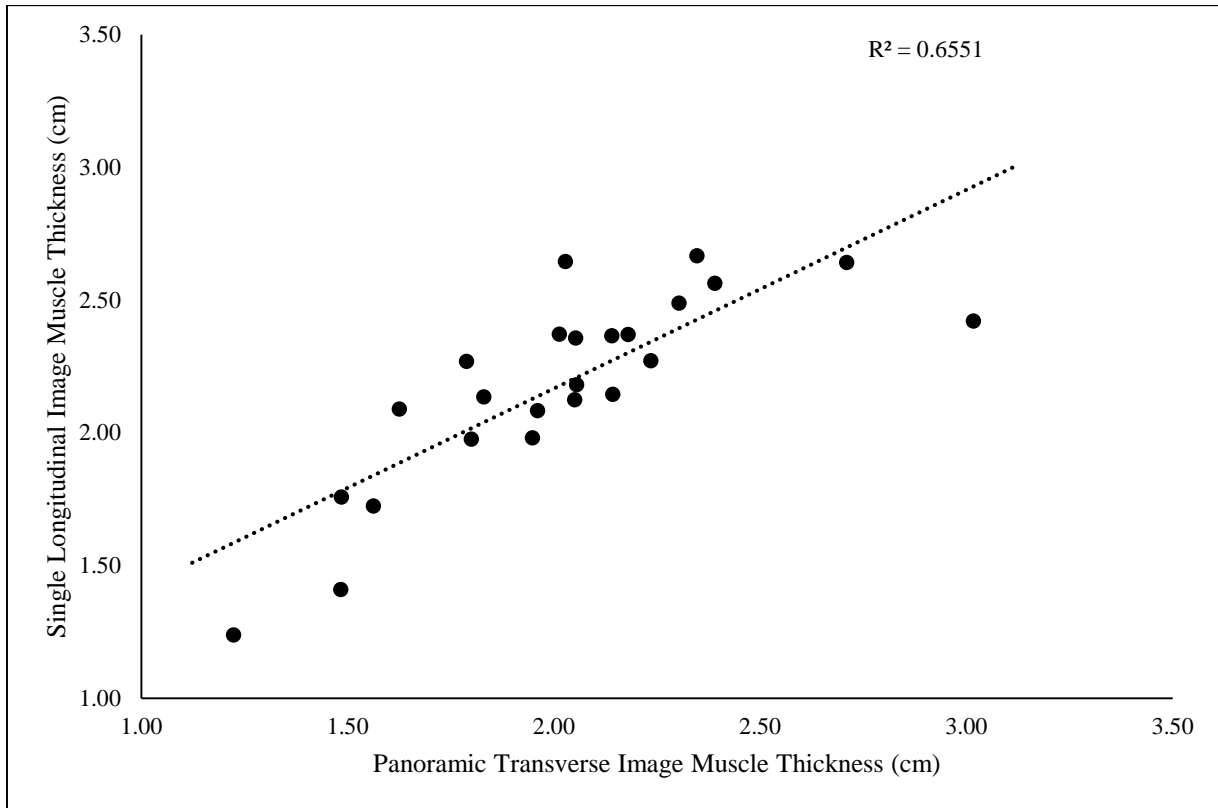


Figure 16: Muscle thickness (MT) values obtained from panoramic transverse images (PTI) and single still longitudinal images (SLI) with corresponding trendline and correlation coefficient.

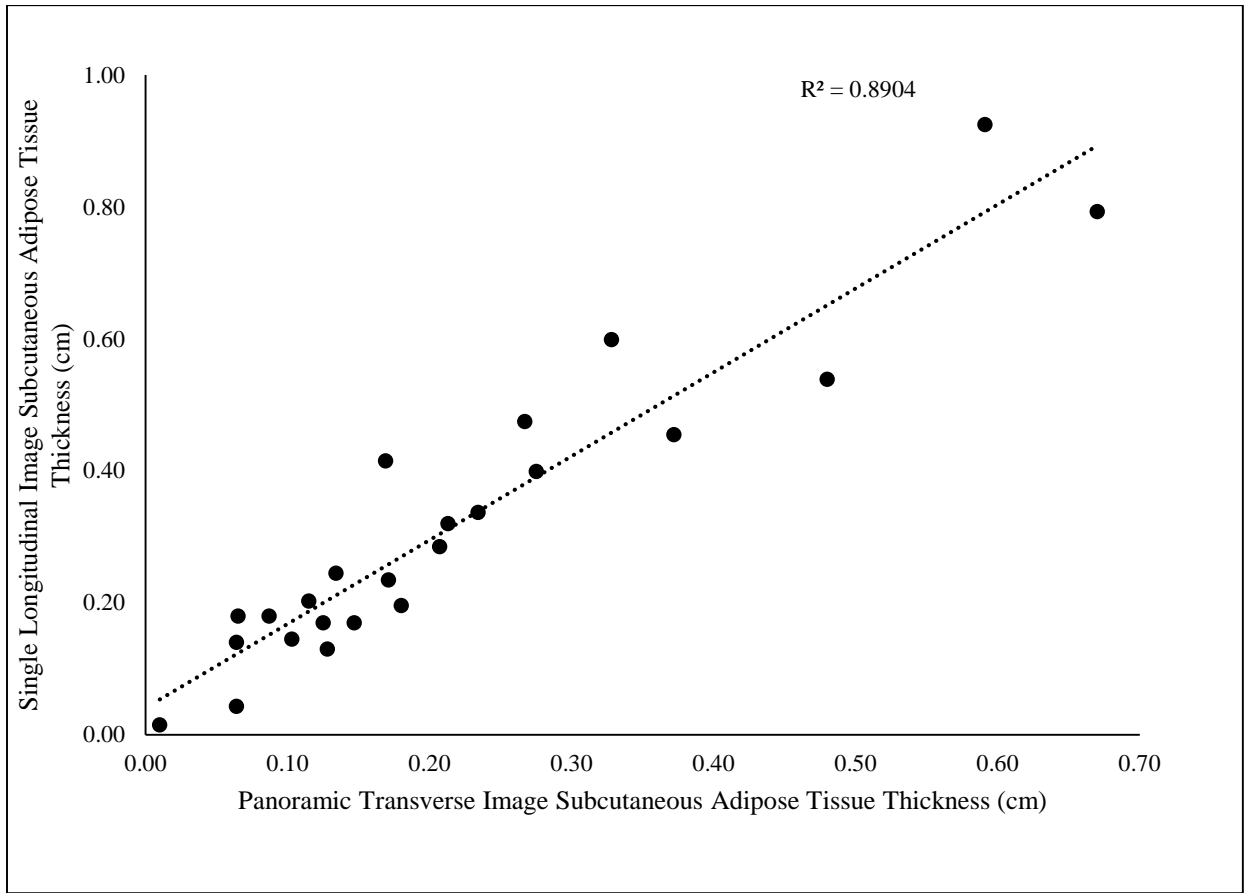


Figure 17: Subcutaneous adipose tissue thickness (SubQ) values obtained from panoramic transverse images (PTI) and single still longitudinal images (SLI) with corresponding trendline and correlation coefficient.

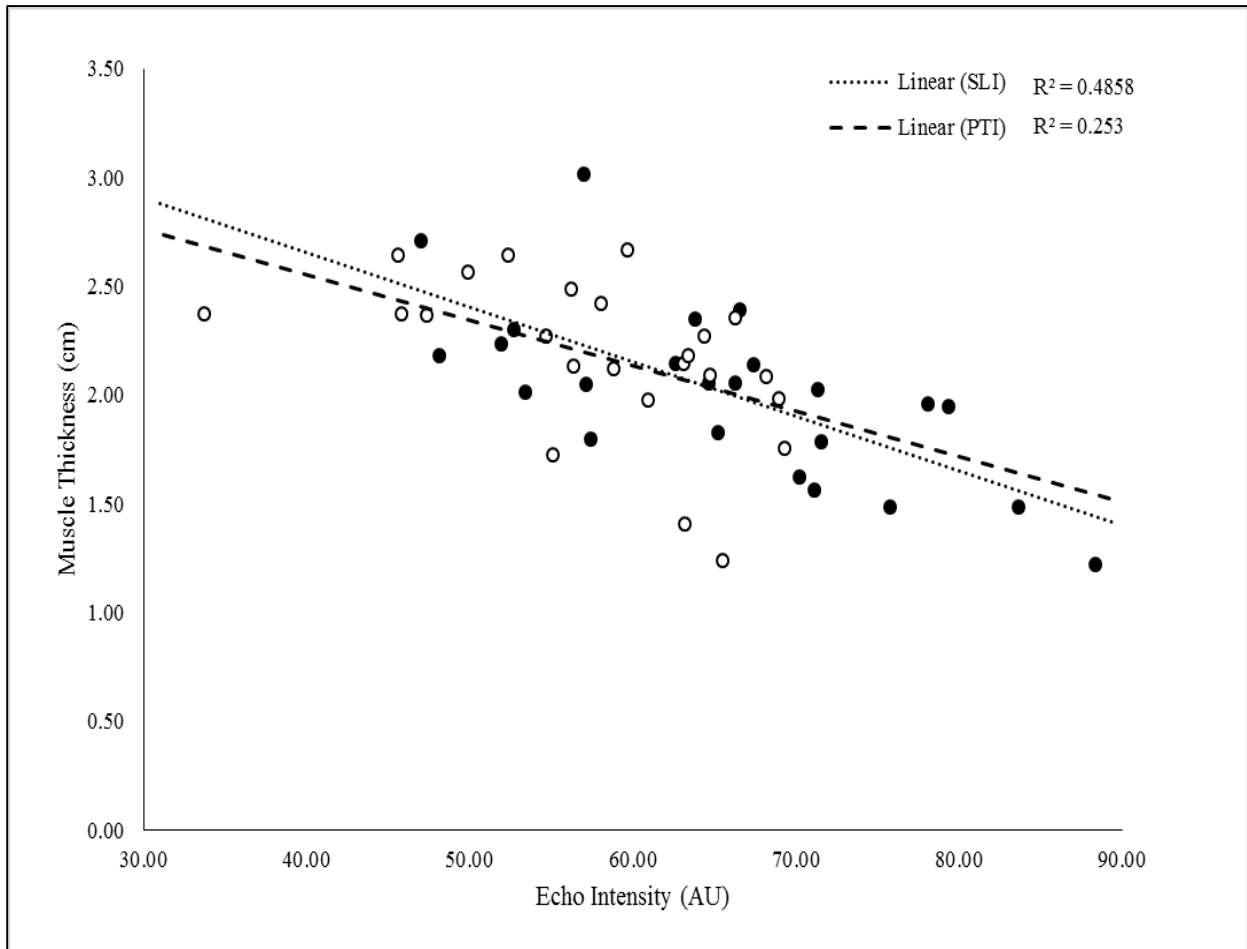


Figure 18: Echo intensity (EI) and muscle thickness (MT) values obtained from panoramic transverse images (PTI) and still longitudinal images (SLI). Open circles represent measures obtained from PTI. Closed circles represent measures obtained from SLI.

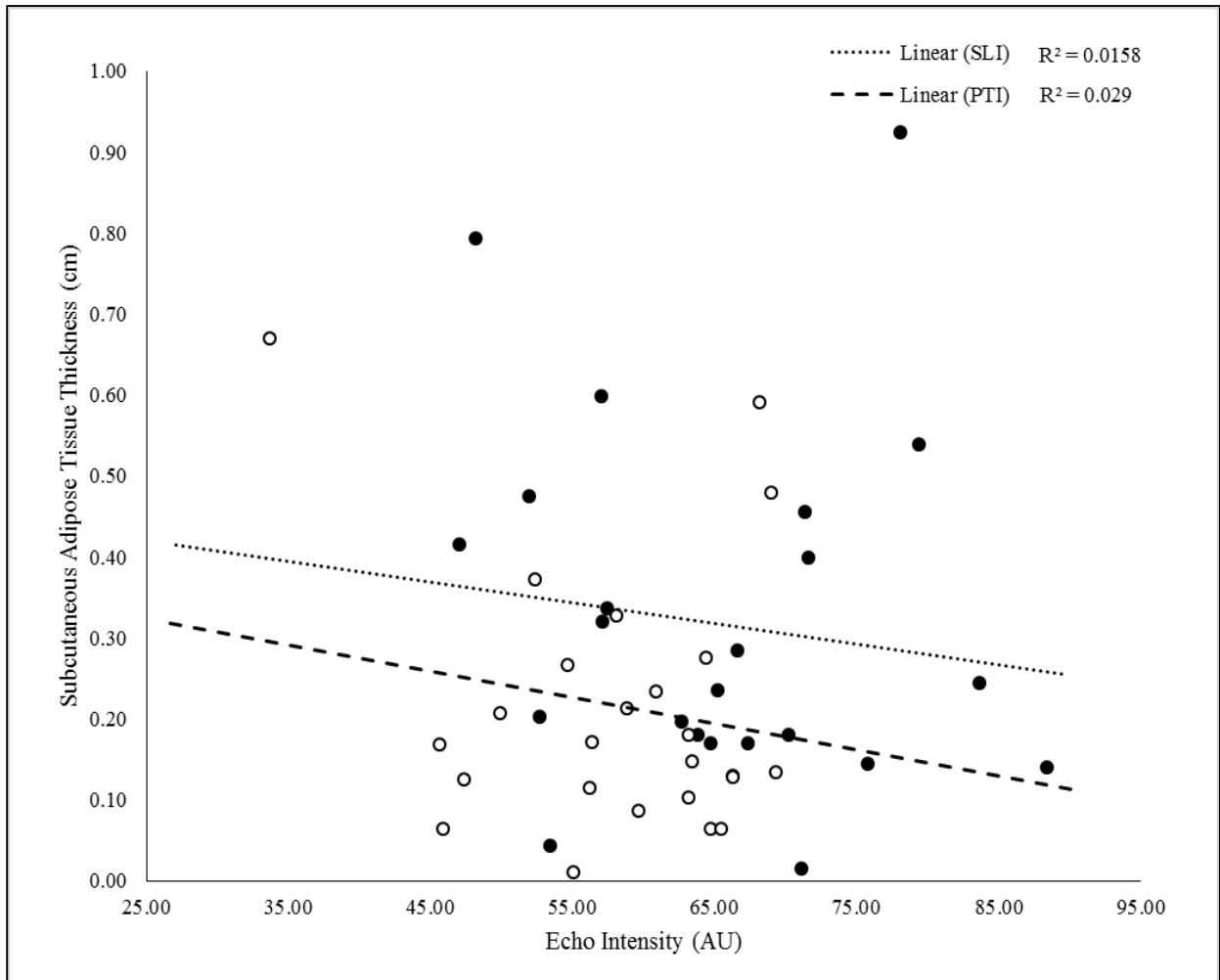


Figure 19: Echo intensity (EI) and subcutaneous adipose tissue thickness (SubQ) values obtained from panoramic transverse images (PTI) and still longitudinal images (SLI). Open circles represent measures obtained from PTI. Closed circles represent measures obtained from SLI.

APPENDIX B: TABLES

Table 1: Participant characteristics (n = 24).

	Mean	Std. Dev.	Minimum	Maximum
Age (y)	20.2	1.6	18.0	24.0
Height (m)	1.78	0.07	1.69	1.94
Weight (kg)	82.2	13.4	62.8	125.7
BMI (kg/m²)	25.84	3.31	20.51	35.57

BMI: Body Mass Index

Table 2: Precision measurements between three consecutive panoramic transverse images (PTI) or still longitudinal images (SLI) for cross-sectional area (CSA), echo intensity (EI), muscle thickness (MT), and subcutaneous adipose tissue thickness (SubQ).

		SEM	CV
PTI	CSA	0.726 cm ²	1.672%
	EI	1.639 AU	2.603%
	MT	0.065 cm	1.885%
	SubQ	0.018 cm	7.634%
SLI	CSA	0.040 cm ²	0.491%
	EI	1.059 AU	1.418%
	MT	0.013 cm	0.544%
	SubQ	0.005 cm	3.025%

SEM: Standard Error of Measurement; CV: Coefficient of Variation

Table 3: Echo intensity (EI; measured in AU), cross-sectional area (CSA; measured in cm²), muscle thickness (MT; measured in cm), and subcutaneous adipose tissue thickness (SubQ; measured in cm) values of the selected panoramic transverse images (PTI), still longitudinal images (SLI), anterior (AT), lateral (LT), and posterior (PT) tertiles. Results are reported as mean \pm standard deviation.

	EI	CSA †	MT	SubQ
SLI	65.453 \pm 11.023	7.750 \pm 1.519	2.015 \pm 0.397	0.316 \pm 0.225
PTI	57.976 \pm 8.806*	34.735 \pm 8.051*	2.178 \pm 0.367*	0.217 \pm 0.167*
AT	59.065 \pm 9.126	14.344 \pm 3.194*	-	-
LT	58.717 \pm 9.877*	11.554 \pm 2.797*	-	-
PT	56.354 \pm 9.887*	8.734 \pm 2.080*	-	-

* Denotes statistically significant difference ($p \leq 0.05$) from SLI.

† Denotes statistically significant difference ($p \leq 0.05$) between all image types.

Table 4: Pearson product-moment correlation coefficients between echo intensity (EI) measures in panoramic transverse images (PTI), still longitudinal images (SLI), anterior (AT), lateral (LT), and posterior (PT) tertiles. P-values are reported below correlation coefficients in parentheses.

	EI_{SLI}	EI_{AT}	EI_{LT}	EI_{PT}
EI_{PTI}	0.681** (<0.001)	0.925** (<0.001)	0.951** (<0.001)	0.855** (<0.001)
EI_{SLI}	-	0.510* (0.011)	0.800** (<0.001)	0.521** (0.009)
EI_{AT}	-	-	0.818** (<0.001)	0.663** (<0.001)
EI_{LT}	-	-	-	0.784** (<0.001)

* Correlation is significant at the $p \leq 0.05$ level.

**Correlation is significant at the $p \leq 0.01$ level.

Table 5: Pearson product-moment correlation coefficients between body mass index (BMI), muscle thickness (MT), cross-sectional area (CSA), and echo intensity (EI) values in panoramic transverse images (PTI) and still longitudinal images (SLI). Correlation coefficients reported with subcutaneous adipose tissue thickness (SubQ) were evaluated using Spearman's rho. P-values are reported below correlation coefficients in parentheses.

	MT_{PTI}	MT_{SLI}	SubQ_{PTI}	SubQ_{SLI}	CSA_{PTI}	CSA_{SLI}	EI_{PTI}	EI_{SLI}
BMI	0.519** (0.009)	0.659** (<0.001)	0.224 (0.293)	0.405* (0.049)	0.776** (<0.001)	0.640** (0.001)	-0.206 (0.335)	-0.379 (0.068)
MT_{PTI}	-	0.809** (<0.001)	0.169 (0.429)	0.217 (0.307)	0.731** (<0.001)	0.824** (<0.001)	-0.503* (0.012)	-0.644** (<0.001)
MT_{SLI}	-	-	0.290 (0.170)	0.339 (0.105)	0.764** (<0.001)	0.997** (<0.001)	-0.441* (0.031)	-0.067** (<0.001)
SubQ_{PTI}	-	-	-	0.915** (<0.001)	0.462* (0.023)	0.294 (0.163)	-0.015 (0.944)	-0.114 (0.597)
SubQ_{SLI}	-	-	-	-	0.571** (0.004)	0.340 (0.104)	-0.067 (0.754)	-0.178 (0.404)
CSA_{PTI}	-	-	-	-	-	0.752** (<0.001)	-0.413* (0.045)	-0.478* (0.018)
CSA_{SLI}	-	-	-	-	-	-	-0.468* (0.021)	-0.717** (<0.001)
EI_{PTI}	-	-	-	-	-	-	-	0.681** (<0.001)

* Correlation is significant at the $p \leq 0.05$ level.

**Correlation is significant at the $p \leq 0.01$ level.

**APPENDIX C: REQUIREMENTS FOR SELECTING THE BEST
PANORAMIC IMAGE**

Panoramic Transverse Image (PTI) Selection:

- Entire muscle area captured in a single image
- Consistent pressure applied throughout entire image
 - Consistent image quality
 - Minimal muscle compression
- Consistent probe speed during image capture
 - No blurriness
 - No discrepancies (overlaps) along epithelial and/or muscle border
- Clearest image of the three
- Analyzed on same computer and on same screen

**APPENDIX D: REQUIREMENTS FOR SELECTING THE BEST SINGLE
STILL LONGITUDINAL IMAGE**

Single Still Longitudinal Image (SLI) Selection:

- Consistent pressure applied by probe
 - Minimal muscle compression
- Superficial aponeurosis of vastus lateralis (adipose tissue/muscle interface) should be as close to horizontal as possible
- Entire length of image consists of muscle fibers (no aponeuroses or inconsistencies in probe pressure or placement)
- Analyzed on same computer and same screen

**APPENDIX E: INTERNATIONAL REVIEW BOARD (IRB) APPROVAL
FORM**



University of Central Florida Institutional Review Board
 Office of Research & Commercialization
 12201 Research Parkway, Suite 501
 Orlando, Florida 32826-3246
 Telephone: 407-823-2901 or 407-882-2276
www.research.ucf.edu/compliance/irb.html

Approval of Human Research

From: UCF Institutional Review Board #1
 FWA00000351, IRB00001138

To: Jay R Hoffman and Co-PIs: David Fukuda, Jeffrey Ray Stout

Date: October 15, 2014

Dear Researcher:

On 10/15/2014 the IRB approved the following human participant research until 10/14/2015 inclusive:

Type of Review: Submission Correction for UCF Initial Review Submission Form
 Expedited Review

Project Title: TRACKING GAME PERFORMANCE AND
 PHYSIOLOGICAL MEASURES IN COLLEGIATE CLUB
 MEN'S RUGBY PLAYERS

Investigator: Jay R Hoffman
 IRB Number: SBE-14-10579

Funding Agency:
 Grant Title:
 Research ID: N/A

The scientific merit of the research was considered during the IRB review. The Continuing Review Application must be submitted 30 days prior to the expiration date for studies that were previously expedited, and 60 days prior to the expiration date for research that was previously reviewed at a convened meeting. Do not make changes to the study (i.e., protocol, methodology, consent form, personnel, site, etc.) before obtaining IRB approval. A Modification Form cannot be used to extend the approval period of a study. All forms may be completed and submitted online at <https://iris.research.ucf.edu>.

If continuing review approval is not granted before the expiration date of 10/14/2015, approval of this research expires on that date. When you have completed your research, please submit a Study Closure request in iRIS so that IRB records will be accurate.

All data, including signed consent forms if applicable, must be retained and secured per protocol for a minimum of five years (six if HIPAA applies) past the completion of this research. Any links to the identification of participants should be maintained and secured per protocol. Additional requirements may be imposed by your funding agency, your department, or other entities. Access to data is limited to authorized individuals listed as key study personnel.

In the conduct of this research, you are responsible to follow the requirements of the [Investigator Manual](#).

On behalf of Sophia Dziegielewski, Ph.D., L.C.S.W., UCF IRB Chair, this letter is signed by:

Signature applied by Patria Davis on 10/15/2014 04:23:19 PM EDT

IRB Coordinator

**APPENDIX F: LETTER TO THE UNIVERSITY OF CENTRAL
FLORIDA'S CLUB RUGBY COACH**

Dear UCF Men's Rugby Club Coach,

The data collected from your team (University of Central Florida Men's Rugby Club), will be used in research performed by the Human Performance Laboratory at University of Central Florida under the direction of Dr. Jay Hoffman and Dr. Satoru Tanigawa.

Data that will be used will include the results of the following tests:

- **Dynavision D2 Visuomotor Reaction testing** – visual and motor reaction time
- **NeuroTracker Core** – multiple object tracking ability
- **Anthropometrics** – height & weight
- **Skinfolds** – estimation of body fat percentage
- **Ultrasound** – muscle architecture of the vastus lateralis (outer quadriceps muscle)
- **VO₂ Max** – maximal oxygen uptake
- **Countermovement jump & drop jump** – power and reactive strength
- **Mid-thigh pull** – power & rate of force development
- **Isokinetic leg extension/flexion** – force at different angular velocities and flexion/extension strength ratios
- **One rep maximum bench press and back squat** – maximal strength
- **One minute all-out sprint on a non-motorized treadmill** – velocity, power, and fatigue rate
- **40 m dash, T-test, and Pro-Agility test** – velocity & agility
- **GPS 3 minute run** – velocity & fatigue rate
- **In-game GPS tracking** – distance covered, player load, and sprint speed & frequency

When data is presented or published, it will be de-identified, meaning no individual names will be associated with the data. As a whole, the data will be identified as coming from the University of Central Florida Men's Rugby Club 2014-2015, which may be shortened to UCF Men's Rugby 2014-2015. Data will also be split and differentiated between A-side and B-side players in order to find predictors of performance.

The information contained in this letter should also be shared with members of the team for their information. Please feel free to contact us with any questions you may have. The Human Performance Laboratory phone number is (407) 823-2367, or you can email Amelia Miramonti at amelia.miramonti@ucf.edu.

Sincerely,

Dr. Jay Hoffman, PhD

Dr. Satoru Tanigawa, PhD

**APPENDIX G: DATA COLLECTION SHEET FOR ULTRASOUND
PROCEDURE RELIABILITY**

Day 1

	CSA _{PTI}	EI _{PTI}	MT _{PTI}	SubQ _{PTI}	CSA _{SLI}	EI _{SLI}	MT _{SLI}	SubQ _{SLI}
Subject 1								
Subject 2								
Subject 3								
Subject 4								
Subject 5								
Subject 6								
Subject 7								
Subject 8								
Subject 9								
Subject 10								

Day 2

	CSA _{PTI}	EI _{PTI}	MT _{PTI}	SubQ _{PTI}	CSA _{SLI}	EI _{SLI}	MT _{SLI}	SubQ _{SLI}
Subject 1								
Subject 2								
Subject 3								
Subject 4								
Subject 5								
Subject 6								
Subject 7								
Subject 8								
Subject 9								
Subject 10								

	CSA _{PTI}	EI _{PTI}	MT _{PTI}	SubQ _{PTI}	CSA _{SLI}	EI _{SLI}	MT _{SLI}	SubQ _{SLI}
ICC (3,1)								
SEM								
MD								
CV								

**APPENDIX H: DATA COLLECTION SHEETS FOR ULTRASOUND
PRECISION VALUES**

Panoramic Transverse Images (PTI)												
	CSA	CSA	CSA	EI	EI	EI	MT	MT	MT	SubQ	SubQ	SubQ
	1	2	3	1	2	3	1	2	3	1	2	3
Subject 1												
Subject 2												
Subject 3												
Subject 4												
Subject 5												
Subject 6												
Subject 7												
Subject 8												
Subject 9												
Subject 10												
Subject 11												
Subject 12												
Subject 13												
Subject 14												
Subject 15												
Subject 16												
Subject 17												
Subject 18												
Subject 19												
Subject 20												
Subject 21												
Subject 22												
Subject 23												
Subject 24												

SEM	
CV	

SEM	
CV	

SEM	
CV	

SEM	
CV	

Single Still Longitudinal Images (SLI)												
	CSA	CSA	CSA	EI	EI	EI	MT	MT	MT	SubQ	SubQ	SubQ
	1	2	3	1	2	3	1	2	3	1	2	3
Subject 1												
Subject 2												
Subject 3												
Subject 4												
Subject 5												
Subject 6												
Subject 7												
Subject 8												
Subject 9												
Subject 10												
Subject 11												
Subject 12												
Subject 13												
Subject 14												
Subject 15												
Subject 16												
Subject 17												
Subject 18												
Subject 19												
Subject 20												
Subject 21												
Subject 22												
Subject 23												
Subject 24												

SEM	
CV	

SEM	
CV	

SEM	
CV	

SEM	
CV	

APPENDIX I: BEST IMAGE SELECTION CHECKBOX

Best Image Selection

Please select the Best of the following images by placing a check mark in the corresponding box:

	Panoramic Transverse Images (PTI)			Single Longitudinal Images (SLI)		
	1	2	3	1	2	3
Subject 1						
Subject 2						
Subject 3						
Subject 4						
Subject 5						
Subject 6						
Subject 7						
Subject 8						
Subject 9						
Subject 10						
Subject 11						
Subject 12						
Subject 13						
Subject 14						
Subject 15						
Subject 16						
Subject 17						
Subject 18						
Subject 19						
Subject 20						
Subject 21						
Subject 22						
Subject 23						
Subject 24						

**APPENDIX J: DATA COLLECTION SHEETS FOR VARIABLES OF
BEST ULTRASOUND IMAGES**

Panoramic Transverse Images (PTI)													
	CSA _{PTI}	El _{PTI}	MT _{PTI}	SubQ _{PTI}	Total Length	1/2 PTI Length	1/3 PTI Length	CSA _{AT}	El _{AT}	CSA _{LT}	El _{LT}	CSA _{PT}	El _{PT}
Subject 1													
Subject 2													
Subject 3													
Subject 4													
Subject 5													
Subject 6													
Subject 7													
Subject 8													
Subject 9													
Subject 10													
Subject 11													
Subject 12													
Subject 13													
Subject 14													
Subject 15													
Subject 16													
Subject 17													
Subject 18													
Subject 19													
Subject 20													
Subject 21													
Subject 22													
Subject 23													
Subject 24													

Single Still Longitudinal Images (SLI)				
	CSA _{SLI}	EI _{SLI}	MT _{SLI}	SubQ _{SLI}
Subject 1				
Subject 2				
Subject 3				
Subject 4				
Subject 5				
Subject 6				
Subject 7				
Subject 8				
Subject 9				
Subject 10				
Subject 11				
Subject 12				
Subject 13				
Subject 14				
Subject 15				
Subject 16				
Subject 17				
Subject 18				
Subject 19				
Subject 20				
Subject 21				
Subject 22				
Subject 23				
Subject 24				

REFERENCES

- Aagaard, P., Andersen, J. L., Dyhre-Poulsen, P., Leffers, A. M., Wagner, A., Magnusson, S. P., Halkhaer-Kristensen, J., & Simonsen, E. B. (2001). A mechanism for increased contractile strength of human pennate muscle in response to strength training: changes in muscle architecture. *The Journal of Physiology*, *534*(2), 613-623.
- Abe, T., Brechue, W. F., Fujita, S., & Brown, J. B. (1998). Gender differences in FFM accumulation and architectural characteristics of muscle. *Medicine and Science in Sports and Exercise*, *30*(7), 1066-1070.
- Abernethy, P. J., Thayer, R., & Taylor, A. W. (1990). Acute and chronic responses of skeletal muscle to endurance and sprint exercise. *Sports Medicine*, *10*(6), 365-389.
- Adams, G. R., Duvoisin, M. R., & Dudley, G. A. (1992). Magnetic resonance imaging and electromyography as indexes of muscle function. *Journal of Applied Physiology*, *73*(4), 1578-1583.
- Ahtiainen, J. P., Hoffren, M., Hulmi, J. J., Pietikäinen, M., Mero, A. A., Avela, J., & Häkkinen, K. (2010). Panoramic ultrasonography is a valid method to measure changes in skeletal muscle cross-sectional area. *European Journal of Applied Physiology*, *108*(2), 273-279.
- Akima, H., Takahashi, H., Kuno, S. Y., & Katsuta, S. (2004). Coactivation pattern in human quadriceps during isokinetic knee-extension by muscle functional MRI. *European Journal of Applied Physiology*, *91*(1), 7-14.
- Akima, H., Takahashi, H., Kuno, S. Y., Masuda, K., Masuda, T., Shimojo, H., Izumi, A., Yuji, I., & Katsuta, S. H. (1999). Early phase adaptations of muscle use and strength to isokinetic training. *Medicine and Science in Sports and Exercise*, *31*(4), 588-594.

- Allen, D. L., Roy, R. R., & Edgerton, V. R. (1999). Myonuclear domains in muscle adaptation and disease. *Muscle & Nerve*, 22(10), 1350-1360.
- An, K. N., Linscheid, R. L., & Brand, P. W. (1991). Correlation of physiological cross-sectional areas of muscle and tendon. *Journal of Hand Surgery (British and European Volume)*, 16(1), 66-67.
- Andersson, A., Sjödin, A., Hedman, A., Olsson, R., & Vessby, B. (2000). Fatty acid profile of skeletal muscle phospholipids in trained and untrained young men. *American Journal of Physiology-Endocrinology and Metabolism*, 279(4), E744-E751.
- Arbanas, J., Starcevic Klasan, G., Nikolic, M., Jerkovic, R., Miljanovic, I., & Malnar, D. (2009). Fibre type composition of the human psoas major muscle with regard to the level of its origin. *Journal of Anatomy*, 215(6), 636-641.
- Arbeille, P., Kerbeci, P., Capri, A., Dannaud, C., Trappe, S. W., & Trappe, T. A. (2009). Quantification of muscle volume by echography: comparison with MRI data on subjects in long-term bed rest. *Ultrasound in Medicine & Biology*, 35(7), 1092-1097.
- Arts, I. M., Pillen, S., Schelhaas, H. J., Overeem, S., & Zwarts, M. J. (2010). Normal values for quantitative muscle ultrasonography in adults. *Muscle & Nerve*, 41(1), 32-41.
- Arts, I. M., Schelhaas, H. J., Verrijp, K. C., Zwarts, M. J., Overeem, S., van der Laak, J. A., Lammens, M.M.Y., & Pillen, S. (2012). Intramuscular fibrous tissue determines muscle echo intensity in amyotrophic lateral sclerosis. *Muscle & Nerve*, 45(3), 449-450.
- Bangsbo, J., Graham, T. E., Kiens, B., & Saltin, B. (1992). Elevated muscle glycogen and anaerobic energy production during exhaustive exercise in man. *The Journal of Physiology*, 451(1), 205-227.

- Bartko, J. J. (1966). The intraclass correlation coefficient as a measure of reliability. *Psychological Reports, 19*(1), 3-11.
- Bemben, M. G. (2002). Use of diagnostic ultrasound for assessing muscle size. *The Journal of Strength & Conditioning Research, 16*(1), 103-108.
- Blomqvist, C. G., & Saltin, B. (1983). Cardiovascular adaptations to physical training. *Annual Review of Physiology, 45*(1), 169-189.
- Buchanan, T. S., Almdale, D. P., Lewis, J. L., & Rymer, W. Z. (1986). Characteristics of synergic relations during isometric contractions of human elbow muscles. *Journal of Neurophysiology, 56*(5), 1225-1241.
- Buckthorpe, M. W., Hannah, R., Pain, T. G., & Folland, J. P. (2012). Reliability of neuromuscular measurements during explosive isometric contractions, with special reference to electromyography normalization techniques. *Muscle & Nerve, 46*(4), 566-576.
- Burkholder, T. J., Fingado, B., Baron, S., & Lieber, R. L. (1994). Relationship between muscle fiber types and sizes and muscle architectural properties in the mouse hindlimb. *Journal of Morphology, 221*(2), 177-190.
- Cadore, E. L., Izquierdo, M., Conceição, M., Radaelli, R., Pinto, R. S., Baroni, B. M., Vaz, M.A., Alberton, C.L., Pinto, S.S., Cunha, G., Bottaro, M. & Kruel, L.F.M. (2012). Echo intensity is associated with skeletal muscle power and cardiovascular performance in elderly men. *Experimental Gerontology, 47*(6), 473-478.
- Caresio, C., Molinari, F., Emanuel, G., & Minetto, M. A. (2015). Muscle echo intensity: reliability and conditioning factors. *Clinical Physiology and Functional Imaging, 35*(5), 393-403.

- Charette, S., McEvoy, L., Pyka, G., Snow-Harter, C., Guido, D., Wiswell, R. A., & Marcus, R. (1991). Muscle hypertrophy response to resistance training in older women. *Journal of Applied Physiology*, *70*(5), 1912-1916.
- Chen, T. C., Chen, H. L., Lin, M. J., Wu, C. J., & Nosaka, K. (2009). Muscle damage responses of the elbow flexors to four maximal eccentric exercise bouts performed every 4 weeks. *European Journal of Applied Physiology*, *106*(2), 267-275.
- Chen, T. C., Lin, K. Y., Chen, H. L., Lin, M. J., & Nosaka, K. (2011). Comparison in eccentric exercise-induced muscle damage among four limb muscles. *European Journal of Applied Physiology*, *111*(2), 211-223.
- Chin, E. R., & Allen, D. G. (1997). Effects of reduced muscle glycogen concentration on force, Ca²⁺ release and contractile protein function in intact mouse skeletal muscle. *The Journal of Physiology*, *498*(1), 17.
- Cruz-Jentoft, A. J., Baeyens, J. P., Bauer, J. M., Boirie, Y., Cederholm, T., Landi, F., Martin, F.C., Michel, J., Rolland, Y., Schneider, S.M., Topinková, E., Vandewoude, M., & Zamboni, M. (2010). Sarcopenia: European consensus on definition and diagnosis Report of the European Working Group on Sarcopenia in Older People. *Age and Ageing*, *39*, 412-423.
- Daneshjoo, A., Rahnama, N., Mokhtar, A. H., & Yusof, A. (2013). Bilateral and unilateral asymmetries of isokinetic strength and flexibility in male young professional soccer players. *Journal of Human Kinetics*, *36*(1), 45-53.
- Dauty, M., Potiron-Josse, M., & Rochcongar, P. (2003). Identification of previous hamstring muscle injury by isokinetic concentric and eccentric torque measurement in elite soccer player. *Isokinetics and Exercise Science*, *11*(3), 139-144.

- Deschenes, M. R., & Kraemer, W. J. (2002). Performance and physiologic adaptations to resistance training. *American Journal of Physical Medicine & Rehabilitation*, 81(11), S3-S16.
- Duthie, G., Pyne, D., & Hooper, S. (2003). Applied physiology and game analysis of rugby union. *Sports Medicine*, 33(13), 973-991.
- Elder, G. C., Bradbury, K., & Roberts, R. (1982). Variability of fiber type distributions within human muscles. *Journal of Applied Physiology*, 53(6), 1473-1480.
- Elias, L. J., Bryden, M. P., & Bulman-Fleming, M. B. (1998). Footedness is a better predictor than is handedness of emotional lateralization. *Neuropsychologia*, 36(1), 37-43.
- Ema, R., Wakahara, T., Miyamoto, N., Kanehisa, H., & Kawakami, Y. (2013). Inhomogeneous architectural changes of the quadriceps femoris induced by resistance training. *European Journal of Applied Physiology*, 113(11), 2691-2703.
- Ema, R., Wakahara, T., Mogi, Y., Miyamoto, N., Komatsu, T., Kanehisa, H., & Kawakami, Y. (2013). In vivo measurement of human rectus femoris architecture by ultrasonography: validity and applicability. *Clinical Physiology and Functional Imaging*, 33(4), 267-273.
- English, C., Fisher, L., & Thoirs, K. (2012). Reliability of real-time ultrasound for measuring skeletal muscle size in human limbs in vivo: a systematic review. *Clinical Rehabilitation*, 26(10), 934-944.
- English, A. W., Wolf, S. L., & Segal, R. L. (1993). Compartmentalization of muscles and their motor nuclei: the partitioning hypothesis. *Physical Therapy*, 73(12), 857-867.
- Esformes, J. I., Narici, M. V., & Maganaris, C. N. (2002). Measurement of human muscle volume using ultrasonography. *European Journal of Applied Physiology*, 87(1), 90-92.

- Fanelli, M. T., & Kuczmarski, R. J. (1984). Ultrasound as an approach to assessing body composition. *The American Journal of Clinical Nutrition*, 39(5), 703-709.
- Fredricks, G. A., & Nelsen, R. B. (2007). On the relationship between Spearman's rho and Kendall's tau for pairs of continuous random variables. *Journal of Statistical Planning and Inference*, 137(7), 2143-2150.
- Fisher, M.J., Meyer, R.A., Adams, G.R., Foley, J.M., & Potchen, E.J. (1990). Direct relationship between proton T2 and exercise intensity in skeletal muscle MR images. *Investigative Radiology*, 25(5), 480-485.
- Fleckenstein, J. L., Bertocci, L. A., Nunnally, R. L., Parkey, R. W., & Peshock, R. M. (1989). 1989 ARRS Executive Council Award. Exercise-enhanced MR imaging of variations in forearm muscle anatomy and use: importance in MR spectroscopy. *American Journal of Roentgenology*, 153(4), 693-698.
- Fukumoto, Y., Ikezoe, T., Yamada, Y., Tsukagoshi, R., Nakamura, M., Mori, N., Kimura, M., & Ichihashi, N. (2012). Skeletal muscle quality assessed from echo intensity is associated with muscle strength of middle-aged and elderly persons. *European Journal of Applied Physiology*, 112(4), 1519-1525.
- Fukunaga, T., Miyatani, M., Tachi, M., Kouzaki, M., Kawakami, Y., & Kanehisa, H. (2001). Muscle volume is a major determinant of joint torque in humans. *Acta Physiologica Scandinavica*, 172(4), 249-255.
- Fukutani, A., & Kurihara, T. (2015). Comparison of the muscle fascicle length between resistance-trained and untrained individuals: cross-sectional observation. *SpringerPlus*, 4(1), 1-6.

- Gan, S. K., Samaras, K., Thompson, C. H., Kraegen, E. W., Carr, A., Cooper, D. A., & Chisholm, D. J. (2002). Altered myocellular and abdominal fat partitioning predict disturbance in insulin action in HIV protease inhibitor-related lipodystrophy. *Diabetes*, *51*(11), 3163-3169.
- Häkkinen, K., Pakarinen, A., Kraemer, W. J., Häkkinen, A., Valkeinen, H., & Alen, M. (2001). Selective muscle hypertrophy, changes in EMG and force, and serum hormones during strength training in older women. *Journal of Applied Physiology*, *91*(2), 569-580.
- Hargreaves, M., Meredith, I., & Jennings, G. L. (1992). Muscle glycogen and glucose uptake during exercise in humans. *Experimental Physiology*, *77*, 641-644.
- Henrich, W., Schmider, A., Kjos, S., Tutschek, B., & Dudenhausen, J. W. (2003). Advantages of and applications for extended field-of-view ultrasound in obstetrics. *Archives of Gynecology and Obstetrics*, *268*(2), 121-127.
- Hill, J. C., & Millán, I. S. (2014). Validation of musculoskeletal ultrasound to assess and quantify muscle glycogen content. A novel approach. *The Physician and Sports Medicine*, *42*(3), 45-52.
- Hinkle, D. E., Wiersma, W., & Jurs, S. G. (2003). *Applied Statistics for the Behavioral Sciences*. Boston: Houghton Mifflin.
- Housh, D. J., Housh, T. J., Johnson, G. O., & Chu, W. K. (1992). Hypertrophic response to unilateral concentric isokinetic resistance training. *Journal of Applied Physiology*, *73*(1), 65-70.
- Hurley, B. F., Nemeth, P. M., Martin, W. H. D., Hagberg, J. M., Dalsky, G. P., & Holloszy, J. O. (1986). Muscle triglyceride utilization during exercise: effect of training. *Journal of Applied Physiology*, *60*(2), 562-567.

- Ihnatsenka, B., & Boezaart, A. P. (2010). Ultrasound: Basic understanding and learning the language. *International Journal of Shoulder Surgery*, 4(3), 55-62.
- Ikai, M., & Fukunaga, T. (1970). A study on training effect on strength per unit cross-sectional area of muscle by means of ultrasonic measurement. *Internationale Zeitschrift für Angewandte Physiologie Einschliesslich Arbeitsphysiologie*, 28(3), 173-180.
- Ivey, F. M., Tracy, B. L., Lemmer, J. T., NessAiver, M., Metter, E. J., Fozard, J. L., & Hurley, B. F. (2000). Effects of strength training and detraining on muscle quality age and gender comparisons. *The Journals of Gerontology Series A: Biological Sciences and Medical Sciences*, 55(3), B152-B157.
- Jajtner, A. R., Hoffman, J. R., Scanlon, T. C., Wells, A. J., Townsend, J. R., Beyer, K. S., Mangine, G.T., McCormack, W.P., Bohner, J.D., Fragala, M.S., & Stout, J. R. (2013). Performance and muscle architecture comparisons between starters and nonstarters in National Collegiate Athletic Association Division I women's soccer. *The Journal of Strength & Conditioning Research*, 27(9), 2355-2365.
- Jajtner, A. R., Hoffman, J. R., Gonzalez, A. M., Worts, P. R., Fragala, M. S., & Stout, J. R. (2015). Comparison of the effects of electrical stimulation and cold-water immersion on muscle soreness after resistance exercise. *Journal of Sport Rehabilitation*, 24(2), 99-108.
- Janssen, I., Heymsfield, S. B., & Ross, R. (2002). Low relative skeletal muscle mass (sarcopenia) in older persons is associated with functional impairment and physical disability. *Journal of the American Geriatrics Society*, 50(5), 889-896.

- Jenkins, N. D., Miller, J. M., Buckner, S. L., Cochrane, K. C., Bergstrom, H. C., Hill, E. C., Smith, C.M., Housh, T.J., & Cramer, J. T. (2015). Test–retest reliability of single transverse versus panoramic ultrasound imaging for muscle size and echo intensity of the biceps brachii. *Ultrasound in Medicine & Biology*, *41*(6), 1584-1591.
- Johnson, M. A., Sideri, G., Weightman, D., & Appleton, D. (1973). A comparison of fibre size, fibre type constitution and spatial fibre type distribution in normal human muscle and in muscle from cases of spinal muscular atrophy and from other neuromuscular disorders. *Journal of the Neurological Sciences*, *20*(4), 345-361.
- Jones, J. K., Krow, A., Hariharan, S., & Weekes, L. (2008). Measuring angles on digitalized radiographic images using Microsoft PowerPoint. *West Indian Medical Journal*, *57*(1), 14-19.
- Kim, S. H., Choi, B. I., Kim, K. W., Lee, K. H., & Han, J. K. (2003). Extended field-of-view sonography advantages in abdominal applications. *Journal of Ultrasound in Medicine*, *22*(4), 385-394.
- Koppenhaver, S. L., Parent, E. C., Teyhen, D. S., Hebert, J. J., & Fritz, J. M. (2009). The effect of averaging multiple trials on measurement error during ultrasound imaging of transversus abdominis and lumbar multifidus muscles in individuals with low back pain. *Journal of Orthopaedic & Sports Physical Therapy*, *39*(8), 604-611.
- Kraemer, W. J. (1997). A Series of Studies-The Physiological Basis for Strength Training in American Football: Fact Over Philosophy. *The Journal of Strength & Conditioning Research*, *11*(3), 131-142.

- Kubo, K., Kanehisa, H., Miyatani, M., Tachi, M., & Fukunaga, T. (2003). Effect of low-load resistance training on the tendon properties in middle-aged and elderly women. *Acta Physiologica Scandinavica*, 178(1), 25-32.
- Lee, I. A., & Preacher, K. J. (2013, September). Calculation for the test of the difference between two dependent correlations with one variable in common [Computer software]. Available from <http://quantpsy.org>.
- Levine, J. A., Abboud, L., Barry, M., Reed, J. E., Sheedy, P. F., & Jensen, M. D. (2000). Measuring leg muscle and fat mass in humans: comparison of CT and dual-energy X-ray absorptiometry. *Journal of Applied Physiology*, 88(2), 452-456.
- Lexell, J., & Taylor, C. C. (1991). Variability in muscle fibre areas in whole human quadriceps muscle: effects of increasing age. *Journal of Anatomy*, 174, 239.
- Lixandrão, M. E., Ugrinowitsch, C., Bottaro, M., Chacon-Mikahil, M. P., Cavaglieri, C. R., Min, L. L., de Souza, E.O., Laurentino, G.C., & Libardi, C. A. (2014). Vastus Lateralis muscle cross-sectional area ultrasonography validity for image fitting in humans. *The Journal of Strength & Conditioning Research*, 28(11), 3293-3297.
- Lopez-Rivero, J. L., Serrano, A. L., Diz, A. M., & Galisteo, A. M. (1992). Variability of muscle fibre composition and fibre size in the horse gluteus medius: an enzyme-histochemical and morphometric study. *Journal of Anatomy*, 181(1), 1-10.
- MacKay, E. M., & Bergman, H. C. (1932). The relation between glycogen and water storage in the liver. *Journal of Biological Chemistry*, 96, 373-380.
- Mahon, M., Toman, A., Willan, P. L. T., & Bagnall, K. M. (1984). Variability of histochemical and morphometric data from needle biopsy specimens of human quadriceps femoris muscle. *Journal of the Neurological Sciences*, 63(1), 85-100.

- Mangine, G. T., Fukuda, D. H., LaMonica, M. B., Gonzalez, A. M., Wells, A. J., Townsend, J. R., Jajtner, A.R., Fragala, M.S., Stout, J.R., & Hoffman, J. R. (2014). Influence of gender and muscle architecture asymmetry on jump and sprint performance. *Journal of Sports Science & Medicine, 13*(4), 904.
- Mangine, G. T., Fukuda, D. H., Townsend, J. R., Wells, A. J., Gonzalez, A. M., Jajtner, A. R., Bohner, J.D., La Monica, M., Hoffman, J.R., Fragala, M.S., & Stout, J. R. (2015). Sprinting performance on the Woodway Curve 3.0 TM is related to muscle architecture. *European journal of sport science, 15*(7), 606-614.
- Mangine, G. T., Hoffman, J. R., Gonzalez, A. M., Jajtner, A. R., Scanlon, T., Rogowski, J. P., Wells, A.J., Fragala., M.S., & Stout, J. R. (2014). Bilateral differences in muscle architecture and increased rate of injury in national basketball association players. *Journal of Athletic Training, 49*(6), 794-799.
- Mayhew, J. L., Piper, F. C., & Ware, J. S. (1993). Anthropometric correlates with strength performance among resistance trained athletes. *The Journal of Sports Medicine and Physical Fitness, 33*(2), 159-165.
- McCall, G. E., Byrnes, W. C., Dickinson, A., Pattany, P. M., & Fleck, S. J. (1996). Muscle fiber hypertrophy, hyperplasia, and capillary density in college men after resistance training. *Journal of Applied Physiology, 81*(5), 2004-2012.
- Melnyk, J. A., Rogers, M. A., & Hurley, B. F. (2009). Effects of strength training and detraining on regional muscle in young and older men and women. *European Journal of Applied Physiology, 105*(6), 929-938.

- Melvin, M. N., Smith-Ryan, A. E., Wingfield, H. L., Ryan, E. D., Trexler, E. T., & Roelofs, E. J. (2014). Muscle characteristics and body composition of NCAA division I football players. *The Journal of Strength & Conditioning Research*, 28(12), 3320-3329.
- Miljkovic, I., & Zmuda, J. M. (2010). Epidemiology of myosteatosis. *Current Opinion in Clinical Nutrition and Metabolic Care*, 13(3), 260.
- Moreau, N. G., Teefey, S. A., & Damiano, D. L. (2009). In vivo muscle architecture and size of the rectus femoris and vastus lateralis in children and adolescents with cerebral palsy. *Developmental Medicine & Child Neurology*, 51(10), 800-806.
- Moreau, N. G., Simpson, K. N., Teefey, S. A., & Damiano, D. L. (2010). Muscle architecture predicts maximum strength and is related to activity levels in cerebral palsy. *Physical Therapy*, 90(11), 1619-1630.
- Morgan, T. E., Short, F. A., & Cobb, L. A. (1969). Effect of long-term exercise on skeletal muscle lipid composition. *American Journal of Physiology-Legacy Content*, 216(1), 82-86.
- Mudholkar, G. S. (1983). Fisher's Z-Transformation. *Encyclopedia of Statistical Sciences*.
- Narici, M. V., Hoppeler, H., Kayser, B., Landoni, L., Claassen, H., Gavardi, C., Conti, M., & Cerretelli, P. (1996). Human quadriceps cross-sectional area, torque and neural activation during 6 months strength training. *Acta Physiologica Scandinavica*, 157(2), 175-186.
- Narici, M. V., Roi, G. S., & Landoni, L. (1988). Force of knee extensor and flexor muscles and cross-sectional area determined by nuclear magnetic resonance imaging. *European Journal of Applied Physiology and Occupational Physiology*, 57(1), 39-44.

- Narici, M. V., Roi, G. S., Landoni, L., Minetti, A. E., & Cerretelli, P. (1989). Changes in force, cross-sectional area and neural activation during strength training and detraining of the human quadriceps. *European Journal of Applied Physiology and Occupational Physiology*, 59(4), 310-319.
- Nielsen, P., Jensen, B. R., Darvann, T., Jørgensen, K., & Bakke, M. (2006). Quantitative ultrasound tissue characterization in shoulder and thigh muscles—a new approach. *BMC Musculoskeletal Disorders*, 7(1), 1-11.
- Nijboer-Oosterveld, J., van Alfen, N., & Pillen, S. (2011). New normal values for quantitative muscle ultrasound: obesity increases muscle echo intensity. *Muscle & Nerve*, 43(1), 142-143.
- Nimphius, S., McGuigan, M. R., & Newton, R. U. (2012). Changes in muscle architecture and performance during a competitive season in female softball players. *The Journal of Strength & Conditioning Research*, 26(10), 2655-2666.
- Noorkoiv, M., Nosaka, K., & Blazeovich, A. J. (2010). Assessment of quadriceps muscle cross-sectional area by ultrasound extended-field-of-view imaging. *European Journal of Applied Physiology*, 109(4), 631-639.
- Nygaard, E., & Sanchez, J. (1982). Intramuscular variation of fiber types in the brachial biceps and the lateral vastus muscles of elderly men: how representative is a small biopsy sample? *The Anatomical Record*, 203(4), 451-459.
- Olsson, K. E., & Saltin, B. (1970). Variation in total body water with muscle glycogen changes in man. *Acta Physiologica Scandinavica*, 80(1), 11-18.
- O'Donoghue, P. (2013). *Statistics for Sport and Exercise Studies: An Introduction*. Routledge.

- Petrofsky, J. (2008). The effect of the subcutaneous fat on the transfer of current through skin and into muscle. *Medical Engineering & Physics*, 30(9), 1168-1176.
- Pillen, S. (2010). Skeletal muscle ultrasound. *European Journal of Translational Myology*, 20(4), 145-156.
- Pillen, S., Arts, I. M., & Zwarts, M. J. (2008). Muscle ultrasound in neuromuscular disorders. *Muscle & Nerve*, 37(6), 679-693.
- Pillen, S., Tak, R. O., Zwarts, M. J., Lammens, M. M., Verrijp, K. N., Arts, I. M., van der Laak, J.A., Hoogerbrugge, P.M., van Engelen, B.G.M., & Verrips, A. (2009). Skeletal muscle ultrasound: correlation between fibrous tissue and echo intensity. *Ultrasound in Medicine & Biology*, 35(3), 443-446.
- Pillen, S., & van Alfen, N. (2011). Skeletal muscle ultrasound. *Neurological Research*, 33(10), 1016-1024.
- Pineau, J. C., Filliard, J. R., & Bocquet, M. (2009). Ultrasound techniques applied to body fat measurement in male and female athletes. *Journal of Athletic Training*, 44(2), 142-147.
- Radaelli, R., Botton, C. E., Wilhelm, E. N., Bottaro, M., Lacerda, F., Gaya, A., Moraes, K., Peruzzolo, A., Brown, L.E., & Pinto, R. S. (2013). Low-and high-volume strength training induces similar neuromuscular improvements in muscle quality in elderly women. *Experimental Gerontology*, 48(8), 710-716.
- Reeves, N. D., Maganaris, C. N., & Narici, M. V. (2004). Ultrasonographic assessment of human skeletal muscle size. *European Journal of Applied Physiology*, 91(1), 116-118.
- Reimers, K., Reimers, C. D., Wagner, S., Paetzke, I., & Pongratz, D. E. (1993). Skeletal muscle sonography: a correlative study of echogenicity and morphology. *Journal of Ultrasound in Medicine*, 12(2), 73-77.

- Richardson, R. S., Frank, L. R., & Haseler, L. J. (1998). Dynamic knee-extensor and cycle exercise: functional MRI of muscular activity. *International Journal of Sports Medicine*, *19*(3), 182-187.
- Rosenberg, J. G., Ryan, E. D., Sobolewski, E. J., Scharville, M. J., Thompson, B. J., & King, G. E. (2014). Reliability of panoramic ultrasound imaging to simultaneously examine muscle size and quality of the medial gastrocnemius. *Muscle & Nerve*, *49*(5), 736-740.
- Sale, D. G. (1988). Neural adaptation to resistance training. *Medicine and Science in Sports and Exercise*, *20*(5), S135-45.
- Scanlon, T. C., Fragala, M. S., Stout, J. R., Emerson, N. S., Beyer, K. S., Oliveira, L. P., & Hoffman, J. R. (2014). Muscle architecture and strength: Adaptations to short-term resistance training in older adults. *Muscle & Nerve*, *49*(4), 584-592.
- Scholten, R. R., Pillen, S., Verrips, A., & Zwarts, M. J. (2003). Quantitative ultrasonography of skeletal muscles in children: normal values. *Muscle & Nerve*, *27*(6), 693-698.
- Schrauwen-Hinderling, V. B., Schrauwen, P., Hesselink, M. K. C., Van Engelshoven, J. M. A., Nicolay, K., Saris, W. H. M., Kessels, A.G.H., & Kooi, M. E. (2003). The increase in intramyocellular lipid content is a very early response to training. *The Journal of Clinical Endocrinology & Metabolism*, *88*(4), 1610-1616.
- Scott, J. M., Martin, D. S., Ploutz-Snyder, R., Caine, T., Matz, T., Arzeno, N. M., Buxton, R., & Ploutz-Snyder, L. (2012). Reliability and validity of panoramic ultrasound for muscle quantification. *Ultrasound in Medicine & Biology*, *38*(9), 1656-1661.
- Segal, R. L. (1992). Neuromuscular compartments in the human biceps brachii muscle. *Neuroscience Letters*, *140*(1), 98-102.

- Segal, R. L., Wolf, S. L., DeCamp, M. J., Chopp, M. T., & English, A. W. (1991). Anatomical partitioning of three multiarticular human muscles. *Acta Anatomica*, *142*(3), 261-266.
- Selkow, N. M., Pietrosimone, B. G., & Saliba, S. A. (2011). Subcutaneous thigh fat assessment: a comparison of skinfold calipers and ultrasound imaging. *Journal of Athletic Training*, *46*(1), 50-54.
- Seynnes, O. R., de Boer, M., & Narici, M. V. (2007). Early skeletal muscle hypertrophy and architectural changes in response to high-intensity resistance training. *Journal of Applied Physiology*, *102*(1), 368-373.
- Shen, W., Punyanitya, M., Wang, Z., Gallagher, D., Onge, M. P. S., Albu, J., Heymsfield, S.B., & Heshka, S. (2004). Total body skeletal muscle and adipose tissue volumes: estimation from a single abdominal cross-sectional image. *Journal of Applied Physiology*, *97*(6), 2333-2338.
- Steiger, J. H. (1980). Tests for comparing elements of a correlation matrix. *Psychological Bulletin*, *87*(2), 245.
- Strasser, E. M., Draskovits, T., Praschak, M., Quittan, M., & Graf, A. (2013). Association between ultrasound measurements of muscle thickness, pennation angle, echogenicity and skeletal muscle strength in the elderly. *Age*, *35*(6), 2377-2388.
- Thomaes, T., Thomis, M., Onkelinx, S., Coudyzer, W., Cornelissen, V., & Vanhees, L. (2012). Reliability and validity of the ultrasound technique to measure the rectus femoris muscle diameter in older CAD-patients. *BMC Medical Imaging*, *12*(1), 1-6.
- Toomey, C., McCreesh, K., Leahy, S., & Jakeman, P. (2011). Technical considerations for accurate measurement of subcutaneous adipose tissue thickness using B-mode ultrasound. *Ultrasound*, *19*(2), 91-96.

- van Loon, L. J., & Goodpaster, B. H. (2006). Increased intramuscular lipid storage in the insulin-resistant and endurance-trained state. *Pflügers Archiv*, *451*(5), 606-616.
- Vincent, W. J., & Weir, J. P. (2012). *Statistics in Kinesiology*. Champaign: Human Kinetics.
- Wagner, D. R. (2013). Ultrasound as a tool to assess body fat. *Journal of Obesity*, *2013*.
- Wakahara, T., Miyamoto, N., Sugisaki, N., Murata, K., Kanehisa, H., Kawakami, Y., Fukunaga, T., & Yanai, T. (2012). Association between regional differences in muscle activation in one session of resistance exercise and in muscle hypertrophy after resistance training. *European Journal of Applied Physiology*, *112*(4), 1569-1576.
- Watanabe, Y., Yamada, Y., Fukumoto, Y., Ishihara, T., Yokoyama, K., Yoshida, T., Miyake, M., Yamagata, E., & Kimura, M. (2013). Echo intensity obtained from ultrasonography images reflecting muscle strength in elderly men. *Clinical Interventions in Aging*, *8*(1), 993-8.
- Wattjes, M. P., Kley, R. A., & Fischer, D. (2010). Neuromuscular imaging in inherited muscle diseases. *European Radiology*, *20*(10), 2447-2460.
- Weir, J. P. (2005). Quantifying test-retest reliability using the intraclass correlation coefficient and the SEM. *The Journal of Strength & Conditioning Research*, *19*(1), 231-240.
- Weits, T., Van Der Beek, E. J., & Wedel, M. (1985). Comparison of ultrasound and skinfold caliper measurement of subcutaneous fat tissue. *International Journal of Obesity*, *10*(3), 161-168.
- Wells, A. J., Fukuda, D. H., Hoffman, J. R., Gonzalez, A. M., Jajtner, A. R., Townsend, J. R., Mangine, G.T., Fragala, M.S., & Stout, J. R. (2014). Vastus Lateralis exhibits non-homogenous adaptation to resistance training. *Muscle & Nerve*, *50*(5), 785-793.

- Wilhelm, E. N., Rech, A., Minozzo, F., Radaelli, R., Botton, C. E., & Pinto, R. S. (2014). Relationship between quadriceps femoris echo intensity, muscle power, and functional capacity of older men. *Age*, *36*(3), 1113-1122.
- Wong, A. Y., Parent, E., & Kawchuk, G. (2013). Reliability of 2 ultrasonic imaging analysis methods in quantifying lumbar multifidus thickness. *Journal of Orthopaedic & Sports Physical Therapy*, *43*(4), 251-262.
- Wu, J. S., Darras, B. T., & Rutkove, S. B. (2010). Assessing spinal muscular atrophy with quantitative ultrasound. *Neurology*, *75*(6), 526-531.
- Young, A., Stokes, M., & Crowe, M. (1985). The size and strength of the quadriceps muscles of old and young men. *Clinical Physiology (Oxford, England)*, *5*(2), 145-154.
- Young, H. J., Jenkins, N. T., Zhao, Q., & McCully, K. K. (2015). Measurement of intramuscular fat by muscle echo intensity. *Muscle & Nerve*, *52*(6), 963-971.
- Yue, G., Alexander, A. L., Laidlaw, D. H., Gmitro, A. F., Unger, E. C., & Enoka, R. M. (1994). Sensitivity of muscle proton spin-spin relaxation time as an index of muscle activation. *Journal of Applied Physiology*, *77*(1), 84-92.
- Zajac, F. E. (1992). How musculotendon architecture and joint geometry affect the capacity of muscles to move and exert force on objects: a review with application to arm and forearm tendon transfer design. *The Journal of Hand Surgery*, *17*(5), 799-804.