



Spring 6-30-2019

Craniofacial growth of untreated children: A longitudinal CBCT study

Leah S. Yi

leahyi90, Leahyi@upenn.edu

Follow this and additional works at: https://repository.upenn.edu/dental_theses



Part of the [Dentistry Commons](#)

Recommended Citation

Yi, Leah S., "Craniofacial growth of untreated children: A longitudinal CBCT study" (2019). *Dental Theses*. 42.
https://repository.upenn.edu/dental_theses/42

This paper is posted at ScholarlyCommons. https://repository.upenn.edu/dental_theses/42
For more information, please contact repository@pobox.upenn.edu.

Craniofacial growth of untreated children: A longitudinal CBCT study

Abstract

Objectives: To conduct a longitudinal study of growth in untreated patients using CBCT. **Materials and Methods:** CBCT images were obtained for eleven male children (mean age 8.8 years at T1, 11.8 years at T2) and eighteen females (mean age 9.1 years at T1, 10.8 years at T2) and had been taken at least 1 year apart. A non-magnified 2D lateral cephalogram was derived from each CBCT image and superimposed to evaluate sagittal and vertical growth. The transverse widths of various skeletal areas (anterior and posterior nasal cavity, infra orbital foramina, infrazygomatic, mental foramina, Gonion, Antegonion, condyle) and the dentoalveolus at the first molar (2 mm, 6 mm, and 10 mm apical to the CEJ) were measured. **Results:** This study reports separated male and female average values. Relative to the cranial base, Orbitale, A point, and B point move anteriorly and inferiorly. Porion moves posteriorly and inferiorly. Nasion moves anteriorly and has a wide range of vertical movement. Within the maxilla, A point had variable sagittal movement and moves inferiorly. Within the mandible, B point has variable sagittal movement and moves superiorly, and the condyle moves superiorly. True rotation of the mandible and maxilla occurs in a counterclockwise direction, the inferior border remodels in a clockwise direction, the condyle rotates forward relative to the mandible, and the gonial angle reduces. These processes are correlated with each other and one subject had clockwise rotation of the jaws. The upper and lower first molars mesialize, upright bucco-lingually, and erupt vertically with age. The upper and lower central incisors erupt and the lower incisors procline. The transverse width of the posterior portions of the face increase more than the anterior. The mandibular and maxillary dentoalveoli increase at similar rates corono-apically. The maxillary dentoalveolus increases more than the mandibular dentoalveolus. **Conclusions:** Angular measurements with N, Or, Po, A, and B may not be reliable for longitudinal growth evaluation. This study confirms the unique facial patterns and correlations between developing processes described by Bjork and Skieller. The posterior skeletal increases in the mandible seems to primarily be the result of lengthening of the mandibular body. The small dentoalveolar increases in the mandible is likely the result of periosteal apposition. The skeletal and dentoalveolar transverse increases in the maxilla reflect the greater increases in the posterior than anterior portions of the mid-palatal suture. The width of the posterior portions of the maxilla and mandible increase in a coordinated fashion. The vertical eruption and bucco-lingual uprighting of the upper and lower first molars seem to bridge the differential sagittal, vertical, and transverse growth of the maxilla and mandible.

Degree Type

Thesis

Degree Name

MSOB (Master of Science in Oral Biology)

Primary Advisor

Chun-Hsi Chung

Keywords

CBCT, craniofacial, three-dimensional, longitudinal, growth, orthodontics

Subject Categories
Dentistry

Craniofacial growth of untreated children:

A longitudinal CBCT study.

By

Leah Yi, DMD,^a Chun-Hsi Chung, DMD, MS,^b Normand Boucher, DDS^c

^a Former Orthodontic Resident, Department of Orthodontics, University of Pennsylvania School of Dental Medicine

^b Chauncey M. F. Egel Endowed Chair and Associate Professor, Department of Orthodontics, University of Pennsylvania School of Dental Medicine

^c Clinical Associate Professor, Department of Orthodontics, School of Dental Medicine, University of Pennsylvania.

PART I - Sagittal and Vertical Growth

Abstract:

Objectives: To conduct a longitudinal study of sagittal and vertical dentofacial growth in untreated patients using CBCT-derived lateral cephalograms. **Materials and methods:** Eleven male children (mean age 8.8 years at T1, 11.8 years at T2) and eighteen females (mean age 9.1 years at T1, 10.8 years at T2). CBCT images were obtained that had been taken at least 1 year apart. An orthogonal 2D lateral cephalogram was derived from each CBCT image using the right side of the patients head to the center of the left central incisor. The T1 and T2 lateral cephalograms were superimposed to evaluate displacement of cephalometric landmarks and rotation of the jaws. **Results:** This study reports separated male and female averages. The average of the total sample is presented here. Relative to the cranial base, Orbitale moves anteriorly about 0.68 mm/year and inferiorly about 0.26 mm/year; A point moves anteriorly 0.78 mm/year and inferiorly about 0.89 mm/year; B point moves anteriorly 1.50 mm/year and inferiorly 0.87 mm/year; Porion moves 0.35 mm/year posteriorly and inferiorly. Nasion moves anteriorly 0.75 mm/year and has a wide range of vertical movement. Within the maxilla, A point had variable sagittal movement and moves inferiorly 0.36 mm/year, which is statistically significant only in males. Within the mandible, B point has variable sagittal movement and moves superiorly 0.43 mm/year, which is only statistically significant in males. The mandible and maxilla on average rotate about 0.55 and 1.24 degrees/year respectively. One subject had counterclockwise rotation of the jaws. There was 0.97 degrees/year forward rotation of the condyle relative to the mandible; 0.42 degrees/year of counterclockwise rotation of the remodeling at the inferior border; and 0.50 degrees/year reduction of the gonial angle. The mandibular length increased by 2.23 mm/year. The condyle grew vertically 2.51 degrees/year. The upper first molar erupts 0.86 mm/year and mesializes about 0.36 mm/year. The lower first molar erupts 0.49 and 0.60 mm/year. The upper central incisor erupts 0.97 mm/year and the tip moves anteriorly 0.36 mm/year. The lower central incisor erupts 0.55 mm/year and the tip moves anteriorly 0.30 mm/year. **Conclusions:** Sella-Nasion and Frankfort horizontal may not be reliable as reference planes for longitudinal growth evaluation. Despite the clarity offered by the CBCT derived 2D images, uncontrollable factors seem to cause a large variability in the displacement of A and B point, which suggests these points also may not be reliable for longitudinal comparisons of maxillary and mandibular growth. This study confirms the unique facial patterns and correlations between developing processes described by Bjork and Skieller. The identification of the all structures on these images are unhindered by the usual limitations that affect identification on 2D lateral cephalograms.

Introduction:

Currently, there is a general consensus that certain facial types can be characterized by unique growth patterns. Bjork and Skieller¹ used implants to show that the maxilla and mandible display counterclockwise rotation and a clockwise rotation in a minority of patients (facing right). They also demonstrated the interconnectedness of these developing processes. There is a high positive correlation between the direction of rotation of the jaws. The counterclockwise rotation is accompanied by forward growth of the condyles. The remodeling that occurs on the nasal floor and inferior mandibular border is dependent and opposite of the direction of rotation.

Implant and anthropomorphic studies have identified what areas of the craniofacial complex are stable and maintain a predictable relationship with each other throughout growth. These stable craniofacial structures have been used to evaluate sagittal and vertical growth on lateral cephalograms. The anterior wall of sella turcica, greater wings of the sphenoid, cribriform plate, ethmoid crest, planum sphenoidale and cerebral surfaces of the frontal bone have been shown to be stable by 2D and 3D studies and are the current standard for cranial base superimposition set by the American Board of Orthodontists (ABO).²⁻⁶ To assess intramaxillary changes, the maxilla should be superimposed on the anterior surface of the zygomatic process and maxilla-zygomatico-temporal sulci. A maxillary superimposition should demonstrate downward and backward remodeling of the lower aspect of the key ridge and apposition and resorption of the orbital and nasal floor in a 3/5 to 2/5 ratio, respectively.⁷⁻¹⁰ The point on the anterior surface of the chin just below pogonion, the inner contour of the most inferior aspect of the symphysis, and the posterior contour of the inferior alveolar canal are considered the stable superimposition structures in the mandible.¹¹⁻¹⁴

Most of the literature on craniofacial growth is based on 2D radiography. However, magnification, superimposition of structures, and variable head positioning limit the accuracy of 2D images analyses. These limitations are overcome with 3D Cone beam Computed Tomography (CBCT) images, which can be compressed to produce an orthogonal, or non-magnified 2D lateral cephalogram. The 2D image can also be produced from one side of the face, which increases the clarity of structures that are normally obscured by the superimposed contralateral side.

The purpose of this study is to conduct a longitudinal evaluation of craniofacial growth in the sagittal and vertical dimensions in untreated children using orthogonal lateral cephalograms derived from CBCT images.

Materials and Methods:

This study was approved by the University of Pennsylvania International review board and ethics committee. All CBCT images were oriented and analyzed using the Dolphin Imaging 3D software (version 11.9, Dolphin Imaging & Management Solutions, Chatsworth, Calif).

Sample

Twenty-nine untreated subjects who had CBCT images taken at different time periods were collected from various private practices utilizing CBCT imaging in routine records exams. The subjects were not treated at T1 for various clinical reasons that caused delays in treatment. The sample examined in this study includes 11 males at an average age of 8.8 years old at T1 (5.4 – 11.5 yo) and 11.8 years old at T2 (8.7 – 14.7 yo) as well as 18 females who are at an average age of 9.1 years old at T1 (6.2 – 11.7 yo) and 10.8 years old at T2 (7.2 – 13.7 yo).

Orientation

Roll: The cranium was oriented such that a midline could be drawn through the midpoint of the frontonasal suture and base of the nose and is parallel to the true vertical. In addition, a true horizontal line goes through the most inferior aspect of the orbits.

Yaw: The cranium was oriented to achieve best symmetry of the cranium, zygomatic, and maxillary structures on either side of the midline.

Pitch: The cranium was oriented such that the Frankfort horizontal was parallel to the true horizontal.

Lateral Cephalograms

Superimposition structures and landmarks were identified on the CBCT 3D image so that they could be clearly identified and used for accurate superimposition of T1 and T2 lateral cephalograms as shown in Figure 1A. Lateral cephalograms were generated as an orthogonal view (0% magnification) of the right side of the face to the midpoint of the left maxillary central incisor as done by Habeeb et al.¹⁵

The T1 and T2 lateral cephalograms tracings were superimposed using research supported stable structures in the cranial base, maxilla, and mandible. On the cranial base, the tracings would be superimposed on the anterior wall of sella turcica, cribriform plate, ethmoid crest, and the greater wing of the sphenoid. If more clarification was needed, then the planum sphenoidale and the cerebral surface above the orbits was used.¹⁶ On the T1 lateral cephalogram, a line going through two points on the anterior wall of sella turcica and on the cribriform plate was drawn. On a T1 and T2 cranial base superimposition, the line and two points was replicated onto the T2 cephalogram, as shown in Figure 1B. This “Cranial base core line” serves not only as a method by which the cranial base superimposition can be easily reproduced, but also as a stable reference line from which various angular measurements can be made.

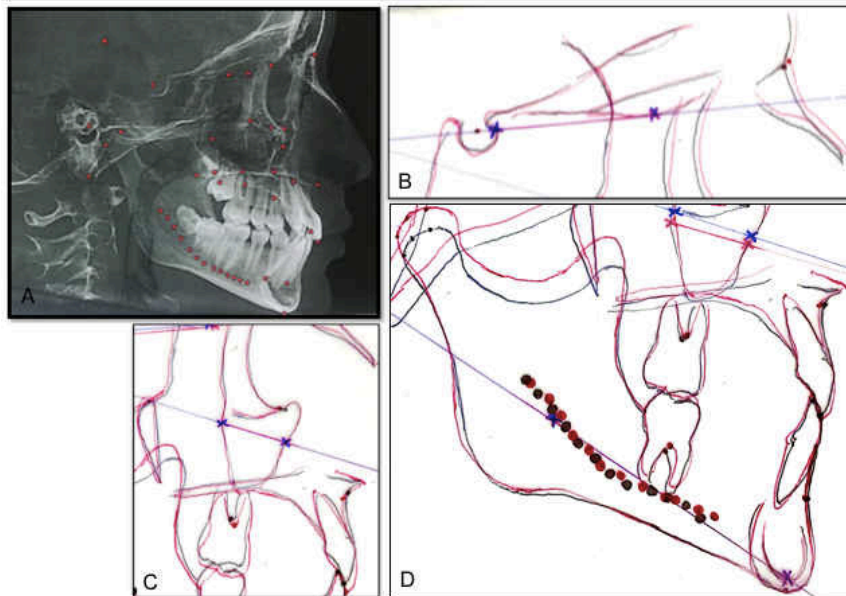


Figure 1. (A) Landmarks were placed on the CBCT image to facilitate the identification of certain structures. (B) The cranial base core line is drawn on the T1 lateral cephalograms and transferred onto the T2 tracing on a cranial base superimposition. (C) The maxillary core line and (D) the mandibular core lines are placed in a similar manner.

The maxillary core points were placed on the anterior surface of the zygoma and on the maxillary-zygomatico-temporal sulcus. A “maxillary core line” was drawn through those points on the T1 image and then replicated on the T2 image on a maxillary superimposition as shown in Figure 1C. The maxillary tracings were superimposed on the anterior surface of the zygomatic process and the maxillary-zygomatico-temporal sulcus. The maxillary tracing is vertically positioned so that the orbital floor of T2 is above that of T1 and the nasal floor of T2 is below that of T1 in a 3/5 to 2/5 ratio, respectively.¹⁶ The mandibular core points were placed on the inferior surface of the inner contour of the symphysis and on the posterior contour of the inferior alveolar nerve. The “mandibular core line” was drawn through those points on the T1 image and then

replicated on the T2 image on a mandibular superimposition as shown in Figure 1D. The mandibular tracings were superimposed on the anterior-inferior contours of the symphysis just below the pogonion, the inner contour of the cortical plate at the lower border of the symphysis and at the posterior contours of the alveolar canal.¹⁶

Of note, the location of the T1 core points on the T1 cephalogram are arbitrary and therefore, cannot be used for cross sectional comparison of measurements made at a single time point. Rather, T1 and T2 measurements can only be compared longitudinally or the T2-T1 differences can be evaluated cross sectionally, as done in this study.

On a cranial base superimposition of the T1 and T2 cephalograms, the T1 to T2 horizontal (x) and vertical (y) distance of the following cephalometric points were measured. The directionality of the horizontal and vertical movement was recorded by measuring on a coordinate system (i.e. anterior movement is positive, posterior movement is negative, superior movement is positive, inferior movement is negative).

- Nasion (N): The junction of the frontal and nasal bones.
- Orbitale (Or): The most inferior point of the orbital rim.
- Porion (Po): The most superior point of the external auditory meatus
- A point (A): The most concave point along the maxillary dentoalveolus between the anterior nasal spine and the crestal bone
- B point (B): The most concave point along the mandibular dentoalveolus between the crestal bone and pogonion

On a maxillary superimposition of the T1 and T2 cephalograms, the T1 to T2 horizontal (x) and vertical (y) distance of the following cephalometric points were measured.

- Maxillary first molar (U6): The furcation of the maxillary first molar mesiobuccal and distobuccal roots
- Maxillary central incisor (U1): The incisal edge of the maxillary central incisor
- A point (A): The most concave point along the maxillary dentoalveolus between the anterior nasal spine and the crestal bone

On a mandibular superimposition of the T1 and T2 cephalograms, the T1 to T2 horizontal (x) and vertical (y) distance of the following cephalometric points were measured.

- Mandibular first molar (L6): The furcation of the mandibular first molar roots
- Mandibular central incisor (L1): The incisal edge of the mandibular central incisor
- Condylion (Co): The midpoint between the most posterior and superior point of the condyle
- B point (B): The most concave point along the mandibular dentoalveolus between the crestal bone and pogonion

The following angles and distances were measured on the lateral cephalograms:

- SN: The millimeter distance between Sella and Nasion. This represents the length of the anterior cranial base.
- CoGn: The millimeter distance between Condylion and Gnathion. This represents the mandibular length.
- SNA: The angle between a line through Sella to Nasion and a line through Nasion to A point.
- SNB: The angle between a line through Sella to Nasion and a line through Nasion to B point.
- ANB: The difference between SNA and SNB. This represents the maxillomandibular relationship.
- SN-GoGn: The angle between a line through Sella to Nasion and a line through Gonion and Gnathion. Gnathion was identified as the midpoint between the most anterior and

inferior points of the symphysis. Gonion was identified as the mid point between the best fit lines tangent to the posterior and inferior border of the mandible as described below.

- Gonial angle: The angle formed by a best fit lines to the posterior and inferior border of the mandible. The best fit line of the posterior border is a tangent line that goes through the most posterior point of the condyle and a point near the gonial angle. The best fit line of the inferior border is a tangent line that goes through menton and a point near the gonial angle.
- CB line-A: The angle between the cranial base core line and a line through the CB core point (anterior point of the CB core line) and A point. This represents maxillary sagittal position relative to the Cranial base instead of SN, thereby eliminating the influence of remodeling of SN.
- CB line-B: The angle between the cranial base core line and a line through line through the CB core point (anterior point of the CB core line) and B point. This represents mandibular sagittal position relative to the Cranial base instead of SN, thereby eliminating the influence of remodeling of SN.
- A-CB point-B: The difference between CB line-A and CB line-B. This represents maxillomandibular relationship. It is analogous to ANB but uses CB point instead of Nasion thereby eliminating the influence of remodeling of Nasion on ANB.
- CB line-GoGn: The angle between the cranial base core line and a line through Gonion and Gnathion. The T2-T1 difference represents mandibular plane rotation relative to the cranial base.
- CB line-Mx line: The angle between the cranial base core line and the maxillary core line. The T2-T1 difference represents maxillary rotation relative to the cranial base.
- CB line-Md line: The angle between the cranial base core line and the mandibular core line. The T2-T1 difference represents true mandibular rotation relative to the cranial base.
- Co-Md line: The angle between the mandibular core line and a line through the posterior end of the mandibular core line and Condylion. The T2-T1 difference represents the direction of condylar growth relative to the mandibular body.
- Md line-Md Border: The angle between the mandibular core line and the best fit line to the inferior border of the mandible, as defined above. The T2-T1 difference represents the degree of remodeling that occurs on the mandibular inferior border.
- CB line-Mx point: The angle between the cranial base core line and a line through the cranial base and maxillary core points. The cranial base core point is the anterior point of the cranial base core line and the maxillary core point is the anterior point of the maxillary core line. The T2-T1 difference represents the changes in maxillary prognathism.
- CB line-Md point: The angle between the cranial base core line and a line through the cranial base and mandibular core points. The mandibular core point is the anterior point of the mandibular core line. The T2-T1 difference represents the changes in mandibular prognathism.
- Mx point-CB line-Md point: The difference between CB line-Mx point and CB line-Md point. This also represents the maxillomandibular relationship.

Statistical Analysis

The mean, standard deviations, and ranges were calculated for the resulting data which is composed of the annual differences between the T1 and T2. A student T-test was used to confirm the statistical significance that there is a change between T1 and T2 ($p < 0.05$). Intraexaminer reproducibility was tested by having all measurements of 8 randomly selected patients remeasured and reanalyzed by the same examiner (L.S.Y.) at least 1 month later. A student paired t test and Pearson correlation coefficient were done to determine whether there are statistically significant differences at $p < 0.05$ between the two sets of data.

Results:

The intraexaminer reproducibility test revealed no statistically significant differences ($p > 0.05$) between the data collected for the re-analyzed sample of 8 random patients. In each case the Pearson correlation coefficient varied between 0.90 and 0.99.

Cephalometric point distance

The T1 and T2 lateral cephalograms were superimposed on the cranial base and oriented so that Frankfort horizontal was the true horizontal. The sagittal (X) and vertical (Y) components of the distance between cephalometric points on the T1 and T2 lateral cephalograms were measured and are shown in Table 1, Figure 2, and Figure 3 below.

As shown on Table 1, all points on the cranial base superimposition move anteriorly with the exception of Porion which moves posteriorly 0.40 and 0.25 mm/year in males and females, respectively. All points move inferiorly, with the exception of Nasion. Nasion shows a large range of vertical movement in both males and females, which explains the large P-value. The greatest sagittal and vertical movement is seen in the mandibular points, B point and Md. In males, B point moves anteriorly 1.25 mm/year and inferiorly 0.80 mm/year. The average annual inferior movement of B point in males is not significant to $P < 0.05$. In females, B point moves anteriorly 1.64 mm/year and inferiorly 0.90 mm/year. The sagittal and vertical movement of the maxilla is generally less than that of the mandible. In males, A point moves anteriorly 0.91 mm/year and inferiorly 0.98 mm/year. In females, A point moves anteriorly 0.70 mm/year and inferiorly 0.84 mm/year.

On the maxillary and mandibular superimpositions, A point and B point have a large range in sagittal movement resulting in a small average annual movement that is statistically insignificant ($P > 0.05$) in males. In females, both sagittal and vertical movement of A and B point in females have a large range and the averages are statistically insignificant. ($P > 0.05$) The U6 and U1 display greater vertical dentoalveolar eruption than the L6 and L1 in both genders. The U6 and U1 descend 0.94 and 1.01 mm/year in males and 0.82 and 0.95 mm/year in females. The L6 and L1 ascend 0.66 and 0.88 mm/year in males and 0.41 mm/year in females. The L6 mesializes more than the U6 in both genders. The L6 and U6 moves anteriorly 0.57 and 0.34 mm/year in males and 0.62 and 0.28 mm/year in females. Condylion (Co) demonstrates the greatest vertical movement per year. In males, Co moves 2.75 mm/year superiorly and in females Co moves 2.37 mm/year superiorly.

Table 1. Sagittal (X) and Vertical (Y) Movement of Cephalometric Points in Males and Females (mm/year)

		Male						Female						
		N	Average	S.D.	Min	Max	P-value	N	Average	S.D.	Min	Max	P-value	
Cranial Base	N	x	11	0.78	0.48	0.00	1.60	p < 0.05	18	0.66	0.60	0.00	1.87	p < 0.05
		y	11	0.15	0.46	-0.60	1.26	p > 0.05	18	0.07	0.73	-2.23	1.35	p > 0.05
	Or	x	11	0.49	0.47	0.00	1.54	p < 0.05	19	0.79	0.54	-0.21	1.76	p < 0.05
		y	11	-0.37	0.41	-1.37	0.00	p < 0.05	19	-0.19	0.53	-1.12	0.81	p > 0.05
	Po	x	11	-0.40	0.33	-0.93	0.16	p < 0.05	19	-0.25	0.51	-1.33	0.73	p < 0.05
		y	11	-0.33	0.44	-1.52	0.00	p < 0.05	19	-0.34	0.46	-1.17	0.49	p < 0.05
	A	x	11	0.91	0.68	-0.56	1.74	p < 0.05	19	0.70	0.91	-0.95	1.88	p < 0.05
		y	11	-0.98	0.34	-1.74	-0.49	p < 0.05	19	-0.84	0.68	-2.29	0.56	p < 0.05
	B	x	7	1.25	1.15	-0.81	2.90	p < 0.05	13	1.64	0.96	0.00	3.12	p < 0.05
		y	7	-0.80	1.08	-2.26	0.90	p > 0.05	13	-0.90	1.36	-3.03	1.07	p < 0.05
Maxilla	U6	x	9	0.33	0.21	0.00	0.54	p < 0.05	18	0.37	0.37	0.00	1.13	p < 0.05
		y	9	-0.94	0.61	-1.87	0.00	p < 0.05	18	-0.82	0.61	-1.74	0.00	p < 0.05
	U1	x	9	0.27	0.24	0.00	0.77	p < 0.05	18	0.40	0.89	-0.79	2.06	p > 0.05
		y	9	-1.01	0.66	-2.44	0.00	p < 0.05	18	-0.95	1.21	-5.03	0.00	p < 0.05
	A	x	11	0.07	0.43	-0.73	0.77	p > 0.05	19	0.03	0.43	-1.28	0.78	p > 0.05
		y	11	-0.42	0.47	-1.36	0.00	p < 0.05	19	-0.32	0.67	-2.36	0.62	p > 0.05
Mandible	L6	x	8	0.57	0.42	0.00	1.16	p < 0.05	19	0.62	0.49	0.00	1.39	p < 0.05
		y	8	0.66	0.35	0.00	1.04	p < 0.05	19	0.41	0.40	0.00	1.40	p < 0.05
	L1	x	8	0.34	0.27	0.00	0.86	p < 0.05	18	0.28	0.56	-0.85	1.84	p < 0.05
		y	8	0.88	0.50	0.16	1.54	p < 0.05	18	0.41	0.45	0.00	1.71	p < 0.05
	B	x	10	0.05	0.11	0.00	0.26	p > 0.05	19	-0.08	0.29	-0.79	0.46	p > 0.05
		y	10	0.74	0.81	-0.49	1.96	p < 0.05	19	0.27	1.06	-2.43	2.23	p > 0.05
	Co	x	11	-0.62	0.51	-1.72	0.00	p < 0.05	19	-0.43	0.99	-2.47	1.67	p > 0.05
		y	11	2.75	0.80	0.73	3.89	p < 0.05	19	2.37	1.13	0.19	5.15	p < 0.05

Table 1 shows the average annual sagittal (X) and vertical (y) components of movement of cephalometric points on a cranial base, maxillary, and mandibular superimposition of the T1 and T2 lateral cephalograms. On a cranial base superimposition, N, Or, Po, A, and B were evaluated. On a maxillary superimposition, U6, U1, and A were evaluated. On a mandibular superimposition L6, L1, B, and Co were evaluated.

Figure 2. Sagittal (X) and Vertical (Y) Movement of Cephalometric Points in Males (mm/year)

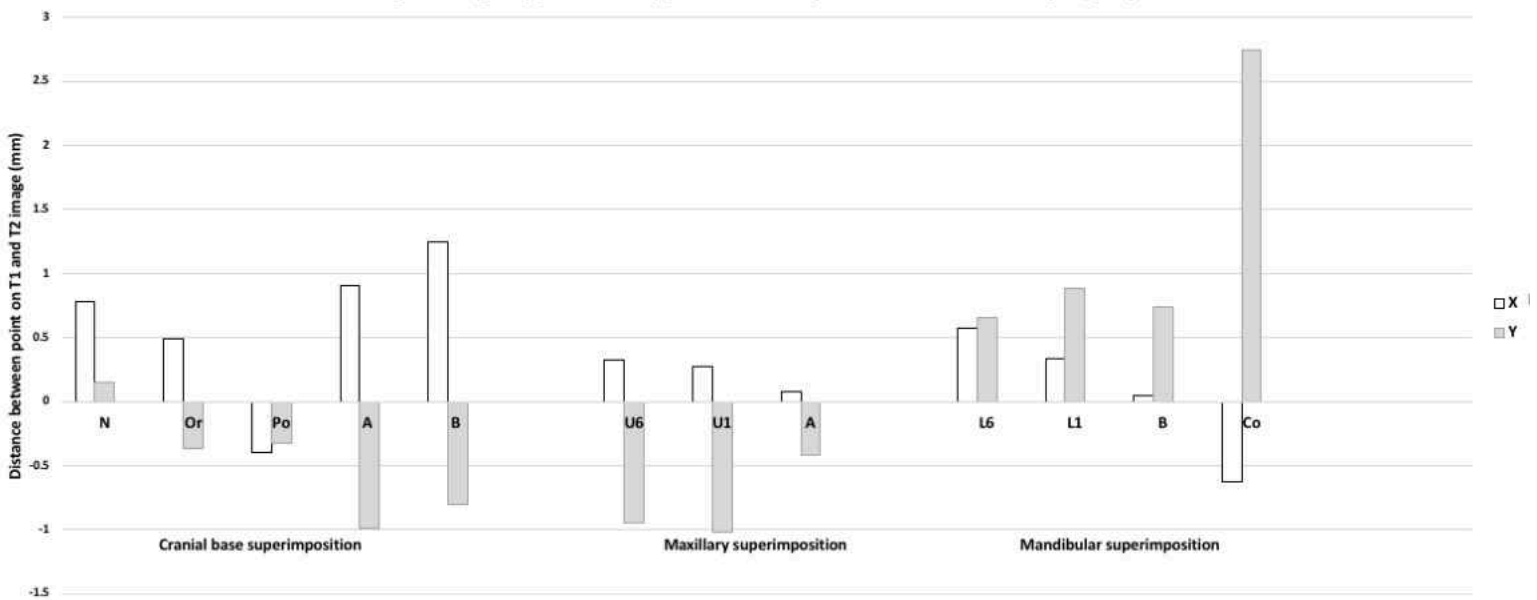


Figure 2 is a graphic representation of the average annual sagittal (X) and vertical (y) components of movement of cephalometric points on a cranial base, maxillary, and mandibular superimposition of the T1 and T2 lateral cephalograms in males.

Figure 3. Sagittal (X) and Vertical (Y) Movement of Cephalometric Points in Females (mm/year)

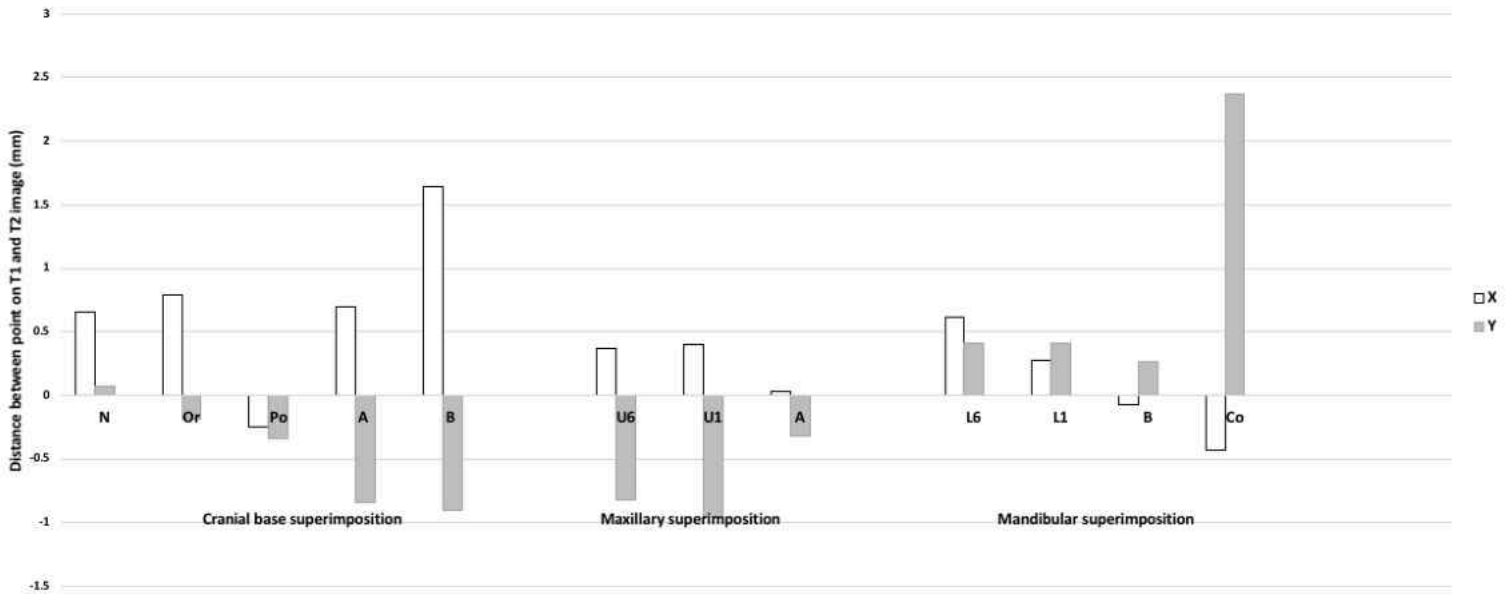


Figure 3 is a graphic representation of the average annual sagittal (X) and vertical (y) components of movement of cephalometric points on a cranial base, maxillary, and mandibular superimposition of the T1 and T2 lateral cephalograms in females.

Angular and Linear changes

The angular and linear changes are shown in Table 2 in males and females. In males, it was found that the anterior cranial base (SN) increases in length 0.90 and 0.98 mm/year in males and females respectively. Mandibular length (Co-Gn) increases in length 2.51 and 2.06 mm/year in males and females respectively. This increase was found to be significantly greater in males than females ($p < 0.05$). SNA, SNB, and ANB, which are the traditional methods of assessing maxillary and mandibular position relative to S and N displayed a mean annual change that was not shown to be greater or less than 0 mm/year to a statistical significance of $P < 0.05$ in males. In females, SNA was also not statistically significant ($P > 0.05$), but SNB and ANB show an annual increase of 0.71 degrees/year and decrease of 0.66 degrees/year, respectively. SN-GoGn, the traditional method of assessing mandibular plane displayed an annual decrease of 0.54 mm/year in males and was not statistically significant in females ($p > 0.05$).

CB line-A and CB line-B assesses maxillary and mandibular position relative to the cranial base core line, instead of SN. Both values also display a mean annual change that were not found to be greater or less than 0 mm/year to a statistical significance of $P < .05$ in males. In females, CB line-A was also not statistically significant ($P > 0.05$), but CB line-B displayed an increase of 0.91 degrees/year. In males and females, A – CB point – B decreases 0.43 and 0.67 degrees/year.

CB line-Mx point and CB line-Md point also assesses maxillary and mandibular position relative to the cranial base core line using the Mx point and Md point instead of A and B. Unlike the former measures of maxillary and mandibular position and interrelationship, both show statistically significant ($P < 0.05$) annual increases in both genders. CB line-Mx point increases 0.47 and 0.48 degrees/year in males and females, respectively, and CB line-Md point increases 0.69 and 1.08 degrees/year in males and females, respectively. Mx point-CB line-Md point displays a decrease of 0.19 and 0.41 degrees/year in males and females, respectively.

Maxillary and mandibular rotation was quantified with CB line-Mx line and CB line-Md line. CB line-Mx line decreases by 0.53 and 0.57 degrees/year in males and females, which indicates a counterclockwise rotation of the maxilla. CB line-Md line decreases by 1.26 and 1.24 degrees

per year in males and females respectively, which also indicates a counterclockwise rotation of the mandible. The mandibular plane relative to the cranial base core line (CB line-GoGn) decreases 0.67 and 0.49 degrees/year in males and females, respectively indicating a counterclockwise rotation of the mandibular plane. The inferior mandibular border (Md line-Md border) remodels in the opposite, clockwise direction by 0.41 and 0.43 mm/year in males and females, respectively. The long axis of the condyle was found to move in a forward clockwise direction relative to the mandibular core line (Co-Md) by 0.94 and 0.99 mm/year in males and females, respectively. Gonial angle decreases by 0.63 and 0.43 mm/year in males and females, respectively.

Table 2. Angular (degrees) and Linear (mm) changes per Year for Males and Females

	Males					Females						
	N	Average	SD	Min	Max	P-Value	N	Average	SD	Min	Max	P-Value
SN (mm)	11	0.90	0.49	0.00	1.82	p < 0.05	18	0.98	0.77	0.00	3.34	p < 0.05
Co-Gn (mm)	11	2.51	0.51	1.51	3.18	p < 0.05	19	2.06	0.92	0.50	3.80	p < 0.05
SNA (°)	11	-0.02	0.77	-2.00	0.95	p > 0.05	18	0.15	0.94	-2.12	1.30	p > 0.05
SNB (°)	8	0.23	0.49	-0.49	0.84	p > 0.05	13	0.71	0.75	-0.64	1.95	p < 0.05
ANB (°)	8	-0.37	0.53	-1.57	0.11	p > 0.05	13	-0.66	0.64	-2.35	0.00	p < 0.05
SN-GoGn (°)	8	-0.54	0.37	-1.20	0.08	p < 0.05	13	-0.35	0.86	-1.85	0.57	p > 0.05
CB line - A (°)	11	0.16	0.59	-0.85	1.06	p > 0.05	19	0.15	0.89	-1.75	1.25	p > 0.05
CB line - B (°)	8	0.48	0.61	-0.35	1.48	p > 0.05	13	0.91	0.63	-0.29	2.01	p < 0.05
A - CB point - B (°)	8	-0.43	0.35	-1.13	-0.07	p < 0.05	13	-0.67	0.69	-2.27	0.03	p < 0.05
CB line-GoGn (°)	8	-0.67	0.69	-2.17	0.08	p < 0.05	13	-0.49	0.69	-2.45	0.31	p < 0.05
CB line - Mx point (°)	11	0.47	0.64	-0.33	1.65	p < 0.05	19	0.48	0.81	-1.30	1.61	p < 0.05
CB line - Md point (°)	8	0.69	0.58	0.00	1.65	p < 0.05	13	1.08	0.73	0.00	2.46	p < 0.05
Md point - CB point - Mx point (°)	8	-0.19	0.22	-0.65	0.00	p < 0.05	13	-0.48	0.59	-1.64	0.08	p < 0.05
CB line - Mx line (°)	11	-0.53	0.47	-1.43	0.10	p < 0.05	19	-0.57	1.05	-2.87	2.63	p > 0.05
CB line - Md line (°)	8	-1.26	0.66	-2.52	-0.47	p < 0.05	13	-1.24	1.27	-3.90	0.39	p < 0.05
Co - Md line (°)	11	-0.94	0.68	-1.90	0.10	p < 0.05	19	-0.99	1.18	-4.41	0.00	p < 0.05
Md line - Md border (°)	11	-0.41	0.39	-0.84	0.58	p < 0.05	19	-0.43	0.68	-1.41	1.26	p < 0.05
Gonial Angle (°)	11	-0.63	0.54	-1.33	0.20	p < 0.05	19	-0.43	0.77	-2.15	1.02	p < 0.05

Table 2 shows the annual average changes in the linear and angular measurements in males (left) and females (right).

Figure 4. Angular (degrees) and Linear (mm) changes per Year for Males and Females

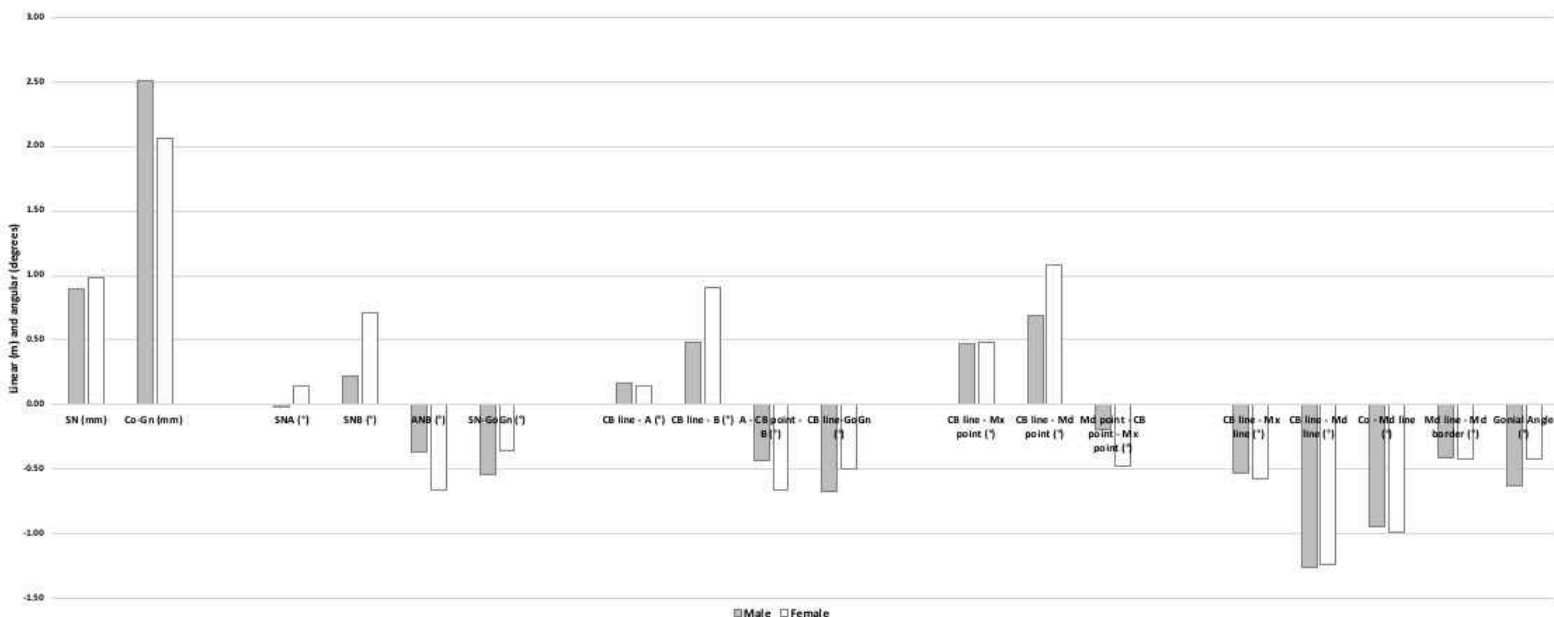


Figure 4 is a graphical representation of the annual average changes in the linear and angular measurements in males (grey) and females (white).

Discussion:

CBCTs were used in this study to enhance a method of lateral cephalogram analysis that has been used and verified by 2D implant studies and 3D CBCT studies. The 2D images in this study are devoid of the usual limitations of 2D xrays. Orthogonal images were created to eliminate magnification error. The right half of the face was studied to improve visibility of normally superimposed structures. Therefore, the results of our study convey a more accurate depiction of facial development. Sella has been reported by past studies to exhibit downward and backward remodeling.⁵ On a cranial base superimposition, nasion grew forward in all patients relative to the cranial base due to a combination of apposition on the frontal bone and enlargement of the frontal sinus.^{17,18} In this study, nasion displayed a large variation in vertical movement which is consistent with the findings of Bjork and Skieller.¹⁹ The movement of sella and nasion warrants question into whether SN is a reliable reference plane for longitudinal comparisons. The Frankfort Horizontal also demonstrates questionable reliability as a reference plane. Orbitale exhibits a wide range of vertical change relative to the cranial base, which is likely due to variable apposition that occurs as compensation for the descending maxilla.¹⁹ Porion displaces inferiorly and posteriorly in most subjects. This is expected as the glenoid fossa, which is also a part of the temporal bone has been shown to displace inferiorly and posteriorly due to the lengthening and flexure of the posterior cranial base from the developing sphenoccipital synchondrosis.^{20,21}

The maxillary and mandibular superimpositions show that A point and B point also have a large range of sagittal movement that is likely due to a combination of growth, remodeling, influence of permanent dentition tooth buds, and tracing error. Therefore, angular measurements using S, N, A, and B may not reflect the true annual changes in maxillary and mandibular sagittal development. For example, although A point and B point display significant forward and downward movement on a cranial base superimposition, SNA in males and females is close to 0 degree/year, consistent with what has been reported by Ranly¹⁸, but this is not statistically significant ($P > 0.05$) and clearly does not reflect maxillary growth.

The magnitude of change in CB line-A, CB line-B, and CB line-GoGn are more positive than SNA, SNB, and SN-GoGn, respectively. CB line-Mx point and CB line-Md point have even greater differences. This demonstrates how the remodeling of S, N, A, and B can partially or wholly mask true craniofacial development. The angular measurements using the cranial base core line as a reference line are presumably a more accurate tool for longitudinal comparison or cross sectional comparison of T2-T1 differences. A limitation of this technique is that it cannot be used for cross sectional comparison of single time point values. Additionally, more vertical than horizontal growth of the jaws results in a negative difference for CB line-Mx point and CB line-Md point and a positive difference for Mx point-CB point-Md point, which can be misleading. Future studies that utilize this technique for analysis should place the CB point between the Mx point and Md point instead of posterior to both points.

Relative to the cranial base core line, our study reports that true mandibular and maxillary rotation occurs in a counterclockwise direction (CB line-Md line: -1.26 and -1.24 degrees/year; CB line-Mx line: -0.53 and -0.57 degrees/year in male and female respectively). The mandible rotates approximately twice as much as the maxilla and the rotation of the jaws are positively correlated with each other ($R = 0.75$, p -value < 0.01), which is consistent with the findings of Bjork and Skieller¹ and other implant studies.^{19,20} Bjork and Skieller¹ also reported 2 out of 19 patients that exhibited clockwise rotation of the jaws. In this study, one female displayed clockwise rotation of the maxilla and mandible. One male displayed clockwise rotation of the maxilla, but mandibular rotation could not be assessed because the patient was not in occlusion. Wang et al.²² and Spady et al.²³ used a similar method and found true mandibular rotation of about 1.3 and 0.8 degrees per year, respectively, during the primary and early mixed dentition phase.

The mandibular border remodels in the opposite direction (Md line-Md border: -0.41 and -0.43 deg/yr in males and females respectively) at about a third of the true rotational rate of the mandible, which is consistent with the findings of Wang et al.²² and less than what was found by Bjork and Skieller¹ who reported compensatory remodeling masked about half of the true rotation

of the mandible. There was also a positive correlation between the true mandibular rotation and compensatory remodeling of the mandibular inferior border ($R = 0.73$, $P < 0.001$), which is consistent with past studies' findings.^{1,22-24} Spady et al.²³ reports differing rates of true rotation and remodeling depending on the age of the group, which would explain the consistency of this study's reported rates with that of Lavergne et al.²⁴ who reported an average over a longer age interval (7-19 year old; 0.9 degree/year true rotation and 0.5 degree/year of remodeling). Wang et al.²² suggested that the proportionate increase in compensatory remodeling can be explained by increased tension from the suprahyoid muscles at the anterior border causing apposition and compression forces of the masticatory muscle sling causing resorption at the mandibular angle.

Bjork and Skieller¹ found that the extent of counterclockwise rotation of the jaws were also strongly correlated with the forward growth of the condyle and reduction of the gonial angle. In our study, the condyle appears to rotate forward relative to the mandibular body (Co-Md line: -0.94 and -0.99 deg/year in male and female respectively) and is positively correlated with true mandibular rotation ($R = 0.80$, $P < 0.0001$). The gonial angle displayed only a weak to moderate correlation with true mandibular rotation ($R = 0.48$, $P < 0.05$). Overall, this study confirms the presence of facial types that are characterized by differing, but coordinated processes. Herein lies the limitation of this study that the reported annual changes are an average of multiple facial types. Thus, the amount of counterclockwise rotation of the jaws, condylar rotation relative to the mandible, and compensatory remodeling of the mandibular border that was reported for females is underestimated due to the presence of one patient who was found to be a "clockwise grower." Future studies that have greater sample sizes should separate those who have backward and forward rotation of the jaws into separate groups for analysis.

True mandibular rotation (CB-Md line) has a negative correlation with the sagittal protrusion of the mandible (CB-Md point), which means that the greater the mandibular rotation, the greater the protrusion of the mandible relative to the cranial base ($R = -0.76$, $P < 0.0001$). Bjork and Skieller¹ reported mandibular rotation had a strong correlation with the amount and direction of condylar growth. It would make sense that a patient with strong forward mandibular rotation, any condylar growth will direct the mandible more anteriorly than inferiorly.

This study reports ANB reduced by -0.37 and -0.66 degrees per year in males and females respectively, but this is only statistically significant for females ($P < 0.05$). Past studies have reported lower rates. The Philadelphia Center for Research in Child²⁵ growth reported ANB decreases of 0.26 deg/year in males and less than 0.20 deg/year in females 10-15 years old. Sassouni²⁶ reported even lower rates of change of about 0.1 deg/year. The greater differences found in this study can be explained by the fact that most of the sample is younger than 10 years at T1 and 15 years at T2 and will therefore exhibit more average mandibular growth relative to maxillary growth. A-CB point-B and Mx point-CB point-Md point also show statistically significant decreases in the maxillomandibular relationship and the latter shows smaller decreases. The difference can only be attributed to the intra-jaw variation in location of A and B point.

Condylion grew vertically 2.75 mm/year in males and 2.37 mm/year in females, which is consistent with the rate reported in past studies.^{27, 28} Mandibular length (Co-Gn) and vertical growth of condylion have a positive correlation with amount of vertical eruption of the upper and lower first molars ($R = 0.52$, $P < 0.003$ and $R = 0.58$, $P < 0.001$, respectively). Liu and Buschang²⁹ reported that dentoalveolar eruption compensates for vertical mandibular growth and that the two components develop in harmony.

The upper first molar also shows less mesialization (0.33 and 0.37 mm/year in male and female respectively) than the mandibular first molar (0.57 and 0.62 mm/year in male and female respectively) likely due to the presence of more leeway space in the mandibular arch. The eruption of the upper first molar (-0.94 and -0.82 mm/year in male and female respectively) is greater than the eruption of the lower first molar (0.66 and 0.41 mm/year in male and female respectively). While this difference is statistically significant ($p < 0.05$) in females, it was not so in males likely due to small sample size.

Liu and Buschang²⁹ reported that females 10 to 15 years old exhibited a range of 0.42 mm/year to 0.76 mm/year of mandibular molar eruption, which is consistent with the findings of

our study. They also reported the lower incisors erupted 0.3 to 0.6 mm/year, which is consistent with our findings of 0.88 and 0.41 mm/year in male and female, respectively. The authors²⁹ also reported that the rate of dental eruption accelerates before and decelerate after the age of 11-12 year old, and thus a limitation of this study is that the reported values are averages of a likely fluctuating rate.

The upper central incisors display similar rate of vertical eruption (-1.01 and -0.95 mm/year in male and female, respectively) as the upper first molars. This is consistent with the findings of Iseri and Solow³⁰ who have reported about 5.5 mm of maxillary first molar eruption and 5 mm of maxillary central incisor eruption in females from age 10 to 15 years. Both Iseri and Solow³⁰ and Bjork and Skieller¹ found posterior eruption was greater than anterior eruption. Our study reports forward movement of the lower incisor tip relative to the mandible and a variation in sagittal movement of the upper incisor tip. This can be explained by Bjork and Skieller's characterization of occlusal adaptation in forward rotators who have a stable anterior occlusion versus those with an instable anterior occlusion. In both scenarios, they find the lower incisors procline relative to the mandible to compensate for the forward rotation. In those who have a stable anterior occlusion, the upper anteriors maintain their inclination relative to the maxilla or move forward as it is supported palatally by the lower anteriors. In those who have an instable anterior occlusion, the upper anteriors retrocline relative to the maxilla to compensate for the forward rotation because they are not supported palatally by the lower anteriors.

Conclusion:

The following conclusions can be made from this study:

1. On a cranial base superimposition, Orbitale, A point and B point move anteriorly and inferiorly. Porion moves posteriorly and inferiorly. Nasion moves inferiorly and shows a large variation in vertical displacement. SN and Frankfort horizontal may not be reliable as reference planes for longitudinal evaluation of growth.
2. A point displays inferior movement that is only statistically significant in males and variable sagittal movement on a maxillary superimposition. B point displays superior movement that is only statistically significant in males and variable sagittal movement on a mandibular superimposition. The inter-individual variability in A and B point may be due to remodeling, influence of permanent dentition tooth buds, and tracing error.
3. The angular measurements that use CB line instead of SN, CB point instead of N, Mx point instead of A point and/or Md point instead of B point, may be a more accurate depiction of growth as it negate those variables that affect the position of N, S, A and B.
4. Most subjects display counterclockwise rotation of jaws and correlated processes, such as the forward growth of the condyle, clockwise rotation of the compensatory remodeling of the inferior mandibular border, and reduction of the gonial angle. These correlated processes occur in the opposite direction for the individual who had clockwise rotation of the jaws.
5. Males have greater increases in mandibular length than females. Increases in mandibular length and vertical growth of the condyle are correlated with vertical dentoalveolar eruption.
6. The maxillary and mandibular molars and incisors erupt at similar rates. The maxillary molars erupt more than the mandibular molars. The mandibular molar mesializes more than the maxillary molar due to greater leeway space. The maxillary and mandibular incisors procline only slightly on a maxillary and mandibular superimposition, respectively.

References:

1. Björk A, Skieller V. Facial development and tooth eruption: An implant study at the age of puberty, *American Journal of Orthodontics* 1972; 62(4): 339-83
2. Scott J. The cranial base. *Am J Phys Anthropol* 1958;16:319-48.

3. Steuer I. The cranial base for superimposition of lateral cephalometric radiographs. *Am J Orthod* 1972;61:493-500.
4. Melsen B. The cranial base: the postnatal development of the cranial base studied histologically on human autopsy material. *Arhus*; 1974;66(6):689-91
5. Afrand M, Ling CP, Khosrotehrani S, Flores-Mir C, Lagravere-Vich MO. Anterior cranial-base time-related changes: a systematic review. *Am J Orthod Dentofacial Orthop* 2014;146(1):21-32.e6.
6. Afrand M, Oh H, Flores-Mir C, Lagravere-Vich, MO. Growth changes in the anterior and middle cranial bases assessed with cone-beam computed tomography in adolescents *Am J Orthod Dentofacial Orthop* 2017;151(2):342-50.e2.
7. Björk A, Skieller V. Growth of the maxilla in three dimensions as revealed radiographically by the implant method, *Br J Orthod* 1977: 4:53–64.
8. Nielsen IL. Maxillary superimposition: a comparison of three methods for cephalometric evaluation of growth and treatment change, *Am J Orthod Dentofacial Orthop* 1989; 95:422–431.
9. Doppel DM, Damon WM, Joondeph DR, Little RM. An investigation of maxillary superimposition techniques using metallic implants. *Am J Orthod Dentofacial Orthop* 1994;105:161-8.
10. Ruellas ACO, Ghislanzoni LTH, Gomes MR, Danesi C, Lione R, Nguyen T, McNamara JA, Cozza P, Franchi L, Cevidane LHS. Comparison and reproducibility of two regions of reference for CBCT maxillary regional registration. *Am J Orthod Dentofacial Orthop*. 2016; 149(4): 533–542
11. Björk A, Skieller V: Normal and abnormal growth of the mandible: a synthesis of longitudinal cephalometric implant studies over a period of 25 years, *Eur J Orthod*. 1983 5:1–46.
12. Springate SD, Jones AG. The validity of two methods of mandibular superimposition: a comparison with tantalum implants. *Am J Orthod Dentofacial Orthop*. 1998; 113(3):263–70.
13. Krarup S, Darvann TA, Larsen P, Marsh JL, Kreiborg S. Three-dimensional analysis of mandibular growth and tooth eruption. *J Anat*. 2005; 207(5):669–82.
14. Buschang PH, LaPalme L, Tanguay R, Demirjian A. The technical reliability of superimposition on cranial base and mandibular structures. *Eur J Orthod*. 1986; 8: 152-156.
15. Habeeb M, Boucher N, Chung CH. Effects of rapid palatal expansion on the sagittal and vertical dimensions of the maxilla: A study on cephalograms derived from cone-beam computed tomography. *Am J Orthod Dentofacial Orthop* 2013; 144(3):398-403
16. English JD, Tadlock L, Briss BS, Litschel K. *Diagnosis of Orthodontic Problems*. Mosby's *Orthodontic Review* 2 Ed. Chapter 6:92-96.
17. Knott VB. Change in cranial base measures of human males and females from age 6 years to early adulthood. *Growth* 1971;35:145-58.
18. Ranly DM. Craniofacial growth. *Pediatric Dentistry*. 2000; 44(3): 462.
19. Björk A, Skieller V: Growth of the maxilla in three dimensions as revealed radiographically by the implant method, *Br J Orthod* 4:53–64, 1977
20. Baumrind S, Korn EL, Issacson RJ, et al: Superimpositional assessment of treatment-associated changes in the temporomandibular joint and the mandibular symphysis, *Am J Orthod* 84:443–465, 1983.
21. Buschang PH, Santos-Pinto A: Condylar growth and glenoid fossa displacement during childhood and adolescence, *Am J Orthod Dentofacial Orthop* 113:437–442, 1998.
22. Wang MK, Buschang PH, Behrent R. Mandibular Rotation and remodeling changes during early childhood. *Angle Orthodontist*. 2009; Vol 79(2): 271-75

23. Spady M, Buschang PH, Demirjian A, LaPalme L. Mandibular rotation and angular remodeling during childhood and adolescence. *Am J Hum Biol.* 1992;4:683–689.
24. Lavergne J, Gasson N. Direction and intensity of mandibular rotation in the sagittal adjustment during growth of the jaws. *Scand. J. Dent. Res.* 1977; 85: 192-99.
25. Saksena SS, Walker GF, Bixler D, Yu P: A clinical atlas of roentgeno-cephalometry in norma lateralis, New York, 1987, Alan R. Liss.
26. Sassouni V: A classification of skeletal types, *Am J Orthod* 55:109–123, 1969.
27. Baumrind S, Ben-Bassat Y, Korn EL, et al: Mandibular remodeling measured on cephalograms. 1. Osseous changes relative to superimposition on metallic implants, *Am J Orthod Dentofacial Orthop* 102:134–142, 1992.
28. Buschang PH, Santos-Pinto A, Demirjian A: Incremental growth charts for condylar growth between 6 and 16 years of age, *Eur J Orthod* 21:167–73, 1999.
29. Liu SS, Buschang PH. How does tooth eruption relate to vertical mandibular growth displacement? *Am J Orthod Dentofacial Orthop* 2011;139(6): 745-51
30. Iseri H and Solow B. Continued eruption of maxillary incisors and first molars in girls from 9 to 25 years, studied by the implant method. *Eur J Orthod* 1996; 18: 245-56

PART II: Transverse Growth

Abstract:

Objectives: To conduct a longitudinal study of transverse growth in untreated patients using CBCT. **Materials and methods:** Two sets of scans of 12 male (mean age 8.75 years at T1 and 11.52 at T2) and 18 female (mean age 9.09 years at T1 and 10.80 years at T2) untreated adolescents were analyzed using Dolphin 3D imaging. The transverse widths of various skeletal landmarks and the dentoalveolus at the first molar were measured.

Results: The anterior nasal width increases at 0.30 and 0.35 mm/year and inter-condylar width increases at 1.52 and 1.34 mm/year, in males and females, respectively. The transverse width of the posterior maxilla (Mx-Mx), increases at 1.21 and 0.92 mm/year in males and females and is positive correlated with increases in the intercondylar width. The Gonion triangle (Gonion-Menton-Gonion) maintains its angle from T1 to T2. The maxillary dentoalveolus 2 mm apical to the CEJ increases at 1.20 and 0.97 mm/year and at 10 mm apical to the CEJ increases 1.25 and 1.07 mm/year in males and females respectively. The mandibular dentoalveolus 2 mm apical to the CEJ increases at 0.46 and 0.48 mm/year and at 10 mm apical to the CEJ increases 0.63 and 0.45 mm/year in males and females respectively. The maxillary intermolar width at the buccal cusp tips increases 0.47 and 0.66 mm/year and the mandibular intermolar width increases 0.42 and 0.70 mm/year in males and females respectively. The maxillary and mandibular first molars upright about 1-2 degrees per year. **Conclusions:** There are generally greater increases in the transverse dimension in the posterior than anterior portions of the maxilla and mandible. The width of the posterior portions of the maxilla and mandible increase in a coordinated fashion. The width of the posterior portion of the mandible also seems to increase primarily as a result of lengthening of the mandibular body. The maxillary and mandibular dentoalveolar processes at the first molar increase at an equal rate corono-apically independent of the changes in molar inclination. The greater increases in the maxillary dentoalveolus reflect the presence of sutural growth in the maxilla which the mandible lacks. The first molars maintain their coordination with each other despite the differential increase in the maxillary and mandibular dentoalveolar processes. Both maxillary and mandibular molars also upright with age.

Introduction:

The transverse dimension remains the least understood of the three dimensions of craniofacial growth. This is primarily due to a lack of reliable tools for an accurate analysis. Most of our current understanding of transverse growth comes from implant studies, which were longitudinal assessments of patients who had implants inserted into their jaws and evaluated with two dimensional posteroanterior (PA) and lateral cephalograms. Bjork and Skieller¹ found that there is three times as much sutural growth between posterior implants in the infrazygomatic area than the anterior implants placed below ANS. Korn and Baumrind² found similar rates of transverse growth in the maxilla of about 0.4 mm/year, and additionally used mandibular implants to characterize transverse growth of the mandibular dentoalveolar region at about 0.39 degrees per year.

Ricketts et al.^{6,7} introduced the use of Jugale (J; the point of intersection of the maxillary tuberosity and zygoma) and Antegonion (Ag; the antegonial notch) as potential landmarks from which we could measure the transverse dimension of the maxilla and mandible, respectively. They reported that J-J increases by about 1 mm per year and Ag-Ag increases by 1.5 mm per year from age 3 to 21 years old, slightly more than their previous study that reported 0.6 mm/year and 1.4 mm/year respectively from age 9-16.

Cortella et al.⁸ reported similar initial rates of increase in J-J and Ag-Ag. However, contrary to Ricketts et al. they found that the rate is not sustained over growth and that it decelerates at different times depending on the gender. For females, J-J and Ag-Ag growth ceases around 16 years old. For males, J-J only slightly reduces its growth rate and Ag-Ag maintains its growth rate at least until 18 years old. Wagner and Chung⁹ reported that the rate of transverse growth also differs among vertical facial types. J-J increases at a similar rate from age 6-14 years old for high angle, low angle and normal females. However, Ag-Ag discontinues growth in high angle females earlier than that of low and normal angle females. The inconsistency among the literature reflects the limitations of PA cephalograms as a tool for evaluation. Two-dimensional radiography is distorted by radiographic enlargement and the superimposition of structures makes it difficult to identify certain landmarks as shown by Major et al.¹⁰ Head position adds another uncontrollable variable that influences measurements as shown by Shokri et al.¹¹

Moyers et al.³ used dental models to demonstrate that intermolar width increases more in males than females from ages 6 to 16 years old and that maxillary intermolar width increases more than the mandibular intermolar width in both genders. While other studies using dental models found no gender differences in intermolar width, most agree with an initially increasing intermolar width that ceases with the development of full permanent dentition.^{4,5} While dental models are a useful tool in assessing the transverse changes in the dentition, they are limited in an evaluation of transverse changes of the dentoalveolar and skeletal components of the face.

Through advances in technology, cone beam computer tomography (CBCT) has become a widely used form of diagnostic imaging in a clinical setting. CBCT eliminates errors from head positioning, magnification, and obstructed visibility. Three dimensional imaging allows us to make transverse measurements in different coronal sections going antero-posteriorly and hence more information can be gleaned from these images. For example, multiple CBCT studies¹²⁻¹⁴ have shown the presence of slight buccal and lingual inclination of the maxillary and mandibular 1st molars, respectively, and the uprighting of molars into adulthood. Along with other studies on expansion, Christie et al.¹⁶ described the widening of the nasal cavity, midpalatal suture, and maxillary basal bone with expansion and that expansion occurs more inferiorly than superiorly.

CBCT studies also have the potential to create transverse norms which we can use to diagnose "transverse discrepancies" and answer the question as to whether treatment of a perceived "transverse discrepancy" is necessary from the standpoint of keeping the dentition centered within the alveolar housing. Miner et al.¹⁵ described a norm ratio of the width of the maxilla and mandible at the first molar and that those who fall under that norm tend to have posterior crossbites or excessive compensatory inclination of the first molars. While the potential

of CBCTs in evaluation of the transverse dimension is vast, the limitation in our progress is the lack of images from untreated patients.

The purpose of this study is to evaluate the longitudinal transverse growth changes in untreated children using CBCT.

Materials and Methods

This study was approved by the University of Pennsylvania International review board and ethics committee. All CBCT images were oriented and analyzed using the Dolphin Imaging 3D software (version 11.9, Dolphin Imaging & Management Solutions, Chatsworth, Calif).

Sample

Thirty untreated subjects who had CBCT images taken at different time periods were collected from various private practices utilizing CBCT imaging in routine records exams. The subjects were not treated at T1 for various clinical reasons that caused delays in treatment. The sample examined in this study includes 12 males who are at an average age of 8.75 years old at T1 (5.4 – 11.48 yo) and 11.52 years old at T2 (8.7 – 14.7 yo) as well as 18 females who are at an average age of 9.09 years old at T1 (6.2 – 11.7 yo) and 10.8 years old at T2 (7.2 – 13.7 yo).

Orientation

Roll: The cranium was oriented such that a midline could be drawn through the midpoint of the frontonasal suture and base of the nose and is parallel to the true vertical. In addition, a true horizontal line goes through the most inferior aspect of the orbits.

Yaw: The cranium was oriented to achieve best symmetry of the cranium, zygomatic, and maxillary structures on either side of the midline.

Pitch: The cranium was oriented such that the Frankfort horizontal was parallel to the true horizontal for measurements on the non-tooth bearing, skeletal features of the face. The cranium was oriented such that the functional occlusal plane was parallel to the true horizontal for measurements on the tooth bearing, dentoalveolar areas.

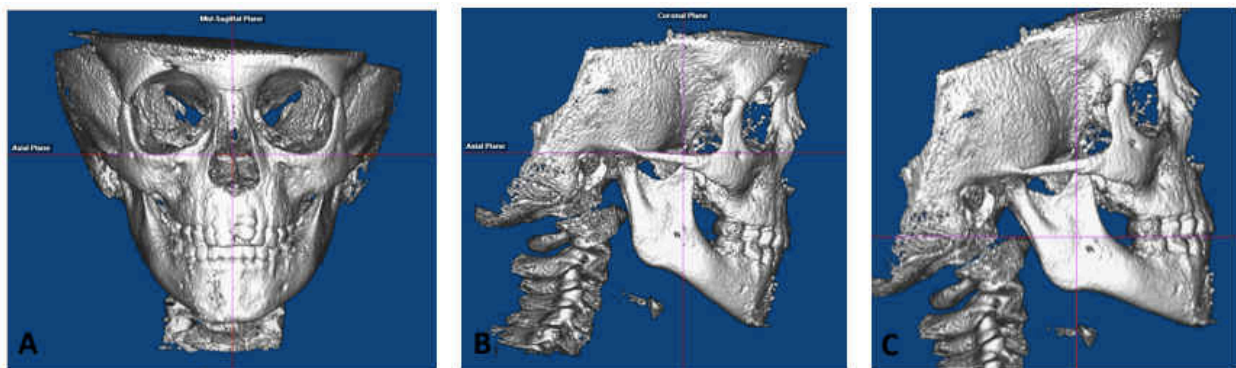


Figure 1. (A) Roll was oriented such that a true vertical midline could be drawn through the midpoint of the frontonasal suture and the base of the nose. A perpendicular true horizontal line could also be drawn through the most inferior aspect of the orbits and/or the most concave aspects of the infrazygomatic space. Yaw was oriented such that approximately equal widths of the maxilla and cranium can be seen on either of the midline. (B) Pitch was oriented with the Frankfort Horizontal which was used for skeletal measurements. (C) Pitch was oriented with the functional occlusal plane for the dental and dentoalveolar measurements.

Skeletal measurements

The transverse changes in the non-tooth bearing, skeletal areas of the face were measured with the cranium oriented with Frankfort horizontal as the true horizontal. All measurements were parallel to the true horizontal. The following skeletal measurements were made and are shown in Figure 2:

- lo-lo: when viewed from the frontal, the distance between the mesiodistal and inferosuperior center of the infraorbital foramen
- Mf-Mf: when viewed from the frontal, the distance between the most mesial margin of the mental foramen
- Anterior nasal width: when viewed from the frontal, the distance between the most convex point along the lateral nasal margins
- Mx-Mx: when viewed from the frontal, the distance between the most concave point in the infrazygomatic area
- Go-Go: when viewed from the inferior, the distance between the mesiodistal center at the most infero-posterior point of the inferior mandibular border
- Cd-Cd medial: the distance between the most medial points of the condyle that could be seen on axial cross sections of the condyle
- Cd-Cd lateral: the distance between the most lateral points of the condyle that could be seen on axial cross sections of the condyle
- Cd-Cd middle: the average of Cd-Cd medial and Cd-Cd lateral and represents the midpoint of the condylar head
- U6 nasal width: the distance between the most convex point along the lateral nasal wall on a coronal section at the mesiodistal center of the maxillary 1st molar
- Gonion triangle: when viewed from the inferior, the angle between left and right gonion and menton. The points are identified on a profile view and the angle lies in the axial plane.

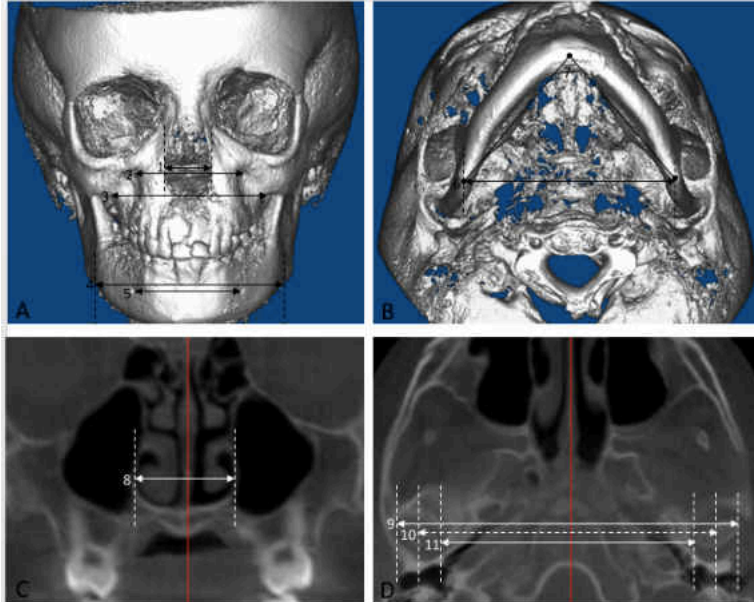


Figure 2. The transverse width of various non-tooth bear areas of the maxilla and mandible was measured (“Skeletal measurements”), as described above. (A) 1. anterior nasal width, 2. lo-lo, 3. Mx-Mx, 4. Ag-Ag, 5. Mf-Mf. (B) 6. Go-Go, 7. Gonion triangle. (C) 8. U6 nasal width. (D) 9. Cd-Cd lateral, 10. Cd-Cd middle, 11. Cd-Cd medial

Dentoalveolar Measurements:

The transverse width of the tooth bearing areas on the T1 CBCT image were measured with the cranium oriented with the functional occlusal plane. The new true horizontal was transferred onto the T2 lateral cephalogram tracing on a maxillary superimposition as well as on

a mandibular superimposition. The maxillary superimposition was done on the anterior surface of the zygoma, the maxillo-zygomatico-temporal sulci and centered within the T2 tracing.^{1,17,18} The mandibular superimposition was done via the "Structural Method."^{19,20} These transferred lines were then used to orient the T2 CBCT image for the maxillary and mandibular dentoalveolar transverse measurements. This would ensure the T2 image was oriented in a way that would enable the observer to make measurements in areas comparable to that of the T1 image.

On the T1 image, the transverse width was measured on axial cross sections at the following vertical levels, also shown in Figure 3 below:

- Mx/Md 1: 2 mm apical to the U/L6 CEJ on the T1 image. The most coronal axial cut on the T2 image.
- Mx/Md 2: 6 mm apical to the U/L6 CEJ on the T1 image. The mid-axial cut between the most coronal and most apical cut on the T2 image
- Mx/Md 3: 10 mm apical to the U/L 6 CEJ on the T1 image. The most apical axial cut on the T2 image.
- Mandibular inferior border: the most inferior point on the mandibular border identified on a coronal section.

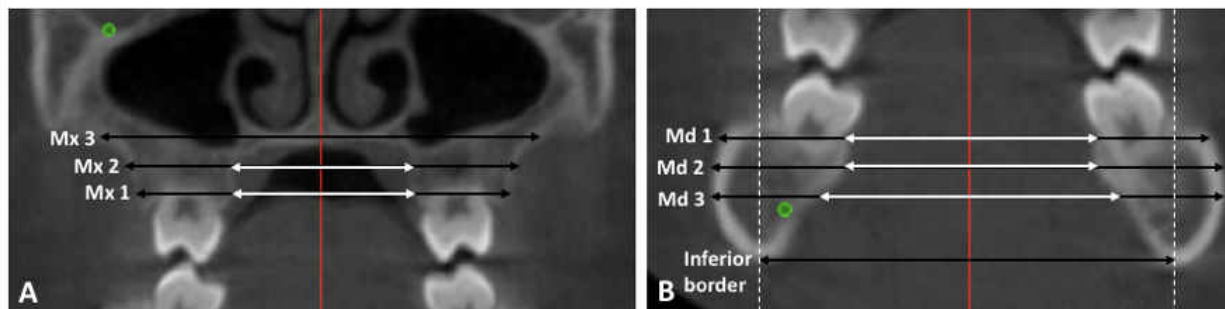


Figure 3. (A) Shown is a coronal section going through the mesiodistal midpoint of the maxillary first molar. The transverse width was measured at Mx 1, Mx 2, and Mx 3 as shown and described above. (B) Shown is a coronal section going through the mesiodistal midpoint of the mandibular first molar. The transverse width was measured at Md 1, Md 2, Md 3, and inferior border as shown and described above. The black arrow shows the buccal transverse width and the white arrow shows the lingual transverse width. The coronal and axial cross sections at which measurements were completed on the T2 image were identified by using the infraorbital and mental foramina.

The buccal and lingual transverse widths were measured at the Mx/Md 1, 2, and 3 levels as described above on a coronal plane going through the mesiodistal center of the upper and lower first molars on the T1 image (U/L6). On the T2 image, the location of this coronal plane and the Mx/Md 1, 2, and 3 levels were calculated and identified based on distance from the right infraorbital foramen for the maxillary measurements and the right mental foramen for the mandibular measurements. If the maxillary and mandibular tracing superimpositions revealed movement of Mf and Io, the x and y components of this movement was factored into the calculation. Therefore, the location of the axial and transverse measurements on T2 are based on known standardized stable sagittal structures. As a result, the Mx/Md 1, 2, 3 levels identified on the T2 image were more than 2, 6, 10 mm apical to the 1st molar CEJ due to vertical dental eruption that occurs with growth. The coronal plane T2 was usually at or slightly distal to the mesiodistal center of the first molar due to mesial drift of the first molar into leeway space.

Dental

All dental measurements were made with the cranium oriented using the functional occlusal plane of the T1 image. The intermolar measurements were made at the cusp tips on the

upper and lower first molar. The cusp tips were identified on coronal sections going through the mid point of the buccal furcation of the right and left first molar. The intermolar width is measured within a single coronal plane.

The molar inclination was measured as an angle formed by the long axis of the molar and true horizontal in a single coronal section. The long axis was identified by the mesiodistal and buccolingual center at the furcation and the deepest point of the occlusal table on the coronal section as done by Alkhatib and Chung.¹³ The inner angle was measured for both maxillary and mandibular first molars.

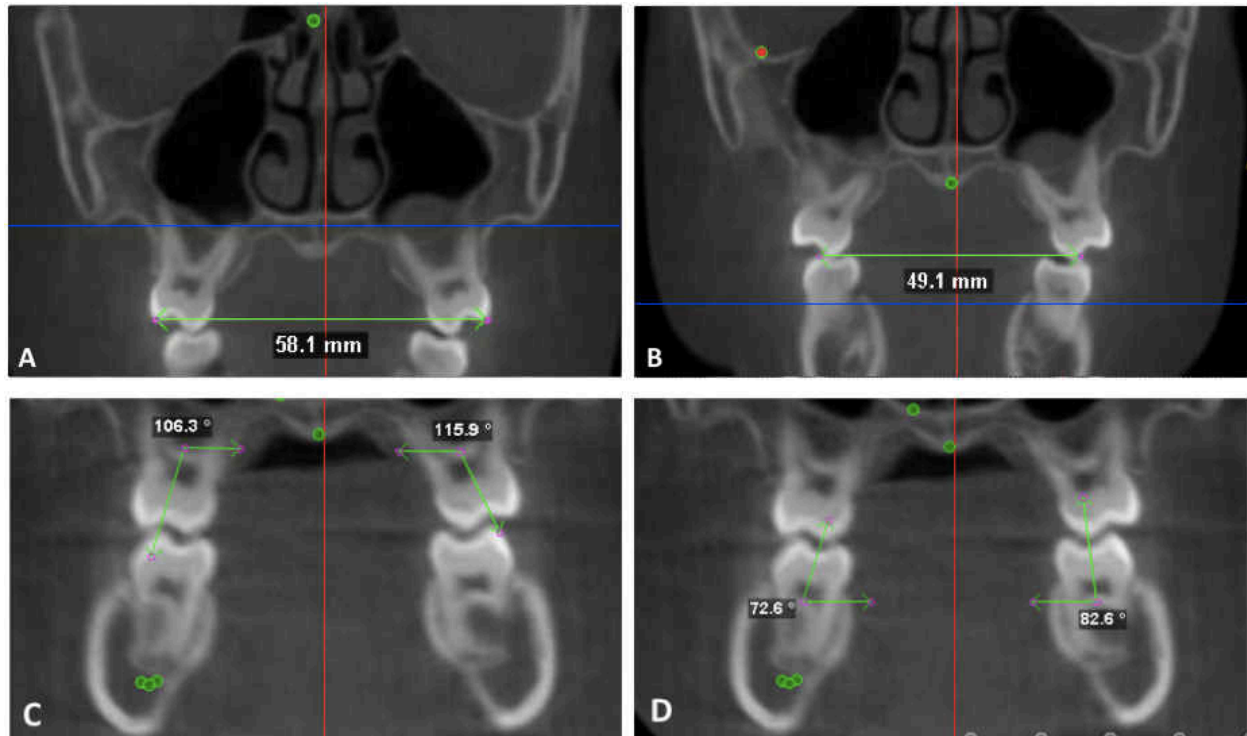


Figure 4. Intermolar width and inclination with the maxillary and mandibular first molars. (A) maxillary intermolar width at the buccal cusp tips. (B) mandibular intermolar width at the buccal cusp tips. (C) maxillary molar buccolingual inclination (D) mandibular molar buccolingual inclination

Statistical analysis

The mean, standard deviations, and ranges were calculated for the resulting data which is composed of the annual differences between the T1 and T2. A student T-test was used to confirm the statistical significance that there is a change between T1 and T2 ($p < 0.05$). Intraexaminer reproducibility was tested by having all measurements of 8 randomly selected patients remeasured and reanalyzed by the same examiner (L.S.Y.) at least 1 month later. A student paired t test and Pearson correlation coefficient were done to determine whether there are statistically significant differences at $p < 0.05$ between the two sets of data.

Results

The intraexaminer reproducibility test revealed no statistically significant differences ($p > 0.05$) between the data collected for the re-analyzed sample of 8 random patients. In each case the Pearson correlation coefficient varied between 0.95 and 0.99 except for the maxillary intermolar measurements which had Pearson correlation coefficients above 0.91.

Skeletal

Table 1 and Figure 1 show the average annual changes for the transverse width of non-tooth bearing skeletal structures of the face in males and females. All measurements except the gonion triangle display annual increases ($p < 0.05$) and are in millimeters. The gonion triangle is in degrees and shows slight annual decreases but it is not significant ($p > 0.05$). Among the maxillary and mandibular skeletal measurements, the anterior nasal width displays the smallest annual increases at 0.30 and 0.35 mm/year for males and females respectively. The nasal width increases more posteriorly (U6 nasal width) at 0.94 and 0.73 mm/year for male and female respectively. The intermaxillary width (Mx-Mx) has the largest annual increase of the maxillary transverse measurements at 1.21 and 0.92 mm/year in males and females respectively. The inter-infraorbital foramen width (Io-Io) increases 0.73 and 0.81 mm/year in males and females respectively. The inter-mental foramen width (Mf-Mf) increases 0.71 and 0.41 mm/year in males and females, respectively. Io-Io, Mx-Mx, and U6 nasal width increase significantly more than Mf-Mf in females only.

The inter-mental foramen width (Mf-Mf) has the smallest annual increases among the mandibular measurements and second smallest overall in both genders. The inter-condylar width at the lateral aspect of the condyles (Cd-Cd lateral) increases at 2.02 and 1.71 mm/year in males and females respectively. In males, Cd-Cd lateral increases significantly more than all skeletal measurements except the inter-gonion width (Go-Go). In females, Cd-Cd lateral increases significantly more than all but Go-Go and the inter-Antegonion width (Ag-Ag). The inter-gonion width (Go-Go) increases 1.81 and 1.38 mm/year in males and females respectively. In both genders, Go-Go increases significantly more than all maxillary measurements, Mf-Mf, and Cd-Cd medial. The inter-condylar width at the medial aspect of the condyles (Cd-Cd medial) increases 1.03 and 0.98 mm/year in males and females respectively. The inter-condylar width from the middle of the condyles (Cd-Cd middle) is an average of Cd-Cd lateral and Cd-Cd medial and is 1.52 and 1.34 mm/year for males and females respectively. In males, Cd-Cd med has significantly smaller increases than Ag-Ag, Go-Go, Cd-Cd lat, and Cd-Cd mid. In females, Cd-Cd medial has significantly smaller increases than Go-Go and Cd-Cd lateral. Cd-Cd middle has significantly smaller increases than Cd-Cd lateral in males only. Cd-Cd middle and Cd-Cd lateral are larger than Mf-Mf in both genders.

Table 1. Skeletal Changes Per Year in Males and Females

	Male						Female					
	N	Mean	SD	Min	Max	p-value	N	Mean	SD	Min	Max	p-value
Anterior Nasal Width (mm)	12	0.30	0.23	-0.02	0.72	$p < 0.05$	18	0.35	0.29	0.00	0.89	$p < 0.05$
U6 Nasal Width (mm)	10	0.94	0.40	0.58	1.87	$p < 0.05$	17	0.73	0.27	0.23	1.14	$p < 0.05$
IO-IO (mm)	12	0.73	0.48	0.09	1.71	$p < 0.05$	18	0.81	0.62	0.13	2.53	$p < 0.05$
Mx-Mx (mm)	12	1.21	1.04	0.03	4.03	$p < 0.05$	17	0.92	0.71	0.00	2.62	$p < 0.05$
Mf-Mf (mm)	12	0.71	0.60	0.00	2.30	$p < 0.05$	18	0.41	0.39	0.05	1.48	$p < 0.05$
Ag-Ag (mm)	11	1.55	0.59	0.43	2.30	$p < 0.05$	17	1.37	0.84	0.13	3.33	$p < 0.05$
Go-Go (mm)	11	1.81	0.41	1.28	2.78	$p < 0.05$	16	1.38	0.52	0.19	2.16	$p < 0.05$
Cd-Cd medial (mm)	12	1.03	0.58	0.35	2.59	$p < 0.05$	17	0.98	0.52	0.08	1.85	$p < 0.05$
Cd-Cd middle (mm)	12	1.52	0.42	1.04	2.52	$p < 0.05$	17	1.34	0.50	0.11	2.13	$p < 0.05$
Cd-Cd lateral (mm)	12	2.02	0.42	1.23	2.89	$p < 0.05$	17	1.71	0.77	0.00	3.75	$p < 0.05$
Gonion Menton Triangle (degrees)	12	-0.10	0.44	-0.92	0.72	$p > 0.05$	17	-0.14	0.65	-1.23	0.82	$p > 0.05$

Figure 1. Skeletal changes per year for males and females

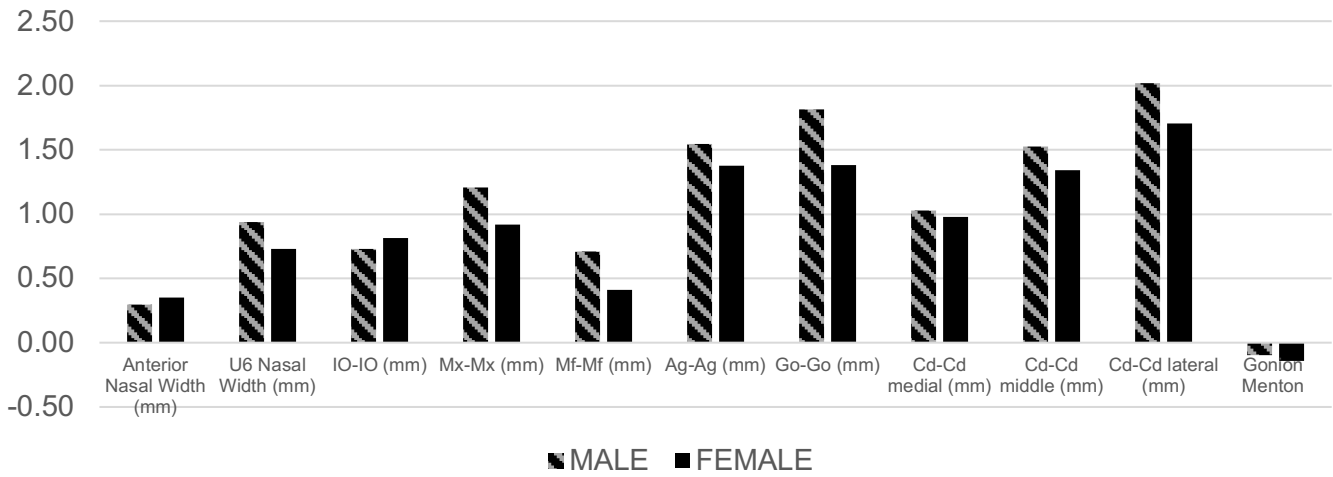


Table 1 and Figure 1 show the average annual changes in transverse width of certain skeletal, or non-toothbearing regions of the face for males (stripes) and females (solid). All changes are significant, except the gonion triangle.

Dentoalveolar

Table 2 and Figure 2 show the transverse changes in and near the tooth bearing region in the maxilla and mandible respectively. In the posterior aspect of the maxillary dentoalveolus at the 1st molar (U6), the buccal transverse width at the Mx 1, Mx 2, and Mx 3 levels increase at 1.20 mm/year, 1.06 mm/year, and 1.25 mm/year respectively in males and 0.97 mm/year, 0.73 mm/year, and 0.82 mm/year respectively in females. The transverse width when measured from the lingual aspect of the alveolus at the Mx 1 and Mx 2 level increases 0.47 mm/year and 0.12 mm/year respectively in males and 0.31 mm/year and 0.82 mm/year respectively in females. The lingual aspect of the alveolus could not be measured at the Mx 3 level because this level was superior to the palatal vault.

In the posterior aspect of the mandibular dentoalveolus at the 1st molar (L6), the buccal transverse width at the Md 1, Md 2, and Md 3 levels, and the inferior aspect of the mandibular border increases at 0.46 mm/year, 0.48 mm/year, 0.63 mm/year, and 0.56 mm/year respectively in males and 0.48 mm/year, 0.40 mm/year, 0.45 mm/year, and 0.61 mm/year in females respectively. The lingual transverse width at Md 1, Md 2, and Md 3 increases 0.30 mm/year, 0.52 mm/year, and 0.77 mm/year respectively in males and 0.31 mm/year, 0.40 mm/year, and 0.51 mm/year respectively in females.

The buccal transverse widths at Mx 1, 2, and 3 show greater annual increases than the lingual transverse width at Mx 1 in both genders. The differences among the buccal and lingual transverse widths at Md 1, Md 2, and Md 3 and the mandibular inferior border are not statistically significant in either gender. In males, the buccal transverse width at Mx 1, Mx 2, and Mx 3 have greater annual increases of all the mandibular dentoalveolar annual changes except the Md 3 lingual. In females, the buccal transverse width at Mx 1 and Mx 3 have greater annual increases than Md 1 buccal and lingual, Md 2 buccal and lingual, and Md 3 buccal.

Table 2. Maxillary and Mandibular Dentoalveolar Changes Per Year in Males and Females

	Male						Female					
	N	Mean	SD	Min	Max	p-value	N	Mean	SD	Min	Max	p-value
Mx 1 buccal	11	1.20	0.63	0.09	2.25	p < 0.05	18	0.97	0.56	0.22	2.58	p < 0.05
Mx 1 lingual	11	0.47	0.55	-0.07	1.87	p < 0.05	17	0.31	0.41	-0.24	1.22	p < 0.05
Mx 2 buccal	12	1.06	0.52	0.15	2.04	p < 0.05	18	0.73	0.58	-0.36	1.56	p < 0.05
Mx 2 lingual	5	0.12	0.24	-0.09	0.53	p > 0.05	8	0.82	0.64	0.00	1.95	p < 0.05
Mx 3 buccal	10	1.25	0.87	-0.07	2.87	p < 0.05	17	1.07	1.06	-0.37	3.31	p < 0.05
Md 1 buccal	12	0.46	0.57	-0.42	1.22	p < 0.05	18	0.48	0.93	-1.45	2.08	p < 0.05

Figure 2. Maxillary and Mandibular dentoalveolar changes per year for males and females

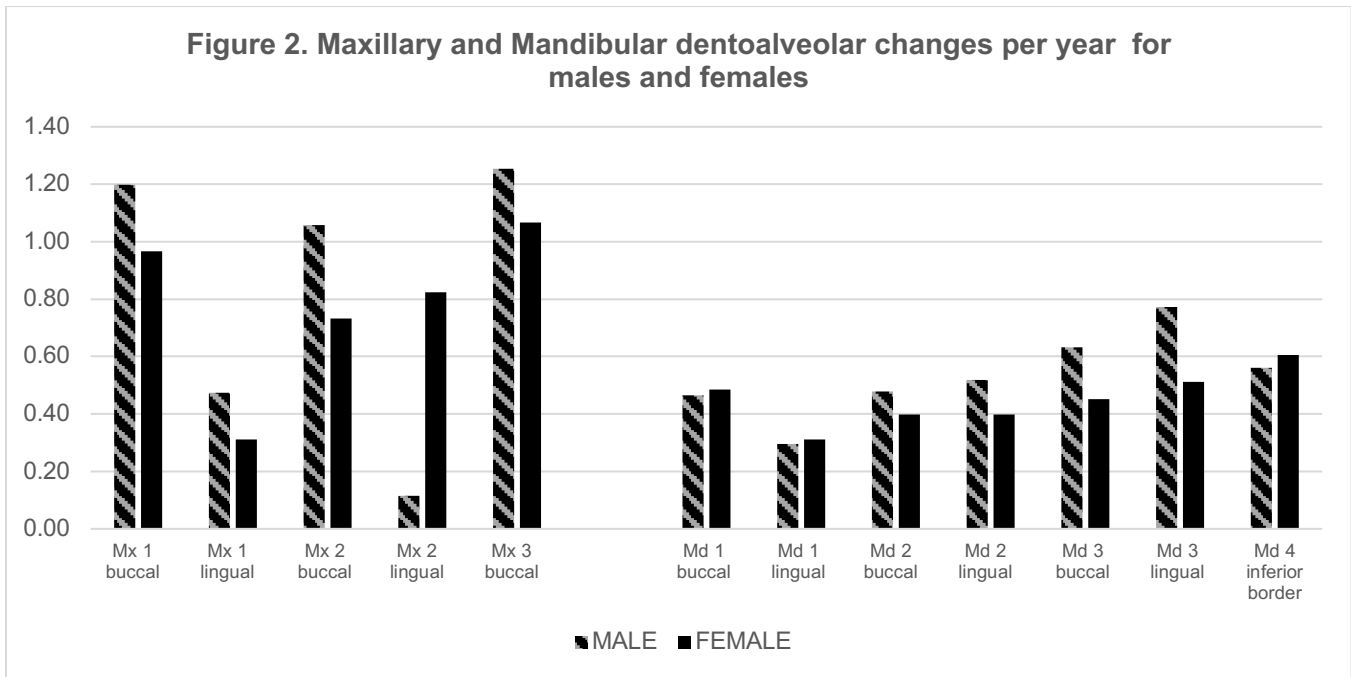


Table 2 and Figure 2 show the average annual changes in transverse width of the maxillary and mandibular dentoalveoli when measured from the buccal and lingual surfaces for males (stripes) and females (solid) at three levels apical to the CEJ . Mx/Md 1 is most coronal and Mx/Md 3 is most apical.

Dental

Table 3 and Figure 3 show the annual transverse dental changes occur in the maxillary and mandibular first molars. The maxillary right and left first molars upright 2.27 degrees/year and 1.43 degrees/year respectively in males and 0.60 degrees/year and 2.11 degrees/year respectively in females. The mandibular right and left first molars upright 1.51 degrees/year and 1.16 degrees/year respectively in males and 2.41 degrees/year and 2.28 degrees/year respectively in females. The maxillary intermolar width measured at the cusp tips increases at 0.47 mm/year in males and 0.66 mm/year in females and the mandibular intermolar width at the cusp tips which is 0.42 mm/year in males and 0.70 mm/year in females.

Table 3. Dental Changes Per Year in Males and Females

	Male						Female					
	N	Mean	SD	Min	Max	p-value	N	Mean	SD	Min	Max	p-value
Long axis of LR6 (degrees)	9	1.51	1.77	0.06	5.62	p < 0.05	17	2.41	1.85	0.27	6.11	p < 0.05
Long axis of LL6 (degrees)	9	1.16	1.23	0.15	3.57	p < 0.05	17	2.28	2.03	-0.11	6.36	p < 0.05
Long axis of UR6 (degrees)	9	-2.27	1.80	-6.05	-0.60	p < 0.05	17	-0.60	1.06	-2.52	1.53	p < 0.05
Long axis of UL6 (degrees)	9	-1.43	1.51	-4.43	-0.09	p < 0.05	16	-2.11	1.43	-4.54	-0.14	p < 0.05
U6 buccal cusp tips (mm)	9	0.47	0.35	0.09	1.01	p < 0.05	16	0.66	0.60	-0.19	1.88	p < 0.05
L6 buccal cusp tips (mm)	9	0.42	0.44	-0.29	1.01	p < 0.05	17	0.70	0.84	-0.34	2.88	p < 0.05

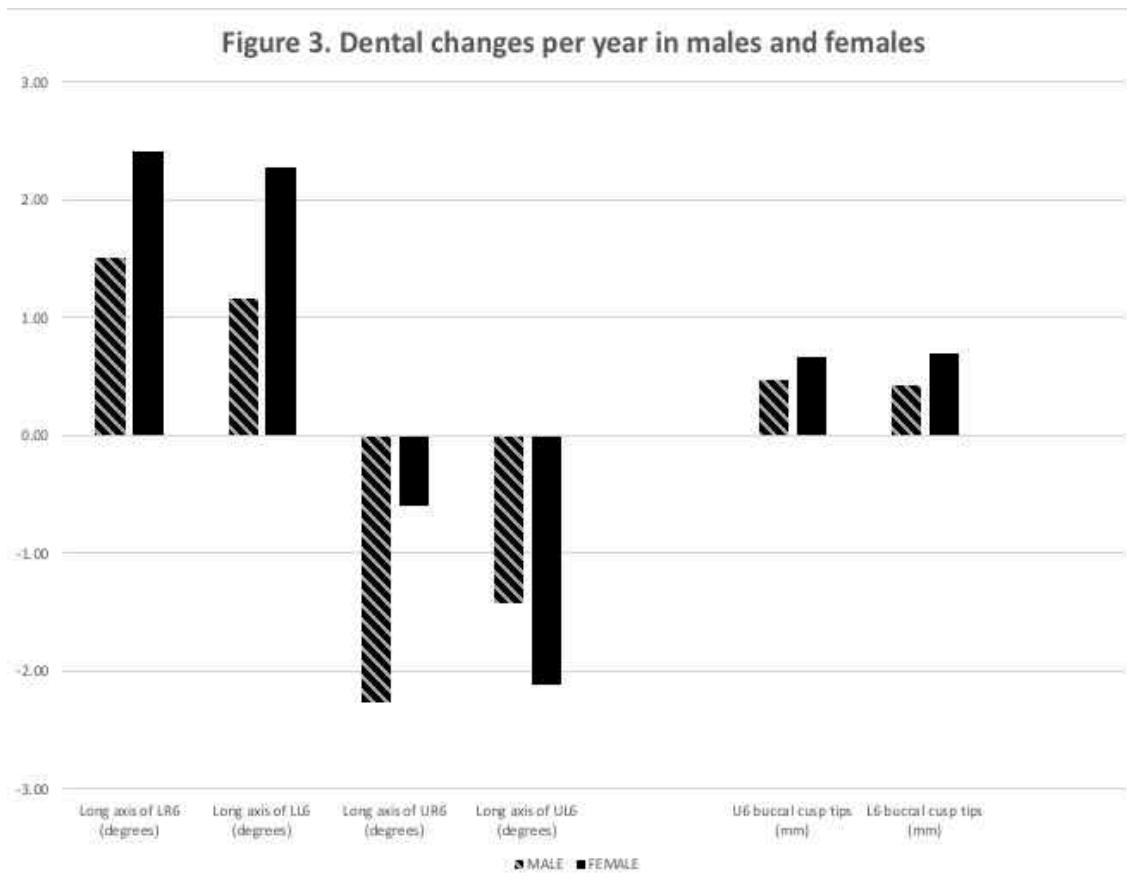


Table 3 and Figure 3 show the average annual changes in first molar position. The buccolingual molar inclination of the maxillary right (UR6), maxillary left (UL6), mandibular right (LR6), and mandibular left (LL6) first molars are in degrees. The intermolar width when measured from the buccal cusp tips is in millimeters.

Discussion:

Skeletal

Our data portrays a trend in which the posterior maxillary and mandibular structures generally have greater increases in transverse width than the anterior structures in both genders. This is consistent with the findings of Bjork and Skieller¹ who attributed this observation to greater opening in the midpalatal suture posteriorly than anteriorly. We found that the anterior nasal width increases less than posterior maxillary transverse measurements such as the inter-maxillary width (Mx-Mx) and the posterior nasal width (U6 nasal width) in both genders. Interestingly, annual increases in the Mx-Mx and the U6 posterior nasal width are positively correlated ($R = 0.75$, $p < 0.01$) in males. This is expected because Mx-Mx tends to be apical to the U6s and there are studies that have reported expansion increases the nasal cavity width.^{16,28} In the mandible, the same trend is observed. The inter-mental foramen width (Mf-Mf), which is the most anterior measurement on the mandible had smaller increases than most of the posterior mandibular transverse measurements i.e. inter-condylar (Cd-Cd), inter-gonion (Go-Go), and inter-antegonion

(Ag-Ag) widths in both genders. In general, males display higher average annual transverse increases than females, but this observation is only statistically significant for Go-Go. The lack of significance for the other measurements is likely due to small sample size.

The inter- and intra-condylar width increases in both genders. The intra-condylar width increases as demonstrated by the greater increases in Cd-Cd lateral than Cd-Cd medial. Males have greater average increases in intra-condylar width (0.50 mm/condyle/year) than females (0.34 mm/condyle/year), but this difference is not statistically significant ($P = 0.13$), likely due to small sample size. Cd-Cd middle represents the inter-condylar width at the middle of the condylar head and is the average of Cd-Cd medial and lateral. Cd-Cd middle increases at about the same rate as Go-Go and Ag-Ag in both genders, thus suggesting the posterior border of the mandible increases in a parallel fashion. In males, increases in Mx-Mx is positively correlated with increases in Cd-Cd middle ($R = 0.61$ and $p\text{-value} = 0.04$) and it increases at about the same rate as Cd-Cd medial. The condyle serves as an indirect point of articulation for the mandible to the maxilla so it would be probable that the intercondylar width would be coordinated with the posterior maxillary width. The increasing inter- and intra-condylar width also suggests that the glenoid fossae remodels and displaces laterally as well which is consistent with the findings of Ghoussoub et al.²¹ and McLeod et al.²² who reported that the inter-glenoid and inter-condylar distance increases more in patients who were expanded compared to controls.

The minimal change in the gonion triangle suggests that the increase in the posterior mandibular width (i.e. Ag-Ag and Go-Go) is commensurate to the anteroposterior lengthening of the mandible that occurs with growth, and thus, the posterior width of the mandible increases primarily due to the lengthening of the mandibular body and ramus. This is contrary to the findings of Gandini et al.²³ and Korn and Baumrind², who found an increase in the transverse width of the mandibular basal bone which suggested a rotational increase in the mandible that is coordinated with the maxilla. The differences can be explained by the location of the implants which were placed mid-body and on the buccal surfaces where surface apposition occurs from masticatory muscle insertion. McWade et al.²⁴ demonstrated through an examination of patients with a Frankel appliance that the amount of periosteal apposition in this region is affected by occlusal forces and cheek pressure. Hence the mid-mandibular body area may show greater transverse increases than the more posterior Ag-Ag and Go-Go areas.

Dentoalveolar

The maxillary dentoalveolus increases its transverse dimension primarily by opening of the midpalatal suture and secondarily by periosteal apposition.^{1,23,25} The mandibular basal bone directly beneath the dentoalveolus has been shown to increase its transverse dimension.^{2,23} This likely occurs by periosteal apposition as the midsymphysal suture is fused at birth.²⁵ Therefore, the presence of a widening suture in the maxilla and not the mandible would explain the generally greater increases in the buccal transverse width of the maxillary dentoalveolus than the mandibular dentoalveolus in both genders.

Not much is known about the transverse growth of the mandibular dentoalveolar region. This study demonstrates that the mandibular transverse width with at the first molar increases at similar and small positive rates coronopically from the crestal bone to the basal bone. The transverse width of the maxillary dentoalveolus at the first molar also displays similar rates of increase coronopically from Mx 1 to Mx 3 and Mx-Mx. It should be noted that Mx-Mx often coincided with the U6 area where the maxillary dentoalveolar measurements were done. Therefore, Mx-Mx which is identified frontally can be a good indicator of dentoalveolar growth.

The rate of increase in Ag-Ag is consistent with that of past studies.^{6,7} Ag-Ag and Go-Go, which represent the posterior mandible, increase more than all of the mandibular dentoalveolar measurements ($P < 0.05$). This suggests that Ag-Ag cannot be used to predict the transverse growth of the mandibular dentoalveolus and should be considered independent. This is in agreement with Hesby et al.²⁶ who used PA cephs to demonstrate that the transverse width of the mandibular dentoalveolar complex at the first molar has only limited increases when compared to the transverse width at Go and Ag. This observation signifies the importance of understanding

that the maxillary dentoalveolus should be compared to the width of the mandibular dentoalveolus or basal bone rather than Ag-Ag to determine a norm ratio for the maxillomandibular transverse relationship.

The maxillary dentoalveolus seems to increase in thickness by about 0.7 mm/year in both genders, which is indicated by the greater annual increase in Mx 1 buccal over that of Mx 1 lingual ($P < 0.02$). Further investigation would be needed to determine whether the increase in thickness is due to remodeling of the buccal and/or lingual aspect of the alveolus. The same is not seen in the mandibular dentoalveolus.

Dental

The maxillary and mandibular molars uprighted with age in agreement with Yang and Chung¹² and Alkhatib and Chung.¹³ Initial speculation on whether the mandibular molars upright more than the maxillary molars to compensate for the lack of sutural growth was only observed in the right side of the female group. ($p < 0.05$). The mandibular left first molar also demonstrated greater average uprighting than the maxillary first molar, but this was not statistically significant ($P > 0.05$). In males, there was no significant difference in mandibular versus maxillary molar uprighting, which may be due to small sample size. Greater sample sizes could yield more information on relative molar uprighting in the maxilla and mandible as well as confirm past studies findings that bucco-lingual molar inclination could also differ among facial types.²⁷

Despite the differential increases in the maxillary and mandibular dentoalveolus transverse widths, the maxillary intermolar width at the buccal cusp tips (U6 buccal cusp tips) increased at a similar rate as the mandibular intermolar width at the cusp tips (L6 buccal cusp tips), which would be expected as the maxillary and mandibular molars maintain their relationship throughout growth.

Conclusions:

The following conclusions can be made from this study:

1. The nasal cavity increases its transverse dimension more posteriorly than anteriorly in both genders.
2. The mandible increases more posteriorly than anteriorly in both genders.
3. The inter- and intra condylar width increases at a similar rate to the posterior maxillary width (Mx-Mx) and the two are positively correlated.
4. The inter-condylar width and inter-gonion width increase at the same rate. The posterior border of the ascending mandibular ramus grows laterally in a parallel fashion.
5. The maxillary dentoalveolus at the first molar generally has greater increases than the mandibular inferior border and mandibular dentoalveolus at the first molar.
6. The maxillary and mandibular dentoalveolus increases in width equally corono-apically. The growth of the alveoli seem to be independent of dental inclination.
7. The maxillary and mandibular molars upright with age and the maxillary and mandibular intermolar widths when measured from the buccal cusp tips increase at an equal rate.

References:

1. Bjork A, Skieller V. Growth of the maxilla in three dimensions as revealed radiographically by the implant methods. *British J Orthod.* 1977;4:53–64.
2. Korn EL, Baumrind S. Transverse Development of the Human Jaws Between the Ages of 8.5 and 15.5 Years, Studied Longitudinally With Use of Implants. *J Dent Res* 1990; 69(6)/1298-1306
3. Moyers RE, van der Linden FPGM, Riolo ML, McNamara Jr. JA: Standards of human occlusal development, Ann Arbor, Michigan, 1976, Center for Human Growth and Development, University of Michigan Monograph #5, Craniofacial Growth Series
4. Bishara SE, Bayati P, Jakobsen JR: Longitudinal comparisons of dental arch changes in normal and untreated Class II, Division 1 subjects and their clinical implications, *Am J Orthod Dentofacial Orthop* 1996; 110:483–489.

5. DeKock WH: Dental arch depth and width studied longitudinally from 12 years of age to adulthood, *Am J Orthod.* 1972; 62:56–66
6. Ricketts RM, Roth RH, Chaconas SJ, Schulhof RJ, et al. *Orthodontic Diagnosis and Planning.* Denver: Rocky Mountain Data Systems; 1982.
7. Ricketts RM, Grummons D. Frontal cephalometrics: practical applications, part I. *World J Orthod.* 2003;4:297–316.
8. Cortella S, Shofer FS, Ghafari J. Transverse development of the jaws: norms for the posteroanterior cephalometric analysis. *Am J Orthod Dentofacial Orthop.* 1997;112:519–522
9. Wagner D, Chung CH. Transverse growth of the maxilla and mandible in untreated females with low, average, and high MP-SN angles: a longitudinal study. *Am J Orthod Dentofacial Orthop.* 2005;128:716–23.
10. Major PW, Johnson DE, Hesse KL, Glover KE. Landmark identification error in posterior anterior cephalometrics. *Angle Orthod.* 1994;64(6):447-54.
11. Shokri A, Miresmaeili A, Farhadian N, Falah-Kooshki S, Amini P, Mollaie N. Effect of changing the head position on accuracy of transverse measurements of the maxillofacial region made on cone beam computed tomography and conventional posterior-anterior cephalograms. *Dentomaxillofac Radiol.* 2017;46(5): 20160180
12. Yang B, Chung CH. Buccolingual inclination of molars in untreated children and adults: a CBCT study. *Angle Orthod.* 2019;89:87–92.
13. Alkhatib R, Chung CH. Buccolingual inclination of first molars in untreated adults: a CBCT study. *Angle Orthod.* 2017;87:598–602.
14. Sayania B, Merchant M, Josephs P, Chung C-H. Changes in the buccolingual inclination of first molars with growth in untreated subjects: a longitudinal study. *Angle Orthod.* 2017;87:681–687.
15. Miner RM, Al Qabandi S, Rigali P, Will LA. Cone-beam computed tomography transverse analysis. Part 1: normative data. *Am J Orthod Dentofacial Orthop.* 2012;142: 300–307.
16. Christie KF, Boucher N, Chung C-H. Effects of bonded rapid palatal expansion on the transverse dimensions of the maxilla: a cone-beam computed tomography study, *Am J Orthod Dentofacial Orthop* 2010; 137:S79–S85.
17. Doppel D, Damon W, Joondeph D, et al. An investigation of maxillary superimposition techniques using metallic implants, *Am J Orthod Dentofacial Orthop* 1994; 105 161-68
18. Nielsen IL: Maxillary superimposition: a comparison of three methods for cephalometric evaluation of growth and treatment change, *Am J Orthod Dentofacial Orthop* 1989; 95:422–431.
19. Buschang PH, LaPalme L, Tanguay R, et al. The technical reliability of superimposition on cranial base and mandibular structures, *Eur J Orthod* 1986; 8:152-156.
20. Duterloo HS, Planché P: *Handbook of cephalometric superimposition*, Hanover Park, IL, 2011, Quintessence Publishing
21. Ghoussoub MS, Rifai K, Garcia R, Sleilaty G. Effect of Rapid Maxillary Expansion on Glenoid Fossa and Condyle-Fossa Relationship in Growing Patients (MEGP): Study Protocol for a Controlled Clinical Trial. *J Contemp Dent Pract.* 2018;19(10):1189-1198.
22. McLeod L, Hernandez IA, Heo G, Legraverre MO. Condylar positional changes in rapid maxillary expansion assessed with cone-beam computer tomography. *International Orthodontics.* Volume 14, Issue 3, September 2016, Pages 342-356
23. Gandini LG Jr, Buschang PH. Maxillary and mandibular width changes studied using metallic implants. *Am J Orthod Dentofacial Orthop.* 2000;117(1):75-80.
24. McWade RA, Mamandras AH, Hunter WS. The effects of Fränkel II treatment on arch width and arch perimeter. *Am J Orthod Dentofacial Orthop.* 1987;92(4):313-20.

25. Chung CH. Diagnosis of transverse problems. *Seminars in Orthodontics*. 2019; 25(1):16-23
26. Hesby RM, Marshall SD, Dawson DV, Southard KA, Casco JS, Franciscus RG, Southard TE. Transverse skeletal and dentoalveolar changes during growth. *Am J Orthod Dentofacial Orthop*. 2006;130(6):721-31.
27. Masumoto T, Hayashi I, Kawamura A, Katsuji T, Kazutaka K. Relationships among facial type, buccolingual molar inclination, and cortical bone thickness of the mandible. *Eur J Orthod*. 2001;23(1):15-23.
28. Garrett BJ, Caruso JM, Rungcharassaeng K, Farrage JR, Kim JS, Taylor GD. Skeletal effects to the maxilla after rapid maxillary expansion assessed with cone-beam computed tomography. *Am J Orthod Dentofacial Orthop*. 2008 Jul;134(1):8-9