

2017

# Tanshinone IIA inhibits VEGF secretion and HIF-1a expression in cultured human retinal pigment epithelial cells under hypoxia

Rami Alzhrani  
*University of Toledo*

Follow this and additional works at: <http://utdr.utoledo.edu/theses-dissertations>

---

## Recommended Citation

Alzhrani, Rami, "Tanshinone IIA inhibits VEGF secretion and HIF-1a expression in cultured human retinal pigment epithelial cells under hypoxia" (2017). *Theses and Dissertations*. 2147.  
<http://utdr.utoledo.edu/theses-dissertations/2147>

This Thesis is brought to you for free and open access by The University of Toledo Digital Repository. It has been accepted for inclusion in Theses and Dissertations by an authorized administrator of The University of Toledo Digital Repository. For more information, please see the repository's [About page](#).

A thesis

entitled

**Tanshinone IIA Inhibits VEGF Secretion and HIF-1 $\alpha$  Expression in Cultured Human  
Retinal Pigment Epithelial Cells under Hypoxia**

by

Rami Alzhrani

Submitted to the Graduate Faculty as partial fulfillment of the requirements for the Master  
of Science Degree in Pharmaceutical Science - Industrial Pharmacy

---

Sai Hanuman Sagar Boddu, Ph.D., Committee Chair

---

Zahoor Shah, Ph.D., Committee Member

---

Jerry Nesamony, Ph.D., Committee Member

---

Caren Steinmiller, Ph.D., Committee Member

---

Amanda Bryant-Friedrich, Dr. rer. Nat., Dean  
College Of Graduate Studies

The University of Toledo

August 2016

Copyright 2016, Rami Alzhrani

This document is copyrighted material. Under copyright law, no parts of this document may be reproduced without the expressed permission of the author.

An Abstract of

**Tanshinone IIA inhibits VEGF and HIF-1 $\alpha$  expression in Cultured Human Retinal  
Pigment Epithelial Cells under Hypoxia**

by

Rami Alzhrani

Submitted to the Graduate Faculty as partial fulfillment of the requirements for the  
Master of Science Degree in Pharmaceutical Sciences

The University of Toledo

August 2016

**Aim:** The current work intends to study the activity of tanshinone IIA on expression of HIF-1 $\alpha$  and secretion of VEGF in human retinal pigment epithelial cells (ARPE-19 cells) under hypoxic condition.

**Methods:** The cytotoxicity of tanshinone IIA was tested in ARPE-19 and bovine corneal endothelial cells by MTT assay. ARPE-19 cells were incubated with different concentrations of cobalt chloride (100, 150, and 200  $\mu$ M) for 12 hours and levels of expressed HIF-1 $\alpha$  and secreted VEGF were quantified through Western blot and ELISA, respectively. Further, ARPE-19 cells were pretreated for one hour with different concentrations of tanshinone IIA (5, 10, 15 and 18  $\mu$ M). After one hour, the cells were subjected to hypoxic condition using 150  $\mu$ M cobalt chloride for 12 hours in the presence and absence of tanshinone IIA. The cells were then harvested and the secreted VEGF and expressed HIF-1 $\alpha$  was studied.

Results: Tanshinone IIA at concentrations 5, 10, 15 and 18  $\mu\text{M}$  did not show cytotoxicity in both ARPE-19 and bovine corneal endothelial cells. Chemical hypoxia induced by cobalt chloride caused a significant increase in VEGF level in a dose dependent manner and HIF-1 $\alpha$  expression peaked at 150  $\mu\text{M}$ . Based on the data, cobalt chloride concentration was maintained at 150  $\mu\text{M}$  for further studies. Tanshinone IIA decreased the level of HIF-1 $\alpha$  and VEGF secretion in a dose dependent manner under hypoxic condition.

Conclusion: This study is the first report on the effects of tanshinone IIA on HIF-1 $\alpha$  expression and VEGF secretion in hypoxic ARPE-19 cells. Tanshinone IIA could be a potential new treatment option for various neovascular diseases such as AMD.

## Acknowledgements

I would like to express my sincere gratitude to my advisor Dr. Sai Boddu for the continuous support during my Master's degree study and research, for his patience, motivation, enthusiasm, and immense knowledge. His guidance helped me in conducting research and completing this thesis. I could not have imagined having a better advisor and mentor for my Master's study. I would like also to thank Dr. Zahoor Shah for being a member of my thesis committee. I also would like to thank Dr. Shah for giving me an opportunity to use his cell culture facility and instruments to finish the work. My thesis would not have been completed without his help and timely feedback. Also, I would like to thank Dr. Jerry Nesamony for serving as a member of my thesis committee and for his valuable courses which made me think deeper and out of the box. I would like to thank Dr. Alexander Kenneth for his valuable courses. I would also like to thank Dr. Caren Steinmiller for her fabulous course and being my graduate representative in my defense. I would like to thank Qasim Alhadidi who taught me cell culture, MTT assay, Western blot and immunohistochemistry. Also, I would like to thank Dr. Pannee Burckel who helped me with SEM instrument. I would like to thank Saudi Arabian Cultural Mission (SACM), Ministry of Education, Saudi Arabia and College of Pharmacy at Taif University for providing scholarship and funds to complete my Master's degrees. Also, I would like to

acknowledge Kastel's Slaughterhouse (Riga, MI) for providing bovine eyes. I would like also to thank senior and junior members of our lab, especially, Hashem Alasab and Rinda Bachu, who have helped me in my research and for being such great colleagues and friends. I would like to thank all my friends and classmates for supporting me throughout all challenges I faced. Although, the past two years were tough, I really enjoyed every single moment with my classmates. It was an unforgettable experience. Also, I would like to thank Saleh Alaqel, Qaseem Hakami, Fawaz Alasmari, Fahad Alshehri, Youssef Althibiti, Mohammed Shahadat and Kevin Nash for their support and suggestions especially in Western Blot.

Most of all, I would like to thank my parents for unlimited support, love and care especially during my study abroad, which charged me with strength, hope, and enthusiasm. I would to thank my brothers and sisters who have been encouraging, and supporting me since I started my abroad educational journey.

Table of content

ABSTRACT .....	iii
ACKNOWLEDGEMENTS.....	v
TABLE OF CONTENT .....	vii
LIST OF FIGURES .....	xi
CHAPTER 1 .....	1
1.1    OVERVIEW .....	1
1.2    ANATOMY OF THE EYE .....	3
1.2.1    Structure and anatomy of retina.....	4
1.2.2    Photoreceptors .....	5
1.2.3    Retinal Pigment Epithelium.....	6
1.2.4    Bruch’s Membrane: .....	7
1.2.5    Choriocapillaris (CC) .....	8
1.3    MAJOR TYPES OF AMD .....	8
1.3.1    Neo-vascular AMD/Wet/Exudative .....	8
1.3.2    Non-neovascular/Dry/Atrophic AMD .....	9



1.4	STAGES OF AMD .....	10
1.4.1	Early AMD .....	10
1.4.2	Late stages of Dry AMD (Geographic atrophy).....	10
1.5	RISK FACTORS.....	10
1.6	PATHOGENESES .....	11
1.6.1	HIF-1 $\alpha$ regulated AMD.....	13
1.6.2	Inflammation mediated AMD .....	15
1.7	DIAGNOSIS .....	15
1.7.1	Amsler Grid.....	16
1.7.2	Optical coherent tomography (OCT).....	17
1.7.3	Fundus Fluorescein Angiography (FFA) and Indocyanine Green (ICG):.....	18
1.8	MANAGEMENT OF AMD .....	19
1.8.1	Ocular Photodynamic Therapy (OPT).....	19
1.8.2	Argon-laser photocoagulation therapy .....	19
1.8.3	Anti-angiogenic therapy .....	19
1.8.4	Newer research .....	21
	Novel therapies in clinical trials for wet AMD .....	22

CHAPTER 2 .....	23
2.1. POTENTIAL USE OF TANSHINONE IIA IN WET AMD: .....	25
CHAPTER 3 .....	27
3.1. ABSTRACT: .....	27
3.2. INTRODUCTION:.....	29
3.3. MATERIALS.....	32
3.4. METHODS.....	33
3.4.1. Cell Culture.....	33
3.4.2. Preparation of Tanshinone IIA stock solution .....	34
3.4.3. Cytotoxicity assay.....	34
3.4.4. Effects of hypoxia on HIF-1 $\alpha$ . release and VEGF secretion.....	35
3.4.5. Enzyme-linked immunosorbent assay (ELISA) .....	35
3.4.6. Western Blot .....	36
3.4.7. Treatment of ARPE-19 with tanshinone IIA .....	37
3.5. RESULTS.....	37
3.5.1. Cytotoxicity assay.....	37
3.5.2. Effect of hypoxia on secretion of VEGF in ARPE-19 cells .....	42
3.5.3. Effect of hypoxia on HIF-1 $\alpha$ expression in ARPE-19 cells .....	43

3.5.4. Effect of Tanshinone IIA on expression of HIF-1 $\alpha$ and secretion of VEGF in hypoxic ARPE-19 cells .....	45
3.6. DISCUSSION.....	48
3.7. CONCLUSION.....	52
REFERENCES .....	53

## List of Figures

Figure 1: Anatomy of the eye .....	4
Figure 2: Anatomical structure of the retina .....	5
Figure 3: Pathogenesis of AMD .....	13
Figure 4: Amsler grid.....	17
Figure 5: Chemical structure of Tanshinone IIA .....	24
Figure 6: Viability of ARPE-19 cells after being exposed to various concentrations of Tanshinone IIA .....	39
Figure 7: Morphology of ARPE-19 cells after exposure to various concentrations of Tanshinone IIA for 24 hours.....	40
Figure 8: Viability of bovine corneal endothelial cells after being exposed to various concentrations of Tanshinone IIA for 24 hours. ....	41
Figure 9: Secretion of VEGF under normoxic and hypoxic conditions in ARPE-19 cells after exposure to different concentration of cobalt chloride.....	42
Figure 10: Immunoblot analysis showing the protein expression of HIF-1 $\alpha$ in ARPE-19 .....	43

Figure 11: The levels of HIF-1 $\alpha$  expression after application of different concentrations of cobalt chloride on ARPE-19 cells. .... 44

Figure 12: Immunoblot analysis showing the protein expression of HIF-1 $\alpha$  after being exposed to various concentrations of Tanshinone IIA..... 46

Figure 13: Effect of tanshinone IIA on the expression of HIF-1 $\alpha$  under hypoxic condition  
..... 47

Figure 14: Effect of tanshinone IIA on secretion of VEGF under hypoxic condition..... 47

# **Chapter 1**

## **Introduction**

### **1.1 Overview**

Age-related macular degeneration (AMD) is an acquired, irreversible and multifactorial neurodegenerative disease. AMD is characterized by progressive deterioration of retinal photoreceptors and retinal pigment epithelium (RPE) and thickening of Bruch's membrane (BM). AMD also affects choriocapillaris predominantly in the macular region of the retina, resulting in the loss of central vision [1-6]. In developed countries, AMD is the leading cause of central vision impairment in individuals over 50 years. AMD is known to affect nearly 10% of those older than 65 years, and more than 25% of those older than 75 years [1]. Based on 2010 statistics obtained from the National Eye Institute, the prevalence of AMD is higher in women (about 65%) when compared to men (about 35%). Also, a majority of AMD cases was observed among white Americans (89%) compared to the black and Hispanic populations (8%). From 2000-2010, the number of people in the United States diagnosed with AMD increased from 1.75 to 2.01 million,

and it is expected to rise by more than double (approximately 5.44 million) by the end of 2050 [7].

AMD is majorly categorized into two forms, oxidative (or wet or neovascular) AMD and non-oxidative (or dry or non-neovascular) AMD. The oxidative form of AMD is characterized by choroidal neovascularization (CNV) resulting in the growth of abnormal blood vessels from the choroid beneath the macula. These abnormal blood vessels leak fluids, lipids and blood into the retina eventually resulting in a fibrous scar, leading to permanent loss of central vision [8]. The non-oxidative AMD is characterized by the presence of yellow to yellowish-white nodular deposits called drusen [2]. This form does not lead to central vision loss, but has substantial functional limitations, including vision fluctuations, difficulty in reading and poor vision at night or reduced illumination conditions. It tends to progress at a slower rate when compared to oxidative AMD. However, in some cases it might be transformed into oxidative AMD, which is much more severe and aggressive [9-11]. Although the etiology of the disease is unknown [12], genetic variants, environmental and life-style factors are responsible for causing AMD. Genetic variants include positive family history, ethnic differences and mutations in genes responsible for causing AMD [13]. Environmental and lifestyle factors include cigarette smoking, low dietary intake of vitamin A, C, zinc, lutein and Omega-3 fatty acids [8]. Another important factor which causes AMD is oxidative stress mediated by reactive oxygen intermediates (ROIs). ROIs are usually the byproducts of oxygen metabolism, which include free radicals, hydrogen peroxide and singlet oxygen. The retina is highly susceptible to oxidative stress due to its high oxygen consumption, high



proportion of polyunsaturated fatty acids and its exposure to visible light. Research indicates that the hypoxic condition triggers neovascularization, eventually leading to the loss of central vision [14].

## **1.2 Anatomy of the eye**

The eye is composed of three main layers as shown in Figure 1. The fibrous layer forms the outer coat of the eye, which is composed of tough, fibrous sclera and the transparent, avascular cornea for focusing light. The layer next to fibrous layer is the vascular layer, which is composed of choroid layer, ciliary muscle and iris. The choroid layer contains dark pigment which prevents internal reflection of light. The ciliary muscle undergoes contractions making the lens more convex and aids in the process of focusing light onto the retina. The iris is the colored part of the eye, which contains sphincter papillae and dilator papillae smooth muscles. These help in regulating the amount of light entering the eye by altering pupil diameter and thereby protecting the sensitive cells of the retina. The innermost layer of the eye is known as the retina and is explained in detail in the later section [15, 16].

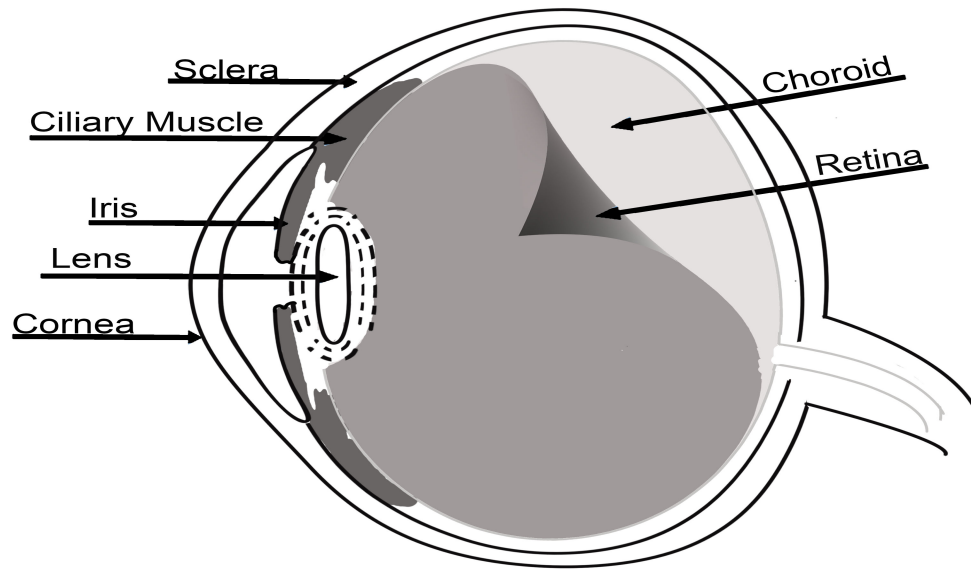


Figure 1: Anatomy of the eye

### ***1.2.1 Structure and anatomy of retina***

The retina is a thin layer of photoreceptor and neuronal cells found between the choroid layer and vitreous body (Fig. 2) [15]. It is mainly divided into two parts, optic and non-visual retina. The optic part is further subdivided into pigmented and neural layers. The pigmented layer consists of a sheet of melanin composed of cuboidal epithelial cells called the retinal pigment epithelium (RPE). RPE aids the choroid layer in ensuring visual activity by preventing light scattering [15] and melanin absorbs free radicals, thereby protecting the light sensitive structures of the retina. A decrease in melanin content with aging makes individuals more susceptible to short wave radiations and to the toxic effects of free radicals [17]. RPE and neural layers are adhered together by weak junctions which make them susceptible to detachment in conditions like trauma or disease [18]. The non-visual part of the retina is a continuation of the anterior part of the

pigmented epithelium layer and stretches over the ciliary body and posterior surface of the iris to the pupillary margin [15].

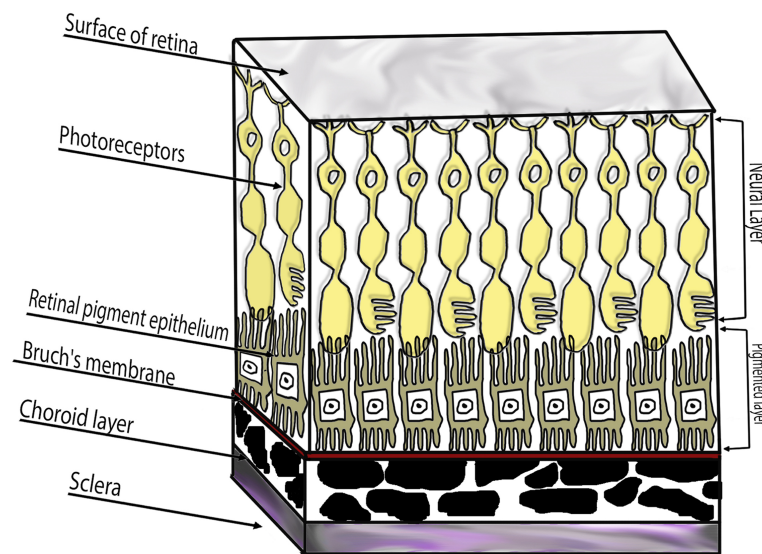


Figure 2: Anatomical structure of the retina

### ***1.2.2 Photoreceptors***

The photoreceptors are a type of neuron located in the posterior part of the retina. These cells are involved in photo transduction, i.e., absorb photons, convert light into electrical signals and simulate the transmission of nerve impulses by triggering a change in cell membrane potential. Photoreceptors are metabolically very active cells and consume high amount of oxygen per gram of tissue weight than any other cells in the body. The energy required is derived from their inner segments which are abundantly packed with

mitochondria [11]. In the human retina, there are two types of photoreceptors, rods and cones. The rod cells are narrower than cone cells and are extremely sensitive. They can be triggered even by a small number of photons and are solely responsible for scotopic vision. The cones on the other hand, are responsible for the photopic vision. In humans, three types of cones (red, green, and blue) are identified depending on their response to different wavelengths of light. [19-21]. The macula, an oval shaped pigmented area in the center of the retina, is made up of a cone dominated fovea and rod dominated parafovea [11]. Studies indicate that mitochondrial DNA deletion and cytochrome c oxidase-deficient cones accumulate with age. These changes occurring in the foveal region affect the macular function of individuals as observed in age related maculopathy (ARM) [22]. In AMD, more rods are affected compared to cones. Studies indicate that the integrity of RPE has a significant role in maintaining the number of photoreceptors. The research by Green et al., revealed that the thickness of the scar formed in AMD is directly related to the degeneration of photoreceptors. The thicker the scar, the greater is the distance between the photoreceptors and the nourishing choriocapillaris [23].

### ***1.2.3 Retinal Pigment Epithelium***

Just below the photoreceptors, lies the retinal pigment epithelium (RPE). The RPE is separated from the outer segment of photoreceptors by the subretinal space [24]. It performs a number of complex functions which are essential in maintaining and supporting optimal visual function. The RPE provides nutrients like omega-3 fatty acids and glucose to the outer segments of photoreceptors. They are involved in the transport of water, ions and metabolic end products from the subretinal space to the choroid layer [25]. It plays a major role in forming the blood-retinal barrier (BRB) which prevents the

diffusion of blood-borne substances from the choroid [26]. RPE cells phagocytose the mature outer segments of photoreceptors and thus serves as a part of the garbage disposal system [11]. Studies indicate that RPE is actively involved in wound healing and helps in building and sustenance of both choroid and photoreceptors by secreting different growth factors, including fibroblast growth factor (FGF-1, FGF-2, and FGF-5), transforming growth factor  $\beta$  (TGF- $\beta$ ), insulin-like growth factor-I (IGF-I), platelet-derived growth factor (PDGF), vascular endothelial growth factor (VEGF), lens epithelium-derived growth factor (LEDGF) and pigment epithelium-derived factor (PEDF) [11]. In AMD, RPE undergoes alterations, including pigmentation changes, reduction of melanosomes and cell density, and increase in oxidative stress and lipofuscin granules [27]. The number and the concentration of reactive oxygen species caused by oxidative stress contribute to the pathogenesis of AMD. Also, dysfunction of RPE leads to photoreceptor loss and consequently results in vision impairment [11].

#### ***1.2.4 Bruch's Membrane:***

Bruch's membrane (BM) is a stratified extracellular matrix, complex composed of connective tissue located between the RPE and the choriocapillaris [11]. The membrane consists of five layers (from inside to outside); basement membrane of the RPE (RPE BM), inner collagenous layer, central elastic layer, outer collagenous layer and finally the basement membrane of choriocapillaris. The components which make up the membrane include collagen I, III, IV, V, VI, fibronectin, laminin, heparin sulfate proteoglycans (HSPG) and chondroitin/dermatan sulphate. BM regulates the diffusion of nutrients and electrolytes from the choriocapillaris to the RPE and the removal of waste products from RPE to the choroid layer [28]. In addition, BM supports adhesion, differentiation and

migration of RPE cells. Structural or compositional alterations influence the diffusional properties and therefore affect the function of the RPE and outer retina [11]. Studies indicate that the nature of BM depends on individuals' age, genetics, exposure to the environmental risk factors, retinal location and disease condition. As the nature of BM is different in each individual, the progression of ocular disease is uniquely affected [29]. In AMD, BM gets thicker and harder and thickening is attributed to the accumulation of biomolecules, cross-linked collagen fibers and waste products of RPE metabolism [30]. The process of thickening, leads to several functional alterations, including the changes in elasticity and hydraulic permeability. Aging process decreases the hydraulic conductivity and increases the lipid content. Lower hydraulic conductivity indicates a decreased capacity for fluid exchange between RPE and choroid [11].

### ***1.2.5 Choriocapillaris (CC)***

Choriocapillaris is a layer of capillaries that lie adjacent and posterior to BM. The position of CC in the RPE/BM/CC complex permits it to provide the oxygen needed by the photoreceptors. Under dark conditions, the photoreceptors are almost hypoxic and any disruption in blood flow to the CC would be harmful for the photoreceptors. In AMD, the loss of CC results in ischemic RPE which in turn produces hypoxia-inducible angiogenic factors such as VEGF. VEGF stimulates the growth of CNV from CC, venules, arterioles through the BM that spreads under the RPE [11, 31].

## **1.3 Major Types of AMD**

### ***1.3.1 Neo-vascular AMD/Wet/Exudative***

AMD is the third primary cause of visual impairment in industrialized nations with 8.7%

blindness prevalence. Neovascular AMD accounts for 10% of AMD cases in the United States [32]. It is characterized by choroidal neovascularization, the growth of abnormal blood vessel in the choroidal layer beneath the macula. Also, the incompetent endothelial cells of the newer vasculature present fluid leakage and retinal hemorrhage. This results in the formation of subretinal disciform scars, which appear as white/yellow lesions causing distortion of vision and eventually leading to the permanent loss of central vision. However, a few patients do not experience any changes in spite of the onset of CNV [11]. It is divided into two types: Type I and Type II. Type I CNV is associated with sub-RPE space and presents as a fibrovascular detachment of the RPE. Type II CNV is associated with sub neurosensory retinal space and appears as grey-green lesions underneath the retina thereby increasing the thickness of the retina. These changes can be observed by stereoscopic biomicroscopy [33].

### ***1.3.2 Non-neovascular/Dry/Atrophic AMD***

Non-neovascular accounts for 90% of AMD cases and is characterized by the accumulation of drusen deposits, deterioration of RPE and functional loss of overlying photoreceptors. Different kinds of drusen have been identified in the retina, soft, hard, confluent, crystalline and basal laminar. Hard drusens are small ( $< 50 \mu\text{m}$ ) discrete, yellow nodular deposits occurring in the sub-RPE space. Soft drusens are pale yellow lesions with poorly defined edges and are further classified based on size as small ( $< 63 \mu\text{m}$ ), medium ( $63\text{-}125\mu\text{m}$ ) and large ( $> 125 \mu\text{m}$ ). With time, these drusen coalesce and form multiple irregular structures (confluent drusen) or undergo calcification to crystalline form (crystalline drusen). Basal laminar or cuticular drusen are tiny white deposits accumulated over the thickened Bruch's membrane [34]. Patients with non-

neovascular AMD generally do not lose central vision, but experience limitations of substantial function, including vision fluctuation, difficulty in reading and limited vision under conditions of reduced illumination [2].

## **1.4 Stages of AMD**

### ***1.4.1 Early AMD***

Early stage AMD is characterized by the presence of soft, indistinct and reticular drusen. It is associated with macular changes characterized by abnormalities in RPE [35]. In addition, patients start losing their ability to perform daily tasks such as driving, reading, and facial recognition [2].

### ***1.4.2 Late stages of Dry AMD (Geographic atrophy)***

Late stages are characterized by hemorrhage of pigment epithelium, loss of RPE and increased visualization of the choroid membrane. It is also associated with the presence of exudative CNV, consisting of blood and lipids that eventually results in RPE detachment.

## **1.5 Risk Factors**

Several risk factors which are responsible for the development and progression of AMD have been identified including age, hereditary, race and ethnicity. Aging is a predominant factor associated with the incidence, prevalence and progression of AMD [36-39]. The overall prevalence rate of different forms of AMD is about 9% among Americans who are in their 40's or older [40]. Genome-wide association studies (GWAS) indicate that variations in CFH, C3, C2-CFB, CFI, ARM2, CETP, TIMP3, LIPC, VEGFA, COL10A1,



TNFRSF10A is associated with an increased risk for AMD. AMD is more common in whites than in blacks [41]. Studies indicate that the prevalence of AMD is higher in whites (5.4%) followed by Chinese (4.6%), Hispanics (4.2%) and African Americans (2.4%) [42]. Research on human genome using DNA-sequence data showed that polymorphism (Tyr402His) in the complement factor H gene, located on chromosome 1 (1q31), significantly increases the risk of AMD in whites [42]. These studies suggest that one copy of Tyr402His polymorphism aggravates AMD by a factor of 2.1 to 4.6 and that two copies might increase the risk of AMD by a factor of 3.3 to 7.7. There are certain modifiable lifestyle risk factors for AMD including smoking [43], obesity, hypertension, high dietary intake of fats and low intake of anti-oxidants [44, 45]. It's been reported that smokers, both active and passive, are twice as prone to wet AMD when compared to non-smokers [43]. Other minor (secondary) risk factors associated with AMD include arteriolar sclerosis, angina, stroke and heart attack [2].

## **1.6 Pathogeneses**

The neo-vascular AMD, also known as wet AMD, is characterized by the formation of subretinal choroidal neovascularization (CNV) and is the main cause of vision loss among elderly [8, 46]. CNV is a type of angiogenesis, which involves the process of formation of new blood vessels from the choroid into the subretinal pigment epithelium. It is an important pathogenic process in both benign and malignant diseases. Many markers can influence the process of CNV, which can either have a stimulatory or inhibitory effects. Stimulatory factors for CNV include VEGF, nitric oxide (NO), integrins:  $\alpha 5\beta 1$ ,  $\alpha v\beta 3$  and  $\alpha v\beta 5$ , transforming growth factor beta 1 (TGF $\beta$ 1) and its receptors growth factors: acidic fibroblast growth factor (aFGF), basic fibroblast growth

factor (bFGF), hepatocyte growth factor (HGF), insulin-like growth factor I (IGF-I), platelet-derived growth factor (PDGF), epidermal growth factor (EGF), hypoxia-inducible factor 1 alpha (HIF-1 $\alpha$ ), IL- 8, IL-1, prostaglandin (PGE 1, PGE 2, PGF), erythropoietin, histamine, bradykinin, tumor necrosis factor alpha (TNF $\alpha$ ). Proangiogenic factors including VEGF-A and Placental growth factor (PDGF) are constantly upregulated during the process of CNV.

Under normal conditions, the endothelial cells present in the retinal blood vessels, resist the neovascular stimuli, which results in decreased endothelial cell proliferation. This is due to the presence of balance between pro-angiogenic (VEGF) and anti-angiogenesis factors (PEGF). Disturbance of the balance stimulates the pro-angiogenic factor over anti-angiogenesis leads to CNV [47-49]. The pathogenesis of AMD can be explained by HIF-1 $\alpha$  regulated and inflammatory mediated pathways (Figure 3).

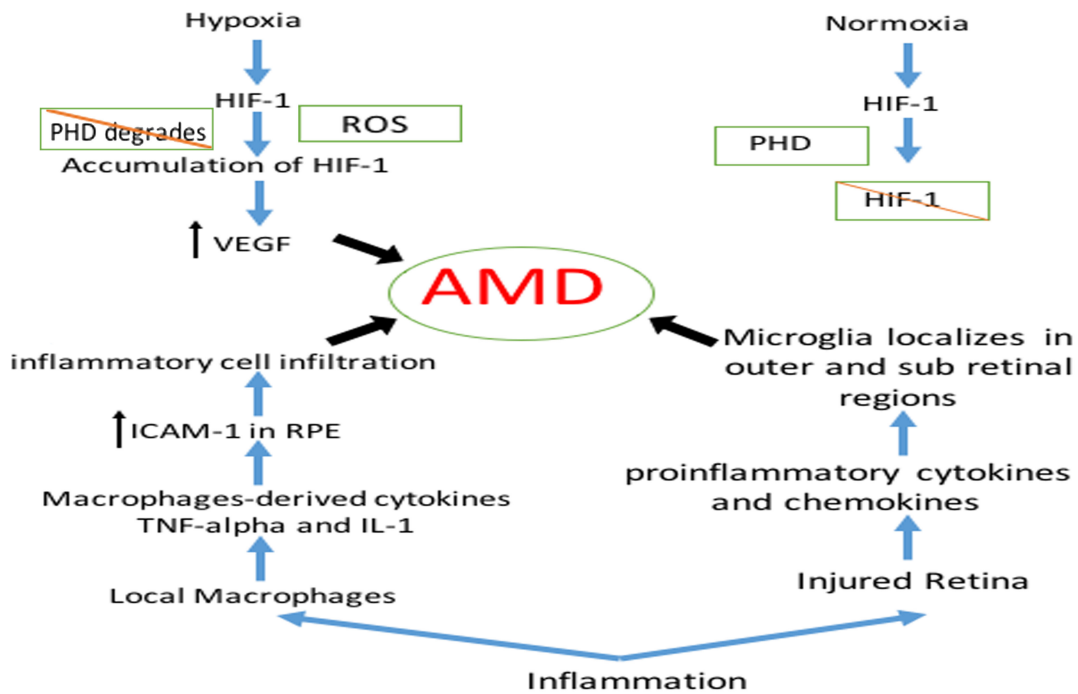


Figure 3: Pathogenesis of AMD

### 1.6.1 HIF-1 $\alpha$ regulated AMD

HIF is an oxygen dependent transcription factor. Studies indicate that hypoxia initiates HIF-1 which further induces the transcription of more than 70 genes. This in turn mediates angiogenesis, cell proliferation/survival and glucose/iron metabolism [50, 51]. HIF has a heterodimeric structure composed of an oxygen labile  $\alpha$  subunit and a stable  $\beta$  subunit. Three different isoforms of the  $\alpha$  subunit exist, the HIF-1 $\alpha$  being most widely studied. Oxygen plays a significant role in the stability of HIF-1 $\alpha$ . Under normoxic conditions, HIF-1 $\alpha$  is hydroxylated by proline hydroxylase enzyme (PHD), which results in degradation of HIF-1 $\alpha$ . In hypoxic conditions, the hydrolysis of proline residues are inhibited, therefore, HIF-1 $\alpha$  escapes degradation and gets accumulated in the cytoplasm

[51]. Accumulated HIF-1 $\alpha$  translocates to the nucleus and acts as a regulator of transcription for VEGF. VEGF plays an important role in the formation of new blood vessels and also increases vascular hyper permeability. It is involved in several components of angiogenesis including endothelial cell proliferation, survival and migration [52].

In AMD, age related changes in various structures such as RPE cells, Bruch's membrane and choriocapillaris, leads to oxygen deficiency in the rods and cones of the neural retina. Therefore, hypoxia is one of the driving factors for neovascularization which eventually results in the overexpression of VEGF [53]. Another factor involved in increasing the expression of VEGF is the level of reactive oxygen species (ROS). High levels of ROS including free radicals, singlet oxygen, hydrogen peroxide increase the accumulation of HIF-1 $\alpha$ , thereby increasing VEGF [54]. The resulting ROS causes damage to the lysosomal membranes of the senescent RPE cells, which decreases their ability to remove the metabolites released from rods and cones. This usually results in the accumulation of a granular pigment called, lipofuscin [9]. A higher level of lipofuscin increases the phagocytic and metabolic load on the macular RPE, which causes damage to the photoreceptors [55]. Many fluorophores were isolated from lipofuscin. Pyridinium bisretinoid A2E is one of the fluorophores, that is associated with the induction of undesirable effects, including apoptosis in RPE cells, inhibition of essential lysosomal transporters, phagocytosis, loss of membrane integrity, disruption of mitochondrial function, activation of complement pathways and oxidative stress. Based on the clinical correlation between the progression of dry AMD and accumulation of A2E, inhibition of

A2E production seems to be a potential treatment strategy for AMD [56]. Current research is focused on determining ways to inhibit transcriptional HIF-1 $\alpha$  which leads to the down regulation of VEGF expression and consequently inhibits the occurrence of choroid neovascularization [51, 57].

### ***1.6.2 Inflammation mediated AMD***

AMD is not considered a classic inflammatory disease, but inflammation has a significant role in pathogenesis and progression of AMD. Studies indicate that innate immunity and autoimmune components like complement factor, chemokines, cytokines, macrophages, and microglia are strongly associated in the development of AMD. It has been reported that macrophages and giant cells localize near drusen deposits in the CNV membrane and at the breakdown of Bruch's membrane. Macrophages-derived cytokines TNF- $\alpha$  and IL-1 are found to induce the expression of intracellular adhesion molecule-1 (ICAM-1) in RPE and vascular endothelial cells, thereby inducing additional inflammatory cell infiltration. Macrophages also induce proliferation and migration of endothelial cells by cytokines, which hastens the process of angiogenesis and CNV [58]. In addition, microglial cells of the retina are also involved in the pathogenesis of AMD. The main role of microglial cells is phagocytosis. Under conditions of retinal injury and degeneration, these cells are activated and localize in outer and sub retinal regions. Activated microglial cells produce various proinflammatory cytokines and chemokines, which create neurotoxic environment resulting in AMD [59].

### **1.7 Diagnosis**

Routine eye examination might help in discovering the early signs of AMD, which

increases the opportunity of having better management. Patients with unilateral exudative and non-exudative AMD in either one or both eyes generally do not present any complaints and may be detected in a routine eye examination. Symptomatic patients with dry AMD present symptoms of blurred vision that requires magnifying lenses or brighter light conditions to help them with their daily activities. Vision loss might be more severe in patients with advanced dry AMD. Patients experience difficulty in reading an entire line of small print or entire letter of a large print because of the central and paracentral scotomas. Significant influence on daily activities, especially in low light conditions is generally observed. On the other hand, patients with wet AMD patients present distorted vision with wavy lines, rapid onset of vision loss, central or paraentral scotomas or they might not notice any changes [60-62].

### ***1.7.1 Amsler Grid***

Amsler Grid is a diagnostic tool used by ophthalmologists to detect any problems resulting from damage to the macula, as seen in AMD or other eye diseases. This test can be self-administered by patients and does not need a clinical setting. The grid should be kept at the same distance as any other reading material. The dot present at the center of the grid should be focused upon, using one of the eyes. The test needs to be done for both eyes and the lines should appear straight. All intersections should form right angles and all the squares should be identical in size. Any irregularity should be reported to the ophthalmologist immediately [63].




Figure 4: Amsler grid

Adapted from “Amsler Grid: Test for Macular Degeneration or Other Vision Problems,” by L. Segre, 2014, Retrieved from <http://www.allaboutvision.com/conditions/amsler-grid.htm>

### ***1.7.2 Optical coherent tomography (OCT)***

OCT is a new diagnostic imaging technique that produces cross-sectional images of the eye, similar to the ones obtained using ultrasound. It is a non-contact, noninvasive technique that produces higher resolution in the posterior part of the eye [64]. In addition, the success of OCT in imaging the anterior [65] and posterior [66] segments of the human eye is well established. Studies proved that OCT has the capability of evaluating vitreoretinal interface, quantifying retinal thickness in macular edema and subretinal fluid accumulation and measuring retinal nerve fiber layer thickness in patients with a variety of muscular diseases and glaucoma [64]. Hee et al. studied the use of OCT for imaging eyes in patients with exudative and non-exudative AMD. They found that OCT was

successful in assessing and monitoring CNV before and after laser photocoagulation; however, it was unable to detect CNV beneath pigment epithelial detachment [64].

### ***1.7.3 Fundus Fluorescein Angiography (FFA) and Indocyanine Green (ICG):***

Fundus Fluorescein Angiography and Indocyanine Green tests involve the use of non-radioactive dyes, fluorescein and Indocyanine Green. After the pupils are dilated using eye drops, the dyes are usually injected into the vein of the patient's arm. The dye, then circulates in the blood stream and reaches the blood vessels in the eye. Photographs of the retina and choroid blood vessels are taken and any case of abnormality can be easily detected from the pictures. FFA works best in examining any abnormalities in the retina blood vessel, but in some occasions does not visualize the choroidal blood vessels properly. Therefore, ICG is used in conjunction with or without FFA to visualize choroid blood vessels [67, 68].



## **1.8 Management of AMD**

### ***1.8.1 Ocular Photodynamic Therapy (OPT)***

Ocular photodynamic therapy is another type of antiangiogenic treatment which involves the administration of photosensitive dye verteporfin (Visudyne, Novartis) and is activated by 689 nm laser beam. This dye, then accumulates in the newer blood vessels and causes a photochemical reaction that result in localized choroid neovascular thrombosis.

However, this therapy is less efficacious as monotherapy and showed infrequent side effects such as extravasation of the dye at the injection site, photosensitivity and back pain [42].

### ***1.8.2 Argon-laser photocoagulation therapy***

Argon-laser photocoagulation therapy is another method used for managing choroidal neovascularity stretched over more than 200 $\mu$ m from the center of the macula. This is therapy is used less commonly as it can create large retinal scars, which results in permanent visual loss [42].

### ***1.8.3 Anti-angiogenic therapy***

Intravitreal anti-angiogenic therapy is currently the primary therapy for wet AMD. The localized treatment provides an advantage of bypassing systemic circulation and thereby preventing systemic side effects of anti-angiogenic agents. However, these intravitreal injections on rare occasions present serious adverse effects, including endophthalmitis, retinal detachment, intra-ocular hemorrhage, increased intraocular pressure and

anaphylaxis [69]. On the other hand, systemic anti-VEGF therapies are associated with serious side effects such as thromboembolic events and death [70]. The first intravitreal agent approved by FDA is pegaptanib sodium (Macugen, OSI Pharmaceuticals). It binds to the 165 isoform of VEGF and thereby inhibits CNV. However, it is no longer used due to limited visual improvement in patients with neovascular AMD [71]. Currently, intravitreal ranibizumab (Lucentis<sup>®</sup>, Genentech) and bevacizumab (Avastin<sup>®</sup>, Genentech) are the most commonly used anti-angiogenic agents. Ranibizumab, a humanized monoclonal antibody acts by inhibiting the VEGF activity. A clinical trial conducted on 240 patients showed an improved vision rate of 90% with 0.5 mg of ranibizumab administered every 28 days [72]. No severe ocular side effects have been reported with ranibizumab, but on rare occasions causes endophthalmitis and uveitis [73]. Bevacizumab is another monoclonal antibody that binds to various isoforms of VEGF. It is primarily used as an anticancer agent, but has also shown to be significant in treating wet AMD. Studies indicate that intravitreal bevacizumab used at a dose of 1.25 mg every 28 days [72] presented a significant improvement in visual acuity comparable to that of ranibizumab [74, 75]. A single intravitreal dose of ranibizumab costs around \$1950 when compared to \$30 for bevacizumab. Off-label use of bevacizumab in treating neovascular AMD continues to grow because of the cost difference in comparison to ranibizumab. The comparative efficacy of these two drugs has been studied in a multicenter, randomized trial in 1208 wet AMD patients for 1 year. Both of the drugs showed a similar improvement in visual activity [72]. Another recently approved drug for treating wet AMD is Aflibercept (Regeneron/Bayer). It is an engineered protein that acts by binding and inhibiting VEGF. Clinical trials showed a comparable efficacy between

aflibercept and ranibizumab in stabilizing vision over one year [8]. The recommended dose of Aflibercept<sup>®</sup> is 2 mg monthly for the first 3 months, followed by 2 mg once every 2 months [76].

#### ***1.8.4 Newer research***

Newer screening methods for detecting AMD are currently under development. Recently, an automated detection system from the signs of retinal photographs for AMD was tested. The method proved to be sensitive with a specificity rate of 75% [8]. A focus on improvising anti-VEGF treatment protocols are being done to reduce the frequency of intravitreal injections. Another approach to target a multifactorial disease like wet AMD would be combination therapy. However, recent studies indicate that the combination of photodynamic therapy with ranibizumab could only result in minor visual improvements [8]. Topical therapy for treating wet AMD is underway. Pazopanib, a tyrosine kinase inhibitor, is currently used as oral anti-angiogenic drug for renal cell cancer. Phase 2 trials of pazopanib showed an improvement in the visual acuity in neovascular patients after 29 days of topical application [77]. OT-551 is another topical agent that acts by targeting NF- $\kappa$ B pathway and thereby inhibiting angiogenesis. Phase 2 trials with topical OT-551 showed moderate improvement in visual stabilization in geographic atrophy [78]. Radiation therapy is another area that is being investigated. Low dose of radiation usually targets the rapidly dividing cells of vascular endothelium in the neovascular complex. The major limitation with the use of radiation therapy is radiation retinopathy. Recently, radiation therapy using epiretinal strontium-90 has been tested in 19 wet AMD patients. After 3 years of treatment, 90% of the patients' experienced visual stabilization and improvement in their visual acuity with no adverse radiation related events[8].

Novel therapies in clinical trials for wet AMD

<b>Drug</b>	<b>Dosage Form/route of administration</b>	<b>Clinical Trial Phase</b>	<b>Mode of action</b>	<b>Purpose</b>	<b>Ref.</b>
Pegpleranib sodium (Fovista™)	Intravitreal injection	Phase III	Blocks platelet derived growth factor (PDGF)	Evaluating the use of Fovista™ in combination with other anti-VEGF agent in treating wet AMD.	[79]
Squalamine (OHR-102)	Eye Drops	Phase III	Anti-angiogenic agent that inhibits multiple growth factors and pathways implicated during the process of angiogenic process, including VEGF, PDGF, and basic fibroblast growth factor (bFGF).	Evaluating the efficacy of Squalamine in treating wet AMD	[80]
X-82	Pills	Phase II	Targets and inhibit growth factors, including, VEGF and PDGF	Evaluating the efficacy of X-82 in treating wet AMD	[81]
PAN-90806	Eye drops	Phase I	Selectively targets and inhibit VEGF	Evaluating the efficacy of PAN-90806 in treating wet AMD, diabetic retinopathy, and DME.	[82]
RO6867461	Intravitreal injection	Phase II	Acts by specific anti-VEGF and anti-angiopoietin-2 properties	Evaluating the efficacy of RO6867461 in treating wet AMD	[83]
REGN2176-3	Intravitreal injection	Phase II	Acts by inhibiting VEGF and PDGFRβ	Evaluating the efficacy of REGN2176-3 in treating newly diagnosed wet AMD	[84]
PF-655 (REDD14NP or RTP801i)	Intravitreal injection	Phase I/IIa	Modified siRNA that inhibits the expression of hypoxia-inducible factor 1-responsive gene, RTP801.	Evaluating the use of PF-655 in treating CNV and DME	[85]

## **Chapter 2**

### **Tanshinone IIA**

Tanshinone IIA is an active compound isolated from *Salvia miltiorrhiza*. Recent studies indicate the use of Tanshinone IIA in treating cancer [86]. The antitumor activity of Tanshinone IIA includes: increasing apoptosis in advanced cervix carcinoma (CaSki) cells; suppressing the formation of new blood vessels in human colorectal cancer; and inhibition of epidermal growth factor in hepatocellular carcinoma cell and suppressing Sat3 in breast cancer [87]. Tanshinone IIA has also been widely used for various cardiovascular and cerebrovascular disorders and recognized as a natural monoacylglycerol lipase inhibitor with an IC50 value of 48 nM [88]. However, Tanshinone IIA has low bioavailability due of its poor water solubility.

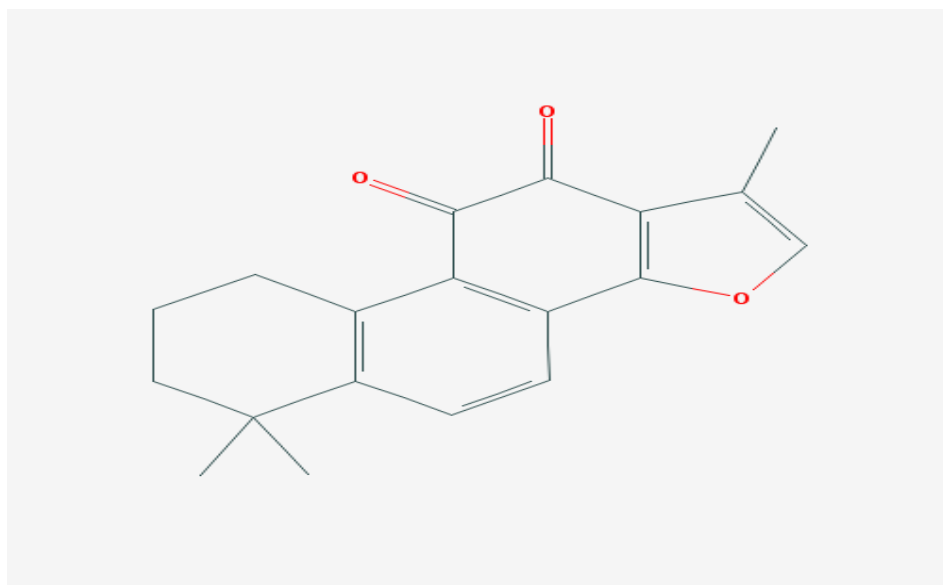


Figure 5: Chemical structure of Tanshinone IIA (PubChem CID: 1646)

### **2.1. Potential use of Tanshinone IIA in wet AMD:**

Vascular endothelial growth factor (VEGF) plays an important role in the angiogenesis process and is one of the major pathways resulting in AMD. The expression of VEGF is mainly regulated by HIF-1 $\alpha$ . A drug that has the ability to inhibit this process might be successful in treating various retinal diseases that involves neovascularization [89]. The drugs currently available in the market for treating wet AMD include Ranibizumab<sup>®</sup>, Bevacizumab<sup>®</sup> and Aflibercept<sup>®</sup>. These anti-VEGF agents target and inhibit VEGF and thus prevent angiogenesis. Nevertheless, delivery of these drugs to the posterior eye is challenging, as wet AMD treatment requires delivery of drugs to the choroid and retina, which are relatively inaccessible to conventional eye drops. Currently, these drugs are administered via implants and intravitreal injections, which are highly invasive and associated with patient non-compliance.

In an attempt to enhance patient compliance, the focus of research has shifted to the development of novel small molecules that could be delivered via less invasive (periocular administration) or non-invasive (topical administration) routes. The current work intends to study the effect of Tanshinone IIA in reducing the expression of VEGF and HIF-1 $\alpha$  in human retinal epithelial (ARPE-19) cells. We hypothesize that Tanshinone IIA might be a potential candidate for treating AMD based on the recent literature demonstrating the ability of Tanshinone IIA in down regulating both VEGF and HIF-1 $\alpha$  in various cancer cell lines [90]. In this work, we tested the cytotoxicity of

Tanshinone IIA in human retinal epithelial cells (ARPE-19) and corneal endothelial cells by MTT assay. The effect of Tanshinone IIA in reducing the expression of VEGF and HIF-1 $\alpha$  was studied using Western blot and ELISA. To our knowledge, this is the first evidence that demonstrates the ability of Tanshinone IIA in treating wet AMD. Further studies are being conducted to design a topical eye drop formulation of Tanshinone IIA for treating wet AMD.



## Chapter 3

### **Tanshinone IIA Inhibits VEGF Secretion and HIF-1 $\alpha$ Expression in Cultured Human Retinal Pigment Epithelial Cells under Hypoxia**

#### **3.1. Abstract:**

**Purpose:** The current work intends to study the activity of tanshinone IIA on secretion of VEGF and expression of HIF-1 $\alpha$  in human retinal pigment epithelial cells (ARPE-19 cells) under hypoxic condition.

**Methods:** The cytotoxicity of Tanshinone IIA was tested in ARPE-19 and bovine corneal endothelial cells by MTT assay. ARPE-19 cells were incubated with different concentrations of cobalt chloride (100, 150, and 200  $\mu$ M) for 12 hours and levels of expressed HIF-1 $\alpha$  and secreted VEGF were quantified through Western blot and ELISA, respectively. Further, ARPE-19 cells were pretreated for one hour with different concentrations of Tanshinone IIA (5, 10, 15 and 18  $\mu$ M). After one hour, the cells were subjected to hypoxic condition using 150  $\mu$ M cobalt chloride for 12 hours in the presence and absence of Tanshinone IIA. The cells were then harvested and the secreted VEGF and expressed HIF-1 $\alpha$  was studied.

**Results:** Tanshinone IIA at concentrations 5, 10, 15 and 18  $\mu\text{M}$  did not show cytotoxicity in both ARPE-19 and bovine corneal endothelial cells. Chemical hypoxia induced by cobalt chloride caused a significant increase in VEGF level in a dose dependent manner and HIF-1 $\alpha$  expression peaked at 150  $\mu\text{M}$ . Based on the data, cobalt chloride concentration was maintained at 150  $\mu\text{M}$  for further studies. Tanshinone IIA decreased the level of HIF-1 $\alpha$  and VEGF secretion in a dose dependent manner under hypoxic condition.

**Conclusion:** This study is the first report on the effects of Tanshinone IIA on VEGF secretion and HIF-1 $\alpha$  level in ARPE-19 cells. Tanshinone IIA could be a potential new treatment option for wet AMD.

### **3.2.Introduction:**

Age-related macular degeneration (AMD) is an acquired, irreversible, multifactorial neurodegenerative disease characterized by progressive deterioration of retinal photoreceptors and retinal pigment epithelium (RPE) and thickening of Bruch's membrane (BM). AMD also affects choriocapillaris predominantly in the macular region of the retina, resulting in the loss of central vision [1-6]. It has been reported that AMD is the main cause of central vision loss in individuals over 50 years in developed countries. The percentage of affected people with AMD is 10% of those older than 65 years and more than 25% of those older than 75 years [1]. Based on 2010 statistics obtained from the National Eye Institute, the prevalence of AMD is higher in women (65%) when compared to men (35%). Also, a majority of AMD cases was observed among the white Americans (89%) compared to the black and Hispanic populations (8%). According to statistical studies from 2000-2010, the number of people in the United States diagnosed with AMD increased from 1.75 to 2.01 million, and it is expected to rise by more than double (approximately 5.44 million) by the end of 2050 [7].

The etiology of the AMD is unknown [12], however, genetic variants, environmental and life-style factors are responsible for causing this disease. Wet AMD is the severe form of AMD, which is characterized by choroidal neovascularization (CNV) resulting in the growth of abnormal blood vessels from the choroid beneath the macula. The abnormal growth of blood vessels leaks fluids, lipids and blood into the retina eventually resulting in a fibrous scar, leading to permanent loss of central vision [8]. The retina is considered as the most metabolically active tissue that consumes more oxygen compared to the other

body tissues by weight [91]. Therefore, a deficiency in oxygen level plays a major role in angiogenesis that cause most of sight threatening diseases such as diabetic retinopathy (DR) and AMD [92, 93].

HIF is an oxygen dependent transcription factor. It has been reported in many studies that hypoxia initiates HIF-1 $\alpha$  which further induces the transcription of more than 70 genes that mediate angiogenesis, cell proliferation/survival and glucose/iron metabolism [50, 51]. Oxygen is the predominant controller of HIF-1 $\alpha$  stability. Under normoxic conditions, HIF-1 $\alpha$  is hydroxylated by a proline hydroxylase enzyme (PHD), which results in degradation of HIF-1 $\alpha$ . Under hypoxic conditions, the hydrolysis of proline residues are inhibited, therefore, HIF-1 $\alpha$  does not degrade and gets accumulated in the cytoplasm [51]. Accumulated HIF-1 $\alpha$  translocates to the nucleus and acts as a regulator of transcription for VEGF. Studies indicate that VEGF is a predominant protein that promotes the formation of new blood vessels [94] and also increases vascular hyper permeability [52]. In AMD, age related changes in RPE cells, Bruch's membrane and choriocapillaris, leads to oxygen deficiency in the rods and cones of the neural retina. Therefore, hypoxia is one of the driving factors for neovascularization which eventually results in the overexpression of VEGF [53].

Tanshinone IIA is a popular drug used in China for treating cardiovascular diseases, and it has successfully completed a phase II clinical trial in the US (*ClinicalTrials.gov identifier* NCT00797953). Tanshinone IIA is well-known for its antioxidant [95], anti-angiogenic [95], and anti-inflammatory [96] properties. It exhibits its antioxidant

property by inhibiting the association of lipid peroxidation products with DNA [95]. The anticancer activity of Tanshinone IIA has been tested on a variety of tumor cells, including vascular endothelial cells [97] leukemia [98], lung cancer [99], breast cancer [100], gastric cancer [101], prostate cancer [102], and liver cancer [103]. Although the anti-angiogenic mechanism of Tanshinone IIA is not fully understood, several characteristics of this drug such as the inhibition of VEGF, HIF-1 $\alpha$ , c-Myc, and angiogenic differentiation have been elucidated. Despite these interesting findings, the effect of Tanshinone IIA on treating wet AMD remains largely unknown.

The current work intends to study the effect of Tanshinone IIA in reducing the expression of VEGF and HIF-1 $\alpha$  in human retinal epithelial cells (ARPE-19). We hypothesized that Tanshinone IIA might be a potential candidate for treating wet AMD based on the recent literature demonstrating the ability of Tanshinone IIA in down regulating both VEGF and HIF-1 $\alpha$  in various cancer cell lines [90]. In this work, we tested the cytotoxicity of Tanshinone IIA in human retinal epithelial cells (ARPE-19) and corneal endothelial cells by MTT assay. The effect of Tanshinone IIA in reducing the secretion of VEGF and expression of HIF-1 $\alpha$  was studied using ELISA and Western Blot, respectively. To our knowledge, this is the first evidence which demonstrates the ability of Tanshinone IIA in treating wet AMD.

### 3.3. Materials

Tanshinone IIA (catalog #: sc-200932) was obtained from Santa Cruz (Dallas, TX), ARPE-19 cell line (ATCC<sup>®</sup> CRL-2302<sup>™</sup>) was obtained from American Type Culture Collection (Manassas, VA), Dulbecco's Modified Eagle Medium F-12 (1:1 mix) (DMEM/F-12) (catalog No. 12-719F) was obtained from Lonza (Atlanta, GA). Fetal Bovine Serum (lot #: FB-004) was obtained from Fisher scientific (Pittsburgh, PA), Penicillin/Streptomycin solution (lot #: J130006) was obtained from Hyclone, and 1X trypsin-EDTA (lot #: C2030) was obtained from MP Biomedicals (Santa Ana, CA). Hemocytometer (catalog # 0267110) was obtained from Fisher Scientific (Pittsburgh, PA). 6 well plates (catalog #: 657160), 60 mm plates (lot #: F141036T) and 96 well plates (catalog #: 657160) were procured from Fisher Scientific (Pittsburgh, PA). Greiner bio-one MTT cell proliferation assay kit (catalog #: 4890-25-01), was obtained from Trevigen, Dimethyl Sulfoxide (lot #: 100508) was obtained from Fisher Scientific (Pittsburgh, PA). Protease inhibitors cocktail (lot #: 095M4022V), sodium orthoandate (lot #: MKBP8646V), sodium pyrophosphate (Batch #: 020M0057), sodium fluoride (lot #: 089K0029), phenylmethylsulfonyl fluoride (PMSF) (lot #: BCBB3770), Igepal CA630 (NP-40) (I3021-50ML) were obtained from Sigma Aldrich (St. Louis, MO). Bio-Rad Protein Assay Dye Reagent concentrate (catalog #:5000006), 30% Acrylamide/Bis Solution 37.5:1 (catalog #: 161-0158), 4X Laemmli Sample Buffer (catalog #: 161-0747) were obtained from Bio Rad (Hercules, California). Immobilon-FL PVDF membrane Millipore (catalog # IPFL00010) was obtained from EMD, dry non-fat milk (Lot #

12037, Cat # M0841), was obtained from lab scientific. VEGF antibody (catalog #: sc-507) and HIF-1 $\alpha$  antibody (catalog #: H-206) were obtained from Santa Cruz (Dallas, TX). Clarity western ECL substrate (catalog #: 170-5060) was obtained from Bio Rad (Hercules, California) and Human VEGF Elisa Kit (lot #: 1610564A) was obtained from Invitrogen (Carlsbad, CA).

### **3.4.Methods**

#### **3.4.1. Cell Culture**

##### *Human Retinal Pigment Epithelial cells (ARPE-19 cells)*

Arising ARPE-19 cells were cultured in 1:1 mixture of DMEM/F-12 50/50 mixed with L-glutamine and 15 mM HEPES. The medium was also supplied with 10% fetal bovine serum, 100 U/ml penicillin and 100  $\mu$ g/ml streptomycin. The cells were cultured at 37°C with 5% CO<sub>2</sub>. The cells were subcultured every 3-5 days and the medium was changed 2-3 times a week.

##### *Bovine corneal endothelial cells*

Corneal endothelial cells were harvested from bovine eyes corneas that were obtained from Kastel's Slaughter House & Processing Center (Riga, MI). The corneal cells were harvested according to the protocol mentioned in MacCallum Lillie et al. [104] with some modifications. Briefly, the procured eyes were covered by Kim-wipes wetted with chlortetracycline (50  $\mu$ g/ml) for 15 minutes. The endothelial surface of the harvested corneas was covered with DMEM/F-12 for an hour. Then the medium was removed and the endothelial surface was covered by trypsin-EDTA and incubated for 5-10 minutes at 37°C in an incubator. The endothelial surface was gently rubbed with a cell culture

scraper to detach the endothelial cells. The harvested cells were centrifuged at 1500 rpm. Finally, the cells were plated in a 60mm petri dish. The medium was changed 2-3 times a week. The cells were confluent after almost a month.

#### ***3.4.2. Preparation of Tanshinone IIA stock solution***

Tanshinone IIA was dissolved in DMSO to produce a stock solution of concentration 10 mM. The stock solution was further diluted with a sterile cell culture medium to obtain concentrations of 5, 10, 15 and 18  $\mu$ M.

#### ***3.4.3. Cytotoxicity assay***

Cell viability was assessed in ARPE-19 and bovine corneal endothelial cells using the 3-(4,5-dimethyl-2-thiazolyl)-2,5-diphenyl-2H-tetrazolium bromide (MTT) assay. Briefly, cells were seeded in 96-well plates at a density of 10,000 cells/well and incubated at 37°C in a 5% CO<sub>2</sub> environment for 24 hours to assist cell attachment. Cells were then exposed to various concentrations of Tanshinone IIA with and without cobalt chloride (150  $\mu$ M) for 12 and 24 hours respectively. The medium was later aspirated and the cells were incubated with MTT reagent for 3 hours in 5% CO<sub>2</sub> at 37°C. The yellow medium was aspirated, and 150  $\mu$ l of 100% DMSO was added to each well to allow dissolution of the formazan salt formed. The viable cells were quantified by measuring the absorbance at 570 nm.



#### ***3.4.4. Effects of hypoxia on HIF-1 $\alpha$ release and VEGF secretion***

The levels of expressed HIF-1 $\alpha$  and secreted VEGF were quantified through Western blot and ELISA, respectively. The cells were incubated with different concentrations of cobalt chloride (100, 150, and 200  $\mu$ M) for 12 hours. The medium was collected and the secreted VEGF was quantified via ELISA and HIF-1 $\alpha$  expression was quantified using Western blot.

#### ***3.4.5. Enzyme-linked immunosorbent assay (ELISA)***

The amount of secreted VEGF into the medium after exposing ARPE-19 cells to hypoxic conditions was measured using a sandwich ELISA following the manufacturer's instructions. Briefly, the standard (100  $\mu$ l) and sample (50  $\mu$ l) were added to a 96 well plate pre-coated with a polyclonal antibody specific for human VEGF for 2 hours. Later, the used wells were washed four times with washing buffer to remove unbounded antigen, followed by the addition of 100  $\mu$ l of biotinylated Hu VEGF (Biotin Conjugate) solution for 1 hour. Excess biotinylated Hu VEGF was removed by washing for 4 times followed by the addition of 100  $\mu$ l streptavidin-HRP and incubation for 30 minutes followed by washing for 4 times. One hundred microliters of chromogen was added to each well and incubated for 30 minutes, followed by the addition of 100  $\mu$ l of stop solution (0.16M sulfuric acid). The level of Hu VEGF was quantified by measuring the absorbance at 450 nm using the Synergy H<sup>1</sup> plate spectrophotometer (Biotek®, VT)

### **3.4.6. Western Blot**

The cell extracts were obtained as described by Dimauro et al. [105] with some modifications. Briefly, after exposing ARPE-19 to hypoxic condition with and without Tanshinone IIA for 12 hours, cells were washed three times with PBS and harvested using ice-cold lysis buffer containing 20 mM HEPES (pH 7.5), 1.5 mM MgCl<sub>2</sub>, 10 mM KCl, 0.1 mM phenylmethylsulfonyl fluoride (PMSF), 50 mM NaF, 10 mM Na vanadate, 20 mM Na pyrophosphate and protease inhibitor. Cell homogenates were kept in ice for 15 minutes and vortexed every 5 minutes and then centrifuged at 14,000 rpm for 15 minutes. The supernatant was collected. Protein concentrations were quantified using Bradford reagent (Bio-Rad Laboratories, CA). The samples were boiled for 5 minutes and then the equivalent amount of protein (20µg/lane) was loaded in 12 % SDS polyacrylamide gels. The protein was then transferred to a polyvinylidene difluoride (PVDF) membrane. The membrane was kept for one hour in blocking buffer (1X PBS and 5% powdered dry non-fat milk) at room temperature followed by the addition of primary antibody, rabbit anti-HIF-1 $\alpha$  (1:500), and rabbit-anti GAPDH (1:2000) and kept overnight at 4°C. Later, the blots were washed and incubated with horseradish peroxidase (HRP) conjugated with a goat anti-rabbit secondary antibody (1:2000) (Jackson ImmunoResearch, PA) for one hour at room temperature. Protein levels were quantified by using a ChemiDoc XRS chemiluminescence (Bio Rad, CA).

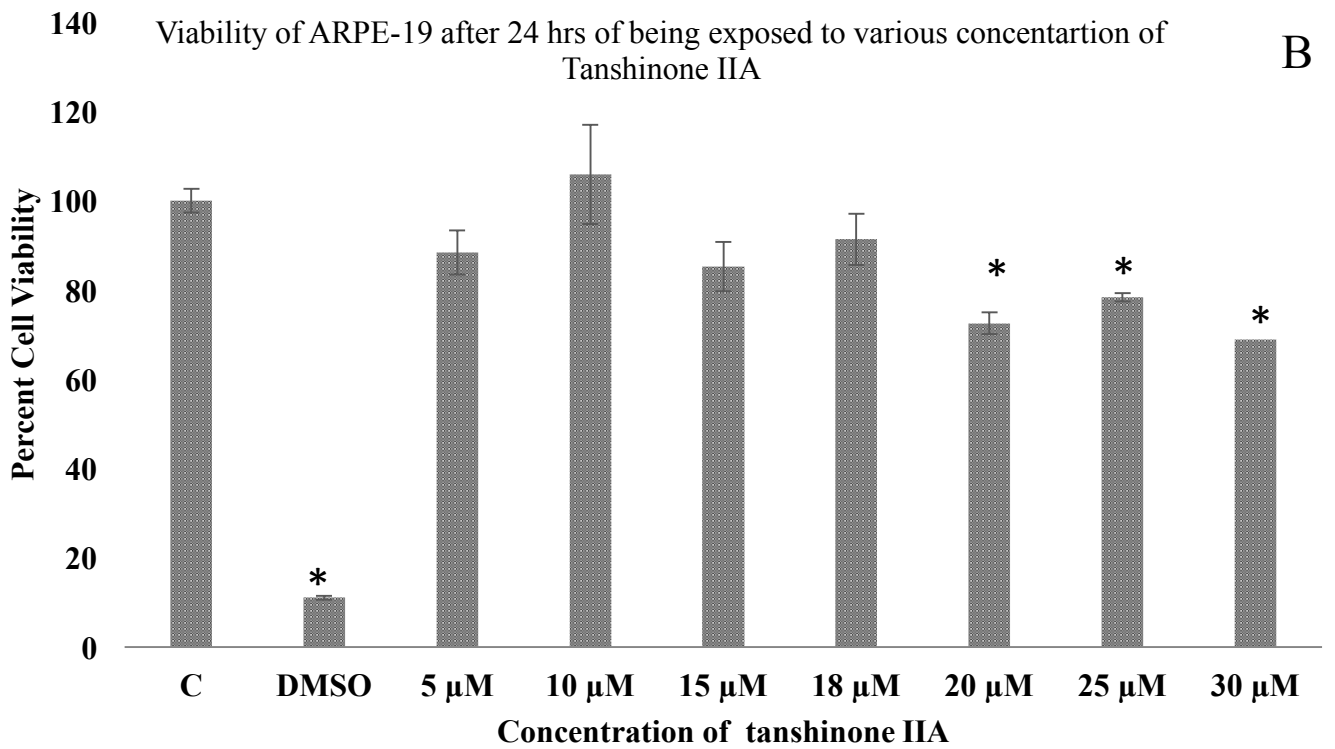
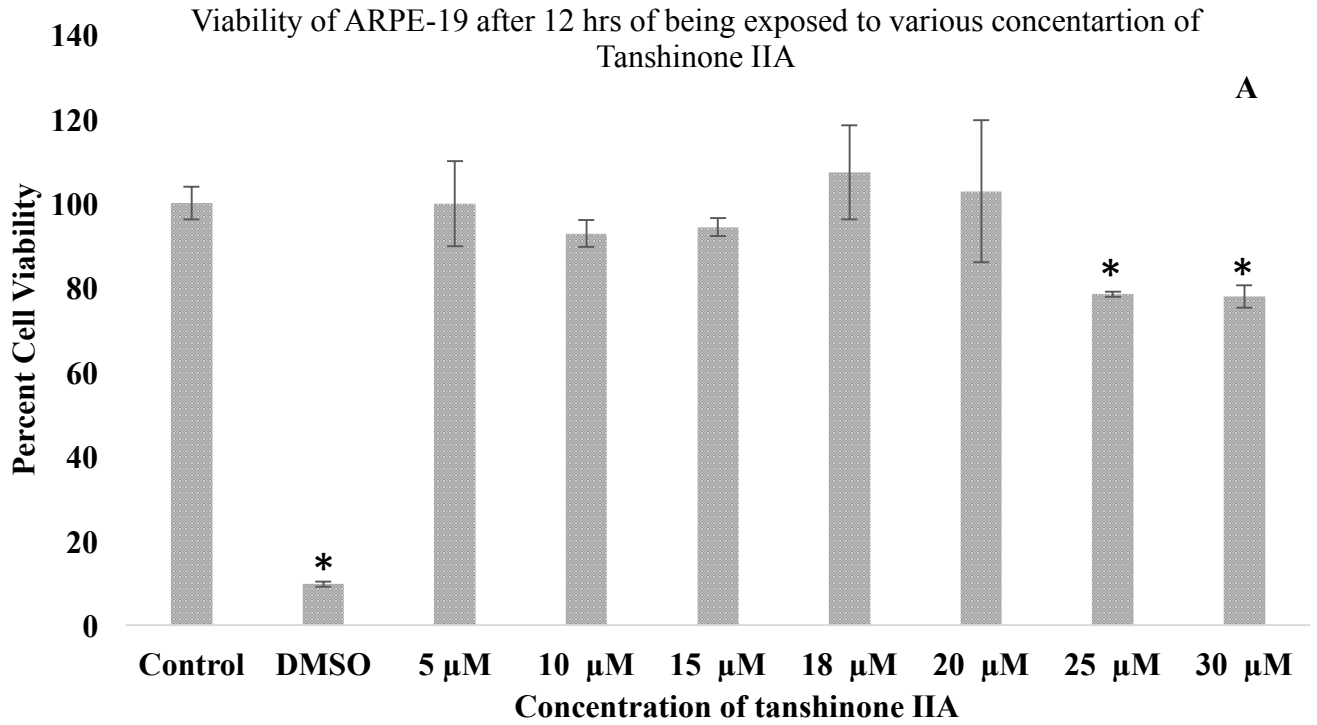
### ***3.4.7. Treatment of ARPE-19 with tanshinone IIA***

ARPE-19 cells were pretreated for one hour with different concentration of Tanshinone IIA (5, 10, 15 and 18  $\mu\text{M}$ ). After one hour, the cells were subjected to normoxic condition and hypoxic condition using 150  $\mu\text{M}$  cobalt chloride for 12 hours in the presence and absence of Tanshinone IIA. The cells were then harvested and the secreted and expressed protein was studied using Western blot and ELISA.

## **3.5. Results**

### ***3.5.1. Cytotoxicity assay***

The MTT assay was carried out to examine the possible cytotoxicity of Tanshinone IIA on bovine corneal endothelial cells and ARPE-19. The cytotoxicity of a wide range of Tanshinone IIA concentrations (5, 10, 15, 18, 20, 25 and 30  $\mu\text{M}$ ) were tested with and without cobalt chloride for 12 and 24 hours respectively. After 12 hours of incubation, the concentrations 25 and 30  $\mu\text{M}$  were found to significantly ( $P < 0.05$ ) cytotoxic in ARPE-19 cells (Fig. 6A and 6B) and 20  $\mu\text{M}$  showed cytotoxicity after 24 hours. Lower drug concentrations such as 5, 10, 15 and 18  $\mu\text{M}$  did not show any cytotoxicity in ARPE-19 cells for up to 24 hours and the morphology of remained same after the incubation period (Fig. 7). Similar results were obtained in bovine corneal endothelial cells for 24 hours and concentrations above 20  $\mu\text{M}$  were found to be cytotoxic ( $P < 0.05$ ) as shown in figure 8. Tanshinone IIA concentration less than 20  $\mu\text{M}$  was used in further studies.



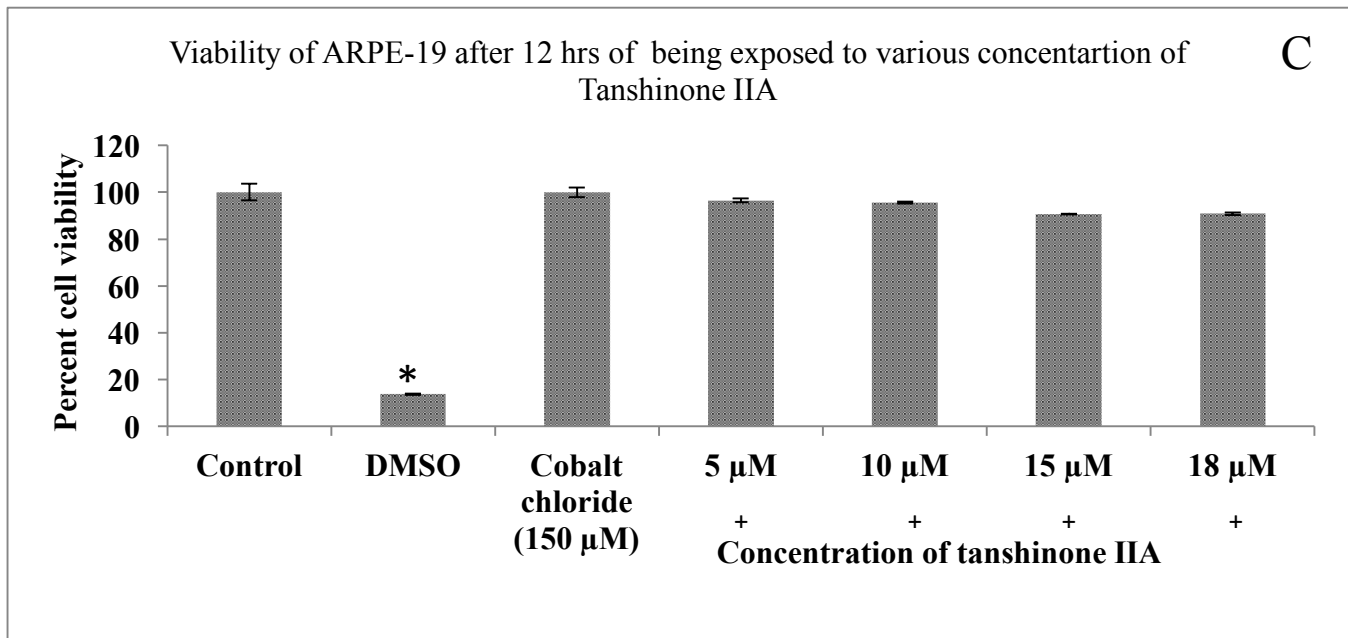


Figure 6: Viability of ARPE-19 cells after exposure to various concentrations of Tanshinone IIA. (A) After 12 hours of exposure, (B) After 24 hours of exposure, (C) After 12 hours in the presence of cobalt chloride (150 μM). Data are expressed as mean ± standard error of the mean (SEM). n=3, \*P < 0.05,




Figure 7: Morphology of ARPE-19 cells after exposure to various concentrations of Tanshinone IIA for 24 hours.

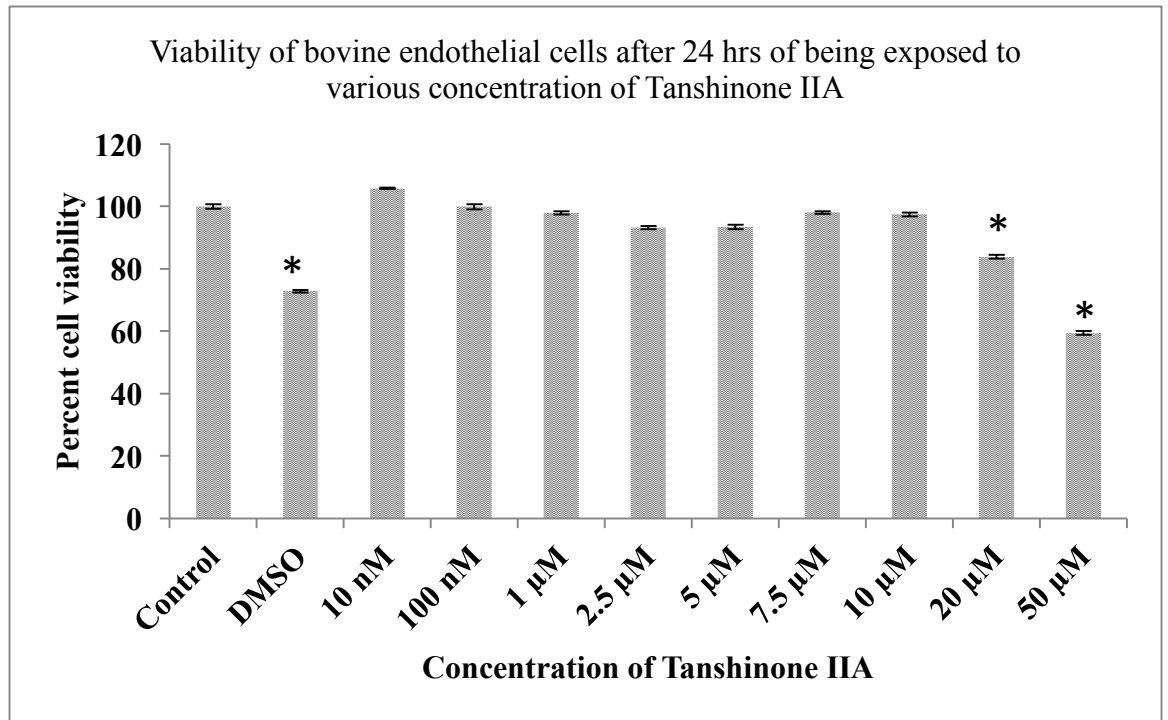


Figure 8: Viability of bovine corneal endothelial cells after being exposed to various concentrations of Tanshinone IIA for 24 hours. Data are expressed as mean  $\pm$  standard error of the mean (SEM). n=3, \*P < 0.05.

### 3.5.2. Effect of hypoxia on secretion of VEGF in ARPE-19 cells

Secretion of VEGF in ARPE-19 cells under normoxia and hypoxia was studied using ELISA. Chemical hypoxia induced by cobalt chloride at concentrations of 100, 150 and 200  $\mu\text{M}$  caused a significant increase in VEGF level in a dose dependent manner ( $P = 0.039, 0.021$  and  $0.012$ , respectively). The highest secretion of VEGF was at 200  $\mu\text{M}$  of cobalt chloride which was 1.9 folds compared to normoxic cells (Figure 9).

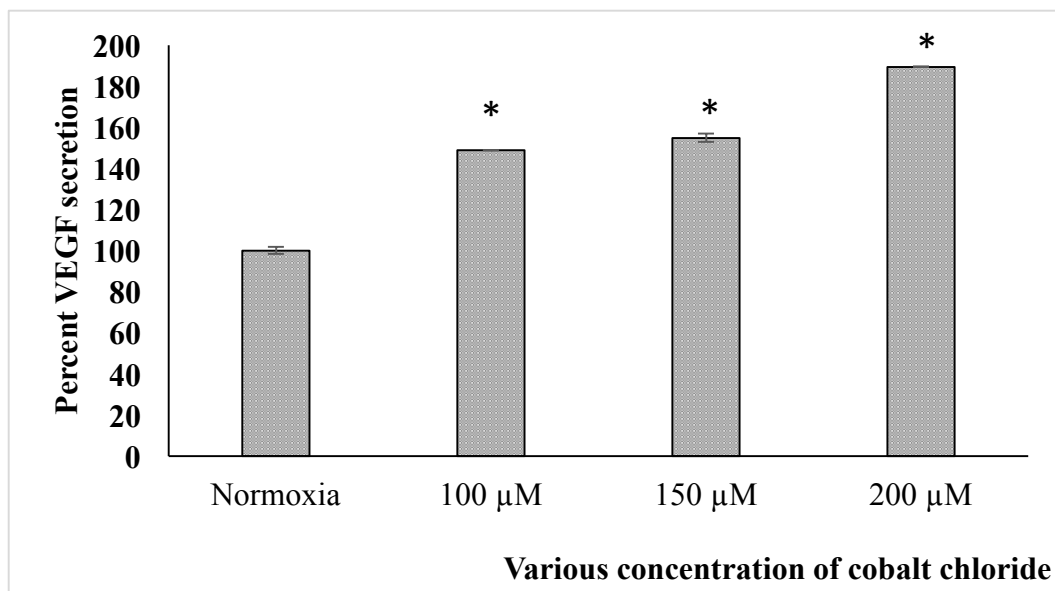


Figure 9: Secretion of VEGF under normoxic and hypoxic conditions in ARPE-19 cells after exposure to different concentration of cobalt chloride. Data expressed as mean  $\pm$  standard error of the mean (SEM), (n=2). \* $P < 0.05$ .



### 3.5.3. Effect of hypoxia on HIF-1 $\alpha$ expression in ARPE-19 cells

The level of HIF-1 $\alpha$  was studied in normoxic and hypoxic conditions in ARPE-19 cells. Cobalt chloride at 100, 150 and 200  $\mu$ M concentrations increased the level of HIF-1 $\alpha$  by 7, 8, and 6 folds respectively as observed in figures 10 and 11. Based on the data, cobalt chloride concentration was maintained at 150  $\mu$ M for further studies.

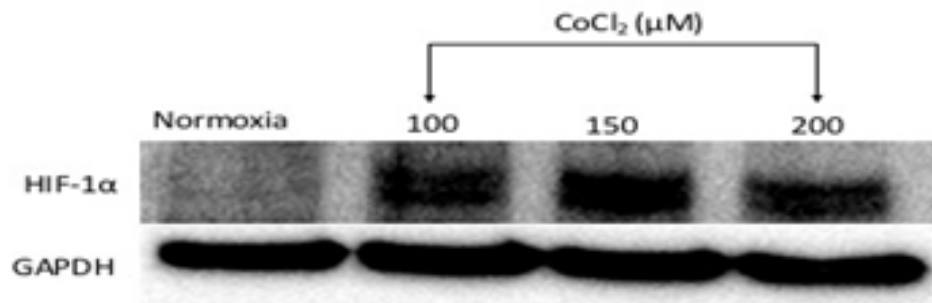


Figure 10: Immunoblot analysis showing the protein expression of HIF-1 $\alpha$  in ARPE-19 cells

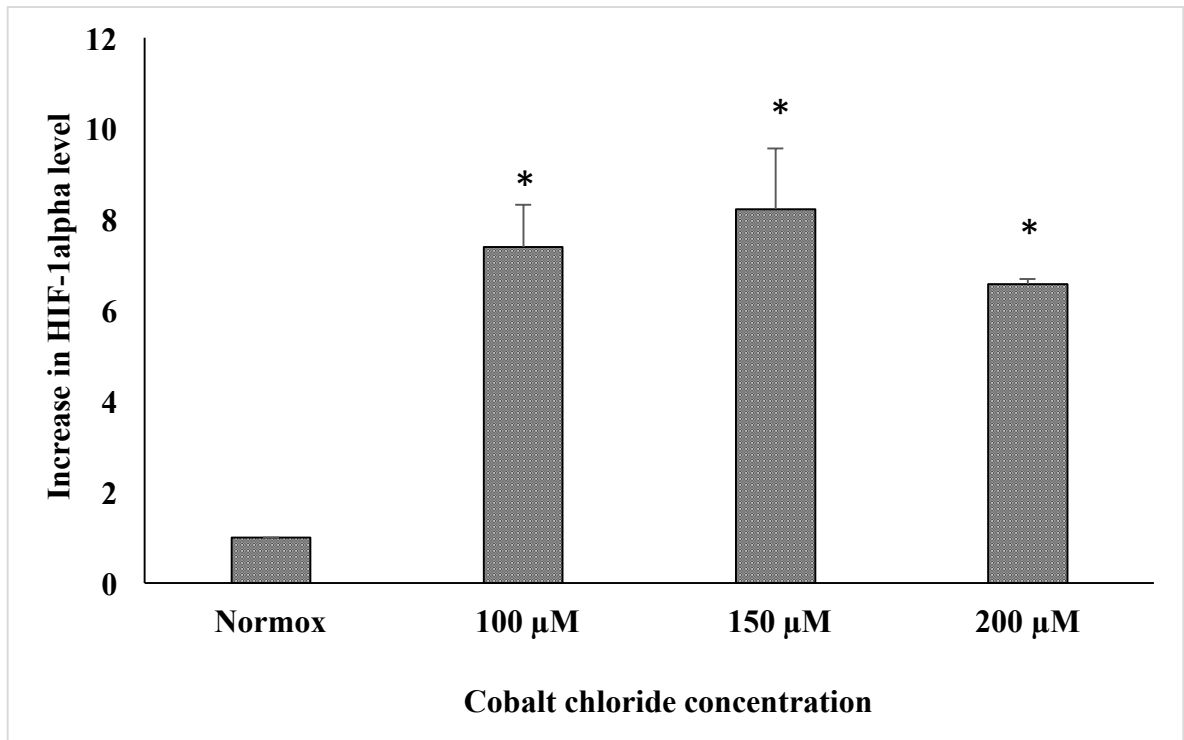


Figure 11: The levels of HIF-1 $\alpha$  expression after application of different concentrations of cobalt chloride in ARPE-19 cells. Data are expressed as mean  $\pm$  standard error of the mean (SEM), (n=3). \*P<0.05

#### ***3.5.4. Effect of Tanshinone IIA on expression of HIF-1 $\alpha$ and secretion of VEGF in hypoxic ARPE-19 cells***

Western blot and ELISA were performed to determine the expression of HIF-1 $\alpha$  and the secreted VEGF after exposure to different concentrations of Tanshinone IIA. ARPE-19 cells were cultured in hypoxic condition (150  $\mu$ M concentration of cobalt chloride) for 12 hours with and without Tanshinone IIA. After 12 hours, the VEGF level in the culture medium was determined via ELISA, while HIF-1 $\alpha$  protein was extracted, electrophoresed and detected via Western blot. The level of HIF-1 $\alpha$  under normoxic condition was negligible. After 12 hours, hypoxic condition elevated the levels of HIF-1 $\alpha$  almost 6 folds compared to normoxic condition. The level of HIF-1 $\alpha$  started to decrease in a dose dependent manner with Tanshinone IIA as observed in figure 12. The exposure of ARPE-19 cells to 150  $\mu$ M cobalt chloride stabilized the expression HIF-1 $\alpha$  and Tanshinone IIA in hypoxic condition facilitated the degradation of HIF-1 $\alpha$  which can also be observed in figure 13.

The secreted VEGF level was analyzed using ELISA. Under hypoxic condition, the secreted VEGF was increased 1.6 folds compared to the normoxic culture medium. Interestingly, the level of VEGF was decreased in a dose dependent manner after applying different concentrations of Tanshinone IIA as observed in figure 14 thus proving the ability of Tanshinone IIA to inhibit VEGF secretion.

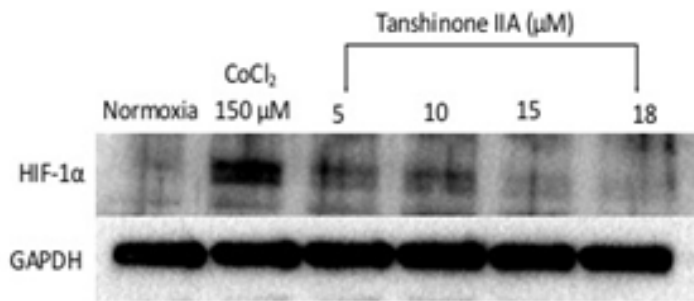
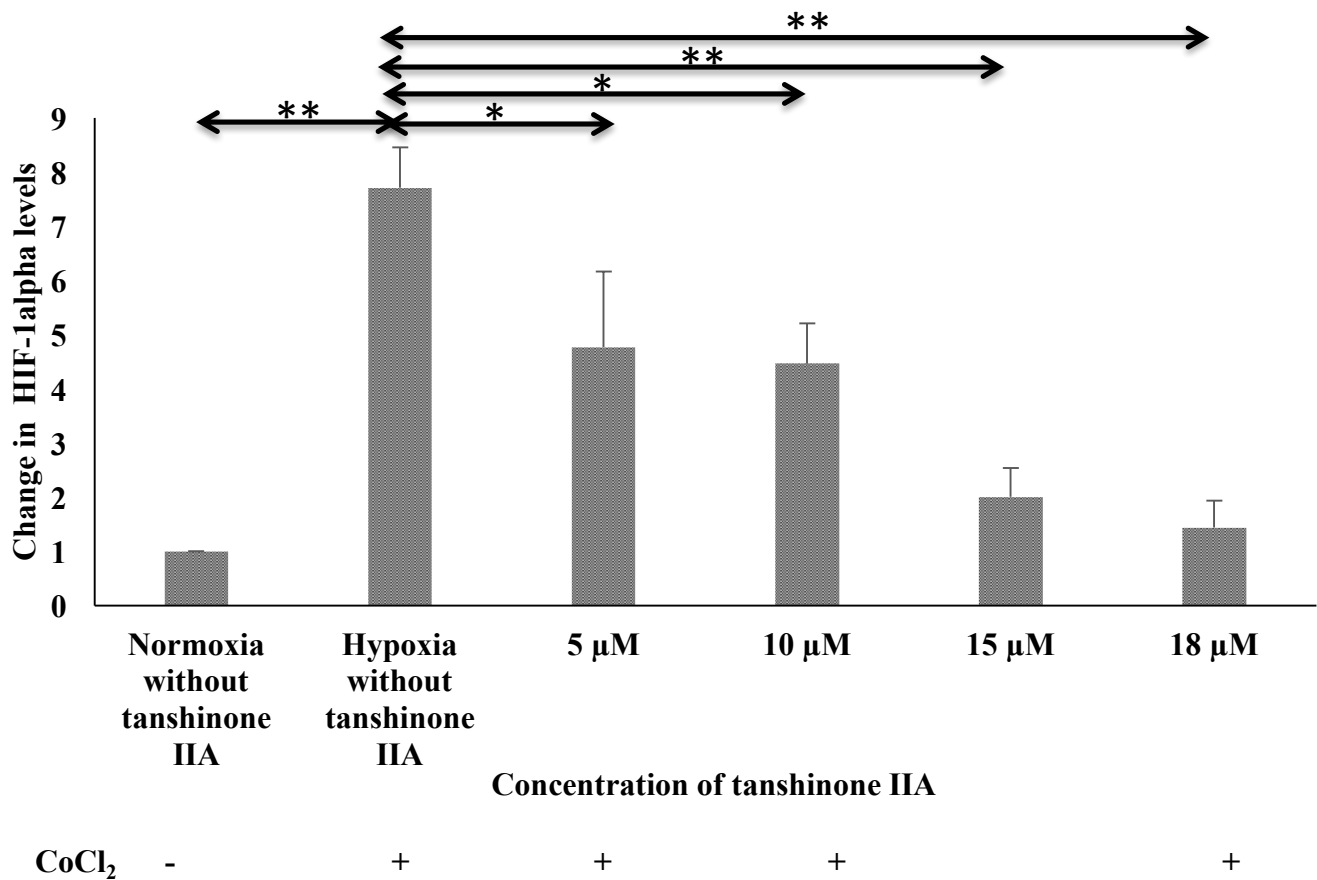


Figure 12: Immunoblot analysis showing the protein expression of HIF-1 $\alpha$  in hypoxic (150  $\mu$ M concentration of cobalt chloride, CoCl<sub>2</sub>) ARPE-19 cells after exposure to



various concentrations of Tanshinone IIA

Figure 13: Effect of Tanshinone IIA on the expression of HIF-1 $\alpha$  under hypoxic condition (150  $\mu$ M concentration of cobalt chloride, CoCl<sub>2</sub>). Data are expressed as mean  $\pm$  standard error of the mean (SEM). (n=4), \*P<0.05, \*\*P<0.001

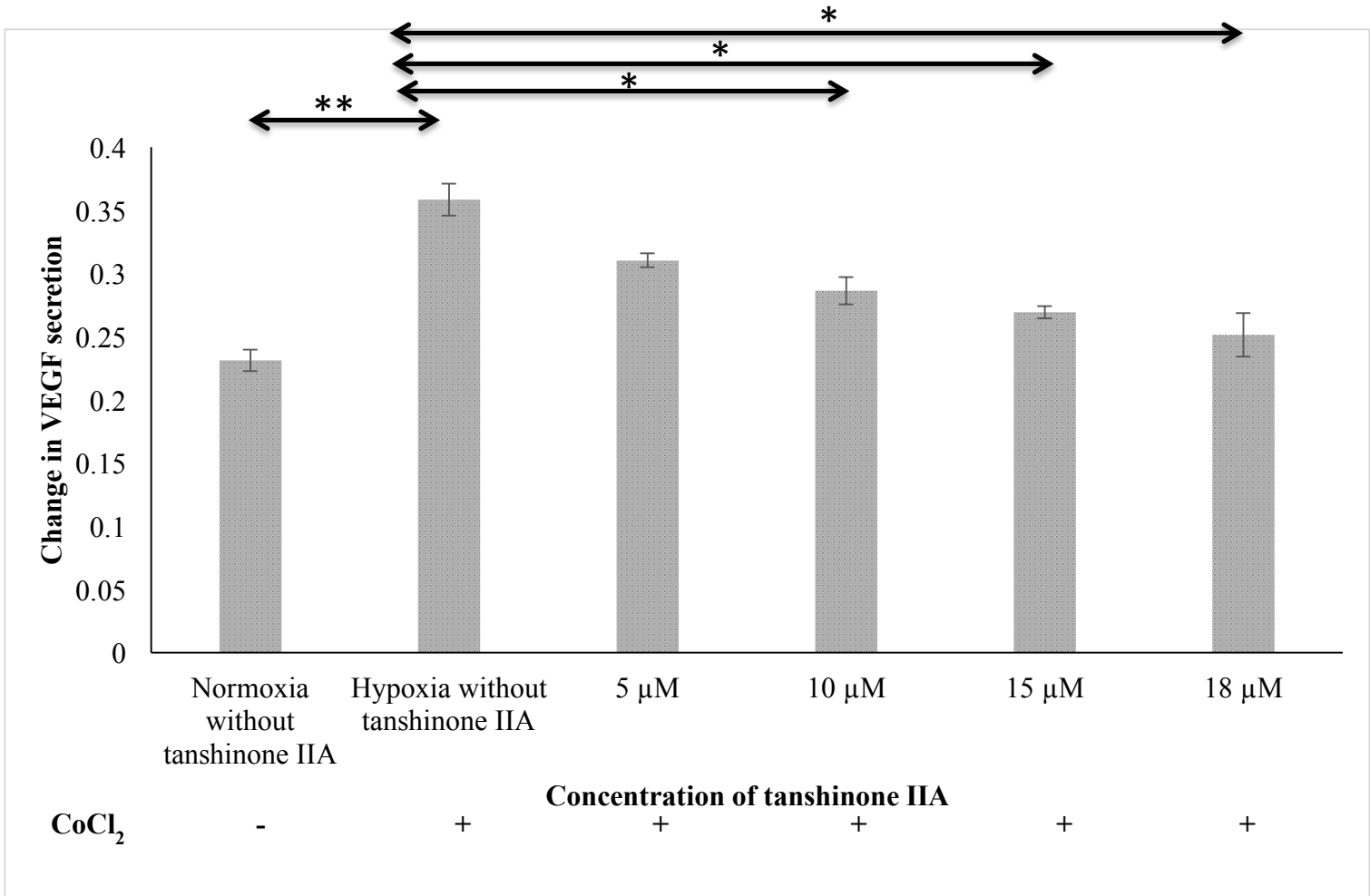


Figure 14: Effect of Tanshinone IIA on secretion of VEGF in ARPE-19 cells under hypoxic condition (150  $\mu$ M concentration of cobalt chloride, CoCl<sub>2</sub>). Data expressed as mean  $\pm$  standard error of the mean (SEM), (n=2), \*P<0.05, \*\*P<0.001.

### **3.6.Discussion**

The role of Tanshinone IIA in treating wet AMD is virtually unknown, despite its beneficial effects in treating coronary heart disease and various types of cancers. This project seeks to investigate the anti-angiogenic effects of Tanshinone IIA in human retinal cells. The current literature suggests that the pathogenesis of wet AMD is complex, and no single available treatment addresses all of the contributing elements of pathogenesis [106]. The general consensus in the literature is that attacking the disease on multiple fronts using drugs that exhibit anti-angiogenic and anti-inflammatory properties might produce synergistic effects, resulting in the inhibition of the pathological processes of CNV. Because of the substantial amount of evidence suggesting the beneficial anti-angiogenic, anti-inflammatory, and anti-oxidant properties of Tanshinone IIA, it is logical to study the drug as a potential alternative to existing anti-VEGF agents.

Hypoxia and cobalt chloride play a major role in the activation of HIF-1 $\alpha$ ., which acts as transcriptional regulator of angiogenesis [89, 107, 108]. Retinal hypoxia triggers the elevation of HIF-1 $\alpha$ . that triggers the expression of several growth factors such as VEGF [109], platelet derived growth factor-BPDGF-B, placenta growth factor and their receptors [110]. These induced growth factors lead to the formation of new blood vessels (choroid new vascularization) which is the hallmark of wet AMD [8]. Angiogenesis is an important factor that is responsible for causing wet AMD and anti-angiogenesis therapy could play a major role in treating the disease [111].

Angiogenic factors in the retina are mainly released from RPE cells. ARPE-19 cell line is commonly considered as an *in vitro* model for RPE cells for studying the effects of hypoxia in RPE physiology [51, 112]. Moreover, the structural and functional characters of ARPE-19 cells are similar to RPE cells. So, we have selected ARPE-19 cells in the current study. Initial studies were carried out to assess the cytotoxicity of Tanshinone IIA in ARPE-19 cells after 12 and 24 hours exposure. Tanshinone IIA concentrations of 5, 10, 15 and 18  $\mu\text{M}$  did not produce cytotoxicity in ARPE-19 cells up to 24 hours. Similar effects were observed in bovine corneal endothelial cells. The data from the cytotoxicity study in corneal endothelial cells will help us in identifying the toxic effects of Tanshinone IIA on other ocular tissues. As our intention is to study the anti-angiogenic properties of Tanshinone IIA without producing toxic effects in ARPE-19 cells, concentrations less than 20  $\mu\text{M}$  were used in further studies.

Cobalt chloride was used to induce hypoxia in ARPE-19 cells. A significant rise in the expression levels of HIF-1 $\alpha$  and VEGF secretion was observed in ARPE-19 cells after 12 hours exposure to 150  $\mu\text{M}$  cobalt chloride solution. Expression levels of HIF-1 $\alpha$  and secretion of VEGF was confirmed using Western blot and ELISA, respectively. Cobalt chloride is a well-known HIF-1 $\alpha$  stabilizer that decreases the degradation of HIF-1 $\alpha$ . [113]. Cobalt chloride works as a hypoxia mimicking agent by increasing VEGF production [114]. It is proved that HIF-1 $\alpha$  has an oxygen dependent degradation mechanism. Under normoxic condition, HIF-1 $\alpha$  is extensively degraded via hydroxylation by proline hydroxylase enzyme, while under hypoxic condition  $\alpha$ -subunit

of HIF-1 is stabilized and readily available to bind to the  $\beta$ -subunit to form active transcriptional heterodimer [115]. In our study, we observed that a change in HIF-1 $\alpha$  expression produced a parallel change in VEGF production. Therefore, HIF-1 $\alpha$  is considered an important regulatory factor of VEGF secretion under hypoxic condition. The secreted VEGF in culture medium showed an increase in a dose dependent manner of cobalt chloride. This result is consistent with Rosen et.al [89] who investigated the effects of zeaxanthin on the expression and secretion of VEGF by RPE cells under normoxic and hypoxic conditions.

Tanshinone IIA is a derivative of phenanthrene-quinone isolated from *Salvia miltiorrhiza* [116, 117]. Both *in vitro* and *in vivo* studies showed Tanshinone IIA has anti-VEGF and anti-angiogenic activity in vascular endothelial cells [95]. Tu et al. showed the ability of Tanshinone IIA to inhibit endothelial cell proliferation, migration and the tube formation in Human Umbilical Vein Endothelial Cells (HUVEC). The same group also revealed the ability of Tanshinone IIA in inhibiting VEGF/VEGFR2 pathway. Tanshinone IIA also has the ability to down regulate both CD146 and kinase insert domain receptor (KDR) which are the starting point in VEGF signaling. Hypoxic condition plays a major role in the activation of HIF-1 $\alpha$  which is a regulatory factor of many angiogenesis factors [107]. Studies proved that Tanshinone IIA has the ability to inhibit expression of HIF-1 $\alpha$  in breast cancer cells. Additionally, Tanshinone IIA can also inhibit angiogenesis process through inhibition both HIF-1 $\alpha$ . and VEGF in breast cancer lines [90]. Hence, Tanshinone IIA was evaluated for inhibition of HIF-1 $\alpha$  expression and VEGF secretion



in ARPE-19 cells as this inhibition can provide therapeutic interventions for diseases caused by pathological neovascularization.

In the present study, Tanshinone IIA significantly inhibited the secretion of VEGF in ARPE-19 cells line in a dose dependent manner. Studies indicate that VEGF overexpression is one of the main factors that cause CNV in ARPE-19 cells [119]. It is noteworthy that all FDA approved drugs in the treatment of wet AMD such as bevacizumab, ranibizumab and pegaptanib are anti-VEGF agents [92]. Current therapies, targeting VEGF to treat neovascular diseases such as wet AMD might have some side effects on long term usage. It has been suggested that the drugs targeting HIF pathway might be safer and more effective than that targeting VEGF alone [94]. When ARPE-19 cells are exposed to various concentrations of Tanshinone IIA, the overexpressed HIF-1 $\alpha$ . started to decrease significantly in a dose dependent manner compared to hypoxic conditions. This study also proved the ability of Tanshinone IIA to inhibit VEGF secretion, which could be due to inhibition of the HIF pathway that inhibits the expression of angiogenic factors. Based on the cytotoxicity studies, it is further understood that the changes in protein expression levels are not attributed to drug toxicity or hypoxia. Although many inhibitors of HIF-1 $\alpha$  are in clinical trials, Tanshinone IIA exhibits an additional benefit with an ability to act as anti-inflammatory agent, which might decrease the formation of drusen caused by inflammation.

### **3.7.Conclusion**

In summary, this study is the first report on the effects of Tanshinone IIA on HIF-1 $\alpha$  expression and VEGF secretion in hypoxic ARPE-19 cells. The exposure of ARPE-19 cells to various concentrations of cobalt chloride for 12 hours significantly increased the expression of HIF-1 $\alpha$  compared to normoxic condition. Tanshinone IIA significantly inhibited the expression of HIF-1 $\alpha$  and secretion of VEGF in a dose dependent manner at 5, 10, 15 and 18  $\mu$ M concentrations. This inhibition may reduce retinal neovascularization which is the hallmark of wet AMD. These preliminary findings suggest the potential of Tanshinone IIA as a promising agent in wet AMD therapy.

## References

1. Ratnapriya, R. and E.Y. Chew, Age-related macular degeneration-clinical review and genetics update. *Clin Genet*, 2013. 84(2): p. 160-166.
2. Association, A.O., Care of the patient with age-related macular degeneration. 1997, St. Louis (MO): American Optometric Association.
3. Hageman, G.S., et al., An integrated hypothesis that considers drusen as biomarkers of immune-mediated processes at the RPE-Bruch's membrane interface in aging and age-related macular degeneration. *Progress in retinal and eye research*, 2001. 20(6): p. 705-732.
4. Lutty, G., et al., Changes in choriocapillaris and retinal pigment epithelium in age-related macular degeneration. *Mol Vis*, 1999. 5(35): p. 35.
5. Ferris, F.L., S.L. Fine, and L. Hyman, Age-related macular degeneration and blindness due to neovascular maculopathy. *Archives of ophthalmology*, 1984. 102(11): p. 1640-1642.
6. Wood, A.J., et al., Age-related macular degeneration. *New England Journal of Medicine*, 2000. 342(7): p. 483-492.
7. MuÈller, R.H., K. MaÈder, and S. Gohla, Solid lipid nanoparticles (SLN) for controlled drug delivery—a review of the state of the art. *European journal of pharmaceutics and biopharmaceutics*, 2000. 50(1): p. 161-177.
8. Lim, L.S., et al., Age-related macular degeneration. *The Lancet*, 2012. 379(9827): p. 1728-1738.

9. Miller, J.W., Age-related macular degeneration revisited—piecing the puzzle: the LXIX Edward Jackson memorial lecture. *American journal of ophthalmology*, 2013. 155(1): p. 1-35. e13.
10. Strahlman, E.R., S.L. Fine, and A. Hillis, The second eye of patients with senile macular degeneration. *Archives of Ophthalmology*, 1983. 101(8): p. 1191-1193.
11. Bhutto, I. and G. Luty, Understanding age-related macular degeneration (AMD): relationships between the photoreceptor/retinal pigment epithelium/Bruch's membrane/choriocapillaris complex. *Molecular aspects of medicine*, 2012. 33(4): p. 295-317.
12. !!! INVALID CITATION !!!
13. Tuo, J., C.M. Bojanowski, and C.-C. Chan, Genetic factors of age-related macular degeneration. *Progress in retinal and eye research*, 2004. 23(2): p. 229-249.
14. Beatty, S., et al., The role of oxidative stress in the pathogenesis of age-related macular degeneration. *Surv Ophthalmol*, 2000. 45(2): p. 115-34.
15. Moore, K.L., A.F. Dalley, and A.M. Agur, *Clinically oriented anatomy*. 2013: Lippincott Williams & Wilkins.
16. Hiatt, J.L. and L.P. Gartner, *Textbook of head and neck anatomy*. 2001: Lippincott Williams & Wilkins.
17. Alberti, W.E., G. Richard, and R.H. Sagerman, *Age-Related Macular Degeneration: Current Treatment Concepts; with 33 Tables*. 2000: Springer Science & Business Media.

18. Porte, C., Pathogenesis and management of age-related macular degeneration. *Scottish Universities Medical Journal*, 2012. 1(2): p. 141-153.
19. Curcio, C.A., N.E. Medeiros, and C.L. Millican, Photoreceptor loss in age-related macular degeneration. *Investigative ophthalmology & visual science*, 1996. 37(7): p. 1236-1249.
20. Curcio, C.A. and C.L. Millican, Basal linear deposit and large drusen are specific for early age-related maculopathy. *Archives of ophthalmology*, 1999. 117(3): p. 329-339.
21. Curcio, C.A., Photoreceptor topography in ageing and age-related maculopathy. *Eye*, 2001. 15(3): p. 376-383.
22. Barron, M.J., et al., Mitochondrial abnormalities in ageing macular photoreceptors. *Investigative Ophthalmology and Visual Science*, 2001. 42(12): p. 3016-3022.
23. Green, W.R. and C. Enger, Age-related macular degeneration histopathologic studies: the 1992 Lorenz E. Zimmerman Lecture. *Ophthalmology*, 1993. 100(10): p. 1519-1535.
24. Mitchell, C.H. and D. Reigada, Purinergic signalling in the subretinal space: a role in the communication between the retina and the RPE. *Purinergic signalling*, 2008. 4(2): p. 101-107.
25. Besharse, J. and D. Defoe, Role of the retinal pigment epithelium in photoreceptor membrane turnover. 1998, chapter. p. 152.
26. Bok, D., The retinal pigment epithelium: a versatile partner in vision. *Journal of cell science*, 1993. 1993(Supplement 17): p. 189-195.

27. Delori, F.C., et al., Macular pigment density measured by autofluorescence spectrometry: comparison with reflectometry and heterochromatic flicker photometry. *JOSA A*, 2001. 18(6): p. 1212-1230.
28. Curcio, C.A. and M. Johnson, Structure, function, and pathology of Bruch's membrane. *Elastic*, 2012. 146(152): p. 210-213.
29. Booij, J.C., et al., The dynamic nature of Bruch's membrane. *Progress in retinal and eye research*, 2010. 29(1): p. 1-18.
30. Hildebrand, G.D. and A.R. Fielder, Anatomy and Physiology of the Retina, in *Pediatric retina*. 2011, Springer. p. 39-65.
31. Alm, A. and A. Bill, The oxygen supply to the retina, II. Effects of high intraocular pressure and of increased arterial carbon dioxide tension on uveal and retinal blood flow in cats. *Acta physiologica Scandinavica*, 1972. 84(3): p. 306-319.
32. Organization, W.H. *Prevention of Blindness and Visual Impairment*. 2012; Available from: <http://www.who.int/blindness/causes/priority/en/>.
33. Yonekawa, Y., J.W. Miller, and I.K. Kim, Age-Related Macular Degeneration: Advances in Management and Diagnosis. *Journal of Clinical Medicine*, 2015. 4(2): p. 343-359.
34. Lim, J.I., *Age-related macular degeneration*. 2007: CRC Press.
35. Group, A.-R.E.D.S.R., A randomized, placebo-controlled, clinical trial of high-dose supplementation with vitamins C and E, beta carotene, and zinc for age-related macular degeneration and vision loss: AREDS report no. 8. *Archives of ophthalmology*, 2001. 119(10): p. 1417.

36. Klein, R., B.E. Klein, and K.L. Linton, Prevalence of age-related maculopathy: the Beaver Dam Eye Study. *Ophthalmology*, 1992. 99(6): p. 933-943.
37. VanNewkirk, M.R., et al., The prevalence of age-related maculopathy: The visual impairment project11Received December 30, 1999. Accepted March 27, 2000. *Ophthalmology*, 2000. 107(8): p. 1593-1600.
38. Augood, C.A., et al., Prevalence of age-related maculopathy in older Europeans: the European Eye Study (EUREYE). *Archives of ophthalmology*, 2006. 124(4): p. 529-535.
39. Miyazaki, M., et al., The 5-year incidence and risk factors for age-related maculopathy in a general Japanese population: the Hisayama study. *Investigative ophthalmology & visual science*, 2005. 46(6): p. 1907-1910.
40. Klein, R., M.L. Rowland, and M.I. Harris, Racial/ethnic differences in age-related maculopathy: Third National Health and Nutrition Examination Survey. *Ophthalmology*, 1995. 102(3): p. 371-381.
41. Friedman, D.S., et al., Racial differences in the prevalence of age-related macular degeneration: The Baltimore eye survey11The authors have no proprietary interest in any of the instruments used in this study. *Ophthalmology*, 1999. 106(6): p. 1049-1055.
42. Jager, R.D., W.F. Mieler, and J.W. Miller, Age-related macular degeneration. *New England Journal of Medicine*, 2008. 358(24): p. 2606-2617.
43. Khan, J., et al., Smoking and age related macular degeneration: the number of pack years of cigarette smoking is a major determinant of risk for both geographic atrophy and choroidal neovascularisation. *British Journal of Ophthalmology*, 2006. 90(1): p. 75-80.

44. van Leeuwen, R., et al., Dietary intake of antioxidants and risk of age-related macular degeneration. *Jama*, 2005. 294(24): p. 3101-3107.
45. VandenLangenberg, G.M., et al., Associations between antioxidant and zinc intake and the 5-year incidence of early age-related maculopathy in the Beaver Dam Eye Study. *American journal of epidemiology*, 1998. 148(2): p. 204-214.
46. Chappelow, A.V. and P.K. Kaiser, Neovascular age-related macular degeneration. *Drugs*, 2008. 68(8): p. 1029-1036.
47. Das, A. and P.G. McGuire, Retinal and choroidal angiogenesis: pathophysiology and strategies for inhibition. *Progress in retinal and eye research*, 2003. 22(6): p. 721-748.
48. Ng, E.W. and A.P. Adamis, Targeting angiogenesis, the underlying disorder in neovascular age-related macular degeneration. *Canadian Journal of Ophthalmology/Journal Canadien d'Ophthalmologie*, 2005. 40(3): p. 352-368.
49. Nguyen, Q., et al., Bevacizumab suppresses choroidal neovascularisation caused by pathological myopia. *British journal of ophthalmology*, 2005. 89(6): p. e1-e1.
50. Semenza, G.L. and G.L. Wang, A nuclear factor induced by hypoxia via de novo protein synthesis binds to the human erythropoietin gene enhancer at a site required for transcriptional activation. *Molecular and cellular biology*, 1992. 12(12): p. 5447-5454.
51. Forooghian, F., R. Razavi, and L. Timms, Hypoxia-inducible factor expression in human RPE cells. *British Journal of Ophthalmology*, 2007. 91(10): p. 1406-1410.
52. Bressler, S.B., Introduction: Understanding the role of angiogenesis and antiangiogenic agents in age-related macular degeneration. *Ophthalmology*, 2009. 116(10): p. S1-S7.



53. Schlingemann, R.O., Role of growth factors and the wound healing response in age-related macular degeneration. *Graefes archive for clinical and experimental ophthalmology*, 2004. 242(1): p. 91-101.
54. Adamis, A., et al., Synthesis and secretion of vascular permeability factor/vascular endothelial growth factor by human retinal pigment epithelial cells. *Biochemical and biophysical research communications*, 1993. 193(2): p. 631-638.
55. Nowak, J.Z., Age-related macular degeneration (AMD): pathogenesis and therapy. *Pharmacol rep*, 2006. 58(3): p. 353-363.
56. Petrukhin, K., Pharmacological inhibition of lipofuscin accumulation in the retina as a therapeutic strategy for dry AMD treatment. *Drug Discovery Today: Therapeutic Strategies*, 2013. 10(1): p. e11-e20.
57. Zhang, P., et al., Inhibition of VEGF expression by targeting HIF-1 $\alpha$  with small interference RNA in human RPE cells. *Ophthalmologica*, 2007. 221(6): p. 411-417.
58. Wang, Y., V. Wang, and C. Chan, The role of anti-inflammatory agents in age-related macular degeneration (AMD) treatment. *Eye*, 2011. 25(2): p. 127-139.
59. Gupta, N., K.E. Brown, and A.H. Milam, Activated microglia in human retinitis pigmentosa, late-onset retinal degeneration, and age-related macular degeneration. *Experimental eye research*, 2003. 76(4): p. 463-471.
60. Sunness, J.S., et al., Visual function abnormalities and prognosis in eyes with age-related geographic atrophy of the macula and good visual acuity. *Ophthalmology*, 1997. 104(10): p. 1677-1691.

61. Steinmetz, R.L., et al., Symptomatic abnormalities of dark adaptation in patients with age-related Bruch's membrane change. *British Journal of Ophthalmology*, 1993. 77(9): p. 549-554.
62. Fine, A.M., et al., Earliest symptoms caused by neovascular membranes in the macula. *Archives of ophthalmology*, 1986. 104(4): p. 513-514.
63. Segre, L. Amsler Grid: Test for Macular Degeneration or Other Vision Problems. 2014; Available from: <http://www.allaboutvision.com/conditions/amsler-grid.htm>.
64. Hee, M.R., et al., Optical coherence tomography of age-related macular degeneration and choroidal neovascularization. *Ophthalmology*, 1996. 103(8): p. 1260-1270.
65. Izatt, J.A., et al., Micrometer-scale resolution imaging of the anterior eye in vivo with optical coherence tomography. *Archives of ophthalmology*, 1994. 112(12): p. 1584-1589.
66. Hee, M.R., et al., Optical coherence tomography of the human retina. *Archives of ophthalmology*, 1995. 113(3): p. 325-332.
67. eyemedics. Fundus Fluorescein Angiography. Available from: <http://www.eyemedics.com.au/assets/pdf/FFA-BROCHURE-SEPT-2013.pdf>.
68. Northwest, E.H. FLUORESCEIN AND INDOCYANINE GREEN (ICG) ANGIOGRAPHY. Available from: [http://www.ehnpc.com/pdfs/fluorescein\\_and\\_indocyanine\\_green.pdf](http://www.ehnpc.com/pdfs/fluorescein_and_indocyanine_green.pdf).
69. Jager, R.D., et al., Risks of intravitreal injection: a comprehensive review. *Retina*, 2004. 24(5): p. 676-698.

70. van Wijngaarden, P., D.J. Coster, and K.A. Williams, Inhibitors of ocular neovascularization: promises and potential problems. *Jama*, 2005. 293(12): p. 1509-1513.
71. Gragoudas, E.S., et al., Pegaptanib for neovascular age-related macular degeneration. *New England Journal of Medicine*, 2004. 351(27): p. 2805-2816.
72. Group, C.R., Ranibizumab and bevacizumab for neovascular age-related macular degeneration. *The New England journal of medicine*, 2011. 364(20): p. 1897.
73. Rosenfeld, P.J., et al., Ranibizumab for neovascular age-related macular degeneration. *New England Journal of Medicine*, 2006. 355(14): p. 1419-1431.
74. Fung, A.E., P.J. Rosenfeld, and E. Reichel, The International Intravitreal Bevacizumab Safety Survey: using the internet to assess drug safety worldwide. *British Journal of Ophthalmology*, 2006. 90(11): p. 1344-1349.
75. Wu, L., et al., Twelve-month safety of intravitreal injections of bevacizumab (Avastin®): results of the Pan-American Collaborative Retina Study Group (PACORES). *Graefe's Archive for Clinical and Experimental Ophthalmology*, 2008. 246(1): p. 81-87.
76. fda.gov. HIGHLIGHTS OF PRESCRIBING INFORMATION. 2011; Available from: [http://www.accessdata.fda.gov/drugsatfda\\_docs/label/2011/125387lbl.pdf](http://www.accessdata.fda.gov/drugsatfda_docs/label/2011/125387lbl.pdf).
77. Truong, A., T.Y. Wong, and L.M. Khachigian, Emerging therapeutic approaches in the management of retinal angiogenesis and edema. *Journal of molecular medicine*, 2011. 89(4): p. 343-361.
78. Wong, W.T., et al., Treatment of geographic atrophy by the topical administration of OT-551: results of a phase II clinical trial. *Investigative ophthalmology & visual science*, 2010. 51(12): p. 6131-6139.

79. Dunaief, J. A Promising New Treatment for Wet Age-Related Macular Degeneration (AMD). 2015 October 6th 2015 [cited 2016 May 19th ]; Available from: <http://www.brightfocus.org/macular/article/promising-new-treatment-wet-age-related-macular>.
80. Inc., O.P. Ohr Pharmaceutical Announces Successful End of Phase II Meeting With the FDA on Squalamine Eye Drops (OHR-102) in Wet AMD. Available from: <http://www.ohrpharmaceutical.com/media-center/press-releases/detail/304/ohr-pharmaceutical-announces-successful-end-of-phase-ii>.
81. AMD.org. X-82 Phase 2 Study for Wet AMD. 2015; Available from: <http://www.amd.org/x-82-phase-2-study-for-wet-amd/>.
82. panopticapharma. Pan-90806: Our lead development compound. Available from: <http://www.panopticapharma.com/pan.html>.
83. Washington, T.R.G.o. AVENUE | Clinical Trials | The Retina Group of Washington (RGW). Available from: <http://rgw.com/research/clinical-trials/age-related-macular-degeneration/avenue>.
84. Washington, T.R.G.o. CAPELLA | Clinical Trials | The Retina Group of Washington (RGW). Available from: <http://rgw.com/research/clinical-trials/age-related-macular-degeneration/capella>.
85. quarkpharma. PF-655. Available from: [http://quarkpharma.com/?page\\_id=28](http://quarkpharma.com/?page_id=28).
86. Xu, S. and P. Liu, Tanshinone II-A: new perspectives for old remedies. Expert opinion on therapeutic patents, 2013. 23(2): p. 149-153.

87. Chen, S.-J., A potential target of Tanshinone IIA for acute promyelocytic leukemia revealed by inverse docking and drug repurposing. *Asian Pacific journal of cancer prevention: APJCP*, 2013. 15(10): p. 4301-4305.
88. Yang, R., Y. Lu, and J. Liu, Identification of tanshinone IIA as a natural monoacylglycerol lipase inhibitor by combined in silico and in vitro approach. *MedChemComm*, 2014. 5(10): p. 1528-1532.
89. Rosen, R., et al., Zeaxanthin inhibits hypoxia-induced VEGF secretion by RPE cells through decreased protein levels of hypoxia-inducible factors-1 $\alpha$ . *BioMed research international*, 2015. 2015.
90. Li, G., et al., Tanshinone IIA inhibits HIF-1 $\alpha$  and VEGF expression in breast cancer cells via mTOR/p70S6K/RPS6/4E-BP1 signaling pathway. *PloS one*, 2015. 10(2): p. e0117440.
91. Kaur, C., W.S. Foulds, and E.-A. Ling, Hypoxia-ischemia and retinal ganglion cell damage. *Clin Ophthalmol*, 2008. 2(4): p. 879-889.
92. Vadlapatla, R.K., A.D. Vadlapudi, and A.K. Mitra, Hypoxia-inducible factor-1 (HIF-1): a potential target for intervention in ocular neovascular diseases. *Current drug targets*, 2013. 14(8): p. 919.
93. Caprara, C. and C. Grimm, From oxygen to erythropoietin: relevance of hypoxia for retinal development, health and disease. *Progress in retinal and eye research*, 2012. 31(1): p. 89-119.
94. Vadlapatla, R., et al., Ritonavir inhibits HIF-1 $\alpha$ -mediated VEGF expression in retinal pigment epithelial cells in vitro. *Eye*, 2014. 28(1): p. 93-101.

95. Tsai, M.-Y., et al., Anti-angiogenic effect of Tanshinone IIA involves inhibition of matrix invasion and modification of MMP-2/TIMP-2 secretion in vascular endothelial cells. *Cancer letters*, 2011. 310(2): p. 198-206.
96. Dong, X., et al., Anti-inflammatory effects of tanshinone IIA on radiation-induced microglia BV-2 cells inflammatory response. *Cancer Biotherapy and Radiopharmaceuticals*, 2009. 24(6): p. 681-687.
97. Yang, L.-J., et al., Tanshinone IIA isolated from *Salvia miltiorrhiza* elicits the cell death of human endothelial cells. *Journal of biomedical science*, 2005. 12(2): p. 347-361.
98. Liu, J.-J., et al., Tanshinone IIA inhibits leukemia THP-1 cell growth by induction of apoptosis. *Oncology reports*, 2009. 21(4): p. 1075-1081.
99. Chiu, T.-L. and C.-C. Su, Tanshinone IIA induces apoptosis in human lung cancer A549 cells through the induction of reactive oxygen species and decreasing the mitochondrial membrane potential. *International journal of molecular medicine*, 2010. 25(2): p. 231-236.
100. Lu, Q., et al., Experimental study of the anti-cancer mechanism of tanshinone IIA against human breast cancer. *International journal of molecular medicine*, 2009. 24(6): p. 773-780.
101. Chen, J., et al., Tanshinone IIA induces growth inhibition and apoptosis in gastric cancer in vitro and in vivo. *Oncology reports*, 2012. 27(2): p. 523.
102. Gong, Y., et al., Bioactive tanshinones in *Salvia miltiorrhiza* inhibit the growth of prostate cancer cells in vitro and in mice. *International Journal of Cancer*, 2011. 129(5): p. 1042-1052.

103. Chien, S.-Y., et al., Tanshinone IIA inhibits human hepatocellular carcinoma J5 cell growth by increasing Bax and caspase 3 and decreasing CD31 expression in vivo. *Mol. Med. Rep*, 2012. 5: p. 282-286.
104. MacCallum, D.K., et al., Bovine corneal endothelium in vitro: elaboration and organization of a basement membrane. *Experimental cell research*, 1982. 139(1): p. 1-13.
105. Dim Mauro, I., et al., A simple protocol for the subcellular fractionation of skeletal muscle cells and tissue. *BMC research notes*, 2012. 5(1): p. 513.
106. Ambati, J. and Benjamin J. Fowler, Mechanisms of Age-Related Macular Degeneration. *Neuron*, 2012. 75(1): p. 26-39.
107. Pugh, C.W. and P.J. Ratcliffe, Regulation of angiogenesis by hypoxia: role of the HIF system. *Nature medicine*, 2003. 9(6): p. 677-684.
108. Seong, H., et al., Resveratrol suppresses vascular endothelial growth factor secretion via inhibition of CXC-chemokine receptor 4 expression in ARPE-19 cells. *Molecular medicine reports*, 2015. 12(1): p. 1479-1484.
109. Hoeben, A., et al., Vascular endothelial growth factor and angiogenesis. *Pharmacological reviews*, 2004. 56(4): p. 549-580.
110. Campochiaro, P.A., Ocular neovascularization. *Journal of molecular medicine*, 2013. 91(3): p. 311-321.
111. Tadayoni, R., Choroidal neovascularization induces retinal edema and its treatment addresses this problem. *Journal of ophthalmic & vision research*, 2014. 9(4): p. 405.
112. Vadlapatla, R.K., et al., Ritonavir inhibits HIF-1 $\alpha$ -mediated VEGF expression in retinal pigment epithelial cells in vitro. *Eye*, 2014. 28(1): p. 93-101.

113. Zhang, Y.-B., et al., The effects of CoCl<sub>2</sub> on HIF-1 $\alpha$  protein under experimental conditions of autoprogressive hypoxia using mouse models. *International journal of molecular sciences*, 2014. 15(6): p. 10999-11012.
114. Grasselli, F., et al., Cobalt chloride, a hypoxia-mimicking agent, modulates redox status and functional parameters of cultured swine granulosa cells. *Reproduction, Fertility and Development*, 2005. 17(7): p. 715-720.
115. Al Okail, M.S., Cobalt chloride, a chemical inducer of hypoxia-inducible factor-1 $\alpha$  in U251 human glioblastoma cell line. *Journal of Saudi Chemical Society*, 2010. 14(2): p. 197-201.
116. Zhang, Y., et al., Tanshinones: sources, pharmacokinetics and anti-cancer activities. *International journal of molecular sciences*, 2012. 13(10): p. 13621-13666.
117. Wang, X., et al., Potential anticancer activity of tanshinone IIA against human breast cancer. *International journal of cancer*, 2005. 116(5): p. 799-807.
118. Xing, Y., et al., Anti-angiogenic effect of tanshinone IIA involves inhibition of the VEGF/VEGFR2 pathway in vascular endothelial cells. *Oncology reports*, 2015. 33(1): p. 163-170.
119. Semeraro, F., et al., Aflibercept in wet AMD: specific role and optimal use. *Drug Des Devel Ther*, 2013. 7: p. 711-722.



