



Prevention of Petersen's hernia using jejunal mesentery fixing (Mefix)

Jae-Seok Min, Sang-Ho Jeong, Ji-Ho Park, Tae-Han Kim, Soon-Chan Hong, Eun-Jung Jung, Young-Tae Ju, Chi-Young Jeong, Jin-Kwon Lee, Miyeong Park & Young-Joon Lee

To cite this article: Jae-Seok Min, Sang-Ho Jeong, Ji-Ho Park, Tae-Han Kim, Soon-Chan Hong, Eun-Jung Jung, Young-Tae Ju, Chi-Young Jeong, Jin-Kwon Lee, Miyeong Park & Young-Joon Lee (2020): Prevention of Petersen's hernia using jejunal mesentery fixing (Mefix), *Minimally Invasive Therapy & Allied Technologies*, DOI: [10.1080/13645706.2020.1848872](https://doi.org/10.1080/13645706.2020.1848872)

To link to this article: <https://doi.org/10.1080/13645706.2020.1848872>



© 2020 The Author(s). Published by Informa UK Limited, trading as Taylor & Francis Group.



[View supplementary material](#)



Published online: 03 Dec 2020.



[Submit your article to this journal](#)



Article views: 309





[View related articles](#)



[View Crossmark data](#)

Prevention of Petersen's hernia using jejunal mesentery fixing (Mefix)

Jae-Seok Min^a , Sang-Ho Jeong^{b,c} , Ji-Ho Park^b, Tae-Han Kim^c, Soon-Chan Hong^b, Eun-Jung Jung^b, Young-Tae Ju^b, Chi-Young Jeong^b, Jin-Kwon Lee^b, Miyeong Park^d and Young-Joon Lee^b

^aDepartment of Surgery, Dongnam Institute of Radiological and Medical Sciences, Cancer Center, Busan, Republic of Korea; ^bDepartment of Surgery, Gyeongsang National University School of Medicine, Jinju, Republic of Korea; ^cDepartment of Surgery, Gyeongsang National University Changwon Hospital, Changwon, Republic of Korea; ^dDepartment of Anesthesiology, Gyeongsang National University Changwon Hospital, Changwon, Republic of Korea

ABSTRACT

Background: The aim of this study was to compare the 1 year incidence of Petersen's hernia between individuals who were treated with the jejunal mesentery fixing (Mefix) method and those with the closure of Petersen's space method.

Material and methods: We retrospectively collected clinical data of patients who underwent gastrectomy for gastric cancers with the closure of Petersen's space defect ($N=49$) and Mefix ($N=26$). The Mefix method was performed by fixing the jejunal mesentery (jejunojejunostomy below 30 cm) to the transverse mesocolon using nonabsorbable barbed sutures.

Results: The procedure time for mesentery fixing (3.7 ± 1.1 mins) was significantly shorter than that for Petersen's space closure (7.5 ± 1.5 mins) ($p < .001$) although the operation times were similar between the two groups. There was no incidence of Petersen's hernias postoperatively in both groups. One case of reoperation was reported in the closure group due to small bowel obstruction by kinking of the jejunojejunostomy.

Conclusion: We found no occurrence of Petersen's hernias postoperatively in either group. We also found that the Mefix method was faster and easier to perform than the closure method. The Mefix method is an excellent alternative method to prevent the occurrence of Petersen's hernia after B-II or Roux-en-Y reconstruction.

Abbreviations: Mefix: jejunal mesentery fixing; B-II: Billroth II; G-J: gastrojejunostomy; EGC: early gastric cancer; BMI: Body mass index; RNY: Roux-en Y; GJ: gastrojejunostomy; EJ: esophagojejunostomy; ASCPC: accordion severity classification of postoperative complications

ARTICLE HISTORY

Received 21 March 2020
Accepted 29 October 2020

KEYWORDS



Petersen's hernia; hernia; laparoscopy; gastric neoplasm; bariatric surgery


Introduction

Petersen's hernia was first reported in 1900 by German surgeon Walther Petersen following the occurrence of an internal hernia after gastrectomy and gastrojejunostomy (G-J) [1]. Petersen's hernia occurs in the free space posterior to a G-J site after any type of G-J and is caused by herniation of the small bowel through the defect between the small bowel mesentery and the transverse mesocolon. Recently, the laparoscopic approach for gastrectomy used in early gastric cancer has been considered a standard method worldwide. The laparoscopic approach reduces the occurrence of postoperative adhesions and can also increase the incidence of Petersen's hernias. The occurrence rate of Petersen's

hernias after laparoscopic Roux-en-Y G-J is approximately 1.7~9.7% [2-7]. The incidence of internal hernia has been reported to be higher in laparoscopic approaches than in open gastrectomy [3,5,6,8].

The closure of mesenteric defects can prevent the occurrence of internal hernias, including Petersen's hernias, after gastrectomy for cancer [3,7,9,10]. The mechanism of a Petersen's hernia is the twisting of the small bowel mesentery between the Roux-en-Y mesentery and the remaining small bowel. We prevented the twisting of the small bowel mesentery by fixing the jejunal mesentery to the peritoneum, not by closing Petersen's space, which may be time-consuming. We conducted jejunal mesentery fixing (Mefix) to the transverse mesocolon with a non-absorbable suture to

CONTACT Sang-Ho Jeong  shjeong@gnu.ac.kr  Department of Surgery, Gyeongsang National University College of Medicine and Gyeongsang National University Changwon Hospital, 11, Samjeongja-ro, Seongsan-gu, Changwon-si, Gyeongsangnam-do, Republic of Korea

 Supplemental data for this article can be accessed [here](#)

© 2020 The Author(s). Published by Informa UK Limited, trading as Taylor & Francis Group.

This is an Open Access article distributed under the terms of the Creative Commons Attribution-NonCommercial-NoDerivatives License (<http://creativecommons.org/licenses/by-nc-nd/4.0/>), which permits non-commercial re-use, distribution, and reproduction in any medium, provided the original work is properly cited, and is not altered, transformed, or built upon in any way.

prevent a Petersen's hernia. The aim of this study was to compare the postoperative incidence of Petersen's hernia using the Mefix and the closure of Petersen's space methods. We investigated whether the Mefix method is an effective method for preventing Petersen's hernias compared with the closure method.

Material and methods

A retrospective observational study was designed and carried out according to the principles of the Declaration of Helsinki, 1989. This study was approved by the institutional review board (GNUCH-IRB-202003008).

Patients

Between 2016 and 2018, we analyzed the data of patients who underwent gastrectomy for gastric cancers at the Gyeongsang National University Hospital in Changwon and at the Dongnam Institute of Radiological and Medical Sciences in Busan, Korea. Two expert surgeons with experience of more than 400 cases of minimally invasive gastrectomy enrolled the cases. The inclusion criteria of this study were as follows: histologically proven primary gastric adenocarcinoma; no evidence of other distant metastasis; R0 resection; laparoscopic or robotic gastrectomy; and reconstructed by Roux-en-Y reconstruction or the Billroth II procedure. We excluded patients with the following: active double cancer (synchronous and metachronous double cancer within five disease-free years), carcinoma *in situ*, open gastrectomy, reconstructed by Billroth I procedure, gastric cancer recurrence, or a history of gastrectomy. We retrospectively collected clinical data from 75 patients who underwent laparoscopic or robotic gastrectomy with Petersen's space closure or jejunal mesentery fixing with Roux-en-Y reconstruction or the Billroth II procedure.

We collected data on the operation, pathologic reports, postoperative complications, and courses by retrospective chart review after surgery. We also reviewed the operation video clips to check the procedure time for the Petersen's space closure or mesentery fixing. We found 48% (36/75) of the operation video clips (closure group, 26/49; Mefix group, 10/26). All patients visited the hospital at six months and one year after surgery, and they were examined by CT scan to check for the recurrence of gastric cancer and the occurrence of Petersen's hernia.

Application of procedure by period

We closed Petersen's space defect between March 1st, 2016 and Dec 31st, 2017 ($N=49$), and we performed the Mefix procedure between July 1st, 2017 and June 30th, 2018 ($N=26$). We classified patients into the Petersen's space closure group (closure group) and the mesentery fixing group (Mefix group).

Operative methods for gastrectomy

Total, distal or proximal gastrectomy with partial omentectomy and D1+ lymph node dissection was performed *via* laparoscopic or robot-assisted gastrectomy when the preoperative diagnosis, using gastrofibroscopy and spiral CT scans, revealed early gastric cancer (EGC). Lymph node stations were identified according to the Japanese Classification of Gastric Carcinoma from 2011 [11]. Gastric resection and determination of the resection area for the lymph node stations were performed according to the Japanese Gastric Cancer Association treatment guidelines from 2014 [12]. Total or distal gastrectomy with total omentectomy and D2 lymph node dissection were performed in cases of advanced gastric cancer. We performed the intracorporeal Roux-en-Y reconstruction or the Billroth II procedure with antecolic manner.

Operative methods for Petersen's space closure (closure group)

To prevent Petersen's hernias, we first performed tagging sutures between the jejunum and transverse colon using Sof silk 3-0 (Medtronic®, Minneapolis, MN, USA), and we closed Petersen's space (Figure 1(A), purple dotted line) between the mesentery of the jejunal Roux limb and the mesentery of the transverse colon at the posterior side of esophago-jejunostomy (E-J) or G-J from the mesentery root to the bowel side using a non-absorbable barbed suture V-Loc™ 3-0 (Medtronic®, Minneapolis, MN, USA). In the final step, we performed anchoring suture using one or two-point backward suture with V-Loc™ 3-0 continuously.

Operative methods for distal jejunal fixing (Mefix group)

The same method for the gastric resection and reconstruction step was performed in the Mefix group as in the closure group. To prevent Petersen's hernias, we fixed the jejunal mesentery (blue area, jejunojejunostomy [J-J] distal 30 cm) to the transverse mesocolon

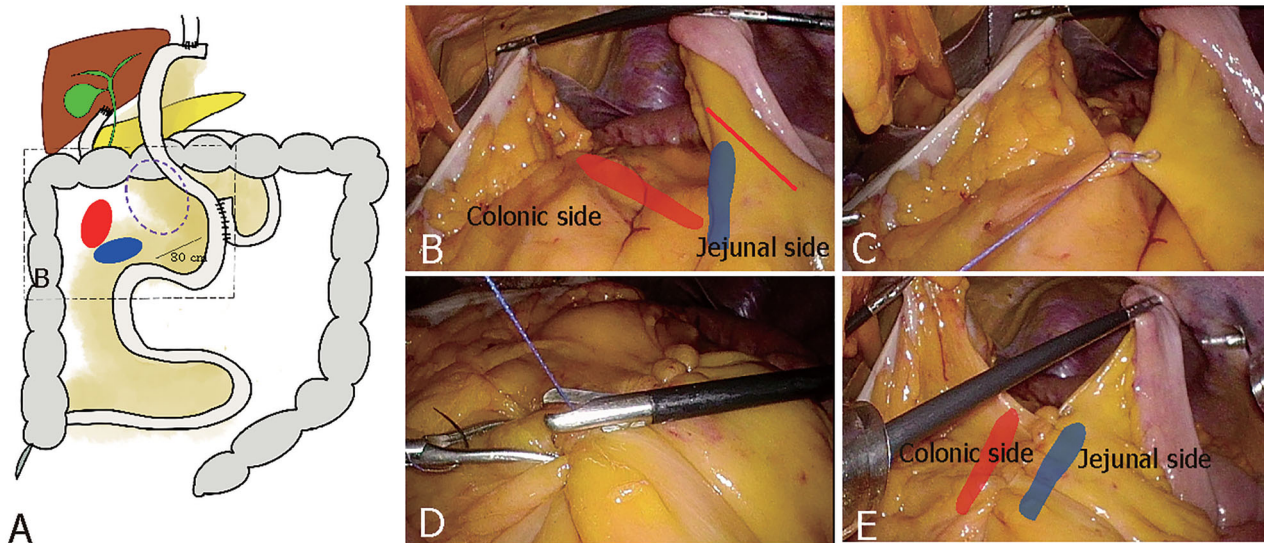


Figure 1. Steps of the Mefix procedure. (A) Schematic diagram of Petersen's space (purple dotted line), jejunal mesentery (blue area, jejunal side), at site 30 cm distal J-J) with transverse mesocolon (red area, colonic side). (B) Exposure of the suture area jejunal side & colonic side (red line, SMA vascular arcade) (Step 1). (C) Step 2. The suture started between jejunal side just below of SMA vascular arcade and colonic side. (D,E) Step 3. To anchor the mesentery, two-point backward sutures were performed, and Mefix was done.

(red area) using non-absorbable barbed suture V-Loc™ 3-0 sutures (Figure 1(A)). The aim of the Mefix method was to prevent small bowel mesentery twisting by fixing the jejunal mesentery to the transverse mesocolon at the site far from the Petersen's space. It was not used for the closure of Petersen's space (Supplement mefix_video).

Step 1: The suture area was exposed by grasping the jejunum side mesentery (blue area, jejunal side, at site 30cm distal J-J) and the transverse mesocolon (red area, colonic side, Figure 1(B)).

Step 2: The jejunal side mesentery (blue area) was fixed to the colonic side mesocolon (red area) between the jejunum and the transverse colon using nonabsorbable barbed V-Loc™ 3-0 sutures. The red line represents the SMA vascular arcade. The suture started between jejunal mesentery just below of SMA vascular arcade and transverse mesocolon, and it finished when it reaches the root of the mesentery (Figure 1(C)).

Step 3: To anchor the mesentery, continuous suturing with V-Loc two-point backward sutures were performed at the final step (Figure 1(D,E)).

All statistical analyses were performed using SPSS Statistics version 24 (IBM SPSS, Inc., Chicago, IL, USA). Continuous data were compared using Student's t-test and are presented as the mean \pm standard deviations, and noncontinuous variables were assessed with the Chi square test. In all

analyses, p values $< .05$ were considered statistically significant.

Results

Patient demographics

Table 1 shows the demographics of patients. The average patient age was 60.9 ± 11.9 years. The male to female ratio was about 3:1. The mean BMI was 22.2 ± 3.0 . The mean tumor size was 3.1 ± 1.6 cm. Analysis of the TNM stages revealed that 77.3% ($n = 58$), 18.7% ($n = 14$), and 4.0% ($n = 3$) of the patients had stage I, II, and III disease, respectively. The mean operation time was 254.1 ± 63.0 min. The mean duration of the postoperative hospital stay was 14.2 ± 10.1 days. Laparoscopic gastrectomy and robot-assisted gastrectomy were used in 72.0% ($n = 54$) and 28.0% ($n = 21$) of patients, respectively. Among the types of operations performed, distal gastrectomy was the most commonly performed resection method (88.0%, $n = 66$), followed by total (6.7%, $n = 5$) and proximal gastrectomy (5.3%, $n = 4$). Among the types of anastomoses performed, Billroth II was the most common procedure (40.0%, $n = 30$), followed by Roux-en Y G-J (37.3%, $n = 28$), uncut Roux-en Y G-J (12.0%, $n = 9$), Roux-en Y E-J (5.3%, $n = 4$), and double tract reconstruction (5.3%, $n = 4$). The Petersen's space was closed in 65.3% ($n = 49$, March, 2016 ~ Dec, 2017), and mesentery fixing was performed in 34.9% of cases ($n = 29$, July 2017 ~ June, 2018). The mean follow-up period was 25.4 ± 7.6 months.

Clinicopathologic analysis between the closure and Mefix groups

There were no significant differences in age, BMI, TNM stage, operation time, hospital stay, or approach method between the closure group and the Mefix

Table 1. Patient demographics.

Factors	Value
Age (years)	60.9 ± 11.9
Sex	
Male	57 (76.0%)
Female	18 (24.0%)
BMI	22.2 ± 3.0
Tumor size (cm)	3.1 ± 1.6
TNM stage (AJCC TNM stage 7th edition)	
I	58 (77.3%)
II	14 (18.7%)
III	3 (4%)
Operation time (minutes)	254.1 ± 63.0
Hospital stay (days)	14.2 ± 10.1
Approach methods	
Laparoscopy	54 (72%)
Robot-assisted	21 (28%)
Operation type	
Subtotal gastrectomy	66 (88%)
Total gastrectomy	5 (6.7%)
Proximal gastrectomy	4 (5.3%)
Anastomosis type	
Billroth II	30 (40%)
RNY GJ	28 (37.3%)
uncut RNY GJ	9 (12%)
RNY EJ	4 (5.3%)
Double tract	4 (5.3%)
Petersen's space repair	
Closure	49 (65.3%)
Mesentery fixing	26 (34.9%)
Postoperative intestinal obstruction	1/75 (1.3%)
Follow up period (months)	25.4 ± 7.6

BMI: Body mass index; RNY: Roux-en Y; GJ: gastrojejunostomy; EJ: esophagojejunostomy; AJCC: AJCC TNM stage 7th edition; ASCPC: accordion severity classification of postoperative complications.

Table 2. Clinicopathologic comparison between Petersen closure group (closure) and distal mesentery fixing group (Mefix).

Factors	Closure group (N = 49)	Mefix group (N = 26)	p Value
Age (years)	61.1 ± 12.2	60.5 ± 11.4	.41
Sex			
Male	32	25	.003
Female	17	1	
BMI	21.9 ± 3.2	22.8 ± 2.6	.27
TNM stage*			
I	37	21	.28
II	11	3	
III	1	2	
Approach methods			
Laparoscopy	37	17	.32
Robot-assisted	12	9	
Operation type			
Subtotal gastrectomy	46	20	.01
Total gastrectomy	3	2	
Proximal gastrectomy	0	4	
Op time (minutes)	244.9 ± 55.3	244.5 ± 52.2	.85
Closure or jejunal mesentery fixing time (minutes)	7.5 ± 1.5	3.7 ± 1.1	<.001
Hospital stay (days)	11.8 ± 7.6	8.8 ± 3.6	.06
Follow up period (months)	27.9 ± 7.9	20.7 ± 4.0	<.01
Postoperative Petersen's hernia incidence	0	0	NS
Postoperative small bowel obstruction	1	0	1.0

*AJCC TNM stage 7th edition, BMI: Body mass index; RNY: Roux-en Y; GJ: gastrojejunostomy; EJ: esophagojejunostomy; ASCPC: accordion severity classification of postoperative complications; NS: not-significant.

group ($p > .05$) (Table 2). However, females were dominant in the closure group as compared to the Mefix group ($p = .003$), distal gastrectomy was more common in the closure group than in the Mefix group, and proximal gastrectomy was more common in the Mefix group than in the closure group ($p = .01$).

In terms of the operation time, there was no difference between the groups ($p = .06$); on the other hand, the procedure times for mesentery fixing (3.7 ± 1.1 min) were significantly shorter than those for Petersen's space closures (7.5 ± 1.5 min) ($p < .001$).

Comparison of Petersen's hernia incidence in the closure and Mefix groups

All patients visited the hospital at six months and one year after surgery, and a CT scan was performed to check for the recurrence of gastric cancer. We determined the incidence of Petersen's hernia by abdominal CT scan, and we found no incidence of Petersen's hernias in either group. We found one case of small bowel obstruction due to the kinking of the J-J site which occurred during the early postoperative period in the closure group (Table 2). In follow-up period, closure group (27.9 ± 7.9 months) had a significantly longer follow-up than the Mefix group (20.7 ± 4.0) ($p < .001$).

Discussion

The aim of this study was to compare the postoperative incidence of Petersen's hernia between individuals who underwent the Mefix and closure of Petersen's

space methods in order to investigate whether the Mefix method is not an inferior method compared to the closure method for preventing Petersen's hernias. We found no incidence of Petersen hernia one year postoperatively in either group, and we also found that the Mefix method had a shorter procedure time than the closure method.

One possible cause of the increasing incidence of Petersen's hernias is the recent development of minimally invasive surgery. A higher incidence of internal hernia is reported in minimally invasive gastrectomy than in open gastrectomy [3]. After open surgery, adhesion was formed between the small bowel and the operative wound site; however, with minimally invasive surgery, adhesion is remarkably decreased, due not only to the fact that there is no open wound in the upper abdomen, but also the use of antiadhesive agent [13]. The author encountered an internal hernia early in the postoperative period at Petersen's closure site, and we found that the Petersen's closure site was tearing and that the small bowel had herniated.

The Petersen's space defect should be closed to prevent internal hernia after gastrectomy with G-J for gastric cancers [3,14]. However, the closure of the defect at Petersen's space can induce bleeding by injuring the mesenteric vessels, as well as small bowel ischemia, caused by injuring the peripheral mesenteric vessels near the small bowel lumen. It has also been reported that early postoperative obstruction could be due to jejunal kinking of the closing site of the mesenteric defect [9]. The closure of mesenteric defects has increased the risk for severe postoperative complications in the early postoperative phase (<30 days) following the closure, mainly because of kinking of the jejunostomy site. We also encountered kinking of the jejunostomy in the early postoperative period after gastrectomy. However, it is not easy to determine whether the complications are due to kinking of the entero-entero anastomosis or to the adhesion effect from the closure of Petersen's space. After encountering kinking of the J-J, we tried to fix the mesentery to the peritoneum (Mefix) to avoid kinking of the J-J because the Mefix method, which can prevent the occurrence of Petersen's hernia, does not touch the bowel near the J-J site.

To prevent Petersen's hernias in laparoscopic procedures, there are two strategies. The first modality is the closure of the Petersen's defect itself between the small bowel mesentery and the transverse mesocolon [15]. Closures have reportedly been performed with nonabsorbable barbed V-LocTM sutures [14], with a

bioabsorbable prosthesis with fibrin glue fixing [16], and by closing the space with a laparoscopic stapler clip [17]. The second strategy is fixing of the small bowel. The fixing jejunal maneuver has been reported previously and is similar to the Mefix method [18]. The fixing jejunal maneuver was a single stitch with a nonabsorbable suture between the jejunal mesentery (10 cm from the duodenojejunal angle) and the transverse mesocolon. They reported that there were no Petersen's hernias in 52 cases of Roux-en-Y gastric bypass during a mean follow-up period of 15.1 months. This fixing jejunal maneuver [18] is different from our Mefix method as follows: First, the fixing points of the previous jejunal fixing maneuver are directly on the jejunum and the transverse mesocolon, whereas in the Mefix method, the fixing points are on the jejunal mesentery and the transverse mesocolon. The fixation of jejunum to mesocolon without closing the mesenteric defect can cause another internal hernia. Second, the fixing location in the jejunal fixing maneuver is 10 cm from the duodenojejunal angle before the enteroenterostomy site; however, the Mefix method fixes the mesentery with the peritoneum 30 cm below the area of the enteroenterostomy, which makes a trap for the jejunal mesentery to prevent excessive movement of small bowel to herniation. Third, the jejunal fixing maneuver was presented in a report that only analyzed the result of a single arm after fixing the jejunum. However, we compared the results from the Petersen closure and Mefix groups.

The theory of the Mefix method is as follows. When the mesentery of the small intestine is fixed to the transverse mesocolon between the small bowel and the colon mesentery, the defect still remains. However, the small bowel does not enter the defect because the small bowel mesentery is fixed at the transverse mesocolon; consequently, a Petersen's hernia does not occur. The major advantages of the Mefix method are that it does not cause postoperative obstruction because we handle only the mesentery, and it could make a relatively deep suture. Additionally, the Mefix method has a faster procedure time than the closure method. The Mefix method can also reduce the incidence of bleeding or ischemia due to injury of peripheral mesenteric vessels because the fixing suture for the Mefix procedure is along the long vascular recta and does not progress to the peripheral vascular arcade of the superior mesentery artery at the near site of the jejunum. In addition, the surgery may be more comfortable when it is a completion total gastrectomy for remnant gastric cancers,

since there is no adhesion between the mesentery and mesocolon near the G-J site.

This study had a retrospective design, and it has limitations. The number of cases was small, the follow-up period was rather short for the Mefix group, and there are no data related to clinical outcomes, including survival and recurrence. Additionally, the closure and Mefix groups were heterogeneous in terms of reconstruction methods, and fewer operative videos for review can limit the reliability of the procedure time. However, the Mefix method is a new concept and technique never before reported, and it is applicable not only in gastric cancer but also in obesity surgery, especially in the Roux-en-Y gastric bypass procedure.

In conclusion, we found no occurrence of Petersen's hernias postoperatively in either group, and we also found that the Mefix method was faster and easier to perform than the closure method. The Mefix method is an excellent alternative method to prevent the occurrence of Petersen's hernia after Roux-en-Y and B-II reconstruction.

Acknowledgements

The authors would like to thank Mi Kyung Seo, RN for assisting with data collection.

Ethical approval

All procedures followed were in accordance with the ethical standards of the responsible committee on human experimentation (institutional and national) and with the Helsinki Declaration of 1964 and later versions. The exemption from informed consent requirement was permitted by Gyeongsang National University Hospital in Changwon and at the Dongnam Institute of Radiological and Medical Sciences in Busan, Korea Institutional Review Board.

Declaration of interest

Dr. Jae-Seok Min, Sang-Ho Jeong, Ji-ho Park, Taehan Kim, Soon-Chan Hong, Eun-Jung Jung, Young-tae Ju, Chi-Young Jeong, Jin-Kwon Lee, Miyeong Park, and Young-Joon Lee have no conflicts of interest or financial ties to disclose.

ORCID

Jae-Seok Min  <http://orcid.org/0000-0002-5798-4595>
Sang-Ho Jeong  <http://orcid.org/0000-0001-9061-6236>

References

- [1] Petersen W. Ueber darmveschlingung nach der gastro-enterostomie. *Arch Klin Chir.* 1900;62:94–114.
- [2] Iannelli A, Facchiano E, Gugenheim J. Internal hernia after laparoscopic Roux-en-Y gastric bypass for morbid obesity. *Obes Surg.* 2006;16(10):1265–1271.
- [3] Kang KM, Cho YS, Min SH, et al. Internal hernia after gastrectomy for gastric cancer in minimally invasive surgery era. *Gastric Cancer.* 2019;22(5):1009–1015.
- [4] Bauman RW, Pirrello JR. Internal hernia at Petersen's space after laparoscopic Roux-en-Y gastric bypass: 6.2% incidence without closure—a single surgeon series of 1047 cases. *Surg Obes Relat Dis.* 2009;5(5):565–570.
- [5] Hosoya Y, Lefor A, Ui T, et al. Internal hernia after laparoscopic gastric resection with antecolic Roux-en-Y reconstruction for gastric cancer. *Surg Endosc.* 2011;25(10):3400–3404.
- [6] Himpens J, Verbrugge A, Cadiere GB, et al. Long-term results of laparoscopic Roux-en-Y gastric bypass: evaluation after 9 years. *Obes Surg.* 2012;22(10):1586–1593.
- [7] Kojima K, Inokuchi M, Kato K, et al. Petersen's hernia after laparoscopic distal gastrectomy with Roux-en-Y reconstruction for gastric cancer. *Gastric Cancer.* 2014;17(1):146–151.
- [8] Han WH, Eom BW, Yoon HM, et al. Clinical characteristics and surgical outcomes of internal hernia after gastrectomy in gastric cancer patients: retrospective case control study. *Surg Endosc.* 2019;33(9):2873–2879.
- [9] Stenberg E, Szabo E, Agren G, et al. Closure of mesenteric defects in laparoscopic gastric bypass: a multicentre, randomised, parallel, open-label trial. *Lancet.* 2016;387(10026):1397–1404.
- [10] Amor IB, Kassir R, Debs T, et al. Impact of mesenteric defect closure during laparoscopic Roux-en-Y gastric bypass (LRYGB): a retrospective study for a total of 2093 LRYGB. *Obes Surg.* 2019;29(10):3342–3347.
- [11] Japanese Gastric Cancer Association. Japanese classification of gastric carcinoma: 3rd English edition. *Gastric Cancer.* 2011;14:101–112.
- [12] Japanese Gastric Cancer Association. Japanese gastric cancer treatment guidelines 2014 (ver. 4). *Gastric Cancer.* 2017;20:1–19.
- [13] Park JH, Jeong SH, Lee YJ, et al. Current status of the use of antiadhesive agents for gastric cancer surgery: a questionnaire survey in South Korea. *J Korean Surg Soc.* 2013;84(3):160–167.
- [14] Hara K, Hayashi T, Nakazono M, et al. An easy and reliable method to close Petersen's defect using barbed suture to prevent internal hernia from developing after gastrectomy with Roux-en-Y reconstruction. *Asian J Endosc Surg.* 2020;13(2):238–241.
- [15] Hirahara N, Matsubara T, Hayashi H, et al. Easy and secure closure of Petersen's defect after laparoscopic distal gastrectomy with Roux-en-Y reconstruction. *J Laparoendosc Adv Surg Tech A.* 2015;25(1):55–59.
- [16] Magdy M, Suh H, Kuzinkovas V. Novel technique using a bioabsorbable prosthesis with fibrin glue

- fixation to prevent a Petersen's space hernia. *J Surg Case Rep.* 2017;12:rjx246.
- [17] Aghajani E, Nergaard BJ, Leifson BG, et al. The mesenteric defects in laparoscopic Roux-en-Y gastric bypass: 5 years follow-up of non-closure versus closure using the stapler technique. *Surg Endosc.* 2017;31(9):3743–3748.
- [18] Murad-Junior AJ, Scheibe CL, Campelo GP, et al. Fixing jejunal maneuver to prevent Petersen hernia in gastric bypass. *Arq Bras Cir Dig.* 2015;28(Suppl 1):69–72.