



Dose-dependent effects of mosapride citrate on duodenal and cecal motility in donkeys (*Equus asinus*)

Naglaa A. Gomaa, Hussam M.M. Ibrahim, Mitsuo Ishii, Medhat N. Nassif & Sabry A. El-khodery

To cite this article: Naglaa A. Gomaa, Hussam M.M. Ibrahim, Mitsuo Ishii, Medhat N. Nassif & Sabry A. El-khodery (2013) Dose-dependent effects of mosapride citrate on duodenal and cecal motility in donkeys (*Equus asinus*), International Journal of Veterinary Science and Medicine, 1:2, 51-56, DOI: [10.1016/j.ijvsm.2013.09.001](https://doi.org/10.1016/j.ijvsm.2013.09.001)

To link to this article: <https://doi.org/10.1016/j.ijvsm.2013.09.001>



© Faculty of Veterinary Medicine, Cairo University



Published online: 03 May 2019.



Submit your article to this journal [↗](#)



Article views: 93



View related articles [↗](#)



Citing articles: 5 View citing articles [↗](#)



Full Length Article

Dose-dependent effects of mosapride citrate on duodenal and cecal motility in donkeys (*Equus asinus*)

Naglaa A. Gomaa^a, Hussam M.M. Ibrahim^b, Mitsuo Ishii^c, Medhat N. Nassif^a, Sabry A. El-khodery^{b,d,*}

^a Department of Animal Medicine, Faculty of Veterinary Medicine, Kafrelsheikh University, Egypt

^b Department of Internal Medicine and Infectious Diseases, Faculty of Veterinary Medicine, Mansoura University, Mansoura 35516, Egypt

^c Large Animal Medicine Research Unit, Research Center for Animal Hygiene and Food Safety, Obihiro University of Agriculture and Veterinary Medicine, 2-11 Nishi, Inada-cho, Obihiro, Hokkaido 080-8555, Japan

^d Department of Internal Medicine, Faculty of Veterinary Medicine, University of Tripoli, 13662 Tripoli, Libya

Received 24 April 2013; revised 8 September 2013; accepted 9 September 2013

Available online 11 October 2013

KEYWORDS

Mosapride citrate;
Duodenum;
Caecum;
Ultrasonography;
Donkeys

Abstract Prokinetic drugs are used for the management of gastrointestinal motility disorders in horses; however, little is known about their efficacy in donkeys. Therefore, the aim of the present study was to evaluate the effect of different doses of mosapride citrate on duodenal and cecal motility in normal donkeys. Six donkeys ($n = 6$) were used in a crossover study. Mosapride citrate was administered orally via a nasogastric tube at dose rate of 1, 2 and 3 mg kg⁻¹. Duodenal and cecal motility were evaluated using ultrasonography before administration and at 15, 30, 60, 120 and 180 min post-administration. There was a significant increase of duodenal contractions ($p < 0.05$) after 30 min of mosapride citrate administration at 3 mg kg⁻¹ with a prolonged ($p < 0.05$) prokinetic effect at 2 mg kg⁻¹. Cecal contractions were significantly increased ($p < 0.05$) after 15 min at different doses of mosapride with a prolonged effect at 3 mg kg⁻¹. The results of the present study indicate that mosapride citrate has a dose-dependent prokinetic effect

Abbreviations: POI, post-operative ileus; GI, gastro-intestinal; 5-HT₄, 5-hydroxytryptamine 4; B.W., body weight; Mg kg⁻¹, milligram per kilogram body weight

* Corresponding author at: Department of Internal Medicine and Infectious Diseases, Faculty of Veterinary Medicine, Mansoura University, Mansoura 35516, Egypt. Tel.: +20 50 2216625; fax: +20 50 2247900.

E-mail address: khodery@mans.edu.eg (S.A. El-khodery).

Peer review under responsibility of Faculty of Veterinary Medicine, Cairo University.



Production and hosting by Elsevier

on the duodenal and cecal contractions in healthy donkeys. Further studies need to determine whether mosapride citrate is effective in treatment of intestinal disorders in donkey.

© 2013 Production and hosting by Elsevier B.V. on behalf of Faculty of Veterinary Medicine, Cairo University.

1. Introduction

Gastrointestinal motility disorders are common in donkeys and result in colic. The main disorders are intestinal impaction and typhlocolitis [1–3]. Impaction colic represents 50% of the colic episodes in donkeys with incidence rate of 3.9 per 100 donkeys per year [4]. The impaction was diagnosed in all parts of the intestine, but the majority of impactions (51%) occurred in the pelvic flexure [5]. The recovery rate in donkeys with impaction colic was approximately 49% [4].

Prokinetic drugs are commonly used for management of Post-operative ileus (POI) in horses [6]. Generally, prokinetic agents increase the release or availability of acetylcholine from cholinergic pathways (e.g., neostigmine), enhance activity at dopamine-1 and 5-hydroxytryptamine 4 (5-HT₄) receptors and antagonize inhibitory neurotransmitters (e.g., metoclopramide), or simulate non-cholinergic non-adrenergic molecules that promote contractile activity (e.g., erythromycin) [7].

The recently developed GI prokinetic agent (mosapride citrate) is a substituted benzamide that acts as a selective 5-HT₄ agonist; thereby it is increasing neuronal release of acetylcholine from nerve endings in the digestive tract and promoting GI motility including small intestine and caecum of experimental animals and horses [8,9]. Mosapride citrate has been demonstrated to promote jejunal and cecal motility in normal horses without adverse effects compared with other prokinetic agents [10,11].

At the moment, only limited information is available about intestinal motility disorders in donkeys. Ultrasonographic examination is a valuable non-invasive method for evaluating intestinal motility in horses [12–15]. Therefore, the purpose of the present study was to evaluate the effect of different doses of mosapride citrate on the duodenal and cecal motility in donkeys using ultrasonography.

2. Materials and methods

2.1. Study overview and animals

Six adult healthy donkeys (*Equus asinus*), (4 geldings and 2 mares) were used in a crossover study. The age of donkeys ranged from 9 to 17 years and body weight from 100 to 220 kg. None of those donkeys had gastrointestinal disorders or evidence of systemic diseases. Two weeks before starting the study, each donkey was stabled on straw-bedded boxes and fed twice a day with 1 kg hay/100 kg B.W. and 0.5 kg concentrate with unlimited access to water. This study was carried out at Department of Animal Medicine, Faculty of Veterinary Medicine, Kafr El-sheikh University, Egypt. These trials were approved by Animal Welfare and Ethics Committee, Faculty of Veterinary Medicine, Kafr Elsheikh University.

2.2. Protocol of the study

Each donkey underwent four trials with one week interval between each trial and the consecutive one. Each trial was started one hour after feeding. Intestinal contractions at descending duodenum and body of cecum were counted via ultrasonography. The first trial was carried out by oral administration of 1000 ml of clean water via a nasogastric tube (control group). Second, third and fourth trials were conducted by oral administration of mosapride citrate (Gasmotin powder®, Dainippon Pharmaceutical Co., Ltd., Japan) dissolved in 1000 ml of water at dose rates of 1, 2 and 3 mg kg⁻¹ respectively (treated groups). The intestinal contractions were counted over a period of 3 min before treatment and at 15, 30, 60, 120 and 180 min post-treatment. During the monitoring periods, there was no access to food or water. Evidence of any adverse effects as behavioral abnormalities was also monitored following the administration of mosapride citrate.

2.3. Ultrasonographic examination

Transcutaneous ultrasonographic examinations were performed with a 5 MHz curved-linear transducer (CHISON Digital Color Doppler Ultrasound system, iVis 60 EXPERT VET, CHISON Medical Imaging Co., Ltd.). The donkeys were restrained in stocks without any sedation during ultrasonographic examinations. The position of the descending duodenum and cecal body in each donkey was identified before the beginning of ultrasonographic examinations. The descending duodenum was located at the right thoracic area extending from the 8th to the 18th rib along the line joining the olecranon and tuber coxae. The cecal body was identified in the upper part of the right para-lumbar region. The abdomen was clipped at those identified regions, cleaned with alcohol and then coupling gel was applied to enhance the contact with the probe.

Intestinal contractions per three min were counted via ultrasonographic examination according to Freeman [13], Mitchell et al. [14] and Gomaa et al. [15]. One hour after feeding, ultrasonographic examinations and counting of segmental contractions were carried out at 9:00 AM by the same person to avoid any individual variations and revised again by two persons to overcome the lack of randomization and blindness during drug administration.

2.4. Statistical analyses

Data analyses were performed using a statistical software program (SPSS for windows Version 16, SPSS Inc., Chicago, USA). Data were tested for normal distribution using Kolmogorov-Smirnov test. The data were normally distributed; there-

fore, mean and standard deviation for each assessed treatment at each time point was calculated. ANOVA (with repeated measures on dose and time) were used to determine the main effect of dose and time. Wilks' Lambda test indicated a statistically significant difference between groups. One way ANOVA with Turkey *post-hoc* multiple comparison tests was used to identify which group was statistically different from the rest. Differences between means at $p < 0.05$ were considered significant.

3. Results

The descending duodenum was constantly observed at 12th–13th intercostal space. During ultrasonographic examination, descending duodenum was visualized between the liver and the right dorsal colon as an oval to round shape (Figs. 1 and 2). Only the segmental contractions of descending duodenum were counted.

The cecal body's wall appeared as a mobile hypoechoic line overlying a hyperechoic gas shadow adjacent to the right abdominal wall by ultrasonographic examination (Fig. 3). In the cecum, the normal motility comprised either localized segmental contractions (mixing) or propagating (propulsive) motility in both forward and backward directions during ultrasonographic examination. The cecal contractions were counted by visualizing the movement of cecal body away from abdominal wall (Fig. 4).

The duodenal and cecal body contractions before treatments were 6.9 ± 1.3 and 4.0 ± 0.8 contractions/3 min, respectively. Furthermore, administration of clean water did not exert a significant effect on both duodenal and cecal body contractions.

Mosapride citrate showed a dose-dependent effect on duodenal contractions (Wilks, Lambda test for time effect, $p < 0.05$; Wilks, Lambda test for time x dose interaction, $p < 0.05$). At a dose rate of 3 mg kg^{-1} the duodenal contractions were increased significantly after 30 min post-administration compared with control (13.7 ± 4.8 vs 8.3 ± 1.8 contractions/3 min). At 120 min. post-administration, doses of 2 and 3 mg kg^{-1} were significantly higher than control. However, at 180 min, only 2 mg kg^{-1} showed a significant increase compared with control (Fig. 5).

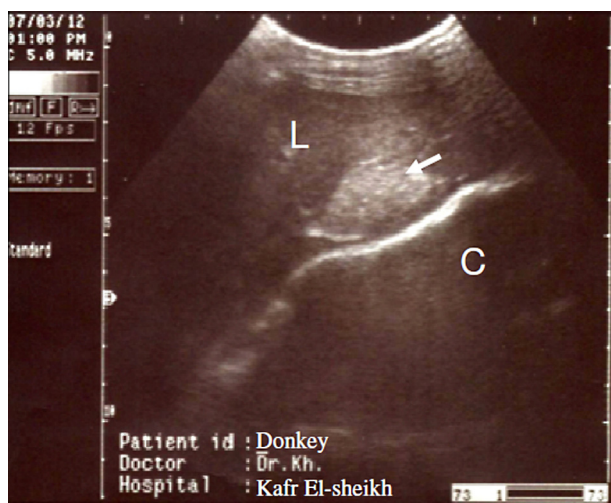


Fig. 1 Ultrasonographic picture of descending duodenum in a donkey during relaxation phase. (C) right dorsal colon; (L) liver; (Arrow) duodenum which appears an oval shape.

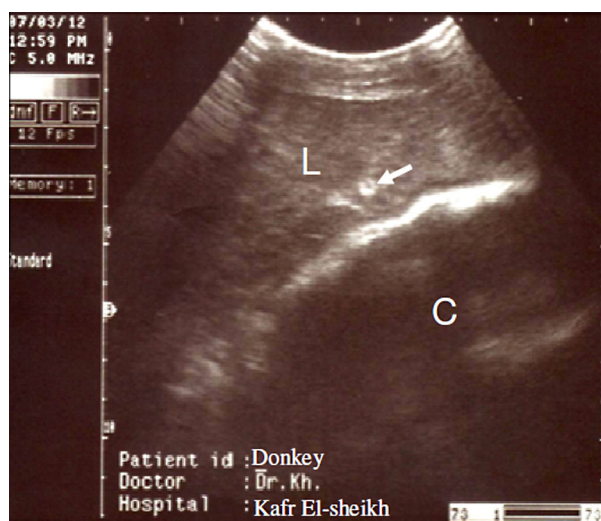


Fig. 2 Ultrasonographic picture of descending duodenum in a donkey during segmental contraction phase. (C) right dorsal colon; (L) liver; (Arrow) duodenum which appears a round shape.

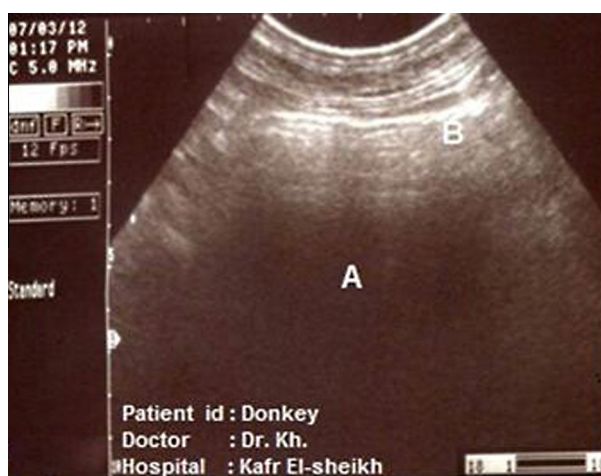


Fig. 3 Ultrasonographic picture of cecum in a donkey. It appears adjacent to body wall at the most upper part of picture. The cecal wall (B) appears hyperechoic line from multiple refraction, and acoustic shadow (A) from gas in cecum.

A dose-dependent effect of mosapride citrate on cecal motility was also recorded (Wilks, Lambda test for time effect, $p < 0.05$; Wilks, Lambda test for time x dose interaction, $p < 0.05$). Cecal motility increased after 15 min post-administration at 1, 2 and 3 mg kg^{-1} (4.3 ± 0.5 , 6.5 ± 1.4 , 6.0 ± 1.3 contractions/3 min, respectively). Only at a dose rate of 3 mg kg^{-1} , the motility still has a significant increase at 120 min post-administration (Fig. 6).

Regarding to adverse effect, no behavioral abnormalities or other adverse reactions was observed in treated donkeys at different dose rates.

4. Discussion

Prokinetic drugs are usually used for management of POI in horses after small intestinal injury but less commonly used for large intestinal disorders [6]. In donkeys, although large

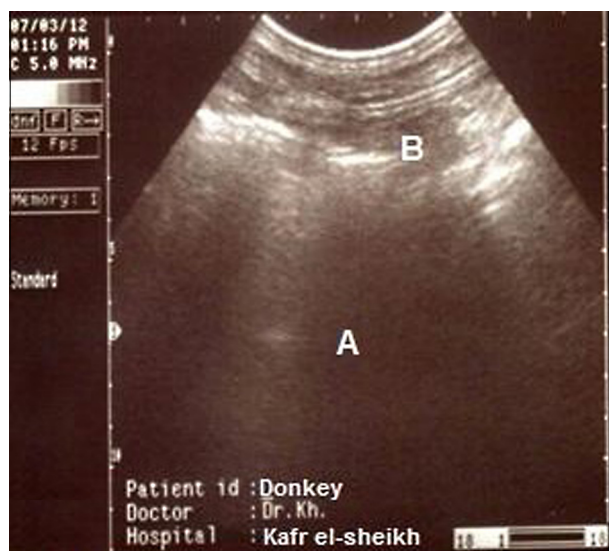

Fig. 4 Ultrasonographic picture of cecum during mixing contraction. The cecal body wall (B) moves away the abdominal wall about 2 cm which representing the mixing contraction. An acoustic shadow (A) from has in cecum.

intestinal impaction is the most common disorder [1–4], occurrence of other motility disorders cannot be ruled out. The present study was constructed to evaluate the duodenal and cecal motility in donkeys and to assess the prokinetic effect of different doses of mosapride citrate. For this purpose, transcutaneous abdominal ultrasonography was used.

Duodenum and cecum could be easily visualized because they are a relatively superficially located adjacent to the abdominal wall. This result is in concurrent with previous reports in horses and ponies [12,15,16]. Before treatment, the frequency of duodenal and cecal contractions in donkeys was 6.9 ± 1.3 and 4.0 ± 0.8 contractions/3 min, which are closely similar those in horses [14,15,17]. It appears that donkeys may have decreased duodenal contractions than ponies [16]. Variations in duodenal and cecal contractions among members of

equidae were attributed to time of ultrasonographic examination, feeding practice and diet composition [16]. Our ultrasonographic findings in donkeys are in agreement with previous studies, which highlight the importance of ultrasound as non-invasive technique for examination of gastrointestinal tract in equines [13,18]. On the contrary, electrointestinography (EIG) has been found superior to ultrasonography to assess the intestinal motility, because EIG can be performed continuously for 24 h, and can determine intestinal smooth muscle contractility more objectively [19].

In this study, mosapride citrate provided a dose-dependent effect on duodenal contraction ($p < 0.05$). The effect started at 30 min post-administration, and persisted until 3 h. Other studies reported an increase in gastric emptying in horses after 30 min of oral administration of 1 mg kg^{-1} of mosapride citrate [9,20] and also a significant increase in small intestinal motility after 120 min at 2 mg/kg of mosapride citrate [11]. This could be attributed to the effect of mosapride as substituted benzamide selective 5-HT₄ agonist on the motility of GI tract [21,22].

5-HT₄ receptors are abundantly distributed along the GI tract and modulate smooth muscle tone, peristaltic reflex and mucosal secretion [23,24]. Mosapride selectively acts on 5-HT₄ receptors and increases the level of acetylcholine released from cholinergic nerve endings in the digestive tract [7,9,24]. Acetylcholine binds to muscarinic receptors on the smooth muscle and stimulates the contractions [25,26]. Another mode of action of mosapride citrate is based on the pharmacological effect of mosapride on gastrointestinal function, which is closely related to changes in motilin immunoreactive substance level in plasma. In human, the peak of plasma motilin level is achieved 60 min after oral administration of a single dose of mosapride, and returns to base line level within 120 min [27].

Based on the pharmacokinetics of oral mosapride in horses, the maximum concentration of mosapride (C_{max}) in plasma is a dose dependent. The C_{max} reaches the highest level at a dose rate of 1.5 mg kg^{-1} . However, the time to peak serum concentration (t_{max}) and apparent serum elimination half-life ($t_{1/2}$) reach the highest level at a dose rate of 0.5 mg kg^{-1} [28]. Similar to the present result, a dose-dependent effect of mosapride

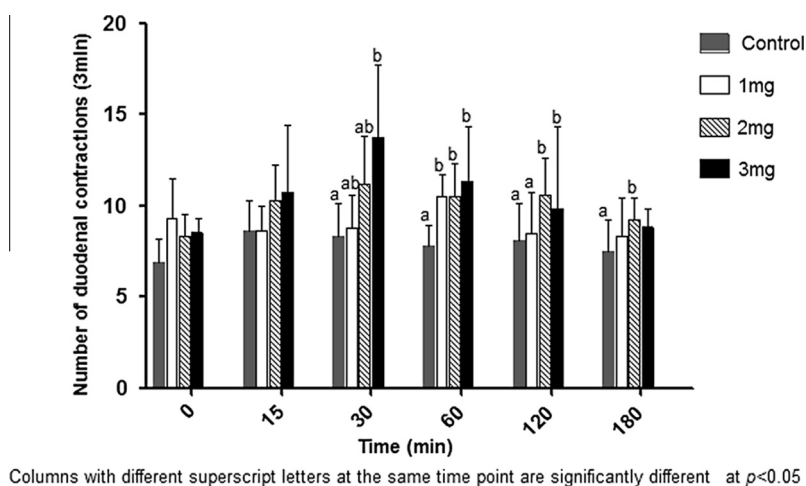
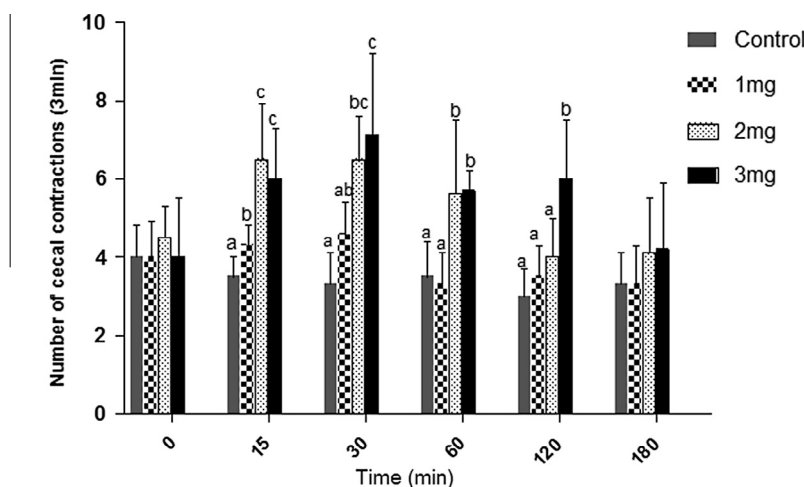


Fig. 5 Duodenal contractions (number/3 min) in donkeys after oral administration of different doses of mosapride citrate.



Columns with different superscript letters at the same time point are significantly different at $p < 0.05$

Fig. 6 Cecal contractions (number/3 min) in donkeys after oral administration of different doses of mosapride citrate.

on gastric emptying has also been reported in mice for the dosage range of 0.03–3.0 mg kg⁻¹ [7].

Actually, the pharmacokinetic profile of mosapride citrate is quite different from human to animal and from animal to another [29]. It depends mainly on the first pass effect of mosapride or its bio-availability or metabolism. It is suggested that mosapride undergoes less first pass effect in horse [28] than in dog and monkey [30], but higher than human [31]. The maximum serum levels of the mosapride reach 1–2 h after oral administration in horses [28]. It is also suggested that half-life ($t_{1/2}$) of mosapride in horses is 2 folds longer than in healthy man. This criterion is attributed to low metabolism of mosapride citrate in horses compared with human [28,32]. In the present study, although the prokinetic effect of oral mosapride citrate is closely similar to those reported in horses, complete pharmacokinetic profile of mosapride citrate in donkeys is needed to have more accurate conclusion.

In this study, mosapride citrate showed a dose-dependent ($p < 0.05$) prokinetic effect on cecal motility in donkeys at 2 and 3 mg kg⁻¹ which started after 15 min of oral administration. This conflicted with other previous studies on horses that reported an increase of cecal motility after 180 to 300 min at 2 mg kg⁻¹ of mosapride administration [20]. This could be attributed to difference of mosapride metabolism in donkeys from horses. The rapid effect of mosapride citrate on cecal motility rather than on duodenum could be attributed to the activation of muscarinic receptors, which are more concentrated in cecum and colon [33]. Previous studies suggested that neither intravenous nor oral administration of 1 mg kg⁻¹ of mosapride citrate was effective in the lower region of gastrointestinal tract in dogs [22,34]. However, other reports concluded that mosapride could improve colonic motility at 3 mg kg⁻¹ in rat and at 2 mg kg⁻¹ in horse [20,34].

According to this study, the administration of mosapride citrate at 2 mg kg⁻¹ has a similar effect to 3 mg kg⁻¹ on duodenum and cecal contractions. Therefore, 2 mg kg⁻¹ is considered to be sufficient to promote the duodenal and cecal motility in donkey. However, it was recorded that mosapride citrate has a prolonged effect on duodenal and cecal contractions at 2 and 3 mg kg⁻¹ respectively. This enhancement of colonic motility as well as duodenal motility may lead to

improvement of constipation with dysfunction of the lower GI motility [21].

Interestingly, mosapride citrate showed no adverse effect in experimental donkeys. Similar findings have been reported in horses [20] and human [35]. In dogs, oral administration of mosapride citrate at 3 mg kg⁻¹ could alter the electrocardiographic parameters by increasing the heart rate, shortening QT interval and prolongation of the QTc [36]. Cisapride may also trigger tachycardia and supraventricular dysrhythmia through stimulation of 5-HT₄ atrial receptors [37].

The present investigation was constructed as a crossover study, which doesn't allow for randomization of the order for mosapride and water administration. Water was administered first to prevent residual effects of mosapride during the water administration period. The other limitations of present study are lack of information about the pharmacokinetic of mosapride citrate in donkeys and failure to assess the propulsive contractions of the duodenum and cecum. Therefore, avoidance of these limitations in further studies is warranted.

In conclusion, mosapride citrate showed dose-dependent effects on small intestinal and cecal motility in conscious donkeys without any adverse effects. Mosapride at 2 mg kg⁻¹ seems to be the most effective prokinetic dose, which promotes duodenal and cecal contraction. However, 3 mg kg⁻¹ is more efficient on cecal contractions. These findings could be unpractical in donkeys with GIT dysfunction. Therefore, further studies on the effect of mosapride citrate in donkeys with ileus or cecal impaction are needed.

References

- [1] Duffield H., Bell N, Henson FMD. The common presenting signs and causes of colic in the donkey. In: BEVA, editors, Proceedings of the 41st British Equine Veterinary Association Congress, Glasgow, UK 2002; p. 214.
- [2] Fintl C, Hudson NP, Pearson GT, Gallagher J, Mayhew IG. A study of the interstitial cells of Cajal in aged donkeys with and without intestinal disease. *J Comp Pathol* 2010;142:242–7.
- [3] Toit N, Burden FA, Getachew M, Trawford AF. Idiopathic typhlocolitis in 40 aged donkeys. *Equine Vet Educ* 2010;22(2):53–7.

- [4] Cox R, Proudman CJ, Trawford AF, Burden F, Pinchbeck GL. Epidemiology of impaction colic in donkeys in the UK. *Biomed Cent Vet Res* 2007;3:1–11.
- [5] Cox R, Burden FA, Gosden L, Proudman C, Trawford AF, Pinchbeck GL. Case control study to investigate risk factors for impaction colic in donkeys in the UK. *Prev Vet Med* 2009;92:179–87.
- [6] Van Hoogmoed LM, Nieto JE, Snyder JR, Harmon FA. Survey of prokinetic use in horses with gastrointestinal injury. *Vet Surg* 2004;33:279–85.
- [7] Reynolds JC, Putnam PE. Prokinetic agents. *Gastroenterol Clin North Am* 1992;21:567–97.
- [8] Kim HS, Choi EJ, Park H. The effect of mosapride citrate on proximal and distal colonic motor function in the guinea-pig in vitro. *Neurogastroenterol Motil* 2008;20:169–76.
- [9] Okamura K, Sasaki N, Kikuchi T, Murata A, Lee I, Yamada H, Inokuma H. Effects of mosapride on motility of the small intestine and caecum in normal horses after jejunocecostomy. *J Vet Sci* 2009;10:157–60.
- [10] Tonini M, Cipollina L, Poluzzi E, Crema F, Corazza GR, De Ponti F. Review article: clinical implications of enteric and central D2 receptor blockade by antidopaminergic gastrointestinal prokinetics. *Aliment Pharmacol Ther* 2004;19:379–90.
- [11] Sasaki N, Okamura K, Yamada H. Effects of mosapride, a 5-hydroxytryptamine 4 receptor agonist, on electrical activity of the small intestine and cecum in horses. *Am J Vet Res* 2005;66:1321–3.
- [12] Kirberger MR, Berg J, Gottschalk RD, Guthriem A. Duodenal ultrasonography in the normal adult horse. *Vet Radiol Ultrasound* 1995;36:50–6.
- [13] Freeman LS. Ultrasonography of the equine abdomen: techniques and normal findings. In *Practice* 2002;24:204–11.
- [14] Mitchell CF, Malone ED, Sage AM, Niksich K. Evaluation of gastrointestinal activity in healthy horses using B mode and Doppler ultrasonography. *Can Vet J* 2005;46:134–40.
- [15] Gomaa N, Uhlig A, Schusser GF. Effect of Buscopan compositum on the motility of the duodenum, cecum and left ventral colon in healthy conscious horses. *Berl Munch Tierarztl Wochenschr* 2011;124:168–74.
- [16] Epstein K, Short D, Parente E, Reef V, Southwood L. Gastrointestinal ultrasonography in normal adult ponies. *Vet Radiol Ultrasound*. 2008;49:282–6.
- [17] Freeman LS, England CWG. Effect of romifidine on gastrointestinal motility, assed by transrectal ultrasonography. *Equine Vet J* 2001;33:570–6.
- [18] Kihurani DOG, Carstens A, Saulez MN, Donnellan CBM. Transcutaneous ultrasonographic evaluation of the air-filled equine stomach and duodenum following gastroscopy. *Vet Radiol Ultrasound* 2009;50:429–35.
- [19] Sasaki N, Murata A, Lee I, Yamada H. Evaluation of equine cecal motility by auscultation, ultrasonography and electrointestinography after jejunocecostomy. *Res Vet Sci* 2008;84:305–10.
- [20] Okamura K, Sasaki N, Yamada M, Yamada H, Inokuma H. Effects of mosapride citrate, metoclopramide hydrochloride, lidocaine hydrochloride, and cisapride citrate on equine gastric emptying, small intestinal and caecal motility. *Res Vet Sci* 2009;86:302–8.
- [21] Inui A, Yoshikawa T, Nagai R, Yoshida N, Ito T. Effects of mosapride citrate, a 5-HT4 receptor agonist, on colonic motility in conscious guinea pigs. *Jpn J Pharmacol* 2002;90:313–20.
- [22] Mine Y, Yoshikawa T, Oku S, Nagai R, Yoshida N, Hosok K. Comparison of effect of mosapride citrate and existing 5-HT4 receptor agonists on gastrointestinal motility in vivo and in vitro. *J Pharmacol Exp Ther* 1997;283:1000–8.
- [23] Hegde SS, Eglan RM. Peripheral 5-HT4 receptors. *J Federation Soc Exp Biol* 1996;10:1398–407.
- [24] Grider JR, Foxx-Orenstein AE, Jin JG. 5-Hydroxytryptamine 4 receptor agonists initiate the peristaltic reflex in human, rat and guinea-pig intestine. *Gastroenterology* 1998;115:370–80.
- [25] Boeckxstaens GE, Pelckmans PA, Rampart M. Pharmacological characterization of 5-hydroxytryptamine receptors in the canine terminal ileum and ileocolonic junction. *J Pharmacol Exp Ther* 1990;254:652–7.
- [26] Schuurkes JAJ. Facilitation of acetylcholine release via serotonin receptors: effect of cisapride? In: Heading RC, Wood JD, editors. *Gastrointestinal dysmotility: focus on cisapride*. New York: Raven Press, Ltd.; 1992. p. 107–15.
- [27] Itoh H, Naganot T, Takeyama T. Effect of mosapride citrate on human plasma level of motilin, gastrin, somatostaine and secretin. *Biol Pharm Bull* 2001;24:1072–5.
- [28] Okamura K, Sasaki N, Fukunaka M, Yamada H, Inokuma H. Pharmacokinetics of the gastroprokinetic agent mosapride citrate after single oral administration in horses. *J Vet Med Sci* 2010;72:1023–6.
- [29] Matsumoto S, Tagawa M, Amejima H, Nakao M, Kagemoto A, Fujii T, Miyazaki H, Sekine Y. Absorption, distribution and excretion of [carbonyl-14C] mosapride citrate after a single oral administration in rats, dogs and monkeys. *Arzneimittelforschung* 1993;43:1084–94.
- [30] Sakashita M, Mizuki Y, Yamaguchi T, Miyazaki H, Sekine Y. Pharmacokinetics of the gastrokinetic agent mosapride citrate after intravenous and oral administrations in dogs and monkeys. *Arzneimittelforschung* 1993;43:864–6.
- [31] Sakashita M, Yamaguchi T, Miyazaki H, Sekine Y, Nomiyama T, Tanaka S, Miwa T, Harasawa S. Pharmacokinetics of the gastrokinetic agent mosapride citrate after single and multiple oral administrations in healthy subjects. *Arzneimittelforschung* 1993;43:867–72.
- [32] Okamura K, Sasaki N, Fukunaka M, Yamada H, Inokuma H. The prokinetic effect of mosapride citrate on horse gastric emptying rates. *J Vet Med Sci* 2008;70:627–8.
- [33] Tytgat NG. Hyoscine butylbromide. a review of its use in the treatment of abdominal cramping and pain. *Drugs* 2007;67:1343–57.
- [34] Yoshida N, Ito T, Karasawa T, Itoh Z. AS-4370, a new gastrokinetic agent, enhances upper gastrointestinal motor activity in conscious dogs. *J Pharmacol Exp Ther* 1991;257:781–7.
- [35] Carlsson L, Amos GJ, Andersson B, Drews L, Duker G, Wadstedt G. Electrophysiological characterization of the prokinetic agents cisapride and mosapride in vivo and in vitro: implications for proarrhythmic potential. *J Pharmacol Exp Ther* 1997;282(220):7.
- [36] Chae JS, Ahn JO, Coh YR, Park CW, Youn HY. Effects of 5-HT4 selective receptor agonist, mosapride citrate on electrocardiogram in dogs. *Korean J Vet Res* 2012;2012(52):163–7.
- [37] Kaumann AJ, Sanders L. 5-Hydroxytryptamine causes rate-dependent arrhythmias through 5-HT4 receptor in human atrium: facilitation by chronic β -adrenoceptor blockade. *Naunyn-Schmiedeberg's Arch Pharmacol* 1994;349(331):7.