



## Molecular genotyping of the infectious bursal disease virus (IBDV) isolated from Broiler Flocks in Egypt

Sara Abdel Mawgod, Abdel Satar Arafa & Hussein A. Hussein

To cite this article: Sara Abdel Mawgod, Abdel Satar Arafa & Hussein A. Hussein (2014) Molecular genotyping of the infectious bursal disease virus (IBDV) isolated from Broiler Flocks in Egypt, International Journal of Veterinary Science and Medicine, 2:1, 46-52, DOI: [10.1016/j.ijvsm.2014.02.004](https://doi.org/10.1016/j.ijvsm.2014.02.004)

To link to this article: <https://doi.org/10.1016/j.ijvsm.2014.02.004>



© Faculty of Veterinary Medicine, Cairo University



Published online: 03 May 2019.



Submit your article to this journal [↗](#)



Article views: 388



View related articles [↗](#)



View Crossmark data [↗](#)



Citing articles: 8 View citing articles [↗](#)



Cairo University

International Journal of Veterinary Science and Medicine

www.vet.cu.edu.eg  
www.sciencedirect.com



Full Length Article

# Molecular genotyping of the infectious bursal disease virus (IBDV) isolated from Broiler Flocks in Egypt



Sara Abdel Mawgod <sup>a,\*</sup>, Abdel Satar Arafa <sup>a</sup>, Hussein A. Hussein <sup>b</sup>

<sup>a</sup> National Laboratory for Veterinary Quality Control on Poultry Production, Animal Health Research Institute, P.O. Box 264, Dokki, Giza 12618, Egypt

<sup>b</sup> Virology Department, Faculty of Veterinary Medicine, Cairo University, Giza 11221, Egypt

Received 2 January 2014; revised 21 February 2014; accepted 28 February 2014

Available online 2 June 2014

## KEYWORDS

Infectious bursal disease virus (IBDV);  
VP2 gene hypervariable region;  
Molecular characterization of IBDV

**Abstract** Re-emergence of highly virulent forms of IBDV has been the cause of significant economic losses. In present study, 52 bursa samples were assayed using reverse transcriptase-polymerase chain reaction (RT-PCR) for IBDV targeting VP2 gene. Out of the tested samples 20 were positives. Eleven IBDV-positive samples were selected for further isolation and characterization. Histopathological analysis of the bursa revealed necrosis, presence of depleted follicles and some infiltration of heterophils, characteristic to previously reported in IBDV. The virus was isolated by inoculating bursa suspension into embryonated specific pathogen-free (SPF) eggs. Chorioallantoic membrane(s) (CAMs) were collected and tested by AGPT confirming the presence of IBDV. The virus was detected by RT-PCR and sequence analysis of PCR products of 11 selected samples was carried out. Nine samples were characterized as very virulent (vvIBDV) and 2 samples were classical IBDV similar to vaccine strains. The genotyping of Egyptian vvIBDV indicate progressive evolution of IBDV in Egypt and they were closely related to previous isolated strains from Egypt.

© 2014 Production and hosting by Elsevier B.V. on behalf of Faculty of Veterinary Medicine, Cairo University.

**Abbreviations:** IBDV, infectious bursal disease virus; HVR, hypervariable region; VP2, viral protein 2; RT-PCR, reverse transcription-polymerase chain reaction; CAM, chorio-allantoic-membrane; AGPT, agar gel precipitation test

\* Corresponding author. Tel.: +2 0224398235, +2 01006282405; fax: +2 0233370957.

E-mail address: [drsara\\_vet2006@yahoo.com](mailto:drsara_vet2006@yahoo.com) (S.A. Mawgod).

Peer review under responsibility of Faculty of Veterinary Medicine, Cairo University.



Production and hosting by Elsevier

## 1. Introduction

IBD is a highly contagious and acute viral disease that is characterized by destruction of lymphoid cells in the bursa of fabricius causing severe immunosuppression [1,2]. IBDV was first recognized as a disease entity in “Gumboro” district of Delaware State in USA in 1957 by A.S. Cosgrove while it was first recorded in Egypt by El-Sergany in 1974 [3,4]. IBDV belongs to the genus Avibirnavirus of the family Birnaviridae. The genome consists of two segments, A and B, of double-stranded RNA, which are encapsidated within a single-shelled

icosahedral particle with a diameter of 65–70 nm. The larger segment, A, encodes a polyprotein of approximately 110 kDa that is proteolytically cleaved by the viral protease VP4 to form the viral proteins (VP) VP2, VP3, and VP4 and four structural peptides deriving from the VP2 precursor, pVP2. A second open reading frame preceding and partially overlapping the polyprotein gene encodes VP5, which has been detected both in IBDV-infected chicken embryo cells and in bursal cells of IBDV-infected chickens [5].

Two distinct serotypes of the virus have been recognized. Serotype 1 viruses are pathogenic to chickens while serotype 2 viruses are nonpathogenic. Serotype 1 has been divided into several groups on the basis of antigenic variation and virulence: classical strains, variant strains, and very virulent strains [6]. Classic IBDV strains cause bursal damage and lymphoid necrosis resulting into 20–30% mortality [7]. In the mid-1980s very virulent (vv) IBDV strains emerged and caused devastating outbreaks resulting in 30% and 60–70% mortality in broiler and layers, respectively, then spread to Middle East, Asia, Africa and South America [5,8]. In Egypt very virulent were reported since its first introduction in 1989 [9]. Variant IBD strains were also reported in Egyptian flocks [10]. Presently, evidence of circulating variant IBDV strains was isolated from flocks vaccinated using classical IBDV vaccines [11,12].

The use of molecular techniques to detect and identify IBDV strains has increased in recent years. RT-PCR have been used to amplify sections of the IBDV genome. The VP2 gene is commonly studied because it encodes for the major protective epitopes, contains determinants for pathogenicity, and is highly variable among strains [8,13].

The infectious bursal disease virus continuous to be a serious problem in Egypt. The aim of this study was to determine the molecular characterization of IBDV recently isolated from Broiler Flocks in Egypt using RT-PCR, isolation and sequence analysis of HVR part of the VP2 gene. In present study, 50 broiler outbreaks over the period 2012–2013 were investigated in an attempt to molecular characterization of IBDV using RT-PCR, isolation, sequence analysis of HVR part of the VP2 gene, and histopathological examination.

## 2. Materials and methods

### 2.1. Field samples

During 2012–2013, broiler farms in different Egyptian Governorates showed sudden onset of high mortality. Necropsy revealed haemorrhages and gelatinous exudates in Bursa of Fabricus. Fifty-two bursae were collected for viral isolation and detection by RT-PCR.

### 2.2. Histopathological examination

The specimens for histopathology were dehydrated in several grades of alcohol, embedded in paraffin and sectioned at 4 µl thickness, then stained by H&E stain for bursa samples [15].

### 2.3. IBDV detection by RT-PCR

RNAs were extracted from the Bursal homogenates [one part of each bursa sample disrupting in sterile saline (1:1)] using QIAmp Viral RNA Mini kit (Qiagen GmbH, Hilden,

Germany) according to the manufacturer's instructions. A set of primers were used for the RT-PCR reaction and for the subsequent sequence analysis using forward and reverse PCR primers for amplification of a 620 bp fragment within IBDV on VP2:

Forward primer: [AUS GU: 5'-TCA CCG TCC TCA GCT TAC CCA CAT C-3'].

Reverse primer: [AUS GL: 5'-GGA TTT GGG ATC AGC TCG AAG TTG C-3'] [14].

Briefly, the 50 µl reaction mixture contained 10 µl of extracted RNA, 10 µl of 5× RT-PCR buffer, 2 µl primer F, 2 µl primer R, 2 µl dNTP mix containing 400 µM each dATP, dGTP, dCTP, dTTP, and 2 µl of Qiagen One Step Enzyme Mix. A fragment of 620 bp of the 5'-noncoding region was amplified by PCR thermo cycling using (T3 Biometra-Germany) as follows: 20 min at 50 °C (RT reaction); 95 °C for 15 min (initial PCR activation); 39 three-step cycles of 94 °C for 30 s (denaturation), 59 °C for 40s (annealing) and 72 °C for 1 min; then 72 °C for 10 min (final extension). After amplification, 5 µl of PCR products were analyzed by electrophoresis on a 1.5% agarose gel containing ethidium bromide with final concentration of 0.5 µg/ml at 95 V for 30 min in 1× TBE buffer, against GeneRuler™ 100 bp Plus DNA Ladder (Fermentas). Images of the gels were photographed on BioDoc Analyze Digital Systems (Biometra, Germany).

### 2.4. Virus isolation

For virus isolation, a 10% suspension was prepared in PBS (phosphate buffer saline) with 1 mg/mL of streptomycin sulphate, 0.4 mg/mL of gentamicin sulphate and 1000 UI/mL of penicillin. The suspension (0.2 mL) was inoculated in 10 day-old SPF embryonated chicken eggs via chorio-allantoic-membrane (CAM) then incubated at 37 °C with candling daily. CAMs were collected at 96 h post inoculation [16].

Scoring of lesions after virus isolation calculated as Mild, Severe and Negative where Mild describe the lesion of mild hemorrhage on the CAM and low embryos mortalities, sever describe the lesion of sever hemorrhage on the CAM, greenish liver and high embryos mortalities and negative describe no lesions on the CAM and no embryo mortalities.

### 2.5. Confirmation of the isolated virus by AGPT

Using standard known positive and negative precipitating reference antisera against IBDV were obtained from Doorn Animal Health Research Institute, the Netherlands [17].

### 2.6. Sequence analysis of VP2 of IBDV

Gel containing DNA band of the expected size (620 bp) was excised and purified with the QIAquick Gel Extraction Kit (Qiagen) according to the manufacturer instruction. The purified PCR products were sequenced directly using the ABI PRISM® BigDye™ Terminators v3.1 Cycle Sequencing Kit (Applied Biosystems, Foster City, CA, USA) and the ABI PRISM® 3130 genetic analyzer (Applied Biosystems) with 80 cm capillaries. The sequences were edited with SeqScape® Software Version 2.5 (Applied Biosystems), assembly of the consensus sequences and alignment trimming was performed with the Lasergene DNASTAR group of programs

(DNASTAR Inc., Madison, WI), Using Clustal V method. The phylogram was drawn using also MEGA 5 software [18]. The alignment of the viruses in the study was done using DNASTAR – MegAlign software. Egyptian viruses and other international reference strains from the Genbank and were available from the National Center for Biotechnology Information (NCBI) infectious bursal disease viruses resource (<http://www.ncbi>). Finally the identity percent and divergence between all viruses was carried out. Eleven partial sequences of VP2 gene reported were submitted to genbank under Accession Numbers from KF444824 to KF444834.

### 3. Results

#### 3.1. Post mortem findings

Chickens from 16 flocks showed severe hemorrhages on breast and thigh muscles, severely edematous and hemorrhagic bursa with history of high mortalities (10–13%). Chickens of 4 flocks showed mild edematous bursa with history of high mortalities. While the rest of examined flocks showed dehydration with slight muscular congestion and slightly enlarged bursa.

#### 3.2. Histopathological analysis

Bursa of Fabricius from diseased birds with typical lesions showed depleted lymphoid follicles and atrophy with presence of vacuoles in the cortical and medullar portion and heterophils invasion (Fig. 2).

#### 3.3. IBDV detection by RT-PCR

Out of 52 bursal samples tested with RT-PCR, 20 samples (38%) were positive (Table 1). All RT-PCR positive samples showed specific bands at 620 bp on agarose gel (Fig. 1).

#### 3.4. Virus isolation and confirmation

Table 2 summarize the obtained results of virus isolation. Gross lesions (hemorrhages on the CAM, greenish liver) with different degree of severity were observed. AGPT employed on the harvested CAMs confirms the isolation of five IBDV viruses

**Table 1** Results of detection of IBDV using RT-PCR.

Provinces	No. of cases	No. of positives	No. of negatives
Dakahlia	5	2	3
Fayoum	5	1	4
Sharkia	12	5	7
Kaliobeya	10	4	6
Giza	12	6	6
Monofyia	4	2	2
Behera	4	–	4
Total No.	52	20	32

Describes the tested 52 bursal sample with RT-PCR where 20 samples were positives and 32 samples were negatives with positive percent 38%.

#### 3.5. Results of sequence analysis and phylogenetic tree

Sequence analysis of the 359 nucleotides which express 119 amino acid sequence (position: 183–302 bp) from the 11 isolates was carried out.

At amino acid level, the deduced amino acid sequence revealed that Isolates (IBD-121S, IBD-122S, IBD-123S, IBD-124S, IBD-125S, IBD-126S, IBD-127S, IBD-1310S and IBD-1311S) have amino acid sequence identity between each other (96.7–100%) and between Egyptian vvIBDV (Giza 2008, Giza 2000) strains (97.2–100.0%). On other hand, isolates (IBD-1318S, IBD-1319S) have amino acid sequence identity between each (100%) and between Egyptian classical strains (Kal 2001) (96.7%). As shown in Table 3.

Sequence analysis of isolates (IBD-121S, IBD-122S, IBD-123S) differed from the previous isolated strains from Egypt (Giza 2008, Giza 2000) IBDV, they have alanine (A) residue at position 198 instead of aspartic acid (D). Isolates (IBD-1318S, IBD-1319S) (classic) isolates have one amino acid substitution (L 263 F) in comparison to other Egyptian classic strains (kal2001) which is similar to vaccines strain (Bursavac and Univac) resulting in 100% amino acid identity with Univac vaccine.

The nine vvIBDV isolates under study were found to have specific restriction site (SspI site) while it was not observed in vaccine (classic attenuated) strain.

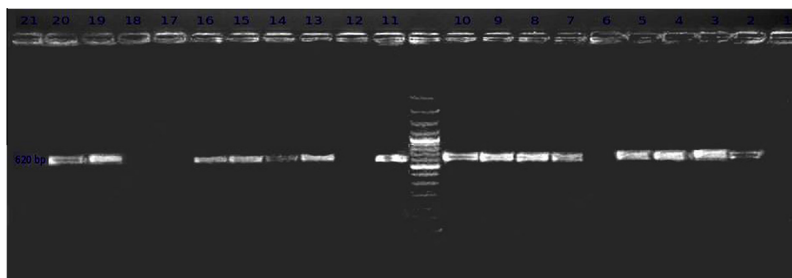
Phylogenetic tree (Fig. 3) indicated that the nine strains in this study (IBD-121S, IBD-122S, IBD-123S, IBD-124S, IBD-125S, IBD-126S, IBD-127S, IBD-1310S, IBD-1311S) showed close relationships between the previously isolated Egyptian IBDVs and they are clustered together except isolates (IBD-1318S, IBD-1319S) were grouped with classic attenuated vaccine strains (Bursavac and Univac).

### 4. Discussion

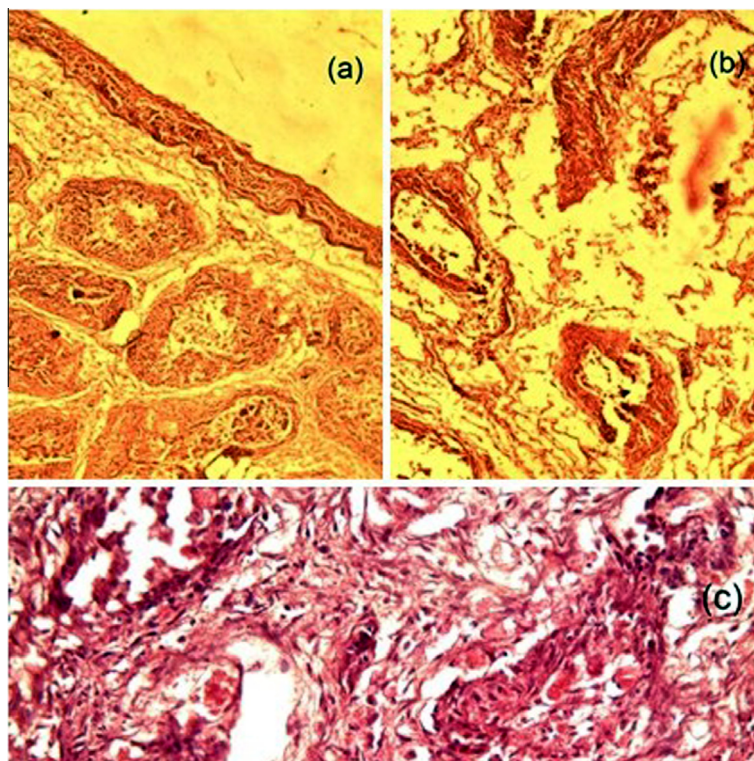
The infectious bursal disease virus continuous to be a serious problem in Egypt as it does in other poultry producing countries all over the world. A preventive program is crucial to avoid virus spread and disease appearance [11,12].

The clinical diagnosis of the acute forms of IBD relies on the observation of the symptoms and post-mortem examination of the pathognomonic lesions on the bursa of Fabricius. In this study, the post mortem lesions vary from mild to severe congestion, haemorrhage on thigh muscle and edematous hemorrhagic bursa. Clinical manifestations depend on the virulence, age of birds and the presence or absence of passive immunity [19,20]. It was suggested that pathogenesis and viral multiplication is more pronounced in very virulent strains comparing to the milder strains [21]. In this study, the histopathological findings were characteristic to IBDV infection, depletion of lymphoid follicles with different degrees was observed, for vvIBDV the lymphoid follicles depletion were more rapid and severe comparing to milder strains [22–24].

The definite identification of IBDV was obtained using RT-PCR which was known to be a sensitive test to detect the IBDV [7,8,25]. In this study 20 out of 52 field samples were positive by RT-PCR. In a similar to study carried out by Abdel-Alem [8]. Virus isolation of bursa suspension in SPF embryonated chicken eggs was carried out. Gross lesions



**Figure 1** Gel electrophoresis of RT-PCR showing 620 kbp band in positive samples and no band was observed in negative samples.



**Figure 2** Histopathological findings of bursa recovered from diseased birds with IBDV. (a and b) The lymphoid follicles appear depleted and atrophied with presence of vacuoles in the cortical and medullar portion, thickness of bursal wall. (c) Bursa with infectious bursitis presenting necrosis and heterophils invasion.

showed hemorrhages on the CAM, greenish liver with different degree of severity were observed. Similar results have also been reported [26]. AGPT employed on the harvested CAMs confirmed the isolation of five IBDV viruses (Table 2). Variability in results in AGPT was previously reported [27,28].

The hypervariable region (206–350 a.a.) contain the most informative genetic data regarding strain variability, it was chosen for sequence analysis to characterize IBDV strains molecularly, allowing analysis of variations that happen naturally or by attenuation in different strains, leading to changes in antigenicity and/or virulence [1,13]. In this study, a comparative alignment and phylogenetic analysis of the hypervariable domain of the VP2 grouped the IBDV local isolates into at least two different pathogenic subgroups and assess geographical subtypes.

The isolates (IBD-121S, IBD-122S and IBD-123S) differed from the previously isolated strains Giza 2008, Giza 2000

IBDV by having alanine (A) residue at position 198 instead of aspartic acid (D). The reported mutation in these three isolates may be as results of the extensive abuse of IBDV vaccines as well as the heavily use of IBD different vaccination programs in delta area where the outbreaks occur.

It was reported that the major Hydrophilic region (peak A 210–225) to be important in the binding of neutralizing monoclonal antibodies (Mabs) and are presumed to be the dominant parts of the neutralizing domain. Therefore, variation in these region are likely to induce significant antigenic variation [29,30]. The nine very virulent isolates reported here and other Egyptian vvIBDV strains (Giza 2008, Giza 2000) have one amino acid substitution (Y 220 F) comparing with other vvIBDV strains. This amino acid substitution may affect virus antigenicity change which may has an important role in increasing virulence that may cause disease in the presence of high maternal antibody. Residues present in the VP2 region

**Table 2** Results of virus isolation and confirmation by AGPT.

Samples code	Lesions in inoculated eggs			Results of AGPT
	Passage (1)	Passage (2)	Passage (3)	
IBD-121S (Dakahlia)	+++	Nd	Nd	Pos
IBD-122S (Kaliobeya)	+++	Nd	Nd	Pos
IBD-123S (Sharkia)	+++	Nd	Nd	Pos
IBD-124S (Kaliobeya)	+	+	+	Neg
IBD-125S (Giza)	+++	Nd	Nd	Pos
IBD-126S (Giza)	+++	Nd	Nd	Pos
IBD-127S (Monofyia)	Neg	Neg	Neg	Neg
IBD-138S (Sharkia)	+	+	+	Neg
IBD-139S (Sharkia)	+	+	+	Neg
IBDV-1310S (Giza)	Neg	Neg	Neg	Neg
IBDV-1311S (Fayoum)	Neg	Neg	Neg	Neg

The results of virus isolation and confirmation by AGPT. +, Mild lesions; + + +, severe lesions; CAM, chorio-allantoic-membrane; AGPT, agar gel percipitation test; Pos, positive; Neg, negative; Nd, not done.

**Table 3** Identity and diversity of IBDV.

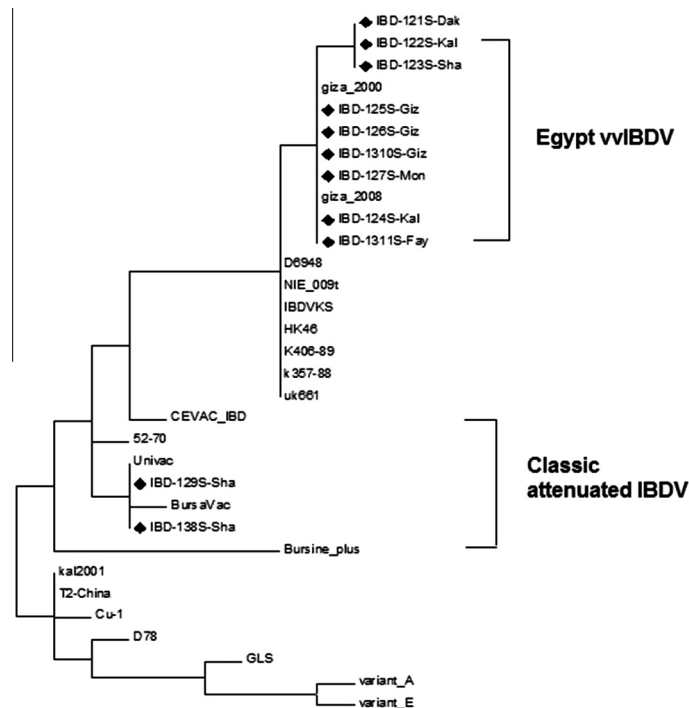
		Percent Identity																			
		1	2	3	4	5	6	7	8	9	10	11	12	13	14	15	16	17	18		
Divergence	1	■	100.0	100.0	99.2	99.2	99.2	96.7	91.7	91.7	99.2	99.2	99.2	99.2	90.0	94.2	90.0	90.8	91.7	1	IBD-121S/Dak
	2	0.0	■	100.0	99.2	99.2	99.2	96.7	91.7	91.7	99.2	99.2	99.2	99.2	90.0	94.2	90.0	90.8	91.7	2	IBD-122S/Kal
	3	0.0	0.0	■	99.2	99.2	99.2	96.7	91.7	91.7	99.2	99.2	99.2	99.2	90.0	94.2	90.0	90.8	91.7	3	IBD-123S/Sha
	4	0.8	0.8	0.8	■	100.0	100.0	97.5	92.5	92.5	100.0	100.0	100.0	100.0	90.8	95.0	90.8	91.7	92.5	4	IBD-124S/Kal
	5	0.8	0.8	0.8	0.0	■	100.0	97.5	92.5	92.5	100.0	100.0	100.0	100.0	90.8	95.0	90.8	91.7	92.5	5	IBD-125S/Giz
	6	0.8	0.8	0.8	0.0	0.0	■	97.5	92.5	92.5	100.0	100.0	100.0	100.0	90.8	95.0	90.8	91.7	92.5	6	IBD-126S/Giz
	7	0.9	0.9	0.9	0.0	0.0	0.0	■	91.7	91.7	97.5	97.5	97.5	97.5	90.0	93.3	90.0	90.8	91.7	7	IBD-127S/Mon
	8	8.9	8.9	8.9	7.9	7.9	7.9	6.2	■	100.0	92.5	92.5	92.5	92.5	96.7	97.5	95.0	99.2	100.0	8	IBD-138S/Sha
	9	8.9	8.9	8.9	7.9	7.9	7.9	6.2	0.0	■	92.5	92.5	92.5	92.5	96.7	97.5	95.0	99.2	100.0	9	IBD-139S/Sha
	10	0.8	0.8	0.8	0.0	0.0	0.0	0.0	7.9	7.9	■	100.0	100.0	100.0	90.8	95.0	90.8	91.7	92.5	10	IBD-1310S/Giz
	11	0.8	0.8	0.8	0.0	0.0	0.0	0.0	7.9	7.9	0.0	■	100.0	100.0	90.8	95.0	90.8	91.7	92.5	11	IBD-1311S/Fay
	12	0.8	0.8	0.8	0.0	0.0	0.0	0.0	7.9	7.9	0.0	0.0	■	100.0	90.8	95.0	90.8	91.7	92.5	12	giza 2000
	13	0.8	0.8	0.8	0.0	0.0	0.0	0.0	7.9	7.9	0.0	0.0	0.0	■	90.8	95.0	90.8	91.7	92.5	13	giza 2008 w
	14	10.8	10.8	10.8	9.8	9.8	9.8	8.1	3.4	3.4	9.8	9.8	9.8	9.8	■	95.8	98.3	95.8	96.7	14	kal2001
	15	6.1	6.1	6.1	5.2	5.2	5.2	4.4	2.5	2.5	5.2	5.2	5.2	5.2	4.3	■	95.8	96.7	97.5	15	52-70 c
	16	10.8	10.8	10.8	9.8	9.8	9.8	8.1	5.2	5.2	9.8	9.8	9.8	9.8	1.7	4.3	■	94.2	95.0	16	D78 va
	17	9.8	9.8	9.8	8.9	8.9	8.9	7.2	0.8	0.8	8.9	8.9	8.9	8.9	4.3	3.4	6.1	■	99.2	17	BursaVac
	18	8.9	8.9	8.9	7.9	7.9	7.9	6.2	0.0	0.0	7.9	7.9	7.9	7.9	3.4	2.5	5.2	0.8	■	18	Univac
	1	2	3	4	5	6	7	8	9	10	11	12	13	14	15	16	17	18			

The similarity between IBDV isolates and other Egyptian and representative reference strains.

at position (P222A), (V256I), (N279I), 294I, (N299S) showed to be unique for all vvIBDV strains as compared to classical strains [31–33]. In this study, the nine (very virulent) isolates show the same amino acids at position 222 A, 256 I, 294 I, 299 except at position N 279 D. Further studies are needed to confirm if this substitution is involved in the cell tropism of virulent IBDV strains.

Amino acids found at positions 253 and 284 were found to be responsible for pathogenicity and are unique to highly virulent IBDVs. [34,35]. It was supposed that they were also

involved in cell culture adaptation, where (Q 253 H; A 284 T) are specific amino acids for cell tropism [36]. Our isolates show (253 Q, 284 A) these results suggested the difficulty of cell culture of these isolated strains. Strains which have glutamine at position 253 reported to be high pathogenicity than those with a histidine at position 253 are much less pathogenic. A glutamine residue at position 253 was found in the nine isolates examined in the present study as well as the previously isolated Giza 2008, Giza 2000 IBDV indicating high pathogenicity. Recently, special attention was given to amino acids at



**Figure 3** Phylogenetic tree of deduced amino acid sequences of the eleven IBDV isolates and other reference classical, very virulent, and variant and vaccine strains of IBDV.

position 253 where histidine or glutamine is found. Because of the intensive vaccination programs performed in the field with live attenuated viruses, there is a possibility that the viruses used mutate and subsequently change their pathogenic potential [37].

A specific SspI site on VP2 has previously been identified in all vvIBDV strains [31]. Consequently, this SspI site has been used as a genetic marker to predict a very virulent phenotype that must be confirmed by *in vivo* studies. However, not all vvIBDV have this marker and some non-vvIBDV strains have been found to contain the SspI marker [38]. It is interesting that all vvIBDV isolates under study had this restriction site while it was not observed in vaccine (classic) strain.

The presence of two viruses of vaccine origin indicate circulation of vaccine viruses in the field and that may be due to improper vaccine application in the field that permit emergence antigenic variants which may attribute to severe post vaccination reaction of intermediate-plus vaccines. The intensive use of vaccination programs performed with live attenuated viruses may lead to the possibility of emergence of mutants and subsequently they constantly change their pathogenic potential and that require review the vaccination programs in Egypt.

## 5. Conclusion

This study successfully characterize nine vvIBDV and two classical strains from field cases of IBD in Egypt during 2012–2013. The genotyping of Egyptian vvIBDV indicate progressive evolution and they were belonging to previously isolated strains and that indicate persistence of the vvIBDV in the Egyptian environment.

## References

- [1] Banda AP, Villegas El-Attrache J. Molecular characterization of infectious bursal disease virus from commercial poultry in the United States and Latin America. *Avian Dis* 2003;47(1):87–95.
- [2] Lukert PD, Saif YM. Infectious bursal disease. In: Saif YM, Barnes HJ, Glisson JR, Fadly AM, McDougald LR, Swayne DE, editors. *Diseases of poultry*. Ames: Iowa State Press; 2003. p. 161–79.
- [3] Cosgrove AS. An apparently new disease of chickens – avian nephrosis. *Avian Dis* 1962;6:385–9.
- [4] El-Sergany HA, Ann Moursi, Saber MS, Mohamed MA. A preliminary investigation on the occurrence of Gumboro disease in Egypt. *Egypt J Vet Sci* 1974;11–17:185–208.
- [5] Birnaviridae. In: Murphy FA, Gibbs EPJ, Horzinek MC, Studdert MJ, editors. *Veterinary virology*. Orlando: Academic Press; 1999. p. 405–9.
- [6] Zierenberg K, Nieper H, van den Berg TP, Ezeokoli CD, Voß M, Müller H. The VP2 variable region of African and German isolates of infectious bursal disease virus: comparison with very virulent, “classical” virulent, and attenuated tissue culture adapted strains. *Arch Virol* 2000;145:113–25.
- [7] Muller H, Islam MR, Raue R. Research on infectious bursal disease-the past, the present and the future. *Vet Microbiol* 2003; 97:153–65.
- [8] Abdel-Alem GA, Awaad MHH, Saif YM. Characterization of Egyptian field strains of infectious bursal disease virus. *Avian Dis* 2003;47:1452–7.
- [9] El-Batravi AM, El-Kady m MF. Studies on sever outbreaks of infectious bursal disease 3-determination of the critiealage of syseptigility in maternally immune chicks. *Proc Second Sci Conf Egypt Vet Poult* 1990:264–9.
- [10] El-Sonusi A, Madbouly MM, Saber, Msis El-Bagoury GF, Abd El Bar NA, El-Batravi A, et al. III Antigenic characterization

- of IBDV by the antigenic capture ELISA. (Ac-ELISA) using monoclonal antibodies. *Beni Suef Vet Res* 1994;4(1/2):300–8.
- [11] Hussein AH, Aly AN, Sultan H, Al-Safty M. Transmissible viral pronventriculitis and stunting syndrome in broiler chicken in Egypt. 1. Isolation and characterization of variant infectious bursal disease virus. *Vet Med J Giza* 2003;51(3):445–62.
- [12] Metwally AM, Sabry MZ, Sami AM, Omer MN, Yousif AA, Reda M. Direct detection of variant infectious bursal disease virus in vaccinated Egyptian broiler flocks using antigen – capture Elisa. *Vet Med J Giza* 2003;51(1):105–19.
- [13] Jackwood DJ, Sommer-Wagner SE. Genetic characteristics of infectious bursal disease viruses from four continents. *Virology* 2007;365:369–75.
- [14] Metwally AM, Ausama AYousif, Iman BShaheed, Walaa AMohammed, Attia MSamy, Ismail MReda. Re-emergence of very virulent IBDV in Egypt. *Int J Virol* 2009;5:1–17.
- [15] Bancroft JD, Stevens A, Turner DR. Theory and practice of histological techniques. 4th ed. New York, London: Churchill Livingstone; 1996.
- [16] Hitchner SB. Infectivity of infectious bursal disease VIMS for embryonating eggs. *Poult Sci* 1970;49:511–6.
- [17] Wood GW, Muskett JC, Hebert CN, Thornton DH. Standardisation of the quantitative agar gel precipitin test for antibodies to infectious bursal disease. *J Biol Stand* 1979;7: 89–96.
- [18] Tamura K, Peterson D, Peterson N, Stecher G, Nei M, Kumar S. MEGA5: molecular evolutionary genetics analysis using maximum likelihood, evolutionary distance, and maximum parsimony methods. *Mol Biol Evol* 2011;28:2731–9.
- [19] Hassan MK. Very virulent infectious bursal disease virus in Egypt: epidemiology, isolation and immunogenicity of classic vaccine. *Vet Res Commun* 2004;28(4):347–56.
- [20] Rauw F, Lambrecht B, Van den Berg T. Pivotal role in the pathogenesis of ChIFN $\gamma$  and immunosuppression of infectious bursal disease. *Avian Pathol* 2007;36(5):367–74.
- [21] Van Den Berg TP. Acute infectious bursal disease in poultry: a review. *Avian Pathol* 2000;29:175–94.
- [22] Islam MN, Rashid SMH, Hoque MF, Juli MSB, Khatun M. Pathogenicity of IBDV related to outbreaks in the vaccinated flocks and the causes of vaccination failure. *J Innov Dev Strat* 2008;2(3):22–30.
- [23] Shrivastav A-K, Minaksih, Swati-Dahiya, Mahajan N-K. Direct detection of viral genome and histopathological studies of bursan tissues collected from an infectious bursal disease suspected outbreak. *Indian J Poul Sci* 2004;39(2):201–3.
- [24] Raue R, Islam MR, Islam MN, Islam KM, Badhy SC, Das PM, et al. Reversion of molecularly engineered, partially attenuated very virulent infectious bursal disease virus during infection of commercial chickens. *Avian Pathol* 2004;33(2):181–9.
- [25] Abdel-Alem GA, Saif YM. Immunogenicity and antigenicity of very virulent strains of infectious bursal disease viruses. *Avian Dis* 2001;45:92–101.
- [26] Islam M-A, Khatun M-M, Rahman M-M, Hossain M-T. Serologic and pathogenic characterization of infectious bursal disease virus isolated from broiler chickens Bangladesh. *Veterinarian* 2005;22(2):57–64.
- [27] Kadam M, Jhala MK. Comparison of serological tests for detection of infectious bursal disease virus in bursal samples. *Indian Vet J* 2003;80:723–6.
- [28] Parthiban M, Thiagarajan V. Application of polymerase chain reaction for early detection of infectious bursal disease virus infection. *Indian J Anim Sci* 2000;70:1201–3.
- [29] Domanska K, Mato T, Rivallan G, Smietanka K, Minta Z, de Boisseson C, et al. Antigenic and genetic diversity of early European isolates of infectious bursal disease virus prior to the emergence of the very virulent viruses: early European epidemiology of infectious bursal disease virus revisited. *Arch Virol* 2004;3:465–80.
- [30] Etteradossi N, Arnauld C, Toquin D, Rivallan G. Critical amino acid changes in VP2 variable domain are associated with typical and atypical antigenicity in very virulent infectious bursal disease viruses. *Arch Virol* 1998;143:1627–36.
- [31] Jackwood DJ, Sreedevi B, LeFever LJ, Sommer-Wagner SE. Studies on naturally occurring infectious bursal disease viruses suggest that a single amino acid substitution at position 253 in VP2 increases pathogenicity. *Virology* 2008;377:110–6.
- [32] Kasanga CJ, Yamaguchi T, Wambura PN, Maeda-Machang'u AD, Ohya K, Fukushi H. Molecular characterization of infectious bursal disease virus (IBDV): diversity of very virulent IBDV in Tanzania. *Arch Virol* 2007;152:783–90.
- [33] van den Berg TP, Morales D, Enterradossi N, Rivallan G, Toquin D, Raue R, et al. Assessment of genetic, antigenic and pathotypic criteria for the characterization of IBDV strains. *Avian Pathol* 2004;1:1–2.
- [34] Brandt M, Yao K, Liu M, Heckert RA, Vakharia VN. Molecular determinants of virulence, cell tropism, and pathogenic phenotype of infectious bursal disease virus. *J Virol* 2001;75:11974–82.
- [35] Islam MR, Zierenberg K, Etteradossi N, Toquin D, Rivallan G, Müller H. Molecular and antigenic characterization of Bangladeshi isolates of infectious bursal disease virus demonstrate their similarities with recent European, Asian and African very virulent strains. *J Vet Med B* 2001;48:211–21.
- [36] Van Loon AAWM, de Haas N, Zeyda I, Mundt E. Alteration of amino acids in VP2 of very virulent infectious bursal disease virus results in tissue culture adaptation and attenuation in chickens. *J Gen Virol* 2002;83:121–9.
- [37] Zierenberg K, Raue R, Muller H. Rapid identification of “very virulent” strains of infectious bursal disease virus by reverse transcription-polymerase chain reaction combined with restriction enzyme analysis. *Avian Pathol* 2001;30:55–62.
- [38] Sapats SI, Ignjatovic J. Restriction fragment length polymorphism analysis of the VP2 gene of Australian strains of infectious bursal disease virus. *Avian Pathol* 2002;31:566–99.