



## The air-Q as a conduit for fiberoptic aided tracheal intubation in adult patients undergoing cervical spine fixation: A prospective randomized study

Enas M. Samir & Sameh A. Sakr

To cite this article: Enas M. Samir & Sameh A. Sakr (2012) The air-Q as a conduit for fiberoptic aided tracheal intubation in adult patients undergoing cervical spine fixation: A prospective randomized study, Egyptian Journal of Anaesthesia, 28:2, 133-137, DOI: [10.1016/j.egja.2011.12.002](https://doi.org/10.1016/j.egja.2011.12.002)

To link to this article: <https://doi.org/10.1016/j.egja.2011.12.002>



© 2011 2011 Egyptian Society of Anesthesiologists. Production and hosting by Elsevier B.V.



Published online: 17 May 2019.



Submit your article to this journal [↗](#)



Article views: 89



View related articles [↗](#)



Citing articles: 3 View citing articles [↗](#)



Egyptian Society of Anesthesiologists  
Egyptian Journal of Anaesthesia

www.elsevier.com/locate/egja  
www.sciencedirect.com



Research Article

# The air-Q as a conduit for fiberoptic aided tracheal intubation in adult patients undergoing cervical spine fixation: A prospective randomized study

Enas M. Samir <sup>a,\*</sup>, Sameh A. Sakr <sup>b</sup>

<sup>a</sup> Anesthesia Department, Kasr Alinin, Cairo University, Cairo, Egypt

<sup>b</sup> Neurosurgery Department, Kasr Alinin, Cairo University, Cairo, Egypt

Received 7 August 2011; revised 24 November 2011; accepted 1 December 2011  
Available online 29 December 2011

## KEYWORDS

Air-Q™ intubating laryngeal airway;  
Fiberoptic intubation;  
Cervical spine fixation

**Abstract** The air-Q™ intubating laryngeal airway is a supraglottic airway device which was designed to allow adequate patient ventilation and reliable blind endotracheal tube intubation.

**Objectives:** To investigate the efficacy of air-Q as a conduit for fiberoptic endotracheal intubation in adult patients with limited cervical spine mobility compared with fiberoptic-guided intubation alone.

**Design:** Prospective randomized study.

**Patients:** Sixty adult (12 female) patients, ASA physical status I and II scheduled for cervical spine fixation under general anesthesia. Patients were randomized into two parallel groups. Exclusion criteria includes, history of difficult airway, mouth opening < 3 cm, Mallampati class ≥ III and, increased risk of aspiration of gastric contents.

**Intervention:** In the first group, endotracheal intubation was aided with the fiberoptic scope while patients in the second group were intubated with the fiberoptic scope guided with the air-Q as a conduit. The number of attempts and time to successful insertion of air-Q and endotracheal tube were recorded. The fiberoptic quality of the vocal cords view as seen through the air-Q and ease of endotracheal tube insertion were also assessed.

\* Corresponding author. Tel.: +20 0121054817.

E-mail addresses: enahamdy@yahoo.com (E.M. Samir), samehsakr@hotmail.com (S.A. Sakr).

1110-1849 © 2011 Egyptian Society of Anesthesiologists. Production and hosting by Elsevier B.V. Open access under [CC BY-NC-ND license](#).

Peer review under responsibility of Egyptian Society of Anesthesiologists.  
doi:10.1016/j.egja.2011.12.002



Production and hosting by Elsevier

**Results:** The air-Q was easily inserted in all patients of the second group with mean insertion time ( $22.6 \pm 4.3$  s). The air-Q provided a good fiberoptic view of the vocal cords and successful tracheal intubation in 29 (96.7%) patients of the second group on the first attempt. Time to tracheal intubation in the second group was significantly shorter than the first group ( $21.6 \pm 5.7$  and  $29.8 \pm 6.2$  s respectively). The air-Q was easily removed without any complications.

**Conclusions:** The air-Q as a conduit for fiberoptic scope provided a better view of the vocal cords and, less insertion time of the endotracheal compared to fiberoptic-aided endotracheal intubation in adult patients with limited cervical spine mobility scheduled for cervical spine fixation.

© 2011 Egyptian Society of Anesthesiologists. Production and hosting by Elsevier B.V.

Open access under [CC BY-NC-ND license](#).

## 1. Introduction

Difficult airway should always be considered in patients presenting for surgery of the cervical spine. Thorough preoperative patient assessment should be performed, including previous history of difficult intubation, restricted neck mobility and stability of cervical spine. The decision must be reached after preoperative assessment whether to intubate the patient awake or asleep, and whether to intubate with or without the fiberoptic bronchoscope. Endotracheal intubation using direct laryngoscopy with manual in-line stabilization or a hard collar is acceptable for many patients provided that it can be performed without detrimental neck movement. The intubating laryngeal mask airway is a good alternative for intubation in these patients, with or without the aid of fiberoptic bronchoscopy [1].

The development of laryngeal mask airway LMA Fastrach and LMA-CTrach have facilitated LMA-aided tracheal intubation. The main advantages of LMA-assisted tracheal intubation includes: easy insertion, better alignment of the glottis opening, and continuous patient oxygenation and ventilation. The air-Q™ Intubating Laryngeal Airway (ILA) is a new supraglottic airway device (available in different sizes, including pediatric sizes), which was designed to allow adequate patient ventilation and blind endotracheal intubation [2]. Advantages of the air-Q ILA over the classic laryngeal mask airway include: shorter, more curved and wider shaft which facilitates the insertion of cuffed endotracheal tube, easy removal of the airway adaptor, and availability of the option of removal of the laryngeal airway after tracheal intubation [3].

The air-Q Intubating Laryngeal Airway (ILA) is a useful device for intubation which can be used as a conduit for tracheal intubation with or without fiberoptic guidance in patients undergoing spine surgery with limited neck mobility. The efficiency of the Air-Q ILA for difficult airway management in adult patients has not been established.

The objective of this prospective study was to determine the efficacy of the air-Q ILA as a conduit for the fiberoptic scope for tracheal intubation in patients with limited cervical mobility with respect to insertion success rate, time, fiberoptic view of the glottis opening, and intra- and post-operative complications.

## 2. Methods

After institutional Ethics Committee approval and obtaining written informed consent from each patient, this study was conducted in Kasr El Aini hospital, Cairo University, Egypt. The study was conducted from March, 2010 to April 2011. Sixty patients scheduled for cervical spine fixation under general

anesthesia for cervical spine instability and fracture spine were enrolled in the study. Inclusion criteria were patient age 18–65 yr, ASA physical status I and II and, body mass index (BMI)  $< 30$  kg/m<sup>2</sup>. Patients were excluded if they have a previous history of difficult airway, mouth opening  $< 3$  cm, Mallampati class  $\geq$  III and, patients with gastroesophageal reflux disease (GERD) or other causes of increased risk of aspiration of gastric contents. Patients were randomized into two equal groups of 30 patients each using a sealed envelope technique. In the first group, tracheal intubation was aided with the fiberoptic bronchoscope alone (Group F), and in the second group tracheal intubation was facilitated using the air-Q as a conduit for the fiberoptic bronchoscope (Group A).

Upon arrival to the operating room standard monitors were applied, including noninvasive arterial blood pressure, electrocardiography and pulse oximetry monitoring (General electric, Solar 8000 M. Tram. Rac 4A). Patients were wearing a Philadelphia collar (Micromedex), which was kept on during the intubation. An i.v. cannula 16G was placed in a peripheral vein under local infiltration anesthetic, i.v. atropine 400  $\mu$ g was given to the patient before induction of anesthesia.

After 3 min of preoxygenation, induction of anesthesia was achieved with fentanyl 2  $\mu$ g/kg and propofol 2 mg/kg. After confirmation of adequate face mask ventilation, atracurium 0.5 mg/kg was given to facilitate endotracheal intubation. Patients were ventilated via a facemask with 100% oxygen until neuromuscular monitoring revealed absent response to a train-of-four stimulus.

In the first group (Group F), a fiberoptic bronchoscope (Karl Storz. Endoskope. Intubation fiberscope 5.2  $\times$  65. Ref. 11301BN1), was adequately lubricated, and loaded with a cuffed endotracheal tube (ETT) (7 mm inner diameter in females and 8 mm in males) and inserted through the patient mouth. Jaw thrust, tongue pull by an assistant and gentle manipulation of the scope were allowed to facilitate visualization of the glottic opening. Once visualizing the carina the tube was passed into the trachea.

Successful tracheal intubation was confirmed with end-tidal carbon dioxide and auscultation of the patient's chest. The time to successful intubation was measured in seconds (using a digital timer) from placement of the bronchoscope into the patient's mouth until capnographic confirmation of correct placement of the ETT.

In the second group (Group A), an air-Q ILA (Cookgas LLC, Mercury Medical, Clearwater, FL) (reusable version, size 3.5–4.5 according to the patient's weight) was inserted in patient's mouth with the aid of a tongue depressor or jaw thrust maneuver then the ILA cuff was inflated following the manufacturer's instructions. Successful insertion of the ILA

was confirmed by observing adequate bilateral chest inflation and square wave end-tidal capnogram with positive pressure ventilation. Time to successful insertion of the air-Q ILA was measured in seconds from touching the patient's mouth with the device until capnographic confirmation.

A fiberoptic bronchoscope (the same model used in group I), loaded with a cuffed endotracheal tube, was introduced through the air-Q ILA lumen after removal of the connector. Once the carina was visualized the tube was passed through the air-Q ILA into the patient's trachea. Successful tracheal intubation was confirmed with end-tidal carbon dioxide and auscultation of the patient's chest. Time to successful intubation was measured in seconds from advancing the fiberoptic scope into the ILA until capnographic confirmation of intubation. After intubation the ILA cuff was deflated, and with the aid of the manufacturer's removal stylet the ILA was removed, connecting the patient to the anesthesia circuit again and observing the end-tidal carbon dioxide.

In either group, insertion of the air-Q ILA or fiberoptic-aided tracheal intubation was considered a failure after 2 unsuccessful attempts.

Maintenance of anesthesia was achieved with oxygen 50% and air, sevoflurane, and intermittent boluses of intravenous fentanyl as needed. Atracurium infusion was adjusted to maintain adequate muscle relaxation as monitored with the nerve stimulator. During maintenance of anesthesia mean arterial blood pressure (MAP), oxygen saturation (SpO<sub>2</sub>), heart rate (HR), end-tidal CO<sub>2</sub> concentration were continuously monitored.

At the end of surgery atracurium infusion was stopped and reversal of muscle relaxant was achieved with i.v. neostigmine 0.04 mg/kg and atropine in a dose of 0.01 mg/kg. Patients were extubated and transferred to the recovery area and assessed for any adverse events.

### 3. Measurements

The quality of fiberoptic view (as seen through the air-Q) was assessed and classified as grade I – full view of the vocal cord, II – partial view of the vocal cords including arytenoids, III – epiglottis only, IV – other (ILA cuff, pharynx, others) [4]. Number of attempts and, time to successful insertion of the ILA and ETT were recorded.

The ease of tracheal intubation was also assessed and graded as: grade I – easy intubation, II – mild difficulty, III – moderate difficulty, IV – failure of fiberoptic intubation.

Complications as oxygen desaturation (SpO<sub>2</sub> < 92%), tracheal tube dislodgment during removal of the ILA, upper airway trauma (as evident by blood staining of the ILA, and sore throat) in the first postoperative hour, were also recorded.

### 4. Statistical analysis

Assuming that a difference of 20% or more in the intubation time between the two groups would be of clinical interest a sample size of 30 patients per group was calculated to achieve a power of 80% and a significance level of 0.05.

Data were analysed using Prism 5.0a (GraphPad Software, Inc.). Data were expressed as mean ( $\pm$ SD), ratio or percent as indicated. Comparison between groups was performed using unpaired *t* test. Categorical variables were compared using

contingency tables and Fisher's exact test. A *P* value of <0.05 was considered statistically significant.

### 5. Results

The study included 60 patients (48 males and 12 females) scheduled for cervical spine fixation under general anesthesia, their mean age was (48.05  $\pm$  5.166) yr and BMI was (26.85  $\pm$  2.74) Kg/m<sup>2</sup>. Patients were divided into two equal groups.

Demographic data and clinical characteristics of patients are summarized in Table 1.

Insertion of the air-Q ILA was easily achieved on the first attempt in all patients of the second group (Group A) with mean insertion time (22.6  $\pm$  4.3) s.

Successful insertion of the ETT was achieved in 28 patients (93.3%) of the first group (group F) on the first attempt, 2 patients (6.7%) required a second attempt for successful intubation. Mean time to successful intubation was (29.8  $\pm$  6.2) s. Tracheal intubation was also successful in 29 (96.7%) patients of the second group (Group A) on the first attempt; one patient (3.3%) required a second attempt for intubation. The mean time to successful intubation was (21.6  $\pm$  5.7) s, the insertion time was significantly shorter than group F (*P* = 0.0001) (Table 2)

Regarding the fiberoptic quality of the laryngeal view (as seen through the air-Q), full view of the vocal cords was recorded in 18 (60%) patients and partial view of the vocal cords was reported in 11 (36.7%) patients of the second group (Group A). On the other hand, grade III (view of the epiglottis only) was reported in one patient (3.3%) of that group. No patients had a grade IV view. (Fig. 1)

Endotracheal intubation was reported to be easy in 19 patients of the first group (Group F) in comparison to 27 patients of the second group (Group A). This difference was statistically significant. (Table 3)

The air-Q ILA was successfully removed after tracheal intubation in all patients of the second group without any incidence of tube dislodgment.

Oxygen desaturation (SpO<sub>2</sub> < 92%) was not reported in any patient of both groups; the minimum oxygen saturation reached during the study was 94% in one patient of the first group (Group F) who required a second attempt to successful intubation. Postoperative sore throat was not also reported in any of the study patients. Only one instance of blood staining of the ILA was recorded.

### 6. Discussion

Endotracheal intubation of patients with cervical spine pathology or fractures has to be performed with care avoiding excessive flexion, extension or rotation of the spine. Wearing a Philadelphia collar is very effective in preventing movement of the cervical spine while intubating these patients. However, this collar may limit mouth opening, rendering laryngoscopy and intubation more difficult. The fiberoptic bronchoscope is the method of choice for tracheal intubation in these patients [5].

The air-Q ILA is a new supraglottic airway device available in adult and pediatric sizes, in both single-use and reusable versions, and can be used as a primary airway during maintenance of anesthesia as well as a conduit for blind and fiberoptic-assisted tracheal intubation [6]. This study evaluated

**Table 1** Demographic data and clinical characteristics of patients {mean (SD)} or ratio.

	Group I (F) (n = 30)	Group II (A) (n = 30)	P value
Age (yr)	49.30 (5.402)	46.80(4.679)	0.0603
Gender (male/female)	23/7	25/5	0.7480
Weight (kg)	77.67 (6.814)	75.57(6.658)	0.2322
Height (cm)	168.26 (5.362)	169.46 (6.180)	0.4251
Body mass index (Kg/m <sup>2</sup> )	27.35(2.319)	26.34(3.068)	0.1571
ASA I/II	17/13	22/8	0.2789

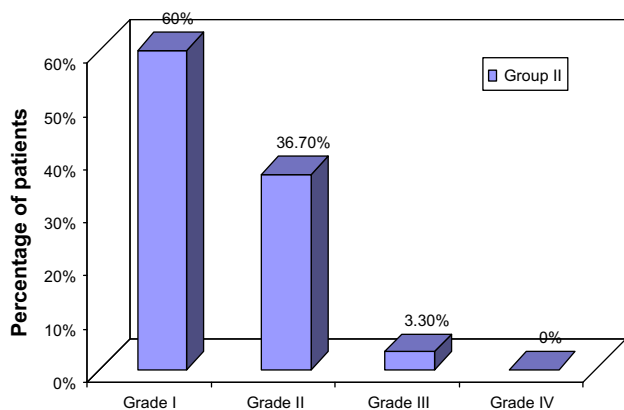
ASA = American society of Anesthesiologists, P value < 0.05 was considered significant.

**Table 2** Number of attempts {n (%)} and time to successful insertion of Endotracheal tube {mean (SD)}.

	Group I (F) (n = 30)	Group II (A) (n = 30)	P value
<i>ETT insertion attempts</i>			
First	28 (93.3%)	29 (96.7%)	
Second	2 (6.7%)	1 (3.3%)	
Fail	0 (0%)	0 (0%)	
Intubation time (S)	29.8 ± 6.2	21.6 ± 5.7*	0.0001

S = seconds, ETT (endotracheal tube), tube insertion was considered as failure after 2 attempts. P value < 0.05 was considered significant.

\* Statistically significant in relation to group I.



**Figure 1** Fiberoptic quality of the vocal cord view (through the air-Q) Grade I – full view of the vocal cord, II – partial view of the vocal cords including arytenoids, III – epiglottis only, IV – other (ILA cuff, pharynx, others). Data are presented as percentage. Number of the patients in the group = 30 patients.

the air-Q ILA as a conduit for fiberoptic-aided tracheal intubation in patients with limited cervical mobility subjected to cervical spine fixation under general anesthesia.

The insertion attempts of the air-Q ILA were limited to two attempts in our study in order to avoid undue trauma to the pharyngeal and laryngeal structures.

In the current study, the air-Q ILA was easily and successfully inserted with adequate patient ventilation in all patients of (Group A), and the insertion time was  $22.6 \pm 4.3$  s. These results are in agreement with the obtained data by Joffe et al. [4] who reported a successful insertion time of  $22 \pm 14$  s and successful insertion rate of 100% in 70 adult patients. They additionally evaluated the air-Q ILA as a primary airway in 57 of their patients. In another, earlier study, Bakker et al. [6] conducted a pilot study of the air-Q ILA in 59 patients, intubating 19 patients blindly through the ILA. They reported a mean ILA insertion time of  $26 \pm 13$  s, and a success rate of ILA insertion of 100%. Comparing the insertion time and number of insertion attempts recorded in the current study with the reported time to successful insertion of the same device or other supraglottic airway devices, our results are in agreement with the previous results [7].

The air-Q ILA provided a superior view of the glottis opening during fiberoptic-aided tracheal intubation and this could be explained by that the device was designed to lift the epiglottis and improve airway alignment, increasing the success rate of blind endotracheal intubation. In the current study the air-Q ILA provided an adequate view of the vocal cords allowing easy endotracheal intubation in 27 (90%) patients, and mild difficulty with intubation in 2 (6.7%) patients. These results

**Table 3** Ease of fiberoptic tracheal intubation {n (%)}.

	Group I (F) (n = 30)	Group II (A) (n = 30)	P value
Easy intubation	19 (63.3%)	27 (90%)*	0.0303
Mild difficulty	8 (26.7%)	2 (6.7%)	
Moderate difficulty	3 (10%)	1 (3.3%)	
Cannot intubate	0 (0%)	0 (0%)	

P value < 0.05 was considered significant.

\* Statistically significant in relation to group I.

were in agreement with the results reported by Joffe et al. [4] who obtained adequate exposure of the vocal cords allowing intubation with minimal or slight resistance to passage of the endotracheal tube in 92% of their patients.

In the current study, 2 patients in (Group F) required a second attempt to successful intubation. The difficulty to intubate these patients was due to excessive secretions obstructing the view of the cords in one patient, and in the other patient there was a difficulty to visualize the glottic opening due to large size epiglottis. Additionally, one patient in (Group A) needed a second attempt to intubate due to difficult threading of the tracheal tube.

Although previous studies have shown high success rate of blind tracheal intubation with the air-Q ILA within three attempts (60–74%) [6], we did not examine the air-Q ILA as conduit for blind intubation as we preferred to use the bronchoscope to assist fiberoptic intubation in our patients with a potentially difficult airway.

As a conduit for fiberoptic-aided tracheal intubation, successful intubation was achieved in 29 patients of (Group A) on the first attempt and the insertion time was significantly lower than (Group F). Our results are in consistence with the reported results by Jagannathan et al. [8] who studied the use of the air-Q ILA as a conduit for ETT in 100 children. In their study, insertion of the ILA on the first attempt was successful in 99 children, and successful intubation in 97 of his patients on the first attempt and 3 patients on the second attempt with an average time of  $24.8 \pm 10.6$  s.

Several methods for stabilizing the tracheal tube in place during removal of the air-Q after tracheal intubation were reported and include, the use of a second tracheal tube, laryngeal forceps, airway exchanger catheter, the removal stylet and a fiberoptic bronchoscope [9–12]. However, in the current study subsequent removal of air-Q after successful intubation was achieved in all patients of the second group using the removal stylet without tube dislodgement or oxygen desaturation in any of the patients.

Mucosal injury as recognized by the presence of blood on the air-Q ILA after removal was only recorded in one patient in the current study. Occurrence of sore throat was not observed during the current study. These results, being less than the incidence reported from other studies [4,6], may be explained by the fact that in our study, the air-Q ILA was promptly removed after successful intubation in all patients, as opposed to being used as the primary airway in the majority of the patients in these studies.

None of our patients reached  $\text{SpO}_2$  of  $< 92\%$  at any point during intubation. The minimum oxygen saturation recorded in the current study was 94% in one patient in (Group F) due to failed first attempt at fiberoptic intubation, thereby prolonging intubation time. However, our study included only ASA I and II patients, thereby excluding patients with any significant pulmonary pathology. Had this study included a wider selection of patients, including those with pulmonary morbidity, there may have been a significantly higher rate and degree of desaturation during fiberoptic intubation attempt, demonstrating an advantage to using the air-Q as a conduit through which ventilation is possible.

## 7. Conclusion

In patients with limited (or undesirable) cervical spine mobility, the air-Q ILA appeared to be a safe and effective supra-glottic airway device when used as a conduit for fiberoptic-aided tracheal intubation during cervical spine fixation. There was a significantly shorter insertion time of the ETT with the air-Q ILA used as a conduit compared to fiberoptic-aided tracheal intubation with no conduit. Intubation was achieved without significant airway trauma, and there was no dislodgement of the endotracheal tube during removal of the device.

Further studies with a larger number of patients with higher ASA scores and more difficult airway are needed to confirm the feasibility of using the air-Q as a conduit for tracheal intubation (either aided with the fiberoptic scope or blindly).

## References

- [1] Raw DA, Beattie JK, Hunter JM. Anesthesia for spinal surgery in adults. *Brit J Anaesth* 2003;91(6):886–904.
- [2] Erlacher W, Tiefenbrunner H, Kästenbauer T, et al. CobraPLUS and Cookgas air-Q versus Fastrach for blind endotracheal intubation: a randomised controlled trial. *Eur J Anaesth* 2011;28(3):181–6.
- [3] Jagannathan N, Roth AG, Sohn LE, et al. The new air-Q intubating laryngeal airway for tracheal intubation in children with anticipated difficult airway: a case series. *Paediatr Anaesth* 2009;19(6):618–22.
- [4] Joffe AM, Liew EC, Galgon RE, et al. The second-generation air-Q® intubating laryngeal mask for airway maintenance during anaesthesia in adults: a report of the first 70 uses. *Anaesth Intens Care* 2011;39:40–5.
- [5] Nileshwar A, Thudamaladinne A. Comparison of intubating laryngeal mask airway and Bullard laryngoscope for orotracheal intubation in adult patients with simulated limitation of cervical movements. *Brit J Anaesth* 2007;99(2):292–6.
- [6] Bakker EJ, Valkenburg M, Galvin EM. Pilot study of the air-Q intubating laryngeal airway in clinical use. *Anaesth Intens Care* 2010;38:346–8.
- [7] Vaida SJ, Gaitini D, Ben-David B, et al. A new supraglottic airway, the Elisha Airway Device: a preliminary study. *Anesth Analg* 2004;99(1):124–7.
- [8] Jagannathan N, Kozlowski RJ, Sohn LE, et al. A clinical evaluation of the intubating laryngeal airway as a conduit for tracheal intubation in children. *Anesth Analg* 2011;112:176–82.
- [9] Jagannathan N, Kho MF, Wong DT. Caution is essential when using a tracheal tube as a stabilizing rod to remove the Intubating Laryngeal Airway (ILA) after tracheal intubation in children. *Can J Anaesth* 2010;57:710–1.
- [10] Fiadjoe JE, Stricker PA, Kovatsis P, et al. Initial experience with the air Q as a conduit for fiberoptic tracheal intubation in infants. *Paediatr Anaesth* 2010;20(2):205–6.
- [11] Ellis DS, Potluri PK, O'Flaherty JE, et al. Difficult airway management in the neonate: a simple method of intubating through a laryngeal mask airway. *Paediatr Anaesth* 1999;9(5):460–2.
- [12] Jagannathan N, Kozlowski RJ. An airway exchange catheter facilitates removal of the intubating laryngeal airway after tracheal intubation in children. *Can J Anaesth* 2010;57(11):1044–5.