



## Ultrasound guided two-in-one technique for sciatic and femoral nerve block in below knee surgery: Comparison between two entry points

Sanaa A. Eltohamy

To cite this article: Sanaa A. Eltohamy (2012) Ultrasound guided two-in-one technique for sciatic and femoral nerve block in below knee surgery: Comparison between two entry points, Egyptian Journal of Anaesthesia, 28:4, 261-267, DOI: [10.1016/j.egja.2012.05.004](https://doi.org/10.1016/j.egja.2012.05.004)

To link to this article: <https://doi.org/10.1016/j.egja.2012.05.004>



© 2012 Egyptian Society of Anesthesiologists. Production and hosting by Elsevier B.V.



Published online: 17 May 2019.



Submit your article to this journal [↗](#)



Article views: 169



View related articles [↗](#)



Citing articles: 1 View citing articles [↗](#)



Egyptian Society of Anesthesiologists  
**Egyptian Journal of Anaesthesia**

www.elsevier.com/locate/egja  
www.sciencedirect.com



Research Article

# Ultrasound guided two-in-one technique for sciatic and femoral nerve block in below knee surgery: Comparison between two entry points

Sanaa A. Eltohamy

Department of Anesthesiology, Faculty of Medicine, Zagazig University, Egypt

Received 27 April 2012; accepted 26 May 2012

Available online 2 July 2012

## KEYWORDS

Combined sciatic and femoral;  
Peripheral nerve block;  
Anterior approach;  
One puncture;  
Ultrasound guided

**Abstract** *Background:* Anesthesia for lower limb surgery requires the combination of femoral and sciatic nerve blocks. Although the anterior approach to the sciatic nerve block has rarely been performed, ultrasound guidance may make performance of this approach easier. This prospective, randomized, double blind study was designed to evaluate the success rate, the clinical use and complications of performing ultrasound-guided combined sciatic and femoral nerve block with one needle entry technique in adult patients scheduled for below knee surgery using two different anterior approaches.

*Patients and methods:* Fifty-one patients ASA1 and 11 (25–49 years) were randomly divided into two groups according to the method used for identification of the puncture point: (Para  $n = 26$ ) using the parafemoral approach, (Aysun  $n = 25$ ) using Aysun et al. approach for anterior sciatic nerve block using 0.5% bupivacaine 20 ml for each block. Measurements included block execution time, needle and nerve depth, onset time of sensory and motor block, duration of the block, the degree and the quality of block.

*Results:* The sciatic nerve was located significantly deeper and the needle depth was significantly greater in Para group compared with Aysun group. The execution time of the sciatic nerve block and for the combined sciatic and femoral nerve block were statistically significant longer in Para group than Aysun group. There were no statistically significant differences in success rate, onset time or duration of blockade between the two groups. In 24 cases of each group, complete sensory and motor block (successful block) were obtained. No patient in both groups had a failed block. For patients with complete block, there was no statistical difference regarding the quality of block in both groups. No side effects or complication were recorded in both groups.

E-mail address: [sahmedtoha@yahoo.com](mailto:sahmedtoha@yahoo.com)

Peer review under responsibility of Egyptian Society of Anesthesiologists.



Production and hosting by Elsevier

**Conclusion:** Combined sciatic and femoral block guided with US could be performed easily, successfully and safely in adult patients using single needle/one puncture point technique through two different anterior approaches.

© 2012 Egyptian Society of Anesthesiologists. Production and hosting by Elsevier B.V.

Open access under CC BY-NC-ND license.

## 1. Introduction

Anterior approach to the sciatic nerve block is performed with the patient in supine position and therefore, there is a significant group of patients who would benefit from this block, those who are unable to assume lateral decubitus or lithotomy position [1].

Anterior approach to sciatic nerve block was first described by Beck [1] in 1963, the anatomic landmark was the greater trochanter which may be unidentifiable for some anesthesiologists. So, several groups of researchers have later reported different anatomical landmarks, such as the inguinal crease and femoral artery [2] or the anterior–superior iliac spine and pubic symphysis [3].

Sciatic nerve block by anterior approach has many advantages over the posterior [4] or lithotomy [5] position; the block performed in the supine position, the limb needs not to be flexed [1,5] and both sciatic and femoral blocks can be placed with the patient in the same position [6].

Although clinicians claim that anterior approach for the sciatic nerve is deep and difficult to locate at the hip or thigh level, the feasibility of a combined approach, via single skin needle entry, in supine position is reported. The combined sciatic and femoral nerve block was demonstrated in two studies as a well suited technique for both knee and below knee surgeries.

Steur [6] reported a technique for combined sciatic and femoral nerve block in children with one needle injection. The application of this technique was only limited to children. He utilized the landmark and the puncture point of Beck.

Pandin et al. [7] reported a combined sciatic and femoral nerve block with a single skin injection site by utilizing the classical Winnie's and Beck's landmarks. Some difficulties were faced by using these techniques, including inability to locate the greater trochanter and other landmarks especially in obese patients or patients with trauma or severe arthritis in the lower limb.

Aysun et al. [8] conduct an anatomical study defining safe and accurate landmarks for anterior approach for the sciatic nerve and examine whether the femoral nerve can be blocked simultaneously with such approach through a cadaveric feasibility study, the landmark was the inguinal crease and the femoral artery and the site of needle placement was found to be on a point corresponds to a point  $3.5 \pm 0.4$  cm below the inguinal crease and 1–2 cm lateral to the femoral artery. This site correlates well to landmarks used by Chelly and Delaunay [3].

Anterior parafemoral technique for sciatic nerve block is a new technique with many advantages over Beck's approach; the landmarks are very simple and distinct in most patients (femoral crease and femoral artery), the proximal extent of anesthesia of the thigh is greater than in the classical approach because the nerve is approached more proximally and lastly the lesser trochanter does not obstruct the path of the needle towards the sciatic nerve [9].

There has been an increase in interest in the use of ultrasound for peripheral nerve blocks [10,11] including applications using the posterior approach to sciatic nerve at the subgluteal level [12,13].

Also, the sciatic nerve can be identified successfully at the lesser trochanter level, where the anterior approach to the sciatic nerve block is also performed guided with US [14], although at this level, the sciatic nerve is situated more deeply from the anterior aspect of the thigh and less visible with ultrasound than the posterior approach [15].

Ultrasound imaging, an alternative tool to localize peripheral nerves, may facilitate block performance; however, its usefulness during anterior combined femoral and sciatic block in one needle injection has not been assessed.

So, the aim of this study was to evaluate the success rate as well as the difficulties encountered and complications of performing combined sciatic femoral block with one needle/one puncture point technique guided with ultrasound and neurostimulation in adults subjected to elective surgery below knee comparing two entry points: parafemoral, the method described by New York School Of Regional anesthesia, (NYS-ORA) or by the method described by Aysun et al. for the anterior approach of the sciatic nerve.

## 2. Patients and methods

After approval by the local hospital ethical committee, 51 adult patients (ASA I and II), undergoing elective below knee surgery after giving an oral and written informed consent were included in this study. Patients with a history of diabetes mellitus, neurologic disease, coagulation disorder, infections at the site of injection and uncooperative patients were excluded. All patients fasted for approximately 8 h before entering an operating room, standard noninvasive monitors were applied. Fentanyl 50–100 µg with midazolam 1–2 mg was given IV, ensuring that the patients remained responsive to verbal cues. Patients were randomly divided into two groups according to the method used for identification of the puncture point: *Parafemoral group (26)*: The puncture point was identified using parafemoral technique for the anterior approach of sciatic nerve. Patients were placed in the supine position, with the lower limb in the neutral position. The inguinal area is disinfected and the femoral crease, femoral artery were identified. The ultrasound probe inside a sterile cover (linear, high frequency 9–12 MHz) was positioned perpendicular to the femoral crease (Fig. 3). *Aysun group (25)*: The puncture point was identified using the landmark described by Aysun et al. for anterior approach of sciatic nerve. Patients were in supine neutral position, the US probe (linear, high frequency 9–12MHz) was positioned perpendicular to the skin approximately 4–6 cm distal to the inguinal crease (Fig. 4).

Both approaches were performed using ultrasound device (Honda HS 2001 portable ultrasound). The location in the two groups was scanned by tilting and sliding the transducer

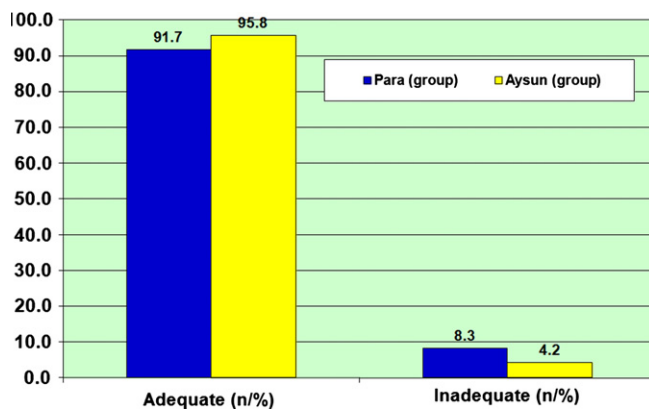


Figure 1 Quality of the complete block.

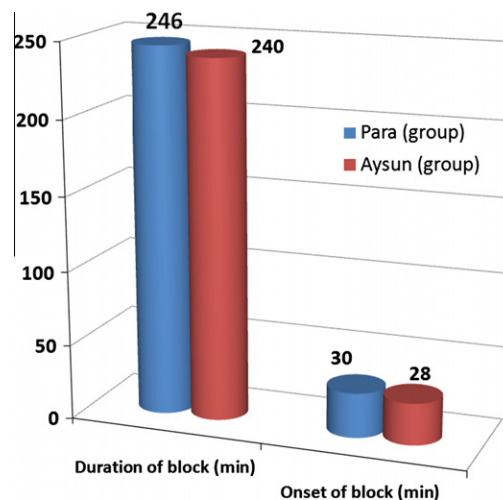


Figure 2 Duration and Onset of block.

horizontally till visualization of the femoral artery, then move the probe slightly lateral, the femoral nerve visualized as hyperechoic, structure immediately lateral to the femoral artery. After skin infiltration with lidocaine, a 15-cm insulated b- beveled stimuplex needle (B-Braun™ Melsungen, AG, Germany) was inserted at the lateral end of the probe, parallel in line with US transducer, the needle connected to a stimuplex peripheral nerve stimulator (Braun, Boulogne-Billancourt, France). The needle was advanced slowly until it approach the femoral nerve under the US guidance, the nerve stimulator was then turned on and adjusted to deliver a current of 0.5 mA to elicit a brisk ‘patellar snap’. After a negative aspiration test, 20 ml of bupivacaine 0.5% was injected.

After complete injection around the femoral nerve, the needle was then withdrawn to the subcutaneous region and the assistant replaced US probe with a curved, low frequency (2–5 MHZ) one, so the needle was at the lateral end of the probe. The location was scanned until a clear image of the sciatic nerve was visualized, then the needle redirected toward the nerve until it was in close proximity to the sciatic nerve, simultaneously the assistant operated nerve stimulator to elicit foot planter-flexion or dorsi-flexion, at 0.7 mA, then 20 ml bupivacaine 0.5% was injected incrementally. The needle tip was repositioned so that a circumferential spread of the solution could be produced.

The observations of the success of the block as well as all other parameters were done by another trained anesthesiologist. If general anesthesia was required, the patient was excluded from the study. Sensory and motor blocks were assessed preoperatively every 5 min up to 45 min after the performance of the block and then every 30 min postoperatively till recovery of sensory and motor function. The Sensory block was assessed using a 18 gauge needle, sensory block was considered complete when the patient did not feel pinprick sensation while the motor block was assessed by the ability of moving the different parts of the leg.

Assessment included the following nerves: *Femoral nerve*: sensory block was assessed over the anterior compartment of the thigh, while motor block was assessed by the degree of paralysis of the quadriceps muscle (judged by the ability to move the knee and calf muscle). *Common peroneal nerve*: motor block assessed by the ability to perform dorsi-flexion of the foot, sensory block was assessed over the lateral aspect of the leg and foot. *Tibial nerve*: motor block was assessed by

the ability to perform planter-flexion of the foot and toes; sensory block was assessed over the medial aspect of the leg and foot.

The degree of block was evaluated by a three-level scale: No block = normal motor or sensory function/Partial block = the presence of either sensory or motor block at any of the examined nerves/Complete block = complete sensory and motor block at all nerves examined. Only the patients with complete block were considered ready for surgery under regional anesthesia. So, number of patients with no, partial or complete block was recorded at maximum 45 min. while patients with partial or failed blocks were subjected to the induction of general anesthesia. Then, the time required till readiness to surgery (considered as the onset of block) was recorded.

The duration of the sensory and motor block was defined as the time between the onset of the block and the recovery of sensory and motor function respectively. Block execution time (the time needed to perform the block); defined as the time elapsed from insertion till removal of the needle was recorded.

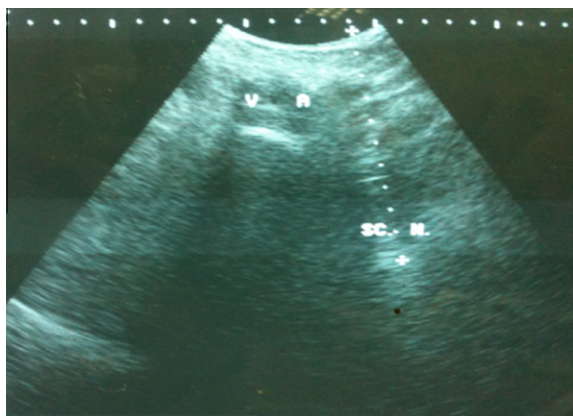
For patients with complete block and according to the need for additional sedation and/or analgesia during surgery, the quality of the block was graded as: adequate block (patients with no response and no need for additional analgesia or sedation) or inadequate block (patients required additional analgesia and/or sedation during surgery).

Quality of US sciatic image was recorded Using the following scale: good = nerve outline clearly, fair = not entirely visualized and poor = doubt as to the nature of the image [16]. The depth of the sciatic nerve and the needle depth (the distance from the skin to the needle tip that was confirmed to be in contact with the sciatic nerve both with the US and nerve stimulation) were recorded.

During sciatic nerve block, the effect of leg rotation on nerve visualization was recorded. Also, any side effects or complications were noted; intravascular injection, hemodynamic changes, or postoperative motor or sensory deficit.

### 3. Results

Fifty-one patients enrolled in the study, both groups were similar in age, sex, weigh, height and physical status (Table 1).



**Figure 3** Parafemoral approach for sciatic nerve block.

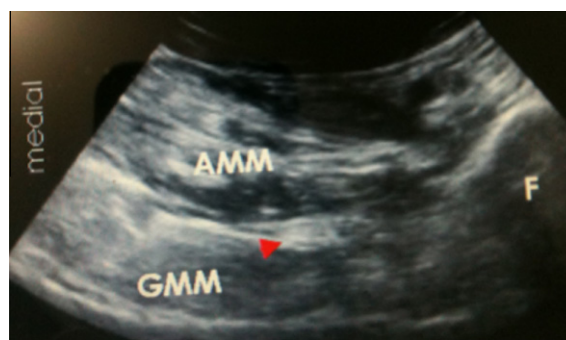The sciatic nerve was located significantly deeper in the Para group than Aysun group (Table 2).

There was significant difference ( $p < 0.05$ ) in time to visualize the sciatic nerve on the US screen between the two groups ( $42.1 \pm 5.1$  s, versus  $38.6 \pm 3.2$  s) for Para and Aysun groups respectively (Table 2).

Although the entire needles could rarely be seen while being advanced in either group, needle tip was visualized in most cases by movement of the tissue around the needle. When the contact between the nerve and the needle tip was confirmed using both ultrasound and nerve stimulation with similar electric currents between the groups, the depth of the needle was significantly longer in the Para group than Aysun group ( $13.15 \pm 0.7$  versus  $10.6 \pm 0.5$  cm) (Table 2).

There was a significant difference in the block execution time for the sciatic nerve block between Para and Aysun groups ( $6.4 \pm 1.6$  versus  $5.4 \pm 1.27$  min) respectively (Table 2). The total execution time for Para group was longer for combined femoral and sciatic block ( $12 \pm 1.5$  min) than Aysun group ( $11 \pm 1.1$  min) and this difference was statistically significant (Table 2).

As regard the quality of the sciatic image on the US screen, there was 20 patients out of 26 with good image in Para group



**Figure 4** Aysun approach for sciatic nerve block.

and 21 out of 25 in Aysun group ( $p > 0.05$ ), whereas 4 patients in Para group and 3 patients in Aysun group with fair image ( $p > 0.05$ ). There were two patients with poor image in the Para group and one patient in Aysun group ( $p > 0.05$ ) (Table 3).

A complete motor and sensory blockade at 45 min was recorded in 24 patients out of 26 in Para group (92.3%), while it was 24 patients out of 25 in Aysun group (96%) (Table 4). The remaining patients in both groups demonstrated only partial block as follow: two patients in Para group had no motor at the tibial nerve; while in Aysun group; one patient had no sensory block at common peroneal nerve. No patient in both groups was recorded with failed block. Out of the 24 patients with complete block in Para group, only two patients was considered to have inadequate block (required additional analgesia and sedation during surgery) while in Aysun group, the block was inadequate in one patient out of 24 patients with complete block (Fig. 1), this difference was statistically insignificant ( $p > 0.05$ ).

There were no significant differences as regard the duration of the block and the onset time between the two groups ( $p > 0.05$ ) (Fig. 2). Also, there was no effect of leg rotation on nerve visualization in Para group and for all groups there was no hemodynamic changes, or neurological complication, such as prolonged sensory or motor dysfunction, were observed postoperatively.

Statistical analysis; data were checked, entered and analyzed by using (SPSS version 19). Data were presented as mean + SD for quantitative variables, number and percentage for categorical variables. CHI-squared  $\chi^2$  or Fisher exact and  $t$ -test were used when appropriate.  $p < 0.05$  was considered statistically significant.

#### 4. Discussion

The combination of sciatic nerve and femoral blocks is an alternative to general or neuro-axial blocks for patients undergoing surgery of the lower extremities [17].

The location of the sciatic nerve varies among individuals even with landmarks that can be easily identified. In addition, since the sciatic nerve in the anterior approach is deeply located, the block needle has to travel along distance, and the needle tip can easily deviate from the target nerve. In contrast, ultrasound visualization enabled us to guide the needle to the nerve before a nerve stimulator was turned on despite that visualizing the entire needle was not possible [15].

**Table 1** Demographic data and patient characteristics.

	Paral group (n = 26)	Aysun group (n = 25)	P
Age (years)	37.2 + 6.0 (25–48)	38.0 + 7.0 (25–49)	0.65
Gender			
Male/female	12/14	11/14	0.87
Height (cm)	164.0 + 7.2 (152–175)	164.5 + 6.1 (155–175)	0.79
Weight (kg)	65.8 + 11 (55–72)	66.2 + 13 (54–73)	0.74
BMI (kg/m <sup>2</sup> )	23.9 + 3.9 (18–26)	24.1 + 4.0 (18–27)	0.8
ASA(1/11)	14/12	19/6	

Data are presented as mean + SD,  $p > 0.05$  was considered statistically insignificant.

**Table 2** Ultrasound measurements and block characteristics.

	(Para) group <i>n</i> = 26	(Aysun) group <i>n</i> = 25	<i>p</i>
Nerve depth (cm)	11.5 + 0.7 (10–12)	8.6 + 0.5 (8–9)	< 0.001
Needle depth (cm)	13.15 + 0.7 (12–14)	10.6 + 0.5 (10–11)	< 0.001
Time to perform sciatic nerve block (min)	6.4 + 1.6 (4–9)	5.4 + 1.23 (3–8)	0.016*
Time to perform femoral and sciatic nerve block (min)	12.0 + 1.5 (10–14)	11.0 + 1.1 (10–13)	0.04*
Time to identify sciatic nerve on US screen (s)	38.6 + 3.2 (35–45)	42.1 + 5.1 (35–50)	0.004*

Data are represented as mean + SD, and range.

\*  $p < 0.05$  was considered statistically significant.

Ultrasound guided technique may improve the success and the safety of the sciatic and other peripheral nerve blocks, assessing in avoiding vascular structures, and allowing direct observation of local anesthetic around neural targets [18,19] with nerve stimulator guidance, it is not reliably possible to surround major nerves with local anesthetic.

In Jan Van Gaffen et al. [20] study, they used the electrical nerve stimulation as a complementary technique if there was any doubt as to which tissue was being visualized and the decision to start injection of local anesthetic was based on the ultrasonographic view of the relationship of the needle and nerve.

Ota et al. [15] used a nerve stimulator with US for anterior approach to sciatic nerve in comparison with posterior approach although the authors are experienced with ultrasound and reported that a percentage of 95% is reliable for sciatic nerve visualization and reflects clinical practice, even of those who are most experienced with US guided regional anesthetic techniques.

In the present study, both US and nerve stimulation were used simultaneously in all patients, this was because the sciatic nerve located deep and might have been less clearly visualized. The high rate of visualization of the sciatic nerve with the anterior approach in the present study (96% in Aysun and 92% in Para groups) may be explained by the use of relatively young and non obese patients (BMI, 18–27 kg/m<sup>2</sup>) in both groups) enrolled in the study. In elderly patients, muscles can be atrophic and the fascia may not be distinguishable with ultrasound [21,22], in obese patients, the nerve would have been located deeper and might have been less clearly visualized [23].

One possible explanation for problems to visualize the sciatic nerve in 2 patients in Para group and one patient in Aysun group might be the high anisotropy of this nerve, which requires an exact angulation of the ultrasound probe. Another explanation could be the low frequency sector which was used for the sciatic nerve.

When nerve stimulation is used in conjunction with ultrasound, the fine needle adjustments necessary to obtain the lowest current intensity become unnecessary. Functional feedback such as muscular contraction may serve as a warning to avoid inadvertent injection into the nerve. Nerve stimulation helps to identify the nerve, as mistakes and misinterpretation of ultrasound image can occur specially with the deep nerves [24].

Ultrasound imaging, an alternative tool to localize peripheral nerves, may facilitate block performance; however, its usefulness during anterior combined femoral and sciatic block in one needle injection has not been assessed.

In the present study the complete block was obtained in 96% and 92% in group Aysun and Para respectively. A complete block was obtained in Steur's study [6] with 100% success rate in 197 cases of children scheduled for combined femoral and sciatic block, Steur was considering different criteria rather than used in the present study for estimation of a successful block.

On the other hand Pandin et al. [7] reported a success rate of 83% for combined sciatic and femoral block.

So, in the present study the use of US and nerve stimulator increases the success rate and this is consistent with Dufour et al. [16] study who reported that combined US and neurostimulation guidance increase the success rate of popliteal nerve block. Also Using various techniques of nerve localization, high success rates from 79% to 100% have been reported [25].

The quality of block was evaluated in the present study by measuring the need for additional analgesia and/or sedation during surgery in patients with complete block. The complete block was considered inadequate with 2 patients in Para group out of 24 patients and 1 patient in Aysun group out of 24 patients. As a matter of fact, the need for additional sedation or analgesia during surgery under regional anesthesia attributed for many reasons: the mixture of local anesthetic used, the type of the nerve blocked as well as the injection in close proximity to the nerve [26]. In the present study, only bupivacaine 0.5% was used to perform the block and so the quality of the block could be enhanced if some adjuvant were used.

The present study utilized the plain bupivacaine 0.5% for combined sciatic and femoral block. The onset time of block recorded was 28 and 30 min in both groups. Similarly, Pandin et al. [7] and Ota et al. [15], were reported the mean time for the onset of sciatic nerve block of about 20–30 min by using different mixtures of local anesthetics. Also the duration of the block recorded in the present study with the two groups ranged between 246 ± 10 and 240 ± 12 min, as a matter of fact, it is well known that the onset time as well as the duration of the block depends on mainly the local anesthetic mixture used [27].

**Table 3** Quality of ultrasound sciatic image.

	Para (group)		Aysun (group)		<i>p</i>
	<i>n</i> = 26		<i>n</i> = 25		
Good (nerve outline clearly circumscribed)	20	76.9%	21	84.0%	0.77
Fair (nerve outline not entirely visualized)	4	15.4%	3	12.0%	0.78
Poor (doubt as to the nature of the image)	2	7.7%	1	4.0%	0.79

Data are represented as, No. or % of total patients in each group.  $p > 0.05$  was considered statistically insignificant.

**Table 4** Block assessment (at 45 min).

	Para (group)	Aysun (group)	<i>p</i>
Complete			
Number	24	24	0.97
Percentage	92.3	96.0	
Partial			
Number	2	1	0.98
Percentage	7.7	4.0	
Failed	0	0	

Data are represented as No. or % of total patients in each group.

Volka et al. [18] demonstrated that if the needle is above the lesser trochanter, an internal rotation of thigh leg facilitates the location of the sciatic nerve, whereas an external rotation facilitates an approach of the sciatic nerve below the lesser trochanter.

In the present study as opposed to Aysun et al. approach, rotation of the leg does not have a significant effect on the ability to reach the nerve with Parafemoral approach.

The use of peripheral nerve stimulator for nerve localization has been the “gold standard” for performing peripheral nerve blocks for the last two decades, and has been shown to be a highly effective technique for determining adequate needle placement to produce regional anesthesia/analgesia [28]. Whether or not the use of ultrasound can improve practitioners’ ability to successfully perform peripheral nerve blocks remain controversial [29].

Several randomized controlled trial have been conducted to compare these two modalities [30–33] but the number of patients in each study has been too small to conclusively demonstrate superiority of one technique over another. But, there was a meta-analysis of randomized controlled trials made by Abraham et al. [29] suggested that US guidance of peripheral nerve block produce a higher rate of block success, shorter procedure times, faster onset time, and longer block duration and reduce the risk of inadvertent vascular puncture during block performance. So, US can improve block success rates, especially for anesthetist who don’t frequently perform peripheral nerve blocks or for those supervising trainee.

Although some nerves can be visualized by US, nerve stimulation is needed to ascertain exactly which nerve root or peripheral nerve is closest to the needle tip. It has been shown that the success rates of blocks for surgical anesthesia are influenced by specific individual nerve. Lacking the ability to specifically identify individual nerves with certainty, it is difficult to make an argument that ultrasonography can improve success rate [34].

Urmey 2010 in his study reported that no differences have been shown in block success or complication rates between the two techniques. Gelfand et al. [35] in their meta-analysis suggested that US guided peripheral nerve blocks are associated with increase success rate of some specific blocks (brachial plexus, sciatic nerve and popliteal nerve) even when compared with that by nerve stimulation only.

Anyway it is important to maintain proficiency in the use of both electrical nerve stimulation and ultrasonographic guidance for optimal practice and teaching of peripheral nerve or plexus anesthesia. Ideally both techniques may often be used in conjunction, enabling the practitioner and patient the benefits of each technique during simultaneous use [34].

So, in anterior approach for sciatic nerve block, it is best to use the two techniques simultaneously, this is because the location of the sciatic nerve in anterior approach was deeper than in other approaches.

The mean time required to perform the sciatic block in the present study was  $5.4 \pm 1.23$  and  $6.4 \pm 1.6$  min in the two groups, this is consistent with Ota et al. [15] while in the present study, the total execution time needed to apply combined sciatic and femoral block was  $12 \pm 1.5$  and  $11 \pm 1.1$  min in both groups. The explanation for the prolonged time could be the inclusion of the time required for changing the transducers as well as the time required for surrounding the nerves with the local anesthetic guided with US.

Dufour et al. [16] reported that combined ultrasound and neurostimulation guidance does not decrease block time but increase the success rate of popliteal sciatic nerve block observed at 30 min.

In the present study no complication or adverse events was reported in both groups. Pandin et al. [7] reported failure to locate the sciatic nerve successfully in 4 patients and intravascular injection with one case, but in the present study, the use of US guidance could be considered as the main factor for avoidance of such complications.

The limitation of the study is that it was not possible to blind the anesthetist who performed the nerve block (the author), so a blind observer who investigated the success and the other parameters was available. Also the time needed to change the transducer to perform the sciatic and femoral block was not excluded and so the total execution time was long. One day, there will be an advanced transducer which act in both high and low frequency with no need for change.

In conclusion, these technically easy and reliable combined anterior approaches to perform lower limb anesthesia can be considered a valuable alternative to traditional multiple punctures especially in supine patients who cannot be mobilized easily because of trauma, arthritis, etc. Also, the present study showed that the both anterior approaches can be performed

under US guidance and neurostimulation and there were no differences between them suggest that we can select the approaches interchangeably for lower limb surgery. Further clinical studies with the use of different local anesthetic mixtures or additives are recommended to investigate how to enhance the quality of the block.

## References

- [1] Beck GP. Anterior approach to sciatic nerve block. *Anesthesiology* 1963;24:222–4.
- [2] Van Elstraete AC, Poey, Lebrun T, et al. New landmarks for the anterior approach to the sciatic nerve block: imaging and clinical study. *Anesth Analg* 2002;95:214–8.
- [3] Chelly JE, Delaunay. A new anterior approach to the sciatic nerve block. *Anesthesiology* 1999;91:1655–60.
- [4] Labat G. Its technique and clinical applications. *Regional Anesthesia*. 2nd ed. Philadelphia: Saunders Publishers; 1924, p. 45–55.
- [5] Raj PP, Parks RI, Watson TD. A new single-position supine approach to sciatic-femoral nerve block. *Anesth Analg* 1975;54:489–93.
- [6] Steur RJ. Combined sciatic and femoral nerve block with a one needle/one point injection technique. *Tech Reg Anesth Pain Manage* 2002;6(3):128–30.
- [7] Pandin P, Vancutsem N, Salengros JC, et al. The anterior combined approach via a single skin injection site allow lower limb anesthesia in supine patients. *Can J Anesth* 2003;50(8):801–4.
- [8] Aysun UZ, Apaydin N, Cinar SO, et al. A novel approach for anterior sciatic block: cadaveric feasibility study. *Surg Radiol Anat* 2010;32:873–8.
- [9] New York School of Regional Anesthesia (NYSORA). Siatic nerve (anterior parafemoral technique); 2009.
- [10] Marhofer P, Chan VWS. Ultrasound-guided regional anesthesia: current concepts and future trends. *Anesth Analg* 2007;104:1265–9.
- [11] Marhofer P, Greher M, Kapral S. Ultrasound guidance in regional anesthesia. *Br J Anaesth* 2005;94:7–17.
- [12] Kamakar MK, Kwork WH, Ho AM, et al. Ultrasound-guided sciatic nerve block. Description of a new approach at the subgluteal space. *Br J Anaesth* 2007;9:390–5.
- [13] Jan Van Gaffen G. Ultrasound guided subgluteal sciatic nerve blocks with stimulating catheter in children: a descriptive study. *Anesth Analg* 2006;103:328–33.
- [14] Chan VWS, Nova H, Abbas S, Mccarney CJL, et al. Ultrasound examination and localization of the sciatic nerve: a volunteer study. *Anesthesiology* 2006;104:309–14.
- [15] Ota J, Sakura S, Hara K, et al. Ultrasound guided anterior approach to sciatic nerve block: a comparison with the posterior approach. *Anesth Analg* 2009;108:600–5.
- [16] Dufour E, Quennesson P, Van Robias A, et al. Combined ultrasound and neurostimulation guidance for popliteal sciatic nerve block: a prospective, randomized comparison with neurostimulation alone. *Anesth Analg* 2008;106:1553–8.
- [17] Macalus V, Hogan MD, Richard E, et al. Anesthesia for total hip and knee arthroplasty: a review of lumbar plexus, femoral, and sciatic nerve blocks. *Am J Orthop* 2009;38(8): E129–33.
- [18] Volka JD, Hadzic A, April E, et al. Anterior approach to sciatic nerve block: the effect of leg rotation. *Anesth Analg* 2001;92:460–2.
- [19] Gray AT, Collins AB, Schafhalter-Zoppoth I. Sciatic nerve block in a child: a sonographic approach. *Anesth Analg* 2003;97:1300–2.
- [20] Jan Van Gaffen G, Pirotte T, Gielen MJ, et al. Ultrasound-guided proximal and distal sciatic nerve blocks in children. *J Clin Anesth* 2010(22):241–5.
- [21] Saranteas T, Chantzi C, Iatrou C, et al. Ultrasound and regional anesthesia techniques – is there limitation? *Reg Anesth Pain Med* 2007;32:546–7.
- [22] Peetrans P. Ultrasound of muscles. *Eur Radiol* 2002;12: 35–43.
- [23] Chantz C, Saranteas T, Zogogiannis J, et al. Ultrasound examination of the sciatic nerve at the anterior thigh in obese patients. *Acta Anaesthesiol Scand* 2007;51:132.
- [24] Chan VW, Perlas A, Mc cartney CJ, et al. Ultrasound guidance improve success rate of axillary brachial plexus block. *Can J Anaesth* 2007;54:176–82.
- [25] Borgeat A, Blumenthal A, Karvoic A, et al. Clinical evaluation of a modified posterior anatomical approach to performing the popliteal block. *Reg Anesth Pain Med* 2004;29:290–6.
- [26] Morgan GE, Mikhail MS, Murry MJ. *Peripheral nerve blocks*. In: Morgan GE, Mikhail MS, Murry MJ, editors. *Clinical anesthesiology*. New York:Mc Graw-Hill publisher;2010.p. 344–5.
- [27] Fanelli G, Casati a, Aldegheri G, et al. Cardiovascular effects of two different regional anesthetic techniques for unilateral leg surgery. *Acta Anesth Scand* 1998;42:80–4.
- [28] Fanelli G, Casati A, Garancini P, et al. Nerve stimulator and multiple injection technique for upper and lower limb blockade: failure rate, patient acceptance, and neurologic complications. Study group on regional anesthesia. *Anesth Analg* 1999;88: 847–52.
- [29] Abrahams MS, Aziz MF, Horn JL. Ultrasound guidance compared with electrical neurostimulation for peripheral nerve block: a systematic review and meta-analysis of randomized controlled trials. *Br J Anaesth* 2009;102(3):408–17.
- [30] Kopral S, Greher M, Huber G, et al. Ultrasound guidance improve the success rate of interscalene brachial plexus blockade. *Regional Anesth Pain Med* 2008;33:253–8.
- [31] Macaire P, Singelyn F, Narchi P, et al. Ultrasound or nerve stimulation-guided wrist blocks for carpal tunnel release: a randomized prospective comparative study. *Reg Anesth Pain Med* 2008;33:363–8.
- [32] Sauter AR, Dogson MS, Stubhang A, et al. Electrical nerve stimulation or ultrasound guidance for lateral sagittal infraclavicular blocks: a randomized, controlled, observer-blinded comparative study. *Anesth Analg* 2008;106:1910–5.
- [33] Perlas A, Brull R, Chan VW, et al. Ultrasound guidance improve the success of sciatic nerve block at the popliteal fossa. *Reg Anesth Pain Med* 2008;33:259–65.
- [34] Urmey WF. Electrical stimulation and ultrasound in regional anesthesia. *Eur J Pain* 2010;4:319–22.
- [35] Gelfand HJ, Pierre JP, Ouanes DO, et al. Analgesic efficacy of ultrasound-guided regional anesthesia: a meta-analysis. *J Clin Anesth* 2001;23:90–6.