



## Airway management of post burn contracture neck – An anaesthesiologist's challenge

KiranPreet Kaur, Susheela Taxak, Sarla Hooda, Gunjan Chowdhary & Sanjay Johar

To cite this article: KiranPreet Kaur, Susheela Taxak, Sarla Hooda, Gunjan Chowdhary & Sanjay Johar (2012) Airway management of post burn contracture neck – An anaesthesiologist's challenge, Egyptian Journal of Anaesthesia, 28:3, 233-236, DOI: [10.1016/j.egja.2012.02.011](https://doi.org/10.1016/j.egja.2012.02.011)

To link to this article: <https://doi.org/10.1016/j.egja.2012.02.011>



© 2012 Egyptian Society of Anesthesiologists. Production and hosting by Elsevier B.V.



Published online: 17 May 2019.



Submit your article to this journal [↗](#)



Article views: 76



View related articles [↗](#)



Egyptian Society of Anesthesiologists  
Egyptian Journal of Anaesthesia

www.elsevier.com/locate/egja  
www.sciencedirect.com



Case report

# Airway management of post burn contracture neck – An anaesthesiologist's challenge

KiranPreet Kaur \*, Susheela Taxak, Sarla Hooda, Gunjan Chowdhary,  
Sanjay Johar

Department of Anaesthesiology and Critical Care, Pt. B.D. Sharma PGIMS, Rohtak-124001, India

Received 27 September 2011; revised 10 February 2012; accepted 18 February 2012  
Available online 14 June 2012

## KEYWORDS

Airway management in  
burns;  
Oral fibreoptic;  
Difficult airway;  
Berman's airway

**Abstract** Airway management is a challenge to anaesthesiologist owing to fixed flexion deformity resulting in nonalignment of oral, pharyngeal and laryngeal planes for intubations. The Ovassapian fibreoptic intubating airway, Williams airway intubator and the Berman oropharyngeal airway may provide a conduit for the bronchoscope. We present the successful anaesthetic management of a patient with obliteration of nasal passages, microstomia and severely limited neck extension by awake oral fibreoptic intubation aided by Berman's airway.

© 2012 Egyptian Society of Anesthesiologists. Production and hosting by Elsevier B.V.  
Open access under [CC BY-NC-ND license](#).

## 1. Introduction

Airway management in patients with orofacial and neck burns is often a challenge to the anaesthesiologist. Restricted mouth opening, decreased oropharyngeal space, limited atlanto-occipital joint extension, reduced submandibular space compliance and heavily fibrosed neck inevitably leads to difficult airway

[1]. Contracture of the neck, microstomia and fibroses of nose are sequelae of orofacial burns. These patients generally present to the hospital for release of contractures. Airway management in this setting is a challenge to anaesthesiologist owing to fixed flexion deformity resulting in nonalignment of oral, pharyngeal and laryngeal planes for intubations. Such patients are usually managed along the awake limb of difficult airway algorithm [2].

It is important to emphasise the fact that the basic value of anaesthetic management includes not only technology and the procedures used by anaesthesiologists but also the role of anaesthesiologists in the administrative and organisational support of health care delivery [3].

We present the successful anaesthetic management of a patient with obliteration of nasal passages, microstomia and severely limited neck extension by awake oral fibreoptic intubation aided by Berman's airway. Airway management in such patients is still controversy. This report also describes the alternative mode of airway management such a difficult scenario.

\* Corresponding author. Address: 52/9J, Medical Enclave, Rohtak 124 001, Haryana, India. Tel.: +91 1262 213171.

E-mail address: [kiranpreet72@rediffmail.com](mailto:kiranpreet72@rediffmail.com) (K. Kaur).

Peer review under responsibility of Egyptian Society of Anesthesiologists.



Production and hosting by Elsevier

## 2. Case report

A 26 year old ASA I male with history of acid burn was scheduled for microstomia correction, neck contracture release and skin grafting. He sustained severe orofacial and neck burns 5 months back when someone threw acid on him. His medical history was insignificant. On examination, he had microstomia and mouth opening was just 7 mm. Burns also involved the eye and the nose. There was fibrosis and obliteration of nasal passages (Fig. 1). He had severe fibrosis of anterior neck with fixed flexion deformity. Mallampati examination could not be performed due to limited mouth opening and flexed neck. Apart from airway findings his rest of clinical examination was normal. X-ray soft tissue neck showed decreased oropharyngeal space.

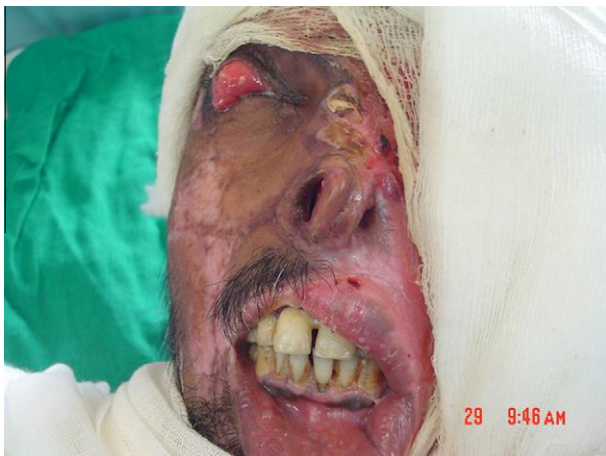### 2.1. Preoperative preparation

Before taking up the patient for surgery, thorough preoperative preparation was done, including the arrangement of difficult airway equipment, including a stylet, different sizes of face mask, oral and nasopharyngeal airways, different sizes of endotracheal tube, Macintosh and McCoy laryngoscope blades, a laryngeal mask airway (LMA), a Proseal laryngeal mask airway (PLMA), an intubating LMA, a fibre-optic bronchoscope and a tracheostomy set.

### 2.2. Anaesthetic management

Our first plan was awake oral fibreoptic bronchoscopy (FOB) and intubation through Berman's airway and alternative plan was release of contracture and microstomia correction under ketamine anaesthesia, followed by direct laryngoscopy intubation or LMA insertion, if FOB intubation failed. On the patient's arrival in the operating room an intravenous line was maintained with 18 gauge cannula. All the monitoring devices were placed, including continuous electrocardiography, O<sub>2</sub> saturation of arterial blood and non-invasive blood pressure cuff. Baseline arterial pressure, heart rate, respiratory rate and room air O<sub>2</sub> saturation were 110/60 mm Hg, 98 beats/min, 18/min and 97%, respectively.

Intravenous glycopyrrolate was administered. Oropharyngeal airway was anaesthetized by gargling and lidocaine spray.



**Figure 1** Clinical photograph of patient with acid burns.

A 6.5 mm flexometallic endotracheal tube was mounted on to adult fiberscope. We negotiated Berman's airway size 9 cm through the narrow mouth opening. FOB was negotiated through Berman's airway and 2 ml of 2% lidocaine was administered through FOB on the vocal cord down to trachea and the intubation was carried out subsequently without any difficulty. The tube position was confirmed, fixed and secured. Anaesthesia was maintained subsequently with N<sub>2</sub>O-oxygen-sevoflurane and incremental doses of injection Atracurium. Intravenous fentanyl (100 microgram) was used to provide intraoperative analgesia. The lungs were mechanically ventilated to achieve normocarbida. The intraoperative period was uneventful and patient's trachea was extubated with patient awake and breathing spontaneously. Patient was stable in the postoperative period, and was shifted to ward after being monitored for 4 h in the recovery room. His further stay in the hospital was uneventful and was discharged home after 10 days.

## 3. Discussion


Post burn contracture of the neck with fixed flexion deformity pose significant challenge to the anaesthetist. The causes of difficult endotracheal intubation fall into four main categories: limited oropharyngeal space, decreased pharyngeal space, decreased atlanto occipital extension and decreased submandibular compliance. Decreased oropharyngeal space or a mouth that is contracted from scarring due to burns may limit space for visualisation on direct laryngoscopy. This contributes to an inability to align the oral and the pharyngeal axes [4]. Various options available for intubation in such cases are: awake fibreoptic intubation, LMA, ILMA, blind nasal intubation, retrograde intubation, tracheostomy. Use of fibreoptic intubation is the gold standard when compared to other techniques [2,5]. ILMA and LMA was not possible in our case due to extremely limited mouth opening. Tracheostomy was not suitable in this patient because of fibrosed neck structures and loss of anatomical landmark [1]. Bullard laryngoscope is another suitable alternative in such situation but its use has been questioned as difficult to operate and expensive, it is a valuable alternative in the management of the difficult airway patient. In the subsets of patients with known mouth opening difficulties, it has been proven to be extremely helpful [6]. Its use was ruled out due to non availability of this instrument in our set up.

Our patient had associated microstomia and fibrosis of bilateral nostrils which made airway management even more problematic and challenging. Nasal route of fibreoptic is generally considered easier because the angle of curvature of the endotracheal tube naturally approximates to that of upper airway [1,7]. However it was not possible in our case, because of avulsion of nasal passages. Oral fibreoptic intubation can be technically more difficult because of the difficulty in advancing a tube over an orally inserted fibrescope as the tube tends to move posterior to the glottis, such as onto the arytenoids cartilage or into the oesophageal inlet. When performing an oral fibreoptic intubation, an alternate channel that creates a more anterior curvature is required, and this is provided by one of the commercially available airways [1].

The Berman oropharyngeal airway, Ovassapian fibreoptic intubating airway and Williams airway intubator and the may provide a conduit for the bronchoscope (Figs. 2-4).



**Figure 2** Berman's airway.



**Figure 3** Ovassipian's airway.

Williams airway intubator and the Berman oropharyngeal airway are superior in this role. Berman's airway allows a tracheal tube to be passed directly through its channel into the glottis [8]. Few authors did not prefer using Berman airway, as it has a longer curved portion which could have resulted in acute angulation and difficulty in advancement of the endotracheal tube [1,8]. In our patient, we were successful in intubating the patient through Berman's airway without any difficulty.

Patil-Syracuse and the Williams airway intubator have anterior channel offering more direct access to an anterior glottis. However, the Patil-Syracuse airway must be removed, from the oropharynx, before a tracheal tube can be advanced over the fiberoptic cable and into the glottis. Removal of the airway from the oropharynx further narrows oropharyngeal space and precludes its use. In contrast, the Williams airway intubator allows for a tracheal tube to be passed directly through its anterior channel into the glottis. It can be removed by slipping it over the tracheal tube [4].

A combination of Trachlight and MADgic atomizer can also provide excellent topical anaesthesia of the airway for awake orotracheal intubation. This technique is easy to perform, well tolerated by the awake patient, and useful in difficult intubation but transillumination can be the problem in patients having dense fibrous band [9]. If all above maneuver fails we are left with option of release of contracture and



**Figure 4** Williams' airway.

microstomia correction under ketamine anaesthesia, followed by direct laryngoscopy intubation or LMA insertion.

Problems are associated with extubation such patients but an effective extubation strategy should have a low reintubation rate and not cause patient discomfort. It also should enable oxygenation and ventilation and facilitate reintubation if necessary. The ASA Task Force on Difficult Airway Management recommends a preformulated strategy for extubation of the difficult airway. The extubation strategy of the difficult airway should be adjusted to the type of surgery, the medical condition of the patient, and the experience and preference of the anesthesiologist. The airway exchange catheter (AEC) is such a device, designed to maintain access to the airway after extubation and considered as an integral part of staged extubation. Availability of appropriate know-how and equipment at the time of, and immediately after, extubation, and preparedness for the possibility of extubation failure will remain the mainstays of any safe extubation strategy [10].

In conclusion, we recommend that thorough understanding of difficulty and preparation for difficult airway should be meticulous before taking up such cases for surgery. Proper intraoperative planning and team work is necessary for a positive outcome to manage such cases. While intubating patients with orofacial burns difficult intubation kit including fiberoptic bronchoscope must be kept ready in the operating room. This will help in timely management of the airway as well as prevent any adverse events in the perioperative period.

## References

- [1] Sahajanandhan R, Saravanan PA, Ponniah M, Jacob JI, Gupta AK, Nambi GI. Post burn contracture neck with extreme microstomia and fibrosed obliterated nose – a unique airway challenge! *J Anaesth Clin Pharmacol* 2010;26(2):267–9.
- [2] Singh SK, Asthana V, Payal YS, Agrawal S, Singh DK, Srivastava N. Airway management in fixed flexion deformity using an alternative method of ILMA insertion. *Ind J Anaesth* 2008;52(4):440–2.

- [3] Belba M, Belba G. Spread of burn and non-burn pathologies, anaesthetic support and some management data. *Ann Burns Fire Dis* 2007;20(3):140–3.
- [4] Gupta P, Talwar V, Verma S, Mahajan S, Gogia AR. Modified mouth prop for orotracheal fiberoptic intubation. *J Anaesth Clin Pharmacol* 2006;22(1):65–7.
- [5] Agrawal S, Asthana V, Chopra G, Sharma J, Saxena A, Ranjan M. Alternative technique Of ILMA insertion in a case of post burn neck contracture release. *Internet J Anesthesiol* 2006;10(2).
- [6] Márquez XG, Márquez AE. The bullard laryngoscope as an alternative in difficult airway management. A review. *Difficult Airway* 2002;(3)1:8–14 <[www.vicer.org](http://www.vicer.org)> .
- [7] Mallampati SR. Clinical sign to predict difficult tracheal intubation (hypothesis). *Can J Anaesth* 1983;30:316.
- [8] Greenland KB, Irwin MG. The Williams Airway Intubator, the Ovassapian Airway and the Berman Airway as upper airway conduits for fiberoptic bronchoscopy in patients with difficult airways. *Curr Opin Anaesthesiol* 2004;17(6):505–10.
- [9] Xue FS, Yang QY, Liao X. Topical anaesthesia of the airway using Trachlight and MADgic atomizer in patients with predicted difficult tracheal intubation. *Br J Anaesth* 2007;99(6):920–1.
- [10] Peter Biro P, Priebe HJ. Staged extubation strategy: is an airway exchange catheter the answer? *Anesth Analg* 2007;105(5):1182–5.