

---

Theses and Dissertations

---

Fall 2011

# Indication specific treatment modalities for spinal disorders - a comprehensive biomechanical investigation

Aditya Vikas Ingalhalikar  
*University of Iowa*

Copyright 2011 Aditya Ingalhalikar

This dissertation is available at Iowa Research Online: <http://ir.uiowa.edu/etd/2717>

---

## Recommended Citation

Ingalhalikar, Aditya Vikas. "Indication specific treatment modalities for spinal disorders - a comprehensive biomechanical investigation." PhD (Doctor of Philosophy) thesis, University of Iowa, 2011.  
<http://ir.uiowa.edu/etd/2717>.

---

Follow this and additional works at: <http://ir.uiowa.edu/etd>



Part of the [Biomedical Engineering and Bioengineering Commons](#)

INDICATION SPECIFIC TREATMENT MODALITIES FOR SPINAL  
DISORDERS  
A COMPREHENSIVE BIOMECHANICAL INVESTIGATION

by

Aditya Vikas Ingalthalikar

An Abstract

Of a thesis submitted in partial fulfillment of the  
requirements for the Doctor of Philosophy  
degree in Biomedical Engineering  
in the Graduate College of  
The University of Iowa

December 2011

Thesis Supervisor: Professor Tae-Hong Lim

## ABSTRACT

The cause and best treatment option for mechanical low back pain due to disc degeneration remains unsolved, despite '*spinal fusion*' being the gold standard of surgical treatment, post conservative care, for a very long time. However, the potential drawbacks of spinal fusion and the ongoing evolution in the understanding of normal and symptomatic spine biomechanics, biology and mechanobiology in conjunction with the advancements in material sciences, and tissue engineering has led to a change in the clinical perspective towards treatment methodologies for spinal disorders. Clinically, a gradual shift in philosophy is being observed from a '*one size fits all*', i.e. spinal fusion for all patients with symptomatic low back pain to a '*customized approach*', i.e. patient and indication specific treatment modalities for spine care. This philosophy has laid the ground for concepts of '*motion preservation*' and '*dynamic stabilization*', the former being an established treatment modality in orthopedics for a long time. The aim of the current study is to perform a comprehensive scientific investigation to understand, evaluate and establish the *in vitro* biomechanical characteristics and performance of indication specific treatment modalities incorporating the concept of Posterolateral Disc Arthroplasty and Posterior Dynamic Stabilization for the treatment of symptomatic mechanical back pain. The results of this comprehensive study may help the clinicians to make an informed decision while selecting and designing a treating modality for their patients. To this end, the current thesis was undertaken to study the biomechanics of indication specific treatment modalities like motion preservation and dynamic stabilization with a goal to guide clinical and product development decision making.

Through the comprehensive biomechanical investigation conducted in the current thesis we were able to theoretically prove the importance of a customized approach towards the treatment of spine care. Also, the most important conclusion of the biomechanical investigation was the fact that Range of Motion results alone are not sufficient to draw significant conclusions. It is imperative that in depth analysis of the quality of motion through the determination of instantaneous center of rotation is extremely important. Previous studies have shown only a single center of rotation between the extremes of motion which is also insufficient as the end points do not determine the path taken to reach the endpoints. This in depth analysis is also important for biomedical engineers to design and develop physiologically viable implants that will mimic the performance of the physiologic spine. Clinical studies are extremely important as a next step towards validating this customized approach towards spine care.

Abstract Approved: \_\_\_\_\_

Thesis Supervisor

\_\_\_\_\_  
Title and Department

\_\_\_\_\_  
Date

INDICATION SPECIFIC TREATMENT MODALITIES FOR SPINAL  
DISORDERS  
A COMPREHENSIVE BIOMECHANICAL INVESTIGATION

by  
Aditya Vikas Ingalhalikar

A thesis submitted in partial fulfillment of the  
requirements for the Doctor of Philosophy  
degree in Biomedical Engineering  
in the Graduate College of  
The University of Iowa

December 2011

Thesis Supervisor: Professor Tae-Hong Lim

Graduate College  
The University of Iowa  
Iowa City, Iowa

CERTIFICATE OF APPROVAL

---

PH.D. THESIS

---

This is to certify that the Ph.D. thesis of

Aditya Vikas Ingalhalikar

has been approved by the Examining Committee for the  
thesis requirement for the Doctor of Philosophy degree  
in Biomedical Engineering at the December 2011 graduation.

Thesis Committee: \_\_\_\_\_

Tae-Hong Lim, Thesis Supervisor

\_\_\_\_\_  
David G. Wilder

\_\_\_\_\_  
Nicole M. Grosland

\_\_\_\_\_  
Madhavan L. Raghavan

\_\_\_\_\_  
Prem Ramakrishnan

## ACKNOWLEDGEMENTS

Indian spiritual and knowledge ethos proposes that a Guru (or Teacher) is the one who leads you from ignorance (darkness) to knowledge (light) and is symbolized as being akin to the Supreme Omnipresent Energy in whose womb and with whose guidance creation manifests and evolves towards its intended goal. I would like to express my deepest gratitude towards my guru Professor Tae-Hong Lim, PhD, whose basic teaching has laid the foundation for my understanding of spine biomechanics and without whose guidance and support I would not have been able to complete my PhD successfully. On the same note, I thank Dr. V.T. Ingalhalikar, Dr. Dilip Sengupta, and David Paul who have guided me extensively towards understanding the ‘clinical’ and ‘product development’ perspective of spine research.

My parents, Aarti and Vikas Ingalhalikar who are essentially my first teachers have influenced and molded every aspect of my life and this thesis is a testament to their efforts and personal sacrifices towards my upbringing and their continuous support for my life and career ventures. In the same light, I would like to acknowledge the teachings and guidance of my spiritual guru Dr. P. V. Vartak, which have guided me through all ups and downs.

It goes without saying, that as I worked on my PhD thesis part time for 2.5 long years, juggling between full time work and studies, my wife, Madhura Ingalhalikar supported me throughout to take on the venture and bring it to fruition. It involved a lot of sacrifices on her part in terms of the time that I had to spend away from family time and matters, while I worked even on weekends and holidays. Without her love, strong support and motivation, I would not have been able to complete my thesis successfully.

Also, as ignorant and dispassionate as I am in any type of coding, it was my wife Madhura who taught me to code in Matlab, which has been extremely useful for me in the Center of Rotation analyses.

I would also like to acknowledge my mother-in-law Manjiri Joshi who helped me brush up my concepts of vector algebra and the continuous support of my friend Prem Ramakrishnan, who also happens to be my committee member.

Last but not the least I acknowledge the support of my company Globus Medical for enabling me to submit my research work at Globus towards the completion of my thesis.

**Conflict of Interest:** I am currently an employee of Globus Medical.



## TABLE OF CONTENTS

LIST OF TABLES	vii
LIST OF FIGURES	viii
CHAPTER	
1. INTRODUCTION	1
1.1 Motivation	1
1.2 Background and Significance	2
1.3 Low Back Pain-Socio Economic Impact	3
1.4 Classification of Low Back Pain	4
1.5 Causes of Low Back Pain – Mechanical Models of Instability and Low Back Pain.	5
1.5.1 Normal Function of the Spinal Stabilizing System	6
1.5.2 Dysfunction of the Spinal Stabilizing System	8
1.5.3 Concept of Neutral Zone	10
1.6 Current Strategies for Back Pain Management and Treatment	11
1.7 Conservation Treatment Modalities	12
1.7.1 NSAIDS	12
1.7.2 Radiofrequency Denervation	13
1.7.3 Injection Therapy	14
1.7.4 Physical Conditioning Program	15
1.7.5 Manipulation and Mobilization	16
1.7.6 Back Schools	16
1.7.7 Acupuncture and Dry-Needling	17
1.7.8 Iyengar Yoga Therapy	19
1.8 Surgical Treatment Modalities	20
1.9 Paradigm Shift in the Continuum of Spine Care	22
1.9.1 Lumbar Disc Arthroplasty	22
1.9.2 Posterior Dynamic Stabilization for Discogenic LBP	25
1.9.3 Posterior Dynamic Stabilization for Transitional Stabilization.	27
1.9.4 Posterior Dynamic Stabilization for Posterior Tethering	27
2. MATERIALS AND METHODS	31
2.1 Specimen Preparation	31
2.2 Multidirectional Flexibility Testing	31
2.3 Test Apparatus	32

2.3.1	Six DOF Spine Motion Simulator	32
2.3.2	Motion Detection	33
2.3.3	Intradiscal Pressure Measurement	34
2.4	Study Design	35
2.4.1	Test Protocol	35
2.4.2	Data Analysis	37
2.4.3	Coupled Motion Complex	37
2.4.4	Effect of Surgical Intervention on Mechanical Effort	39
2.4.5	Instantaneous Center of Rotation (ICR)	40
3.	RESULTS	46
3.1	Biomechanical Characterization of Posterior Disc Arthroplasty	46
3.1.1	Flexion Extension Kinematics	47
3.1.2	Lateral Bending Kinematics	50
3.1.3	Axial Rotation Kinematics	51
3.1.4	Coupled Sagittal Plane Kinematics	53
3.1.5	Effect on Mechanical Effort	54
3.1.6	Effect on Center of Rotation	56
3.2	Biomechanical Characterization of Posterior Dynamic Stabilization	61
3.2.1	Unilateral Model	61
3.2.2	Bilateral Model	64
3.2.3	Neutral Zone (NZ) – Unilateral and Bilateral Models	68
3.2.4	Coupled Sagittal Plane Kinematics	70
3.2.5	Coupled Coronal Plane Kinematics	71
3.2.6	Effect on Mechanical Effort	73
3.2.7	Effect of Center of Rotation	74
3.3	Biomechanical Characterization of Posterior Dynamic Stabilization Adjacent to Rigid Fixation	86
3.3.1	Implanted Level (L4-L5) Kinematics	86
3.3.2	Adjacent Level (L3-L4, L5-S1) Kinematics	87
3.3.3	Load Sharing and Intradiscal Pressure	90
3.4	Biomechanical Characterization of Posterior Disc Arthroplasty in Conjunction with Posterior Tethering	91
3.4.1	Unilateral Facetectomy Model	92
3.4.1.1	Flexion-Extension Kinematics	92
3.4.1.2	Lateral Bending Kinematics	93
3.4.1.3	Axial Rotation Kinematics	94

3.4.2	Bilateral Facetectomy Model	95
3.4.2.1	Flexion-Extension Kinematics	95
3.4.2.2	Lateral Bending Kinematics	97
3.4.2.3	Axial Rotation Kinematics	98
4.	DISCUSSION	99
4.1	Biomechanical Characterization of Posterolateral Disc Arthroplasty in the human lumbosacral spine	103
4.2	Biomechanical Characterization of Posterior Dynamic Stabilization in the human lumbosacral spine	112
4.3	Biomechanical Characterization of Posterior Dynamic Stabilization adjacent to rigid fixation in the human lumbosacral spine	122
4.4	Biomechanical Characterization of Posterolateral Disc Arthroplasty in conjunction with posterior tethering in the human lumbosacral spine	127
5.	CONCLUSION	130
	REFERENCES	132
	APPENDIX A - MATLAB PROGRAM FOR COR TRACKING	141

## LIST OF TABLES

### Table

1. Unilateral model adjacent level ROM and pressure.....63
2. Unilateral model adjacent level ROM and pressure.....86

## LIST OF FIGURES

Figure		
1.	The three subsystems of the Spinal Stabilizing System.....	6
2.	Theoretical interactions between the spinal subsystems during normal functioning.....	6
3.	Theoretical interactions between the spinal subsystems during spinal Dysfunction.....	8
4.	Schematic representation of the Neutral Zone as a component of the Range of Motion.....	10
5.	Graphical Representation of the Hybrid Flexibility Protocol.....	32
6.	Customized 6 DOF Spine Motion Stimulator.....	33
7.	Representative load displacement curve (Kinematic Signature).....	34
8.	Protocols for Specific Aims 1 and 2. Specific Aim 2 was subdivided into 2A and 2B.....	36
9.	Protocols for Specific Aims 3 and 4. Specific Aim 4 was subdivided into 2A and 2B.....	36
10.	Representation of Comparative Coronal – Transverse Coupled Motion Complex.....	38
11.	Representation of Comparative Sagittal Rotation-Translation Coupled Motion Complex.....	39
12.	Representatation of Comparative Kinematic Signature of the Lumbo-Sacral Spine.....	40
13.	2D Radiographic Overlay Method for Center of Rotation.....	41
14.	Joint motion representation from frame $i$ to $i+1$ .....	44
15.	Radiograph of a PLDA system implanted post Unilateral Facetectomy.....	46
16.	Comparative Flexion ROM post surgical intervention (% of intact).....	47
17.	Comparative Flexion NZ post surgical intervention (% of intact).....	48

18.	Comparative Extension ROM post surgical intervention (% of Intact).....	49
19.	Comparative Extension NZ post surgical intervention (% of Intact).....	49
20.	Comparative Lateral Bending ROM post surgical intervention (% of Intact).	50
21.	Comparative Lateral Bending NZ post surgical intervention (% of intact)....	51
22.	Comparative Axial Rotation ROM post surgical intervention (% of Intact)...	52
23.	Comparative Axial Rotation NZ post surgical intervention (% of intact).....	52
24.	Coupled sagittal plane translation of the lumbosacral spine in flexion.....	53
25.	Coupled sagittal plane translation of the lumbosacral spine in extension.....	54
26.	Effect of PLDA placement on flexion moment loads in the lumosacral spine.	55
27.	Effect of PLDA placement on extension moment loads in the lumosacral Spine.....	55
28.	Comparative COR locus of Intact and UF constructs for flexion-extension ROM in the sagittal plane.....	57
29.	Comparative COR locus of Intact and UF constructs for flexion-extension ROM in Local Coordinate System.....	57
30.	Comparative COR locus of Intact and PLDA-P constructs for flexion extension ROM in the sagittal plane.....	58
31.	Comparative COR locus of Intact and PLDA-P constructs for flexion extension ROM in Local Coordinate System.....	58
32.	Comparative COR locus of Intact and PLDA constructs for flexion extension ROM in the sagittal plane.....	59
33.	Comparative COR locus of Intact and PLDA constructs for flexion extension ROM in Local Coordinate System.....	59
34.	Comparative COR locus of Intact and PLDA-A constructs for flexion extension ROM in the sagittal plane.....	60
35.	Comparative COR locus of Intact and PLDA-A constructs for flexion extension ROM in Local Coordinate System.....	60
36.	Radiograph of a Posterior Dynamic Stabilization System.....	61

37.	Results of multidirectional flexibility testing for <i>Unilateral Model</i> .....	62
38.	Index level ROM for Bilateral Model.....	64
39.	Superior level ROM for Bilateral Model.....	65
40.	Inferior level ROM for Bilateral Model.....	65
41.	Superior adjacent level intradiscal pressures for <i>Bilateral Model</i> .....	67
42.	Inferior adjacent level intradiscal pressures for Bilateral Model.....	68
43.	Comparative Flexion NZ post surgical intervention for the Bilateral Model.	69
44.	Comparative Extension NZ post surgical intervention for the Bilateral Model.	69
45.	Coupled sagittal plane translation of the lumbosacral spine in flexion.....	70
46.	Coupled sagittal plane translation of the lumbosacral spine in extension.....	71
47.	Coupled axial rotation during left lateral bending of the lumbosacral spine...	72
48.	Coupled axial rotation during right lateral bending of the lumbosacral spine..	72
49.	Effect of Dynamic Stabilization and Rigid Fixation on Flexion Moment Loads.....	73
50.	Effect of Dynamic Stabilization and Rigid Fixation on Extension Moment Loads.....	74
51.	Comparative Flexion-Extension COR Loci in the Global Coordinate System for Intact and PDS constructs.....	76
52.	Comparative Flexion-Extension COR Loci in the Local Coordinate System for Intact and PDS constructs.....	77
53.	Comparative Flexion-Extension COR Loci in the Global Coordinate System for Intact and BF constructs.....	78
54.	Comparative Flexion-Extension COR Loci in the Local Coordinate System for Intact and BF constructs.....	79
55.	Comparative Flexion-Extension COR Loci in the Global Coordinate System for Intact and BF+PDS constructs.....	80
56.	Comparative Flexion-Extension COR Loci in the Local Coordinate System for Intact and BF+PDS constructs.....	81

57.	Sagittal plane displacement of Intact Spine L4 rigid body origin (local coordinate system) expressed in the global coordinate system.....	82
58.	Sagittal plane displacement of Intact Spine L4 rigid body origin (local coordinate system) expressed in the global coordinate system.....	83
59.	Sagittal plane displacement of the L4-L5 COR in comparison to L4 and L5 body displacements in the global coordinate system.....	83
60.	Sagittal plane displacement of L4 rigid body origin (local coordinate system) of a PDS implanted spine expressed in the global coordinate system.....	84
61.	Sagittal plane displacement of L5 rigid body origin (local coordinate system) of a PDS implanted spine expressed in the global coordinate system.....	85
62.	Sagittal plane displacement of L4-L5 COR post PDS implantation in comparison to L4 and L5 body displacements expressed in the global coordinates.....	85
63.	Range of motion in flexion-extension of index and adjacent levels as normalized to intact motion.....	88
64.	Range of motion in lateral bending of index and adjacent levels as normalized to intact motion.....	89
65.	Range of motion in axial rotation of index and adjacent levels as normalized to intact motion.....	89
66.	Intradiscal pressure for cranial adjacent level normalized with respect to intact pressure.....	90
67.	Posterior tethering of a PLDA implanted motion segment.....	92
68.	Flexion Extension ROM at implanted (L4-L5) and adjacent (L3-L4 and L5-S1) levels Normalized to intact motion.....	93
69.	Lateral Bending ROM at implanted (L4-L5) and adjacent (L3-L4 and L5-S1) levels Normalized to intact motion.....	94
70.	Axial Rotation ROM at implanted (L4-L5) and adjacent (L3-L4 and L5-S1) levels Normalized to intact motion.....	95
71.	Flexion Extension ROM at implanted (L4-L5) and adjacent (L3-L4 and L5-S1) levels Normalized to intact motion.....	96
72.	Comparative Flexion NZ post surgical intervention for the <i>Bilateral Model</i> .....	96



73.	Comparative Extension NZ post surgical intervention for the <i>Bilateral Model</i> ...	97
74.	Lateral Bending ROM at implanted (L4-L5) and adjacent (L3-L4 and L5-S1) levels Normalized to intact motion.....	98
75.	Axial Rotation ROM at implanted (L4-L5) and adjacent (L3-L4 and L5-S1 l) levels Normalized to intact motion.....	98
76.	Continuum of Spine Care: Conventional Treatment Modalities range from a mild to severe approach. Conservative care to decompression procedures to spinal fusions.....	99
77.	Grades A-E for the assessment of lumbar disc degeneration.....	101
78.	Paradigm Shift in the Continuum of Spine Care. Dynamic Stabilization and Disc Arthroplasty have gained ground between uninstrumented treatment and instrumented spinal fusion.....	102

## CHAPTER 1

### INTRODUCTION

#### 1.1 Motivation

The cause and best treatment option for mechanical low back pain due to disc degeneration remains unsolved, despite '*spinal fusion*' being the gold standard of surgical treatment, post conservative care, for a very long time. However, the potential drawbacks of spinal fusion and the ongoing evolution in the understanding of normal and symptomatic spine biomechanics, biology and mechanobiology in conjunction with the advancements in material sciences, and tissue engineering has led to a change in the clinical perspective towards treatment methodologies for spinal disorders. Clinically, a gradual shift in philosophy is being observed from a '*one size fits all*', i.e. spinal fusion for all patients with symptomatic low back pain to a '*customized approach*', i.e. patient and indication specific treatment modalities for spine care. This philosophy has laid the ground for concepts of '*motion preservation*' and '*dynamic stabilization*', the former being an established treatment modality in orthopedics for a long time. The aim of the current study is to perform a comprehensive scientific investigation to understand, evaluate and establish the *in vitro* biomechanical characteristics and performance of indication specific treatment modalities incorporating the concept of Posterolateral Disc Arthroplasty and Posterior Dynamic Stabilization for the treatment of symptomatic mechanical back pain. The results of this comprehensive study may help the clinicians to make an informed decision while selecting and designing a treating modality for their

patients. To this end, the current thesis was undertaken and the study designed to fulfill 4 specific aims:

1. Biomechanical characterization of Posterolateral Disc Arthroplasty in the human lumbosacral spine
2. Biomechanical characterization of Posterior Dynamic Stabilization in the human lumbosacral spine
3. Biomechanical characterization of Posterior Dynamic Stabilization adjacent to rigid fixation in the human lumbosacral spine
4. Biomechanical characterization of Posterolateral Disc Arthroplasty in conjunction with posterior tethering in the human lumbosacral spine

## **1.2 Background and Significance**

Millions of people over the world experience debilitating pain at some point in their lifetime. Pain is a major health problem in the United States, where at least 50 million Americans are partially or totally disabled by intractable pain. It is defined by the International Association of Pain (IASP) as “an unpleasant sensory and emotional experience associated with actual or potential tissue damage or described in terms of such damage” [1]. Pain is typically classified as 1) acute/short term and 2) chronic/long term. Acute pain is defined as pain that may result due to a known incidence (usually mechanical) and may last over a few days or weeks. Chronic pain on the other hand is defined as the pain that persists more than 3 months and is idiopathic in nature.

### **1.3 Low Back Pain – Socio Economic Impact**

Low back pain (LBP) is one of the most common forms of chronic pain [1]. It is a generic term which may involve pathology to any of the structures surrounding the spine, i.e. muscles, vertebral body, intervertebral disc, facets, and/or ligaments. It may or may not be accompanied by radicular symptoms or sciatica. Low back pain is the second leading reason for office visits [2] and third most common reason for hospital admissions and surgical procedures [3] in the United States. Costs related to back pain in terms of lost work, hospital expenses, suffering, and loss of function are immense [4, 5]. Approximately one percent of the U.S. population is chronically disabled because of back pain and an additional one percent is temporarily disabled [6, 7]. The 1992 to 1994 National Health Interview Surveys report that back pain resulted in an average of 297 million restrictive-activity days per year and 87 million bed-disability days. Other data indicate that more than 20 million working days are lost each year. The more recent 2002 NHIS (National Health Interview Survey) and NAMCS (National Ambulatory Medical Care Survey) survey reported that low back pain accounted for a 2.3% of all office visits, which had not changed post survey conducted in 1989-1990 [4, 7]. Although the cost of back pain problems is difficult to estimate because indirect costs are not available, recent estimates suggest that the cost may be as high as \$100 billion per year [6]. In spite of the high prevalence and costs, due to the heterogeneous nature of structures involved in the pathology, a precise and complete understanding about the etiology of low back pain has been difficult [6]. Evolution of diagnostic technologies and basic science research over the last century has resulted in a gradual evolution of the knowledge of etiology of back pain, with the intervertebral disc being identified as the primary pain generator.

#### 1.4 Classification of Low Back Pain

Low Back Pain can be typically classified into five types [8]. **Type I** is the most common and the pain is usually short lived. Disturbance of muscle function is implicated but IVD degeneration may be relevant. Treatment is by fitness and exercise programs and manipulative therapy may help while self-resolution is expected. **Type II** is chronic and the pain is severe and resolves slowly, if at all. Muscle function is abnormal and IVD degeneration is implicated in some patients. However, it is unclear if the disc is intrinsically painful or if the normal segmental motion is disrupted (sometimes called ‘instability’). Treatment is rehabilitation and occasionally surgical fusion. **Type III** is nerve root pain and back pain. The common cause is IVD herniation resulting from a combination of disc degeneration, disc fragmentation and annular tear although not all IVD herniations are painful. The natural history of a symptomatic herniation runs from back pain to lower limb pain over a variable time scale. While most resolve, most that do not have to be treated by surgical excision. This is usually effective in relieving leg pain but not back pain. **Type IV** is walking related back pain and leg pain (neurogenic claudication). The pain is reduced by leaning forward, sitting or squatting. This may result from a developmental stenosis, which might be of unknown origin or associated with achondroplasia. More likely is that the stenosis is acquired by disc degeneration leading to a combination of narrowing, bulging and herniation, which deforms the segment and leads to secondary degenerative changes in the facet joints. Treatment is analgesia or decompression. **Type V** is back pain caused by serious pathology, such as cancer, infection, or fracture.

## 1.5 Causes of Low Back Pain – Mechanical Models Of Instability and Low Back Pain

The functional failure or degeneration of the intervertebral disc either due to aging or mechanical trauma, a.k.a *degenerative disc disease (DDD)* and/or *clinical instability* are clinically accepted causes of low back pain. Clinical instability is defined as the loss of the ability of the spine under physiologic loads to maintain its pattern of displacement without initial or additional neurological deficit, no major deformity and no incapacitating pain [9]. Disc degeneration and the associated back pain are controversial issues in the sense that degeneration being a part of the natural aging process, not all degenerated discs are painful in nature. So also is the case with clinical instability and associated back pain, since not all radiographically unstable discs are painful in nature. In spite of these controversies, the spine being inherently a load bearing biomechanical structure patients presenting with symptomatic disc degeneration present with certain imaging and biomechanical deficiencies based on which different mechanical theories of the causes of low back pain have been proposed. Panjabi [10] proposed a comprehensive three part model for the function, dysfunction, adaptation and enhancement of the spinal stabilizing system. According to this theory, the spinal stabilizing system is comprised of 3 sub-systems, 1.) the passive musculoskeletal subsystem, 2.) the active musculoskeletal subsystem and the 3.) the neural and feedback system. The passive musculoskeletal system includes vertebrae, facet articulations, intervertebral discs, spinal ligaments, and joint capsules, as well as the passive mechanical properties of the muscles. The active musculoskeletal subsystem consists of the muscles and tendons surrounding the spinal column. The neural and feedback subsystem consists of the various force and motion

transducers, located in ligaments, tendons, and muscles, and the neural control centers. These passive, active and neural control subsystems, although conceptually separate are functionally interdependent.

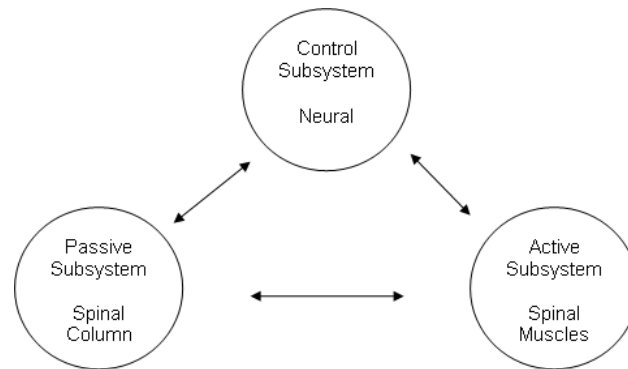


Figure 1. The three subsystems of the Spinal Stabilizing System [10]

### 1.5.1 Normal Function of the Spinal Stabilizing System

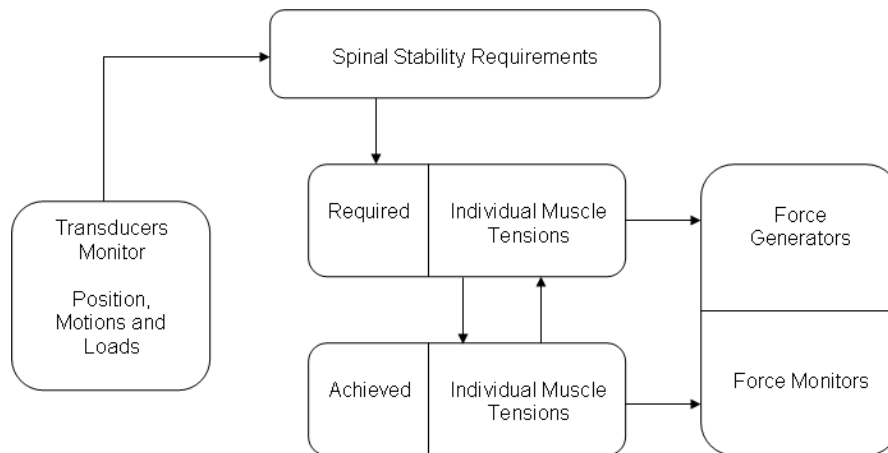


Figure 2. Theoretical Interactions between the spinal subsystems during normal functioning [10]

Components of the passive subsystem (e.g., ligaments) do not provide any significant stability to the spine in the vicinity of the neutral position. It is towards the ends of the ranges of motion that the ligaments develop reactive forces that resist spinal motion. The passive components probably function in the vicinity of the neutral position as transducers for measuring vertebral positions and motions similar to those proposed for the knee ligaments [11], and therefore are part of the neural control subsystem. Thus, this subsystem is passive only in the sense that it by itself does not generate or produce spinal motions, but it is dynamically active in monitoring the transducer signals.

The muscles and tendons of the active subsystem are the means through which the spinal system generates forces and provides the required stability to the spine. The magnitude of the force generated in each muscle is measured by the force transducers built into the tendons of the muscles. Therefore, this aspect of the tendons is part of the neural subsystem.

The neural subsystem receives information from the various transducers, determines specific requirements for spinal stability, and causes the active subsystem to achieve the stability goal. Individual muscle tension is measured and adjusted until the required stability is achieved. The requirements for the spinal stability are dependent on dynamic posture, that is, variation of lever arms and inertial loads of different masses and external loads.



### 1.5.2 Dysfunction of the Spinal Stabilizing System

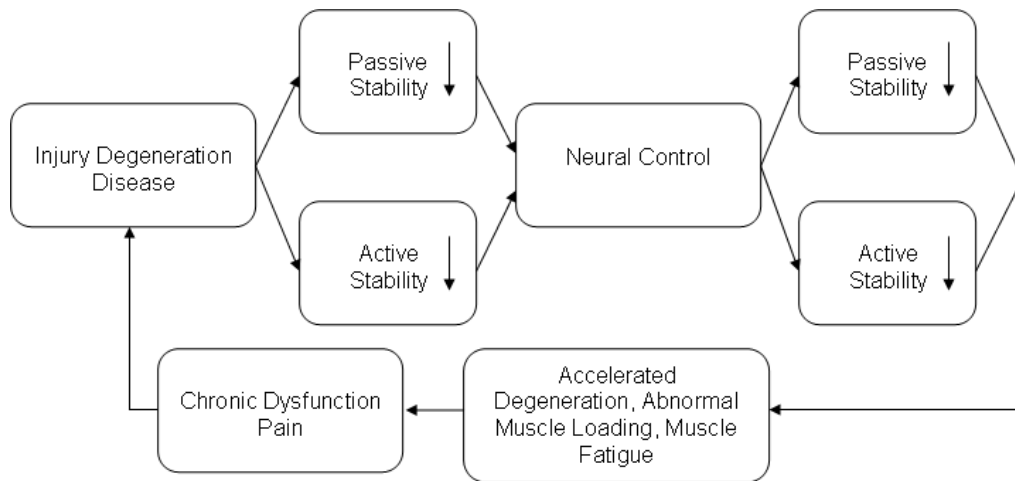


Figure 3. Theoretical Interactions between the spinal subsystems during spinal dysfunction [10]

Degradation of the spinal system may be due to injury, degeneration, and/or disease of any of the subsystems. The neural control subsystem perceives these deficiencies, which may develop suddenly or gradually, and attempts to compensate by initiating appropriate changes in the active subsystem. Although the necessary stability of the spine overall may be reestablished the subsequent consequences may be deleterious to the individual components of the spinal system (e.g., accelerated degeneration of the various components of the spinal column muscle spasm, injury, and fatigue). Over time, the consequences may be chronic dysfunction and pain.

The dysfunction of the passive subsystem may be caused by mechanical injury such as overstretching of the ligaments, development of tears and fissures in the annulus, development of microfractures in the endplates, and extrusion of the disc material into the vertebral bodies. The injury may result from overloading of a normal structure, normal

loading of a weak structure or degeneration and disease which may result in a decrease in the load bearing and stabilizing capacity of the passive subsystem. This may require compensatory changes in the active subsystem.

The active musculoskeletal subsystem may develop deterioration of its ability to receive and/or carry out the neural commands, to provide accurate feedback of muscle tension information to the neural control unit, or to produce coordinated and adequate muscle tensions; such deformation may result from disuse, degeneration, disease or injury. As a result, the stabilizing capacity of the spinal system may be decreased. This may compromise the capability of the system to both provide compensatory help to the passive subsystem when needed, and to withstand unexpected dynamic or abnormally large external loads.

Dysfunction of the neural subsystem can also develop. To achieve the required stability at every instance of time, the neural subsystem has the enormously complex task of continuously and simultaneously monitoring and adjusting the forces in each of the muscles surrounding the spinal column. Instantaneous decisions must be made to redistribute the muscle tensions, if there is a change in the posture and/or the external loads. The task is made much more complex if the posture and/or change dynamically, requiring additional considerations for masses, inertias and accelerations involved.

### 1.5.3 Concept of Neutral Zone

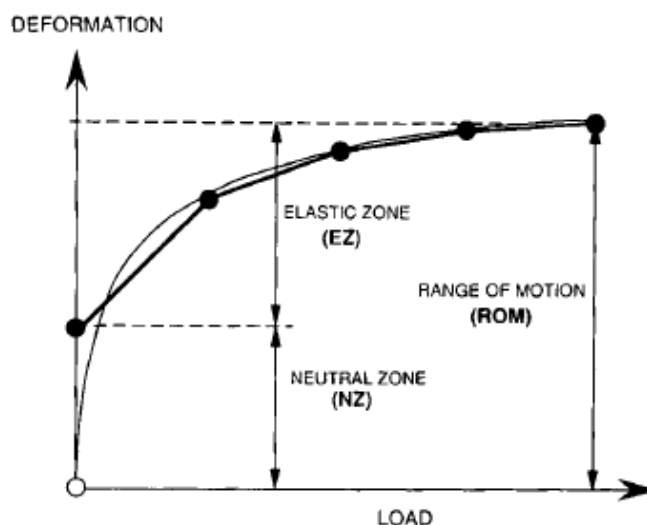


Figure 4. Schematic representation of the Neutral Zone as a component of the Range of Motion [13]

The term Neutral Zone was coined by Panjabi [12] to explain the lack of correlation between disc degeneration / clinical instability and increased Range of Motion (ROM), the degenerated disc exhibiting higher stiffness as exhibited by some studies [13]. The Neutral Zone is defined as that part of physiological intervertebral motion measured from the neutral position, within which the spinal motion is produced with a minimal internal resistance. It is the zone of high flexibility or laxity. Some of the terms and concepts used to define this proposed behavior of the spine and the associated parameters measured during *in-vitro* experimentation are defined as follows:

**Neutral Position:** The posture of the spine in which the overall internal stresses in the spinal column and the muscular effort to hold the posture are minimal

**Range of Motion (ROM):** The entire range of physiological intervertebral motion, measured from the neutral position. It is divided into two parts: neutral and elastic zones.

**Neutral Zone (NZ).** That part of the physiological intervertebral motion, measured from the neutral position, within which the spinal motion is produced with minimal internal resistance. It is the zone of high flexibility or laxity.

**Elastic Zone (EZ):** That part of the physiological intervertebral motion, measured from the end of the neutral zone up to the physiological limit. Within the EZ, spinal motion is produced against a significant internal resistance. It is the zone of high stiffness.

Based on the above concepts, clinical instability was redefined by Panjabi as a significant decrease in the capacity of the stabilizing system of the spine to maintain the intervertebral neutral zones within the physiological limits so that there is no neurological dysfunction, no major deformity and no incapacitating pain.

## **1.6 Current Strategies for Chronic Back Pain**

### **Management and Treatment**

Depending on the clinical indications and patient's response to intervention, the treatment modalities may vary from conservative approaches such as NSAIDs (Non Steroidal Anti Inflammatory Drugs), regional analgesics, physiotherapy, etc. to surgical approaches such as discectomy, laminectomy and spinal fusion.

A typical treatment paradigm for non-traumatic and benign low back pain is initiated by conservative treatment modalities. If the patient does not respond to conservative treatment even after 6 months, appropriate surgical interventions are considered based on clinical symptoms.

## **1.7 Conservative Treatment Modalities**

### **1.7.1 NSAIDS**

Nonsteroidal anti-inflammatory drugs (NSAIDs) are the most frequently prescribed medications for patients with low back pain. Per guidelines for low back pain management in primary care, they are recommended as the first option for symptomatic relief [14-17]. In most guidelines, they are recommended after paracetamol has been tried. NSAIDs may be administered through intramuscular injections, capsules or a combination of both, or gel.

The primary aims of NSAID therapy are 1) symptomatic relief and 2) facilitating early return to normal activities. The advantages of NSAIDs are their analgesic potential and anti-inflammatory action. However, some of the disadvantages of NSAID therapy are their side effects like 1) abdominal pain, 2) diarrhea, 3) edema, 4) dry mouth, 5) rash, 6) dizziness, 7) headache, 8) tiredness, etc. [40]. Recently, selective cyclooxygenase-2 (COX-2) inhibiting NSAIDs has been used as an alternative to lower the risk of gastrointestinal side effects associated with traditional NSAIDs. The efficacy of the COX-2 inhibiting NSAIDs however remains controversial due to their cardiovascular safety [18].

A Cochrane Back Review [18] of the efficacy and safety of NSAIDs concluded that NSAIDs are effective for short term global improvement in patients with acute and chronic low back pain without sciatica, although the effects are small. The effectiveness of NSAIDs relative to simple analgesics like paracetamol and other drugs was found to be unclear. Also, there was no difference in effects due to different types of NSAIDs. Traditional NSAIDs were frequently associated with gastrointestinal side effects, however COX-2 inhibitors were found to have fewer side effects than traditional NSAIDs. The effective control of drug dosage was recommended to lower the risk of serious gastrointestinal complications.

### 1.7.2 Radiofrequency Denervation

Radiofrequency denervation is defined as coagulation of nerves mediating a patient's symptoms in order to provide lasting pain relief [19]. Radiofrequency denervation has been used as a treatment modality for back and neck pain and also in the management of sacroiliac joint pain, thoracic zygapophysial pain, trigeminal neuralgia, sympathetically maintained pain, cervicogenic headaches and intercostal neuralgia [19]. The procedure involves identification of the symptomatic nerve root, minimally invasive insertion of electrodes in its vicinity and applying a current through the electrodes. Application of current and enabling localized heating of tissue to 60-80° C for 60-90 seconds results in coagulation [19].

A systematic review within the framework of Cochrane collaboration reviewed randomized controlled trials examining lumbar zygapophysial joint pain and discogenic low back pain [19]. Conflicting evidence was found on the short term effect of

radiofrequency lesioning on pain and disability in chronic low back pain of zygapophysial joint origin. Also, limited evidence was found as to its ineffectiveness in the treatment of chronic discogenic low back pain. The adverse events reported were minimal except for subsiding pain, numbness and slight loss of muscle strength. Also, due to its invasiveness, the procedure requires skilled personnel for identification and treatment of nervous anatomy and specialized equipment for conducting the procedure.

### 1.7.3 Injection Therapy

Injection therapy is used as a treatment option for patients with sub-acute and chronic low back pain [20]. The injection can be given into the facet joints, the epidural space, the spinal nerve root, the interventional disc, the lumbar sympathetic chain, sacroiliac joints, and also into local ligaments, muscles or trigger points [20]. Depending upon the nature of symptoms, the pharmacological content of the injection and its dosage may vary from different types of corticosteroids to reduce inflammation and anaesthetics to relieve pain.

A Cochrane Review for injection therapy for the treatment of sub-acute and chronic low back pain concluded that there was no sufficient evidence to support or refute the use of any injection therapy, regardless of type and dosage, for long term relief of patients with sub-acute and chronic low back pain without radicular pain [20]. A comparison of injections using different pharmacological agents such as lignocaine, lidocaine, indomethacin sodium hyaluronate, sarapin, morphin and Vitamin B12 [20] for varying symptomatic indications showed short term positive effects, however they do not necessarily translate into a successful treatment modality in clinical practice. Some of the

side effects reported were 1) headaches, 2) dizziness, 3) transient local pain, 4) nausea and 5) vomiting. Certain serious (although rare) complications of injection therapy have also been mentioned in the literature, e.g. cauda equina syndrome, septic facet joint arthritis, discitis, paraplegia, and paraspinal abscesses [20]. In a few cases, hospitalization for meningitis has also been reported in patients with a history of single or repeated injections for low back pain, 1-3 weeks prior to hospitalization.

#### 1.7.4 Physical Conditioning Programs

Physical conditioning, also called as work hardening or functional restoration programs are often recommended for workers disabled by low back pain [21]. The aim of the programs is to facilitate return to work, improve work status of workers performing modified duties, or enable achievement of a higher level of function by increasing strength, flexibility and cardiovascular fitness [21]. These programs involve simulation of work or functional tasks in a supervised environment such as a clinic or a gymnasium.

A systematic review [21] for evaluating physical conditioning as a treatment modality showed that the programs including cognitive behavioral approach and closely related to the workplace were able to reduce the number of sick days lost by workers with chronic low back pain. Also they found that specific exercises were less effective in reducing lost days than physical conditioning programs.



### 1.7.5 Manipulation and Mobilization

Manipulation and mobilization are passive joint movement procedures in which the operator takes a joint or joint complex through all or part of its range of motion (ROM) [22]. The aim of these techniques is to restore ROM and reduce LBP.

Mobilization involves repetitive low velocity passive movements usually within or at the limit of ROM. It enables effective synovial fluid distribution over and through the articular cartilage and disc and partial stretching of the ligamentous joint structures which in turn facilitate efficient functioning and repair of structures involved [22]. Mobilization is a gentle and passive procedure with effects similar to active exercise and without any overt disadvantages.

Manipulation involves small amplitude, high-velocity thrust at the limit of a patient's joint range so that the joint is briefly taken beyond the restricted ROM [22]. There is a considerable controversy in the field over the safety and efficacy of spinal manipulation as a treatment methodology. Some of the primary deterrents are a lack of uniform regimen, lack of description and repeatability of therapeutic techniques [22]. Adverse events such as increases in LBP and functional disorder have been recorded with lumbar spinal manipulation [22]. There have also been cases of herniated lumbar disc and complications involving poor and misdiagnosis of spinal osteoporosis, fracture, bony tumor and in some cases the etiology of the symptom itself [22].

### 1.7.6 Back Schools

Back schools are specialized centers of patient education and treatment of LBP. The first back school was opened in Sweden by Zachrisson-Forsell [23] in 1969. Back

schools typically consist of weekly group sessions of information on anatomy of back, biomechanics, optimal posture, ergonomics and back exercises. There is moderate evidence [23] that back schools conducted in occupational settings seem to be more effective for patients with recurrent and chronic LBP (as opposed to patients from the general population or primary / secondary care) for pain, functional status, and return to work during short and intermediate term follow up.

### 1.7.7 Acupuncture and Dry-Needling

Acupuncture is one of the oldest forms of therapy and has its roots in ancient Chinese philosophy. Manifestation of disease is considered a sign of imbalance between Yin and Yang forces within the body [24]. It is believed that all disorders are reflected at specific points, either on the skin surface or just below it. Vital energy circulates throughout the body along the so-called meridians, which have either Yin or Yang characteristics. An appropriate choice of 361 classic acupuncture points located on these meridians for needling is believed to restore the balance in the body. Successful placement of needles is supposed to cause a sensation of '*The Chi*', which is defined as a subjective feeling of fullness, numbness, tingling and warmth with some local soreness and a feeling of distension around the acupuncture points [24].

Acupuncture commonly includes manual stimulation of the needles. Various adjuncts such as electrical acupuncture (connection of electrical simulator to the needle), injection acupuncture (herbal extracts injected into acupuncture points), heat lamps and acupuncture with moxibustion (burning of moxa herb, *Artemisia vulgaris*) are also used [24].

Dry needling is a technique used to treat myofascial pain in any body part, including the low back region. Myofascial pain syndrome is a disease of muscle that produces local and referred pain [24]. It is characterized by a hard band within the muscle (motor abnormality) and by tenderness (sensory abnormality). If the myofascial trigger points [24] are identified, they can be inactivated by various methods such as systemic muscle relaxants, botulinum toxin, antidepressants, and deep muscle massage, local injections of steroids or lidocaine and dry needling.

Dry needling involves the insertion of a needle at the myofascial trigger points without the injection of any substance. The needles are removed once the trigger points are inactivated. The inactivation is usually followed by stretching exercises or ergonomic adjustments with the purpose of reestablishing a painless full range of motion and avoiding recurrences.

The mechanism of action of acupuncture and dry needling is unclear. It has been suggested that acupuncture might act by principles of the gate control theory of pain. One type of sensory input (low back pain) may be inhibited in the CNS by another type of input (needling). The DNIC (Diffuse Noxious Inhibitory Control) theory suggests that noxious stimulation of heterotopic body areas modulates the pain sensation originating in areas where a patient feels pain [24]. There is also some evidence that acupuncture may stimulate the production of endorphins, serotonin, and acetylcholine within the CNS, enhancing analgesia [24].

A systematic review of RCT's was conducted by Furlan, et al. 2005 to determine the effectiveness of acupuncture for sub acute and chronic nonspecific low back pain and dry needling for myofascial pain syndrome. They found some evidence of the effects of

acupuncture for chronic low back pain. There was evidence for pain relief, and functional improvement for acupuncture at shorter term follow-ups. These effects were however not maintained at longer term follow-ups. Acupuncture when conducted adjunct to other conventional therapies was found to relieve pain and improve function compared to conventional therapies (e.g. NSAIDs, exercises, heat packs, herbal medicines, etc.) alone. Dry needling was also found to be a useful adjunct to other therapies for chronic low back pain.

#### 1.7.8 Iyengar Yoga Therapy

‘Yoga’, derived from the Sanskrit word ‘Yog’ is one of the six schools of Indian Philosophy. It is defined as ‘*Chitta Vritti Nirodha*’ [25]. ‘*Chitta*’ is defined as the consciousness which includes the mind, the intellect and the ego. Thus, Yoga is defined as a method of silencing the vibrations of the ‘*chitta*’. Yoga involves both mental and physical disciplines. The physical discipline is known as ‘*Hatha Yoga*’ which involves ‘*aasanas*’ (postures) and different forms of exercises.

‘Iyengar Yoga’, created by yoga master B. K. S Iyengar is the most prevalent form of Hatha Yoga currently practiced [26] and is known for its use of props such as belts and blocks as aids in performing the ‘*aasanas*’ (postures). It is based on the traditional eight limbs of Yoga propounded in the thesis ‘*Patanjali Yog Sutras*’ (2<sup>nd</sup> Century BC) [25], emphasizing the development of strength, stamina, flexibility and balance as well as concentration (Dharana) and meditation (Dhyana). The Iyengar Yoga focuses on the structural alignment of the body through the development of *aasanas*. Through the practice of a system of *aasanas*, it aims to unite the body, mind and spirit for

health and well being. A number of therapeutic variations of these *aasanas* have been applied to healthcare problems including chronic low back pain [26].

Williams et al. 2009 [26] conducted a randomized control trial to assess the effectiveness and efficacy of a 24 week Iyengar yoga intervention for chronic LBP in comparison with standard medical care (SMC). Patients were assessed at 12 (midway) week, 24 week and 6 month time points and evaluated for functional disability (ODI), pain (VAS) and depression (Beck Depression Inventory (BDI)). The study concluded that yoga improved functional disability, pain intensity, and depression in adults with chronic low back pain. A clinically important trend of reduced pain medication post treatment was observed as compared to the control group. No adverse events were reported for any of the patients.

## **1.8 Surgical Treatment Modalities**

The theory of '*clinical Instability*' related to disc degeneration resulted in spinal fusion (arthrodesis) being the gold standard of surgical treatment for degenerative disc disease associated low back pain. The aim of spinal fusion is to impart pain relief by eliminating the movement of the painful motion segment. However, fusion techniques do not guarantee satisfactory results. Some of the complications associated with fusion are bone graft donor site pain, pseudoarthrosis, spinal stenosis, spondylolysis acquisita, failure of instrumentation, muscle atrophy and accelerated degeneration of adjacent segments [27-32].

Clinical studies indicate that fusion results in altered kinematics and clinical problems at the adjacent motion segments. Frymoyer et al., 1979 [33] reported

roentgenographic evaluation of accelerated degeneration at the free segment above the lumbosacral fusion. Hypertrophic degenerative arthritis of facet joints, spinal stenosis and severe disc degeneration are the major pathologic conditions observed at the level adjacent to fusion [34]. In an investigation of 58 patients, Schlegel et al [35] suggested that incorrect sagittal and coronal alignments caused degeneration at the adjacent level by inducing too much motion at that level.

Biomechanical studies have confirmed these clinical observations through a study of intradiscal pressure (as a measure of increased stress) and motion at the levels adjacent to fusion. It seems to appear that addition of instrumentation significantly affects the intradiscal pressure in the levels above fusion. Chow, *et al* 1996 [36] showed that neighboring unfused segments have to work more frequently toward the extremes of their functional ranges of motion after fusion and these effects are more marked after a double level L4-5-S1 fusion. Also, application of segmental instrumentation changes the motion pattern of the residual intact motion segments, and the changes in the motion pattern become more distinct as the fixation range becomes more extensive and the rigidity of the construct increases [37]. Tomoyuki Akamura., *et al*, 2003 [38] carried out a biomechanical study to investigate effect of fusion on adjacent motion segments in different sagittal alignments and showed that hypolordotic alignment of L4-L5 caused the greatest amount of flexion-extension motion at L3-L4 and the differences were statistically significant in comparison with intact specimen, *in situ* fixation and hyperlordotic fixation. A review of 271 articles found a 12-18% incidence of symptomatic adjacent segment degeneration in patients fused with posterior transpedicular instrumentation [39]. Also, a Cochrane Review of surgery for degenerative

lumbar spondylosis [40] reported a valid scientific evidence of correlation between fusion rates and instrumentation / internal fixation, these fusion rates however did not correlate well with patient outcome measures.

### **1.9 Paradigm Shift in the Continuum of Spine Care**

The potential drawbacks of spinal fusion have led to a change in the clinical perspective towards treatment methodologies for spinal disorders. This patient and clinical need along with the ongoing evolution in the understanding of normal and symptomatic spine biomechanics, biology and mechanobiology in conjunction with the advancements in material sciences, and tissue engineering has led to a paradigm shift in the continuum of spine care. A '*one size fits all*' philosophy i.e. spinal fusion for all patients with symptomatic low back pain is being modulated to a '*customized approach*' philosophy, i.e. patient and indication specific treatment modalities for spine care. This philosophy has laid the ground for concepts of '*motion preservation*' and '*dynamic stabilization*', the former being an established treatment modality in orthopedics for a long time.

#### **1.9.1 Lumbar Disc Arthroplasty**

Lumbar Disc Arthroplasty has been developed as an alternative to lumbar arthrodesis for the treatment of discogenic low back pain [41-44]. The potential benefits of disc arthroplasty over lumbar arthrodesis are removal of the primary pain generator while restoring spinal motion, allowing an early return to function and consequently avoiding long term adjacent level degeneration [41-44]. To achieve these benefits,

anterior disc arthroplasty systems have been developed and are being used for select indications. Newer designs with improvements in materials and motion characteristics are continuously being developed. However, anterior disc arthroplasty has its disadvantages, primarily due to risk of vascular injury, retrograde ejaculation or ureteral injury associated with the surgical approach. The incidence of vascular injury associated with primary anterior lumbar surgery has been reported at 1.9% to 8%, with the greatest risk at the L4-L5 level [45-46]. In the CHARITE IDE study, a 3.6% incidence of vascular injury was reported at the time of the index disc arthroplasty (level II incidence) [47]. The risk of retrograde ejaculation after anterior lumbar fusion procedures has been estimated to be 1.7% with a retroperitoneal approach and as high as 17.5% with a transperitoneal approach (level II evidence) [48-49]. In addition to the surgical morbidity, biomechanically, segmental instability may be induced with the partial or complete removal of the anterior annulus and anterior longitudinal ligament [50].

In addition to the surgical and biomechanical challenges, anterior disc arthroplasty is contraindicated for neural and facet pain caused by central or lateral recess stenosis, and facet arthrosis [51-53]. Herniated nucleus pulposus with radiculopathy may also be a contraindication depending on whether the discectomy is done till the posterior annulus or extended to the PLL [51, 54, 55]. In a retrospective review of 100 consecutive patients who underwent fusion and non-fusion lumbar surgery, Huang et al. reported that 95% of the patients were contraindicated for anterior disc arthroplasty [53]. 96% of the fusion group patients had lumbar stenosis, 66% had facet arthrosis and 20% had a herniated nucleus pulposus with radiculopathy. Also, 36% of the patients in the non-



fusion group had lumbar stenosis 27% had facet arthrosis while 55% had HNP with radiculopathy.

In the light of these observations in patients who seek treatment for low back pain, and are contraindicated for disc arthroplasty due to approach related deficiencies and contraindications, alternative approaches to disc arthroplasty are currently being explored and developed. The concept of Posterior or Posterolateral disc arthroplasty is currently gaining ground in the spine community [56]. The potential advantages of posterior disc arthroplasty are 1) 90% of the disorders require posterior intervention whereas only 5 to 10% disorders can be dealt with anteriorly [53], 2) Ease of access to the main pain generators such as the disc, facets and neural structure, 3) Approach related safety avoiding vascular structures, and 4) Easy access to neural decompression. These potential advantages of the posterior approach may enable patients with neural pain, to gain access to the advantages of disc arthroplasty. In spite of these advantages there are certain concerns which need to be studied and addressed prior to clinical application. A posterior approach to the disc poses risk to the neural elements [57-58]. Additionally, anatomical constraints and the extent of pathology may dictate the implant design and required decompression. Decompression due to a partial or total facetectomy in conjunction with a disc arthroplasty device as well as improper positioning of the device may increase segmental instability. Implant design on the other hand may affect the subsidence characteristics of the device.

### 1.9.2 Posterior Dynamic Stabilization for Discogenic LBP

The concept of clinical instability has been responsible for the justification of ‘spinal fusion’ as a treatment modality for low back pain [59]. However, the concept is controversial in its definition (except in spondylolisthesis) since instability is observed in clinically asymptomatic patients and symptomatic patients may not necessarily exhibit instability [59]. This is also evident from patient outcomes for fusion which do not guarantee a 100% pain relief, even though solid fusion might take place [59].

In recent years, discogenic low back pain has been attributed to both abnormal motion and loading of a degenerated disc. In terms of motion, it is hypothesized that spinal element injury or degeneration results in increase in the Neutral Zone (NZ) of the spine and theoretically causes pain [60-62]. Stabilizing the passive elements of the spine around the NZ may help to reduce the pain associated with the increased NZ [63]. In terms of loading it is hypothesized that the postural nature of low back pain implicates abnormal loading pattern rather than motion as the primary source of pain [59]. Disc degeneration alters the isotropic properties of the disc resulting in a non - homogenous nature of fragmented and condensed collagen, fluid and gas. This anisotropic nature of the degenerated disc may cause uneven loading pattern across the endplates resulting in pain. Subsequently, the loss of disc height may reduce the tension in the annulus leading to infolding and fractures of the annular structures. These changes result in a ‘stone-in-the-shoe’ phenomenon resulting in pain [59].

Dynamic Stabilization of the lumbar spine may be defined as a system that would alter favorably the *motion and load transmission* of a spinal motion segment without the intention of fusion of the segment. The clinical hypothesis is that control of abnormal

motions and more physiologic load transmission would relieve pain at the index segment and prevent adjacent segment degeneration. The theory of dynamic stabilization is based on this hypothesis that if load transmission across the symptomatic degenerated disc were to be modulated it may facilitate pain relief without the elimination of motion. The aim of dynamic stabilization devices therefore is to theoretically create a focal increase in lordosis which may allow the shift of load transmission so that certain positions are more tolerable and limit motion so that painful positions are not experienced [59]. The decrease in overall range of motion may be able to control the increase in Neutral Zone which theoretically causes pain. Dynamic stabilization is typically achieved through a posterior approach and involves placement of a flexible device between pedicle screws. The theoretical advantages of dynamic stabilization are that it may be able to negate the deleterious effects of fusion on the adjacent levels and an overall sagittal balance. Also, patients with spinal stenosis and facet arthropathy who are contraindicated for a disc arthroplasty may be treated with dynamic stabilization [59].

Also, though total disc replacement is an alternative to lumbar fusion for treatment of discogenic low back pain, patients with spinal stenosis and facet arthropathy are often excluded from this procedure because degenerative effects of the posterior column can lead to abnormal kinematics of the artificial disc implanted motion segment [64]. In such cases, decompression and fusion is still the gold standard of treatment, in spite of the variability in clinical outcomes [65], and a potential for adjacent level degeneration in the future [66-68]. It is hypothesized that '*motion stabilization*' and '*load sharing*' at the diseased level would help to alleviate pain at the index level and simultaneously relay less stress at the adjacent levels compared to rigid fixation and

fusion. This may potentially reduce the incidence of adjacent level breakdown and future surgical procedures [66-68].

### 1.9.3 Posterior Dynamic Stabilization for Transitional Stabilization

In addition to its proposed application for alleviation of abnormal loads and motion for discogenic back pain, dynamic stabilization has been proposed for the application of the same concept to reduce the complications associated with multilevel fusion constructs with rigid fixation. Multilevel fusion constructs have been shown to be correlated to higher incidences of up to 11% [69-75] of screw breakage and loosening. It has also been correlated to higher incidences of adjacent level degeneration (12-18%) [76] and consequently revision surgeries.

It has been proposed that surgical treatment be customized to the varying grades of symptomatic degeneration and instability especially in multilevel fusion constructs. This may be achieved by using rigid transpedicular fixation at the most unstable segments and dynamic stabilization at the mildly degenerated or symptomatic level. This may also facilitate a prophylactic measure towards preventing adjacent segment breakdown by allowing load sharing and preventing any abnormal motion and stress distribution.

### 1.9.4 Posterior Dynamic Stabilization for Posterior Tethering

Posterior dynamic stabilization has been also been proposed to be used as a posterior tether adjunct to a disc arthroplasty (DA) system. The two possible clinical

scenarios would be: 1) revision of a disc arthroplasty or 2) Posterior tethering of an anterior or posterolateral disc arthroplasty system [64].

Revision surgery of a DA may be required in the event of symptomatic facet arthropathy or any other posterior column degeneration developed after a number of years [59, 77]. It may also be required in a situation where the DA device is placed eccentrically and/or is undersized creating a functional unit imbalance. In the case of a multilevel anterior DA, resection of the ALL and anterior annulus may cause increased instability potentially leading to a segmental scoliosis [59, 77]. In the event of such clinical scenarios, the surgeon may elect to use a PDS adjunct to the DA instead of fusion.

In the case of a posterolateral disc arthroplasty, surgery may involve unilateral / bilateral, partial or total facetectomy depending on the amount of decompression required and implant design. Partial or total resection of the facet joint may lead to increased ROM in axial rotation. Previous studies have shown an increase in the ROM of stand alone PLIF devices [78]. In such a situation, it has been proposed that a posterior dynamic stabilization system be used adjunct to the PLDA as an index procedure.

Based on the aforementioned clinical needs of implementing indication specific treatment modalities involving the concept of Posterolateral Disc Arthroplasty and Posterior Dynamic Stabilization for the treatment of spinal disorders, it is imperative that a comprehensive scientific investigation be performed to establish the relevant biomechanics of the surgically treated spine. To this end, the four specific aims of the study were established and executed through the measurement of implanted and adjacent level kinematics and loading patterns in the lumbosacral spine.

The cause and best treatment option for mechanical low back pain due to disc degeneration remains unsolved, despite '*spinal fusion*' being the gold standard of surgical treatment for a very long time. However, the potential drawbacks of spinal fusion and the ongoing evolution in the understanding of normal and symptomatic spine biomechanics, biology and mechanobiology in conjunction with the advancements in material sciences, and tissue engineering has led to a change in the clinical perspective towards treatment methodologies for spinal disorders. Clinically, a gradual shift is being observed from a '*one size fits all*', i.e. spinal fusion for all patients with symptomatic low back pain to a '*customized approach*', i.e. patient and indication specific treatment modalities for spine care. This philosophy has laid the ground for concepts of '*motion preservation*' and '*dynamic stabilization*', the former being an established treatment modality in orthopedics for a long time. The aim of the current study is to perform a comprehensive scientific investigation to understand, evaluate and establish the *in vitro* biomechanical characteristics and performance of indication specific treatment modalities incorporating the concept of Posterolateral Disc Arthroplasty and Posterior Dynamic Stabilization for the treatment of symptomatic mechanical back pain. The results of this comprehensive study may help the clinicians make an informed decision while selecting and designing a treating modality for their patients. To this end, the current study was designed to fulfill 4 specific aims:

1. Biomechanical characterization of Posterolateral Disc Arthroplasty in the human lumbosacral spine
2. Biomechanical characterization of Posterior Dynamic Stabilization in the human lumbosacral spine

3. Biomechanical characterization of Posterior Dynamic Stabilization adjacent to rigid fixation in the human lumbosacral spine
4. Biomechanical characterization of Posterolateral Disc Arthroplasty in conjunction with posterior tethering in the human lumbosacral spine

## CHAPTER 2

### MATERIALS AND METHODS

Research methods for this study involved *in vitro* biomechanical investigation using established methods of human cadaveric spine testing [79].

#### 2.1 Specimen Preparation

Human lumbosacral spines were used for this study. All spines were radiographed to ensure the absence of fractures, deformities and any metastatic disease. The spines were stripped of paravertebral musculature while preserving the spinal ligaments, joints and disk spaces. Subsequently, they were mounted at L1 rostrally and S1 caudally in a three-to-one mixture of Bond Auto Body Filler and fiberglass resin [Bondo MarHyde Corp, Atlanta, GA]. Specimens were then stored in double plastic bags at -20°C. Prior to testing, the specimens were removed from the freezer and allowed to thaw at room temperature for 8 hours. At the time of testing, the spine was affixed to a six degree-of-freedom (6-DOF) spine simulator. Specimens were wrapped in saline-soaked (0.9% NaCl) gauze to prevent dehydration during testing. All tests were carried out at room temperature of 25°C.

#### 2.2. Multidirectional Flexibility Testing

Pure unconstrained bending moments were applied in the physiologic planes of the spine at room temperature using a multidirectional hybrid (displacement control) flexibility protocol [80]. The hybrid protocol involves a two step approach. Pure bending



moments were applied to the intact spine and Range of Motion (ROM) recorded at each level as well as for the whole spine. The next step involves subsequent application of the whole spine ROM to the surgically reconstructed spine which is a real life simulation of the patient maintaining his/her full ROM during activities of daily living. The advantage of this hybrid protocol is that it helps evaluate the effect of surgical reconstruction at one spinal level on the non reconstructed levels of the spine. Figure 5 depicts a graphical representation of the hybrid protocol.




Figure 5. Graphical Representation of the Hybrid Flexibility Protocol

## 2.3 Test Apparatus

### 2.3.1 Six Degree of Freedom (DOF) Spine

#### Motion Simulator

Spinal loading and motion was facilitated through a customized 6 DOF spine motion simulator. The spine simulator [81-85] incorporated three cephalad servo motors which apply motion around each of the three physiological rotation axes. Moreover, the supports and motor arms were mounted on air bearings to provide near frictionless

resistance to the natural kinematics of the spine. At a given time, only one motor channel and clutch was activated which applied rotational motion to the spine in a given plane; while the remaining two motor channels and clutches were free. This along with the frictionless slides in the three planes enabled the spine to have unconstrained rotations and translations in all other planes except the plane of active motion. This enabled near physiologic simulation of spinal motion as coupled motions could take place guided by anatomical constraints. The moment loads were recorded in the form of reaction moments by a six axis load cell fixed in the central hub of the machine and attached to the superior spinal level.




Figure 6. Customized 6 DOF Spine Motion Simulator

### 2.3.2 Motion Detection

Intervertebral motion was tracked using the Optotrak Certus [NDI, Inc. Waterloo, Canada] motion analysis system. Plexiglas markers [Fig.6], each having three infrared light-emitting diodes were secured rigidly to each vertebral body via bone screws. The

location of the markers (denoting a rigid body) was approximately aligned sagittally along the curvature of the spine. The Optotrak Certus software calibrated the marker positions in the global coordinate system while superimposing the local coordinate systems of two adjacent vertebral bodies in order to inferentially determine the relative Eulerian rotations in each of the three planes. Load displacement curves were plotted for each of the planes [Fig.7].

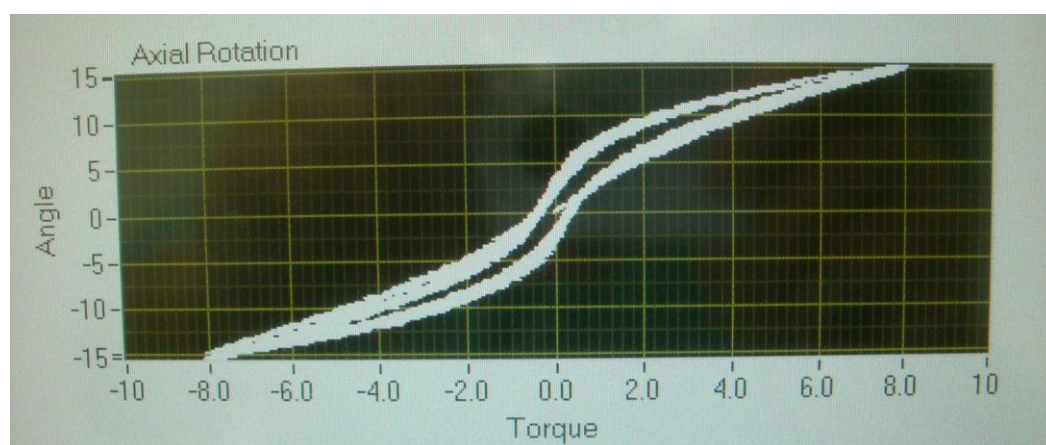


Figure 7. Representative Load Displacement Curve (Kinematic Signature)

### 2.3.3 Intradiscal Pressure Measurement

Intradiscal pressure was measured using miniature pressure transducers (width=1.5mm; height=0.3mm, Precision Measurement Co., Ann Arbor, MI) inserted at the adjacent levels, in the posterior half of the disc space, confirmed by sagittal radiographs [86-87]. A Jamshidi needle was used to create a defect in the intervertebral disc. The pressure transducer was then carefully inserted into the disc space under fluoroscopy, with the final position being maintained slightly posterior to the center of the disc space. The defect was then filled with a cotton gauge to prevent backing out of the

transducer and isolating the interiors of the disc from the atmosphere. The transducers were configured using C-DAQ [National Instruments, Austin, TX] data acquisition module. The intradiscal pressure was recorded continuously, and any discrepancy such as a negative pressure due to the positional correlation of pressure transducer position and spinal lordosis was solved by adjusting the transducer position

## 2.4. Study Design

### 2.4.1 Test Protocol

The following test protocols were followed for each of the specific aims. Specific aims 2 and 4 were subdivided into 2A, 2B and 4A, 4B respectively for analysis purpose. The following acronyms have been used to denote the test constructs: **PLDA**: Posterolateral Disc Arthroplasty [TRIUMPH™, Globus Medical, Audubon, PA]; **PDS**: Posterior Dynamic Stabilization [TRANSITION®, Globus Medical, Audubon, PA] **UPDS**: Unilateral Posterior Dynamic Stabilization; **BPDS**: Bilateral Posterior Dynamic Stabilization; **BF**: Bilateral Facetectomy; **UF**: Unilateral facetectomy; **S**: Spacer; **R**: Rigid rods

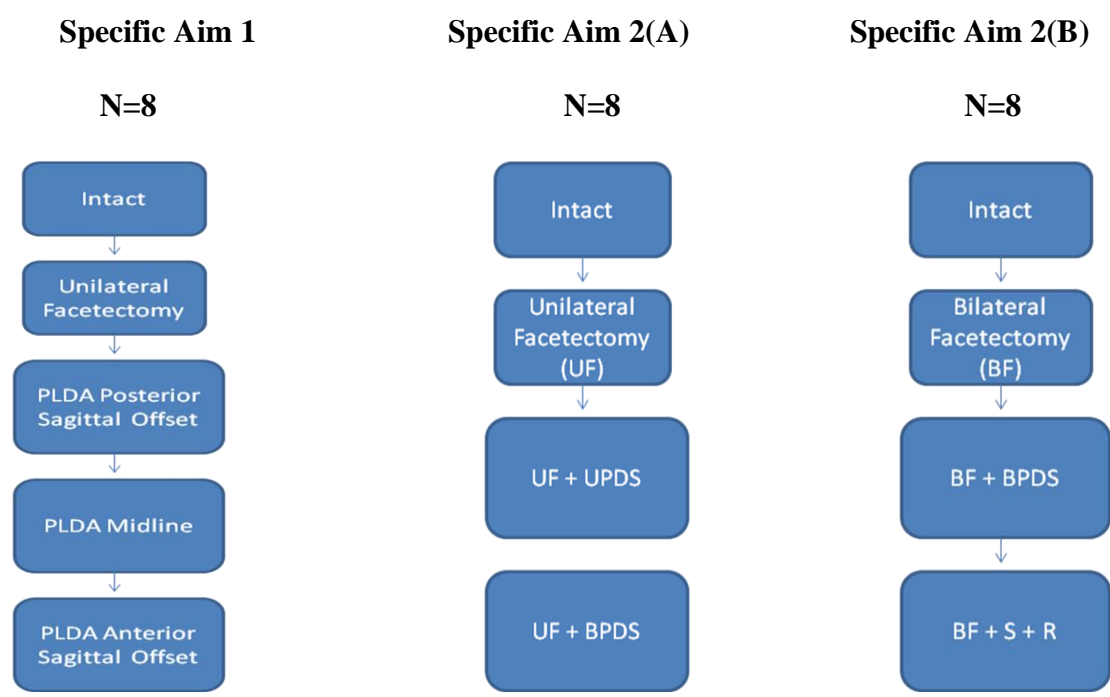


Figure 8. Protocols for Specific Aims 1 and 2. Specific Aim 2 was subdivided into 2A and 2B

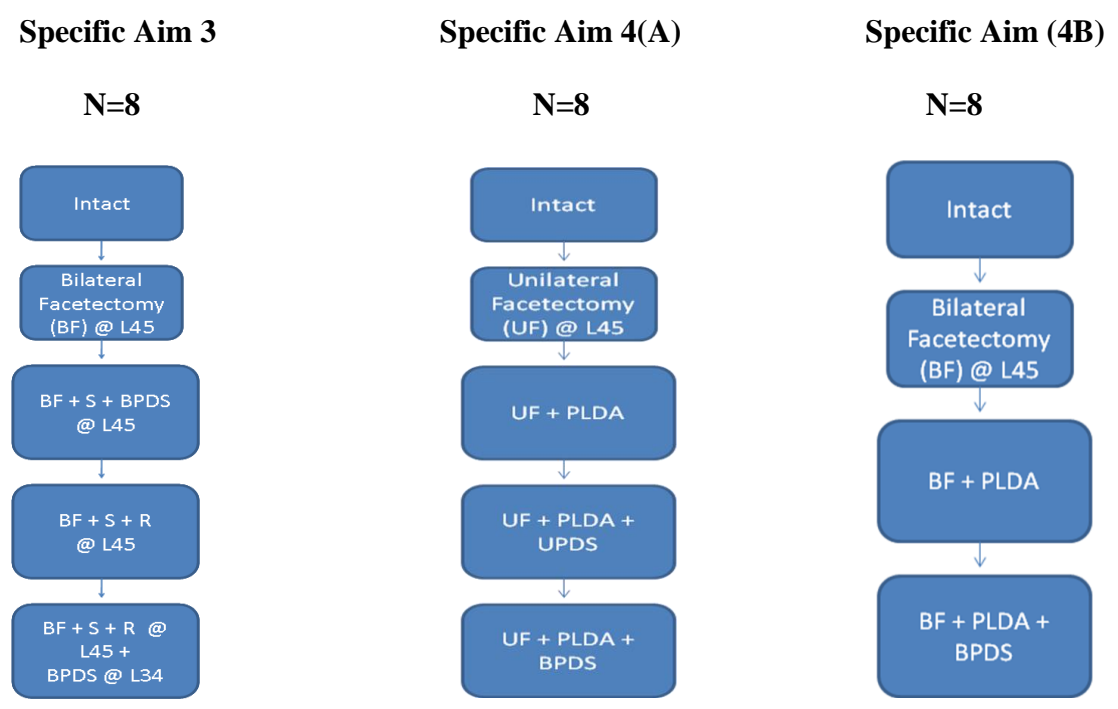


Figure 9. Protocols for Specific Aims 3 and 4. Specific Aim 4 was subdivided into 2A and 2B

### 2.4.2 Data Analysis

A series of three load/unload cycles were performed for each motion and each surgical construct with data analysis based on the final cycle. Each of the constructs was visually examined after testing to confirm absence of any signs of damage, loosening or breakage. ROM, NZ and intradiscal pressure data has been reported as mean  $\pm$  standard deviation. Single Factor Repeated measures ANOVA was used for statistical analysis. Comparisons were made with a probability of type I error,  $\alpha = 0.05$ , using Tukey's *post hoc* comparison for equal sample size. Intradiscal pressure (IDP) profiles were normalized according to the neutral zone 'base pressure' such that only changes between the base pressure and the pressure at maximum displacement were recorded. When percentage change is discussed, unless otherwise stated, the percentages are calculated through differences in normalized ROM of surgical groups, when normalized to the intact spine motion (100%).

### 2.4.3 Coupled Motion Complex

The spinal motion segment is a 3 joint complex with 6 degrees of freedom, 3 rotations and 3 translations as it moves in the sagittal, coronal and transverse planes [88]. As such, the spinal motion is never isolated and is coupled in nature [88].

As newer treatment modalities such as Disc Arthroplasty and Dynamic Stabilization are developed, standard quantitative methods of analysis such as rotational ROM and NZ may be necessary but not sufficient to study the effect of these systems on the spine, e.g. removal of a facet joint for decompression and implantation of a posterior disc arthroplasty may not show a significant change in the flexion-extension ROM of the

spine, however it may significantly affect the antero-posterior translation. Similarly, dynamic spinal stabilization may not stabilize the spine significantly in the transverse plane but may be able to significantly control the coronal-transverse coupled motion complex, which is predominantly seen in the lumbar spine [88]. In the light of this background it is imperative that in addition to the standard quantitative analysis additional qualitative motion analysis be performed studying and comparing the complex motion of the spine to the surgically treated spine.

A study of coupled motions involving rotational motions and intervertebral translations may be able to define the quality of motion better and needs to be studied for such applications. Till date there have been no studies documenting the effect of coupled motions in the lumbar spine post PLDA or PDS implantation. The coupled motion study will involve analysis of the coronal-transverse [Fig. 1] and coronal-sagittal coupled motion complex. Sagittal plane rotation-translation [Fig. 2] coupled motion complex will also be analyzed.

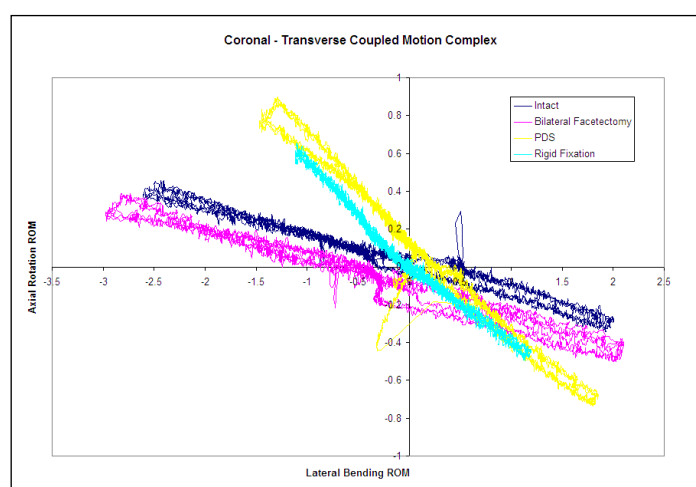


Figure 10. Representation of Comparative Coronal – Transverse Coupled Motion Complex

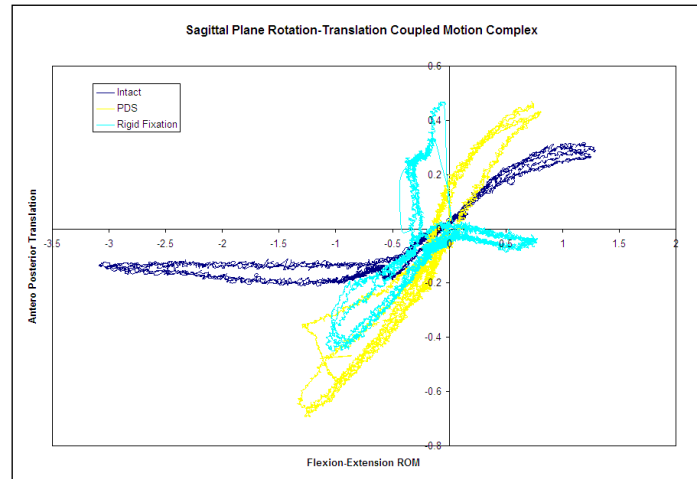


Figure 11. Representation of Comparative Sagittal Rotation-Translation Coupled Motion Complex

Statistical analysis will be performed on the coupled motion at maximum moment. Regression analysis of the comparative coupled motion curves will also be explored.

#### 2.4.4 Effect of Surgical Intervention on Mechanical Effort

Motion sparing treatment modalities like dynamic stabilization and disc arthroplasty make it imperative to determine the moment load required to achieve a given amount of motion. From a clinical perspective, an analysis of comparative moment loads will help to understand the percentage change in effort required by the spinal musculature as the patient moves during his/her activities of daily living.

Statistical analysis will be performed on the moment loads at maximum ROM. Regression of kinematic signature curves will also be explored.



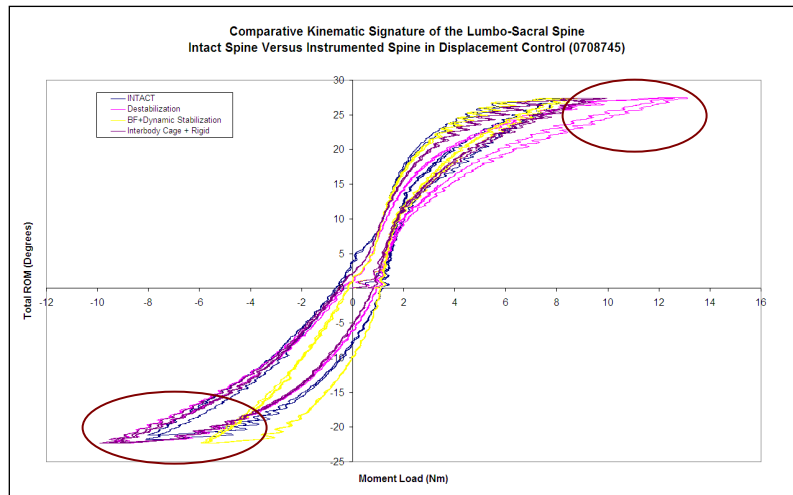


Figure 12. Representation of Comparative Kinematic Signature of the Lumbo-Sacral Spine

#### 2.4.5 Instantaneous Center of Rotation (ICR)

Center of rotation of each motion segment is not fixed and is continuously changing as the spine moves in 3-D space. The knowledge of the location of the ICR can be relevant for clinicians to diagnose mechanical instabilities of the spine [89]. Clinically, overlaying of flexion-extension radiographs to determine the Range of Motion has been considered as a quantitative measure of spinal motion. However, spine motion in 3D space has rotational as well as translatory components. In this light determining the ICR has been considered as a qualitative measure of spinal motion [90]. A number of techniques have been developed to determine the position of the ICR and attempts have been made to apply them in the clinical setting for diagnostic and treatment purposes, as well as for the design of spinal implants and instrumentation [91]. Standard methods of analysis involve the perpendicular bisector method [88]. This is achieved by overlaying



endplate in the posterior half of the L5 vertebral body. Haher et al. 1991 [93] conducted a cadaveric study to determine the effect of loss of the three columns on the location of the instantaneous axis of rotation (IAR). They found that anterior column destruction of the involved level moved the IAR more inferior and posterior under compressive loads. This tendency was enhanced with combined anterior and middle column destruction with a flexion moment. Conversely, destruction of the posterior column led to an anterior and inferior migration of the IAR under compressive loads, and the tendency was enhanced with combined posterior and middle column destruction with an extension moment. The authors concluded that understanding the location of the IAR in various injury patterns could help the clinician determine the type of instrumentation to be used in order to restore the IAR to its anatomical location to achieve stability, e.g. anterior instrumentation would be used in the event of anterior column destruction and posterior instrumentation in the event of posterior column destruction so as to facilitate the mechanical advantage required to restore stability. Advanced methods such as cineradiography have also been used to document the continuous change in the ICR of the lumbar spine. In a clinical study of 10 asymptomatic patients Harada et al. 2000 [94] found that initial motion during lumbar spine flexion started from the upper segments to the lower segments with phase lags. Also, initial motion in extension was found to have started from the lower motion segments to the upper.

Similar studies have been conducted in the cervical spine. Lee et al. 1997 [95] established the ICR of the skull relative to the thorax to determine spinal instability in the cervical spine. The aim of the method was also to reduce the errors associated with ICR location calculated by using the cervical spine motion alone, which is smaller compared

to the skull-thorax relative motion. In this study of 27 healthy subjects, 28 patients with chronic cervical spondylosis and 17 patients undergoing fusion for disc degeneration, they found that the horizontal component of the ICR in the preoperative group shifted anteriorly from 5° to 25° of flexion and 5° of extension compared to the healthy subjects. They also found a significant difference in the vertical component of the ICR at 15° of flexion but no significant differences in the horizontal and vertical components between the normal and preoperative groups.

The location of ICR has also been used to determine the kinematic alteration in the spondylolytic pediatric lumbar spine with pars defects. Sakamaki et al. 2001 [96] found that the ICR in the spondylolytic pediatric spine deviated cranially as the stage of the pars defects advanced, and as the wedge deformity increased. They concluded that this kinematic alteration may potentially affect chondrocytes of the endplate contributing to the consequent spine deformities occurring secondarily to spondylolysis.

Most of the techniques used thus far have involved the use of radiographic images which are two dimensional inspite of the 3 dimensional nature of spinal motion. Though advantageous, the radiographic techniques also run the risk of excessive radiation exposure to the patient, especially those involving continuous motion. In the light of this background, this thesis will explore mathematical methods for joint center calculation which take into account the 3 dimensional positions and orientations of the rigid body markers. Also, ICR analysis using marker positions and orientations has not been conducted post dynamic stabilization and posterior disc arthroplasty implantation.

Motion sensors typically provide with their positions and orientations at a given

instant in real time. If 2 rigid bodies, one proximal segment and another distal segment are considered [Fig. 5] the transformation matrix from the proximal segment reference frame to the distal

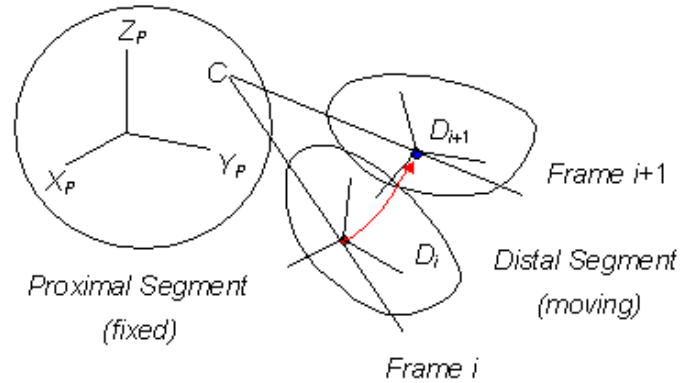


Figure 14. Joint motion representation from frame i to i+1 [10]

segment reference frame can be obtained as follows [10]:

$$\begin{aligned} \mathbf{T}_{D_i/P_i} &= \mathbf{T}_{D_i/G} \cdot \mathbf{T}_{P_i/G}^t \\ \mathbf{T}_{D_{i+1}/P_{i+1}} &= \mathbf{T}_{D_{i+1}/G} \cdot \mathbf{T}_{P_{i+1}/G}^t \end{aligned}$$

where,  $\mathbf{T}_{A/B}$  = the rotational transformation matrix from frame B to frame A and  $\mathbf{T}_{A/G}$  is the transformation matrix from the global reference frame to frame A.

For a multi DOF joint formed by two segments, if vector  $\mathbf{r}_{P_i}$  and  $\mathbf{r}_{D_i}$  are the positions of the sensors on the proximal and the distal segments respectively in frame i, the relative positions of the distal segment to the proximal can be described as [10]:

$$\begin{aligned} \mathbf{r}_{D_i/P_i} &= \mathbf{r}_{D_i} - \mathbf{r}_{P_i} \\ \mathbf{r}_{D_{i+1}/P_{i+1}} &= \mathbf{r}_{D_{i+1}} - \mathbf{r}_{P_{i+1}} \\ &\vdots \end{aligned}$$

where  $r_{D/P_i}$  = the relative position of the distal segment to the proximal in frame i. The relative positions observed in the proximal body reference frame become [10]

$$\begin{aligned} r_{D/P_i}^{(P_i)} &= T_{P_i/G} \cdot (r_{D_i} - r_{P_i}) \\ r_{D/P_{i+1}}^{(P_{i+1})} &= T_{P_{i+1}/G} \cdot (r_{D_{i+1}} - r_{P_{i+1}}) \end{aligned}$$

Where  $r^{(A)}$  = the position vector described in the reference frame A.

The relative positions of the distal to the proximal segment in frame i and i+1 suffice the relationship [10]:

$$\begin{aligned} \left[ r_{D/P_{i+1}}^{(P_{i+1})} - r_c \right] &= R_{D/P}^{i \rightarrow i+1} \cdot \left[ r_{D/P_i}^{(P_i)} - r_c \right] \\ \left( 1 - R_{D/P}^{i \rightarrow i+1} \right) \cdot r_c &= r_{D/P_{i+1}}^{(P_{i+1})} - R_{D/P}^{i \rightarrow i+1} \cdot r_{D/P_i}^{(P_i)} \\ P_i \cdot r_c &= Q_i \end{aligned}$$

Where  $r_c$  = the position of the joint center observed in the proximal reference frame, and

$$\begin{aligned} P_i &= \begin{bmatrix} \rho_{xx_i} & \rho_{xy_i} & \rho_{xz_i} \\ \rho_{yx_i} & \rho_{yy_i} & \rho_{yz_i} \\ \rho_{zx_i} & \rho_{zy_i} & \rho_{zz_i} \end{bmatrix} = 1 - R_{D/P}^{i \rightarrow i+1} \\ Q_i &= \begin{bmatrix} q_{x_i} \\ q_{y_i} \\ q_{z_i} \end{bmatrix} = r_{D/P_{i+1}}^{(P_{i+1})} - R_{D/P}^{i \rightarrow i+1} \cdot r_{D/P_i}^{(P_i)} \end{aligned}$$

once  $r_c$  is known, the global position of the joint center in each frame can be computed [10]:

$$R_{G_i} = r_{P_i} + T_{P_i/G}^t \cdot r_c$$

Where  $R_{G_i}$  = the global position of the joint center in the frame i.

## CHAPTER 3

### RESULTS

#### 3.1 Biomechanical Characterization of Posterolateral

##### Disc Arthroplasty

The first specific aim involved biomechanical evaluation of a Posterolateral Disc Arthroplasty (PLDA) system. The PLDA device was implanted by doing a unilateral decompression/injury model involving a facetectomy. The important aspects studied were:

- Effects of the surgical approach on the native spine kinematics
- Implanted (L4-L5) and adjacent segment (L3-L4, L5-S1) kinematics post PLDA implantation
- Effect of implant positioning on segmental kinematics

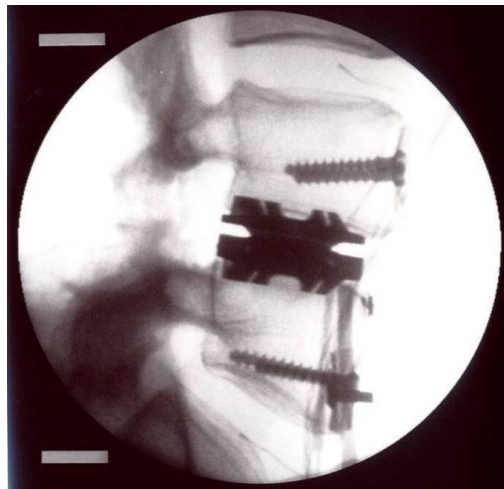


Figure 15. Radiograph of a PLDA system implanted post Unilateral Facetectomy

### 3.1.1 Flexion-Extension Kinematics

Comparative ROM values for different surgical constructs in flexion are as shown in and Figure 16. In flexion, unilateral facetectomy maintained implanted (L4-L5), superior (L3-L4) and inferior (L5-S1) adjacent level ROM at 100%, 93% and 101% of intact respectively. Midline placement of the PLDA device reduced the implanted level ROM to 95%. The superior adjacent level ROM was reduced to 91% and the inferior adjacent level ROM increased to 101%. In flexion, posterior sagittal offset of the PLDA device reduced the implanted and superior adjacent level ROM to 93% and 95% respectively. The inferior adjacent level ROM increased to 105% compared to intact. Anterior sagittal offset of the PLDA device reduced flexion ROM to 88% of intact but it was not statistically significant. The ROM at the superior and inferior adjacent levels was 93% and 105% of intact respectively.

Comparative NZ [Fig. 17] analysis in flexion showed an increasing trend after implantation of the device (Unilateral Facetectomy, 102 < Posterior, 127% < Center, 140%) compared to intact, the differences were however not statistically significant.

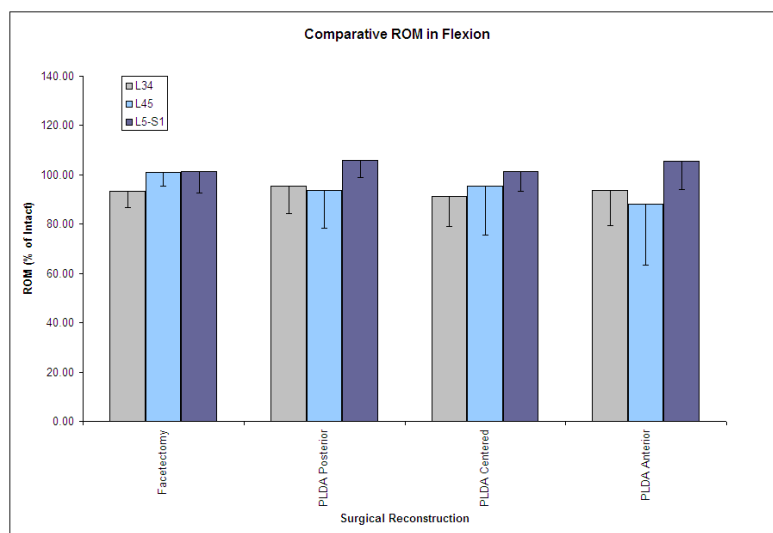


Figure 16. Comparative Flexion ROM post surgical intervention (% of intact)



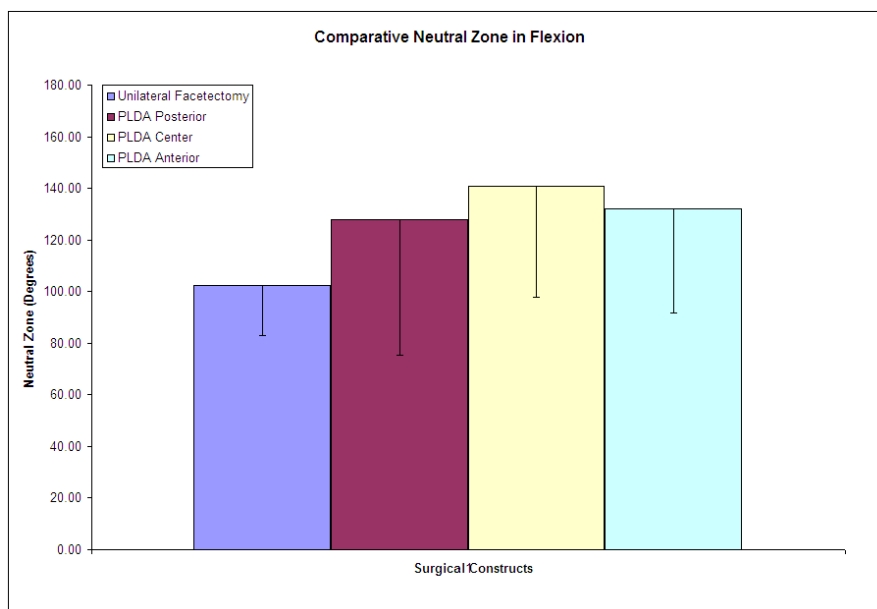


Figure 17. Comparative Flexion NZ post surgical intervention (% of intact)

In extension [Fig.18], unilateral facetectomy showed a slight increase in ROM to 110% and 108% at the implanted (L4-L5) and superior adjacent (L3-L4) levels respectively but it was not statistically significant. The inferior adjacent level L5-S1 was maintained at 101% of the intact. Midline placement of the PLDA device increased ROM in extension to 106%, 106% and 110% respectively at the implanted, superior and inferior adjacent levels. There was no statistically significant difference observed in extension ROM at any level post PLDA midline implantation when compared to intact. Posterior sagittal offset increased ROM to 112%, 103% at the implanted and superior adjacent levels. The ROM at the inferior adjacent level reduced to 93% of intact. In spite of the variations observed in the results there was no observable trend and any statistical significant difference when compared to intact. Anterior sagittal offset increased ROM to 105%, 110% and 108% at the implanted, superior and inferior adjacent levels respectively.

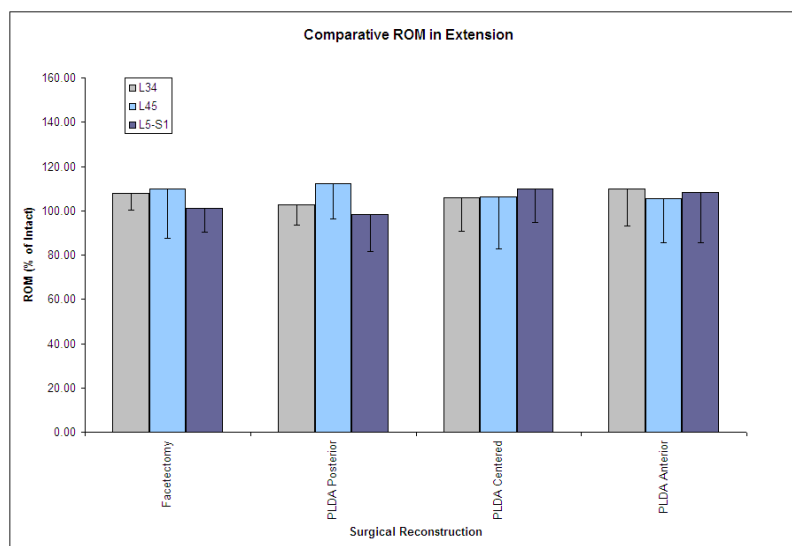


Figure 18. Comparative Extension ROM post surgical intervention (% of Intact)

Comparative NZ [Fig.19] analysis in extension showed an increasing trend after implantation of the device (Unilateral Facetectomy, 101 < Posterior, 121% < Center, 121% < Anterior, 124%) compared to intact, the differences were however not statistically significant.

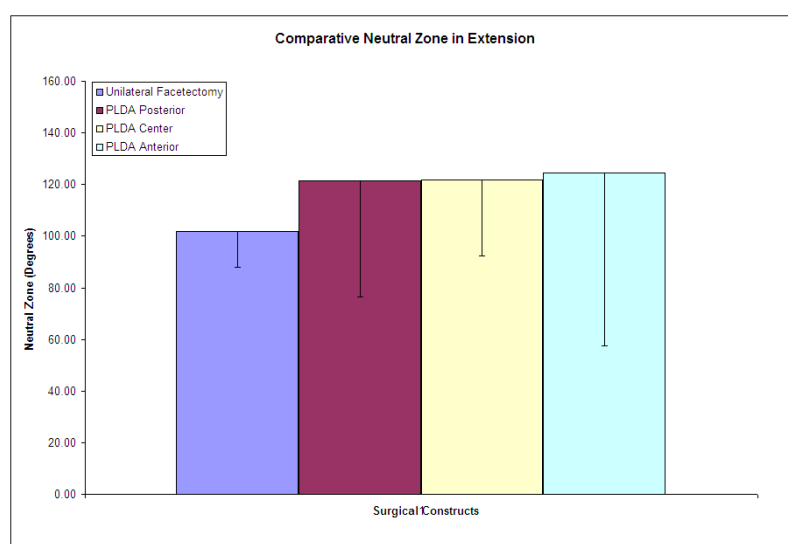


Figure 19. Comparative Extension NZ post surgical intervention (% of Intact)

### 3.1.2 Lateral Bending Kinematics

Comparative ROM values for different surgical constructs in lateral bending are as shown in Fig.20. Unilateral facetectomy did not show any change in ROM at both the implanted and adjacent levels. Midline placement and posterior and anterior sagittal offset placement of the PLDA device increased the implanted level ROM to 120%, 118% and 115% respectively. The increase was statistically significant. There was a corresponding drop in superior adjacent level ROM for all 3 placement positions to 93%. Inferior adjacent level L5-S1 ROM was maintained at 98% for midline and posterior sagittal offset and 101% for anterior sagittal offset respectively.

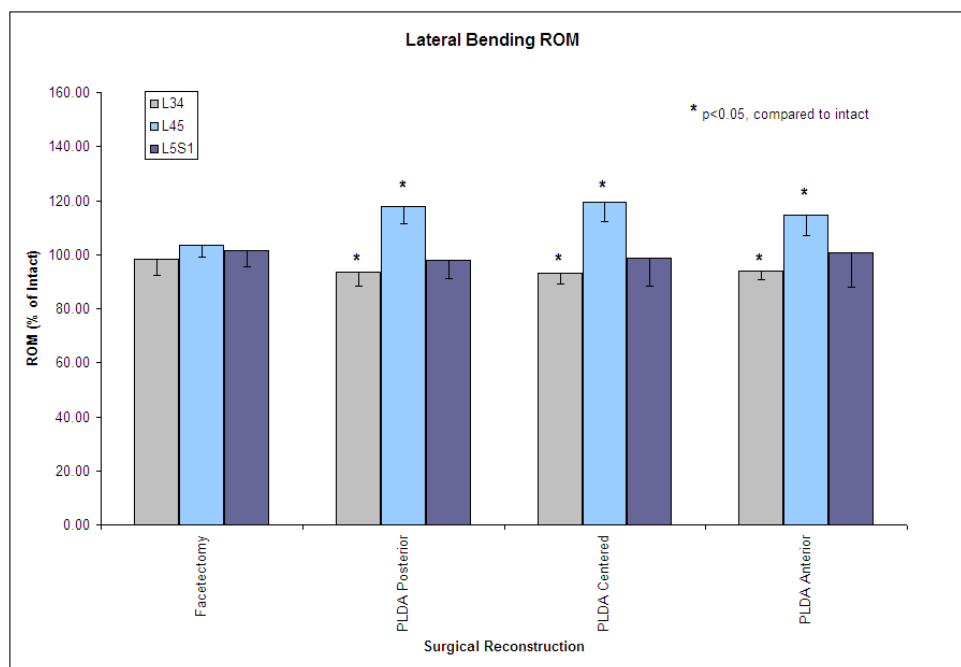


Figure 20. Comparative Lateral Bending ROM post surgical intervention (% of Intact)

Comparative NZ [Fig.21] analysis in lateral bending showed an increasing trend post surgical intervention (Unilateral Facetectomy, 106 < Posterior, 110% < Center,

112% < Anterior, 116%) compared to intact, the differences were however not statistically significant.

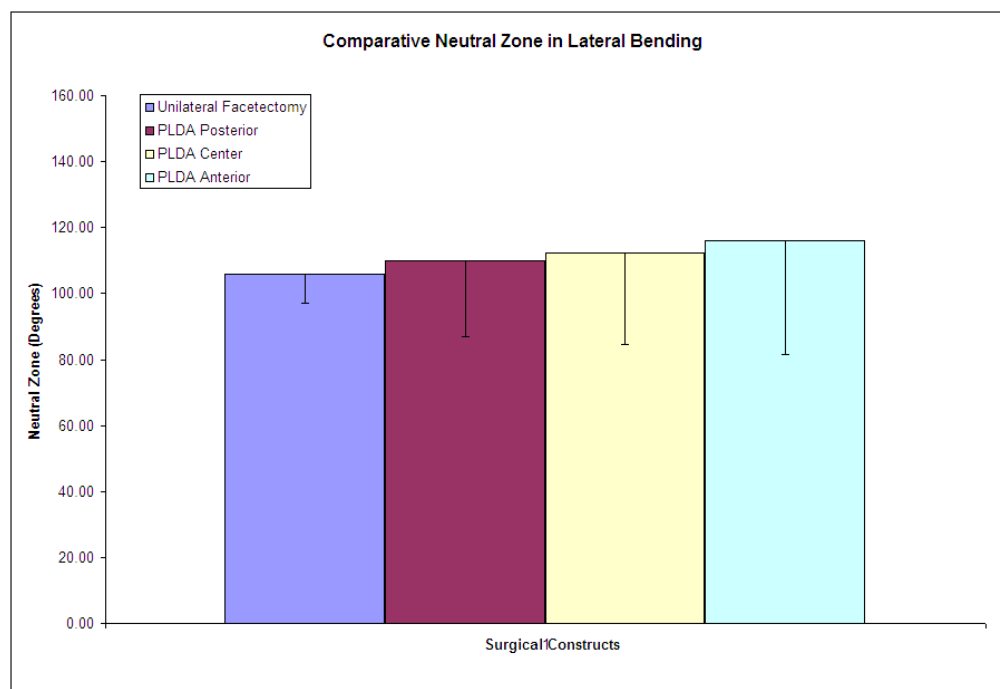


Figure 21. Comparative Lateral Bending NZ post surgical intervention (% of intact)

### 3.1.3 Axial Rotation Kinematics

Comparative ROM values for different surgical constructs are as shown in Figure 22. All surgical constructs showed a statistically significant increase in ROM at the implanted level (Unilateral facetectomy 123%; Posterior offset 130%; Midline 125% and Anterior offset 123%). Superior adjacent level correspondingly showed a statistically significant drop in ROM (Unilateral facetectomy and Midline 92%; Posterior offset 91%; and Anterior offset 93%). Inferior adjacent level showed a slight drop in ROM (96% for Unilateral Facetectomy, Posterior offset and Midline and 99% for Anterior offset)

Comparative NZ [Fig.23] analysis in axial rotation showed an increasing trend post surgical intervention (Unilateral Facetectomy, 106 < Midline, 116 < Posterior, 119% < Anterior, 122%) compared to intact, the differences were however not statistically significant.

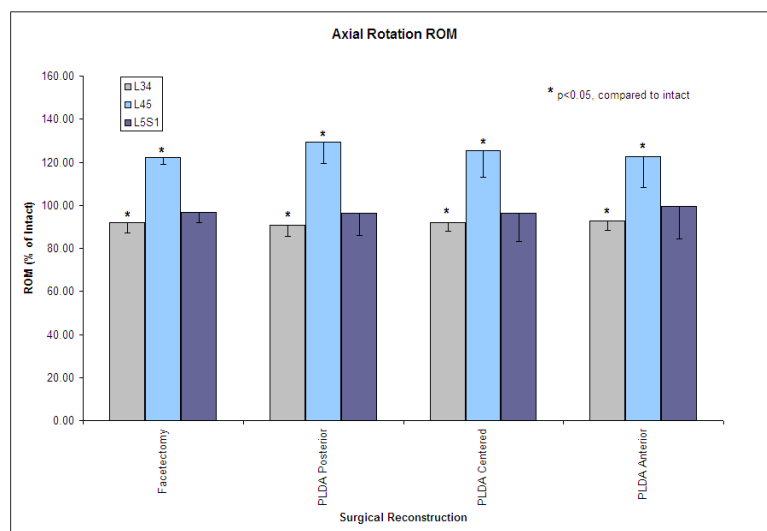


Figure 22. Comparative Axial Rotation ROM post surgical intervention (% of Intact)

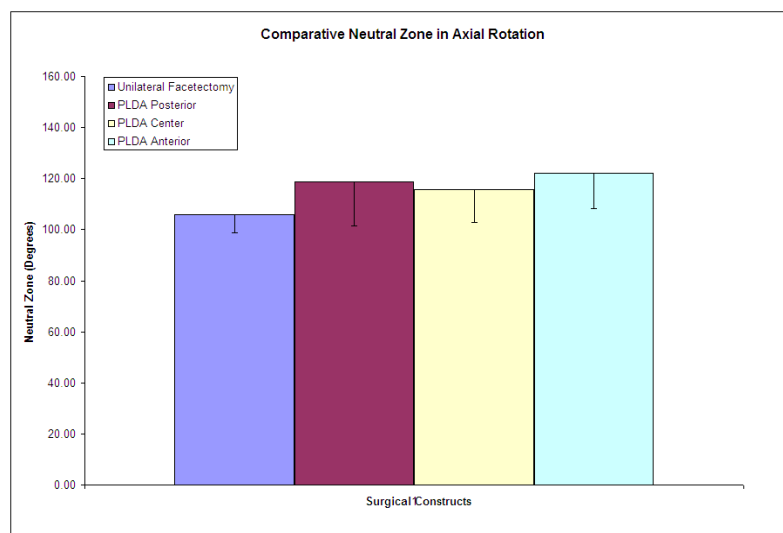


Figure 23. Comparative Axial Rotation NZ post surgical intervention (% of intact)

### 3.1.4 Coupled Sagittal Plane Kinematics

In flexion [Figure 24], anterior sagittal offset of the PLDA device decreased the sagittal plane translation significantly compared to both intact and unilateral facetectomy (78%;  $p < 0.05$ ). Unilateral facetectomy alone did not result in any significant change in sagittal plane translation compared to the intact spine. Posterior sagittal offset and midline placement both showed lower values of sagittal plane translation (90% and 91% respectively) compared to both intact and unilateral facetectomy, however the difference was not statistically significant.

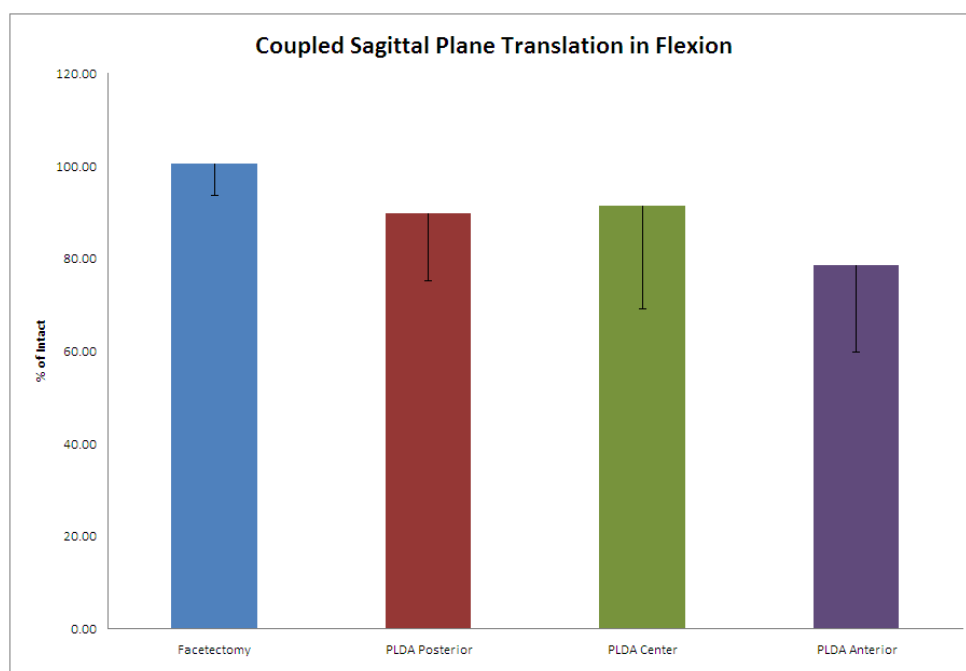


Figure 24. Coupled sagittal plane translation of the lumbosacral spine in flexion

In extension [Figure 25] unilateral facetectomy and PLDA implantation showed a trend towards higher sagittal plane translation (UF:111%, Posterior:117%, Midline:107%, Anterior:109%) compared to intact, however the difference was not statistically significant ( $p > 0.05$ ).

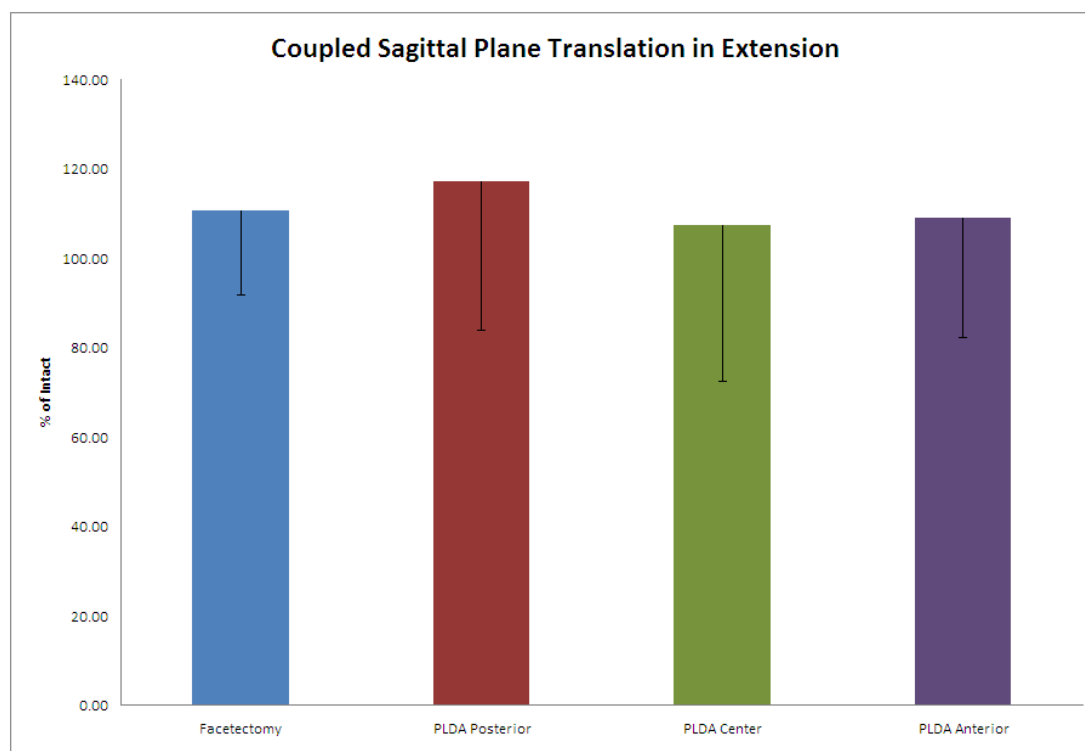


Figure 25. Coupled sagittal plane translation of the lumbosacral spine in extension

### 3.1.5 Effect on Mechanical Effort

In flexion [Figure 26], the moment loads showed an increasing trend from unilateral facetectomy (108%) to posterior (112%), midline (118%) and anterior (126%) sagittal offset placements of the PLDA device respectively. The difference was however not statistically significant.

In extension [Figure 27], the moment loads showed a decreasing trend from unilateral facetectomy (85%) to posterior (84%), midline (76%) and anterior (72%) sagittal offset placements of the PLDA device respectively. The decrease in moment loads with anterior sagittal offset of the PLDA device was statistically significant.

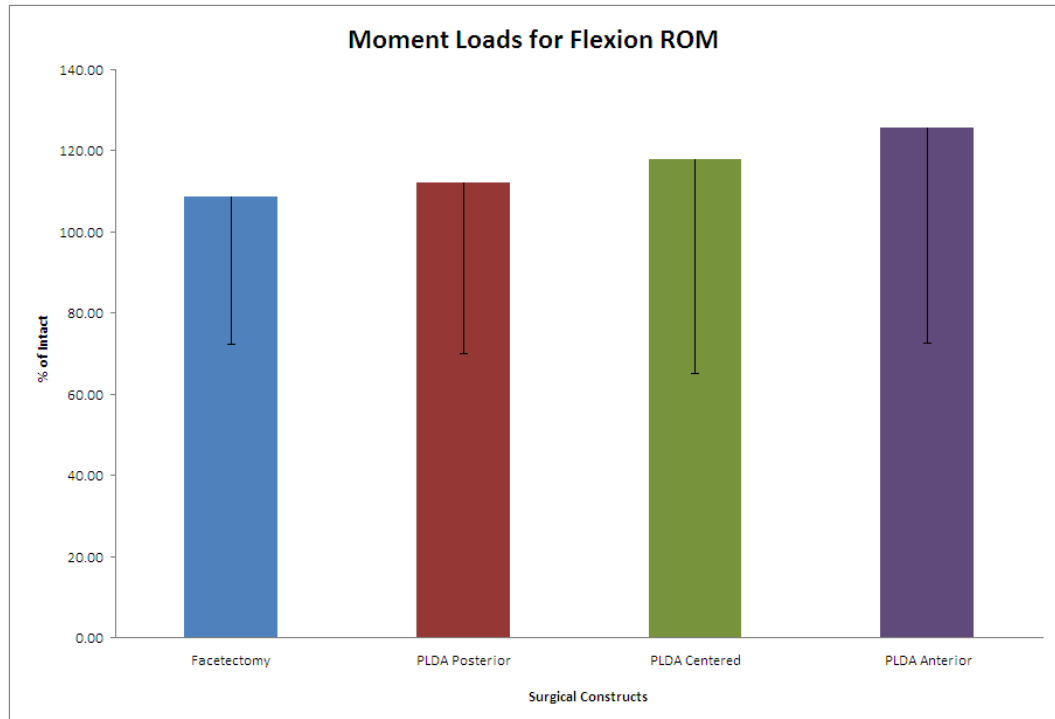


Figure 26. Effect of PLDA placement on flexion moment loads in the lumbar spine

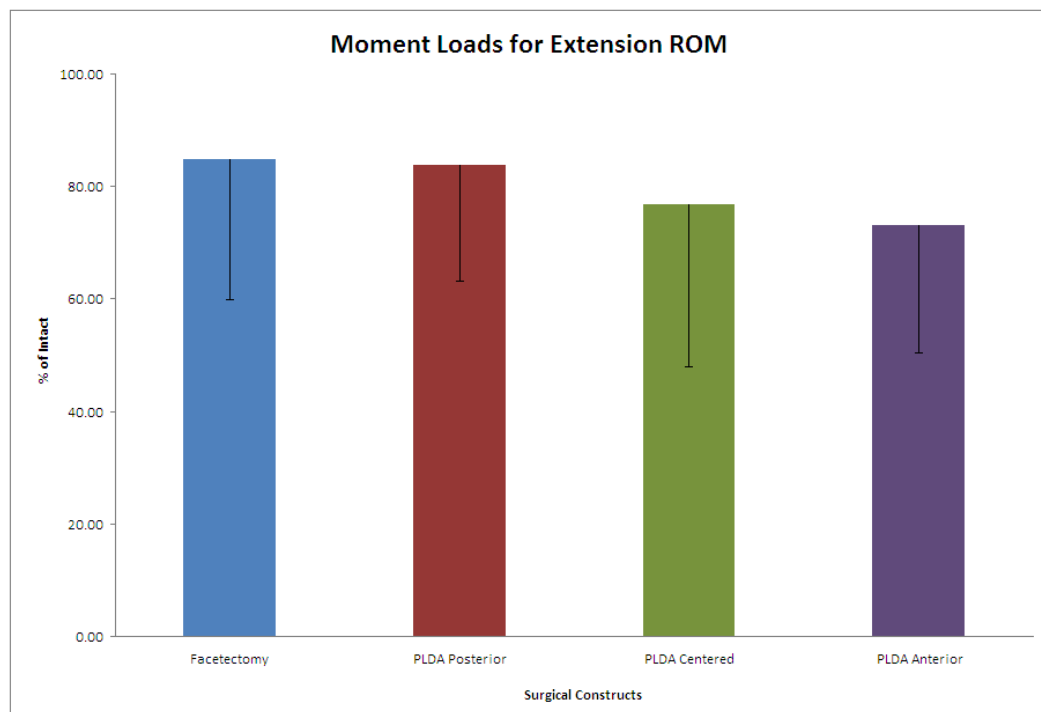


Figure 27. Effect of PLDA placement on extension moment loads in the lumbar spine



### 3.1.6 Effect on Center of Rotation

Figures 28, 30, 32 and 34 depict the COR locus of UF, PLDA-P, PLDA and PLDA-A respectively compared to the intact spine in the sagittal plane. These figures represent the COR locus in the Global Coordinate System. Figures 29, 31, 33, and 35 depict the COR locus of the respective constructs in the Local or Body Coordinate System.

The axis definition differed between the global and local coordinate systems. In the global system XZ plane was the sagittal plane, X being the superior-inferior axis and Z being the anterior-posterior axis. In the local system the YZ plane was the sagittal plane, Y being the superior-inferior axis and Z the anterior-posterior one.

In general, COR for the intact spine moved anteriorly and inferiorly in flexion, while it moved superior and posterior in extension. In terms of length, the COR locus varied from 100mm to 200mm in the superior-inferior direction and 60mm to 150mm in the anterior-posterior direction.

Unilateral facetectomy at the index level diffused the COR locus though following a similar trend. Posterior, Midline, and Anterior sagittal offset placement of the disc arthroplasty system showed a more concentrated locus of the COR compared to the intact and unilateral facetectomy constructs. Also, in some cases, the span of the COR locus increased dramatically compared to the intact. The COR locus did show some displacement with varied placement of the PLDA device at different sagittal offsets, however it was not quantifiable so as to make a tangible conclusion.

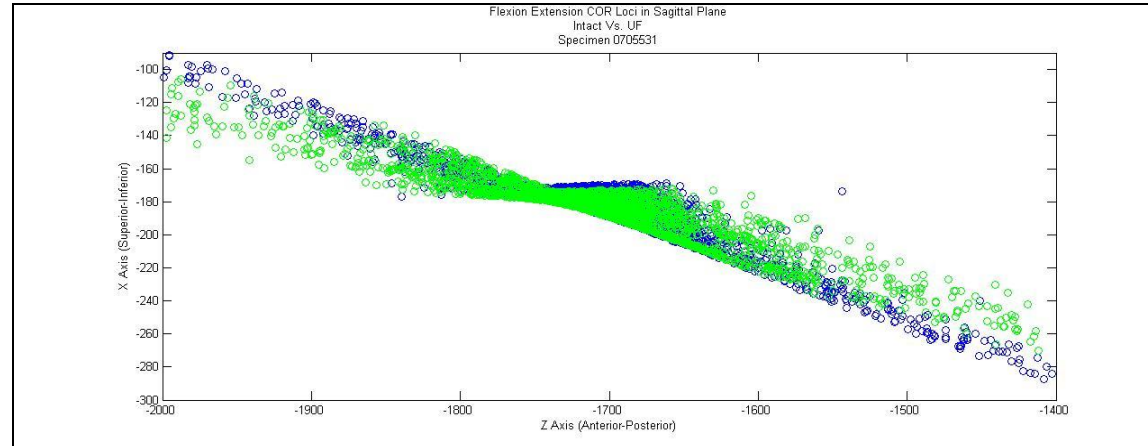


Figure 28: Comparative COR locus of Intact and UF constructs for flexion-extension ROM in the sagittal plane

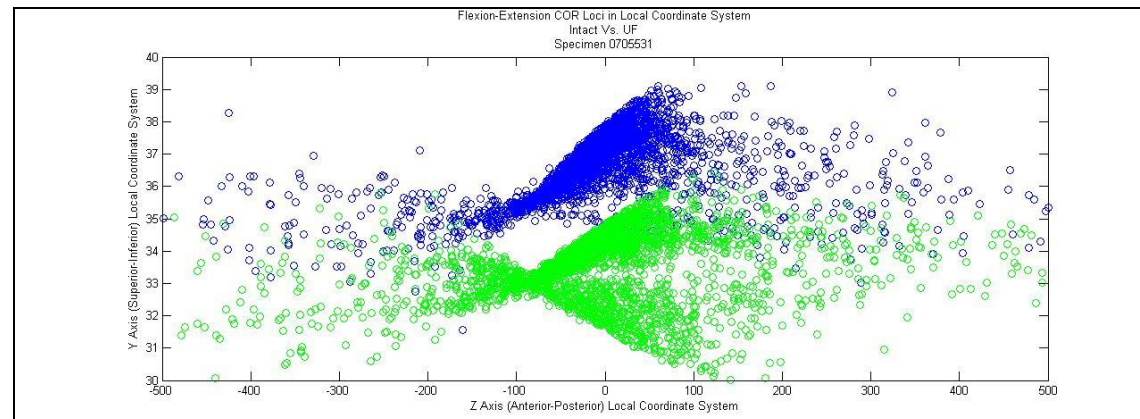


Figure 29: Comparative COR locus of Intact and UF constructs for flexion-extension ROM in Local Coordinate System

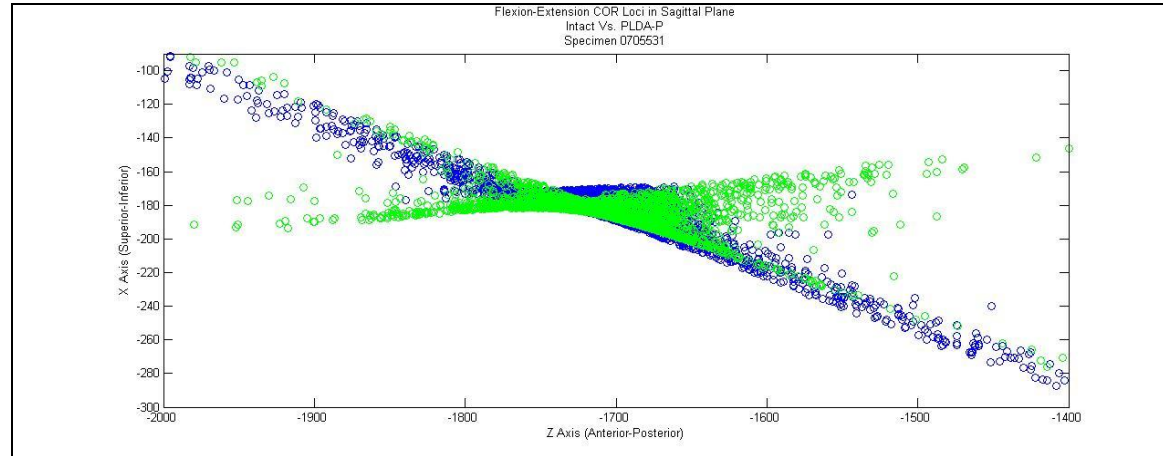


Figure 30: Comparative COR locus of Intact and PLDA-P constructs for flexion-extension ROM in the sagittal plane

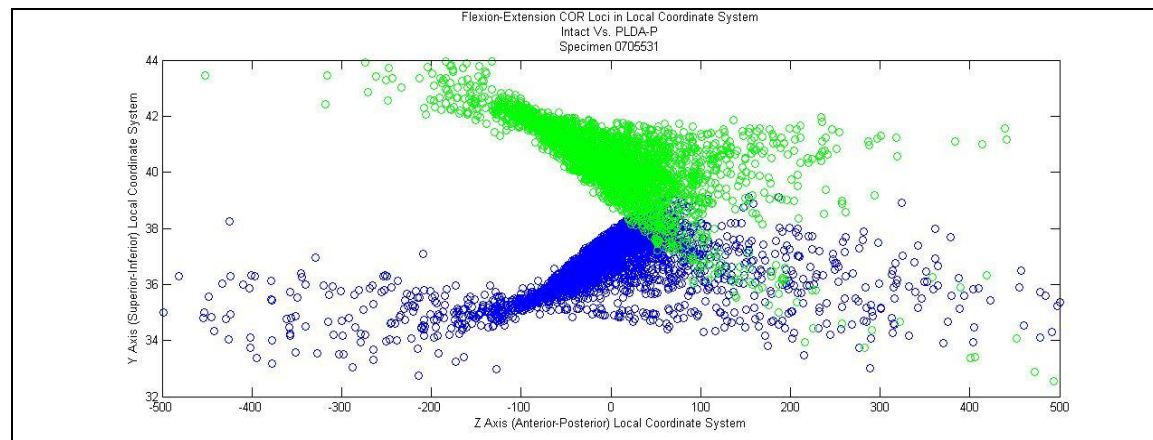


Figure 31: Comparative COR locus of Intact and UF constructs for flexion-extension ROM in Local Coordinate System

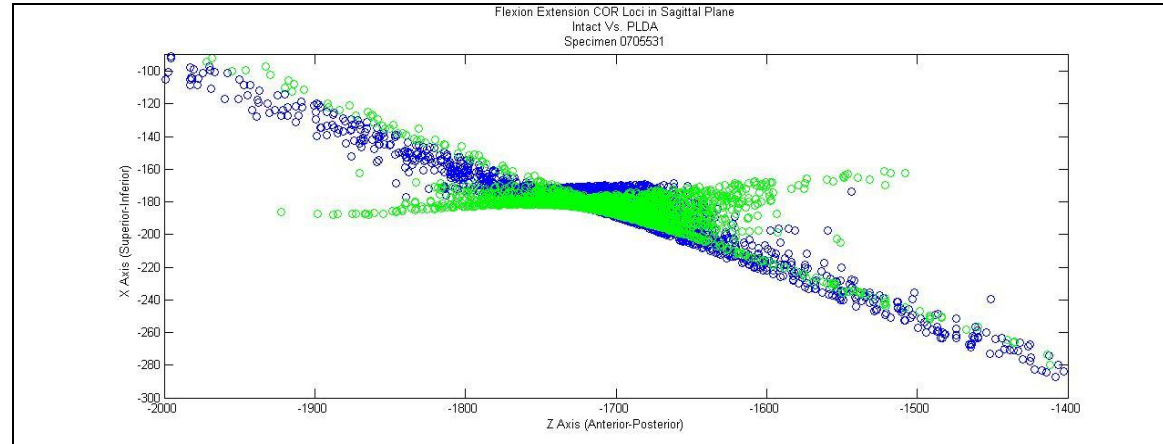


Figure 32: Comparative COR locus of Intact and PLDA constructs for flexion-extension ROM in the sagittal plane

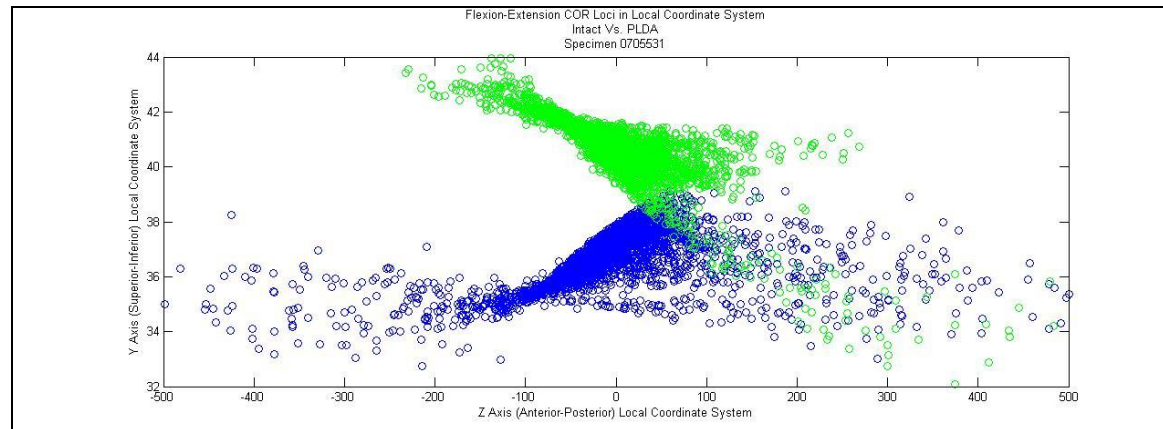


Figure 33: Comparative COR locus of Intact and PLDA constructs for flexion-extension ROM in Local Coordinate System

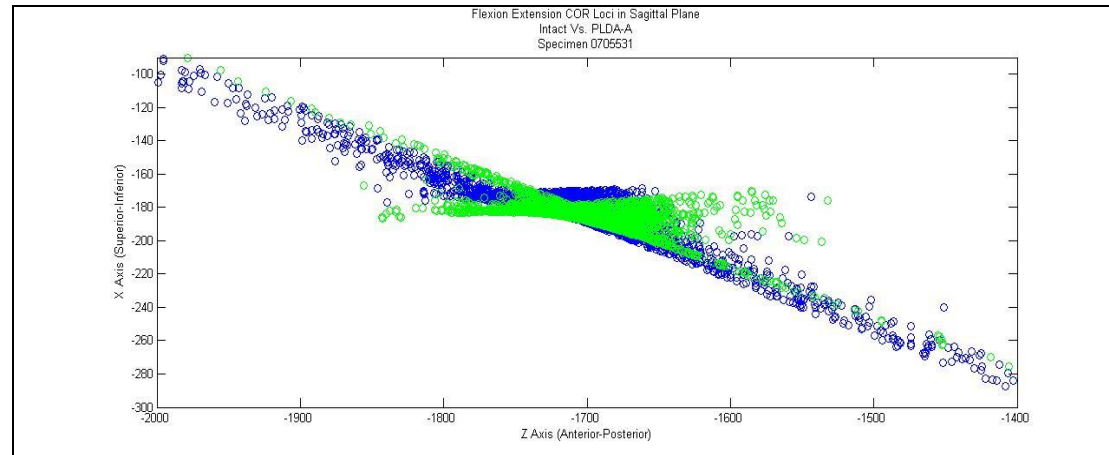


Figure 34: Comparative COR locus of Intact and PLDA-A constructs for flexion-extension ROM in the sagittal plane

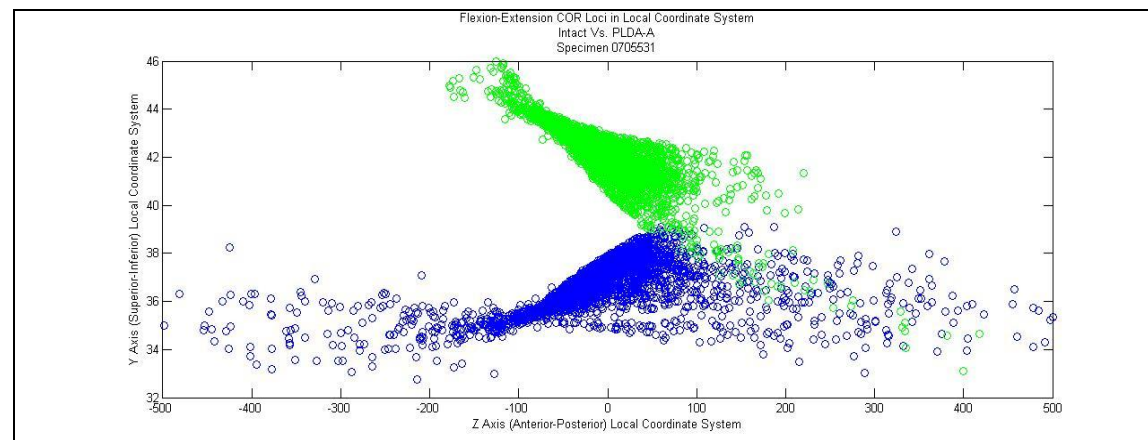


Figure 35: Comparative COR locus of Intact and PLDA-A constructs for flexion-extension ROM in the sagittal plane

## 3.2 Biomechanical Characterization of Posterior Dynamic Stabilization

The second specific aim involved biomechanical evaluation of a Posterior Dynamic Stabilization (PDS) system. The important aspects studied were:

- Effect of indicated surgical intervention on native spine kinematics
- Implanted and adjacent segment kinematics post PDS implantation
- Load sharing and intradiscal pressure at the implanted and adjacent level

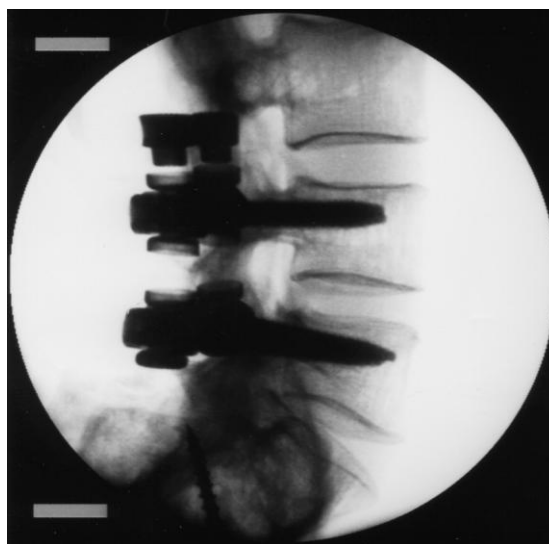


Figure 36. Radiograph of a Posterior Dynamic Stabilization System

### 3.2.1 Unilateral Model

The range of motion (ROM) was determined for each surgical construct [Fig.37], and *post hoc* comparisons were tabulated. Unilateral facetectomy was chosen as the ‘*injury*’ or ‘*surgical decompression*’ model. Unilateral facetectomy (UF) did not cause any significant destabilization in flexion, extension or lateral bending, but increased rotation significantly (124% of intact). Stabilization of the unilateral injury with a

unilateral PDS (UF+UPDS) resulted in reduction of motion which was significant in flexion and axial rotation, (F: 58% of injury; AR: 87% of injury), but insignificant in extension (E: 62% of injury) and lateral bending (LB: 65% of injury). Stabilization of the unilateral injury with a bilateral PDS (UF+BPDS) resulted in reduction of motion which was significant in flexion, lateral bending, and axial rotation (F: 52% of injury; LB: 57% of injury; AR: 85% of injury), but insignificant in extension (E: 65% of injury).

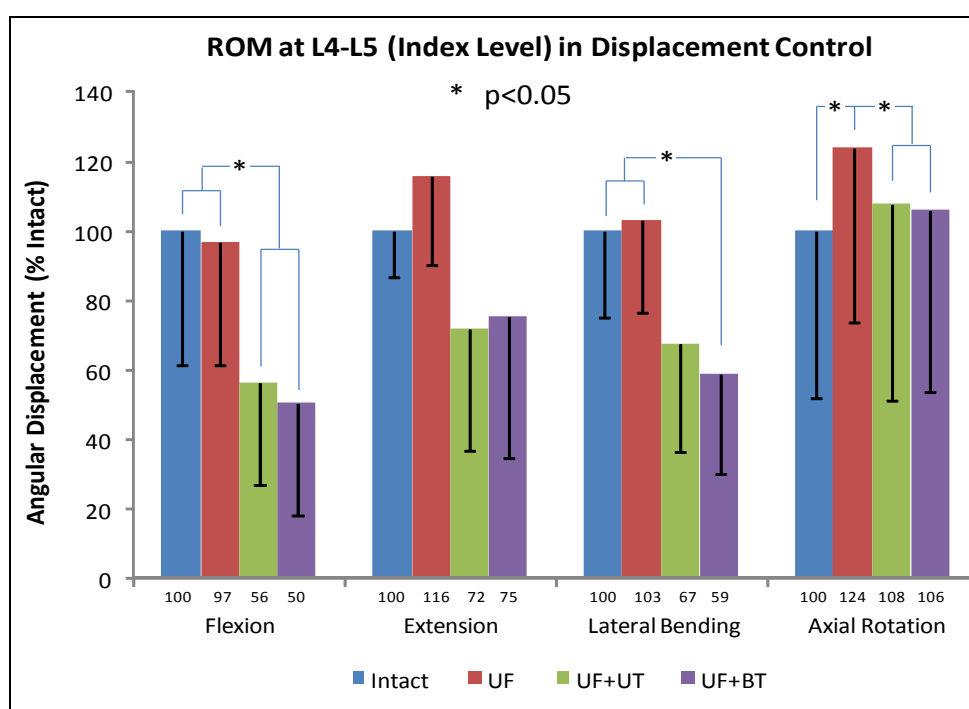


Figure 37. Results of multidirectional flexibility testing for *Unilateral Model*

Note: UF+UT = UF+UPDS; UF+BT = UF+BPDS

Increased motion due to the UF injury was expected to lead to reduced motions at the immediate adjacent levels in a hybrid protocol [Table 1]. This was generally true (especially for L3-L4), but the reduced motions were small and insignificant, except in

axial rotation. Stabilization with the PDS system reduced ROM at L4-L5, and as expected produced larger ROM at the adjacent levels, which reached significance (*w.r.t.* injury) only in lateral bending (L3-L4, L5-S1) and axial rotation (L3-L4). There were few differences between unilateral stabilization (UF+UPDS) and bilateral stabilization (UF+BPDS) on adjacent level motion.

Intradiscal pressure measurements of adjacent levels [Table 1] showed greater differences between intact and injury groups than what was seen kinematically. Even though there were minimal differences between UF and intact ROM in flexion-extension, indicating a minimal destabilization, the differences in IDP between these two constructs were much greater (F: 44%, E: 26%) than the differences in ROM. Therefore, even small changes in kinematics may translate to large changes in load-sharing properties. Statistically, in lateral bending, unilateral injury stabilized with a bilateral PDS (UF+BPDS), was the only construct to produce significantly more adjacent level pressure than the corresponding level of the unilaterally injured spine (only at L3-L4).

Table 1. Unilateral model adjacent level ROM and pressure.

		Intact (1)	UF (2)	UF+UT (3)	UF+BT (4)
ROM (°)	<b>Flexion</b>				
	L3-L4	100±23 (4)	101±20	109±24	111±27 (1)
	L5-S1	100±32	98±26	107±41	108±35
	<b>Extension</b>				
	L3-L4	100±11	91±12	101±16	98±9
	L5-S1	100±26	118±28	133±43	126±35
	<b>Lateral Bending</b>				
	L3-L4	101±16	98±16 (3,4)	105±17 (2)	106±20 (2)
L5-S1	100±28 (3,4)	104±29 (3,4)	114±31 (1,2)	116±31 (1,2)	
Pressure (PSI)	<b>Axial Rotation</b>				
	L3-L4	100±31 (2,3,4)	89±29 (1,3,4)	93±28 (1,2)	94±28 (1,2)
	L5-S1	100±22	99±25	110±27	109±26
	<b>Flexion</b>				
	L3-L4	100±42 (4)	144±33	166±38	220±76 (1)
	L5-S1	100±58 (3,4)	141±62	161±53 (1)	207±82 (1)
	<b>Extension</b>				
	L3-L4	100±21	74±26	78±31	99±24
L5-S1	100±84	103±78	120±89	113±96	
<b>Lateral Bending</b>	L3-L4	100±54 (4)	97±59 (4)	109±66 (4)	127±76 (1,2,3)
	L5-S1	100±78	90±70	90±65	94±70
	<b>Axial Rotation</b>				
	L3-L4	100±44	92±33	110±36	81±21
L5-S1	100±33	85±35	100±45	87±33	

Note: Parentheses show which constructs are significant.

UF+UT = UF+UPDS; UF+BT = UF+BPDS



### 3.2.2 Bilateral Model

The range of motion (ROM) was determined for each surgical construct of the bilateral injury model [Fig.38], and *post hoc* comparisons were tabulated. Bilateral facetectomy (BF) was chosen as the ‘injury’ or ‘surgical decompression’ model. Destabilization after BF increased ROM in all directions, but this reached statistical significance only in axial rotation. In flexion and lateral bending, similar statistical trends were seen, revealing that BF+BPDS provided significant stabilization with respect to intact and BF. In extension, the bilateral injury produced larger motions (119%) when compared to intact. In axial rotation BF motion was 168% of intact ( $p<0.05$ ).

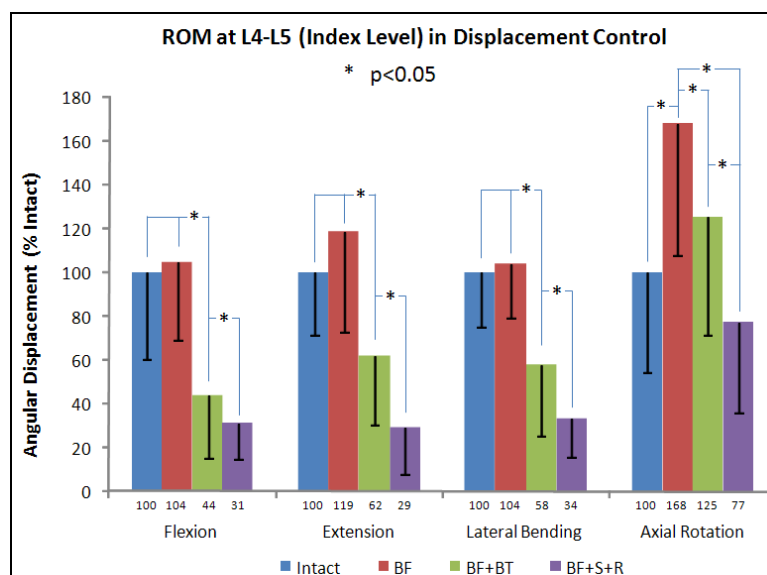


Figure 38. Index level ROM for *Bilateral Model*

The trend of index level motion followed the model  $BF+S+R < BF+BPDS < BF$ , where all constructs were statistically different than one another. Stabilization with the PDS device reduced the ROM values, which were, in terms of intact, 44%, 62%, 58%,

125%, while rigid fixation resulted in ROM values of 31%, 29%, 34%, and 77% in F, E, LB, AR, respectively.

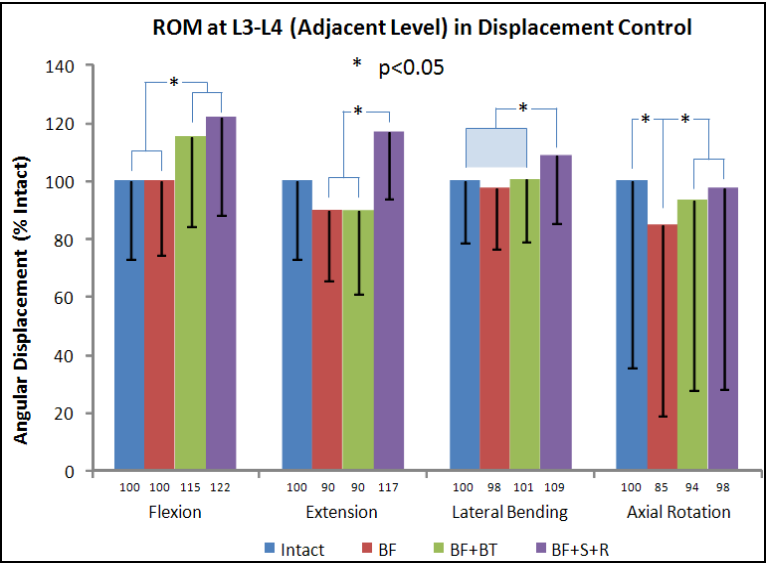


Figure 39. Superior level ROM for *Bilateral Model*

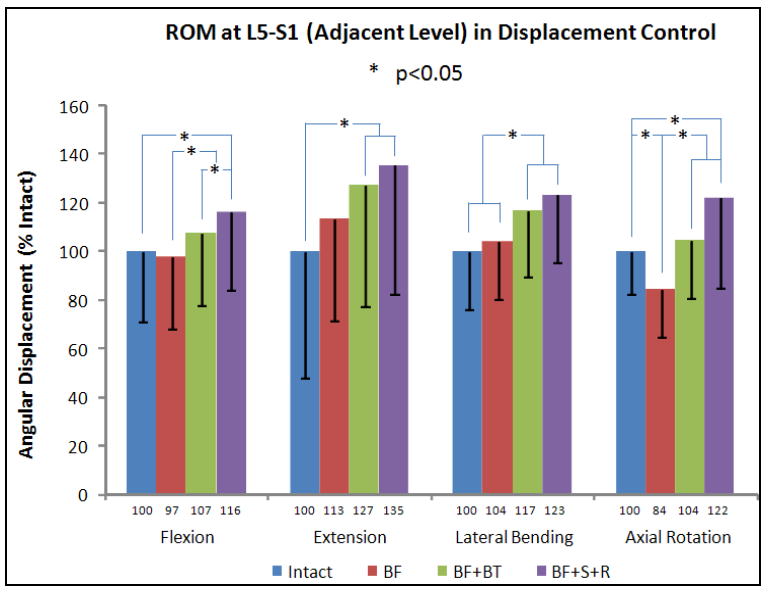


Figure 40. Inferior level ROM for *Bilateral Model*

Increased motion due to the BF injury at the index level is expected to lead to reduced motions at the immediate adjacent levels in a hybrid / displacement control protocol (Figure 39-40). This was generally correct, but the reduced motions were small and insignificant, except for axial rotation where BF was significantly less than intact ( $p < 0.05$ ) (except for L5-S1). Stabilization at L4-L5 increased the ROM at both the adjacent levels, and the trend followed the model  $BF+S+R \geq BF+BPDS \geq BF$  for all loading modes at both L3-L4 and L5-S1, indicating the utility of ‘dynamic stabilization’ to offset adjacent level effects caused by rigid instrumentation. Nevertheless, this trend was not always large enough to warrant significance.

The load-bearing effect at the adjacent levels, as measured by intradiscal pressure, [Figures 41 and 42] demonstrated very similar trends to ROM, i.e., the IDP was decreased or unchanged after facetectomy at the L4-L5 level, and increased with PDS stabilization, with an even greater increase with rigid stabilization. The increase in adjacent segment pressure after stabilization was more pronounced at the superior (L3-L4) level than the inferior (L5-S1) level, reaching a significant level in flexion, lateral bending and rotation at L3-L4, but only in flexion at L5-S1. While adjacent segment ROM changes were more pronounced in rotation, the increase in adjacent segment pressure was most noticeable in flexion. At the superior adjacent level (L3-L4) while the ROM in flexion was increased to 122% after rigid fixation, the corresponding disc pressure was increased to 205% of the intact value. Stabilization with PDS also significantly increased the adjacent segment pressures in flexion, but the increase was smaller (190%) than with rigid fixation ( $p < 0.05$ ). Therefore, though a strong relationship exists between ROM and IDP changes at the adjacent segments, it shows a non-linear

phenomenon in flexion. Additionally, though the use of the particular PDS device reduced the adjacent level pressure, it did not restore it near the intact value in flexion. How and whether this would translate into potential alleviation of adjacent level stresses needs to be corroborated with clinical evidence. The remaining ROM and IDP trends are very similar, though higher variation (standard deviations) in the measurement of pressure resulted in very little significance, and no significance between BF+BPDS and BF+S+R in any loading mode.

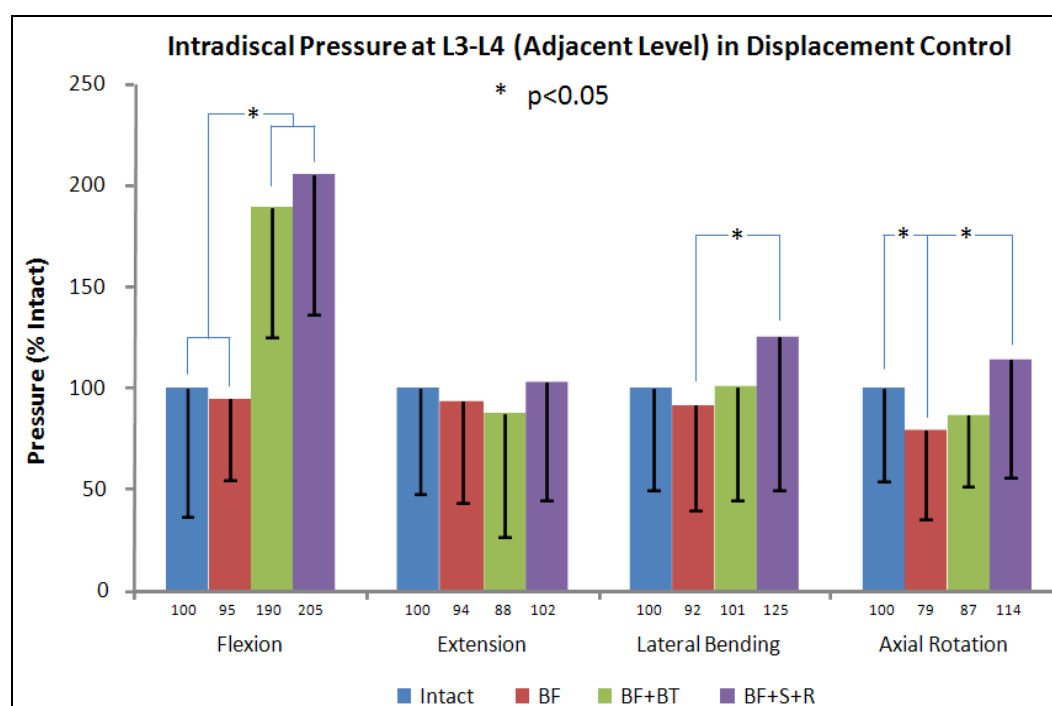


Figure 41. Superior adjacent level intradiscal pressures for *Bilateral Model*

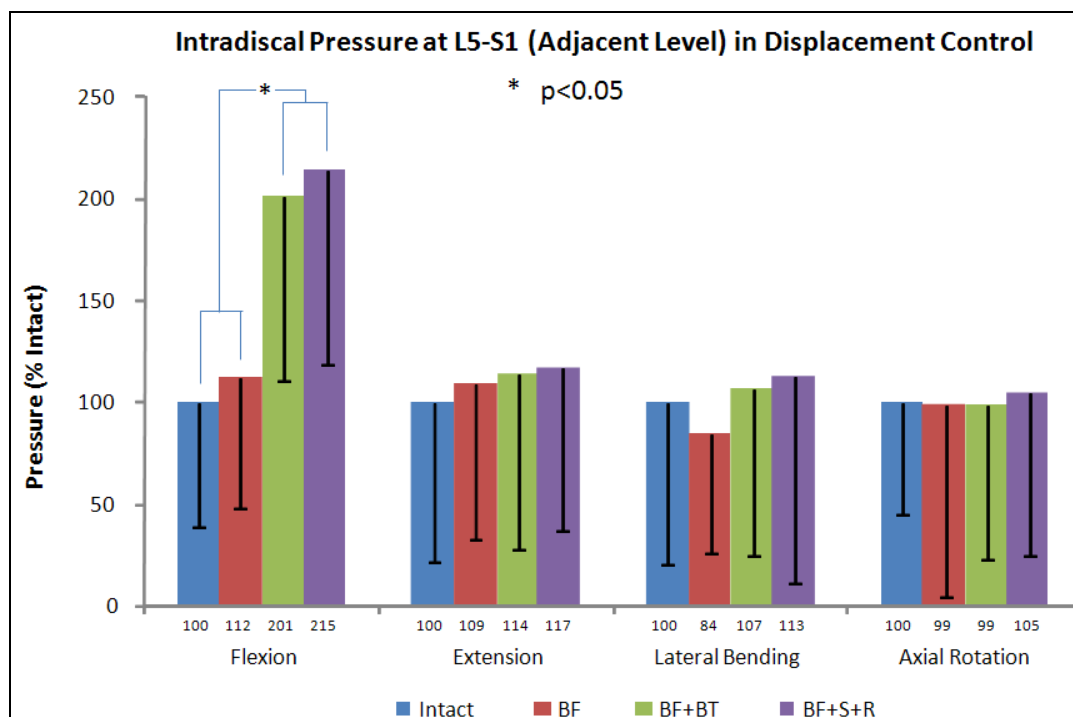


Figure 42. Inferior adjacent level intradiscal pressures for *Bilateral Model*

### 3.2.3 Neutral Zone (NZ) – Unilateral and Bilateral Models

In flexion [Fig.43], unilateral or bilateral injury did not increase the NZ compared to intact. Bilateral stabilization with PDS reduced the NZ significantly compared to intact for both the unilateral and bilateral models (68% and 71%). Rigid fixation also reduced the NZ significantly compared to intact (70%).

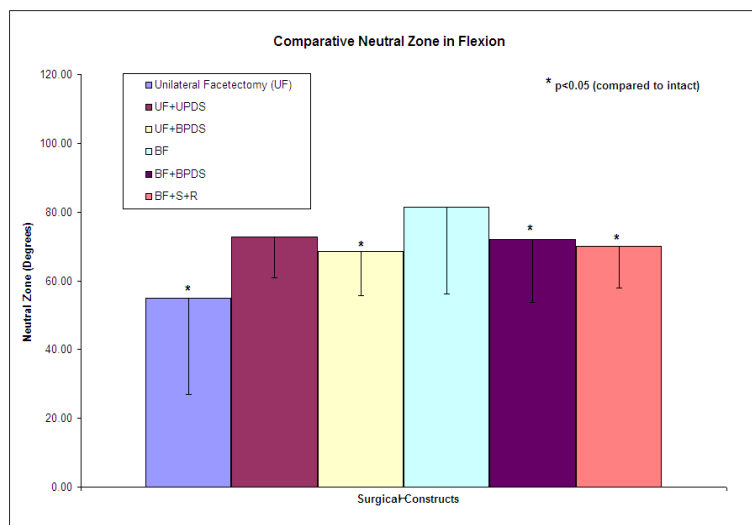


Figure 43. Comparative Flexion NZ post surgical intervention for the *Bilateral Model*

In extension [Fig.44], destabilization followed the trend (UF>BF>I), highlighting the importance of facets in extension. Unilateral injury increased the NZ to 196% ( $p<0.05$ ) and BF to 150%. Unilateral stabilization (UF+UPDS) was not able to bring back the increased NZ, highlighting the importance of a bilateral stabilization construct. Bilateral stabilization with PDS was able to bring back the NZ closer to intact for both the Unilateral (139%) and Bilateral (126%) models.

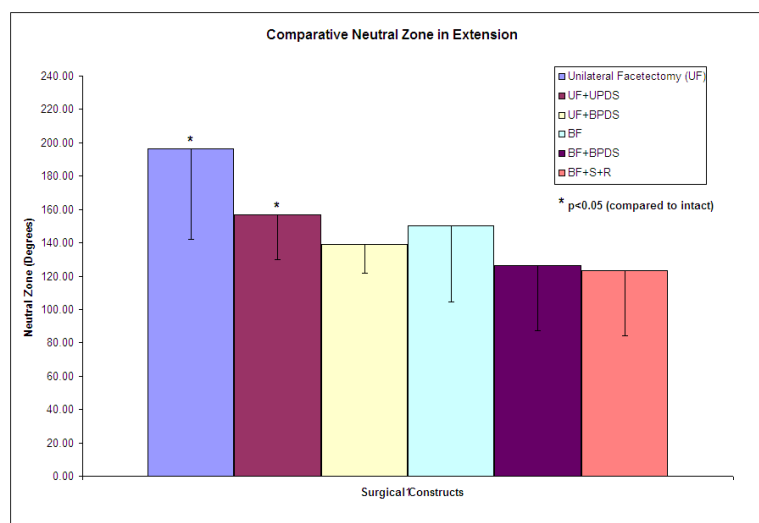


Figure 44. Comparative Extension NZ post surgical intervention for the *Bilateral Model*

### 3.2.4 Coupled Sagittal Plane Kinematics

In flexion [Figure 45], bilateral facetectomy did not show any significant change compared to intact (106%;  $p>0.05$ ). Sagittal plane translation decreased significantly ( $p<0.05$ ) with both posterior dynamic stabilization (43%) and spacer with rigid rods (41%) compared to intact and facetectomy.

In extension [Figure 46], bilateral facetectomy increased the sagittal plane translation (134%), however it was not statistically significant. Posterior dynamic stabilization decreased the sagittal plane translation significantly (64%,  $p<0.05$ ). Spacer with rigid rods too decreased the sagittal plane translation significantly (33%,  $p<0.05$ ). This decrease for both posterior systems was also statistically significant with respect to bilateral facetectomy. Though the decrease in sagittal plane translation with rigid fixation was more than dynamic stabilization, the difference was not statistically significant.

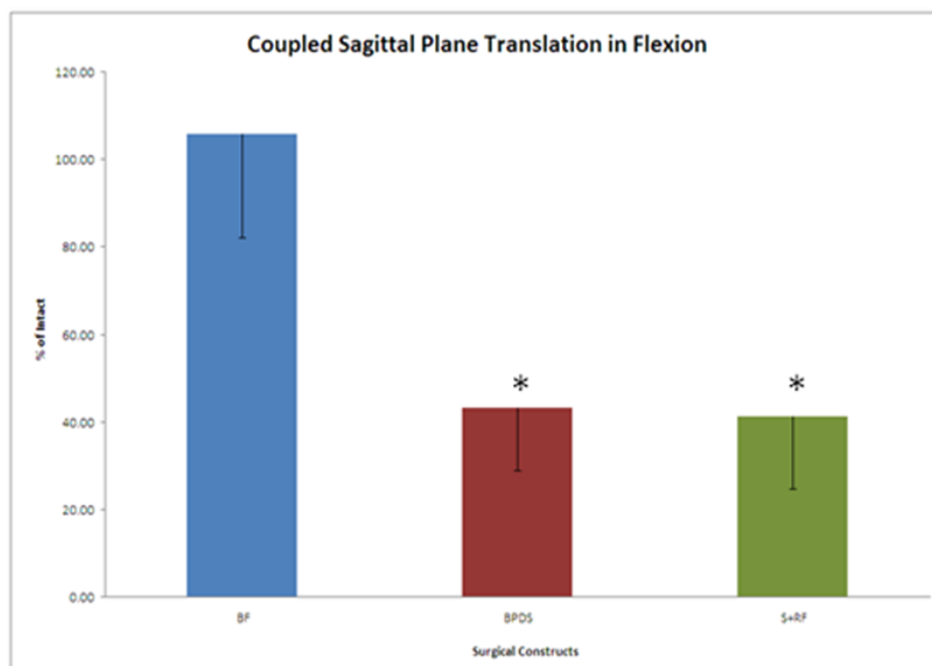


Figure 45. Coupled sagittal plane translation of the lumbosacral spine in flexion

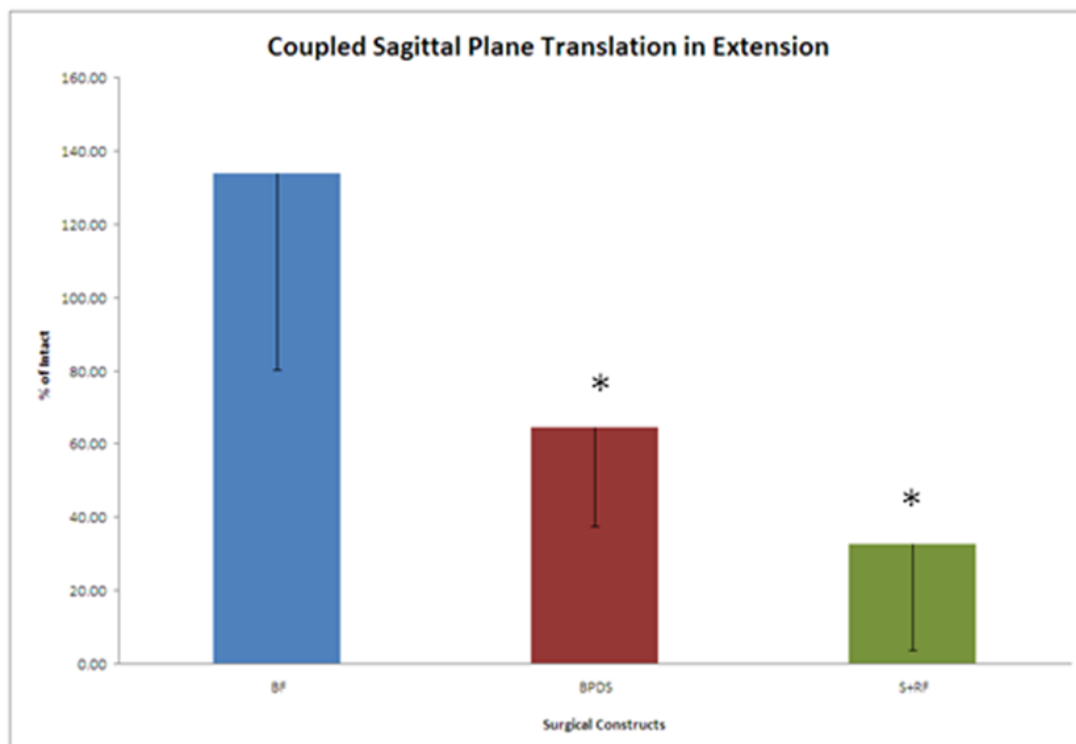


Figure 46. Coupled sagittal plane translation of the lumbosacral spine in extension

### 3.2.5 Coupled Coronal Plane Kinematics

In both left [Figure 47] and right [Figure 48] lateral bending, Posterior Dynamic Stabilization reduced coupled axial rotation compared to the intact spine (68% and 72% respectively), but it was not statistically significant. Bilateral facetectomy with and without posterior dynamic stabilization did not show any statistically significant difference in coupled axial rotation compared to intact spine in both left and right lateral bending (106%, 92%, 98%, & 97%,  $p > 0.05$ ). Rigid fixation with interbody spacer reduced coupled axial rotation in both left and right lateral bending (67%, 57%,  $p < 0.05$ ).



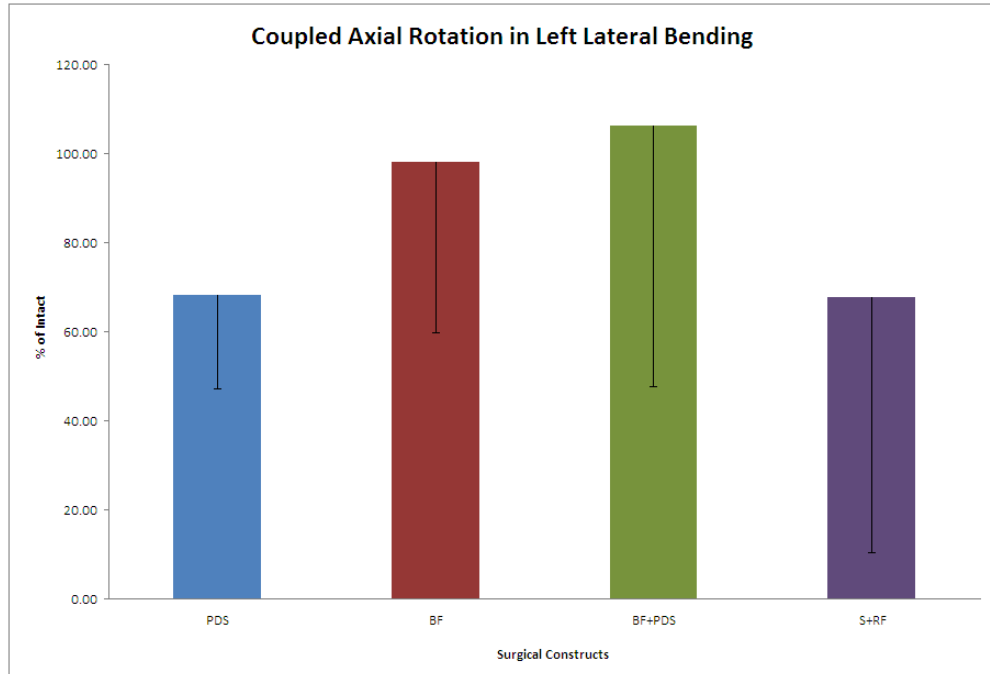


Figure 47. Coupled axial rotation during left lateral bending of the lumbosacral spine

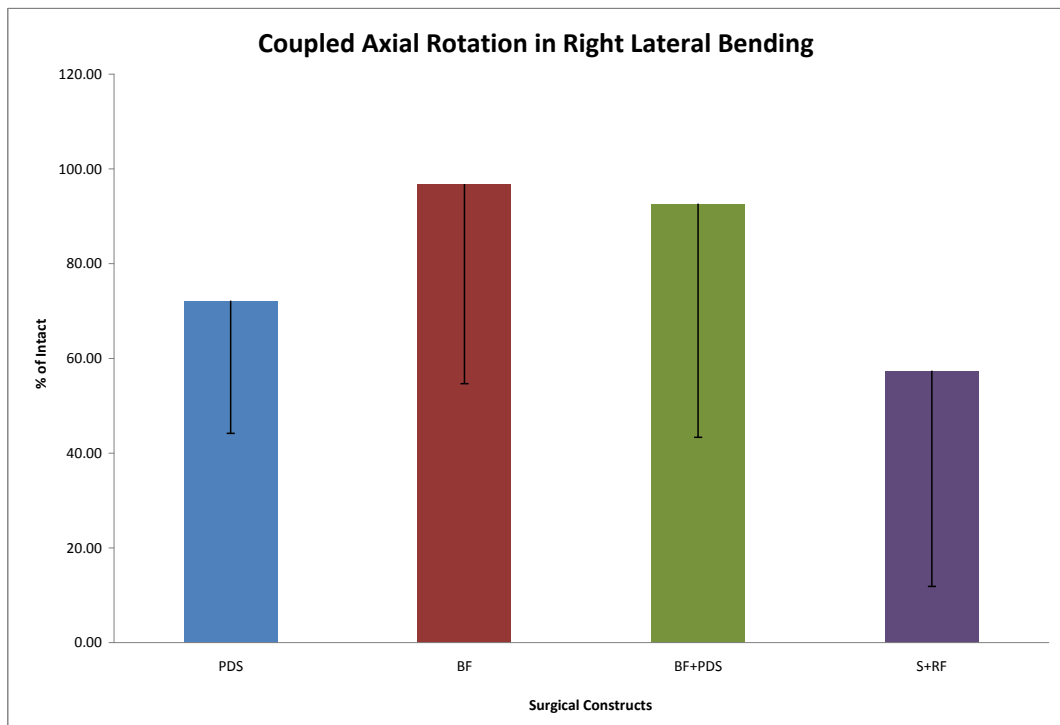


Figure 48. Coupled axial rotation during right lateral bending of the lumbosacral spine

### 3.2.6 Effect on Mechanical Effort

In flexion [Figure 49], posterior dynamic stabilization increased the moment loads significantly to 162% ( $p < 0.05$ ) compared to intact. Bilateral facetectomy decreased the moment loads (96%) but it was not statistically significant. The moment loads increased significantly in all three stabilization constructs of BF+PDS (139%), S+PDS (135%) and S+RF (138%) respectively.

In extension [Figure 50], posterior dynamic stabilization showed a slight increase in moment loads (104%) which was not statistically significant. The moment loads for the surgical constructs of BF, BF+PDS, S+PDS and S+RF reduced to 83%, 99%, 95% and 94% respectively. The decrease was not statistically significant ( $p > 0.05$ ).

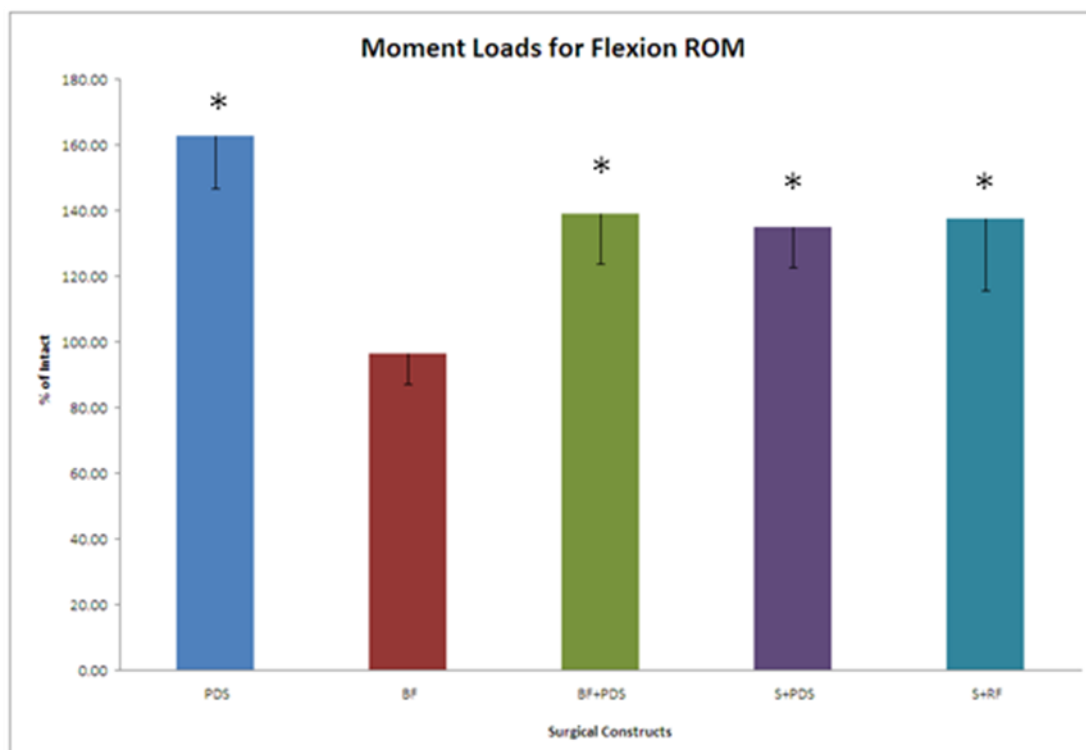


Figure 49. Effect of Dynamic Stabilization and Rigid Fixation on Flexion Moment Loads

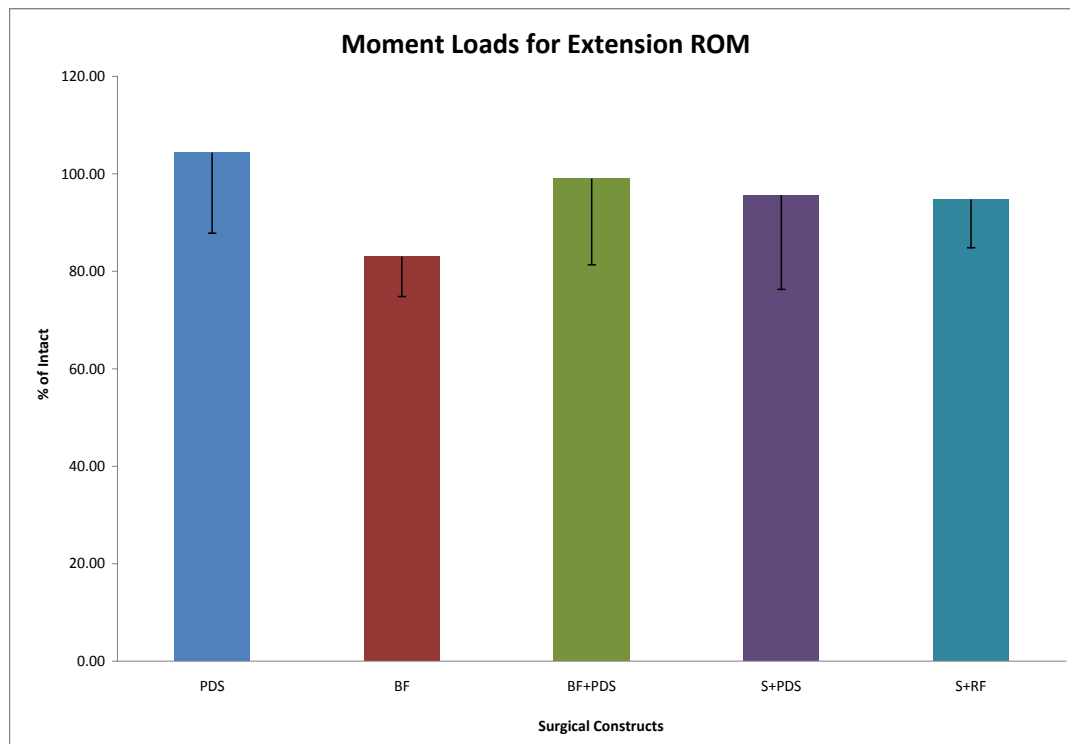


Figure 50. Effect of Dynamic Stabilization and Rigid Fixation on Extension Moment Loads

### 3.2.7 Effect on Center of Rotation

Continuous Instantaneous Center of Rotation (COR) was computed for the intact spine as well as the surgically treated and reconstructed spine. Figures 51, 53 and 55 depict a representative overlay of the PDS, BF and BF+PDS constructs' COR locus over the intact COR locus respectively for flexion-extension in the global coordinate system. Figures 52, 54 and 56 depict the comparative COR loci for the respective constructs in the local coordinate system. The axis definition differed between the global and local coordinate systems. In the global system XZ plane was the sagittal plane, X being the superior-inferior axis and Z being the anterior-posterior axis. In the local system the YZ

plane was the sagittal plane, Y being the superior-inferior axis and Z the anterior-posterior one.

In general, the COR locus of the intact spine had a shorter displacement or span along the superior-inferior axis in flexion (~20mm) compared to extension (~40mm) [Figure 51]. Also, the COR had an increased anterior-posterior translation in conjunction with the superior-inferior displacement in flexion, compared to extension. The COR locus of dynamic stabilization of the intact spine followed a trend similar to the intact spine [Figure 51], though its span along the superior-inferior axis was limited in both flexion and extension in line with the stabilization induced by the dynamic system.

Bilateral facetectomy [Figure 53] showed a very diffused pattern in the COR locus compared to the intact spine. Surgical reconstruction of the bilateral facetectomy using dynamic stabilization [Figure 55] followed a similar diffused pattern of the COR locus. The COR loci of the PDS+BF was drastically diffused compared to the pattern of PDS alone.

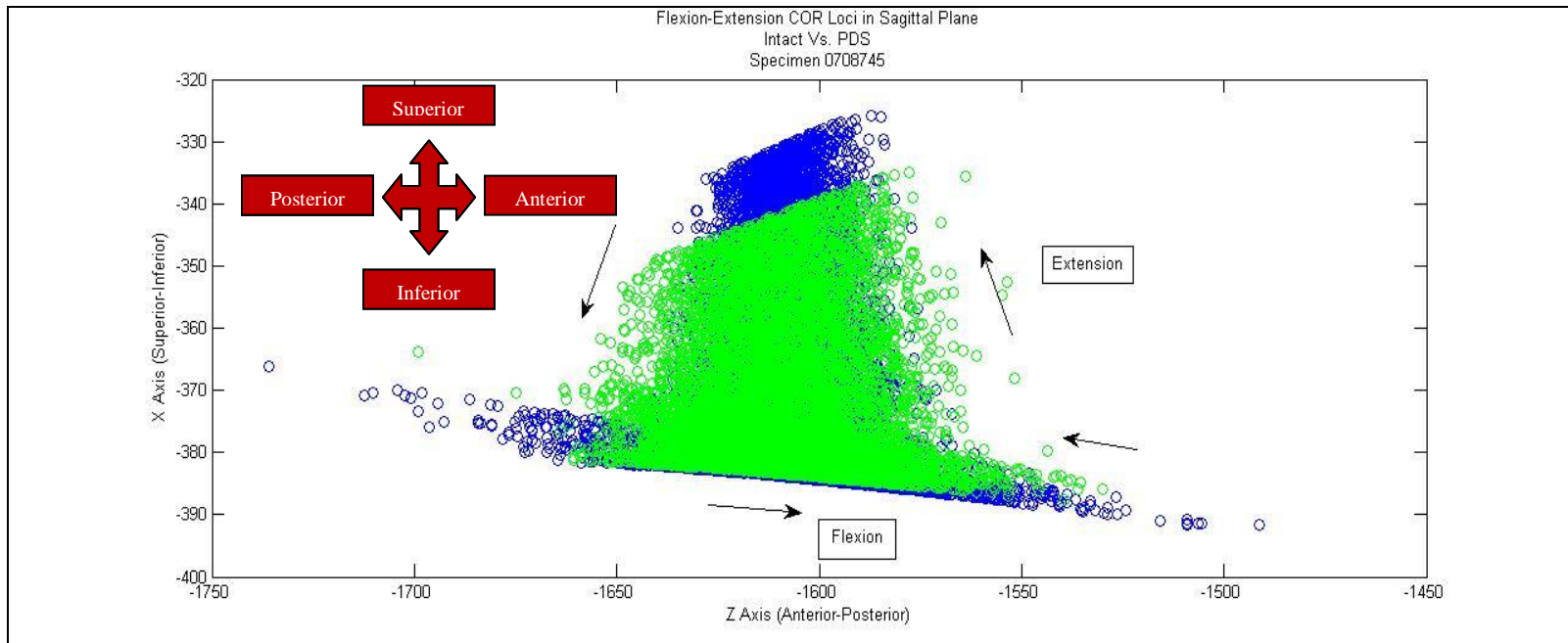


Figure 51. Comparative Flexion-Extension COR Loci in the Global Coordinate System for Intact and PDS constructs

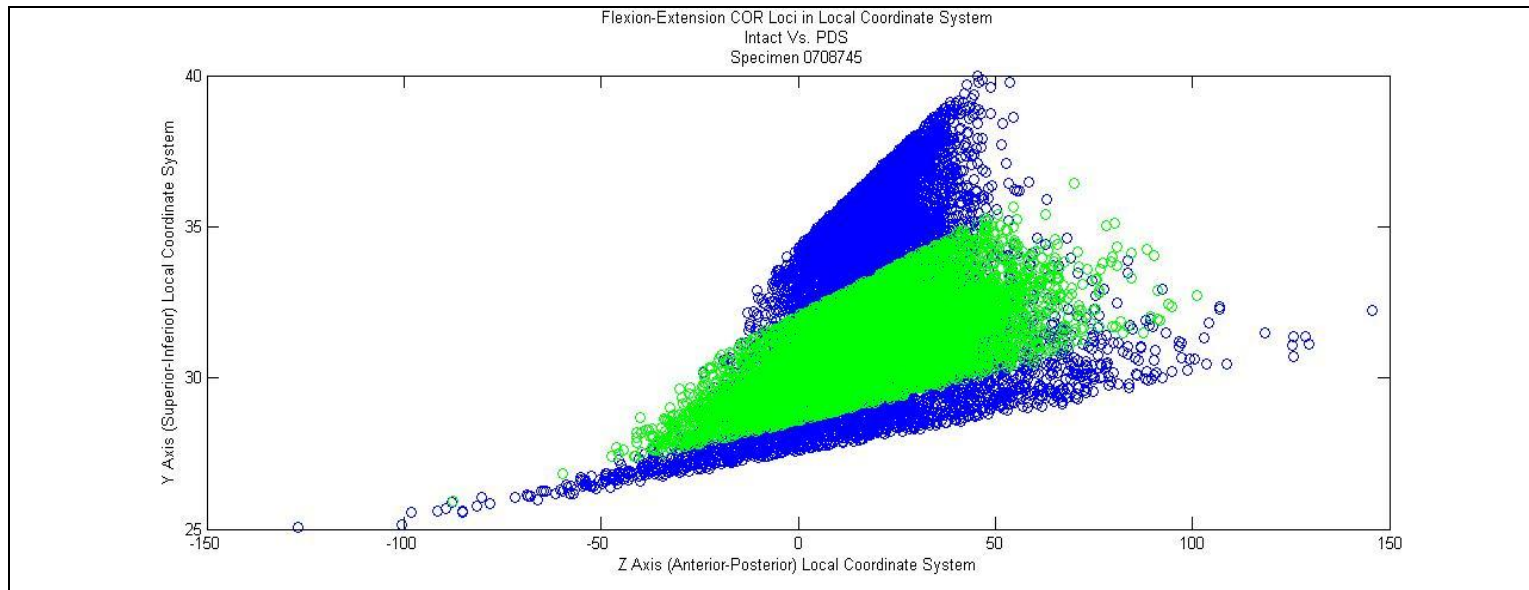


Figure 52. Comparative Flexion-Extension COR Loci in the Local Coordinate System for Intact and PDS constructs

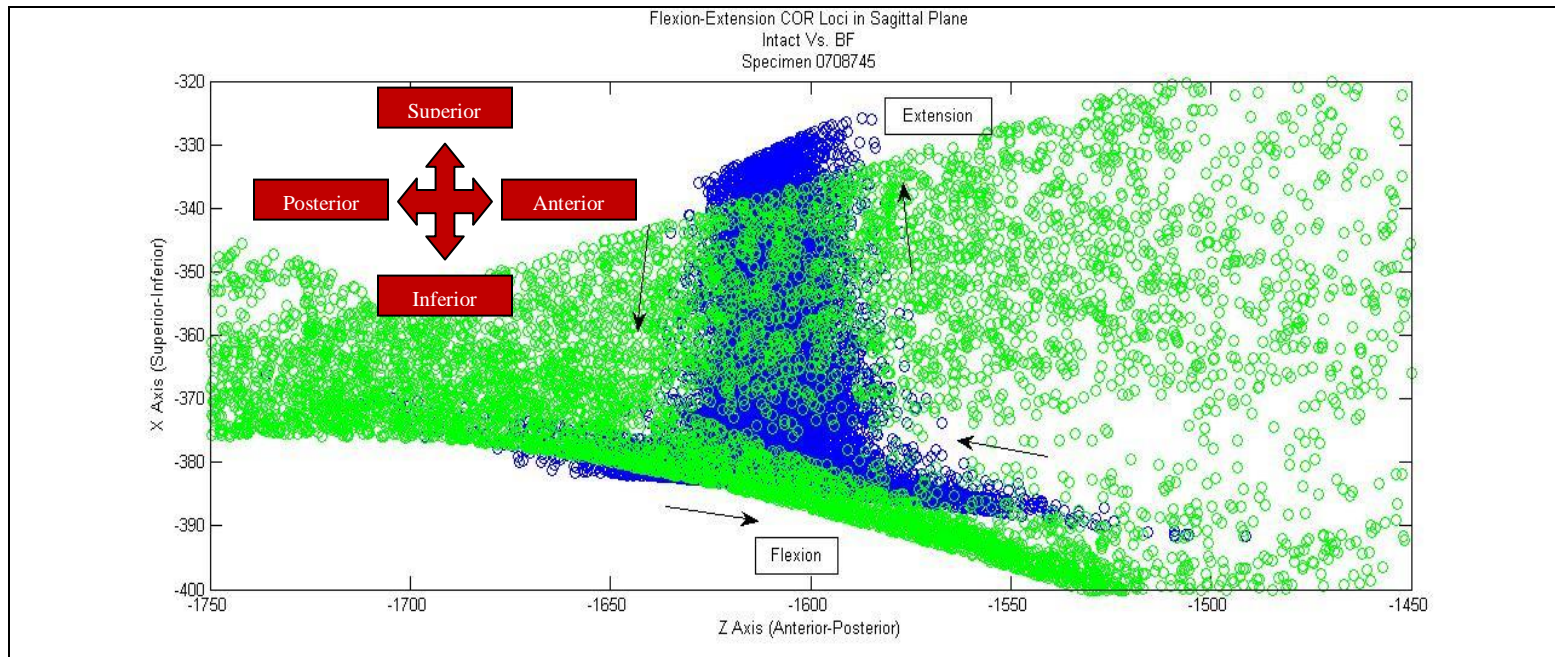


Figure 53. Comparative Flexion-Extension COR Loci in the Global Coordinate System for Intact and BF constructs

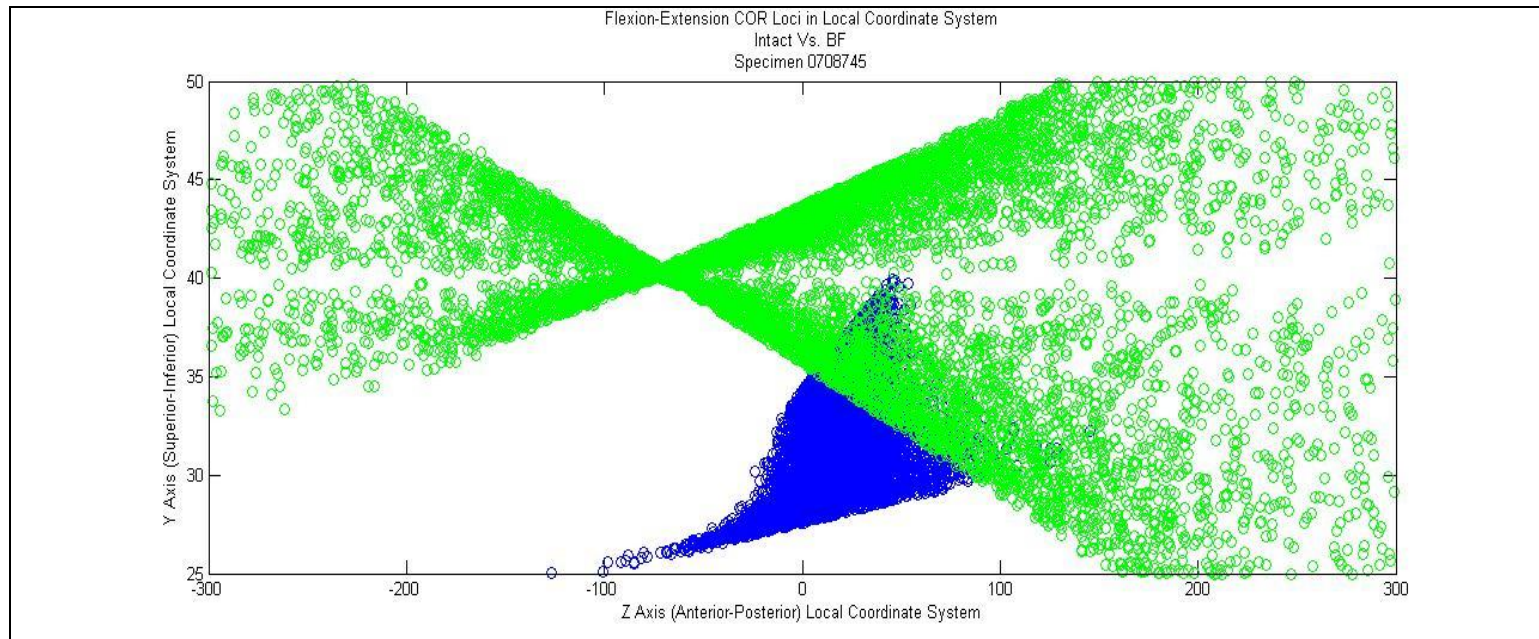


Figure 54. Comparative Flexion-Extension COR Loci in the Local Coordinate System for Intact and BF constructs



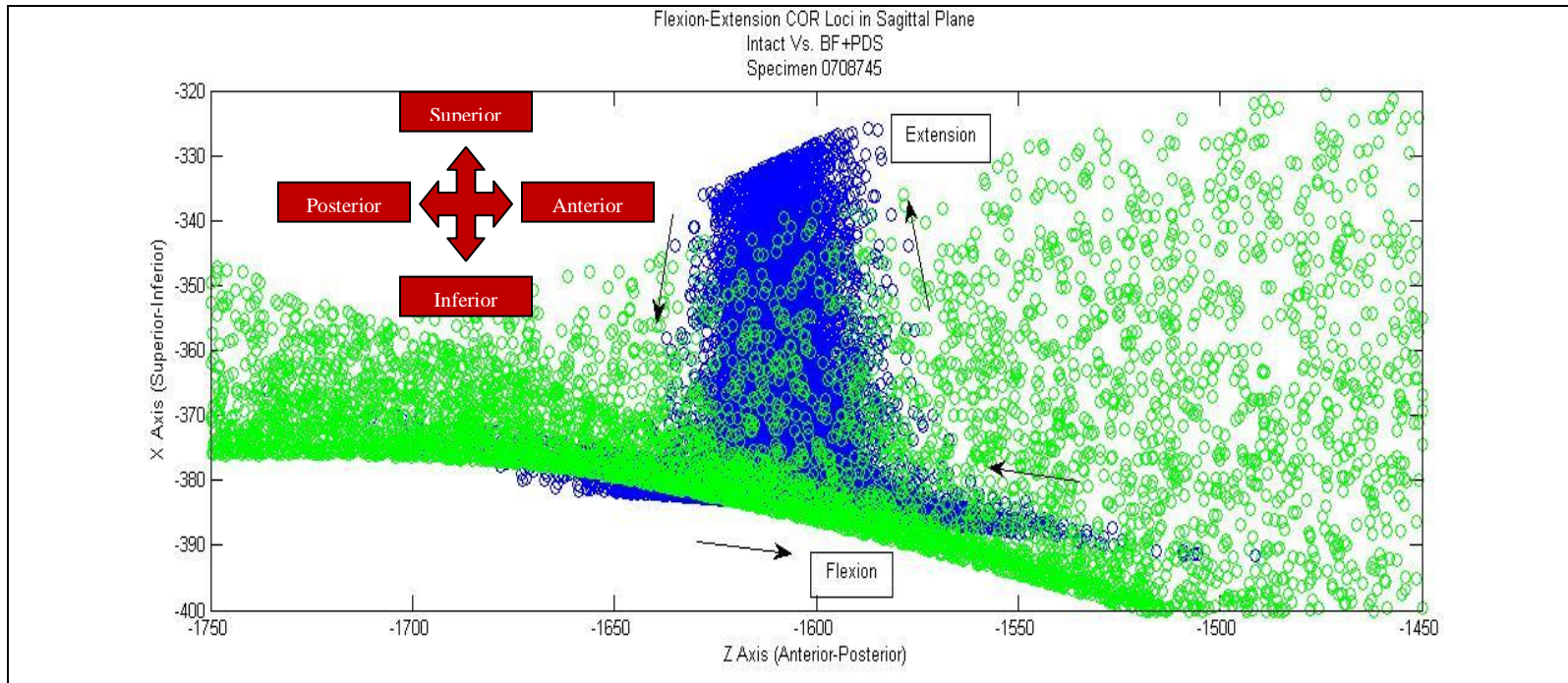


Figure 55. Comparative Flexion-Extension COR Loci in the Global Coordinate System for Intact and BF+PDS constructs

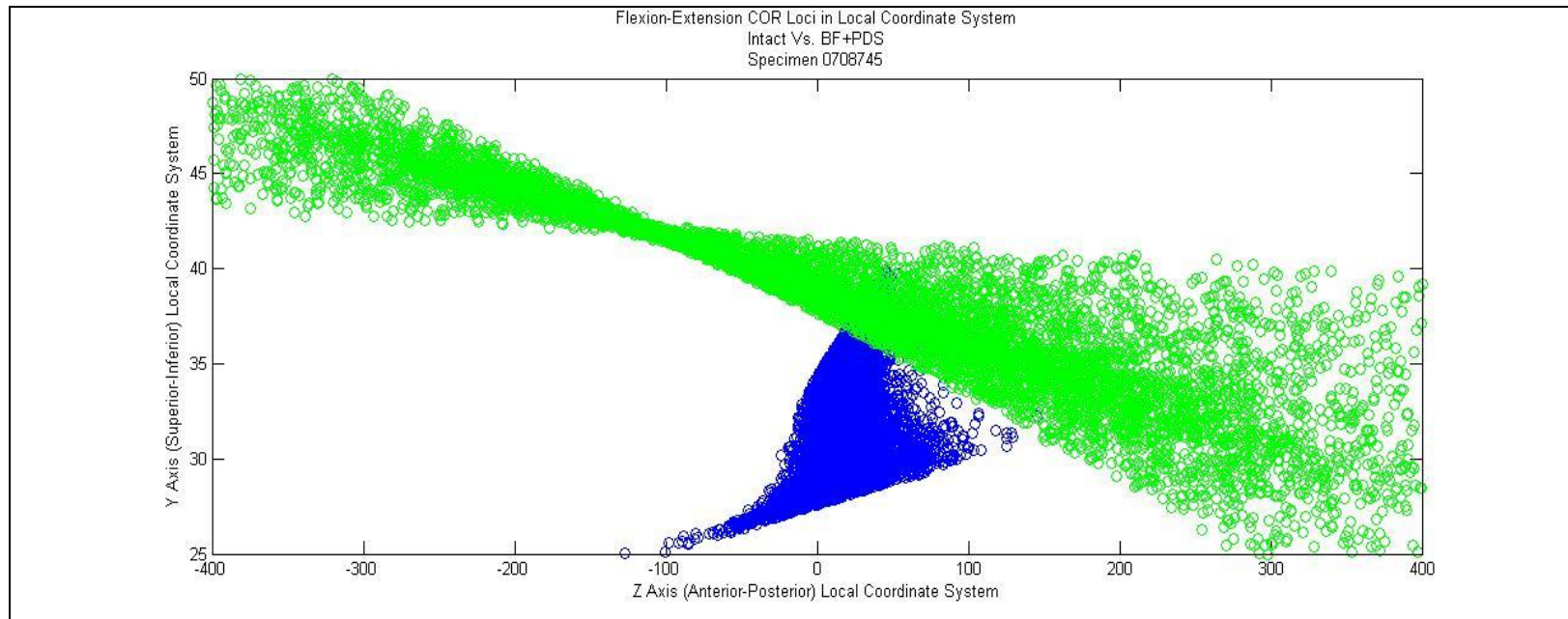


Figure 56. Comparative Flexion-Extension COR Loci in the Local Coordinate System for Intact and BF+PDS constructs

Figures 57, 58 and 59 depict the sagittal plane travel of the intact spine L4 and L5 rigid body origins and the COR with reference to those two bodies in the global coordinate system. L4 vertebral body [Figure 57] has an inferior-anterior (caudal-ventral) coupled motion in flexion and a superior-posterior (cephalad-dorsal) coupled motion in extension. The L5 vertebral body [Figure 58] on the other hand has an inferior-posterior (caudal-dorsal) movement in flexion and superior-anterior (cephalad-ventral) coupled motion in extension.

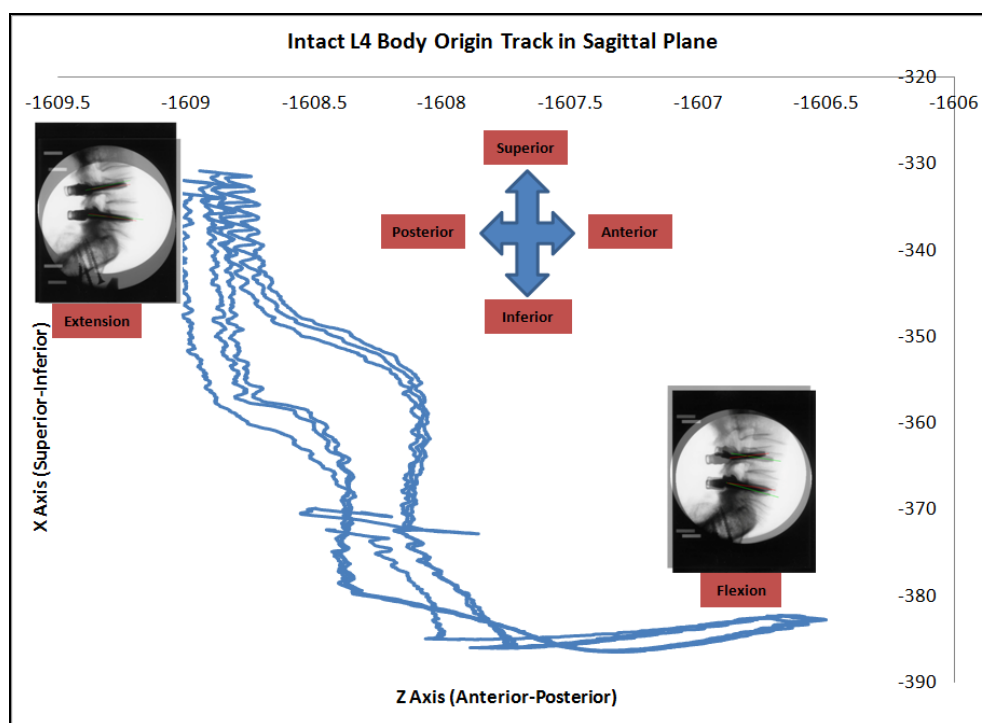


Figure 57. Sagittal plane displacement of Intact Spine L4 rigid body origin (local coordinate system) expressed in the global coordinate system.

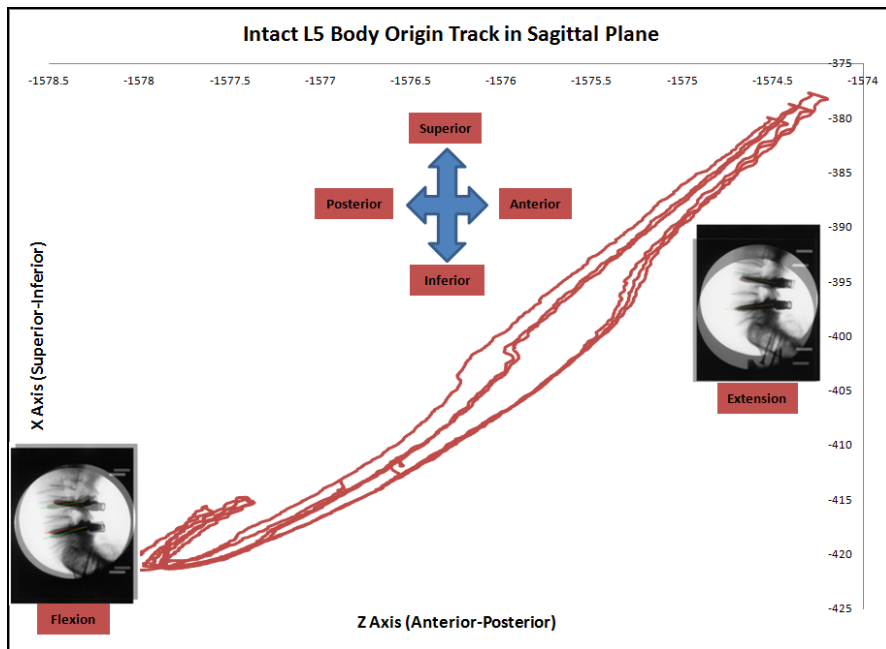


Figure 58. Sagittal plane displacement of Intact Spine L4 rigid body origin (local coordinate system) expressed in the global coordinate system.

The COR of L4-L5 joint [Figure 59] seemed to follow the L4 body pattern of inferior-anterior travel in flexion and superior-posterior travel in extension.

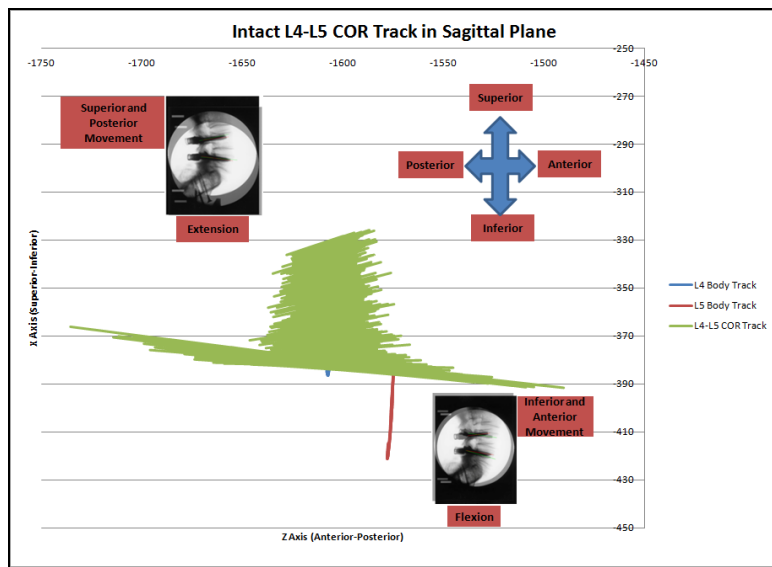


Figure 59. Sagittal plane displacement of the L4-L5 COR in comparison to L4 and L5 body displacements in the global coordinate system.

Figures 60, 61 and 62 depict the sagittal plane travel of the PDS implanted spine L4 and L5 rigid body origins and the COR with reference to those two bodies in the global coordinate system. L4 vertebral body [Figure 60] had an inferior-anterior (caudal-ventral) coupled motion in flexion similar to the intact spine however, its inferior direction motion was reduced compared to the anterior motion as the stiffness of the dynamic system got effected. In extension, the L4 body showed a superior-posterior (cephalad-dorsal) coupled motion in extension similar to the intact spine. The L5 vertebral body [Figure 61] on the other hand showed an inferior-posterior (caudal-dorsal) movement in flexion similar to intact however, the coupled motion was reduced as the stiffness of the dynamic system got effected. In extension [Figure 61], superior-anterior (cephalad-ventral) coupled motion was observed similar to intact.

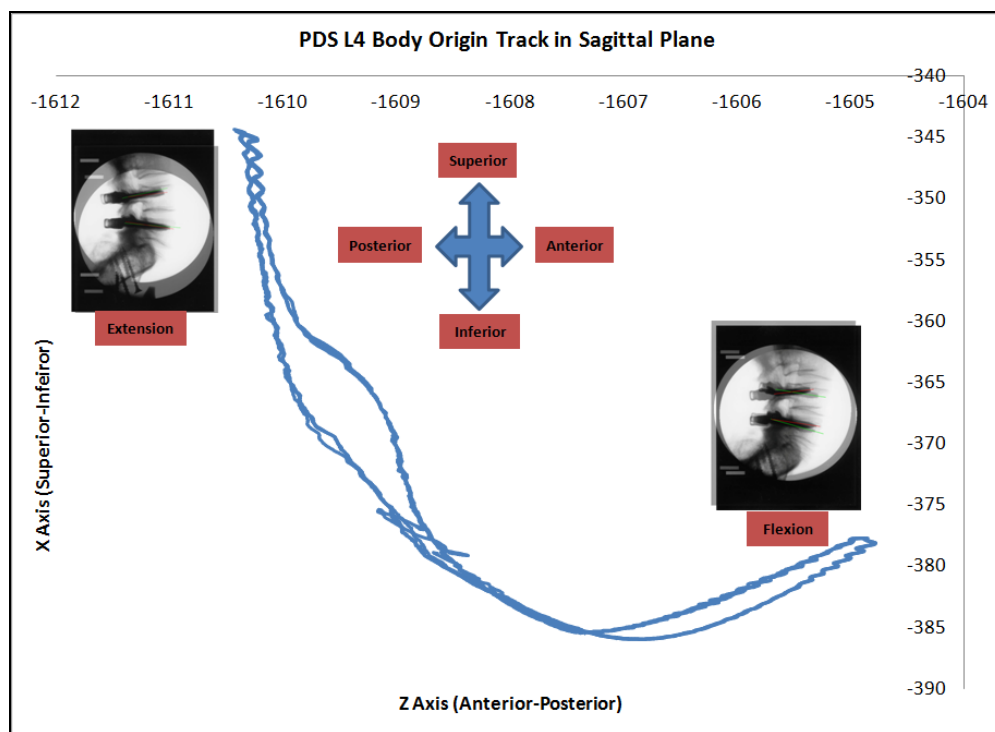


Figure 60. Sagittal plane displacement of L4 rigid body origin (local coordinate system) of a PDS implanted spine expressed in the global coordinate system

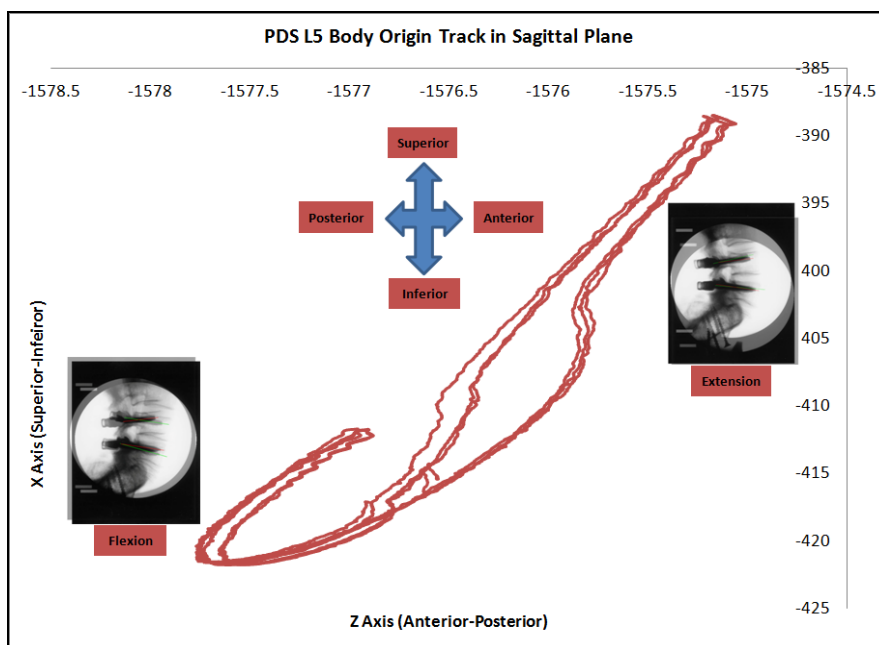


Figure 61. Sagittal plane displacement of L5 rigid body origin (local coordinate system) of a PDS implanted spine expressed in the global coordinate system

The COR of L4-L5 joint [Figure 62] seemed to follow the L4 body pattern of inferior-anterior travel in flexion and superior-posterior travel in extension.

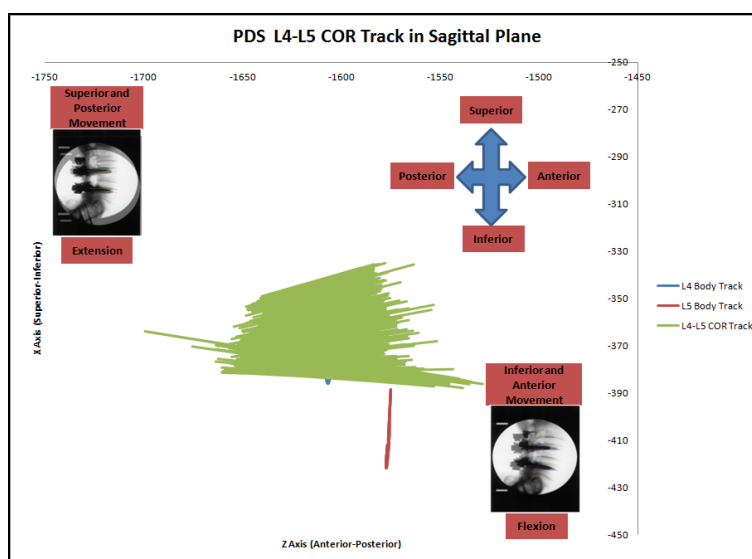


Figure 62. Sagittal plane displacement of L4-L5 COR post PDS implantation in comparison to L4 and L5 body displacements expressed in the global coordinates

### 3.3 Biomechanical Characterization of Posterior Dynamic Stabilization Adjacent to Rigid Fixation

The third specific aim involved biomechanical evaluation of a posterior dynamic stabilization system implanted adjacent to a single level rigid fixation in the lumbosacral spine. Bilateral facetectomy was chosen as the ‘*injury*’ or ‘*surgical decompression*’ model. The important aspects studied were:

- Effect of graduated stiffness fixation versus rigid fixation on Implanted and adjacent level kinematics
- Load sharing and intradiscal pressure at the implanted and adjacent level

#### 3.3.1 Implanted Level (L4-L5) Kinematics

The implanted level (L4-L5) was initially stabilized with both BPDS and Rigid rods to put into perspective the comparative stiffness of the two constructs. Comparisons of these implanted level constructs are presented in Table 2.

Table 2. Index level range of motion of dynamic and rigid stabilization with interbody device

	<i>Intact</i>	<i>BF</i>	<i>BF+S+BPDS</i>	<i>BF+S+R</i>
Flexion-Extension	8.8±2.7°	9.5±2.6°	3.5±1.4°	2.7±1.3°
Lateral Bending	7.1±1.8°	7.4±1.8°	3.8±2.1°	2.4±1.3°
Axial Rotation	3.4±1.6°	5.7±2.0°	4.3±2.2°	2.6±1.4°

Specifically, the reduction in motion during FE, LB, and AR, for BF+S+R resulted in motion which was 31%, 34%, and 77% of intact, and 28%, 32%, and 46% of injured. Likewise the reduction in motion during FE, LB, and AR, for BF+S+BPDS resulted in motion which was 40%, 54%, and 126% of intact, and 37%, 52%, and 75% of injured.

In flexion-extension [Fig.63] and lateral bending [Fig.64], BF led to very limited instability when compared to an intact motion segment (8% and 4% increase). After BF, L4-L5 demonstrated greater instability in axial rotation [168% ( $p<0.05$ ), Fig.65]. All treatment groups, involving rigid fixation of the L4-L5 segment, whether rigid or dynamic in nature (BF+S+R, BF+S+R+BPDS<sub>34</sub>), provided significantly more reduction in motion when compared to the injury (BF) and intact state in flexion-extension and lateral bending. Due to the pronounced effect of an injury in axial rotation, none of the treatment constructs produced a significant difference in motion with respect to the intact spine.

### 3.3.2 Adjacent Level (L3-L4, L5-S1) Kinematics

Increased motion due to the BF injury (especially in extension and axial rotation) is expected to lead to reduced motions at the immediate adjacent levels in a hybrid / displacement control protocol. The limited instability in flexion-extension and lateral bending led to insignificant reductions (FE: 3%, LB: 2% at L3-L4) and insignificant increases (FE: 3%, LB: 4% at L5-S1).



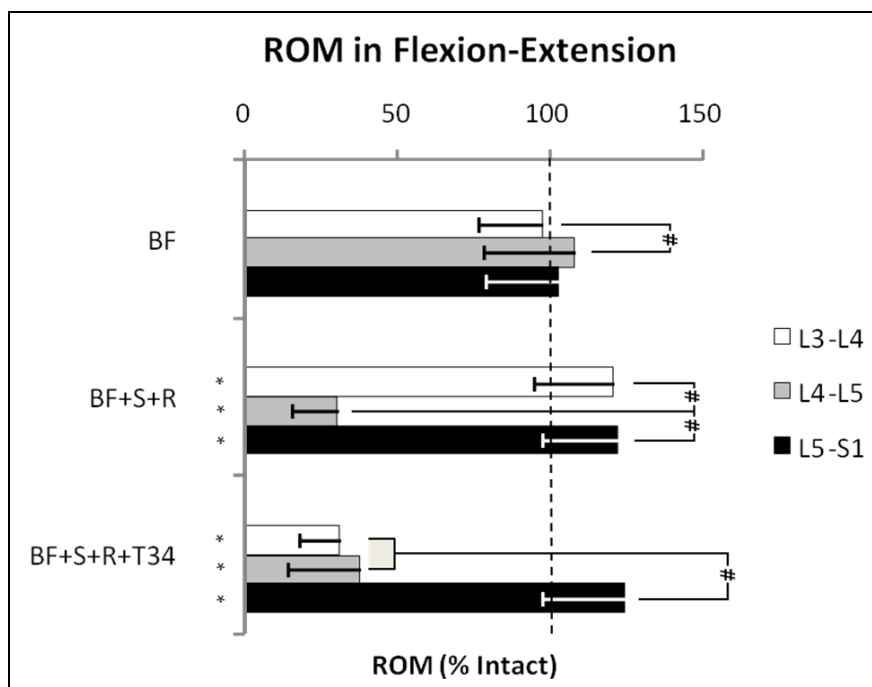


Figure 63: Range of motion in flexion-extension of index and adjacent levels as normalized to intact motion. Note:  $BF+S+R+T_{34} = BF+S+R+BPDS_{34}$

The use of the hybrid construct ( $BF+S+R+BPDS_{34}$ ) which includes the PDS device at L3-L4, resulted in stabilized and reduced motions with respect to the L3-L4 intact spine level, in all loading modes. This stability was quantified as 31%, 37%, and 83% of the intact spine in FE, LB, and AR, respectively. In contrast, the  $BF+S+R$  construct produced adjacent level hypermobile motion at L3-L4 in most loading modes, quantified as 121%, 109%, and 98% of the intact spine in FE, LB, and AR, respectively.

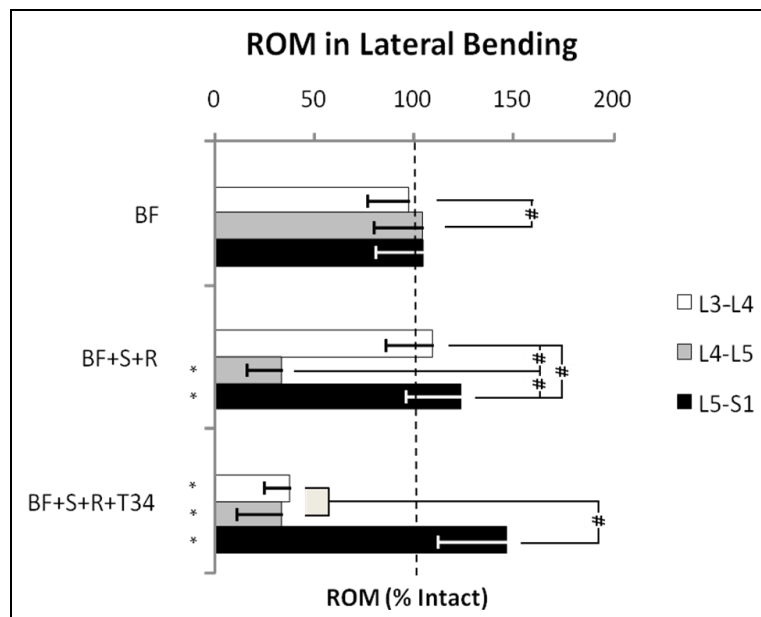


Figure 64: Range of motion in lateral bending of index and adjacent levels as normalized to intact motion. Note: BF+S+R+T<sub>34</sub> = BF+S+R+BPDS<sub>34</sub>

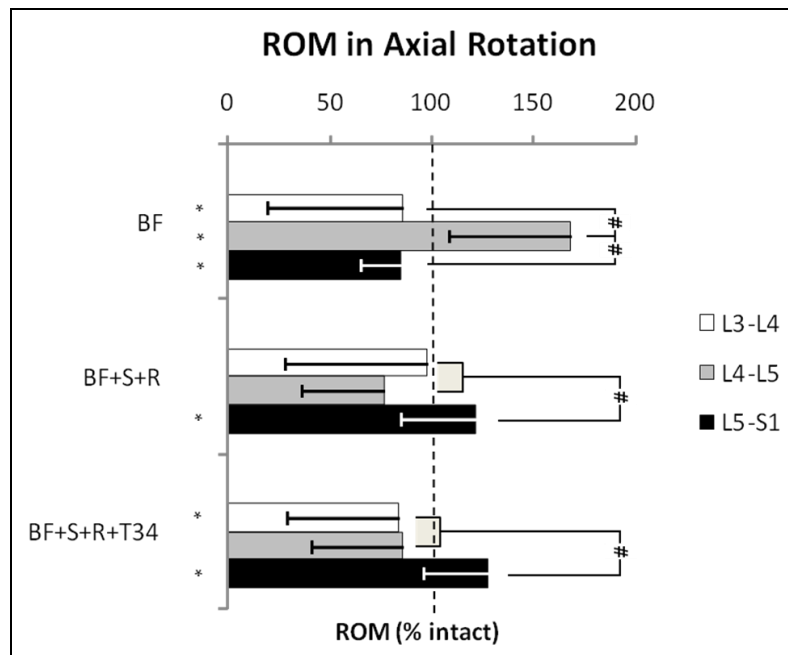


Figure 65: Range of motion in axial rotation of index and adjacent levels as normalized to intact motion. Note: BF+S+R+T<sub>34</sub> = BF+S+R+BPDS<sub>34</sub>

### 3.3.3 Load Sharing and Intradiscal Pressure

The adjacent level IDP was evaluated [Fig.66] and demonstrated very similar trends to ROM, meaning that reduced motion corresponded with reduced pressure. The rigidity of the BF+S+R construct led to high adjacent level pressures at L3-L4 of 147%, 125%, and 114% of intact, and 156%, 136%, and 144% of injury, in FE, LB, and AR, respectively. Statistically significant overloading with respect to injury and intact IDPs was only observed in flexion-extension. The additional dynamic component at L3-L4 of the BF+S+R+BPDS<sub>34</sub> construct resulted in anterior column pressures which were 84%, 30%, and 94% of intact, and 57%, 24%, and 82% of injury, in FE, LB, and AR, respectively.

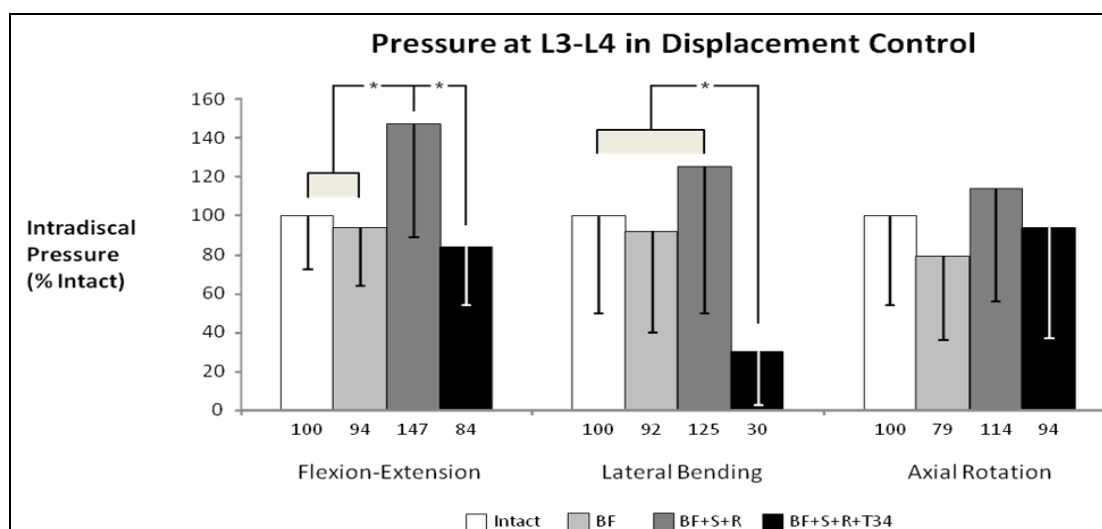


Figure 66: Intradiscal pressure for cranial adjacent level normalized with respect to intact pressure Note: BF+S+R+T<sub>34</sub> = BF+S+R+BPDS<sub>34</sub>

It was noteworthy that while the trends between ROM and IDP were similar, meaning that higher stability constructs demonstrated lower IDP, the relative magnitudes were not. This trend was evident only in flexion-extension. For example, the L3-L4

stability of the dynamic portion of BF+S+R+BPDS<sub>34</sub> was 31% of the intact motion, but the pressure was 84% of the intact pressure, indicating that the device restricted motion, but allowed anterior column load-sharing. In lateral bending and axial rotation, the motion-pressure relationship is more constant at 37%-30% and 83%-94% of intact.

### **3.4. Biomechanical Characterization of Posterolateral Disc**

#### **Arthroplasty in Conjunction with Posterior Tethering**

The fourth specific aim [Protocol 4A] of this study involved evaluation of the biomechanical characteristics of a PLDA stabilized by an adjunctive PDS system [Fig.67]. The *injury* or *surgical decompression* model chosen was unilateral facetectomy. The important aspects studied were:

- Effect of indicated spine surgery on the native spine kinematics: Unilateral Facetectomy Model
- Effect of posterior tethering of a PLDA system simulating Unilateral Posterior Joint Replacement – Implanted (L4-L5) and adjacent level (L3-L4, L5-S1) kinematics: Unilateral Facetectomy Model
- Effect of indicated spine surgery on the native spine kinematics: Bilateral Facetectomy Model
- Effect of posterior tethering of a PLDA system simulating Total Joint Replacement – Implanted (L4-L5) and adjacent level (L3-L4, L5-S1) kinematics: Bilateral Facetectomy Model

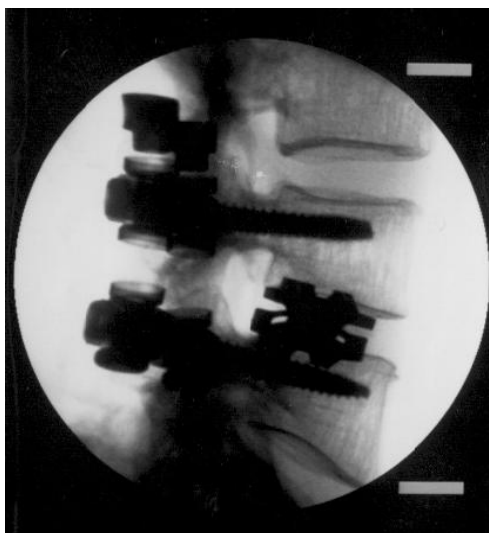


Figure 67. Posterior tethering of a PLDA implanted motion segment

### 3.4.1 Unilateral Facetectomy Model

#### 3.4.1.1 Flexion-Extension Kinematics

Unilateral facetectomy and PLDA did not cause a significant change (107% & 96%) in Flexion-Extension ROM [Fig.68] at the implanted level. Unilateral PDS and Bilateral PDS reduced the implanted level ROM significantly ( $p < 0.05$ ) to 55% and 39% respectively. This decrease in the implanted level ROM led to a trend towards increase in superior and inferior adjacent level ROM for both PLDA + UPDS (114% and 112%) and PLDA + BPDS (117% and 113%), however they were not statistically significant.

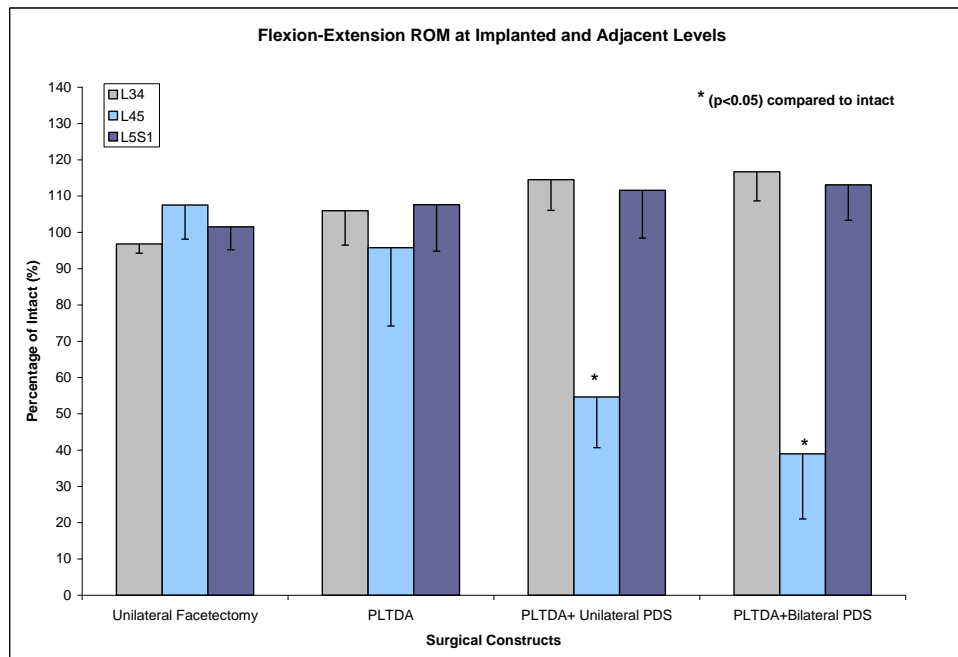


Figure 68. Flexion Extension ROM at implanted (L4-L5) and adjacent (L3-L4 and L5-S1) levels Normalized to intact motion

#### 3.4.1.2 Lateral Bending Kinematics

In lateral bending [Fig.69], unilateral facetectomy increased the implanted level ROM to 106% ( $p > 0.05$ ) while the PLDA system increased the ROM significantly to 118%. This increased ROM was stabilized by unilateral and bilateral posterior tethering to 64% ( $p > 0.05$ ) and 50% ( $p < 0.05$ ) respectively. The reduction in implanted level ROM due to BPDS exhibited an increasing trend in ROM at the adjacent levels L3-L4 (110%) and L5-S1 (115%), but it was not significant.

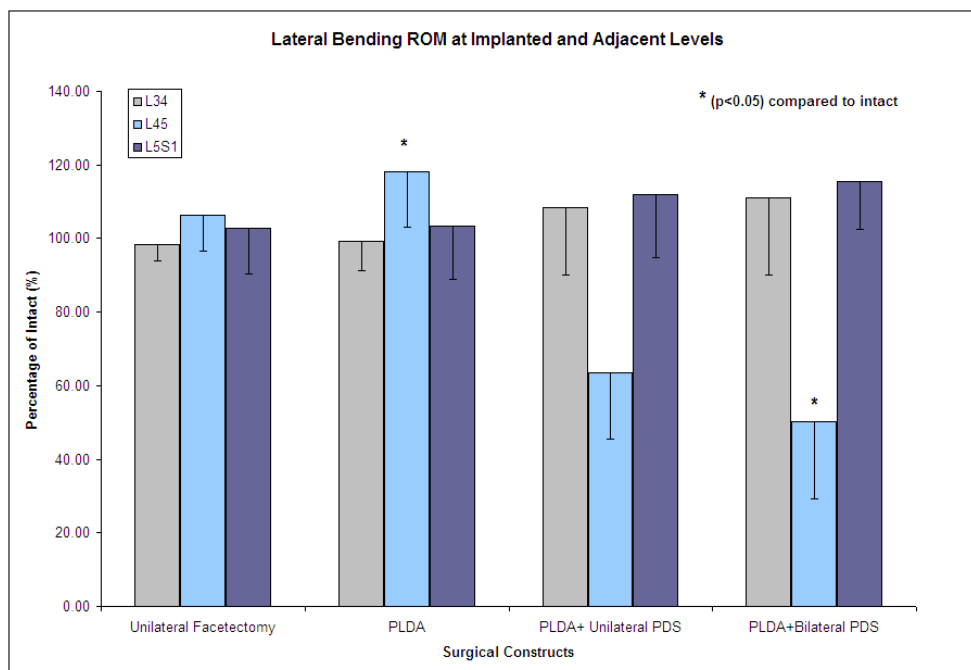


Figure 69. Lateral Bending ROM at implanted (L4-L5) and adjacent (L3-L4 and L5-S1) levels Normalized to intact motion

### 3.4.1.3 Axial Rotation Kinematics

In axial rotation [Fig.70], unilateral facetectomy increased the implanted level ROM significantly to 121% with no significant reduction in the adjacent level ROM. PLDA implantation also maintained the ROM at 120% ( $p < 0.05$ ) without any significant alteration at L3-L4 and L5-S1. Unilateral and bilateral PDS were able to bring back the increased ROM to less than intact (94% and 80%;  $p > 0.05$ ). There was no significant change observed in ROM at the superior and inferior adjacent levels.

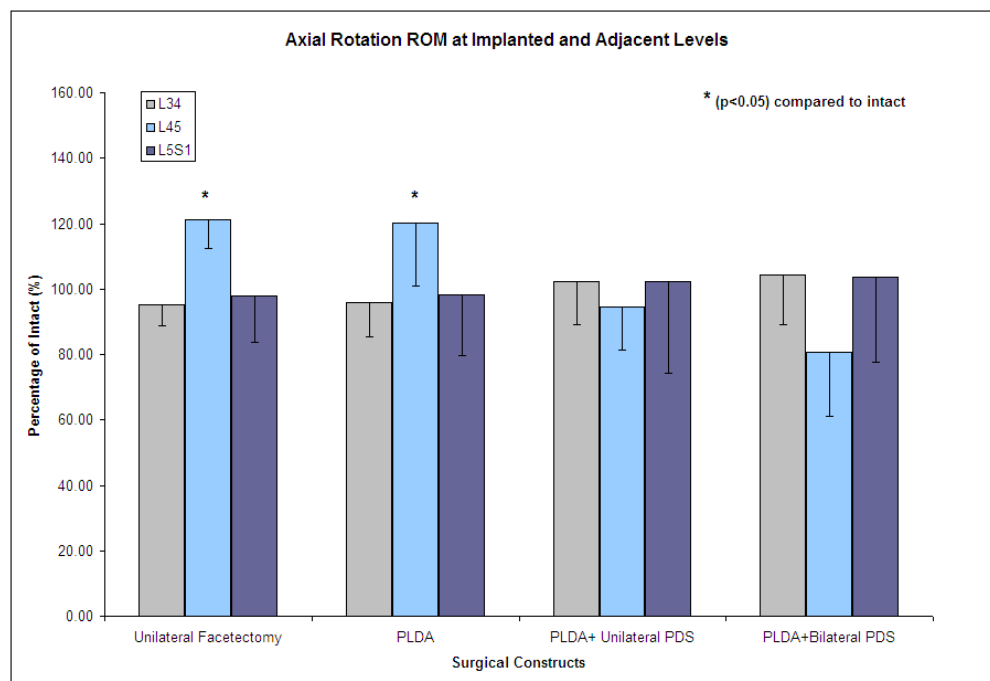


Figure 70. Axial Rotation ROM at implanted (L4-L5) and adjacent (L3-L4 and L5-S1 l) levels Normalized to intact motion

### 3.4.2 Bilateral Facetectomy Model

#### 3.4.2.1 Flexion Extension Kinematics

Bilateral facetectomy and PLDA did not cause a significant change (107% & 101%) in Flexion-Extension ROM [Fig.71] at the implanted level. Bilateral PDS reduced the implanted level ROM significantly ( $p<0.05$ ) to 36%. This decrease in the implanted level ROM led to a trend towards increase in superior and inferior adjacent level ROM for PLDA + PDS (111% and 122%), however they were not statistically significant.



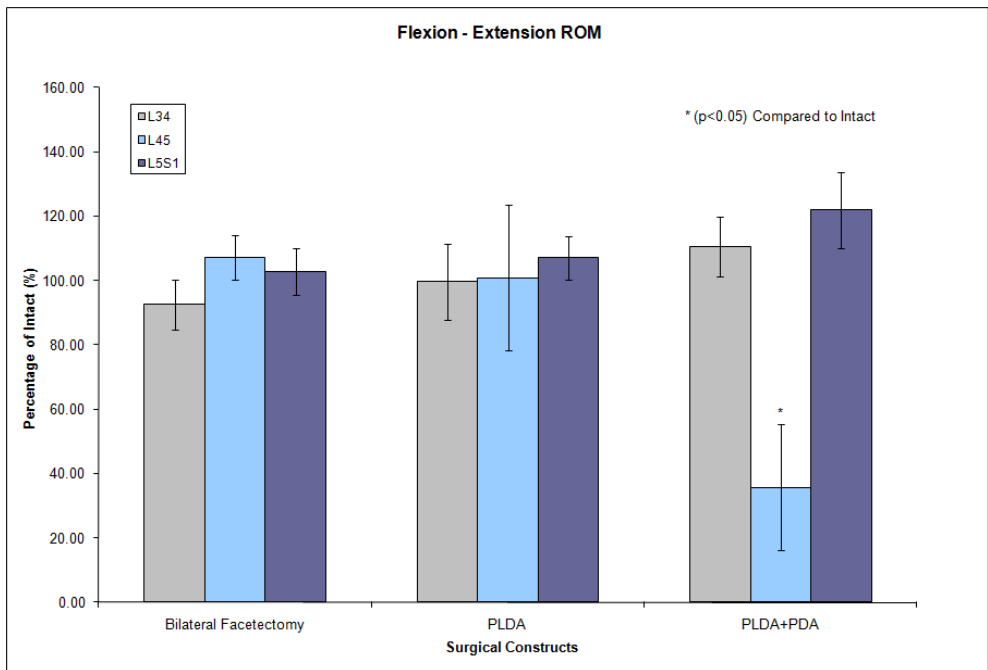


Figure 71: Flexion Extension ROM at implanted (L4-L5) and adjacent (L3-L4 and L5-S1) levels Normalized to intact motion

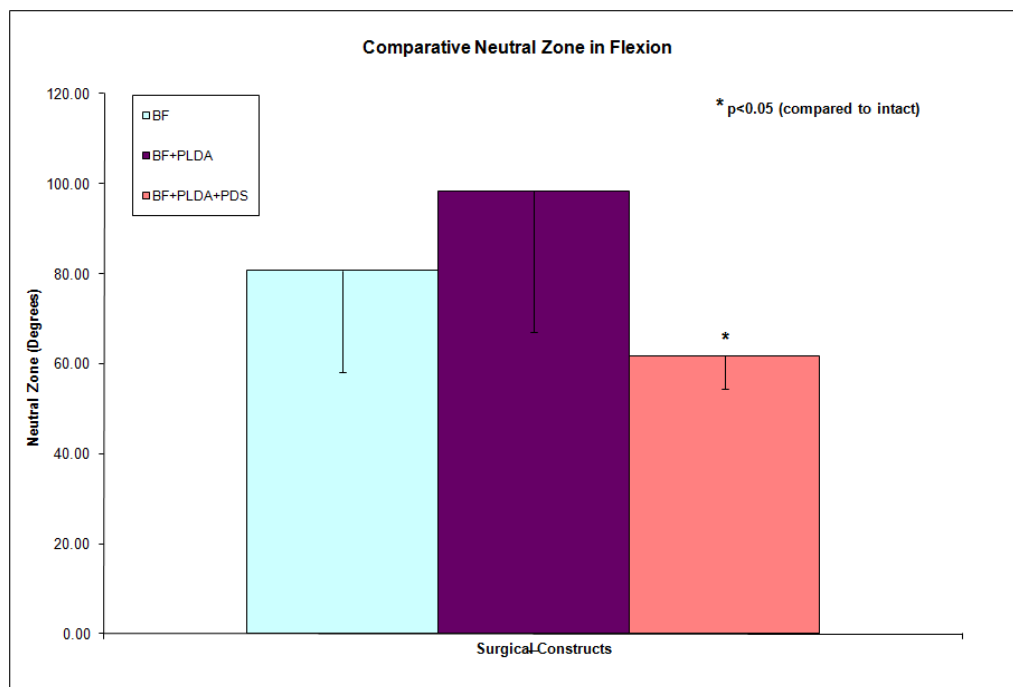


Figure 72. Comparative Flexion NZ post surgical intervention for the *Bilateral Model*

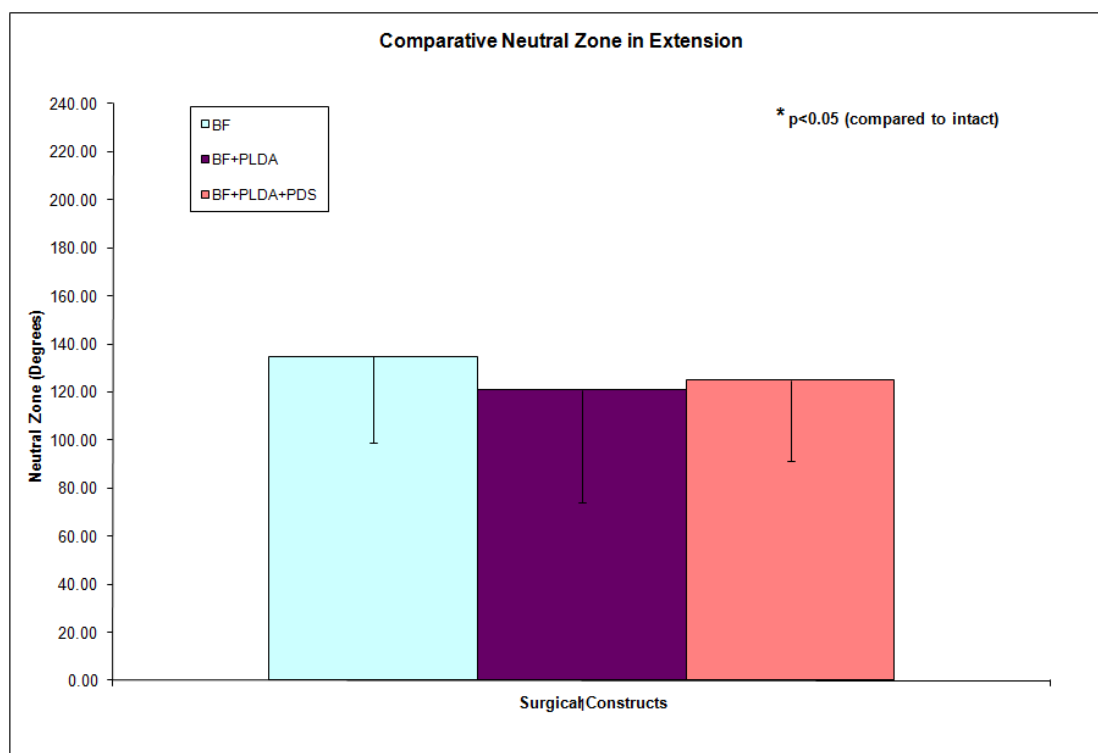


Figure 73. Comparative Extension NZ post surgical intervention for the *Bilateral Model*

### 3.4.2.2 Lateral Bending Kinematics

Bilateral facetectomy and PLDA did not cause a significant change (104% & 95%) in Lateral Bending ROM [Fig. 74] at the implanted level. Bilateral PDS reduced the implanted level ROM significantly ( $p < 0.05$ ) to 38%. The decrease in the implanted level led to a trend towards increase in superior and inferior adjacent level ROM for PLDA+ PDS (104% and 124%), however they are not statistically significant.

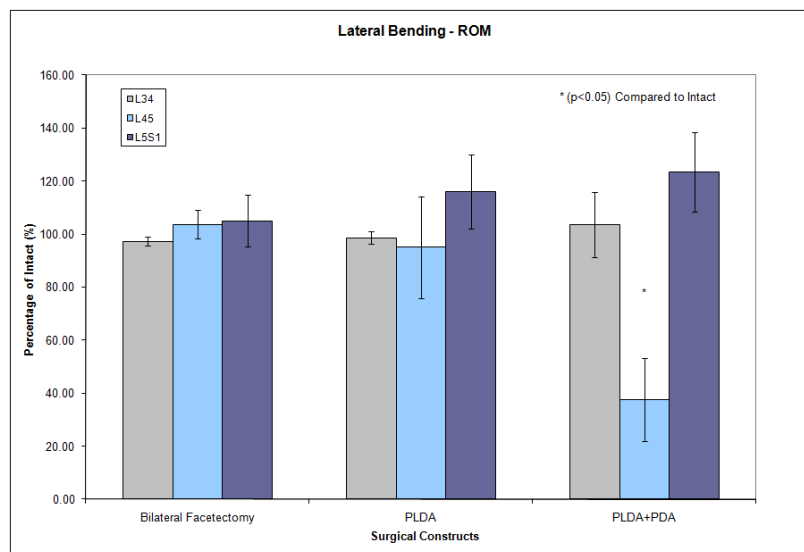


Figure 74: Lateral Bending ROM at implanted and adjacent levels

### 3.4.2.3 Axial Rotation Kinematics

Bilateral facetectomy and PLDA increased axial rotation ROM significantly ( $p < 0.05$ ) to 175% and 182% respectively [Fig. 75] at the implanted level. PDS stabilized the implanted level compared to bilateral facetectomy to 110% of intact.

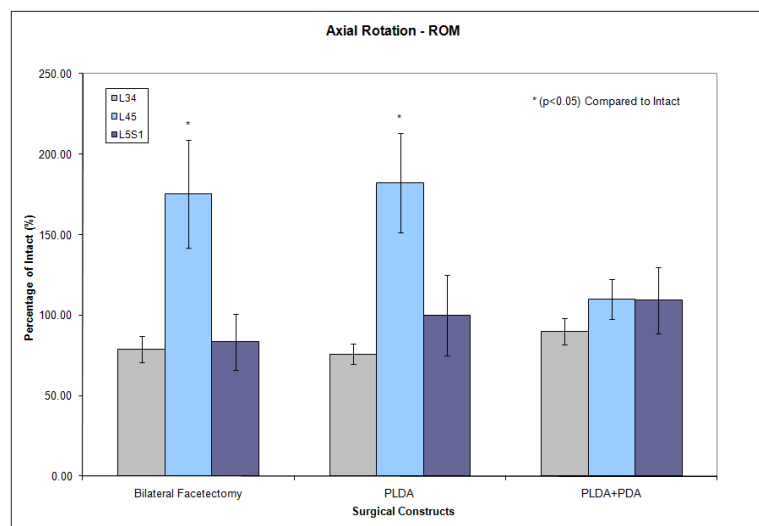


Figure 75: Axial Rotation ROM at implanted and adjacent levels

## CHAPTER 4

### DISCUSSION

The cause and best treatment option for mechanical low back pain due to disc degeneration remains unsolved. The conventional continuum of spine care [Fig. 76] involves a mild to severe approach ranging from conservative care to decompression procedures such as annulotomy, discectomy, laminectomy and laminoplasty to spinal fusion.

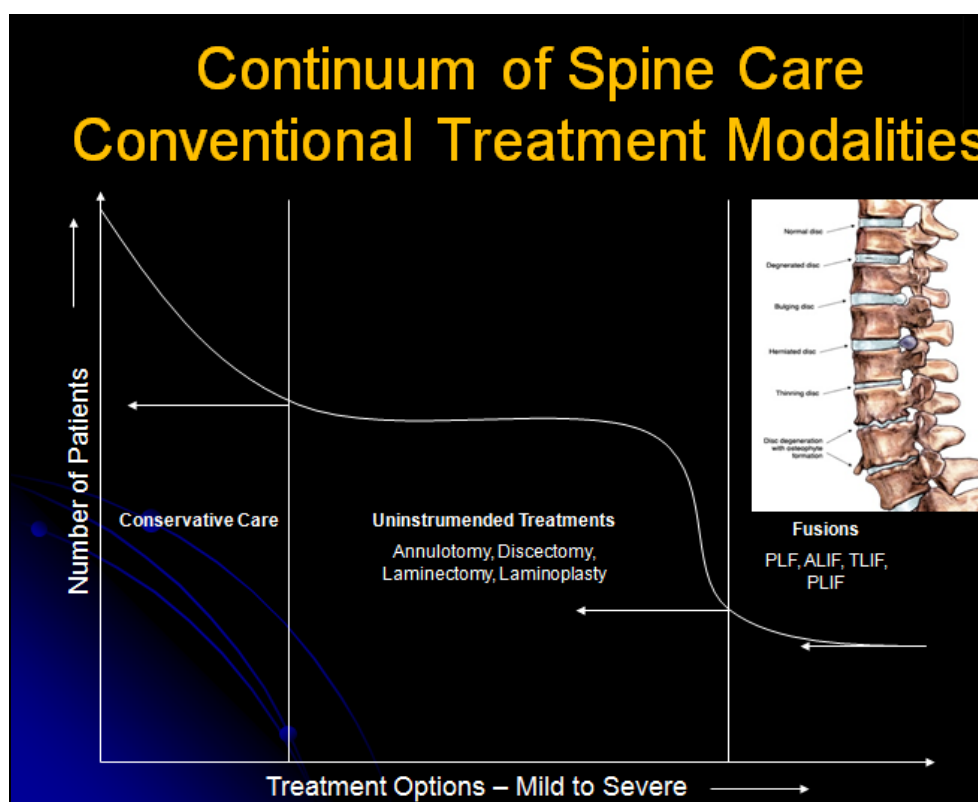


Figure 76: Continuum of Spine Care: Conventional Treatment Modalities range from a mild to severe approach. Conservative care to decompression procedures to spinal fusions

'*Spinal fusion*' for degenerative disc related back pain has been the gold standard for surgical treatment, post conservative care, for a very long time. However, spinal fusion has potential drawbacks such as:

- Bone graft donor site pain, pseudoarthrosis, spinal stenosis, failure of instrumentation, muscle atrophy [27-32],
- Clinical studies have documented altered kinematics, facet and disc degeneration and spinal stenosis at the adjacent motion segments [33-38],
- Biomechanical studies have documented higher intradiscal pressures and motion at the levels above rigid instrumentation [33-38],
- A review of 271 articles found a 12-18% incidence of symptomatic adjacent segment degeneration [39],
- Multilevel fusion constructs have been shown to be correlated to higher incidences of up to 11% of screw breakage and loosening as well as 12-18% adjacent segment degeneration [69-76],
- Higher fusion rates with fusion did not correlate well with patient outcome measures [40].

Also, disc degeneration is not an All or None Phenomenon, but is progressive in nature and can be classified into different grades of degeneration. Different classification methods have been used for classifying grades of disc degeneration. Pfirrmann et al. 2001 [98] proposed a MRI classification for disc degeneration, which is based on the intensity of the nucleus, distinction between the nucleus and the annulus and disc height [Fig. 77]. An 8 level modified Pfirrmann Classification has also been proposed subsequently for discriminating the severity of disc degeneration in elderly patients [99].

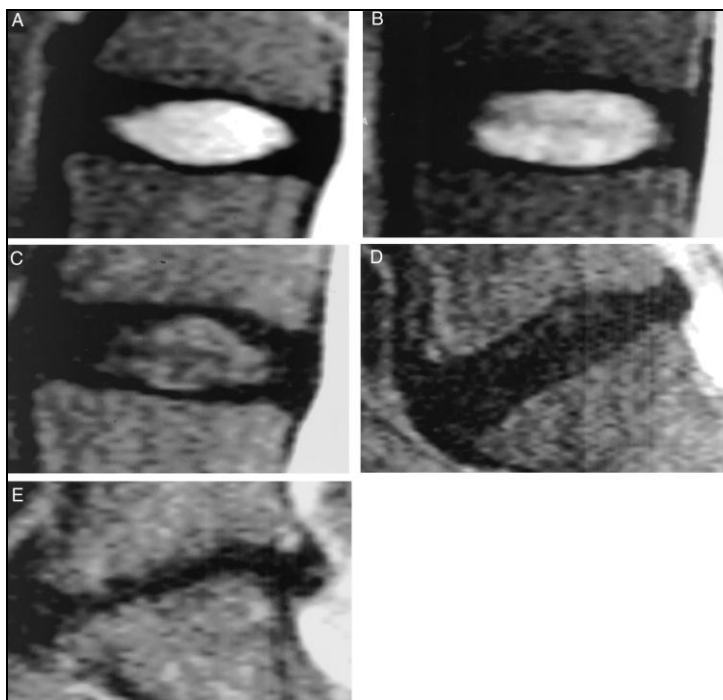


Figure 77: Grades A-E for the assessment of lumbar disc degeneration [98]

Grade I: The structure of the disc is homogeneous, with a bright hyperintense white signal intensity and a normal disc height. Grade II: The structure of the disc is inhomogeneous, with a hyperintense white signal. Also, the distinction between nucleus and anulus is clear, and the disc height is normal, with or without horizontal gray bands. Grade III: The structure of the disc is inhomogeneous, with an intermediate gray signal intensity. The distinction between nucleus and anulus is unclear, and the disc height is normal or slightly decreased. Grade IV: The structure of the disc is inhomogeneous, with an hypointense dark gray signal intensity and the distinction between nucleus and anulus is lost, and the disc height is normal or moderately decreased. Grade V: The structure of the disc is inhomogeneous, with a hypointense black signal intensity. The distinction between nucleus and anulus is lost, and the disc space is collapsed. Grading is performed in T2-weighted midsagittal (repetition time 5000 msec/echo time 130 msec) fast spin-echo images [98].

The disadvantages of spinal fusion as well as the graduated nature of disc degeneration and consequently back pain, has led to a gradual shift in philosophy from a ‘one size fits all’, i.e. spinal fusion for all patients with symptomatic low back pain to a ‘customized approach’, i.e. patient and indication specific treatment modality for spine care. The change in philosophy has also been supported by the continuous evolution in the understanding of normal and symptomatic spine biomechanics, biology and mechanobiology in conjunction with the advancements in material sciences, and tissue engineering. This gradual shift in the continuum of spine care has laid the ground for

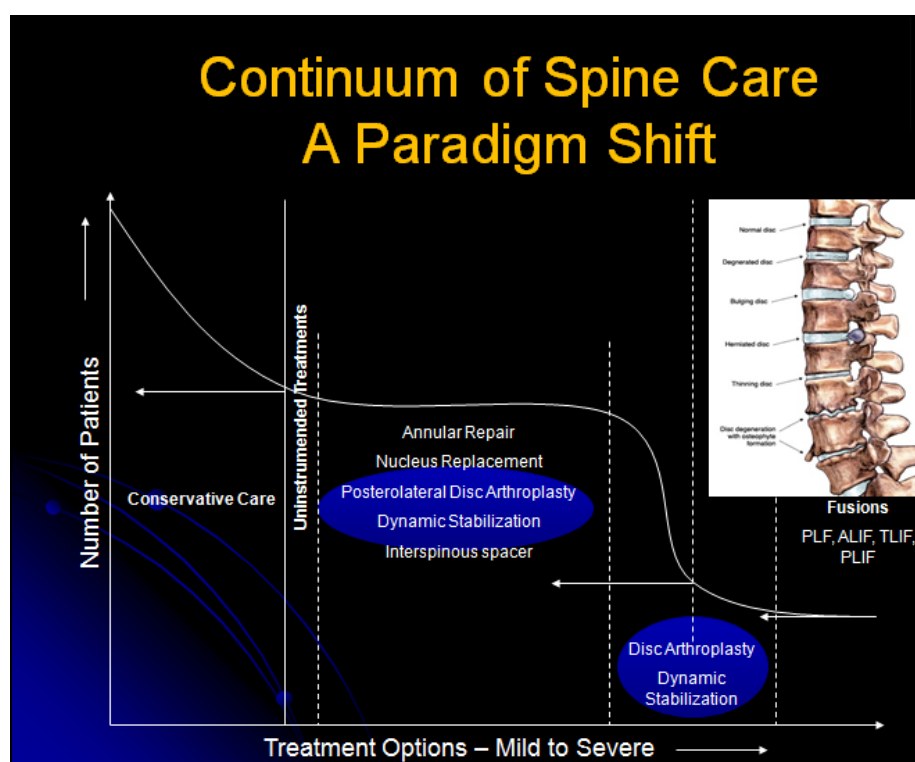


Figure 78: Paradigm Shift in the Continuum of Spine Care. Dynamic Stabilization and Disc Arthroplasty have gained ground between uninstrumented treatment and instrumented spinal fusion.

concepts of ‘motion preservation’ and ‘dynamic stabilization’ [Fig. 78], the former being an established treatment modality in orthopedics for a long time. The aim of the current

thesis was to perform a comprehensive scientific investigation to understand, evaluate and establish the *in vitro* biomechanical characteristics and performance of indication specific treatment modalities incorporating the concept of Posterolateral Disc Arthroplasty and Posterior Dynamic Stabilization for the treatment of symptomatic mechanical back pain. The results of this comprehensive study may help the clinicians to make an informed decision while selecting and designing a treating modality for their patients. To this end, the current thesis was undertaken and the study designed to fulfill 4 specific aims:

1. Biomechanical characterization of Posterolateral Disc Arthroplasty in the human lumbosacral spine
2. Biomechanical characterization of Posterior Dynamic Stabilization in the human lumbosacral spine
3. Biomechanical characterization of Posterior Dynamic Stabilization adjacent to rigid fixation in the human lumbosacral spine
4. Biomechanical characterization of Posterolateral Disc Arthroplasty in conjunction with posterior tethering in the human lumbosacral spine

#### **4.1 Biomechanical characterization of Posterolateral Disc Arthroplasty in the human lumbosacral spine**

Lumbar Disc Arthroplasty has been developed as an alternative to lumbar arthrodesis for the treatment of discogenic low back pain [41-44]. The potential benefits of disc arthroplasty over lumbar arthrodesis are removal of the primary pain generator



while restoring spinal motion, allowing an early return to function and consequently avoiding long term adjacent level degeneration [41-44]. To achieve these benefits, anterior disc arthroplasty systems have been developed and are being used for select indications; however, anterior disc arthroplasty has its disadvantages, primarily due to risk of vascular injury, retrograde ejaculation or ureteral injury associated with the surgical approach [45-49]. In addition to the surgical morbidity, biomechanically, segmental instability may be induced with the partial or complete removal of the anterior annulus and anterior longitudinal ligament [50]. In addition to the surgical and biomechanical challenges, anterior disc arthroplasty is contraindicated for neural and facet pain caused by central or lateral recess stenosis, and facet arthrosis [51-53].

In the light of these observations in patients who seek treatment for low back pain, and are contraindicated for disc arthroplasty due to approach related deficiencies and contraindications, alternative approaches to disc arthroplasty are currently being explored and developed. The concept of Posterior or Posterolateral disc arthroplasty is currently gaining ground in the spine community [56]. However, anatomical constraints and the extent of pathology may dictate the implant design and required decompression. Decompression due to a partial or total facetectomy in conjunction with a disc arthroplasty device as well as improper positioning of the device may increase segmental instability. Implant design on the other hand may affect the subsidence characteristics of the device. To this end, Specific Aim 1 of this thesis was designed to conduct a comprehensive biomechanical evaluation of a Posterolateral Disc Arthroplasty (PLDA) system and to study the effects of surgical technique and device placement on segmental kinematics and kinetics.

In flexion, there was no statistically significant difference in ROM among the 4 treatment groups. Posterior sagittal offset and midline placement of the PLDA device maintained the ROM at the implanted and both superior and inferior adjacent levels similar to intact. Anterior placement of the PLDA device showed a trend towards reduction in implanted level ROM to 88% of intact, though it was not statistically significant. This reduced ROM suggests a resistance to applied mechanical effort towards achieving the intact ROM which is the goal of a hybrid displacement control testing protocol. The reduction in ROM may be due to an anterior offset of the COR of the ball and socket type disc replacement device which may have caused an increased AP force normal to the facet joint capsule resulting in increased frictional resistance to the facet joint motion.

Comparative NZ analysis in flexion showed an increasing trend after implantation of the device (Unilateral Facetectomy, 102 < Posterior, 127% < Center, 140%) compared to intact, the differences were however not statistically significant. The increasing trend in NZ with implantation of the PLDA device compared to intact as well as unilateral facetectomy may suggest that the 3 dimensional stiffness of the intervertebral disc soft tissue effects the Neutral Zone kinematics more than the facet capsule and capsular ligaments. The transforaminal discectomy conducted to implant the ball and socket type PLDA device may have reduced the stability offered by the native disc in the neutral zone. On the contrary, the reduction in NZ with the anterior sagittal offset of the PLDA device compared to the posterior offset and midline placement (though not significant) may be related to the overall resistance to total ROM demonstrated by the anterior placement.

In extension [Fig.18], there was no statistically significant difference in ROM among the 4 treatment groups and in comparison to intact. The 4 treatment groups however did show a trend towards increase in ROM at the implanted level compared to intact. The trend increased from anterior sagittal offset to posterior sagittal offset (UF: 110%; Posterior sagittal offset: 112%; Midline: 106%; Anterior sagittal offset: 105%). The facets play an important role in limiting sagittal plane translation as well as providing stability and limiting extension. The increase in ROM may be due to the unilateral facetectomy. Spinal ROM being a combination of rotation and translation components, excision of any of the structural components of the spinal functional unit is going to affect the resulting function to the some extent. Even if the translatory component of motion is affected, the total ROM being a vector combination will reflect the component change

Comparative NZ [Fig.19] analysis in extension showed an increasing trend after implantation of the device (Unilateral Facetectomy, 101 < Posterior, 121% < Center, 121% < Anterior, 124%) compared to intact, the differences were however not statistically significant. The increase in NZ is similar to that observed in flexion indicating the reduced resistance due to transforaminal discectomy.

In lateral bending, unilateral facetectomy did not show any change in implanted and adjacent level ROM compared to intact. The PLDA treatment groups did show a statistically significant increase in implanted level ROM compared to intact. This increase in ROM may have been due to the unilateral facetectomy and more due to the transforaminal discectomy required for PLDA implantation. (120%, 118% and 115%). There was a corresponding decrease in superior and inferior adjacent level ROM which

was due to the compensatory effects of segmental ROM seen in hybrid displacement control setups. Similar to the ROM, the NZ for all 4 treatment groups increased compared to the intact spine (Unilateral Facetectomy, 106 < Posterior, 110% < Center, 112% < Anterior, 116%) though it was not statistically significant.

In axial rotation, all 4 treatment groups showed a statistically significant increase in ROM at the implanted level (Unilateral facetectomy 123%; Posterior offset 130%; Midline 125% and Anterior offset 123%) compared to intact. These results are in line with the conclusions by Shirazi et al. 1986 [100] that the facet joints along with the anterior annulus are the primary resistors to axial torsion. Shirazi also concluded that at moment loads less than 20 Nm, the anterior column of the spine resists axial torsion more compared to the facet joints. The observations from our study in comparison to the data in the literature are extremely critical since it validates and establishes the stability of a Posterolateral disc Arthroplasty in comparison to an anterior disc Arthroplasty system. A single level biomechanical study conducted on the Charite disc by Cunningham et al. 2006 [50] demonstrated that anterior discectomy for disc replacement increased the axial rotation ROM to 210% while implantation of the Charite disc increased the axial rotation ROM to 160%. In the same study, the rotational instability of the spine increased to 250% when an additional anterior disc was implanted through the anterior approach at the adjacent level. In comparison to the anterior disc replacement results in the literature, the Posterolateral disc replacement involving a transforaminal discectomy along with a unilateral facetectomy provides a stable construct in axial rotation.

Similar to flexion-extension and lateral bending, axial rotation too showed an increase in NZ with the posterior disc implantation compared to intact and unilateral

facetectomy, though it was not statistically significant. The increase in Neutral Zone in all planes of spinal motion highlights an important fact that the nucleus pulposus plays an important role in the Neutral Zone kinematics. This is corroborated by Cannella et al. 2008 [101] in an in vitro biomechanical study where they studied the effect of progressive denucleation on the mechanics of the human lumbar intervertebral disc in axial compression, lateral bending, flexion-extension and axial rotation. The study concluded that the contribution of the nucleus pulposus to the mechanical behavior of the disc was more prominent in the Neutral Zone than at the farther limits of applied loads and moments.

Spinal motion segment being a 3 joint complex, the motion occurs in three dimensional space and is coupled in nature. Analysis of the coupled motion occurring concurrently with the dominant range of motion is extremely important for an accurate representation of spinal kinematics. Coupled sagittal plane translation in flexion decreased with the implantation of the PLDA device. The decrease was statistically significantly with the anterior sagittal offset positioning. The maintenance of sagittal plane translation with unilateral facetectomy similar to intact but a trend towards reduced value with the PLDA device suggests that sagittal translation in flexion is a function of the intervertebral disc and less of the facet. Implantation of the metal on metal ball and socket type of Disc Arthroplasty device increased the resistance to AP sagittal translation compared to the native disc. Anterior placement of the PLDA device affected this further in conjunction with the reduced ROM observed with the same. On the contrary, in extension the results were exactly opposite with an increase in sagittal plane translation for all 4 treatment groups compared to intact, though it was not statistically significant.

These results may have a bearing that in extension, sagittal plane translation is more an effect of the facet joints than that of the intervertebral disc. The posterior sagittal offset position seems to have aided the motion of the joint since the COR of the device was close to the facet joint and may not have caused any undue resistance to facet motion.

Mechanical effort is defined as the moment loads required to achieve the target Range of Motion. The mechanical effort is an important indication of the muscle effort that may be required to facilitate spinal motion. In flexion the moment loads showed an increasing trend from posterior to anterior sagittal offset position, though it was not statistically significant. This increased mechanical effort indicates that the anterior positioning of the PLDA device contradicts the effortless motion of the spine. It seems as if the anterior position fights the guided motion provided by the facet joint. This is also evident with the decrease in ROM observed with anterior positioning. On the contrary, in extension, the moment loads showed a decreasing trend for all 4 treatment groups with the anterior sagittal offset being statistically significant. The decrease in mechanical effort may be due to the facetectomy, since facets play an important role in stabilizing extension. The reduced resistance to motion in the neutral zone as is reflected by the increased NZ with disc implantation may also have contributed to the reduced mechanical effort.

Center of rotation was calculated using rigid body kinematics i.e. each of the motion segments was considered to be formed of two rigid bodies representing the vertebrae. The output of the motion analysis system was in the form of global coordinates of the markers attached to each of these vertebrae or rigid bodies. The 3 marker frame system attached to each of the vertebral bodies was defined as a local coordinate system

with the middle marker as origin. Transformation matrices and vector algebra methods [Appendix B] were used to determine the center of rotation in the global coordinate system between consecutive frames as the spine moved in 3D space. A locus of the COR was then plotted based on the coordinates of the instantaneous COR. The COR locus was plotted for Intact, UF, UF+PLDA-P, UF+PLDA, and UF+PLDA-A constructs. Flexion extension being the predominant motion, COR locus was plotted for the same. In general, COR for the intact spine moved anteriorly and inferiorly in flexion, while it moved superior and posterior in extension. In a clinical study on centrod patterns in the lumbar spine in normal subjects [92], Ogston et al. showed that the centrod moved from posterior to anterior and back to posterior as the spine moved from extension to flexion. Similarly, Wachowski et al. 2009 [107] showed that the instantaneous helical axis (IHA) migrated ventrally in flexion and dorsally in extension. In terms of length, the COR locus varied from 100mm to 200mm in the superior-inferior direction and 60mm to 150mm in the anterior-posterior direction. In the Ogston study, the centrod length was an average of ~44 mm [15.2-81.4mm] in the anterior-posterior direction, while in the Wachowski study it was ~ 30 mm. The difference in locus or centrod length may be due to the differences in cadaveric specimens used in the current study and the Wachowski study and also in the levels studies i.e. L4-L5 (current study) versus L3-L4. Irregularities in tissue properties are also known to cause changes in the COR locus [92, 107]. Also, in the Wachowski study, an axial compressive preload of 200N had been applied to the cadavers, and the moment loads were 6Nm compared to the current study which utilized 8Nm of pure moment loads. The Ogston study was different in that it was a clinical study in which flexion-extension radiographs of 12 patients were taken to track the centrod

pattern. Also, in both studies in the literature only a few points were taken into account for generating the locus whereas in the current study a few thousand points were taken into consideration as the data was recorded at 0.5Hz. Despite the differences in specimens, test setup, loading modes and data points the nature of the COR locus was similar in all three studies.

Unilateral facetectomy at the index level diffused the COR locus though following a similar trend. Posterior, Midline, and Anterior sagittal offset placement of the disc arthroplasty system showed a more concentrated locus of the COR compared to the intact and unilateral facetectomy constructs. Also, in some cases, the span of the COR locus increased dramatically compared to the intact. The COR locus did show some displacement with varied placement of the PLDA device at different sagittal offsets, however it was not quantifiable so as to make a tangible conclusion.

These observations clearly shows the importance of the spinal structures in maintaining the quality of motion or COR locus. This also highlights an important observation that ROM and NZ parameters alone may not be able to shed light on spinal kinematics post destabilization models simulating surgical procedures. COR locus tracking instantaneous centers of rotation is an extremely important parameter that needs to be included in all biomechanical studies which may facilitate an increase understanding. This increased understanding can help product development efforts for biomedical engineers developing implants for the treatment of spinal disorders as well as act as a critical guide for surgeons in choosing surgical treatment options and determining the continuum of care for the indication specific treatment of spinal disorders. In the light of these observations, this study is unique in that to the authors knowledge, no previous



studies have been conducted towards determining the effect of unilateral decompression and Posterolateral disc Arthroplasty. All previous studies have used 2D flexion-extension radiographs and determined only a single COR between neutral position and the extremes of flexion and extension [50]. Single point 2D COR studies may be misleading when comparing surgical constructs in the sense of corroborating a false positive in its similarity to the behavior of the intact spine.

#### **4.2 Biomechanical characterization of Posterior Dynamic Stabilization in the human lumbosacral spine**

The biomechanical goal of Dynamic Stabilization is to alter favorably the *motion and load transmission* of a spinal motion segment so as to potentially:

- Control abnormal motion of the spine,
- Facilitate load sharing with the implanted level, and
- Reduce adjacent segment hypermobility and stresses.

These biomechanical goals are based on the clinical hypothesis that control of abnormal motions and more physiologic load transmission through load sharing with the intervertebral disc would relieve pain at the index segment and prevent adjacent segment degeneration, which is one of the reported drawbacks of spinal fusion [66-68]. Also, patients with spinal stenosis and facet arthropathy who are contraindicated for a disc arthroplasty may be treated with dynamic stabilization [59].

To this end, the second specific aim of this thesis involved biomechanical characterization of Posterior Dynamic Stabilization (PDS) in comparison to conventional rigid fixation. The important aspects studied were:

- Effect of indicated surgical intervention on native spine kinematics
- Implanted and adjacent segment kinematics post PDS implantation
- Load sharing and intradiscal pressure at the implanted and adjacent level

The device used in this study incorporated alternately positioned polymeric (Poly carbonate Urethane) spacers and titanium components beaded over a polymeric cord (Polyethylene Terephthalate), the titanium components of which attach to polyaxial pedicle screws.

There was a significant difference in the kinematic effect of using PDS when compared to rigid stabilization at the index (L4-L5) level. Both the PDS and rigid devices produced significant stabilization, but a consistent and significant trend of increased flexibility was observed in all loading modes for BF+BPDS when compared to BF+S+R (rigid). PDS led to ROM values which were, in terms of intact, 44%, 62%, 58%, 125%, in F, E, LB, AR, respectively, while rigid fixation resulted in ROM values of 31%, 29%, 34%, and 77%. In a previous study on dynamic stabilization Gedet et al. [102] reported (load control protocol using a follower load and partial injury including a 25% nucleotomy) that dynamic stabilization provided stabilization when compared to intact values of ~20%, 40%, 40%, and 100%, for F, E, LB, and AR, respectively. The data from the current study showed a higher ROM baseline, because of facetectomy as opposed to nucleotomy as the injury model, but the stabilization effect followed a similar pattern. A separate study, investigating a more severe injury model without axial preload, revealed that PDS restored motion to ~20%, 100%, 27%, and 130% of the intact values [103-104]. While it is difficult to directly compare the magnitudes reported in the literature sources

to the current data, due to differences in test protocols, injury models, and the use of follower loads, the pattern in data is still comparable.

Also, the difference in the kinematics is attributed to the differences in design of the devices involved in the study [103-104]. The device used in the Gedet study involved modular flexible metal springs and polymeric components, while the Schmoelz study involved a similar material polymeric spacer and cord design (as current study); however the pedicle screws were fixed directly to the cord which resulted higher rigidity in flexion compared to extension due to limited AP rotation + translation of the superior screw in flexion. On the contrary, the data from the present study appears to provide a more uniform rigidity in ROM across flexion, extension, and lateral bending.

In terms of Neutral Zone, surgical decompression (bilateral facetectomy) increased the NZ significantly in extension, while there was a comparable decrease in flexion. There seemed to be a non-linear relationship in between the NZ increase in extension and the corresponding increase in ROM post bilateral facetectomy. E.g. the ROM increased in extension by 20% while the NZ increased by 50% with bilateral facetectomy. The subsequent dynamic stabilization of the spine reduced the NZ closer to the intact. It was interesting to note that there was a trend towards slight increase in ROM ( $p>0.05$ ) in flexion with bilateral facetectomy; however the NZ showed an increasingly decreasing trend post bilateral facetectomy in flexion. These observations play an important role in highlighting the fact that spinal structures due to their mechanical properties show different behavior at different loads and in different directional loading. It has been hypothesized that the soft tissue structures play an important role in the NZ compared to the elastic zone (EZ) of the spine. It has been hypothesized by Panjabi et al.

that the NZ may potentially play an important role in understanding the discrepancy or lack of correlation between disc degeneration/spinal instability and the range of motion. He had hypothesized that instability causing pain may reflect itself more in the NZ or low load curve of the spinal load displacement curve as against the total range of motion. There may be a correlation between this NZ and symptomatic pain in patients. It is therefore extremely important while conducting biomechanical research that multiple parameters be studied and be classified into behavioural patterns at varied loads (low loads or high loads) and also in different directions. It has been observed that multiple studies in the literature combine the flexion extension-response parameters which may not be a realistic representation of spinal behavior and tend to lose on significant trends of spinal kinematics. Similar trends were observed in coupled sagittal plane translation, where bilateral facetectomy showed an increasing trend in extension compared to flexion. Dynamic stabilization reduced sagittal plane translation significantly in flexion and extension. The reduction in extension was less (60%) compared to that exhibited by rigid fixation (~30%), showed an equivalent reduction to rigid fixation in flexion.

In terms of load sharing effect, the current study showed that dynamic stabilization alone with no surgical decompression (facetectomy) increased the IDP at the index level in flexion, while dynamic stabilization post decompression recorded a lesser increase. The dynamic stabilization of the spine though has an aim of motion preservation and non-fusion, the indication dictates that it have some stability which is dissimilar to an Arthroplasty device whose indication is total motion recovery and preservation. The stiffness of the system required for dynamic stabilization requires a higher moment load to reach the same displacement in the hybrid displacement control testing protocol. This

is evident by the fact that the mechanical effort required to reach the intact spine displacement was 62% higher and statistically significant than the mechanical effort for the intact spine. This increase in mechanical effort in the form of increased moment loads may have been the reason for the increased IDP at the index level in flexion. In extension and lateral bending, dynamic stabilization with and without decompression (facetectomy) off loaded the index level disc significantly. These results correlate well with the literature where it was observed that the dynamic device responded to extension by total load-bearing of the implant, resulting in negative pressure in the disc at the index level [103].

The current study showed more uniform kinematics with PDS, so that flexion and extension were more nearly equilibrated at 44% and 62% of intact motion. It is important to highlight that the biomechanical results are a significant function of the design of the system in terms of materials and mechanical function. The system used in the current study had a compressive polymeric component above the cranial pedicle screw, to dampen flexion. Several studies have expounded on the effect of PCU spacer length on the resulting kinematics [105-106]. Larger polymeric spacers in between pedicle screws were seen to off-load facet contact forces, and to result in motion patterns which were more similar to the intact loading condition. In a finite element study by Schmidt et al., the authors predicted the performance of PDS devices in different loading modes, as a function of polymer properties. The material properties of posterior instrumentation were input in the analysis in terms of the bending stiffness and axial stiffness; axial stiffness referring to purely compressing the polymer spacer, bending stiffness similar to folding the spacer. The difference in bending stiffness between a PCU spacer and rigid rod is

expected to be larger than their difference in axial stiffness. In that study, the authors concluded that in each loading mode the resulting ROM of an L4-L5 segment with posterior instrumentation involved a combination of both bending and axial stiffness. However, in flexion-extension, the relationship was mostly determined through axial stiffness, while in lateral bending and axial rotation both stiffness parameters played a role. Extrapolating these results to PDS findings helps explain the relative rigidity of PDS devices in flexion-extension, which despite a polymer spacer, are significantly stabilized with respect to intact values. Moreover, their findings predict that materials with high bending flexibility, would respond with increased motion in lateral bending and axial rotation. These conclusions are consistent with the results reported here as well as other studies. In this study, the polymeric material is a combination of the elements in between and above the pedicle screws. This increased polymeric material and the potential of the cranial pedicle screw to allow interpedicular distance change can be expected to add to the overall flexibility especially in lateral bending and axial rotation.

The PDS test device reduced adjacent level hypermobility caused by rigid fixation. The trend of adjacent level motions followed the model  $BF+S+R \geq BF+BPDS \geq BF$  for all loading modes at both L3-L4 and L5-S1, indicating the utility of semi-rigid stabilization with softer polymeric materials to offset adjacent level effects. This trend is encouraging for the use of PDS devices to alleviate adjacent level stresses however, its clinical relevance needs to be proven. The important question is “How much off-loading is ideal?” remains to be answered. Nevertheless, the PDS device produced significantly smaller motions than rigid fixation at the adjacent levels, in flexion (only at L5-S1), extension (only at L3-L4), and lateral bending (only at L3-L4). Intradiscal pressure

measurements at the adjacent level reflected the same trends as the ROM, but in flexion, the relationship between ROM and IDP was non-linear. A 22% increase in L3-L4 level motion caused by L4-L5 rigid fixation, resulted in 105% increase in the IDP value. Moreover, stabilization with PDS device was not able to restore these large pressure increases to near the intact value. If adjacent level disease is indeed related to a physiological imbalance in load-sharing and kinematics of segments juxtaposed to the fusion site, then the role of motion versus pressure on the rate of disease progression needs to be determined. Since these factors are non-linearly related, restricting the motion may not be sufficient at buffering the load-sharing effects on the adjacent level.

Center of rotation was calculated using rigid body kinematics i.e. each of the motion segments was considered to be formed of two rigid bodies representing the vertebrae. The output of the motion analysis system was in the form of global coordinates of the markers attached to each of these vertebrae or rigid bodies. The 3 marker frame system attached to each of the vertebral bodies was defined as a local coordinate system with the middle marker as origin. Transformation matrices and vector algebra methods [Appendix B] were used to determine the center of rotation in the global coordinate system between consecutive frames as the spine moved in 3D space. A locus of the COR was then plotted based on the coordinates of the instantaneous COR. The COR locus was plotted for Intact, PDS, BF and BF+PDS constructs. Flexion extension being the predominant motion, COR locus was plotted for the same. In general, COR for the intact spine moved anteriorly and inferiorly in flexion, while it moved superior and posterior in extension. In a clinical study on centrod patterns in the lumbar spine in normal subjects [92], Ogston et al. showed that the centrod moved from posterior to anterior and back to

posterior as the spine moved from extension to flexion. Similarly, Wachowski et al. 2009 [107] showed that the instantaneous helical axis (IHA) migrated ventrally in flexion and dorsally in extension. Also, in the current study, the COR travelled more in the anterior-posterior direction in flexion compared to extension, while it travelled more in the superior-inferior (or cephalad-caudal) direction in extension compared to flexion. This may be correlated to the increased AP translation in flexion compared to extension, where the facets prevent posterior translation, whereas in flexion they act as a guide as the disc enables combined rotation and anterior translation. These results are similar to the Ogston study which showed that the centre length had a direct correlation with the amount of joint translation in the sagittal plane. In terms of length, the COR locus was ~100 mm in the anterior-posterior direction while it was ~60 mm in the superior-inferior direction. In the Ogston study, the centre length was an average of ~44 mm [15.2-81.4mm] in the anterior-posterior direction, while in the Wachowski study it was ~ 30 mm. The difference in locus or centre length may be due to the differences in cadaveric specimens used in the current study and the Wachowski study and also in the levels studies i.e. L4-L5 (current study) versus L3-L4. Irregularities in tissue properties are also known to cause changes in the COR locus [92, 107]. Also, in the Wachowski study, an axial compressive preload of 200N had been applied to the cadavers, and the moment loads were 6Nm compared to the current study which utilized 8Nm of pure moment loads. The Ogston study was different in that it was a clinical study in which flexion-extension radiographs of 12 patients were taken to track the centre pattern. Also, in both studies in the literature only a few points were taken into account for generating the locus whereas in the current study a few thousand points were taken into consideration as



the data was recorded at 0.5Hz. Despite the differences in specimens, test setup, loading modes and data points the nature of the COR locus was similar in all three studies.

Implantation of PDS at the index level followed a similar trend to the intact spine however, its span was reduced in both flexion and extension due to the stabilization effect of the PDS device. Bilateral facetectomy diffused the COR locus and increased the span in both anterior posterior and superior inferior directions compared to intact. Stabilization with PDS post BF was not able to restore the COR locus pattern back to intact. These observations clearly shows the importance of the spinal structures in maintain the quality of motion or COR locus. This also highlights an important observation that ROM and NZ parameters alone may not be able to shed light on spinal kinematics post destabilization models simulating surgical procedures. COR locus tracking instantaneous centers of rotation is an extremely important parameter that needs to be included in all biomechanical studies which may facilitate an increase understanding. This increased understanding can help product development efforts for biomedical engineers developing implants for the treatment of spinal disorders as well as act as a critical guide for surgeons in choosing surgical treatment options and determining the continuum of care for the indication specific treatment of spinal disorders. In the light of these observations, this study is unique in that to the authors knowledge, no previous studies have been conducted towards determining the effect of dynamic stabilization, decompression procedures and subsequent stabilization on the COR of the motion segment. All previous studies have used 2D flexion-extension radiographs and determined only a single COR between neutral position and the extremes of flexion and extension [50]. Single point 2D

COR studies may be misleading when comparing surgical constructs in the sense of corroborating a false positive in its similarity to the behavior of the intact spine.

There were certain limitations associated with the study. There was no compressive follower load applied to the spines in this study. A compressive follower preload tends to stiffen the intervertebral disc which may have influenced the NZ and especially the COR. Based on previous COR studies of the intact spine, compressive loads tend to change the magnitude of the locus, not so much the pattern. The PDS device being a load sharing device, the compressive follower preload would have affected the stabilization pattern induced by it. Also, it would have been beneficial to conduct a classification or grading of the disc and facets of the cadaveric specimens. Irregularities or different grades of degeneration affect the COR locus the effect of which was not captured in this study. In terms of the decompression model, bilateral facetectomy injury model may not be the most common scenario of a decompression clinically, compared to previous studies in the literature where a nucleotomy alone was incorporated as an injury or decompression model.

A comprehensive biomechanical investigation from a macro level (ROM, etc.) to a micro level (3D instantaneous COR locus) was conducted on dynamic stabilization, however clinical studies are required to study the effect of the pedicle screw based dynamic stabilization in the continuum of care.

### **4.3 Biomechanical characterization of Posterior Dynamic Stabilization adjacent to rigid fixation in the human lumbosacral spine**

Dynamic stabilization, in addition to its stand-alone application of load sharing for discogenic low back pain and stabilization of a surgically decompressed spine, has been proposed to have potential clinical benefits adjacent to long rigid fixation and fusion (2 levels or more) to reduce the complications associated with multilevel fusion constructs with rigid fixation. It has also been proposed that surgical treatment be customized to the varying grades of symptomatic degeneration and instability especially in multilevel fusion constructs. This may be achieved by using rigid transpedicular fixation at the most unstable segments and dynamic stabilization at the mildly degenerated or symptomatic level following a surgical decompression. E.g., in the case of two level degeneration (L4-S1) with symptomatic high grade degeneration and sagittal slip at the caudal level (L5-S1) accompanied by a bulging/herniated disc or hypertrophic ligaments or facets at the cephalad level (L4-L5), current treatment options warrant a surgical decompression at L4-L5 and rigid fixation and fusion from L4-S1 or decompression (involving microdiscectomy/laminectomy/partial facetectomy) only at L4-L5 and rigid fixation and fusion at L5-S1. In the first scenario of a two level rigid fixation and fusion, there is a potential of adjacent segment symptomatic degeneration due to increased stresses and hypermobility at the adjacent level requiring a future extension of fusion or in the second scenario there is a potential that the patient may revisit for an extension of fusion due to the instability created due to decompression procedures. Multilevel fusion constructs have been shown to be correlated to higher incidences of adjacent level degeneration (12-18%) [76] and consequently revision

surgeries. So also, there is a higher incidence of screw breakage and loosening up to 11% [69-75].

The purpose of this study was to evaluate the stability of a hybrid construct, enabling dynamic stabilization immediately adjacent to rigid fixation, and whether it reduces adjacent level stresses and hypermobility. Both kinematics (range-of-motion) and load sharing (intradiscal pressure) were evaluated from L3-S1, with the exception of L4-L5 intradiscal pressure due to the placement of an interbody spacer. Specifically, the level where the flexible portion of the hybrid construct was positioned (L3-L4), was the focus. To the authors' knowledge this paper represents the first paper to analyze load-sharing while examining a hybrid construct, which ties both rigid and dynamic components together simultaneously.

There are mixed reviews regarding the existence and importance of adjacent level hypermobility. A review of 271 clinical articles found a higher rate of symptomatic ASD in 12-18% of patients fused with rigid transpedicular instrumentation [76]. On the contrary, two studies were able to investigate *in vivo* adjacent level motion measurements using radiographic and MRI markers, and concluded that neither monosegmental posterior instrumentation nor PDS produced increased motion at the disc level above the fixated level [108]. In this light, dynamic stabilization was not deemed necessary as there was no adjacent level issue to counterbalance. Numerous biomechanical studies have confirmed increased stresses at the adjacent level due to rigid instrumentation used for the fusion process [103, 104, 109-111]. A biomechanical comparison of rigid and dynamic instrumentation concluded that while there was only a slight difference in adjacent segment motion between the two, the distribution in the levels was more

favorable with PDS. More specifically, it concluded that rigid stabilization is compensated predominantly in the first cranial adjacent segment, but in the dynamic stabilization scenario, motion was distributed in the first and second cranial segment, and by 20% in the caudal adjacent segment [111].

Hybrid constructs have been introduced to provide a transition in stabilization between completely rigid and uninstrumented segments, and to ease the abrupt change in construct stiffness and effectively ROM and IDP. In this study, the authors show a smooth adjustment between the rigid and flexible portions of the hybrid construct in all loading modes, and no statistical differences between the L4-L5 rigid level and L3-L4 semi-rigid level.

In one of only two previous studies involving the use of hybrid constructs, the authors' concluded that a PDS device when applied to a single segment, as in the case of fusion, will provide stabilization similar to that of rigid fixation. Conversely, if the dynamic component was extended a level above the index surgery, the resulting ROM was large enough to be considered as a dynamic stabilization system, and would act in a motion-preserving manner. Some differences in their protocol and ours exist such as the use of displacement control in this study. Also they defined 'hybrid construct' as a bi-level flexible device with a spacer at the inferior level not as a rigid titanium rod in conjunction with a flexible component, as in the present study [109].

In this study, the PDS adjacent to the rigid fixation resulted in motion which was 31%, 37%, and 83% of the intact spine motion in FE, LB, and AR, respectively. At the index surgical level, the PDS device (BF+S+BPDS) resulted in motion which was 40%, 54%, and 126% of the intact spine motion. Therefore, it cannot be concluded that

extending rigid fixation with a dynamic component leads to any relative increase in motion, or motion-preserving behavior. Moreover, the level of stabilization is similar regardless of whether it used adjacent to the index level or at the index level itself. It should, however, be noted that ROM at the index level is higher for instrumented constructs due to the aggressive decompression/injury model considered.

The load sharing trends across test groups very nearly mimicked the relationships seen in the ROM. It was noteworthy that while the trends between ROM and IDP were similar, meaning that higher stability constructs demonstrated lower IDP, the ROM-IDP ratios were not. This trend was very evident in flexion-extension. For example, the flexible portion of BF+S+R+BPDS<sub>34</sub> construct was 31% of the intact motion, but the pressure was 84% of the intact pressure, indicating that the device restricted motion, but allowed anterior column load-sharing. Also, since a displacement control protocol was used the IDP may have been higher due to higher moment loads being applied to reach the same displacement as intact. In lateral bending and axial rotation, the motion-pressure relationship is more constant at 37%-30% and 83%-94% of intact. This may elude to why radiographic evidence is often not indicative of degenerative changes, which may be caused by stresses, not motion, on the disc. One possible reason for this phenomenon is that PDS system allows interpedicular distance change of the cephalad screw. This travel may account for the increased load sharing in flexion-extension. It appears as if the PDS system provides increased load sharing, yet strong kinematical stability when used in a hybrid construct.

One limitation of this study is the lack of a bi-level rigid rod construct, which would provide a basis of comparison for the BF+S+R+BPDS<sub>34</sub> hybrid construct. For this

reason, the authors included a single-level comparison of rigid fixation versus dynamic fixation (Table 2). In the single-level comparison, the PDS device provided 129%, 160%, and 163% of the motion of the rigid device in FE, LB, and AR, respectively. Based on the observation that the single-level PDS device behaved similarly to the flexible portion of the hybrid construct, the authors believe the bi-level rigid fixation would be similar to the single-level rigid fixation. Literature data shows that in bi-level rigid constructs the superior level shows equivalent or reduced motion compared to the inferior level [112]. Based on this observation in conjunction with the results of Table 2, one can expect the L3-L4 level of the bi-level rigid construct to result in motion less than 31%, 34%, and 77% of intact motion, in FE, LB, and AR, respectively. Therefore, the PDS adjacent to rigid fixation will be similarly less rigid when compared to bi-level rigid fixation.

The goal of dynamic stabilization is to provide stabilization without fusion at the symptomatic level in select patients and potentially offset loads at adjacent segments. Alternatively, they may be used transitionally offload adjacent level effects immediately above or below posterior rigid fixation. Very few biomechanical studies on the subject exist to date. In this study, the authors' conclude that the use of PDS at the adjacent cranial level to a rigid fixation, stabilizes the motion of the cranial segment in all modes, but conversely allows load-sharing in the anterior column during flexion-extension. The relationship between motion and intradiscal pressure under the complex loading of hybrid dynamic stabilization needs more study. Clinical studies are required to evaluate the effect of transitional stabilization.

#### **4.4 Biomechanical characterization of Posterolateral Disc Arthroplasty in conjunction with posterior tethering in the human lumbosacral spine**

Posterior dynamic stabilization has been proposed to be used as a posterior tether adjunct to a disc arthroplasty (DA) system. The two possible clinical scenarios would be: 1) revision of a disc arthroplasty or 2) Posterior tethering of an anterior or posterolateral disc arthroplasty system [64].

Revision surgery of a DA may be required in the event of symptomatic facet arthropathy or any other posterior column degeneration developed after a number of years [59, 77]. It may also be required in a situation where the DA device is placed eccentrically and/or is undersized creating a functional unit imbalance. In the case of a multilevel anterior DA, resection of the ALL and anterior annulus may cause increased instability potentially leading to a segmental scoliosis [59, 77]. In the event of such clinical scenarios, the surgeon may elect to use a PDS adjunct to the DA instead of fusion.

Anterior disc arthroplasty has its disadvantages, primarily due to risk of vascular injury, retrograde ejaculation or ureteral injury associated with the surgical approach [45-49]. In addition to the surgical morbidity, biomechanically, segmental instability may be induced with the partial or complete removal of the anterior annulus and anterior longitudinal ligament [50]. In addition to the surgical and biomechanical challenges, anterior disc arthroplasty is contraindicated for neural and facet pain caused by central or lateral recess stenosis, and facet arthrosis [51-53]. In the light of these observations in patients who seek treatment for low back pain, and are contraindicated for disc arthroplasty due to approach related deficiencies and contraindications, alternative



approaches to disc arthroplasty are currently being explored and developed. The concept of Posterior or Posterolateral disc arthroplasty is currently gaining ground in the spine community [56]. However, anatomical constraints and the extent of pathology may dictate the implant design and required decompression. Decompression due to a partial or total facetectomy in conjunction with a disc arthroplasty device as well as improper positioning of the device may increase segmental instability. In the case of a posterolateral disc arthroplasty, surgery may involve unilateral / bilateral, partial or total facetectomy depending on the amount of decompression required and implant design. Partial or total resection of the facet joint may lead to increased ROM in axial rotation. Previous studies have shown an increase in the ROM of stand-alone PLIF devices [78]. In such a situation, it has been proposed that a posterior dynamic stabilization system be used adjunct to the PLDA as an index procedure. The goal of the current study was to study the stabilizing effect of posterior dynamic stabilization as a tether to posterior disc Arthroplasty in a unilateral and bilateral facetectomy model.

Unilateral facetectomy and implantation of the PLDA device increased the ROM significantly in lateral bending and axial rotation. Unilateral and bilateral PDS tethering were both able to significantly reduce the ROM compared to the destabilization. Similar trend was observed in axial rotation in the bilateral facetectomy model, which was reduced significantly by bilateral tethering using the PDS system.

This is the first study to document the effect of dynamic stabilization and tethering of a posterolateral disc Arthroplasty system. Though the instability created due to unilateral and bilateral facetectomy was restored by the posterior tether, based on the COR locus trends investigated in the previous aims of this thesis, it is clear that

disruption of structural elements (even though relieving clinical symptoms), disturbs the quality of motion of the spine. Tethering of the PLDA system with a PDS system may stabilize the ROM and NZ as observed, however it may not return the quality of motion (COR locus) back to normal. It is possible that an implant exactly mimicking the properties of the surgically removed structural element may be able to help restore the COR locus close to the intact. In the case of the current decompression model of a unilateral and bilateral facetectomy, a facet replacement system mimicking the exact geometry, material and mechanical and functional properties of the native spine may be able to restore intact kinematics in terms of COR. Development of such a system incorporating the right materials, and design may be a potential solution towards achieving this goal.

## CHAPTER 5

### CONCLUSION

The disadvantages of spinal fusion as well as the graduated nature of disc degeneration and consequently back pain, has led to a gradual shift in philosophy from a 'one size fits all', i.e. spinal fusion for all patients with symptomatic low back pain to a 'customized approach', i.e. patient and indication specific treatment modality for spine care. The change in philosophy has also been supported by the continuous evolution in the understanding of normal and symptomatic spine biomechanics, biology and mechanobiology in conjunction with the advancements in material sciences, and tissue engineering. This gradual shift in the continuum of spine care has laid the ground for concepts of *motion preservation* and *dynamic stabilization*, the former being an established treatment modality in orthopedics for a long time.

The aim of the current thesis was to perform a comprehensive scientific investigation to understand, evaluate and establish the *in vitro* biomechanical characteristics and performance of indication specific treatment modalities incorporating the concept of Posterolateral Disc Arthroplasty and Posterior Dynamic Stabilization for the treatment of symptomatic mechanical back pain. The results of this comprehensive study may help the clinicians to make an informed decision while selecting and designing a treating modality for their patients. To this end, the current thesis was undertaken and the study designed to fulfill 4 specific aims evaluating Posterolateral Disc Arthroplasty, Dynamic stabilization as stand-alone and transitional stabilization and also in conjunction with a Posterolateral disc Arthroplasty.

Through the comprehensive biomechanical investigation conducted in the current thesis we were able to theoretically prove the importance of a customized approach towards the treatment of spine care. Also, the most important conclusion of the biomechanical investigation was the fact that Range of Motion results alone are not sufficient to draw significant conclusions. It is imperative that in depth analysis of the quality of motion through the determination of instantaneous center of rotation is extremely important. Previous studies have shown only a single center of rotation between the extremes of motion which is also insufficient as the end points do not determine the path taken to reach the endpoints. This in depth analysis is also important for biomedical engineers to design and develop physiologically viable implants that will mimic the performance of the physiologic spine as well as act as a critical guide for surgeons in choosing surgical treatment options and determining the continuum of care for the indication specific treatment of spinal disorders. Clinical studies are extremely important as a next step towards validating this customized approach towards spine care.

## REFERENCES

1. Joyce A. DeLeo, Beth A. Winkelstein, Physiology of Chronic Spinal Pain Syndromes: From Animal Models to Biomechanics, *Spine* 2000, Volume 27, Number 22, 2526-2537
2. Lemrow N, Adams D, Coffey R, et al. The 50 most frequent diagnosis-related groups (DRGs), diagnoses, and procedures: statistics by hospital size and location. DHHS publication no. PHS) 90-3465, Hospital Studies Program Research Note 13. Rockville, MD: Agency for Health Care Policy and Research, Public Health Service; 1990.
3. Violinn E. Turczyn KM, Loeser JD. Theories of back pain and health care utilization. *Neurosurg Clin N Am* 1991;2:739-48.
4. Hart LG, Deyo RA. Physician office visits for low back pain. Frequency, clinical evaluation, and treatment patterns from a U.S. National Survey. *Spine* 1995;20:11-9.
5. Michel A, Kohlmann T, Raspe H. The association between clinical findings on physical examination and self reported severity in back pain. Results of a population-based study. *Spine* 1997;3:296-304.
6. 1992-1994 National Health Interview Survey
7. Richard Deyo, Sohail Mirza, Brook Martin, Back Pain Prevalence and Visit Rates – Estimates from US National Survey 2002. *Spine* 2006: Volume 31, Number 23, pp 2724-2727
8. J.Fairbank, Clinical importance of the intervertebral disc, or back pain for biochemists. *Biochemical Society Transactiona* (2002) Volume 30, part 6.
9. White AA, Panjabi MM, *Clinical Biomechanics of the Spine*
10. Manohar M Panjabi, The Stabilizing System of the Spine. Part I. Function, Dysfunction, Adaptation and Enhancement, *Journal of Spinal Disorders* 1992, Vol 5, No. 4, pp 383-389.
11. Brand RA: *Knee Ligaments: A new view.* *J Biomech Eng* 108:106-110, 1986
12. Manohar M Panjabi, The Stabilizing System of the Spine. Part II, Neutral Zone and Instability Hypothesis. *Journal of Spinal Disorders* 1992 Vol 5, No. 4, pp390-397.

13. Nobuhiro Tanaka, Howard An, Tae-Hong Lim, et al. The relationship between disc degeneration and flexibility of the lumbar spine. *The Spine Journal* 1 (2001) 47-56.
14. Airaksinen O, Brox JI, Cedraschi C, et al. Chapter 4. European guidelines for the management of chronic nonspecific low back pain. *Eur Spine J* 2006;15(suppl 2):S192–300.
15. Koes BW, Van Tulder MW, Ostelo R, et al. Clinical guidelines for the management of low back pain in primary care: an international comparison. *Spine* 2001;26:2504–13; discussion 13–14.
16. Koes BW, van Tulder MW, Thomas S. Diagnosis and treatment of low back pain. *BMJ* 2006;332:1430–4.
17. van Tulder M, Becker A, Bekkering T, et al. Chapter 3. European guidelines for the management of acute nonspecific low back pain in primary care. *EurSpine J* 2006;15(suppl 2):S169 –91.
18. Peppijn D. D. M. Roelofs, MSc,\* Rick A. Deyo, PhD,† Bart W. Koes Nonsteroidal Anti-Inflammatory Drugs for Low Back Pain An Updated Cochrane Review SPINE Volume 33, Number 16, pp 1766–1774©2008
19. Leena Niemisto, MD, Eija Kalso, MD, PhD, Antti Malmivaara, Radiofrequency Denervation for Neck and Back Pain: A Systematic Review Within the Framework of the Cochrane Collaboration Back Review Group SPINE Volume 28, Number 16, pp 1877–1888©2003
20. J. Bart Staal, PhD,\* Rob A. de Bie, PhD,\* Henrica C. W. de Vet Injection Therapy for Subacute and Chronic Low Back Pain An Updated Cochrane Review SPINE Volume 34, Number 1, pp 49–59©2008
21. Eva Schonstein, D. Kenny, J. Keating, B. Koes Physical Conditioning Programs for Workers With Back and Neck Pain: A Cochrane Systematic Review SPINE Volume 28, Number 19, pp E391–E395©2003
22. Lance Twomey, James Taylor, Exercise and Spinal Manipulation in the Treatment of Low Back Pain, *Spine*, Volume 20, Number 5, 615-619, Spine
23. M. W. Heymans, PT, PhD,\* M. W. van Tulder, PhD,†‡ R. Esmail, Back Schools for Nonspecific Low Back Pain A Systematic Review Within the Framework of the Cochrane Collaboration Back Review Group SPINE Volume 30, Number 19, pp 2153–2163©2005
24. Andrea D. Furlan, MD,\* Maurits van Tulder, PhD,† Dan Cherkin Acupuncture and Dry-Needling for Low Back Pain: An Updated Systematic Review Within the

Framework of the Cochrane Collaboration SPINE Volume 30, Number 8, pp 944–963©2005

25. Patanjali Rishi, 'Patanjali Yog Sutra', 200 B.C.
26. Kimberly Williams, PhD,\* Christiaan Abildso, PhD, MPH, Lois Steinberg  
Evaluation of the Effectiveness and Efficacy of Iyengar Yoga Therapy on Chronic Low Back Pain SPINE Volume 34, Number 19, pp 2066–2076©2009
27. Anderson, C. E. (1956). "Spondyloschisis following spine fusion." *J Bone Joint Surg Am* 38-A(5): 1142-6.
28. Harris, R. I. and J. J. Wiley (1963). "Acquired Spondylolysis as a Sequel to Spine Fusion." *J Bone Joint Surg Am* 45: 1159-70
29. Froning, E. C. and B. Frohman (1968). "Motion of the lumbosacral spine after laminectomy and spine fusion. Correlation of motion with the result." *J Bone Joint Surg Am* 50(5): 897-918.
30. Bitan, F., M. Bex, et al. (1984). "[Success factors in posterolateral arthrodesis of the lumbosacral spine]." *Rev Chir Orthop Reparatrice Appar Mot* 70(6): 465-71.
31. Lee, C. K. and N. A. Langrana (1984). "Lumbosacral spinal fusion. A biomechanical study." *Spine* 9(6): 574-81
32. Lee, C. K. (1988). "Accelerated degeneration of the segment adjacent to a lumbar fusion." *Spine* 13(3): 375-7.
33. Frymoyer JW, Hanley EN Jr., Howe J, et al. A comparison of radiographic findings in fusion and non-fusion patients, ten or more years following lumbar disc surgery, *Spine* 1979; 4:435-440
34. Lee, C. K. (1988). "Accelerated degeneration of the segment adjacent to a lumbar fusion." *Spine* 13(3): 375-7.
35. Schlegel, J. D., J. A. Smith, et al. (1996). "Lumbar motion segment pathology adjacent to thoracolumbar, lumbar, and lumbosacral fusions." *Spine* 21(8): 970-81.
36. Chow, D. H., K. D. Luk, et al. (1996). "Effects of short anterior lumbar interbody fusion on biomechanics of neighboring unfused segments." *Spine* 21(5): 549-55.
37. Shono, Y., K. Kaneda, et al. (1998). "Stability of posterior spinal instrumentation and its effects on adjacent motion segments in the lumbosacral spine." *Spine* 23(14): 1550-8.

38. Akamaru, T., N. Kawahara, et al. (2003). "Adjacent segment motion after a simulated lumbar fusion in different sagittal alignments: a biomechanical analysis." *Spine* 28(14): 1560-6.
39. Park Paul, Garton Hugh, Gala Vishal, et al. Adjacent Segment Disease after Lumbar or Lumbosacral Fusion: Review of the Literature. *Spine* 2004, Volume 29 – Issue 17, pp 1938-1944
40. J.N. Alastair Gibson, MD, FRCS, and Gordon Waddell Surgery for Degenerative Lumbar Spondylosis: Updated Cochrane Review *SPINE* Volume 30, Number 20, pp 2312–2320©2005
41. Polly DW Jr.: Adapting innovative motion preserving technology to spinal practice: what should we expect to happen? *Spine* 28: S104 – S109, 2003
42. Bao QB, McCullen GM, Hingham PA, et al. The artificial disc: theory, design and materials. *Biomaterials* 1996;17:1157-1167
43. Guyer RD, Ohnmeiss DD. Intervertebral Disc Prostheses. *Spine* 2003 Aug 1; 28 (15 Suppl):S15-23
44. Bertagnoli R, Yue JJ, Shah RV, et al. The treatment of single level lumbar discogenic low back pain with total disc arthroplasty utilizing the Prodisc prosthesis : a prospective study with 2-year minimum follow-up.
45. Brau SA, Delamarter RB, Schiffman ML, Williams LA, Watkins RG. Vascular injury during anterior lumbar surgery. *Spine J* 2004;4:409–12.
46. Sasso RC, Best NM, Mummaneni PV, Reilly TM, Hussain SM. Analysis of operative complications in a series of 471 anterior lumbar interbody fusion procedures. *Spine* 2005; 30:670–4.
47. McAfee PC, Geisler FH, Saiedy S, et al. Revisability of the CHARITE artificial disc replacement: analysis of 688 patients enrolled in the U.S. IDE study of the CHARITE Artificial Disc. *Spine* 2006;31:1217–26.
48. Sasso RC, Kenneth Burkus J, LeHuec JC. Retrograde ejaculation after ante- 1282 *Spine* • Volume 33 • Number 11 • 2008 prior lumbar interbody fusion: transperitoneal versus retroperitoneal exposure. *Spine* 2003; 28:1023–6.
49. Tiusanen H, Seitsalo S, Osterman K, Soini J. Retrograde ejaculation after anterior interbody lumbar fusion. *Eur Spine J* 1995;4:339–42.
50. Paul C. McAfee, MD, Bryan W. Cunningham, MMEch, Eng, Victor Hayes, MD, et al. Biomechanical Analysis of Rotational Motions After Disc Arthroplasty:



Implications for Patients With Adult Deformities. *Spine* Volume 31, Number 19 Suppl, pp S152-S160

51. Zigler JE, Burd TA, Vialle EN, et al. Lumbar spine arthroplasty. Early results using the ProDisc II : a prospective randomized trial of arthroplasty versus fusion. *J Spinal Disorders and Techniques* 2003; 16:352-61.
52. Tropiano P, Huang RC, Girard FE, et al. Lumbar disc replacement: preliminary results with ProDisc II after a minimum follow-up period of 1 year. *J Spinal Disorders and Techniques* 2003; 16:362-8
53. Huang RC, Lim MR, Girardi FP, et al. The prevalence of contraindications to total disc replacement in a cohort of lumbar surgical patients. *Spine* 29: 2538 – 2541, 2004.
54. Hochschuler SH, Ohnmeiss DD, Guyer RD, et al. Artificial disc: preliminary results of a prospective study in the United States. *Eur Spine Journal* 2002; 11(suppl 2):106-10.
55. Zeegers WS, Bohnen LM, Laaper M, et al. Artificial disc replacement with the modular type SB Charite III : 2-year results in 50 prospectively studied patients. *Eur Spine Journal* 1999; 8:210-7.
56. Alpesh A. Patel, MD,\* Darrel S. Brodke, MD,\* Luiz Pimenta, MD, PhD,†  
Revision Strategies in Lumbar Total Disc Arthroplasty *SPINE* Volume 33, Number 11, pp 1276–1283
57. Klara PM, Ray CD. Artificial nucleus replacement: clinical experience. *Spine* 2002;27:1374–7.
58. Shim CS, Lee SH, Park CW, et al. Partial disc replacement with the PDN prosthetic disc nucleus device: early clinical results. *J Spinal Disord Tech* 2003;16:324–30.
59. Russ Nockels, Dynamic Stabilization in the Surgical Management of Painful Lumbar Spinal Disorders, *Spine*, Volume 30, Number 16S, S68-S72, 2005
60. Panjabi MM: Clinical instability and low back pain. *J Electromyogr Kinesiol* 13: 371 – 379, 2003
61. Panjabi MM: A hypothesis of chronic low back pain: ligament sub failure injuries lead to muscle control dysfunction. *Eur Spine J* 15: 668-676, 2006
62. Panjabi MM: The stabilizing system of the spine Part I. Function, dysfunction, adaptation and enhancement. *J Spinal Disord* 5: 383 – 389, 397, 1992

63. Panjabi MM: The stabilizing system of the spine Part II. Neutral zone and instability hypothesis. *J Spinal Disord* 5: 390 – 397, 1992
64. McAfee et al. Treatment of lumbar spinal stenosis with a total posterior arthroplasty prosthesis: implant description, surgical technique, and a prospective report on 29 patients
65. Abumi K, Panjabi MM, Kramer KM, et al. Biomechanical evaluation of lumbar spinal stability after graded facetectomies. *Spine* 15: 1142 – 1147, 1990
66. Lee CK: Accelerated degeneration of the segment adjacent to a fusion. *Spine* 13: 375 – 377, 1988
67. Lee CK, Langrana NA: Lumbosacral spinal fusion: A biomechanical study. *Spine* 9: 574 – 581, 1984
68. Olsweaki JM, Garvey RA, Schendel MJ: Biomechanical analysis of facet and graft loading in a Smith-Robinson type cervical spine model. *Spine* 19: 2540-2544, 1994
69. Davne SH, Myers DL. Complications of lumbar spinal fusion with transpedicular instrumentation. *Spine (Phila Pa 1976)* 1992;17:S184-9.
70. Esses SI, Bednar DA. The spinal pedicle screw: techniques and systems. *Orthop Rev* 1989;18:676-82.
71. Jutte PC, Castelein RM. Complications of pedicle screws in lumbar and lumbosacral fusions in 105 consecutive primary operations. *Eur Spine J* 2002;11:594-8.
72. Lonstein JE, Denis F, Perra JH, et al. Complications associated with pedicle screws. *J Bone Joint Surg Am* 1999;81:1519-28.
73. Pihlajamaki H, Myllynen P, Bostman O. Complications of transpedicular lumbosacral fixation for non-traumatic disorders. *J Bone Joint Surg Br* 1997;79:183-9.
74. Steffee AD, Brantigan JW. The variable screw placement spinal fixation system. Report of a prospective study of 250 patients enrolled in Food and Drug Administration clinical trials. *Spine (Phila Pa 1976)* 1993;18:1160-72.
75. West JL, 3rd, Ogilvie JW, Bradford DS. Complications of the variable screw plate pedicle screw fixation. *Spine (Phila Pa 1976)* 1991;16:576-9.
76. Park P, Garton HJ, Gala VC, et al. Adjacent segment disease after lumbar or lumbosacral fusion: review of the literature. *Spine (Phila Pa 1976)* 2004;29:1938-44.

77. Young MS. Posterior dynamic stabilization devices in the coming age of lumbar disc replacement. *Neurosurgery Focus* 22 (1): E14, 2007
78. Saal JA: Dynamic muscular stabilization in the nonoperative treatment of lumbar pain syndromes. *Ortho Rev* 19:691–700, 1990
79. Goel VK, Panjabi MM, Patwardhan AG, Dooris AP, Serhan H; American Society for Testing and Materials. Test protocols for evaluation of spinal implants. *J Bone Joint Surg Am.* 2006 Apr;88 Suppl 2:103-9.
80. Manohar M. Panjabi. Hybrid multidirectional test method to evaluate spinal adjacent level effects. *Clinical Biomechanics* 2007, Volume 22, Issue 3, Pages 257-265
81. Seung-Myung Moon, Aditya Ingalhalikar, Jason M. Highsmith, Alexander R. Vaccaro. Biomechanical rigidity of an all-polyetheretherketone anterior thoracolumbar spinal reconstruction construct: an in vitro corpectomy model. *The Spine Journal.* April 2009 (Vol. 9, Issue 4, Pages 330-335)
82. Josue P. Gabriel, Aditya M. Muzumdar, Saif Khalil, Aditya Ingalhalikar. A novel crossed rod configuration incorporating translaminar screws for occipitocervical internal fixation: an in vitro biomechanical study. *The Spine Journal.* Corrected Proof, 22 October 2010
83. Sengupta D.K., Ingalhalikar A., McAfee P., et al. In-Vitro Evaluation of a Novel Dynamic Stabilization System ‘Transition™’ in motion preservation (SAS - 08)
84. Sengupta D.K., Lindley J., Powers A., Isaza J., Haid R., Ingalhalikar A The Effect of TRANSITION™ Posterior Dynamic Stabilization on Load Sharing Adjacent to Rigid Instrumentation (SAS - 08)
85. McAfee P., Sengupta D., Anand N., Deol G., Khanna N., Tyndall D., Balderston R, Ingalhalikar A. TRIUMPH™ Posterolateral Artificial Disc Biomechanics: The Effect of Posterior Tethering (SAS - 08)
86. Cripton PA, Dumas GA, Nolte LP. A minimally disruptive technique for measuring intervertebral disc pressure in vitro: application to the cervical spine. *J Biomech* 2001;34:545-9
87. Ingalhalikar AV, Reddy CG, Lim TH, Torner JC, Hitchon PW. Effect of lumbar total disc arthroplasty on the segmental motion and intradiscal pressure at the adjacent level: an in vitro biomechanical study: presented at the 2008 Joint Spine Section Meeting Laboratory investigation. *J Neurosurg Spine.* 2009 Dec;11(6):715-23.
88. White A. A., Panjabi M. M. *Clinical Biomechanics of the Spine*, 1978

89. J. V. Seligman, S. D. Gertzbein, M. Tile, et al. Computer Analysis of Spinal Segment Motion in Degenerative Disc Disease With and Without Axial Loading, *Spine*, Vol 9, No. 6, 1984
90. H. van Mameren, H. Sanches, J. Beursgens, et al. Cervical Spine Motion in the Sagittal Plane II – Position of Segmental Averaged Instantaneous Centers of Rotation – A Cineradiographic Study, *Spine*, Volume 17, No. 5, 1992
91. Hendrik Schmidt, Frank Heur, Lutz Claes, et al. The relation between the instantaneous center of rotation and facet joint forces – A finite element analysis. *Clinical Biomechanics* 23 (2008) 270-278
92. N. G. Ogston, G. J. King, S. D. Gertzbein, et al. Centrode Patterns in the Lumbar Spine – Baseline Studies in Normal Subjects. *Spine*, Volume 11, Number 6, 1986
93. Thomas Haer, Marc Bergman, Michael O'Brien, et al. The Effect of the Three Columns of the Spine on the Instantaneous Axis of Rotation in Flexion and Extension. *Spine*, Volume 16, Number 8 Supplement, 1991
94. Masahito Harada, Kuniyoshi Abumi, Manabu Ito, et al. Cineradiographic Motion Analysis of Normal Lumbar Spine During Forward and Backward Flexion. *Spine*, Volume 25, pp 1932-1937, 2000
95. Lee, Sai-Wing; Draper Edward; Hughes Sean. Instantaneous Center of Rotation and Instability of the Cervical Spine: A Clinical Study. *Spine*, 1997, Volume 22, Issue 6, pp 641 – 647
96. Tadanori Sakamaki, Shinsuke Katoh, Koichi Sairyo. Normal and Spondylolytic Pediatric Spine Movements With Reference to Instantaneous Axis of Rotation. *Spine*, Volume 27, Number 2, pp 141 – 145, 2002
97. Young – Hoo Kwon, *Theories and Practices of Motion Analysis*, 1998
98. Christian W. A. Pfirrmann, MD, Alexander Metzdorf, MD, Marco Zanetti, MD, et al. Magnetic Resonance Classification of Lumbar Intervertebral Disc Degeneration. *SPINE* Volume 26, Number 17, pp 1873–1878, 2001.
99. James F. Griffith, MD, Yi-Xiang J. Wang, MD, Gregory E. Antonio, MD. Modified Pfirrmann Grading System for Lumbar Intervertebral Disc Degeneration. *SPINE*, Volume 32, Number 24, pp E708–E712, 2007.
100. Shirazi-Adl, Abdul Ahmed, Suresh Shrivastava. Mechanical Response of a Lumbar Motion Segment in Axial Torque Alone and Combined with Compression. *Spine*, Volume 11, Number 9, 914-927, 1986
101. Marco Cannellaa, Amy Arthurc, Shanee Allena, Michael Keanec, Abhijeet Joshi, et al. The role of the nucleus pulposus in neutral zone human lumbar

- intervertebral disc mechanics. *Journal of Biomechanics* 41 (2008) 2104–2111
102. Gedet P, Haschtmann D, Thistlethwaite PA, et al. Comparative biomechanical investigation of a modular dynamic stabilization system and the Dynesys system. *European Spine Journal*, 2009 Oct; 18(10):1504-11.
  103. Schmoelz W, Huber JF, Nydegger T, et al. Influence of a dynamic stabilization System on load bearing of a bridged disc: an in vitro study of intradiscal pressure. *Eur Spine J* 2006; 15:1276-85.
  104. Schmoelz W, Huber JF, Nydegger T, et al. Dynamic stabilization of the lumbar spine and its effects on adjacent segments: an in vitro experiment. *J Spinal Disord Tech* 2003; 16:418-23.
  105. Niosi CA, Wilson DC, Zhu Q, et al. The effect of dynamic posterior stabilization on facet joint contact forces: an in vitro investigation. *Spine (Phila Pa 1976)* 2008;33:19-26.
  106. Niosi CA, Zhu QA, Wilson DC, et al. Biomechanical characterization of the three-dimensional kinematic behaviour of the Dynesys dynamic stabilization system: an in vitro study. *Eur Spine J* 2006;15:913-22.
  107. Wachowski M.M, M. Mansour, C. Lee, et al. How do spinal segments move? *Journal of Biomechanics* 42 (2009) 2286-2293.
  108. Cakir B, Carazzo C, Schmidt R, et al. Adjacent segment mobility after rigid and semirigid instrumentation of the lumbar spine. *Spine (Phila Pa 1976)* 2009;34:1287-91.
  109. Cheng BC, Gordon J, Cheng J, et al. Immediate biomechanical effects of lumbar posterior dynamic stabilization above a circumferential fusion. *Spine (Phila Pa 1976)* 2007;32:2551-7.
  110. Beastall J, Karadimas E, Siddiqui M, et al. The Dynesys lumbar spinal stabilization system: a preliminary report on positional magnetic resonance imaging findings. *Spine (Phila Pa 1976)* 2007;32:685-90.
  111. Delank KS, Gercek E, Kuhn S, et al. How does spinal canal decompression and dorsal stabilization affect segmental mobility? A biomechanical study. *Arch Orthop Trauma Surg*;130:285-92
  112. Strube P, Tohtz S, Hoff E, et al. Dynamic stabilization adjacent to single-level fusion: Part I. Biomechanical effects on lumbar spinal motion. *Eur Spine J*.

**APPENDIX A**  
**MATLAB PROGRAM FOR INSTANTANEOUS COR TRACKING**

```

Input1 = xlsread('0708745_Intact.xls','b6:s9500');
Input2 = xlsread('0708745_PDS_Pre.xls','b6:s9500');
[l,m] = size(Input1);
[l2,m2] = size(Input2);

for i = 1:l-1

k1d1    =    ((Input1(i,8)-Input1(i,5))*(Input1(i,3)-Input1(i,6)))    -    ((Input1(i,2)-
Input1(i,5))*(Input1(i,9)-Input1(i,6)));
k2d1    =    ((Input1(i,9)-Input1(i,6))*(Input1(i,1)-Input1(i,4)))    -    ((Input1(i,3)-
Input1(i,6))*(Input1(i,7)-Input1(i,4)));
k3d1    =    ((Input1(i,7)-Input1(i,4))*(Input1(i,2)-Input1(i,5)))    -    ((Input1(i,1)-
Input1(i,4))*(Input1(i,8)-Input1(i,5)));

norm1 = sqrt((Input1(i,7)-Input1(i,4))^2 + (Input1(i,8)-Input1(i,5))^2 + (Input1(i,9)-
Input1(i,6))^2);
norm2 = sqrt((Input1(i,1)-Input1(i,4))^2 + (Input1(i,2)-Input1(i,5))^2 + (Input1(i,3)-
Input1(i,6))^2);
norm3 = sqrt(k1d1^2+k2d1^2 +k3d1^2);

```

$$\text{TD1G} = [(\text{Input1}(i,7)-\text{Input1}(i,4))/\text{norm1} \quad (\text{Input1}(i,8)-\text{Input1}(i,5))/\text{norm1} \quad (\text{Input1}(i,9)-\text{Input1}(i,6))/\text{norm1}; \quad (\text{Input1}(i,1)-\text{Input1}(i,4))/\text{norm2} \quad (\text{Input1}(i,2)-\text{Input1}(i,5))/\text{norm2} \\ (\text{Input1}(i,3)-\text{Input1}(i,6))/\text{norm2}; k1d1/\text{norm3} \quad k2d1/\text{norm3} \quad k3d1/\text{norm3}];$$

$$k1p1 = ((\text{Input1}(i,17)-\text{Input1}(i,14))*(\text{Input1}(i,12)-\text{Input1}(i,15))) - ((\text{Input1}(i,11)-\text{Input1}(i,14))*(\text{Input1}(i,18)-\text{Input1}(i,15)));$$

$$k2p1 = ((\text{Input1}(i,18)-\text{Input1}(i,15))*(\text{Input1}(i,10)-\text{Input1}(i,13))) - ((\text{Input1}(i,12)-\text{Input1}(i,15))*(\text{Input1}(i,16)-\text{Input1}(i,13)));$$

$$k3p1 = ((\text{Input1}(i,16)-\text{Input1}(i,13))*(\text{Input1}(i,11)-\text{Input1}(i,14))) - ((\text{Input1}(i,10)-\text{Input1}(i,13))*(\text{Input1}(i,17)-\text{Input1}(i,14)));$$

$$\text{norm4} = \text{sqrt}((\text{Input1}(i,16)-\text{Input1}(i,13))^2 + (\text{Input1}(i,17)-\text{Input1}(i,14))^2 + (\text{Input1}(i,18)-\text{Input1}(i,15))^2);$$

$$\text{norm5} = \text{sqrt}((\text{Input1}(i,10)-\text{Input1}(i,13))^2 + (\text{Input1}(i,11)-\text{Input1}(i,14))^2 + (\text{Input1}(i,12)-\text{Input1}(i,15))^2);$$

$$\text{norm6} = \text{sqrt}(k1p1^2+k2p1^2 +k3p1^2);$$

$$\text{TP1G} = [(\text{Input1}(i,16)-\text{Input1}(i,13))/\text{norm4} \quad (\text{Input1}(i,17)-\text{Input1}(i,14))/\text{norm4} \\ (\text{Input1}(i,18)-\text{Input1}(i,15))/\text{norm4}; \quad (\text{Input1}(i,10)-\text{Input1}(i,13))/\text{norm5} \quad (\text{Input1}(i,11)-\text{Input1}(i,14))/\text{norm5} \quad (\text{Input1}(i,12)-\text{Input1}(i,15))/\text{norm5}; \quad k1p1/\text{norm6} \quad k2p1/\text{norm6} \\ k3p1/\text{norm6}];$$

**%% Compute TdiPi**

TDiPi = TD1G\*TP1G';

**%% Now compute for second frame**

k1d2 = ((Input1(i+1,8)-Input1(i+1,5))\*(Input1(i+1,3)-Input1(i+1,6))) - ((Input1(i+1,2)-  
Input1(i+1,5))\*(Input1(i+1,9)-Input1(i+1,6)));

k2d2 = ((Input1(i+1,9)-Input1(i+1,6))\*(Input1(i+1,1)-Input1(i+1,4))) - ((Input1(i+1,3)-  
Input1(i+1,6))\*(Input1(i+1,7)-Input1(i+1,4)));

k3d2 = ((Input1(i+1,7)-Input1(i+1,4))\*(Input1(i+1,2)-Input1(i+1,5))) - ((Input1(i+1,1)-  
Input1(i+1,4))\*(Input1(i+1,8)-Input1(i+1,5)));

nom1 = sqrt((Input1(i+1,7)-Input1(i+1,4))^2 + (Input1(i+1,8)-Input1(i+1,5))^2 +  
(Input1(i+1,9)-Input1(i+1,6))^2);

nom2 = sqrt((Input1(i+1,1)-Input1(i+1,4))^2 + (Input1(i+1,2)-Input1(i+1,5))^2 +  
(Input1(i+1,3)-Input1(i+1,6))^2);

nom3 = sqrt(k1d2^2+k2d2^2 +k3d2^2);

TD2G = [(Input1(i+1,7)-Input1(i+1,4))/nom1 (Input1(i+1,8)-Input1(i+1,5))/nom1

(Input1(i+1,9)-Input1(i+1,6))/nom1;

(Input1(i+1,1)-Input1(i+1,4))/nom2 (Input1(i+1,2)-Input1(i+1,5))/nom2 (Input1(i+1,3)-  
Input1(i+1,6))/nom2;

k1d2/nom3 k2d2/nom3 k3d2/nom3];



$$k1p2 = ((\text{Input1}(i+1,17)-\text{Input1}(i+1,14)) * (\text{Input1}(i+1,12)-\text{Input1}(i+1,15))) -$$

$$((\text{Input1}(i+1,11)-\text{Input1}(i+1,14)) * (\text{Input1}(i+1,18)-\text{Input1}(i+1,15))));$$

$$k2p2 = ((\text{Input1}(i+1,18)-\text{Input1}(i+1,15)) * (\text{Input1}(i+1,10)-\text{Input1}(i+1,13))) -$$

$$((\text{Input1}(i+1,12)-\text{Input1}(i+1,15)) * (\text{Input1}(i+1,16)-\text{Input1}(i+1,13))));$$

$$k3p2 = ((\text{Input1}(i+1,16)-\text{Input1}(i+1,13)) * (\text{Input1}(i+1,11)-\text{Input1}(i+1,14))) -$$

$$((\text{Input1}(i+1,10)-\text{Input1}(i+1,13)) * (\text{Input1}(i+1,17)-\text{Input1}(i+1,14))));$$

$$\text{nom4} = \text{sqrt}((\text{Input1}(i+1,16)-\text{Input1}(i+1,13))^2 + (\text{Input1}(i+1,17)-\text{Input1}(i+1,14))^2 +$$

$$(\text{Input1}(i+1,18)-\text{Input1}(i+1,15))^2);$$

$$\text{nom5} = \text{sqrt}((\text{Input1}(i+1,10)-\text{Input1}(i+1,13))^2 + (\text{Input1}(i+1,11)-\text{Input1}(i+1,14))^2 +$$

$$(\text{Input1}(i+1,12)-\text{Input1}(i+1,15))^2);$$

$$\text{nom6} = \text{sqrt}(k1p2^2 + k2p2^2 + k3p2^2);$$

$$\text{TP2G} = [(\text{Input1}(i+1,16)-\text{Input1}(i+1,13))/\text{nom4} \quad (\text{Input1}(i+1,17)-\text{Input1}(i+1,14))/\text{nom4}$$

$$(\text{Input1}(i+1,18)-\text{Input1}(i+1,15))/\text{nom4}; (\text{Input1}(i+1,10)-\text{Input1}(i+1,13))/\text{nom5}$$

$$(\text{Input1}(i+1,11)-\text{Input1}(i+1,14))/\text{nom5} \quad (\text{Input1}(i+1,12)-\text{Input1}(i+1,15))/\text{nom5};$$

$$k1p2/\text{nom6} \quad k2p2/\text{nom6} \quad k3p2/\text{nom6}];$$

**%% Compute TdiPix**

$$\text{TDiPi}_x = \text{TD2G} * \text{TP2G}';$$

$$\text{Rdp} = (\text{TD2G} * \text{TP2G}') * (\text{TD1G} * \text{TP1G}');$$

```
rd1= [Input1(i,4) Input1(i,5) Input1(i,6)]';
```

```
rp1 = [Input1(i,13) Input1(i,14) Input1(i,15)]';
```

```
rDP1=TP1G*(rd1-rp1);
```

```
rd2 = [Input1(i+1,4) Input1(i+1,5) Input1(i+1,6)]';
```

```
rp2 = [Input1(i+1,13) Input1(i+1,14) Input1(i+1,15)]';
```

```
rDP2 = TP2G*(rd2-rp2);
```

```
I = [1 0 0; 0 1 0; 0 0 1];
```

```
Pi = I - Rdp;
```

```
Qi = rDP2 - Rdp*rDP1;
```

```
rc1(:,i) = inv(Pi)*Qi;
```

```
Rc1(:,i) = rp1 + TP1G'*rc1(:,i);
```

```
end
```

```
for j = 1:l2-1
```

```
k1d1 = ((Input2(j,8)-Input2(j,5))*(Input2(j,3)-Input2(j,6))) - ((Input2(j,2)-  
Input2(j,5))*(Input2(j,9)-Input2(j,6)));
```

$$k2d1 = ((\text{Input2}(j,9)-\text{Input2}(j,6))*(\text{Input2}(j,1)-\text{Input2}(j,4))) - ((\text{Input2}(j,3)-\text{Input2}(j,6))*(\text{Input2}(j,7)-\text{Input2}(j,4)));$$

$$k3d1 = ((\text{Input2}(j,7)-\text{Input2}(j,4))*(\text{Input2}(j,2)-\text{Input2}(j,5))) - ((\text{Input2}(j,1)-\text{Input2}(j,4))*(\text{Input2}(j,8)-\text{Input2}(j,5)));$$

$$\text{norm1} = \text{sqrt}((\text{Input2}(j,7)-\text{Input2}(j,4))^2 + (\text{Input2}(j,8)-\text{Input2}(j,5))^2 + (\text{Input2}(j,9)-\text{Input2}(j,6))^2);$$

$$\text{norm2} = \text{sqrt}((\text{Input2}(j,1)-\text{Input2}(j,4))^2 + (\text{Input2}(j,2)-\text{Input2}(j,5))^2 + (\text{Input2}(j,3)-\text{Input2}(j,6))^2);$$

$$\text{norm3} = \text{sqrt}(k1d1^2+k2d1^2 +k3d1^2);$$

$$\text{TD1G} = [(\text{Input2}(j,7)-\text{Input2}(j,4))/\text{norm1} \quad (\text{Input2}(j,8)-\text{Input2}(j,5))/\text{norm1} \quad (\text{Input2}(j,9)-\text{Input2}(j,6))/\text{norm1}; \quad (\text{Input2}(j,1)-\text{Input2}(j,4))/\text{norm2} \quad (\text{Input2}(j,2)-\text{Input2}(j,5))/\text{norm2} \quad (\text{Input2}(j,3)-\text{Input2}(j,6))/\text{norm2}; \quad k1d1/\text{norm3} \quad k2d1/\text{norm3} \quad k3d1/\text{norm3}];$$

$$k1p1 = ((\text{Input2}(j,17)-\text{Input2}(j,14))*(\text{Input2}(j,12)-\text{Input2}(j,15))) - ((\text{Input2}(j,11)-\text{Input2}(j,14))*(\text{Input2}(j,18)-\text{Input2}(j,15)));$$

$$k2p1 = ((\text{Input2}(j,18)-\text{Input2}(j,15))*(\text{Input2}(j,10)-\text{Input2}(j,13))) - ((\text{Input2}(j,12)-\text{Input2}(j,15))*(\text{Input2}(j,16)-\text{Input2}(j,13)));$$

$$k3p1 = ((\text{Input2}(j,16)-\text{Input2}(j,13))*(\text{Input2}(j,11)-\text{Input2}(j,14))) - ((\text{Input2}(j,10)-\text{Input2}(j,13))*(\text{Input2}(j,17)-\text{Input2}(j,14)));$$

```
norm4 = sqrt((Input2(j,16)-Input2(j,13))^2 + (Input2(j,17)-Input2(j,14))^2 +
(Input2(j,18)-Input2(j,15))^2);
```

```
norm5 = sqrt((Input2(j,10)-Input2(j,13))^2 + (Input2(j,11)-Input2(j,14))^2 +
(Input2(j,12)-Input2(j,15))^2);
```

```
norm6 = sqrt(k1p1^2+k2p1^2 +k3p1^2);
```

```
TP1G = [(Input2(j,16)-Input2(j,13))/norm4 (Input2(j,17)-Input2(j,14))/norm4
(Input2(j,18)-Input2(j,15))/norm4; (Input2(j,10)-Input2(j,13))/norm5 (Input2(j,11)-
Input2(j,14))/norm5 (Input2(j,12)-Input2(j,15))/norm5; k1p1/norm6 k2p1/norm6
k3p1/norm6];
```

**%% Compute TdiPi**

```
TDiPi = TD1G*TP1G';
```

**%% Now compute for second frame**

```
k1d2 = ((Input2(j+1,8)-Input2(j+1,5))*(Input2(j+1,3)-Input2(j+1,6))) - ((Input2(j+1,2)-
Input2(j+1,5))*(Input2(j+1,9)-Input2(j+1,6)));
```

```
k2d2 = ((Input2(j+1,9)-Input2(j+1,6))*(Input2(j+1,1)-Input2(j+1,4))) - ((Input2(j+1,3)-
Input2(j+1,6))*(Input2(j+1,7)-Input2(j+1,4)));
```

```
k3d2 = ((Input2(j+1,7)-Input2(j+1,4))*(Input2(j+1,2)-Input2(j+1,5))) - ((Input2(j+1,1)-
Input2(j+1,4))*(Input2(j+1,8)-Input2(j+1,5)));
```

$$\text{nom1} = \sqrt{(\text{Input2}(j+1,7)-\text{Input2}(j+1,4))^2 + (\text{Input2}(j+1,8)-\text{Input2}(j+1,5))^2 + (\text{Input2}(j+1,9)-\text{Input2}(j+1,6))^2};$$

$$\text{nom2} = \sqrt{(\text{Input2}(j+1,1)-\text{Input2}(j+1,4))^2 + (\text{Input2}(j+1,2)-\text{Input2}(j+1,5))^2 + (\text{Input2}(j+1,3)-\text{Input2}(j+1,6))^2};$$

$$\text{nom3} = \sqrt{k1d2^2+k2d2^2 +k3d2^2};$$

$$\text{TD2G} = [(\text{Input2}(j+1,7)-\text{Input2}(j+1,4))/\text{nom1} \quad (\text{Input2}(j+1,8)-\text{Input2}(j+1,5))/\text{nom1} \\ (\text{Input2}(j+1,9)-\text{Input2}(j+1,6))/\text{nom1}; \quad (\text{Input2}(j+1,1)-\text{Input2}(j+1,4))/\text{nom2} \quad (\text{Input2}(j+1,2)- \\ \text{Input2}(j+1,5))/\text{nom2} \quad (\text{Input2}(j+1,3)-\text{Input2}(j+1,6))/\text{nom2}; \quad k1d2/\text{nom3} \quad k2d2/\text{nom3} \\ k3d2/\text{nom3}];$$

$$k1p2 = ((\text{Input2}(j+1,17)-\text{Input2}(j+1,14))*(\text{Input2}(j+1,12)-\text{Input2}(j+1,15))) - \\ ((\text{Input2}(j+1,11)-\text{Input2}(j+1,14))*(\text{Input2}(j+1,18)-\text{Input2}(j+1,15)));$$

$$k2p2 = ((\text{Input2}(j+1,18)-\text{Input2}(j+1,15))*(\text{Input2}(j+1,10)-\text{Input2}(j+1,13))) - \\ ((\text{Input2}(j+1,12)-\text{Input2}(j+1,15))*(\text{Input2}(j+1,16)-\text{Input2}(j+1,13)));$$

$$k3p2 = ((\text{Input2}(j+1,16)-\text{Input2}(j+1,13))*(\text{Input2}(j+1,11)-\text{Input2}(j+1,14))) - \\ ((\text{Input2}(j+1,10)-\text{Input2}(j+1,13))*(\text{Input2}(j+1,17)-\text{Input2}(j+1,14)));$$

$$\text{nom4} = \sqrt{(\text{Input2}(j+1,16)-\text{Input2}(j+1,13))^2 + (\text{Input2}(j+1,17)-\text{Input2}(j+1,14))^2 + (\text{Input2}(j+1,18)-\text{Input2}(j+1,15))^2};$$

$$\text{nom5} = \sqrt{(\text{Input2}(j+1,10)-\text{Input2}(j+1,13))^2 + (\text{Input2}(j+1,11)-\text{Input2}(j+1,14))^2 + (\text{Input2}(j+1,12)-\text{Input2}(j+1,15))^2};$$

$$\text{nom6} = \sqrt{k1p2^2+k2p2^2 +k3p2^2};$$

```

TP2G = [(Input2(j+1,16)-Input2(j+1,13))/nom4 (Input2(j+1,17)-Input2(j+1,14))/nom4
(Input2(j+1,18)-Input2(j+1,15))/nom4;(Input2(j+1,10)-Input2(j+1,13))/nom5
(Input2(j+1,11)-Input2(j+1,14))/nom5 (Input2(j+1,12)-Input2(j+1,15))/nom5;
k1p2/nom6 k2p2/nom6 k3p2/nom6];

```

### %% Compute TdiPix

```

TDiPi_x = TD2G*TP2G';

```

```

Rdp = (TD2G*TP2G')*(TD1G*TP1G');

```

```

rd1 = [Input2(j,4) Input2(j,5) Input2(j,6)]';

```

```

rp1 = [Input2(j,13) Input2(j,14) Input2(j,15)]';

```

```

rDP1=TP1G*(rd1-rp1);

```

```

rd2 = [Input2(j+1,4) Input2(j+1,5) Input2(j+1,6)]';

```

```

rp2 = [Input2(j+1,13) Input2(j+1,14) Input2(j+1,15)]';

```

```

rDP2 = TP2G*(rd2-rp2);

```

```

I = [1 0 0; 0 1 0; 0 0 1];

```

```

Pi = I - Rdp;

```

```

Qi = rDP2 - Rdp*rDP1;

```

```
rc2(:,j) = inv(Pi)*Qi;

Rc2(:,j) = rp1 + TP1G'*rc2(:,j);

end

%figure(1);

%k = [1:l-1]';

%plot(k,Rc1(1,:),r*');

%figure(2);

%k1 = [1:l2-1]';

%plot(k1,Rc2(1,:),b*')

%hold on;

%k1 = [1:l2-1]';

%plot(k1,Rc2(1,:),b*')

%figure(3);

%k = [1:l-1]';

%plot(k,Rc1(2,:),r*');

%figure(4);

%k1 = [1:l2-1]';

%%plot(k1,Rc2(2,:),b*')

%hold on;

%k1 = [1:l2-1]';

%plot(k1,Rc2(2,:),b*')
```

```
%figure(5);  
  
%k = [1:l-1]';  
  
%plot(k,Rc1(3,:),r*');  
  
%figure(6);  
  
%k1 = [1:l2-1]';  
  
%plot(k1,Rc2(3,:),b*')  
  
figure(1);  
  
X1 = Rc1(1,:);  
  
Y1 = Rc1(2,:);  
  
Z1 = Rc1(3,:);  
  
x1 = X1(1:1:end);  
  
y1 = Y1(1:1:end);  
  
z1 = Z1(1:1:end);  
  
plot3(x1,y1,z1,'o');  
  
hold on;  
  
X2 = Rc2(1,:);  
  
Y2 = Rc2(2,:);  
  
Z2 = Rc2(3,:);  
  
x2 = X2(1:1:end);  
  
y2 = Y2(1:1:end);  
  
z2 = Z2(1:1:end);  
  
plot3(x2,y2,z2,'go');  
  
figure(2);
```



```
plot(x1,y1,'o');
hold on;
plot(x2,y2,'go');
figure(3);
plot(y1,z1,'o');
hold on;
plot(y2,z2,'go');
figure(4);
plot(x1,z1,'o');
hold on;
%plot(x2,z2,'go');
%hold on;
%k1 = [1:l2-1]';
%plot(k1,Rc2(3,:), 'b*')
%plot(k,Rc1,'ro')
%hold on;
%plot(k,rc2,'go');
%figure 2;
%plot(k,Rc1, '*');
%hold on;
%k1 = [1:l2-1]';
%plot(k1,Rc2(1,:), 'o');
%plot(k1,Rc2, 'o')
```