

Yale University

EliScholar – A Digital Platform for Scholarly Publishing at Yale

Yale Medicine Thesis Digital Library

School of Medicine

11-3-2009

Aesthetics of the Female Breast: Correlation of Pluralistic Evaluations with Volume and Surface Area

Yuen-Jong Liu

Follow this and additional works at: <http://elischolar.library.yale.edu/ymtdl>

Recommended Citation

Liu, Yuen-Jong, "Aesthetics of the Female Breast: Correlation of Pluralistic Evaluations with Volume and Surface Area" (2009). *Yale Medicine Thesis Digital Library*. 172.

<http://elischolar.library.yale.edu/ymtdl/172>

This Open Access Thesis is brought to you for free and open access by the School of Medicine at EliScholar – A Digital Platform for Scholarly Publishing at Yale. It has been accepted for inclusion in Yale Medicine Thesis Digital Library by an authorized administrator of EliScholar – A Digital Platform for Scholarly Publishing at Yale. For more information, please contact elischolar@yale.edu.

Aesthetics of the Female Breast:
Correlation of Pluralistic Evaluations with Volume
and Surface Area

A Thesis Submitted to the
Yale University School of Medicine
in Partial Fulfillment of the Requirements for the
Degree of Doctor of Medicine

by

Yuen-Jong Liu

M.D. Candidate 2009

Aesthetics of the Female Breast: Correlation of Pluralistic Evaluations with Volume and Surface Area. Yuen-Jong Liu, Richard J. Restifo, Brian D. Rinker, Andrew Reis, and J. Grant Thomson. Section of Plastic and Reconstructive Surgery, Department of Surgery, Yale University School of Medicine, New Haven, CT.

Abstract

The goal of cosmetic and reconstructive breast surgery is to fashion symmetric breasts with aesthetically acceptable shapes. Breast shape is largely determined by volume of tissue and surface area of the skin envelope. Values for breast surface area have never been published in the literature. The investigators developed an inexpensive, non-invasive optical method to objectively measure breast volume and surface area. The aims were to validate the method, to assess the accuracy of visual inspection by plastic surgeons, to determine ideal anthropomorphic measurements, and to derive a mathematical relationship between volume and surface area for an aesthetically acceptable shape.

In the novel method, an optical grid was projected onto each breast and two images were captured in order to create a computerized three-dimensional model from which volume (V), surface area (A), and maximum vertical projection (Z) were calculated. The method was used to measure volume and surface area of the breasts of female volunteers. Anthropomorphic measurements were also recorded. Images of their breasts were arranged into a computerized survey, and plastic surgeons, cosmetic patients, and reconstructive patients were interviewed for aesthetic feedback.

The method was validated on geometric shapes and female breasts. Simple geometric shapes ($n = 22$) were analyzed, and the actual V , A , and Z were compared with the imaged values using least-squares linear regression. There was excellent correlation in all three parameters ($R > 0.995$, $p < 10^{-14}$). The mean differences in V , A , and Z were 28 ± 28 mL (mean \pm SD), 2 ± 9 cm², and 0.4 ± 0.5 cm, respectively. Female breasts ($n = 14$) were analyzed, and the actual V and A were measured using plaster casts. Based on least-squares linear regression, there was excellent correlation between the imaged values and actual values ($R > 0.992$, $p < 10^{-11}$), and the mean differences in V and A were 32 ± 22 mL and 3 ± 11 cm², respectively.

The breasts of 109 female volunteers were measured and included for aesthetic evaluation. 252 plastic surgeons, 15 cosmetic patients, and 25 reconstructive patients submitted totals of 3,641, 368, and 437 evaluations, respectively. On average, plastic surgeons underestimated volume by $7\% \pm 49\%$ (mean \pm SD) and overestimated surface area by $15\% \pm 69\%$. Ideal anthropomorphic measurements and volume to surface area ratios were calculated and compared to previously published values. Cosmetic patients were most attentive to insufficient cleavage, and reconstructive patients were most attentive to severe asymmetry.

For the first time, an optical method was demonstrated to measure volume and surface area with accuracy. When applied to the breast, measurement errors were small and clinically insignificant. Plastic surgeons were more accurate in estimating volume than surface area, though showing significant inconsistencies in both parameters from one breast to the next. Ideal anthropomorphic measurements were similar among plastic surgeons and breast surgery patients. Reconstructive patients preferred higher volume to surface area ratios than plastic surgeons and cosmetic patients.

Acknowledgments

The work described herein was performed in the Section of Plastic Surgery, Department of Surgery, Yale University School of Medicine, New Haven, CT. The authors would like to thank Dana Reiver, M.D., Liane Philpotts, M.D., Pia Ali-Salaam, M.D., Maureen Lynch, Elena Barnard, Denise Ferraiuolo, and Yuen-Joyce Liu for their assistance with this project. The thesis author would like to especially acknowledge J. Grant Thomson, M.D., for his mentorship.

Parts of this research were presented at the annual meetings of the Plastic Surgery Research Council (poster) in New York City, New York, May 1995, the New England Society of Plastic and Reconstructive Surgeons in Boston, Massachusetts, June 1995, the Northeastern Society of Plastic Surgeons in Boston, Massachusetts, November 1995, and the New England Society of Plastic and Reconstructive Surgeons in Manchester Village, Vermont, June 2008.

The first phase of this research was accepted for publication in *Plastic and Reconstructive Surgery* in October 2008. A manuscript for the second phase is in preparation.

This research was supported by an Ohse Research Grant from the Department of Surgery at Yale University School of Medicine, a James G. Hirsch, M.D., Endowed Medical Student Research Fellowship, and a Yale University School of Medicine Medical Student Research Fellowship.

Contents

1	Introduction	1
2	Purpose	9
2.1	Specific Aims	9
2.2	Hypotheses	9
3	Methods	10
3.1	Breast Imaging	10
3.2	Computerized Three-Dimensional Model	11
3.3	Validation on Geometric Solids	14
3.4	Validation on Human Female Subjects	14
3.5	Repeatability	16
3.6	Breast Imaging Subjects	17
3.7	Aesthetic Evaluation of the Breast	19
3.8	Evaluator Recruitment	19
3.9	Ideal Anthropomorphic Measurements	21
3.10	Ideal Volume to Surface Area Ratio	21
3.11	Asymmetry and Cleavage	23
4	Results	24
4.1	Validation on Geometric Solids	24
4.2	Validation on Human Female Subjects	24
4.3	Repeatability	25
4.4	Evaluator Recruitment and Subject Evaluations	26
4.5	Accuracy of Visual Estimation	27
4.6	Ideal Anthropomorphic Measurements	28
4.7	Ideal Volume to Surface Area Ratio	28
4.8	Asymmetry and Cleavage	33
5	Discussion	34
6	Conclusions	42
	References	43

1 Introduction

Breasts play an important role in human sexual behavior and are the most visible of the female secondary sex characteristics. No female mammal other than the human has breasts of comparable size in proportion to the rest of the body when not lactating. Moreover, humans are the only primates in which female breasts are permanently enlarged. As the source of life-supporting milk, breasts are considered signs of fertility and have been emphasized throughout history in all forms of art (Figure 1).



Figure 1: Breasts in Art

At the left, the Venus of Willendorf is a 11.1-cm high statuette of an idealized female figure, also known as a Venus figurine, created around 24,000 B.C.–22,000 B.C., in which the breasts, along with the vulva and abdomen, are exaggerated, suggesting an emphasis on fertility. In the middle, one of the most famous works of ancient Greek sculpture, *Venus de Milo* is a 2.03-m high statue representing an ideal of grace and beauty with the breasts exposed. On the right, in *La Liberté guidant le peuple* (*Liberty Leading the People*), a painting by Eugène Delacroix commemorating the French Revolution of 1830, Liberty personified is depicted with unconcealed bosom, a politically significant reference to bourgeois norms of maternal breastfeeding.

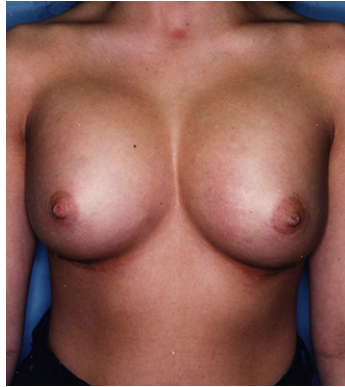

Figure 2: Breast Augmentation

Breast augmentation receives a great deal of public media attention. Techniques have evolved from primitive procedures such as autologous lipoma grafting and paraffin implantation to modern implantation of saline and silicone gel capsules.

No procedure in plastic surgery has received greater scrutiny and controversy, both scientific and political, than breast augmentation (Figure 2). Over 2 million American women, or 1% of the adult female population, have artificial breast implants. Augmentation mammoplasty is the second most commonly performed cosmetic surgical procedure in the United States [1].

Reconstructive breast surgery is also performed to correct many types of congenital and acquired deformities. These may involve the breast mounds themselves, in cases of hyperplasia, hypoplasia, and amastia. Deformities may also extend into underlying structures, such as the pectoralis muscles in Poland syndrome (Figure 3), the rib cage in pectus carinatum and excavatum, and the spine in scoliosis. Varying amounts of asymmetry can be diagnosed, from a small amount that may be easily masked by clothing to severe amounts that prompt reconstruction. Deformities of the breasts may be acquired, often iatrogenically. They may result from biopsy, lumpectomy, or irradiation of the developing breast. Trauma and mastectomy may also produce significant defects. Reconstructive breast surgery is frequently performed after a radical or modified radical mastectomy (Figure 4).

The primary goal of cosmetic and reconstructive breast surgery is to fashion symmetric breasts with natural or aesthetically acceptable shapes, from either autologous tissues

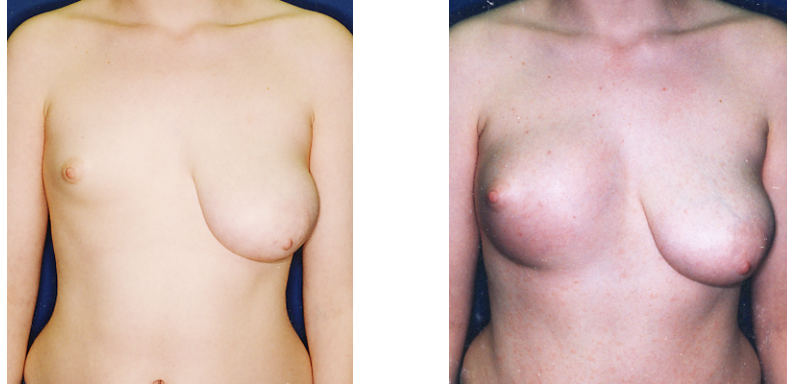


Figure 3: Poland Syndrome with Significant Asymmetry

Poland syndrome represents a congenital defect involving the unilateral underdevelopment or absence of the breast and pectoralis muscles. Reconstructive breast surgery can be performed to correct the original asymmetry (left) to improve the external appearance in clothing (right).

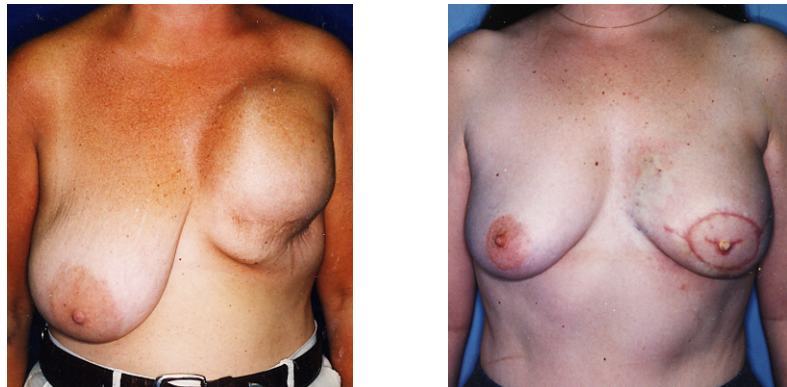


Figure 4: Post-Mastectomy Reconstruction

After mastectomy for breast cancer, the affected breast can be reconstructed with an artificial implant (left) or autologous tissue (right) as in a transverse rectus abdominis myocutaneous (TRAM) flap reconstruction. The goal is usually to restore the pre-mastectomy appearance in clothing.

or artificial implants. The surgery must first compensate for any pre-operative chest wall asymmetry [2]. A significant problem following breast reconstruction is that 40% of patients may have an asymmetry of breast shape and 23% may have an asymmetry in breast size [3]. Post-operative breast asymmetry is one of the more common problems following reduction mammoplasty [4]. Because breast shape is a complex three-dimensional feature, one-dimensional anthropomorphic measurements, while useful for an initial approximation, may not provide sufficient information to completely describe breast shape. Volume

and surface area are also crucial in the planning and execution of breast surgery.

In the past, other investigators have attempted to define standards for anthropomorphic measurements both subjectively and quantitatively [5, 6, 7, 8]. In 1955, Penn used 20 female volunteers whom he considered aesthetically perfect, basing his ideal values on an individual perspective [5]. In 1986, Smith used 55 “normal” female volunteers without any aesthetic judgment to obtain average linear measurements of the breast [6]. However, robustness mandates aesthetic feedback from multiple sources, in order to define acceptable aesthetic standards representative of cosmetic and reconstructive patients and to distinguish any possible biases harbored by plastic surgeons.

Methods for objectively measuring breast volume have been unreliable, inconvenient, or expensive. In the women’s underwear industry, bras are labeled with a number indicating the length of the band encircling the thorax and a letter indicating the depth of the cups which cradle the breasts. Though often used, cup sizes ranging from AA to D and beyond comprise an unreliable measure of volume, as a C-cup may vary from 200 cc to 900 cc depending on the woman’s chest circumference (Figure 5). Plaster casts of breasts have been molded and filled with sand, whose weight is divided by its density to yield volume [6, 9, 10, 11]. This method has been reliable as a “gold standard” of volume measurement in experimental studies, but the mess and discomfort incurred upon the patient precludes its routine clinical application, especially for pendulous breasts, which may prove difficult to extract from hardened casts. Another salient volumetric method has relied on the measurement of water volume displaced by immersing the breasts, or an alternative variation of Archimedes’ principle, but the technique involves significant compression or other distortion of the breasts (Figure 6) [12, 13, 14, 15, 16, 17]. Other methods have purposely distorted the breasts to assist volume measurement [18, 19, 20] with questionable validity (Figure 7) [11, 21]. Non-contact methods such as magnetic resonance imaging [22, 23], stereo photography [7, 8, 24, 25, 26, 27], and laser scanning [23] have been limited by expense and the need for a precise geometric apparatus. Thus, for the sake of convenience,

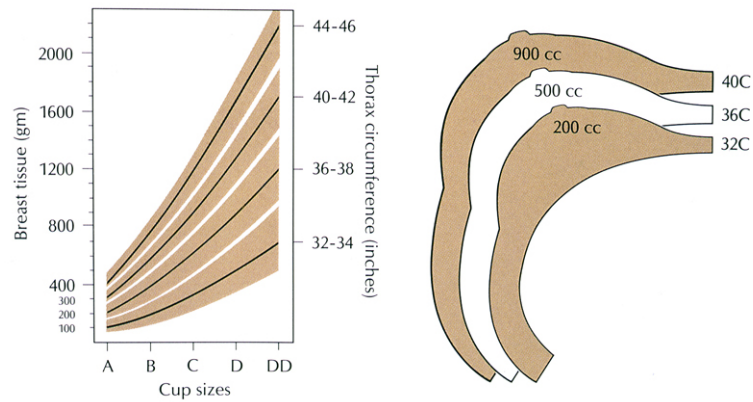


Figure 5: Volume Measurement by Bra Sizes

Bra size constitutes an unreliable measure of breast volume, as each bra cup letter varies over a broad range of volumes depending on chest circumference.

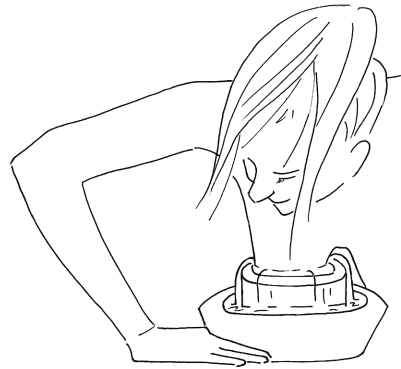


Figure 6: Volume Measurement by Water Displacement

This method requires a certain level of acrobatics to achieve appropriate positioning to immerse the breast, and the breast may become compressed or distorted.

most breast surgeries are performed with only a visual estimation of breast volume. Since breasts with different volumes can have equally aesthetically pleasing shapes, volume measurement alone is insufficient to classify their aesthetic value.

Most plastic surgeons have ignored the systematic measurement or estimation of surface area of the breast. The importance of surface area in determining breast shape has been noted since the early history of breast surgery when the concept of the “skin brassiere” was introduced by Aufrecht in 1949 [28]. Given a certain volume, the breast may vary across a broad range of shapes with a correspondingly broad range of aesthetic values: ptotic with high surface area, round with moderate surface area, or constricted with low surface

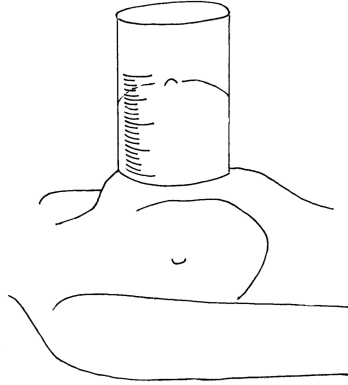


Figure 7: Volume Measurement by Graduated Cylinder

A breast is compressed and distorted to fit within a graduated cylinder, with notable discomfort to the subject, and the aberration in tissue volume from manipulation is difficult to ascertain.

area. Most breast reductions are currently performed using a skin envelope design originally based on a pattern employed by bra manufacturers [29, 30]. Many publications have emphasized the importance of an adequate skin envelope [31, 32, 33, 34, 35], but the literature still lacks standard values for breast surface area and quantitative information to guide the surgeon in designing the skin envelope. Furthermore, surface area measurement either has not been possible or has not been attempted with any previously described technique. Of the aforementioned volumetric techniques, plaster casting may conceptually be adapted for surface area measurement by quantifying the area of the internal surface of a cast. However, this technique is messy and uncomfortable for the surgeon and the subject, and alternatives should be explored.

In this experiment, a simple, inexpensive, non-invasive optical method was developed to quantify breast volume and surface area, addressing the shortcomings of the extant techniques described previously. The method did not require complicated geometric alignment and provided accurate quantitative measurements of volume and surface area without contact or distortion.

In order to visualize the entire breast surface, subjects must be analyzed while prone. When the subject is upright, ptosis may occlude full visualization of the inferior surface

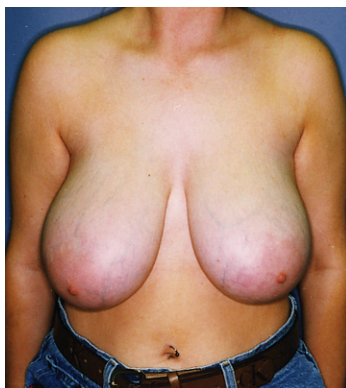

Figure 8: Ptosis

In the upright position, ptosis of the breasts, especially pendulous breasts, obscures a significant portion of the surface area between the base of the breast and the inframammary fold. Therefore, the novel optical method developed in this study analyzes the breasts in a prone position to visualize that surface area.

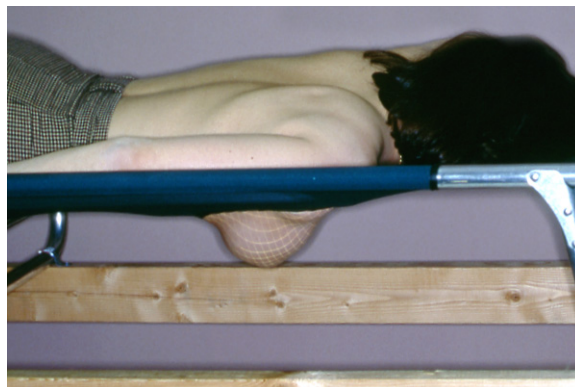
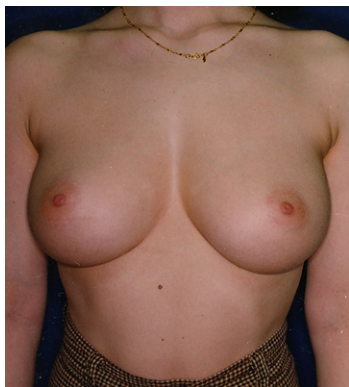

Figure 9: Gravitational Retraction

From the upright position to the prone position in the same subject, gravity retracts the breast from the chest wall with minimal deformity.

of the breast (Figure 8). In the prone position, the breast retracts from the chest wall by hanging to gravity, and the entire skin surface may be visualized in a standardized fashion, free from significant deformity (Figure 9). Prior to using this method to answer clinical questions, it was necessary to validate its accuracy in measuring the parameters of interest, namely, volume, surface area, and maximum vertical projection. After the technique was proven to be accurate in the measurement of these parameters in geometric solids, it was demonstrated on the female breast to yield the same measurements in the prone position as in the upright position, using plaster casting as the control technique.

With the validation of the optical method, normal female subjects were recruited so that their breasts could be photographed and measured. The photographs were shown to plastic surgeons, cosmetic breast surgery patients, and reconstructive breast surgery patients to obtain quantitative and aesthetic evaluations based on pluralistic feedback. The aesthetic evaluations were statistically correlated to the anthropomorphic measurements, volume, and surface area of the subjects' breasts, unilaterally and bilaterally. Thus, it was possible to assess the accuracy with which plastic surgeons visually estimated breast volume and surface area, to determine ideal anthropomorphic measurements and volume to surface area ratios describing an aesthetically acceptable breast as perceived by plastic surgeons, cosmetic patients, and reconstructive patients, and to identify anatomical features that most influenced the aesthetic evaluation as perceived by these three groups.

2 Purpose

2.1 Specific Aims

The goals of this study were

1. to validate a new method of breast volume and surface area measurement by measuring geometric solids and actual female breasts in prone and upright positions,
2. to assess the accuracy with which plastic surgeons estimate breast volume and surface area by visual inspection,
3. to determine the anthropomorphic measurements of an aesthetically acceptable breast shape, and
4. to determine the relationship between breast volume and surface area that would result in an aesthetically acceptable breast shape, with the ultimate goal of optimizing patient satisfaction in cosmetic and reconstructive breast surgeries.

2.2 Hypotheses

The null hypotheses were that the optical method could not be validated, that plastic surgeons would have no accuracy in estimating breast volume and surface area by visual inspection, and that there would not exist any consistent ideals in anthropomorphic measurements, volume, and surface area. As alternative hypotheses, the investigators posited that the optical method could be validated within clinically insignificant error, that plastic surgeons would be highly accurate in estimating breast volume by visual inspection but less accurate in estimating breast surface area because of greater historical focus on volume, and that an ideal set of anthropomorphic measurements and volume to surface area ratio could be determined with statistical significance.

3 Methods

This study was conducted in two phases. In the first phase, the novel optical method was validated. Most of the initial work was performed by J. Grant Thomson, M.D., Richard J. Restifo, M.D., Brian D. Rinker, M.D., and Andrew Reis, M.D., with some data analysis by Yuen-Jong Liu. In the second phase, pluralistic aesthetic evaluations were collected and correlated to objective measurements, and most of the work was performed by Yuen-Jong Liu, under guidance from J. Grant Thomson, M.D.

3.1 Breast Imaging

Each breast was imaged separately. While the subject lay prone on an examining table, one breast was allowed to project dependently to gravity through an opening in the table (Figure 10). A slide projector projected a lattice grid of light onto the breast at a right angle after reflecting off a mirror below the table. The projector was adjusted so that each edge of the grid was 1 cm where it intersected the under-surface of the table. The grid was distorted by the curvature of the breast, and this information was captured by two video cameras positioned cranially and caudally. Any viewing angle apart from 90° provided information about the depth of breast tissue at each vertex of the grid. An angle of 45° was usually approximated. Positioning and alignment of the cameras and the subject were not crucial as image analysis automatically compensated through trigonometric calculations on common landmarks.

The images were transferred through an analog-to-digital converter (Computer Eyes/RT SCSI Video Frame Grabber by Digital Vision, Inc.) to an ordinary personal computer (Apple Macintosh PowerBook) as PICT files. The total time to image four images of two breasts was approximately one minute, including the time used to position the subject.

The optical method was developed and implemented by J. Grant Thomson, M.D., Richard J. Restifo, M.D., Brian D. Rinker, M.D., and Andrew Reis, M.D.

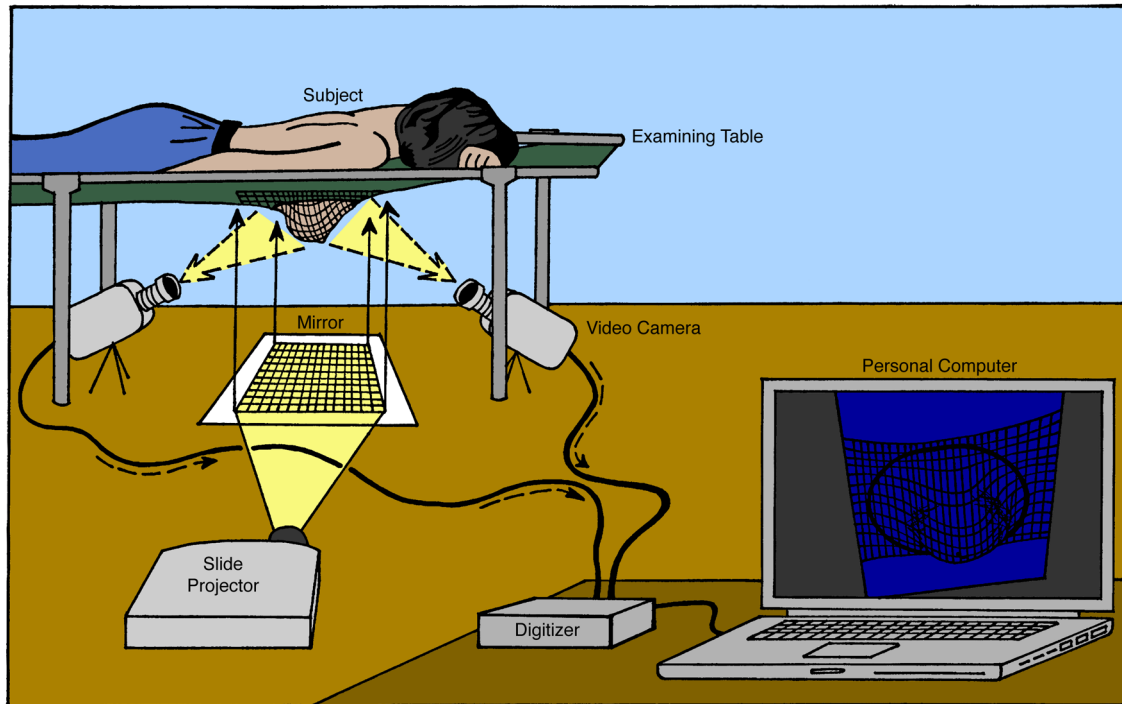


Figure 10: Breast Imaging Setup

The imaging apparatus consisted of a table with an opening, through which one breast was allowed to project dependently to gravity. The image of a lattice grid was projected horizontally to reflect off a mirror under the table and thus illuminate the breast. The magnification of the grid was adjusted so that each edge measured 1 cm on the under-surface of the table. The grid was distorted by the curved surface of the breast. Two video cameras captured images directly into a computer. Analysis of the digitized image provided the tissue depth at each vertex of the grid.

3.2 Computerized Three-Dimensional Model

The PICT files were processed by a computer program written in Perl v5.8.8¹, using a thinning algorithm to reduce the grid to one-pixel width. The precise intersections were labeled in ImageJ v1.38², where first the images were scaled from pixels to centimeters, such that each edge measured 1 cm, and then vertices of the grid were labeled by manually clicking the pixel locations.

The viewing angles of each video camera were calculated from three coordinates along one side of the lattice grid. In Equations 1–3, the actual vertical projection $z_{i,j}$ of the vertex

¹Source code is available upon request.

²ImageJ is public domain software free available from the NIH at <http://rsb.info.nih.gov/ij/>.

at the i -th row and j -th column ($i, j \in \{1, 2, \dots, 25\}$, rows were enumerated from bottom to top and columns from left to right) was calculated from the angle of elevation of the video camera θ and vertical distance within the image $z'_{i,j}$ between the vertex and the first row. Here, distances were measured in millimeters and f was an intermediate value in the calculation.

$$\theta = \sin^{-1} \frac{(z'_{25,1})^2}{480(z'_{25,1} - z'_{13,1})} \quad (1)$$

$$f = \frac{(z'_{25,1} - z'_{13,1}) \cdot 240 \cos \theta}{2z'_{13,1} - z'_{25,1}} \quad (2)$$

$$z_{i,j} = \frac{\left(z'_{i,j} - \frac{z'_{25,1}}{2}\right) \cdot \left(1 + \frac{i \cos \theta}{f}\right) - \left(i - \frac{240(z'_{25,1} - z'_{13,1})}{z'_{25,1}}\right) \sin \theta}{\cos \theta + \frac{\left(z'_{i,j} - \frac{z'_{25,1}}{2}\right) \sin \theta}{f}} \quad (3)$$

These equations were implemented in Microsoft QuickBASIC v1.00E³ (for Apple Macintosh computers) run under Apple System 7.5.⁴ emulated in Basilisk II v1.0 port 19b⁵ on Mac OS X 10.5. The vertices were transformed into a computerized three-dimensional model of the breast and chest wall. The boundary between breast mound and chest wall was identified by comparing the digital images and photographs, and grid squares within the boundary were highlighted on the model in order to be measured for breast volume, surface area, and maximum vertical projection (Figure 11). The position of the underlying chest wall could not be determined exactly without computerized radiography. Therefore, the chest wall contour was approximated by connecting grid lines at the superior and inferior limits of the previously-determined breast boundary, and the height of the contour was subtracted from the height of the model to yield the vertical projection of each vertex from the chest wall. The maximum vertical projection was recorded. In Equation 4, the volume

³Source code is available upon request.

⁴Available from Apple at http://download.info.apple.com/Apple_Support_Area/Apple_Software_Updates/English-North_American/Macintosh/System/Older_System/System_7.5_Version_7.5.3/.

⁵Available at http://www.users.bigpond.com/pear_computers/BasiliskII.html.

Description: Subject 31 - Left Breast
 Total surface area is 263 square centimeters
 Total volume is 429 milliliters
 Maximum projection is 5.97 centimeters

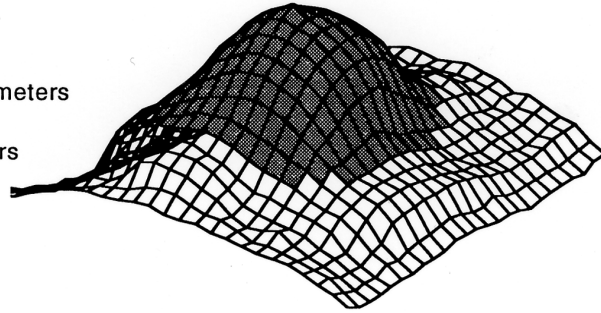


Figure 11: Computerized Three-Dimensional Model

This screenshot of the image analysis shows the quantitative analysis and the computerized model which could be rotated in two planes. In this view, the head of the subject was located beyond the lower left edge. The shaded area was defined by human input during the data analysis by superimposing the boundary of the breast on the digitized image. It corresponded to the part of the computerized model from which volume and surface area were measured. The actual volume and surface area measured from the plaster cast of this breast were 404 mL and 263 cm², respectively.

over each grid square was calculated by considering it as a square prism with an uneven top, where the length of each side of the base was b and h_1 , h_2 , h_3 , and h_4 were the heights at the lower left, lower right, upper left, and upper right corners, respectively.

$$V = b^2 \left(\frac{1}{3}h_1 + \frac{1}{6}h_2 + \frac{1}{3}h_3 + \frac{1}{6}h_4 \right) \quad (4)$$

The surface area was calculated by dividing each quadrilateral of the grid into two triangles, the area of which was calculated from the length of the three sides, a , b , and c , and their average $s = \frac{a+b+c}{2}$, by Hero's formula as in Equation 5.

$$A = \sqrt{s(s-a)(s-b)(s-c)} \quad (5)$$

The total volume and the total surface area were recorded. The total cost of examining table, video cameras, and digital interface was less than \$2,000 in 1993, and the total cost for an equivalent setup using today's technology is expected not to exceed \$500.

The Perl program was written by Yuen-Jong Liu. The QuickBASIC programs were written by J. Grant Thomson, M.D.



Figure 12: Validation on Geometric Solids

Geometric solids such as this truncated cone were analyzed in the same fashion as a breast, protruding through the undersurface of the examining table to receive a projected lattice grid of light.

3.3 Validation on Geometric Solids

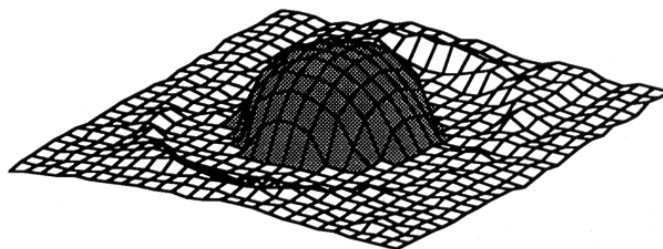
The optical method and subsequent computer image analysis were applied to geometric solids (Figures 12 and 13), including hemispheres, cones, and truncated cones, whose actual volume, surface area, and maximum vertical projection could be calculated exactly by mathematical formulas. Hemispheres were made from hemisected styrofoam balls. Cones were made from cardboard, and truncated cones were constructed as closer approximations to the shape of a breast. Height, base diameter, and apex diameter were varied to generate a range of sizes and shapes.

Validation on geometric solids was performed by J. Grant Thomson, M.D., Richard J. Restifo, M.D., Brian D. Rinker, M.D., and Andrew Reis, M.D.

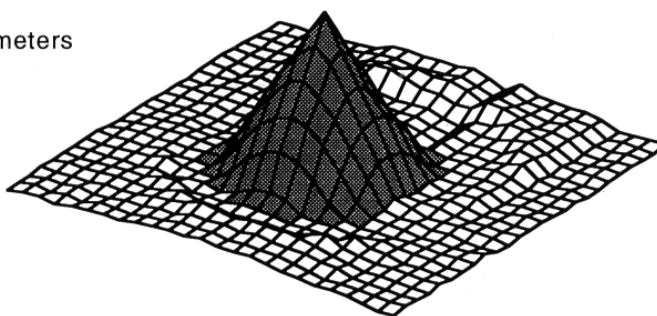
3.4 Validation on Human Female Subjects

Under an IRB-approved protocol, volunteers were recruited through classified advertisements for breast surface imaging. Those whose breast geometry allowed application of

Description: Dome - 10 cm
 Total surface area is 162 square centimeters
 Total volume is 240 milliliters
 Maximum projection is 4.53 centimeters



Description: Cone - 11 cm sides
 Total surface area is 194 square centimeters
 Total volume is 279 milliliters
 Maximum projection is 8.77 centimeters



Description: Truncated Cone 8-7.6-4
 Total surface area is 167 square centimeters
 Total volume is 216 milliliters
 Maximum projection is 7.55 centimeters

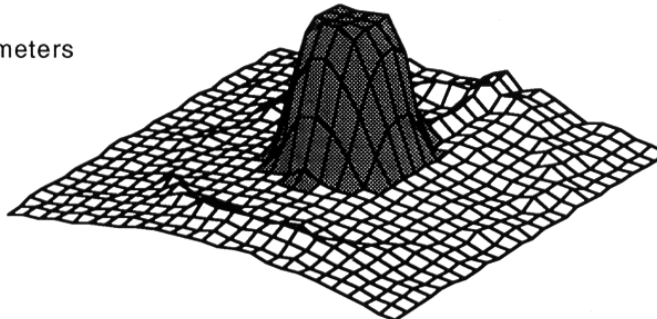


Figure 13: Validation on Geometric Solids

Computerized three-dimensional models were generated on hemispheres, cones, and truncated cones to calculate volume, surface area, and maximum vertical projection. These measurements validated against mathematically calculated values.

plaster casts were recruited for the second stage of validation of the optical method. Extremely pendulous breasts were excluded because the inaccessibility of breast surface obscured between the base and inframammary fold prevented the application and subsequent removal of plaster casts without causing discomfort to the subject or damage to the cast. Imaging measurements were taken in the prone position and compared with plaster cast

measurements taken in the upright position. Casts were made according to previously published techniques (Figure 14) [9]. In brief, a thick layer of petroleum jelly was applied to the skin to prevent adherence of the plaster. As the patient stood upright, three to four layers of four-inch plaster strips were applied, diligently avoiding excess pressure that would cause distortion. After the plaster had hardened, the cast was removed and the breast boundary was outlined on its inside surface. Volume was initially measured by filling the casts with sand and weighing the sample. However, the sand could be compacted to varying degrees, and therefore, its density did not remain constant. Modeling clay (Play-Doh from Tonka Corporation, Playskool, Inc.) was found to be non-compactable and more amenable to volume measurement. The clay was pressed into the mold following the chest wall contour. The weight of the sample was then divided by the density (1.30 g/mL) to obtain the volume.

Surface area of the plaster casts was measured by a tiled method (Figure 15). The entire interior surface was manually divided into small triangles with a felt-tip pen. The length of each edge was measured by a small ruler. The total surface area was calculated from application of Hero's formula (Equation 5) on each triangle.

Anterior projection was not measured from the plaster casts since this was conceptually a different parameter from vertical projection in the prone position.

Statistical analysis was performed using least-squares linear regression.

Validation on human female subjects was performed by J. Grant Thomson, M.D., Richard J. Restifo, M.D., Brian D. Rinker, M.D., and Andrew Reis, M.D.

3.5 Repeatability

One volunteer was imaged on three distinct occasions to demonstrate repeatability of the optical method under the same procedures and conditions.

Imaging was performed by J. Grant Thomson, M.D. Statistical analysis demonstrating the repeatability of the optical method was performed by Yuen-Jong Liu.

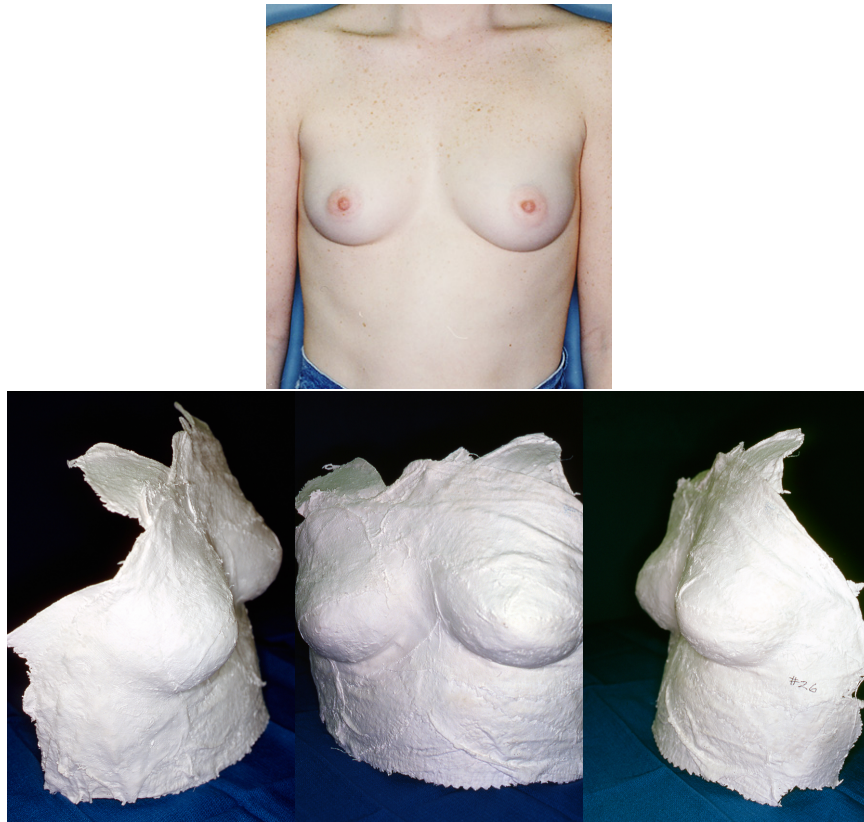

Figure 14: Plaster Casting

In order to validate the accuracy of the novel optical method, volume and surface area were calculated using plaster casts made by previously published techniques. The same breasts were then measured by the optical method and compared to the “gold standard” of plaster casting. The photos show right lateral, anterior, and left lateral views of such a plaster cast of the subject above.

3.6 Breast Imaging Subjects

Breast images and measurements were collected from 109 volunteers through an IRB-approved protocol. For each volunteer, five upright photographs (right lateral, right oblique, anterior, left oblique, and left lateral) were taken of the breasts while she stood in the upright position, and the standard anthropomorphic measurements of the breasts were recorded from distances between sternal notch, mid-clavicle, nipples, sternum, breast base, inframammary fold, and anterior axillary line (Figure 16). The diameters of the areolae were also recorded. In addition, four prone photographs were taken of each volunteer using the novel optical method for volume and surface area.

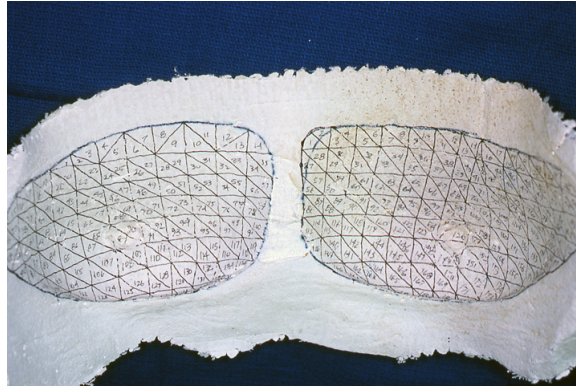


Figure 15: Surface Area Measurement by Plaster Casting

Surface area was calculated by manually partitioning the interior surface of the plaster cast into small triangles, whose areas were calculated by Hero's formula.

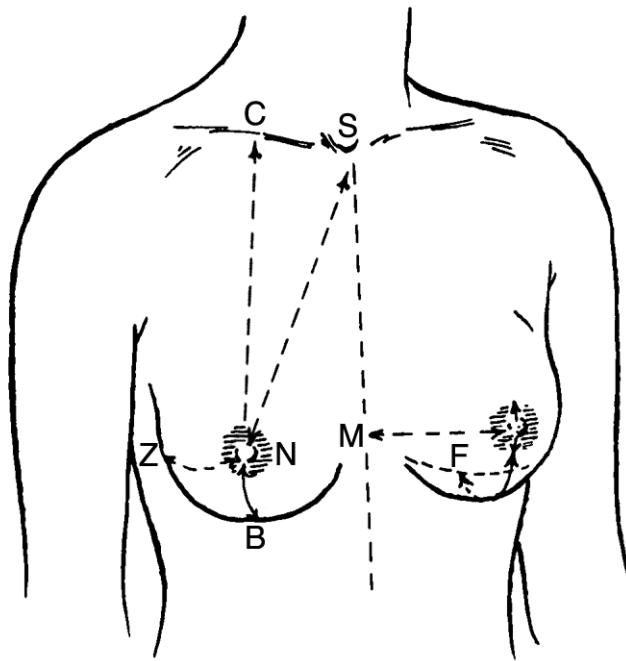


Figure 16: Standard Anthropomorphic Measurements

The standard anthropomorphic measurements of the breast are measured between these labeled landmarks: sternal notch (S), mid-clavicle (C), nipples (N), sternum (M), breast base (B), inframammary fold (F), and anterior axillary line (Z).

Images and anthropomorphic measurements were gathered by J. Grant Thomson, M.D., Richard J. Restifo, M.D., Brian D. Rinker, M.D., and Andrew Reis, M.D. The computer image processing involved in the optical method was performed by Yuen-Jong Liu.

3.7 Aesthetic Evaluation of the Breast

For each pair of breasts, the set of five upright photographs were scanned, resized, cropped, and arranged into a computerized survey programmed in PHP and MySQL⁶ hosted on an Apple PowerMac G4 computer running Mac OS X 10.4 set up as a webserver. Of the right and left breasts individually, each evaluator was asked to assess ptosis, nipple position, areola size, breast shape, breast size, volume, surface area, aesthetic score based on shape only, and aesthetic score based on size and shape. Evaluators were specifically instructed to provide aesthetic scores based on shape only, while ignoring size, and on size and shape together in order to minimize considerations of size in the ideal shape. Then the evaluator was asked to assess asymmetry, cleavage, and overall aesthetic score of both breasts together (Figure 17). If the evaluator was a patient, she was not asked to assess ptosis and breast shape and to numerically estimate volume and surface area of each breast (Figure 18). Aesthetic scores were measured on a Likert-type scale from zero to ten, inclusively, in one-point increments, where zero was considered extremely unappealing and ten was considered extremely appealing.

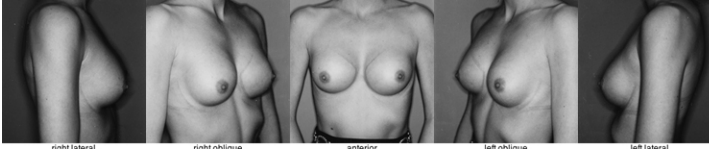
The computerized surveys were designed by Yuen-Jong Liu and J. Grant Thomson, M.D., and were implemented by Yuen-Jong Liu.

3.8 Evaluator Recruitment

Evaluators were recruited according to an IRB-approved protocol. Plastic surgeons were recruited by email correspondence through the member roster of the American Society of Plastic Surgeons (ASPS), and they completed the surveys online on a website created by the investigators. Reconstructive and cosmetic breast surgery patients were recruited in person in the clinics of surgeons in the Section of Plastic Surgery at Yale, and they completed as many of the surveys as possible in one sitting while in clinic.

For each evaluator, the 109 pairs of breasts were presented in a randomized order. Thus,

⁶Source code is available upon request.



	Subject's Right Breast	Subject's Left Breast
Ptoisis:	<input checked="" type="radio"/> 0 <input type="radio"/> I <input type="radio"/> II <input type="radio"/> III <input type="checkbox"/> glandular / pseudoptosis	<input checked="" type="radio"/> 0 <input type="radio"/> I <input type="radio"/> II <input type="radio"/> III <input type="checkbox"/> glandular / pseudoptosis
Nipple position: (ignore if absent)	<input type="radio"/> low <input checked="" type="radio"/> normal <input type="radio"/> high <input type="radio"/> medial <input checked="" type="radio"/> normal <input type="radio"/> lateral	<input type="radio"/> low <input checked="" type="radio"/> normal <input type="radio"/> high <input type="radio"/> medial <input checked="" type="radio"/> normal <input type="radio"/> lateral
Areola size: (ignore if absent)	<input type="radio"/> small <input checked="" type="radio"/> normal <input type="radio"/> large	<input type="radio"/> small <input checked="" type="radio"/> normal <input type="radio"/> large
Breast shape:	<input type="radio"/> atrophic <input type="radio"/> tuberous <input type="radio"/> flat <input checked="" type="radio"/> round	<input type="radio"/> atrophic <input type="radio"/> tuberous <input type="radio"/> flat <input checked="" type="radio"/> round
Breast size:	<input type="radio"/> insufficient <input checked="" type="radio"/> adequate <input type="radio"/> excessive	<input type="radio"/> insufficient <input checked="" type="radio"/> adequate <input type="radio"/> excessive
Breast volume:	<input type="text"/> mL (please estimate)	<input type="text"/> mL (please estimate)
Surface area:	<input type="text"/> square cm (please estimate)	<input type="text"/> square cm (please estimate)
Aesthetic score, shape only:	<input type="text"/> on a 0-10 scale	<input type="text"/> on a 0-10 scale
Aesthetic score, size and shape:	<input type="text"/> on a 0-10 scale	<input type="text"/> on a 0-10 scale
	0 = extremely unappealing. 10 = extremely appealing.	
	Both Breasts Together	
Asymmetry:	<input checked="" type="radio"/> none <input type="radio"/> mild <input type="radio"/> moderate <input type="radio"/> severe	
Cleavage:	<input type="radio"/> insufficient <input checked="" type="radio"/> adequate <input type="radio"/> excessive	
Overall aesthetic score:	<input type="text"/> on a 0-10 scale (0 = extremely unappealing; 10 = extremely appealing)	
	<input type="button" value="Submit"/>	

Figure 17: Breast Evaluation Survey for Plastic Surgeons

This computerized survey was used to interview plastic surgeons for their aesthetic feedback on various features of each subject's breasts, unilaterally and bilaterally. Plastic surgeons were also asked to estimate volume and surface area of each breast.

	Subject's Right Breast	Subject's Left Breast
Nipple position:	<input type="radio"/> low <input checked="" type="radio"/> normal <input type="radio"/> high <input type="radio"/> medial <input checked="" type="radio"/> normal <input type="radio"/> lateral	<input type="radio"/> low <input checked="" type="radio"/> normal <input type="radio"/> high <input type="radio"/> medial <input checked="" type="radio"/> normal <input type="radio"/> lateral
	medial = toward the subject's midline. lateral = away from the subject's midline.	
Areola size:	<input type="radio"/> small <input checked="" type="radio"/> normal <input type="radio"/> large	<input type="radio"/> small <input checked="" type="radio"/> normal <input type="radio"/> large
	areola = area of darkened skin around the nipple	
Breast size:	<input type="radio"/> insufficient <input checked="" type="radio"/> adequate <input type="radio"/> excessive	<input type="radio"/> insufficient <input checked="" type="radio"/> adequate <input type="radio"/> excessive
Aesthetic score, shape only:	<input type="text"/> on a 0-10 scale	<input type="text"/> on a 0-10 scale
Aesthetic score, size and shape:	<input type="text"/> on a 0-10 scale	<input type="text"/> on a 0-10 scale
	0 = extremely unappealing. 10 = extremely appealing.	
	Both Breasts Together	
Asymmetry:	<input checked="" type="radio"/> none <input type="radio"/> mild <input type="radio"/> moderate <input type="radio"/> severe	
Cleavage:	<input type="radio"/> insufficient <input checked="" type="radio"/> adequate <input type="radio"/> excessive	
Overall aesthetic score:	<input type="text"/> on a 0-10 scale (0 = extremely unappealing; 10 = extremely appealing)	

Figure 18: Breast Evaluation Survey for Patients

Cosmetic and reconstructive breast surgery patients were asked most of the same questions in the computerized survey. Ptoisis, breast shape, and numerical estimations of volume and surface area were omitted.

even if an evaluator did not complete surveys for all 109 pairs of breasts, we still obtained overall a uniform sampling of the breast images. All gathered data was stored in a password-protected MySQL database.

Evaluators were recruited and interviewed by Yuen-Jong Liu.

3.9 Ideal Anthropomorphic Measurements

The ideal anthropomorphic measurements (Figure 16) were calculated statistically using Matlab v7.6.0 (R2008a) on Mac OS X 10.5. The sternal notch to inframammary fold distance (SF), the nipple to base distance (NB), and the base to inframammary fold distance (BF) were derived from evaluations of no ptosis versus grade I, II, and III ptosis versus pseudoptosis or glandular ptosis (Figure 19). The sternal notch to nipple distance (SN) and the mid-clavicle to nipple distance (CN) were derived from vertical nipple position, normal versus high or low. The anterior axillary line to nipple distance (ZN), the nipple to mediosternal line distance (NM), and the nipple to nipple distance were derived from horizontal nipple position, normal versus medial or lateral. The areola size was surveyed directly, normal versus too small or too large.

These calculations were performed by Yuen-Jong Liu.

3.10 Ideal Volume to Surface Area Ratio

The ideal volume to surface area ratios were calculated statistically using Matlab v7.6.0 (R2008a) on Mac OS X 10.5. In each evaluation, the volume to surface area ratio was calculated for the right and left breasts individually and paired with its respective aesthetic score. Initially, least-squares linear regression was used to correlate volume to surface area ratio and aesthetic score. Thereafter, three additional approaches were used to obtain greater statistical significance.

Individual breasts were categorized by volume: ≤ 300 mL, 300–400 mL, 400–500 mL, 500–600 mL, and > 600 mL. In each volume range, volume to surface area ratios were analyzed to determine the existence of an optimal ratio that corresponded to consistently higher aesthetic scores.

Alternatively, for each aesthetic score, $i \in \{0, 1, \dots, 10\}$, the two-sample Kolmogorov-Smirnov (K-S) test was used to determine the statistical difference between volume to surface area ratios of relatively attractive breasts, with scores $\geq i$, and relatively unattrac-

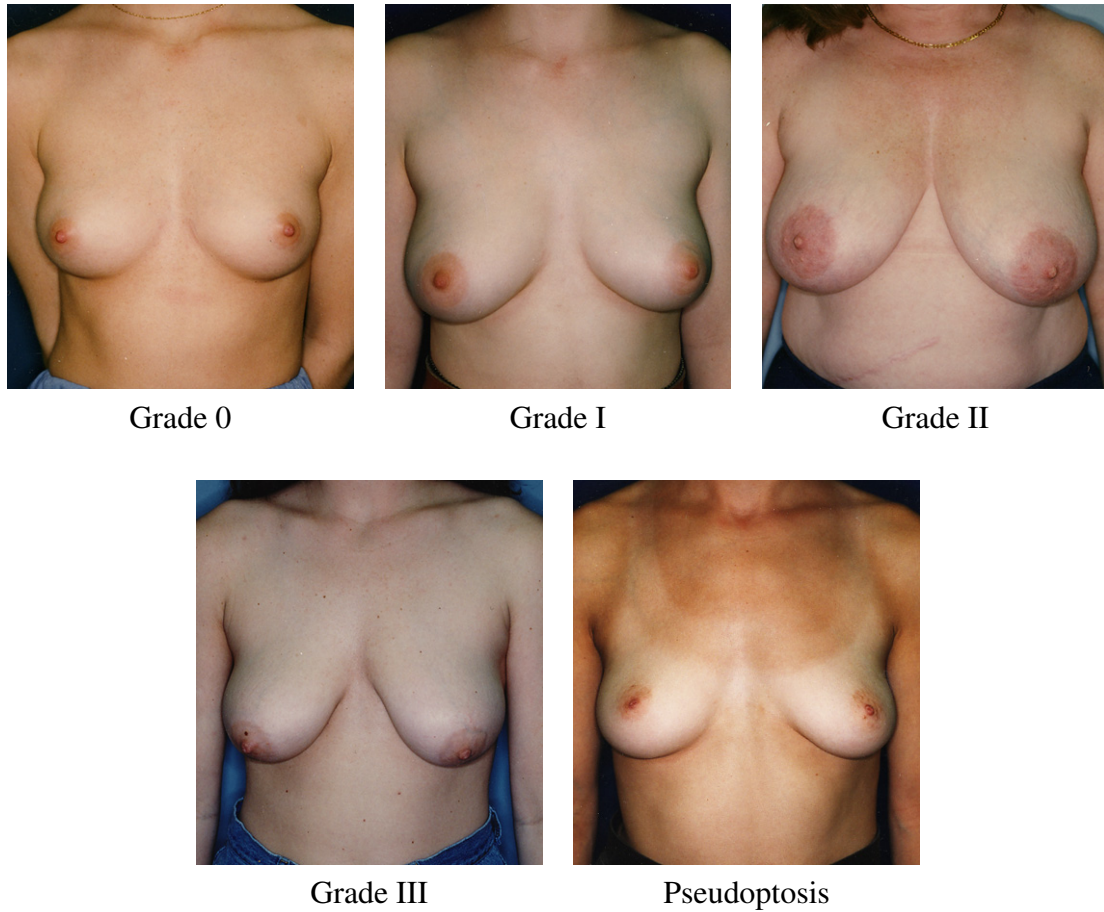


Figure 19: Breast Ptosis

Breast ptosis was originally categorized by Regnault and is classified based on the position of the nipple relative to the inframammary fold and breast base in the standing position. Grade 0 signifies no ptosis, in which the nipple lies above the inframammary fold. Grade I (mild) ptosis occurs when the nipple is at the same level as the inframammary fold. Grade II (moderate) ptosis occurs when the nipple falls below the inframammary fold but lies above the base of the breast. Grade III (severe) ptosis occurs when the nipple falls below the inframammary fold and along the base of the breast or lowest breast contour. Pseudoptosis, also known as glandular ptosis, occurs when the nipple lies above the inframammary fold while a significant amount of breast tissues hangs below the inframammary fold.

tive breasts, with scores $< i$. The two-sample K-S test was chosen because it was a non-parametric test that made no assumptions about the probability distributions of the two samples being compared. The aesthetic score $i_{\text{threshold}}$ that yielded the greatest statistical difference, or minimal p -value, was calculated for the aesthetic evaluations from each group: plastic surgeons, cosmetic patients, and reconstructive patients. The median volume to surface area ratio of relatively attractive breasts, with scores $\geq i_{\text{threshold}}$, was determined

to be the ideal ratio in each group.

In the end, the first statistical approach was revisited, and aesthetic score was approximated by a linear combination of body mass index (BMI), volume to surface area ratio, all anthropomorphic measurements (SN, SF, CN, ZN, NB, BF, and NM), and areola diameter. The best-fit coefficients were determined by multivariate least-squares linear regression.

These statistical analyses were performed by Yuen-Jong Liu.

3.11 Asymmetry and Cleavage

Multivariate least-squares linear regression was used to approximate the aesthetic score of a pair of breasts together as a function of the average rating of the right and left breasts individually. A coefficient for asymmetry was added to the function in cases of moderate or severe asymmetry, and coefficients for insufficient and excessive cleavage were added in these respective cases.

4 Results

4.1 Validation on Geometric Solids

Twenty-two objects (four hemispheres, three cones, and fifteen truncated cones) with volumes ranging 50–1300 mL (mean 414 mL), surface areas ranging 70–600 cm² (mean 230 cm²), and vertical projections ranging 1.5–20 cm (mean 8.7 cm) were imaged using the novel optical method (Figure 13). There was excellent correlation of all three measured parameters with the calculated values for each geometric shape ($R > 0.995$, $p < 10^{-14}$) (Figure 20). The mean errors (optical – actual) in volume, surface area, and maximum vertical projection were -28 ± 28 mL (mean \pm SD), 2 ± 9 cm², and -0.4 ± 0.5 cm, respectively. Thus, the optical method tended to underestimate volume, overestimate surface area, and underestimate maximum vertical projection. The largest errors were seen in the vertical projections of the pointed cones (mean difference = 1.3 ± 0.5 cm, $n = 3$), since the grid did not always align with the vertex of the cone.

4.2 Validation on Human Female Subjects

Seven volunteers were recruited for plaster casting of fourteen breasts, and the volumes and surface areas of the casts were compared with optical measurements using linear regression analysis (Figures 14 and 15). Surface areas ranged 100–350 cm² (mean 213 cm²), and volumes ranged 80–600 mL (mean 271 mL). There was excellent correlation between measurements by the optical method and by plaster casting ($R > 0.992$, $p < 10^{-11}$) (Figure 21), and the mean errors (optical – actual) in volume and surface area were 32 ± 22 mL (mean \pm SD) and -3 ± 11 cm², respectively. No subjects complained of any discomfort during the procedure.

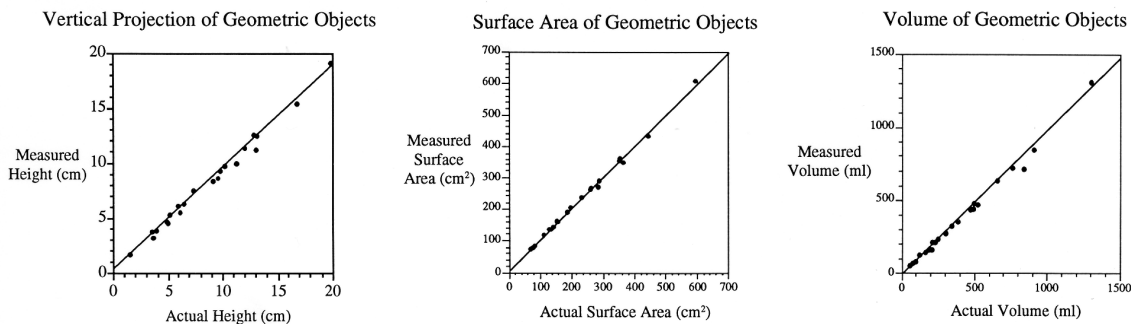


Figure 20: Validation on Geometric Solids

There was strong correlation between the imaged and actual parameters for geometric objects of varied shapes and sizes. The straight lines were calculated by linear regression ($R > 0.995$, $p < 10^{-14}$, $n = 22$).

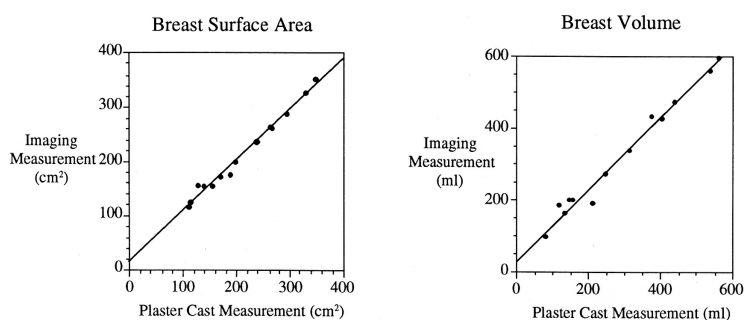


Figure 21: Validation on Human Female Subjects

There was excellent correlation between the imaged and plaster cast measurements. The straight lines were calculated by linear regression ($R > 0.992$, $p < 10^{-11}$, $n = 14$).

4.3 Repeatability

To assess the precision of the optical method, measurements of volume and surface area were repeated threefold on one subject under the same procedure, instrument, observer, conditions, and location. Measurements of volume, surface area, and maximum vertical projection are within 5%, 3%, and 9% of the mean, respectively (Table A). The standard deviation of the error in measurements of volume, surface area, and maximum vertical projection are 4%, 2%, and 6%, respectively, which are clinically insignificant. In a female patient with 36-C breasts measuring 1,000 mL in volume, 500 cm² in surface area, and 10 cm in maximum vertical projection, the optical method can be expected to vary ± 50 mL, ± 15 cm², and ± 0.9 cm between measurements.

	Right Breast		
	Volume (mL)	Surface Area (cm ²)	Vertical Projection (cm)
Measurement 1	116 (−4.13%)	150 (−2.39%)	6.26 (+3.47%)
Measurement 2	122 (+0.83%)	157 (+2.17%)	6.33 (+4.63%)
Measurement 3	125 (+3.31%)	154 (+0.22%)	5.56 (−8.10%)
	Left Breast		
	Volume (mL)	Surface Area (cm ²)	Vertical Projection (cm)
Measurement 1	118 (+4.73%)	142 (−1.84%)	5.52 (−6.65%)
Measurement 2	110 (−2.37%)	146 (+0.92%)	6.09 (+2.99%)
Measurement 3	110 (−2.37%)	146 (+0.92%)	6.13 (+3.66%)

Table A: Repeatability of the Optical Method

Under the same procedure, instrument, observer, conditions, and location, repeated measurements were taken of the same subject's right and left breasts. Volume was recorded in milliliters, surface area in square centimeters, and maximum vertical projection in centimeters, with percent deviation from the mean measurement in parentheses.

4.4 Evaluator Recruitment and Subject Evaluations

Of the 5,720 plastic surgeons emailed through the member roster of the ASPS, 252 responded and submitted a total of 3,641 evaluations, meaning that altogether the 109 pairs of breasts were evaluated 3,641 times. 15 cosmetic breast surgery patients were interviewed in clinic and submitted 368 evaluations, and they included pre- and post-operative patients having augmentation mammoplasty, mastopexy, and cosmetic reduction mammoplasty. 25 reconstructive breast surgery patients were interviewed in clinic and submitted 437 evaluations, and they included pre- and post-operative patients having breast reconstruction and therapeutic reduction mammoplasty. In all, 4,446 evaluations were submitted.

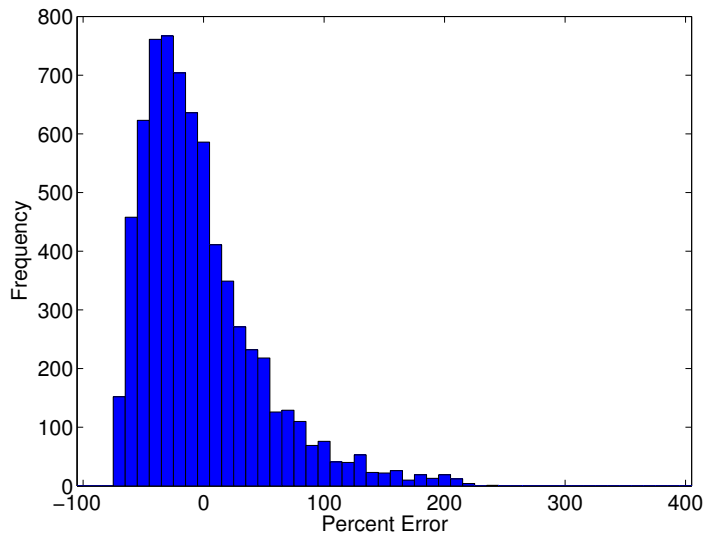


Figure 22: Visual Estimation of Volume

On average, plastic surgeons underestimated volume by 7% or 128 mL with a standard deviation of 49% or 292 mL.

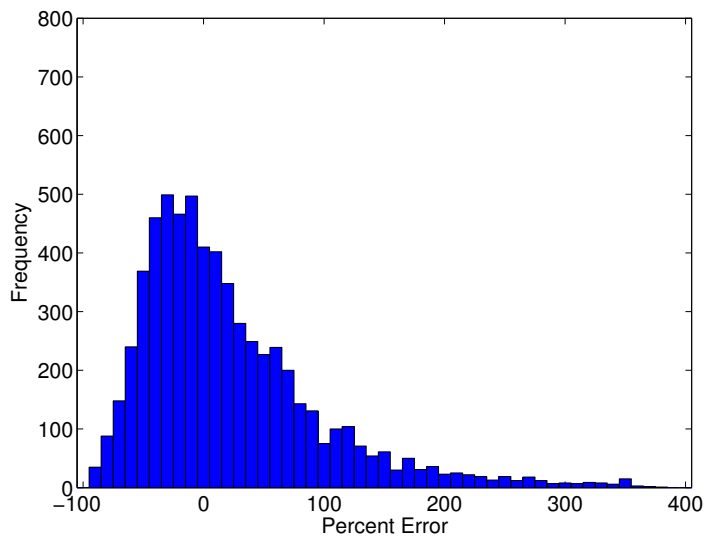


Figure 23: Visual Estimation of Surface Area

On average, plastic surgeons overestimated surface area by 15% or 31 cm² with a standard deviation of 69% or 214 cm².

4.5 Accuracy of Visual Estimation

From these evaluations, it was possible to quantify the accuracy with which plastic surgeons visually estimated breast volume and surface area. On average, plastic surgeons underestimated volume by 7% or 128 mL, with a standard deviation of 49% or 292 mL

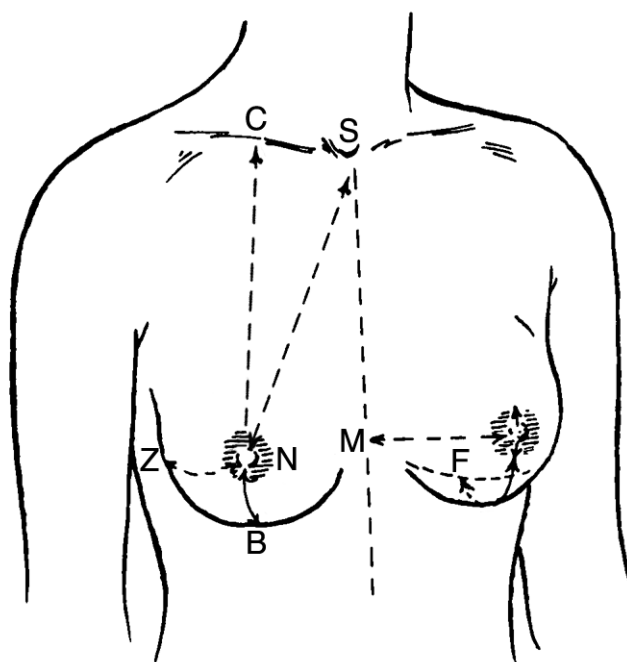
(Figure 22). On the other hand, plastic surgeons fared significantly worse at surface area ($p < 10^{-8}$), overestimating on average 15% or 31 cm², with a standard deviation of 69% or 214 cm² (Figure 23).

4.6 Ideal Anthropomorphic Measurements

The ideal anthropomorphic measurements are listed in Table B for plastic surgeons, cosmetic patients, and reconstructive patients, showing consistent values among the three groups except for statistically significant differences in SN, CN, and areola diameter. Some measurements have only an ideal value for plastic surgeons because they were based on evaluations of ptosis, a parameter that was queried only from this group of evaluators. As described in the Methods section, the ideal values for each measurement were based on breasts that were evaluated as “normal” for the corresponding feature. For most features, the distribution of “normal” evaluations was statistically distinguishable from non-“normal” evaluations (i.e. ptotic, high, low, medial, lateral, etc.) with $p < 0.05$. The ideal amount of ptosis was Grade 0 or no ptosis, followed by Grade I, pseudoptosis, Grade II, and Grade III in descending order (Table C). The distributions of aesthetic scores for the grades of ptosis were pairwise significantly different with $p < 0.005$. These values will be compared with previously published data in the Discussion section.

4.7 Ideal Volume to Surface Area Ratio

In the initial attempt to calculate an ideal volume to surface area ratio, strong correlation could not be found between the ratio and aesthetic score of the breast. Least-squares linear regression was used to approximate aesthetic score S as an algebraic function of volume V



	Plastic Surgeons	Cosmetic Patients	Reconstructive Patients
SF	23 cm		
SN [†]	21 cm	21.5 cm	21.5 cm
CN [†]	21.5 cm	22 cm	22 cm
ZN	13 cm	13 cm	13 cm
NM	12 cm	12 cm	12 cm
NB	6 cm		
BF	2 cm		
NN	21 cm	21 cm	21 cm
Areola Diameter [‡]	4 cm	4.5 cm	4 cm
Ptosis	Grade 0		

Table B: Ideal Anthropomorphic Measurements

The ideal anthropomorphic measurements were calculated from evaluator responses. Values did not differ among the three groups by more than 0.5 cm in any measurement. [†]Preferred values for SN and CN were significantly different in plastic surgeons versus cosmetic and reconstructive patients. [‡]Preferred values for areola diameter were significantly different in cosmetic patients versus plastic surgeons and reconstructive patients.

Ptosis	Average Aesthetic Score
Grade 0	6.0
Grade I	5.4
Pseudoptosis	5.1
Grade II	4.1
Grade III	3.3

Table C: Aesthetic Scores vs. Ptosis

The average aesthetic scores are listed in descending order for breasts categorized by grades of ptosis. The scores for different grades of ptosis are pairwise significantly different with $p < 0.005$.

and surface area A in the following simple forms

$$S = V \cdot x + A \cdot y$$

$$S = V^x \cdot A^y$$

where x and y were positive or negative real numbers acting as coefficients or exponents to volume and surface area, respectively. In these models, x was consistently positive and y consistently negative, demonstrating that aesthetic score correlated directly with increasing volume and decreasing surface area. However, these models were too simple, faring poorly with low predictive value.

Subsequently, another approach was attempted to determine ideal volume to surface area ratios for breasts when categorized by volume: ≤ 300 mL, 300–400 mL, 400–500 mL, 500–600 mL, and > 600 mL. In each category, aesthetic score was highly variable from low to high ratios, and no global maxima could be derived. Even after breasts were selected for those with “normal” horizontal and vertical nipple position and “round” shapes, aesthetic score was still highly variable and no clear trends could be identified.

Alternatively, a robust non-parametric statistical test, the K-S test, was used to calculate ideal volume to surface area ratios as the median ratio in breast evaluations that received




	Plastic Surgeons	Cosmetic Patients	Reconstructive Patients
Ideal Ratio	1.66 cm	1.66 cm	1.69 cm
Examples			

Table D: Ideal Volume to Surface Area Ratios

The K-S test was used to calculate ideal volume to surface area ratios preferred by plastic surgeons, cosmetic patients, and reconstructive patients. Ratios were expressed in cm, as volume in cm^3 was divided by surface area in cm^2 . Values are shown here with representative breasts.

high aesthetic scores. Among plastic surgeons, an aesthetic score of 5 was determined to be the best threshold to separate high from low scores ($p = 3 \times 10^{-79}$) and the median volume to surface area ratio of high scoring breasts was 1.66 cm, versus 1.88 cm in low scoring breasts, suggesting that in an aesthetically acceptable breast, every square centimeter of skin envelope should contain a tissue depth of 1.66 cm on average. Among cosmetic breast surgery patients, an aesthetic score of 5 was determined to be the best threshold ($p = 6 \times 10^{-13}$) and the median volume to surface area ratio of high scoring breasts was 1.66 cm, versus 1.93 cm in low scoring breasts. Among reconstructive breast surgery patients, an aesthetic score of 2 was determined to be the best threshold ($p = 2 \times 10^{-8}$) and the median volume to surface area ratio of high scoring breasts was 1.69 cm, versus 2.11 cm in low scoring breasts (Table D). By the K-S test, the ideal ratios for plastic surgeons were significantly different from the ideal ratios for reconstructive patients with $p < 0.02$, though

Measurement	Best-Fit Coefficient
$\frac{\text{Volume}}{\text{SurfaceArea}}$	-0.48
SN	+0.01
SF	+0.01
CN	-0.02
ZN	+0.02
NB	+0.03
BF	-0.02
NM	+0.00
Areola Diameter	-0.01

Table E: Best-Fit Coefficients in Approximating Aesthetic Score by Volume to Surface Area Ratio and Anthropomorphic Measurements

Aesthetic score was approximated as a linear combination of volume to surface area ratio, all anthropomorphic measurements, and areola diameter. All best-fit coefficients were statistically significant with $p < 0.05$. The coefficient for NM was very small but its confidence interval excluded zero.

the ideal ratios did not differ significantly between plastic surgeons and cosmetic patients, with $p = 0.15$, or between cosmetic patients and reconstructive patients, with $p = 0.78$.

The initial analysis was revisited, using evaluations from plastic surgeons, who submitted the most responses. Best-fit coefficients were determined for a linear combination of volume to surface area ratio, all anthropomorphic measurements (SN, SF, CN, ZN, NB, BF, and NM), and areola diameter (Table E) as an approximation of aesthetic score with a statistically significant regression: $R^2 = 0.30$, $p < 10^{-307}$. Volume to surface area ratio has the greatest weight and a higher ratio was associated with lower aesthetic score. Body mass index (BMI) was also considered as a term in regression, and no significant correlation was found.

	Plastic Surgeons	Cosmetic Patients	Reconstructive Patients
Severe Asymmetry	-0.36	-0.40	-0.72
Insufficient Cleavage	-0.27	-0.74	-0.36
Excessive Cleavage	-0.17	-0.24	+0.08
R^2	0.91	0.85	0.81
p	$< 10^{-307}$	$< 10^{-307}$	$< 10^{-307}$

Table F: Aesthetic Impacts of Asymmetry and Cleavage

Using linear regression, the aesthetic score of both breasts was approximated as a function of the average rating of the right and left breasts. Severe asymmetry and inadequate cleavage incurred the above penalties on a 0-to-10 point scale.

4.8 Asymmetry and Cleavage

Severe asymmetry, insufficient cleavage, and excessive cleavage incurred mostly penalties in terms of aesthetic score (Table F). However, reconstructive breast surgery patients had slightly positive perceptions of excessive cleavage. The linear regression model offered a high degree of correlation, with high R^2 coefficients and low p -values. Most notably, reconstructive patients had the greatest concern about asymmetry, in that the aesthetic score of a pair of breasts would suffer a penalty -0.72 if they exhibited moderate or severe asymmetry. In addition, cosmetic patients cared the most about having an insufficient amount of cleavage, with a penalty of -0.74 .

5 Discussion

Previous attempts at quantitative approaches to breast surgery have focused primarily on nipple position and volume measurement. An evaluation of 20 “aesthetically perfect” female models published in 1955 strove to determine the ideal relationship of the breast to the anterior chest wall but was limited by one investigator’s opinion of perfection [5]. More recently, anthropomorphic measurements and volume were collected in “normal” women [6, 7, 8]. For example, Smith provided average values of 55 consecutive volunteers without aesthetic evaluation [6]. Other investigators attempted to improve the results of breast surgery using various techniques of breast volume measurement [16, 17, 4, 36]. The shortcomings of previous techniques included distortion causing variable results, and equipment complexity and expense. While it is well-recognized that skin surface area is an important parameter in the determination of breast symmetry and shape, there has been no quantitative data in the plastic surgery literature documenting normal or abnormal values. Indeed, until now, there has been no method available to measure these two parameters simultaneously without breast contact or distortion. The authors have described an optical method of breast volume and surface area analysis which is simple to perform and is associated with minimal patient discomfort and inconvenience. The apparatus can be assembled from components that are readily available, can be kept in a physician’s office, and are relatively inexpensive. These are advantages over other surface imaging systems that have been developed with specialized cameras and computer equipment for facial analysis [37]. The significantly higher cost of this technology can be expected to limit widespread clinical availability. Furthermore, this and other stereo photographic systems have not been programmed to measure surface area, and in systems available for breast imaging and analysis, clinical applications of their software have not been reported in scientific literature. The reason may be that imaging using these systems is performed with the subject positioned upright, limiting their use to non-ptotic breasts. To the authors’ knowledge, none of these systems has been programmed to measure surface area, although it should be technically

feasible to do so.

This experiment has shown that the optical method is accurate in the analysis of simple geometric shapes. The accuracy is limited by the use of a grid for imaging which, through random alignment, does not always coincide with surface landmarks, with the result that sharp projections are poorly imaged. Natural breast shape is not acutely pointed, more closely resembling a truncated cone, for which the vertical projection measured in this study was accurate to within several millimeters. Despite this limitation, the errors between optical values and actual parameters were small and clinically insignificant.

In an effort to fully automate the three-dimensional modeling of the breast, computational algorithms from artificial intelligence and image processing were researched for converting information from the two images of deformed lattice grids of each breast into depth measurements at the vertices of the grid. The conversion from two-dimensional images to a three-dimensional model has been well studied in the computer science literature, particularly using “structured light,” a term that refers to the projection of a known light pattern, such as a lattice grid, onto objects of interest [38, 39]. The first obstacle was to filter out noise from each lattice grid image that was photographed from a subject lying prone on the examining table. Though ideally, dark areas would be captured as black pixels and edges of the lattice grid would be captured as white pixels, the lattice grid images contained shades of grey and blue from scattered light and reflections off the examining table. By using the k -means clustering algorithm, pixels were categorized into three clusters: dark pixels corresponding to unlit areas of the image, light pixels corresponding to the lattice grid on the subject’s skin, and bright blue pixels corresponding to the lattice grid on the under-surface of the examining table. The first cluster was replaced with black pixels and the second and third clusters were replaced with white pixels, producing a monochrome image. Then, in order to identify the vertices of the lattice grid, thinning algorithms were applied to the image so that all lattice edges measured one pixel in width [40, 41]. Despite the amount of image processing, there remained too much ambiguity in the lattice grid that

precluded automatic labeling of its vertices. Particularly in the case of a pendulous breast, its curvature while dependent to gravity in the prone position was often too steep for the image processing algorithms to deduce the positions of lattice edges and vertices. Thus, the process of labeling the vertices still required some degree of human intervention, though overlaying the thinned edges provided a helpful guide to facilitate this process.

It is natural to believe that breast volume and surface area may change with positioning of the breast in the upright or prone position. Since the surgeon is primarily interested in the shape of the breast in the upright position, one could argue that all measurements should be performed upright. Unfortunately, optical analysis of the upright breast is usually impossible secondary to ptosis. The inferior surface can be hidden by close proximity to the chest wall. Previous investigators have shown that volume measurements performed in both positions are identical [9]. The results of this study have confirmed these findings by comparing prone optical imaging with upright plaster casting. Moreover, it has been shown for the first time that the differences between surface area measurements performed in the two positions are small and within the measured accuracy of the technique.

Therefore, this study has demonstrated that it is possible and feasible to accurately measure breast volume and surface area in the prone position and that this information is clinically relevant. However, there remain few obstacles to full clinical implementation. The data analysis is cumbersome, requiring significant human intervention in manually identifying the projected light grid and distinguishing breast area from chest wall. This human intervention is not only time-consuming and cumbersome but also may introduce potential variability, especially in determining the limits of the chest wall, though the variability should be minimal in this experiment since only two investigators were closely involved in this aspect of image analysis. Future improvements will allow fully automated data analysis after image capture, with an enhancement of the lattice grid projected onto the breast. More detailed mathematical analysis of chest wall curvature may be able to determine areas where breast tissue projects the skin surface away from chest wall. Furthermore, even

though it is now possible to measure breast surface area, the clinical meaning of variations in this parameter is yet poorly understood and will be elucidated in subsequent experiments using this optical method.

Under many circumstances, breast surgery can be performed successfully without pre-operative quantitative analysis, but there are several clinical situations where surface area measurement may improve the results of breast surgery. An imbalance between volume and surface area can result in an aesthetically unacceptable appearance, leading to a ptotic or a constricted breast. The proper relationship between volume and surface area needed to obviate these deformities has been elucidated. Knowledge of the ideal relationship between volume and surface area may yield improved results following breast surgeries such as mastopexy, reduction mammoplasty, constricted breast reconstruction, or reconstruction following mastectomy.

A significant problem following breast reconstruction is that 40% of patients may have an asymmetry of breast shape, and 23% may have an asymmetry in size [3]. Imaging of the mastectomy site and the contralateral normal breast prior to reconstruction with an autologous flap or a tissue expander may provide data that will allow construction of a flap or insertion of a tissue expander with the proper dimensions to improve symmetry of size and shape.

Postoperative breast asymmetry is one of the more common problems following reduction mammoplasty [4]. During breast reduction for gigantomastia, a small volume difference may go unrecognized without quantitative analysis, and if the same volume is removed from each breast, the volume difference may become clinically significant at the smaller revised volume. For example, the difference between 1500 and 1700 g breasts may not be subjectively obvious, but once each breast has been reduced by the same amount, the difference between the final volumes of 600 and 800 g may be clinically significant. Pre-operative volume measurement may alert the surgeon to such differences so that the surgery can be adjusted appropriately.

In the planning of an augmentation mammoplasty, surface imaging is important for two reasons. First, patient satisfaction of post-operative breast size may be more easily attained through quantitative knowledge of pre-operative volume integrated with the patient's desired size. Second, if the ideal relationship between breast volume and surface area is known, then knowledge of the pre-augmentation skin surface area may allow determination of the volume required to provide an aesthetic breast shape. Thus, quantitative analysis should improve the surgeon's ability to perform a breast augmentation that satisfies the patient's and surgeon's concepts of post-operative size and shape.

During surgical planning to correct breast asymmetry, knowledge of the volume and surface area differences can yield improved post-operative results. If quantitative values for both volume and surface area are known for each breast, then it will be possible to alter these two parameters to achieve identical values. It is hoped that the optical method will thus improve symmetry not only in volume but also in shape.

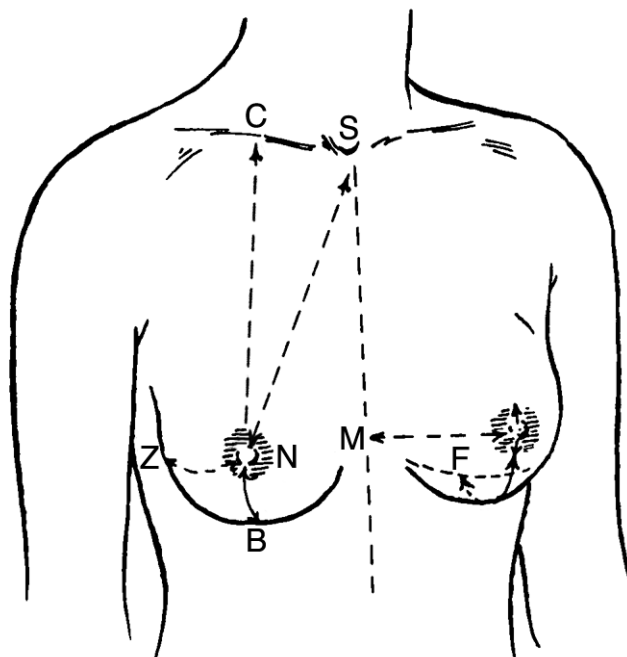
Current programming displays a three-dimensional digital model of the subject's breast. Future improvements may allow alteration on the fly by changing volume and surface area. This feature may aid in pre-operative planning, patient education, and management of patient expectations.

Quantitative surface area measurement was originally conceived by the investigators to be useful for breast imaging. It has become obvious, however, that there are other areas of the body where it may be valuable. For example, imaging of a skin defect requiring tissue expansion can quantify the amount of surface area needed. Imaging of the expanding tissue will yield volume that provides the appropriate amount of skin, thus minimizing over- or under-expansion. The optical method can also be used to quantify facial surface changes following craniofacial surgery, and to correlate these changes with skeletal alterations.

During training, plastic surgeons routinely estimate breast volume in designing breast surgery. Breast implants for augmentations and reconstructions are classified by volume, and the surgeons need to quantify pre-operatively the amount of tissue to be removed in

breast reductions. In mastopexies, surface area of the skin envelope is important for correcting ptosis from excess skin, and in reconstructions with skin-bearing tissue flaps, assessing the area of skin introduced by the flap is necessary to avoid a constricted result. However, both volume and surface area are typically assessed by visual inspection. In the results, the large standard deviations of error for these parameters reflect marked inconsistency for surgeons looking at one breast to the next (Figures 22 and 23), demonstrating a need for an objective method of measurement such as ours, in order to reliably evaluate and achieve symmetry in breast surgery.

The ideal anthropomorphic measurements in this study may be compared to published values (Table G). In 1986, Smith used 55 normal female volunteers without any aesthetic judgment [6], and in 1955, Penn used 20 female volunteers whom he considered aesthetically perfect, basing his ideal values on a singular opinion [5]. Not only is this study more comprehensive than those prior, but this study is also more robust in that pluralistic aesthetic feedback was received from hundreds of evaluators, including surgeons and patients, with statistically significant but perhaps clinically insignificant disagreements (0.5 cm) in ideal measurements of SN, CN, and areola diameter. The ideal anthropomorphic measurements in all the studies are largely in agreement, in summary, describing a near-equilateral triangle between sternal notch and bilateral nipples. The results in this study found ZN and BF distances much greater than those in Smith's [6] and may be explained by the incorporation of aesthetic evaluations, indicating popular preferences for breasts with greater fullness in inferior and lateral poles. Although limited demographic information, such as age, gender, height, weight, and bra size, was collected from each evaluator, it was not used in the final analysis because there were insufficient numbers to distinguish different standards of aesthetic acceptability. Future data collection may identify patterns of aesthetic preferences based on the evaluator's age, physical stature, breast size, level of education, and level of physical activity, allowing plastic surgeons to better anticipate the aesthetic goals of breast surgery patients. Environmental stimuli, such as cultural backgrounds or



	Liu 2009	Smith 1986	Penn 1955
SF	23 cm		
SN	21–21.5 cm		21 cm
CN	21.5–22 cm		21 cm
ZN	13 cm	8.8 cm	
NM	12 cm	11.4 cm	
NB	6 cm	6.6 cm	7 cm
BF	2 cm	0.3 cm	
NN	21 cm	23 cm	21 cm
Areola Diameter	4–4.5 cm		

Table G: Ideal Anthropomorphic Measurements Compared to Published Values

Here the ideal measurements from the results of this study are presented alongside previously reported values. Differences in ideal values may reflect peculiarities in the singular opinions in previous studies or may reflect changes in cultural perception of an aesthetically acceptable breast.

public media exposure, may also affect the evaluator's aesthetic preferences and would be additional demographic parameters of interest.

The ideal volume to surface area ratio may be compared to the ratio approximating a hemisphere. In solid geometry, a hemisphere with radius r has volume of $\frac{4}{3}\pi r^3$ and surface area of $4\pi r^2$, yielding a volume to surface area ratio of $\frac{r}{3}$. In a hypothetical breast with a hemispherical shape and a base diameter of 12 cm, the radius would be 6 cm and the volume to surface area ratio would be 2 cm. The ideal ratios in the results were less, indicating that an aesthetically acceptable breast should have either less volume or more skin envelope to create a shape with greater laxity. The ratios of 1.66–1.69 cm should correspond therefore to a teardrop shape, though volume and surface area by themselves are mathematically insufficient to describe a tear drop shape. Future data gathering or computer modeling will be necessary to explore the aesthetic scores of teardrop shapes. In addition, the additional parameters that specify a teardrop shape may provide improved correlation with aesthetic score than a function of volume and surface alone.

In the final multivariate linear regression correlating aesthetic score to volume to surface area ratio and anthropomorphic measurements, the best-fit coefficients suggested that the ratio had the greatest weight in determining aesthetic acceptability (Table E). The negative value of the relevant coefficient, -0.48 , suggested that lower volume, higher surface area, or both together are associated with higher aesthetic score. Therefore, plastic surgeons should tend towards a minimally ptotic breast instead of a constricted breast.

The results also characterized differences in the importance of asymmetry and adequate cleavage to cosmetic patients and reconstructive patients. Cosmetic patients may pay the most attention to having neither excessive nor insufficient cleavage because they desire a balanced look of fullness in a bikini top or a dress with low décolletage. Reconstructive patients gave the most emphasis to moderate or severe asymmetry. As many of them seek breast surgery after an oncologic mastectomy that has resulted in significant asymmetry, it seems reasonable that this comprises a major feature that they seek to correct.

6 Conclusions

In summary, a new optical method to measure the surface area and volume of simple convex shapes is described. It is simple to use, inexpensive, non-invasive, and accurate. Measurement errors are small and clinically insignificant. Breast volume and surface area can be accurately measured in the prone position using this technique.

Plastic surgeons underestimated volume by 7% or 128 mL, with a standard deviation of 49% or 292 mL and overestimated surface area by 15% or 31 cm², with a standard deviation of 69% or 214 cm². Accuracy was significantly diminished in estimating surface area, and the large standard deviations of error for both volume and surface area demonstrate inconsistency that should be ameliorated with a systematic measuring technique.

Results from the study deduced a set of ideal anthropomorphic measurements describing an aesthetically acceptable breast. Values were very similar among plastic surgeons, cosmetic patients, and reconstructive patients. An ideal volume to surface area ratio was also determined but further modeling is necessary, as these parameters are mathematically insufficient to describe an ideal breast shape.

References

- [1] Thorne, C., Grabb, W. C., and Smith, J. W. *Grabb and Smith's plastic surgery*. Philadelphia: Wolters Kluwer Health / Lippincott Williams & Wilkins. 6th ed. Chapter 57, p. 565. 2007.
- [2] Rohrich, R. J., Hartley, W., and Brown, S. Incidence of breast and chest wall asymmetry in breast augmentation: a retrospective analysis of 100 patients. *Plast Reconstr Surg*. 2006 Dec;118:7S-13S; discussion 14S, 15S-17S.
- [3] Asplund, O. and Nilsson, B. Interobserver variation and cosmetic result of submuscular breast reconstruction. *Scand J Plast Reconstr Surg*. 1984;18:215–220.
- [4] Wilkie, T. and Ship, A. G. Volumetric breast measurement during surgery. *Aesthetic Plast Surg*. 1977;1:301–5.
- [5] Penn, J. Breast reduction. *Br J Plast Surg*. 1955 Jan;7:357–371.
- [6] Smith, D. J. J., Palin, W. E. J., Katch, V. L., and Bennett, J. E. Breast volume and anthropomorphic measurements: normal values. *Plast Reconstr Surg*. 1986 Sep;78:331–335.
- [7] Loughry, C. W., Sheffer, D. B., Price, T. E. J., Lackney, M. J., Bartfai, R. G., and Morek, W. M. Breast volume measurement of 248 women using biostereometric analysis. *Plast Reconstr Surg*. 1987 Oct;80:553–558.
- [8] Loughry, C. W., Sheffer, D. B., Price, T. E., Einsporn, R. L., Bartfai, R. G., Morek, W. M., and Meli, N. M. Breast volume measurement of 598 women using biostereometric analysis. *Ann Plast Surg*. 1989 May;22:380–385.
- [9] Campaigne, B. N., Katch, V. L., Freedson, P., Sady, S., and Katch, F. I. Measurement of breast volume in females: description of a reliable method. *Ann Hum Biol*. 1979 Jul-Aug;6:363–367.

- [10] Katch, V. L., Campaigne, B., Freedson, P., Sady, S., Katch, F. I., and Behnke, A. R. Contribution of breast volume and weight to body fat distribution in females. *Am J Phys Anthropol.* 1980 Jul;53:93–100.
- [11] Palin, W. E. J., von Fraunhofer, J. A., and Smith, D. J. J. Measurement of breast volume: comparison of techniques. *Plast Reconstr Surg.* 1986 Feb;77:253–255.
- [12] Bouman, F. G. Volumetric measurement of the human breast and breast tissue before and during mammoplasty. *Br J Plast Surg.* 1970 Jul;23:263–264.
- [13] Kirianoff, T. G. Volume measurements of unequal breasts. *Plast Reconstr Surg.* 1974 Nov;54:616.
- [14] Tegtmeier, R. E. A quick, accurate mammometer. *Ann Plast Surg.* 1978 Nov;1:625–626.
- [15] Wilmore, J. H., Atwater, A. E., Maxwell, B. D., Wilmore, D. L., Constable, S. H., and Buono, M. J. Alterations in breast morphology consequent to a 21-day bust developer program. *Med Sci Sports Exerc.* 1985 Feb;17:106–112.
- [16] Ward, C. and Harrison, B. The search for volumetric symmetry in reconstruction of the breast after mastectomy. *Br J Plast Surg.* 1986 Jul;39:379–385.
- [17] Schultz, R. C., Dolezal, R. F., and Nolan, J. Further applications of Archimedes' principle in the correction of asymmetrical breasts. *Ann Plast Surg.* 1986 Feb;16:98–101.
- [18] Morris, A. M. Volumetric estimation in breast surgery. *Br J Plast Surg.* 1978 Jan;31:19–21.
- [19] Grossman, A. J. and Roudner, L. A. A simple means for accurate breast volume determination. *Plast Reconstr Surg.* 1980 Dec;66:851–852.

- [20] Lalonde, D. H. *Lalonde Breast Sizer*. Westbury, NY: Accurate Surgical and Scientific Instruments. 2006.
- [21] Hoffman, S. Measuring breast volume [Letter]. *Plast Reconstr Surg*. 1981;68:264.
- [22] Fowler, P. A., Casey, C. E., Cameron, G. G., Foster, M. A., and Knight, C. H. Cyclic changes in composition and volume of the breast during the menstrual cycle, measured by magnetic resonance imaging. *Br J Obstet Gynaecol*. 1990 Jul;97:595–602.
- [23] Kovacs, L., Eder, M., Hollweck, R., Zimmermann, A., Settles, M., Schneider, A., Udovic, K., Schwenzer-Zimmerer, K., Papadopoulos, N. A., and Biemer, E. New aspects of breast volume measurement using 3-dimensional surface imaging. *Ann Plast Surg*. 2006 Dec;57:602–610.
- [24] Sheffer, D. B., Price, T. E., Loughry, C. W., Bolyard, B. L., Morek, W. M., and Varga, R. S. Validity and reliability of biostereometric measurement of the human female breast. *Ann Biomed Eng*. 1986;14:1–14.
- [25] Galdino, G. M., Nahabedian, M., Chiaramonte, M., Geng, J. Z., Klatsky, S., and Manson, P. Clinical applications of three-dimensional photography in breast surgery. *Plast Reconstr Surg*. 2002 Jul;110:58–70.
- [26] Losken, A., Seify, H., Denson, D. D., Paredes, A. A. J., and Carlson, G. W. Validating three-dimensional imaging of the breast. *Ann Plast Surg*. 2005 May;54:471–476.
- [27] Tepper, O. M., Small, K., Rudolph, L., Choi, M., and Karp, N. Virtual 3-dimensional modeling as a valuable adjunct to aesthetic and reconstructive breast surgery. *Am J Surg*. 2006 Oct;192:548–551.
- [28] Aufrecht, G. Mammoplasty for pendulous breasts; empiric and geometric planning. *Plast reconstr surg (1946)*. 1949 Jan;4:13–29.

- [29] Wise, R. J. A preliminary report on a method of planning the mammoplasty. *Plast reconstr surg (1946)*. 1956 May;17:367–375.
- [30] Goldwyn, R. M. *Reduction mammoplasty*. Boston: Little, Brown. 1st ed. 1990.
- [31] Bozola, A. R. Breast reduction with short L scar. *Plast Reconstr Surg*. 1990 May;85:728–738.
- [32] Bostwick, J. *Plastic and reconstructive breast surgery*. St. Louis, MO: Quality Medical Pub. 1990.
- [33] Hudson, D. A. Factors determining shape and symmetry in immediate breast reconstruction. *Ann Plast Surg*. 2004 Jan;52:15–21.
- [34] Rietjens, M., De Lorenzi, F., Venturino, M., and Petit, J. Y. The suspension technique to avoid the use of tissue expanders in breast reconstruction. *Ann Plast Surg*. 2005 May;54:467–470.
- [35] Wijayanayagam, A., Kumar, A. S., Foster, R. D., and Esserman, L. J. Optimizing the total skin-sparing mastectomy. *Arch Surg*. 2008 Jan;143:38–45.
- [36] Ellenbogen, R. A new device to assist in sizing breasts. *Ann Plast Surg*. 1978 May;1:333–335.
- [37] Bhatia, G., Vannier, M. W., Smith, K. E., Commean, P. K., Riolo, J., and Young, V. L. Quantification of facial surface change using a structured light scanner. *Plast Reconstr Surg*. 1994 Nov;94:768–774.
- [38] Hu, G. and Stockman, G. 3-D Surface Solution Using Structured Light and Constraint Propagation. *IEEE Transactions on Pattern Analysis and Machine Intelligence*. 1989 Apr;11:390–402.

- [39] Guisser, L., Payrissat, R., and Castan, S. A New 3-D Surface Measurement System Using A Structured Light. *Computer Vision and Pattern Recognition*. 1992 Jun;92:784–786.
- [40] Nedzved, A. M. and Ablameyko, S. V. Thinning of the Gray-Scale and Color Images by a Sequential Analysis of Binary Layers. *Pattern Recognition and Image Analysis*. 2000 Apr–Jun;10:226–235.
- [41] Nedzved, A., Ablameyko, S., and Uchida, S. Gray-scale thinning by using a pseudo-distance map. *Pattern Recognition*. 2006;2:239–242.