

7-9-2009

Intussusception of the Appendix: New trends and comprehensive analysis of 140 case reports

Barbara Wexelman

Follow this and additional works at: <http://elischolar.library.yale.edu/ymtdl>

Recommended Citation

Wexelman, Barbara, "Intussusception of the Appendix: New trends and comprehensive analysis of 140 case reports" (2009). *Yale Medicine Thesis Digital Library*. 469.
<http://elischolar.library.yale.edu/ymtdl/469>

This Open Access Thesis is brought to you for free and open access by the School of Medicine at EliScholar – A Digital Platform for Scholarly Publishing at Yale. It has been accepted for inclusion in Yale Medicine Thesis Digital Library by an authorized administrator of EliScholar – A Digital Platform for Scholarly Publishing at Yale. For more information, please contact elischolar@yale.edu.

Intussusception of the Appendix: New trends and comprehensive analysis of 140 case reports

A THESIS SUBMITTED TO THE
YALE UNIVERSITY SCHOOL OF MEDICINE
IN PARTIAL FULFILLMENT OF THE REQUIREMENTS FOR THE
DEGREE OF DOCTOR OF MEDICINE

BY
BARBARA A. WEXELMAN
2008

ABSTRACT

Title: INTUSSUSCEPTION OF THE APPENDIX: NEW TRENDS AND COMPREHENSIVE ANALYSIS OF 140 PUBLISHED CASE REPORTS. Barbara A. Wexelman, Cassius Ochoa Char, and Walter Longo. Section of Colorectal Surgery, Department of Surgery, Yale University, School of Medicine, New Haven, CT.

Statement of Purpose: This paper uses 139 published case reports to understand the demographic, diagnostic, and treatment trends of intussusception of the appendix.

Methods: Using the PubMed literature search engine to find all English references of “intussusception” and “appendix”, and reviewing those that contained actual case reports of intussusception of the appendix, we analyzed the demographics, presentation, diagnostic methods, surgical treatment, and histology from 140 articles representing data from 181 patients.

Results: There were 41 (22.5%) pediatric cases and 141 (77.5%) adult cases. The average age was 37.3 years. There were more males in the pediatric set (23 males to 18 females) while there were more females in the adult set (38 males to 101 females). The most prevalent symptoms in children were abdominal pain (87.8%), vomiting (53.7%), and nausea (26.8%). The adults presented with abdominal pain (75.4%), bloody stools (26.1%), and vomiting (18.1%). Most of the patients reported chronic symptoms (62.6% chronic, 30.8% acute). Barium enema was the most prevalent method for both pediatrics (43.9%) and adults (49.3%). The most common surgical procedure for both the children and the adults was appendectomy (43.9%), followed by right hemicolectomy (20.6%). Prior to 1990 the majority of IA cases were diagnosed intra-operatively (64.8%), but since 2000 over half of the patients (56.8%) were given the correct diagnosis pre-operatively, and less than one third (29.6%) of patients were diagnosed intra-operatively. Endometriosis was the most common histopathology in adult women (37.6%).

Conclusions: Adults, especially middle-aged women, make up the majority of patients with intussusception of the appendix. IA should be considered in the workup of chronic abdominal pain in women, and may likely be linked with gastrointestinal endometriosis. Increasingly IA is a pre-operative diagnosis, aided by colonoscopy and CT imaging.

ACKNOWLEDGEMENTS

This project would not have been possible without the scientific, emotional, and financial support from Cassius Chaar M.D., Walter Longo M.D., John Geibel M.D., the Yale Office of Student Research, Dean Nancy Angoff, David Spar M.D., and the librarians and staff of the Cushing/ Whitney Medical Library at the Yale School of Medicine.

I would also like to thank the following surgical mentors that encouraged and nurtured my interest which brought me to this point today: Richard Gusberg, Walter Longo, Michael O'Brien, Charlotte Ariyan, Philip Wai, Paul Barcewicz, Kurt Roberts, Nina Horowitz, Hulda Einarsdottir, Vik Reddy, Charles Cha, and Ronald Salem.

This research was partially funded by a short-term research grant from the Office of Student Research, Yale School of Medicine.

TABLE OF CONTENTS

Introduction	4
Statement of Purpose	20
Methods	22
Results	25
Discussion	27
References	36
Appendix 1: Articles included in Meta-Analysis	38

INTRODUCTION

Intussusception of the appendix (IA) is a rare clinical event. Historically, intussusception of the appendix was found intra-operatively in patients with acute right lower quadrant pain and presumed appendicitis. There is an increasing number of case reports of intussusception of the appendix found in patients with chronic abdominal pain, many thought to have neoplasm of their gastrointestinal tract. In these cases, many of these patients undergo large oncologic resections which carry high morbidity, only to find out there is no cancer, but rather intussusception of the appendix. As endoscopic and radiologic technology advances and becomes more prevalent in the workup of abdominal pain, it is possible that intussusception can be diagnosed pre-operatively, and patients treated with a simple appendectomy. This paper looks at the large body of published case reports and seeks to understand trends in the demographics, diagnosis, and treatment of intussusception of the appendix.

Abdominal Pain

Abdominal pain is the most common symptom requiring a general surgery consultation in the world. Appendicitis is the most common surgical disease manifesting with abdominal pain and requiring emergent intervention by a surgeon. With 250,000 appendectomies performed every year, Addiss et al. estimated the lifetime risk of appendectomy to be 8.6% for males and 6.7% for females [1]. In California alone, appendicitis accounts for over 31,000 admissions per year to hospitals [2]. Of these admissions, over 9,100 result in appendectomies; the other 2/3 of patients seemingly had other sources of their abdominal pain. In this study of California hospitals, the average appendicitis admission lasts four days, with a cost of

over \$12,000. Older patients, covered by the Medicare system had a longer length of stay, 8 days, with a higher cost of over \$25,000 [2]. This is just one example. The burden to society of chronic and acute abdominal pain is enormous. Therefore, it is understandable that emergency medicine clinicians, gastroenterologists, radiologists, surgeons, and hospital administrators and payors all have a stake in the correct and timely diagnosis and treatment of abdominal maladies.

Acute Abdominal Pain

Acute abdominal pain of surgical significance is often diagnosed based on location. Upper abdominal pain may represent cholecystitis, ulcers, or pancreatitis. Lower abdominal pain may be a symptom of appendicitis, inflammatory bowel disease, gastroenteritis, diverticulitis, or multiple gynecologic etiologies such as pelvic inflammatory disease, ectopic pregnancy, or endometriosis. Patient's history and physical exam are the cornerstones of diagnosis with acute abdominal pain. Intussusception is thought to be a primarily acute condition, with similar presenting symptoms as appendicitis.

Chronic Abdominal Pain

Chronic gastrointestinal and liver disorders exact heavy social and economic costs in the United States. The total direct and indirect costs of the 17 most common digestive diseases were estimated to be \$38.8 Billion in the United States in 2002 [3]. Disorders associated with chronic abdominal pain account for a large portion of this figure. Chronic (non-malignant) GI disorders such as diverticular disease, irritable bowel syndrome, Crohns Disease, and Ulcerative Colitis account for \$4.8 Billion per

year. Gastrointestinal cancers add another \$7.3 Billion per year [3]. The most prevalent chronic gastrointestinal syndromes are GERD (19 million people/year) and irritable bowel syndrome (15 million people/ year) [3]. Thus, the understanding of the prevalence and costs of these diseases is important to reduce the burden of chronic abdominal pain and associated illnesses on society.

Chronic abdominal pain may be more difficult to diagnose, and often the correct diagnosis and treatment relies on patient's history and subsequent imaging techniques.

Intussusception

Intussusception is defined as the invagination of a bowel loop with its mesenteric fold (intussusceptum) into the lumen of a contiguous portion of bowel (intussusciens) due to peristalsis. Lesions within the lumen of a portion of bowel have a higher likelihood to cause invagination as peristalsis drags the lesion forward [4]. Intussusception within the gastrointestinal tract is primarily a pediatric disorder. Only a small percentage, some estimate 5% [4] occur in adults. Some authors believe because intussusception in adults is so rare, it is caused by a serious underlying disorder [4].

Patients with intussusception may or may not be symptomatic, and symptoms can be acute, intermittent, or chronic [4]. Complaints depend on the location of the intussusception but there may be a history of episodic cramping abdominal pain, nausea, and vomiting suggesting intestinal obstruction. If a neoplastic process is the lead point of the intussusception, patients may present with symptoms of the neoplasm rather than the intussusception, such as constipation, melena, weight loss, or

a palpable mass. Other causes of lead points include lipomas, Meckel diverticulum, adhesions, and adenomatous polyps [4].

In many cases, intussusception is distinguished from other abdominal pathologies by radiological evidence of bowel-within-bowel. Depending on the location, intussusception typically appears as a target like or sausage-shaped mass. On computerized tomography it is possible to also visualize distinct anatomical features such as the entering wall, mesenteric fat and vessels, the returning wall, and intraluminal space. The presence of a lead point, the configuration of the lead mass, degree of bowel edema, and amount of invaginated mesenteric fat all contribute to the appearance of the intussusception. If bowel wall edema is present due to impaired circulation of the mesenteric vessels, thickened bowel loops make it difficult to differentiate a lead mass from inflammation [4]. The growing reliance on radiological technology in the workup of abdominal pain has led to an increase in the detection of transient asymptomatic intussusceptions without serious pathology [4].

Type of Intussusception

Intussusception is classified by location and can be enteroenteric, ileocolic, ileocecal, or colocolic. They are also classified by etiology, such as benign, malignant, or idiopathic, and whether there is a lead point present. Intussusception without a lead point is more likely transient and does not usually cause proximal bowel obstruction [4].

Small bowel intussusception is more common without a lead point than with a lead point. If intussusception occurs in the small bowel with a lead point, it is likely due to a benign condition rather than malignancy. The most common cancer causing

small bowel intussusception would be a metastasis from another site. In the large bowel, more than half of intussusception results from primary or secondary malignancy, most commonly colon adenocarcinoma requiring surgical treatment and oncologic resection. Benign lesions causing intussusception of the large bowel are entities such as lipoma and adenomatous polyp. Patients with intussusception often present with abdominal pain and vomiting from bowel obstruction [4].

Appendiceal Intussusception

Intussusception of the appendix is a rare disorder with much surgical curiosity. There are over 200 published case reports of IA since 1858, though no recent, comprehensive reviews of these reports exist. The frequently referenced paper by Collins reported a 0.01% incidence of IA from the 70,000 appendix samples he reviewed [5]. Despite the small number of case reports in the literature, it seems likely that a general surgeon will encounter IA in his career. As such Fink reported in his paper published in 1964, that most senior surgeons remembered few cases of IA they operated on in the past. Fink, Santos, and Goldberg reviewed 118 cases and found that the age of occurrence ranged from 10 months to 75 years with average of 16 years, however most cases occurred in the first decade of life. This finding has led to the common belief that IA as a pediatric condition. They found IA occurred most commonly in males with a male: female ration of 5:1 [6]. Later, Jevon et al reviewed cases from 1984- 1992 and found equal gender frequency [7]. Unfortunately, the reviews available in the literature are not comprehensive. There is no clear analysis of age and gender and no appropriate referencing of cases reviewed. Also, Jevon et al. drove their conclusion about equal gender frequency of IA from the data of 12 case

reports from 1984 – 1992. Our comprehensive review of PubMed shows at least 19 cases during the same time frame.

Physiology

There are two general categories of pathophysiologic causes of IA, anatomic and pathologic [8]. Anatomic causes of intussusception of the appendix include:

- fetal type cecum with appendix originating from its tip
- appendix with a wide lumen and the proximal lumen wider than the distal lumen
- thin mesoappendix with a narrow base and minimal fat
- mobile appendicular wall with active peristalsis
- free appendix, unfixed by peritoneal folds or adhesions

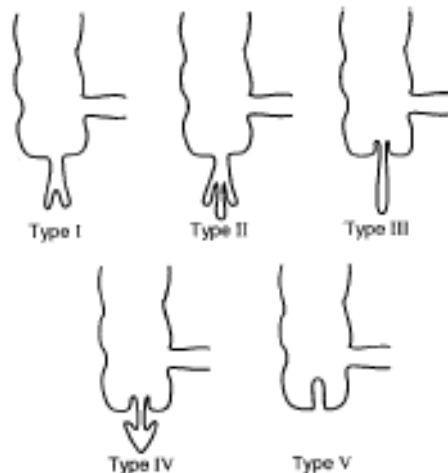
Pathologic causes of intussusception often result from active peristalsis due to fecaliths, foreign bodies, parasites, appendiceal neoplasms, lymphoid follicles, and endometrial implants [8].

Other parts of the bowel may also have a role. Intestinal peristalsis may milk the appendix into cecum. The anatomy of the cecum may also promote intussusception if there is failure of the third stage of rotation of the bowel during development. A fixed cecum is unlikely to intussuscept [6].

Lastly, as Komine notes, IA can occur without any pathologic lesions. There may be metabolic and hemodynamic causes of intussusception. In patients without identifiable lead point, intussusception may be related to submucosal bowel edema, fibrous adhesions, or dysrhythmic contractions [9].

There are different types of intussusception of the appendix (Fig 1). This classification of anatomical types of IA was originally described by Mashowitz (1910), and later modified by McSwain (1941).

Figure 1: Types of Intussusception of the Appendix [6]



1. The tip of the appendix forms the intussusception and is invaginated into the proximal appendix, which forms the intussusciens.
2. The invagination starts at some point along the length of the appendix in the same way as an intussusception starts in the ileum.
3. The invagination starts at the junction of the appendix and cecum. The appendix forms the intussusception and the cecum is the intussusciens. This is the most common type.
4. This is retrograde intussusception, where the proximal appendix is invaginated into the distal appendix.
5. Complete invagination of the appendix into the cecum from progression of types 1, 2, or 3. [6]

In addition compound intussusceptions can occur with all types of intussusception under type 1, where the initial intussusception can initiate a compound or secondary intussusception of the cecocolic type when the invaginated appendix forms the apex. Lastly, all types of appendicular intussusception may be complicated by ileocolic intussusception [6].

Malignant Lesions of the Appendix

As with other intussusceptions, the presence of a mass in the appendix that can act as a lead point will increase the risk of intussusception. In adults, this lead point is generally considered a malignancy until proven otherwise. This paper will look at the question of what pathology serves as the lead point.

Types, Prevalence, and Treatment

Malignancy of the appendix is rare. They make up only 0.5% of all gastrointestinal tumors and are rarely diagnosed pre-operatively [10]. Most commonly, malignancy is discovered on histopathologic section of an appendix removed for another cause, less than half of the tumors are diagnosed intra-operatively [11]. The four main types of appendiceal neoplasms are carcinoid tumors, mucinous cyst-adenocarcinomas, colonic adenocarcinomas, and adenocarcinoid tumors. Notably, even with therapy all types of malignancy of the appendix have a 15% to 20% chance of having a second malignancy, usually in the abdomen, either at the time of the primary cancer or after therapy [12].

Carcinoid is the most common malignant tumor of the appendix, compromising anywhere from 50% to 85% of specimens [12] though there is some

evidence that the prevalence of carcinoid is decreasing over time [11]. While many believe carcinoid tumors are not aggressive lesions, they are considered malignant because they have the potential for invasion, metastasis, and production of physiologically active molecules [12]. Carcinoid is most common in younger women though this may be an artifact due to appendectomies at time of laparotomy for gynecological cases 80% of appendiceal carcinoids are incidental findings in surgery for other indications [12]. The most important factor in considering the malignant potential of carcinoids is the size of the lesion- distant metastases and death occur at more significant rates in patients with tumors larger than 2.0 cm in diameter. In these patients, right hemicolectomy is the standard treatment [12].

The second most common malignancy of the appendix is mucinous cystadenocarcinoma, with prevalence ranging from 25% to 40% depending on the series studied [11]. These lesions may be diagnosed pre-operatively more frequently than carcinoid. Most patients are symptomatic, and some have a palpable mass in the right lower quadrant. Approximately 50% of patients have intra-abdominal metastases or pseudomyxoma peritonei. Mucinous cystadenocarcinomas are differentiated from benign mucinous cystadenomas by histologic features: invasion of the appendiceal wall by atypical glands, and the identification of epithelial cells in any intraperitoneal mucinous collection. Cystadenomas are cured by appendectomy, while malignant cystadenocarcinomas require a right hemicolectomy [12].

Colonic adenocarcinoma of the appendix behaves like other adenocarcinoma, and are microscopically identical [12]. Most tumors arise from the base of the appendix, or even the post-appendectomy stump. Because the appendiceal walls are deficient in muscle, if the malignancy involves the submucosa it is essentially staged

subserosal. Therefore, these cancers can present at late stages, requiring a right hemicolectomy for complete removal of the tumor, if possible [12]. If regional or distant lymph nodes are positive, the patients should be treated like similarly staged colon cancer with chemotherapy.

Adenocarcinoid is the rarest type of appendiceal malignancy. These masses exhibit both adenocarcinoma and carcinoids features, and are also called goblet cell carcinoid, mucinous carcinoid, or crypt cell carcinoma in the literature [12]. They are more aggressive than carcinoid, but less aggressive than adenocarcinoma. They are usually smaller than 2.0 cm in diameter, involve all parts of the appendix equally, and are infiltrative. Here, size is not a reliable predictor of malignant potential. Patients usually have symptoms, and present with an acute appendicitis picture, as such the correct diagnosis is most often made post-operatively on histopathologic inspection. Right hemicolectomy is the best treatment for patients with localized disease [12].

Non-Malignant Lesions of the Appendix

While the lead point is usually feared to be cancer, there have been many reported cases of non-malignant lesions of the appendix with intussusception. The most common lesions are endometriosis and mucocoeles. One aspect of this paper will consider what the common appendiceal histopathologies are associated with the reports of intussusception of the appendix.

Endometriosis

Endometriosis is the presence of endometrial tissue outside the uterine endometrium and myometrium. The disorder affects between 8- 15% of menstruating

women [13]. The most common sites for endometriosis in the GI tract are the recto and sigmoid colon [13]. The first published case of endometriosis of the appendix was by Sampson in 1921. At that time the frequency of endometriosis involving the appendix were estimated between 1% and 5.3% of the female population and the frequency of endometriosis in appendectomy specimens ranging from 0.05% to 0.8% [13]. The first reported case of endometriosis as a cause of intussusception of the appendix was by Deacon in 1949. Interestingly, some cases of appendiceal intussusception had isolated endometriosis of the appendix without evidence of pelvic or visceral involvement. The causal mechanism is thought to be that the endometrial implants, tumors, swelling or post-inflammatory scar nodules may cause irritation leading to increased or irregular peristalsis which is one of the significant factors in producing appendiceal intussusception [6].

Mucoceles

Mucoceles are the accumulation of mucin in the lumen of the appendix due to proximal obstruction of the lumen. The obstruction of the lumen may be “normal” involution changes in the appendix which increases with advancing age, or due to post-inflammatory scarring. If the involution occurs near the base while the tip still secretes mucus, a mucocele may result. Mucoceles may occur in response to, or as the impetus for intussusception of the appendix [6]. An appendix with a mucocele is characterized by marked muscular hypertrophy, injected dilated vessels, and filled with gelatinous mucin. A normal appendix may produce one to two milliliters of secretions per day [6].

Presentation of Intussusception of the Appendix

Presentations of intussusception of the appendix range from asymptomatic patients and incidental findings on laparotomy or autopsy, to an acute appendicitis-type picture. Patients may also complain of chronic abdominal pain, palpable abdominal mass, rectal bleeding, and constipation. Often laboratory data cannot distinguish IA from other causes of abdominal pain [8].

In the acute picture, the symptomatology may mimic appendicitis, with colicky lower right quadrant abdominal pain of several hours duration, nausea, and vomiting. There may be no changes in bowel habits or associated constipation. The patient is usually afebrile, and without leukocytosis. However, in the presence of fever or an elevated white blood count the physician should be alarmed for possible bowel ischemia associated with the intussusception. Occasionally a small mass may be palpated in the right iliac fossa.

Several aspects of the clinical presentation in the acute setting may help differentiate IA from acute appendicitis include [6]

1. History of multiple attacks
2. History of a small, palpable mass
3. Absence of fever
4. Absence of tachycardia
5. Normal white cell count
6. Less severe muscle spasm and tenderness in the right lower quadrant.

Other patients present with a more chronic abdominal pain picture, some with symptoms for years. These patients complain of intermittent, sudden episodes of

severe abdominal pain over the right lower quadrant, with or without vomiting, and possible mucus or blood in their bowel movements. The episode can last for several hours to a day, and then the patient returns to their normal state of health. Physical exam between the episodes is unremarkable, if there is blood in the stool there is a higher likelihood of repeated intussusception [6]. Especially if the patient also complains of nausea and weight loss, many of these patients will undergo diagnostic workup looking for malignant neoplasm. Recent advances in radiology and colonoscopy have made this diagnosis easier. The connection between intussusception and malignancy serves as the logical reasoning why many believe most cases of IA in adults is tumor related [8]. If the workup is negative, patients may be labeled with “waste-basket” type diagnoses, such as Irritable Bowel Syndrome, or referred to psychiatry.

Lastly, appendiceal intussusception may be totally asymptomatic, and be found on laparotomy for other causes [14], commonly gynecologic pathology [15], or on routine colonoscopy screening [5].

Diagnostic Imaging of Intussusception of the Appendix

Through advancements in radiological and endoscopic imaging, it is now possible to diagnose IA pre-operatively. . In fact, the majority of cases reported after the year 2000 were diagnosed with IA before surgery There are several case reports in the recent literature highlighting this finding. Reported radiologic signs of intussusception include:

1. Ultrasound- multiple concentric ring sign / target like appearance

2. Barium Enema- coiled-spring sign and cecal filling defect with non-filling of the appendix

3. Computed Tomography- well-demarcated cylindrical mass of soft tissue

4. Colonoscopy- mushroom like polypoid tumor with dimple on top

The diagnosis of IA has important implications on the management of patients in the acute as well as the chronic setting. Acutely, the diagnosis of intussusception can guide the surgeon to attempt reduction and subsequent appendectomy. A surgeon unfamiliar with this condition may misdiagnose a mass in the cecum and proceed with an unnecessary oncologic hemicolectomy. On the other hand, patients who undergo an elective work up for intermittent abdominal pain by a gastroenterologist may get a colonoscopy. An intussuscepted appendix may be mistaken for a polyp, undergo biopsy, and potential cause cecal perforation and peritonitis. Also, in the hands of an experienced gastroenterologist, an IA can be diagnosed and treated with colonoscopy [16].

Treatment of Appendiceal Intussusception

As this paper will show, there have been many surgical treatments for intussusception of the appendix. The anatomy and surgical approaches will be reviewed now.

Review of Pertinent Anatomy

The appendix is an outpouching of the cecum, initially projecting from the apex of the cecum but the base gradually rotates during development towards the ileocecal valve. A branch of the ileocolic artery, the appendiceal artery, supplies the

appendix. The length of the appendix can vary from 2 to 22 centimeters, but the average is about 9 cm in length. The tip of the appendix can be found retrocecal (65%), in the pelvis (30%) and retroperitoneal (2%). Rarely, the tip is found in pre-ileal or post-ileal locations, complicating the diagnosis of appendiceal disease [10].

Appendectomy

The preferred treatment of intussusception of the appendix, if diagnosed prior to resection, is the standard appendectomy. The intussusception can be reduced at the beginning of the case and the surgeon proceeds with a standard appendectomy. Appendectomy can be performed through an open incision in the right lower quadrant or laparoscopically. The open technique is most commonly done through a transverse incision over McBurney's point (Rocky-Davis incision). After splitting the muscles of the abdominal wall, the peritoneal cavity is penetrated. The cecum and the appendix are delivered through the incision. The mesoappendix is divided between clamps and tied off. The appendix is divided at the base. The appendiceal stump is frequently inverted using a Z stitch, a purse string stitch or a combination of both. The peritoneum and the fascial layer are then closed. If the appendectomy is done through an open incision, it is usually made as a transverse right lower quadrant incision. The appendix is delivered through the incision, and the appendiceal artery within the mesoappendix is tied off or clipped and ligated. Some surgeons then place a pursestring or Z-stitch in the cecum, excise the appendix, and then invert the stump in the cecum. Then the peritoneum is closed. If the appendix has not perforated, the risk of infection is less than 5% [10].

The first case of laparoscopic appendectomy for IA was reported in 1999 by Galatioto. The ability to proceed laparoscopically depends mostly on the possibility to reduce the intussusception laparoscopically. Once this is performed, laparoscopic resection proceeds in a standard fashion with 3 ports: one in the periumbilical location, one the suprapubic location and the last one either in the Left lower quadrant or even the right lower quadrant depending on the surgeon's preference. If the appendectomy is done laparoscopically, generally three ports are placed, one at the umbilicus, and two others in the abdomen. The appendix can be removed using endoloops or an endoscopic stapling device [10].

Hemicolectomy

If the intussusception of the appendix is precipitated by malignancy, an oncologic resection may be indicated. In several of the case reports malignancy was suspected and a right hemicolectomy was performed, histology would show that no cancer was present and intussusception of the appendix is due to benign pathology. In these cases, correct pre-operative diagnosis would prevent these patients from undergoing unnecessary resection with higher morbidity.

The goal of surgical resection of colon (or appendiceal) cancer is the removal of the cancer with adequate margins, regional lymphadenectomy, and restoration of a continuous gastrointestinal tract. The extent that must be sacrificed is determined by the location of the cancer, the blood supply and lymphatic drainage, and the possibility of the malignancy involving adjacent organs. For lesions involving the cecum, appendix, ascending colon, and hepatic flexure, a right hemicolectomy is the procedure of choice. The right hemicolectomy involves resection of 4- 6 centimeters

of the terminal ileum and colon up to the division of the middle colic vessels into the right and left. Anastomosis is created between the terminal ileum and the transverse colon [10]. The blood supply to the right colon is divided close to the origin of the right colic artery and the corresponding draining lymph nodes are removed as well.

STATEMENT OF PURPOSE

To date, there is no comprehensive review of the published case reports of intussusception of the appendix. In our review of the literature, we could not find a comprehensive review looking at all the case reports in the literature. The reported figures on demographics, sex predilection, pathology of IA were based on limited searches of the literature. Thus, this paper includes a complete review of the English literature in Pubmed. This paper uses 139 published case reports to understand the trends in demographic, diagnostics, and treatment of intussusception of the appendix. The figures lack statistical power because they are based on case reports since IA is such a rare event. The goal is to provide the medical community with the best available data and trends in IA based on a comprehensive review of the literature. While I cannot prove causality, or even universalize my results because the data is only based on published case reports, I hope to provide compelling evidence that recent trends in the demographics, presentation, and treatment of intussusception of the appendix may be different than what is commonly considered. The following hypotheses will be tested within these case reports:

1. Opposite from the classic beliefs about IA, chronic abdominal symptoms are more common than acute symptoms. Middle-aged women are more likely afflicted with the chronic syndrome than children or men.

2. Pre-operative diagnosis of IA is increasing due to the ubiquitous use of computerized tomography scanning. In addition, advances in endoscopic techniques and the use of colonoscopy aide in the pre-operative diagnosis of intussusception as well as its treatment.

3. With increasing pre-operative diagnosis of IA, more patients are treated with appendectomy, sparing patients' right hemicolectomy when malignancy is not present.

METHODS

Using the PubMed literature search engine, 6665 articles are listed under “Intussusception”. Combining search fields “Intussusception” and “appendix”, 309 articles are listed. Limiting the references to the English language only, between 1940- 2007, there are 221 references. Of these 221, upon review 67 were not actual case descriptions of intussusception of the appendix, leaving 154 actual references for our database. Of these 154 articles, Cassius Chaar M.D. and I secured copies of 139 (90.3%) of these articles from the Harvey Cushing/ John Hay Whitney Medical Library of the Yale School of Medicine to be included in our database (see Table 1). The 139 articles represent data from 181 patients. In addition, one case of intussusception of the appendix was added from our home institution’s recent experience, totaling 182 individual cases in our data set. I assisted Dr. Chaar in the identification of appropriate and erroneous references using the PubMed search engine through the Medical Library portal.

I reviewed all the accessible case reports in our data set, assigned each an identification number and entered the following pertinent data into a Microsoft Excel database:

- Year, Author, Number of Cases described.
- Gender and Age of the patients described.
- Pertinent presenting symptoms of each case.
- Whether the symptoms were acute or chronic. If the patient presented with less than seven days of abdominal pain, the presentation was considered acute. If the symptoms were intermittent and separated by more than seven days, it was classified as a chronic case.

Table 1: Published case reports used in analysis

Author	Date	n	Author	Date	n	Author	Date	N
O'Beirn, S	1949	1	Ho, L	1975	1	Reddy, KM	1998	1
Ward, JN	1949	1	Pardoll, PM	1976	1	Yoshikawa, A	1998	1
Deacon, AL	1949	1	Geerdsen, J	1976	2	Larsen, S	1999	3
Conway, ME	1949	1	Genell, S	1976	1	Nycum, L	1999	1
Zeifer, H	1951	1	Skaane, P	1977	1	Galatioto C	1999	1
Allman, D	1952	1	Rodriguez, M	1978	1	Kimura, H	1999	1
Morton, P	1952	1	Seaman, W	1978	1	Attard, T	2000	1
Dunavant, D	1952	1	Velik, MM	1978	1	Gupta, P	2000	1
Forshall, I	1953	7	Ekberg, O	1978	1	Chen, YC	2000	1
Beard, D	1955	1	Holck, S	1979	1	Ohno, M	2000	1
Adelman, BP	1955	2	Kleinman, P	1980	1	Ozuner, G	2000	2
Sale, TA	1956	1	Martin, L	1980	1	Patton, K	2000	1
Bevan, G	1957	1	Ackerman, N	1981	1	Pumberger, W	2000	2
William, F	1957	1	Fazio, RA	1982	1	Scully, R	2000	1
Weiner, J	1957	1	Yates, L	1983	4	Sriram, P	2000	1
Elson, M	1958	1	Langsam, L	1984	2	Casey, R	2001	1
Campbell, J	1959	1	Mann, W	1984	2	Hoeksema, M	2001	1
Juca, W	1960	1	Dewan, PA	1985	1	Koumanidou, C	2001	4
Day, W	1962	1	Fullerton, T	1985	1	Rudek, B	2001	1
Schneider, LA	1962	1	Garden, OJ	1985	1	Coulier, B	2001	1
Weiner, J	1962	1	Levine, M	1985	2	Mazaki, T	2002	1
Welch, J	1962	1	Casteels, M	1986	1	Flint, R	2003	1
Watkins, GL	1963	2	Sonnino, R	1986	1	Takahashi, M	2003	1
Fink, VH	1964	2	Bailey, DJ	1987	1	Komine, N	2004	1
Jewett, T	1964	1	Itoh, J	1987	1	Matthew, J	2004	1
Mann, L	1964	1	Maglinte, DD	1987	1	Vogelaar, FJ	2004	1
Shahade, M	1965	1	Chijiwa, Y	1988	1	Ram, A	2005	1
Paul, G	1967	3	Hartman, E	1988	1	Ryu, BY	2005	1
Bridger, GP	1968	1	Gilpin, D	1989	1	Karabulut, R	2005	1
Gorske, K	1968	1	McIntosh, JC	1990	1	Duncan, J	2005	1
Krasna, I	1969	1	Relan, M	1990	1	Akbayir, N	2006	1
Hill, B	1970	2	Ardie, PH	1990	2	Cois, A	2006	1
Howard, RJ	1970	2	Sadahiro, S	1991	1	De Hoyos, A	2006	1
Meyers, M	1970	1	Chetty, R	1992	1	Luzier, J	2006	1
Bachman, A	1971	7	Jevon, G	1992	4	Taban, S	2006	1
Banerjee, AK	1971	1	Tsunoda, T	1992	1	Thomas, R	2006	1
Pearlman, DM	1971	1	Kantarovsky, A	1993	1	Tseng, P	2006	1
Schmidt, F	1971	1	Lauwers, G	1993	1	Kawamura, YJ	2007	1
Tao, H	1971	1	Varty, K	1993	1	Moradi, P	2007	1
Kloppedal, E	1972	1	Schmidt, J	1994	1	Offodile, A	2007	1
Panganiban, W	1972	1	Tonsekar, K	1994	1	Blondiaux, E	2007	1
DeGerome, J	1973	2	Miyahara, M	1995	1	Butte, JM	2007	1
Down, R	1973	2	Panzer, S	1995	1	Swanger, R	2007	1
Brewer, R	1974	1	Sakaguchi, N	1995	3	tavakkoli, H	2007	1
Darby, AJ	1974	1	Kegelaers, B	1996	1	Waseem, T	2007	1
Wirtschaffer, SK	1976	1	Darry Jones, C	1997	1	Ochoa Chaar, CI	2007	1
Atkinson, G	1976	2	Heithold, D	1997	1			

- Diagnostic methods used.
- Type of surgical therapy performed.
- Histopathology of the specimen, if known.
- The timeline of when the intussusception of the appendix was identified (pre-operatively, intra-operatively, post-operatively).

I performed several analyses using the database. I separated the analysis between pediatric cases and adults, and then found the proportion of males and females, and the average age of the patients in each group. I also looked at these factors for the entire patient set. Then I determined the prevalence of each symptom, histology, and surgical treatment. I calculated when the correct diagnosis of intussusception of the appendix was made: pre-operatively, intra-operatively, or post-operatively, and how the timing of the diagnosis changed over time. The numbers derived from our database show the trends in demographic, diagnosis and treatment of intussusception of the appendix based on the best available information in the English literature. Because the condition is rare, the data is limited to case reports and does not have the power to support statistical analysis.

Refworks Web Based Bibliographic Management Software was used to manage the references.

RESULTS

The demographics of the patient data set are described in Table 2. Pediatric cases were defined as patients under the age of 18. There were 41 (22.5%) pediatric cases and 141 (77.5%) adult cases. The range of ages was 5 months to 85 years. The average age of the pediatric patient in our series was 6.9 years, and 46.4 years for the adults. The average age for the entire group was 37.3 years. There were more males in the pediatric set (23 males to 18 females) while there were more females in the adult set (38 males to 101 females). As there are three times the numbers of adults compared to children in the data set, the overall gender balance was skewed towards females (66.1%).

Table 2: Demographics of Patient Population

	Pediatrics		Adult		Total	
Number of Cases	41	(22.5%)	141	(77.5%)	182	
Average Age	6.94 yrs		46.36 yrs		37.3 yrs	
Gender:						
Male	23	(56.1%)	38	(27.3%)	61	(33.9%)
Female	18	(43.9%)	101	(72.7%)	119	(66.1%)

Most of the patients had one or more presenting symptoms (Table 3). Abdominal pain was the most common symptom (78.2%), followed by vomiting (26.3%) and blood in their stools or blood on rectal exam (23.5%). Only three of the 182 patients did not report presenting symptoms (1.7%). If we look at the children only, the most prevalent symptoms were abdominal pain (87.8%), vomiting (53.7%), and nausea (26.8%). The adults presented with abdominal pain (75.4%), bloody stools (26.1%), and vomiting (18.1%).

Overall, most of the patients reported chronic symptoms (62.6% chronic, 30.8% acute). Twelve patients (6.6%) did not report the timeframe of their

symptoms. Of the pediatric patients, 16 (39.0%) had an acute presentation of their symptoms and 25 (61.0%) reported chronic symptoms. The adults had slightly more chronic symptoms (63.1%) than acute (28.4%).

Table 3: Symptoms & Diagnostic Methods in Intussusception of the Appendix

	Pediatric		Adult		Total	
Presenting Symptoms						
Abdominal Pain	36	(87.8%)	104	(75.4%)	140	(78.2%)
Vomiting	22	(53.7%)	25	(18.1%)	47	(26.3%)
Nausea	11	(26.8%)	23	(16.7%)	34	(19.0%)
Constipation	6	(14.6%)	12	(8.7%)	18	(10.0%)
Blood per Rectum	6	(14.6%)	36	(26.1%)	42	(23.5%)
Diarrhea	6	(14.6%)	18	(13.0%)	24	(13.4%)
Weight Loss	1	(2.4%)	10	(7.3%)	11	(6.2%)
Anorexia	2	(4.8%)	4	(2.9%)	6	(3.4%)
Anemia	0	(0%)	5	(3.6%)	5	(2.8%)
Unknown	0	(0%)	3	(2.1%)	3	(1.7%)
Chronicity:						
Acute	16	(39.0%)	40	(28.4%)	56	(30.8%)
Chronic	25	(61.0%)	89	(62.1%)	114	(62.6%)
Unknown	0	(0%)	12	(8.5%)	12	(6.6%)
Diagnostic Methods:						
Mass on Exam	15	(36.6%)	18	(12.9%)	33	(18.2%)
Colonoscopy	5	(12.2%)	39	(27.9%)	44	(24.3%)
CT Scan	2	(4.9%)	21	(15.0%)	23	(12.7%)
Ultrasound	12	(29.3%)	11	(7.9%)	23	(12.7%)
Barium Enema	18	(43.9%)	69	(49.3%)	87	(48.1%)
Abd X-Ray	4	(9.8%)	7	(5.0%)	11	(6.1%)
Incidental/ No Imaging	4	(9.8%)	25	(17.9%)	29	(16.0%)
Other	2	(4.9%)	3	(2.1%)	5	(2.8%)

The diagnostic methods employed in the pre-operative workup of these patients are varied. As we included published reports from 1940 to 2007, several of these modalities (ie. Colonoscopy, CT Scan) were not invented until late into our reference period. Overall, barium enema was the most prevalent method for both pediatrics (43.9%) and adults (49.3%). For children, the next most common

diagnostic method was mass felt on physical exam (36.6%) followed by ultrasound (29.3%). In adults the most common modality after barium enema was colonoscopy (27.9%) followed by incidental finding or no imaging (17.9%).

For the majority of patients treatment was surgical (see Table 4), and none of the cases reported continuation of symptoms after therapy. The most common surgical procedure for both the children and the adults was appendectomy (overall 43.9%), followed by right hemicolectomy (overall 20.6%). Several articles reported alleviation of symptoms with air or barium contrast enema, however the symptoms returned in most cases, requiring surgery. Other surgical procedures included ileo-cecal resection (13.9%), cecectomy (6.7%) and colonoscopic appendectomy (2.8%). One patient in the series underwent a subtotal colectomy.

Table 4: Surgical Treatment and Timeline of Diagnosis

	Pediatric		Adults		Total	
Surgical Treatment:						
Appendectomy	33	(80.5%)	46	(33.1%)	79	(43.9%)
Right Hemicolectomy	2	(4.9%)	35	(25.2%)	37	(20.6%)
Ileo-cecal resection	4	(9.8%)	21	(15.1%)	25	(13.9%)
Cecectomy	0	(0%)	12	(8.6%)	12	(6.7%)
Colonoscopic Appendectomy	0	(0%)	5	(3.6%)	5	(2.8%)
Other	2	(4.9%)	9	(6.5%)	11	(6.1%)
Unknown	0	(0%)	10	(7.2%)	10	(5.6%)
Timeline of Diagnosis						
Pre-operative	19	(46.3%)	40	(29.0%)	59	(33.0%)
Intra-operative	22	(53.7%)	79	(57.3%)	101	(56.4%)
Post-operative	0	(0%)	19	(13.7%)	19	(10.6%)

When we reviewed the timeline of the diagnosis of intussusception of the appendix we found most patients were brought to the operating room with a working diagnosis of something other than intussusception of the appendix. Only 59 cases (19

children, 40 adult) representing 33.0% of all patients had a pre-operative diagnosis of intussusception of the appendix. More than half of the children and adults (overall 56.4%) found the intussusception of the appendix intra-operatively. Nineteen adults (13.77% of adults) and no children were found to have intussusception of the appendix post-operatively on histopathologic examination.

We wanted to understand if pre-operative diagnosis of IA was increasing in prevalence over time (see Table 5). Prior to 1990, the majority of IA cases were diagnosed intra-operatively (64.8%), the patients were taken to the operating room with a diagnosis other than intussusception of the appendix. Only 25.7% of patients were diagnosed pre-operatively. Since 2000 however this trend has changed. Over half of the patients (56.8%) were given the correct diagnosis pre-operatively, and less than one third (29.6%) of patients were diagnosed intra-operatively. Similar numbers of cases were diagnosed post-operatively on histo-pathology before and after 2000.

Table 5: Changes in Timeline of Correct Diagnosis across Time

	Prior to 1990		After 1990		After 2000	
Timeline of Diagnosis						
Pre-operative	27	25.7%	32	43.8%	25	56.8%
Intra-operative	68	64.8%	31	42.5%	13	29.6%
Post-operative	10	9.5%	10	13.7%	6	13.6%

Histopathology differed between the children and the adults (see Table 6). In the pediatric population, twelve cases did not report a final pathology (29.3%). The most common described pathology was chronic inflammation or acute appendicitis (24.39%), followed by lymphoid hyperplasia and fibrosis (19.5%). Other common histology included mucocoeles (4.9%) and histologically normal appendix with

intussusception (4.9%). Two pediatric patients (4.9%) had malignancy in the intussuscepted specimen- one with MALT lymphoma, and one with papillary adenocarcinoma.

Table 6: Histology of Intussusception of the Appendix specimens

	Pediatric		Adults		Total	
Histology						
Endometriosis	0	(0%)	38	(29.5%)	38	(22.4%)
Carcinoid	0	(0%)	9	(7.0%)	9	(5.3%)
Mucin/Mucocele	2	(4.8%)	18	(14.0%)	20	(11.8%)
Villous Papilloma	0	(0%)	2	(1.6%)	2	(1.2%)
Adenocarcinoma	0	(0%)	7	(5.4%)	7	(4.1%)
Mucinous Carcinoma	0	(0%)	2	(1.6%)	2	(1.2%)
Chronic Inflammation	10	(24.4%)	9	(7.0%)	19	(11.2%)
Normal Appendix w/ intussusception	2	(4.8%)	9	(7.0%)	11	(6.5%)
Lymphoid Hyperplas.	8	(19.5%)	8	(6.2%)	16	(9.4%)
Villous Adenoma	0	(0%)	6	(4.7%)	6	(3.5%)
Mucinous Cyst- Adenoma	0	(0%)	9	(7.0%)	9	(5.3%)
Ulcerated Appendix	0	(0%)	2	(1.6%)	2	(1.2%)
Ischemic/ Necrosis	1	(2.4%)	4	(3.1%)	5	(2.9%)
Fecalith	0	(0%)	3	(2.3%)	3	(1.8%)
Hyperplastic Polyps	0	(0%)	4	(3.1%)	4	(2.4%)
Other	6	(14.6%)	2	(1.6%)	8	(4.7%)
Ovarian Cancer	0	(0%)	1	(0.8%)	1	(0.6%)
Melanosis Coli	0	(0%)	1	(0.8%)	1	(0.6%)
Unknown	12	(29.3%)	12	(8.5%)	24	(14.1%)
MALIGNANCY	2	(4.8%)	20	(15.5%)	22	(12.9%)

The adults had different and quite varied appendiceal histology. The most common reported histology was endometriosis of the appendix tip (29.46%), followed by mucocèles (14.0%) and non-reported histology (8.5%). Nine patients (7.0%) had each of the following diagnoses: carcinoid, chronic inflammation, normal appendix with intussusception, and mucinous cystadenoma. Twenty adult patients (15.5%) had malignancy on pathologic inspection. The malignancies included adenocarcinoma (5.4%), carcinoid, mucinous carcinoma (1.6%), ovarian cancer (0.8%), and melanosis coli (0.8%).

DISCUSSION

From our data it appears that the demographics of intussusception of the appendix do not correspond to what is cited in the literature about IA. While most commonly considered a pediatric disorder [6], in fact 77.5% of the cases reviewed were adults. When we break apart pediatric from adult intussusception, the average age of the children was 6.9 years, and the adults were 46.4 years. Most of the children with intussusception were age seven or younger (65.9%). It is possible that there may be a bimodal distribution of IA occurring for different reasons first in the young child and then again in middle age.

In addition, while intussusception is believed to be more common in males [6], in our review we found more women reported intussusception of the appendix. In the pediatric group there were 23 boys (56.1%) and 18 girls (43.9%), far from the 5:1 ratio of boys to girls that Fink reported. In the adult group, women made up 72.7% of the cases. Since our data set represents only published case reports it is possible that authors are more likely to write about women with intussusception than men, which may account for part of this difference. Even so it is clear that intussusception of the appendix in women is a real entity, and should be on the differential for women with chronic or acute lower abdominal pain.

While both pediatric and adult patients presented most commonly with abdominal pain (overall 78.2%), children were much more likely to have vomiting (53.7%) and nausea (26.8%) while adults had bloody stools (26.1%). The melena may be an important trigger for further diagnostic workup, especially in the older adult when malignancy may be considered. This diagnostic workup or ultimate treatment may lead to the identification of the intussusception. When mentioned, all

the patients in the series had a resolution of symptoms after surgical treatment and removal of the intussusception.

We hypothesized that the children would present with acute symptomatology while the adults had more chronic abdominal complaints. This proved not to be the case- both groups had high percentage of patients with chronic symptoms [chronic pediatric (61.0%), adults (63.1%)]. Many of the children had intermittent or recurrent symptoms lasting more than a week, some complaining of recurrent symptoms for years. In adults over 50 years old, 80.4% of the IA cases were chronic (of the cases where the chronicity was mentioned). It is important to recognize that intussusception of the appendix must be part of a chronic abdominal pain differential and that it may in fact be a more common presentation of intussusception of the appendix than the commonly thought of acute, lower abdominal pain. These chronic patients presented with different symptoms than those with the acute presentation. Chronic adult sufferers reported more constipation (12.6%) than adults overall (8.7%) as well as weight loss (9.2% in chronic sufferers, 7.2% in all adult sufferers). Conversely, the chronic sufferers had far less nausea (9.2% in chronic adults versus 16.7% adult sufferers overall) and vomiting (13.8% in chronic sufferers versus 18.1% of all adults) than the overall group of adult patients. The symptomatic picture of the patient with chronic intussusception of the appendix looks different from patients with acute intussusception and appendicitis. Chronic sufferers have more weight loss, constipation, and may paint a more ominous clinical picture as this profile raises concern for malignancy, especially with blood in the stools, which more than one quarter of the adult patients reported.

The children had different histology, and we believe lead points, of their intussusception compared to the adults. The children had a variety of histopathology, most commonly unknown histology when the authors of the case report did not comment (29.3%), chronic or acute appendicitis (24.4%), or lymphoid hyperplasia and fibrosis (19.5%). The adults were more likely to have significant pathology involved in the intussusception. Most common was endometriosis (29.5%), or mucocele (14.0%). Other pathology included carcinoid (7.0%), adenocarcinoma (5.4%), and mucinous cystadenoma (7.0%). When we analyzed the male and female adults separately, endometriosis stood out as the most common cause of the intussusception in women with over one third of cases reporting endometriosis on histopathology (37.6%). While mucoceles are reportedly more common in men [6], in our review women had mucoceles at higher rates (13.9% vs. 10.5%) than men. Interestingly, women had 8/9 cases (88.9%) of the mucinous cystadenomas reported, and relatively similar numbers of carcinoid compared to men (women 6.9%, men 5.3%).

Malignancy was reported in 20 of the adult cases (15.5%) and 2 pediatric cases (4.9%). This proportion is consistent with the increased risk of malignancy with increasing age. When separated by gender, malignancy was more common in men (18.4%) than women (12.9%), though there were still a significant number of malignancies found in the women (13) considering gastrointestinal cancer is more prevalent in men.

Intussusception is considered a rare clinical finding, considered hard to diagnose pre-operatively. Our data shows the majority of cases are in fact diagnosed intra-operatively (56.4%); the patient is taken to the surgical suite for a diagnosis

other than intussusception of the appendix. There are increasing numbers of reported correct pre-operative diagnosis- before 1990 only 25.7% of IA diagnosis was made pre-operatively, with 64.8% of the cases diagnosed intra-operatively. Since 1990, the majority of cases are reported pre-operatively (43.8%) compared to a declining amount of cases diagnosed intra-operatively (42.5%). We believe this change is due to an increasing reliance on diagnostic imaging, including colonoscopy, which was not as widely available before 1990. If we look at case reports from 2000 the results are even more striking- 56.8% of the cases (25 cases of a total of 44 cases) were diagnosed pre-operatively, while only 13 cases (29.6%) were diagnosed intra-operatively. That represents a significant decline from the overall average of 56.4% intra-operative diagnosis of all the cases in the data set. It is possible that in the future more pre-operative diagnosis of IA will lead to more appropriate matching of surgical treatment to pathology.

We believe the rise in pre-operative diagnosis of appendiceal intussusception is likely due to increased use of helpful diagnostic radiology and endoscopy. The availability and use of CT scans and colonoscopy has increased significantly in the last decade. Similarly, these technologies have been used increasingly in the workup of abdominal pain and the diagnosis of intussusception of the appendix. Since 2000, 55.6% of case reports used colonoscopy in the workup of patients with IA, more than doubling the overall use of colonoscopy in 24.3% of all the patients in the set. CT scans were also used in more than one third of patients (35.6%) compared to the entire data set (12.7%). The use of ultrasound also rose significantly, from 12.7% overall to 31.1% of patients diagnosed after 2000. As expected, the use of barium enemas declined to 15.6% after 2000, from 48.1% overall.

One end point we wanted to test was whether the type of surgical intervention changed over the time period of our investigation. Overall, appendectomy was the most common surgical intervention (43.9%), and chosen in children with an overwhelming rate (80.5%). The next most common surgical treatment was right hemicolectomy in adults (25.2%) and ileo-cecal resection in children (10%). The type of surgical treatment did not differ significantly when we considered cases since 2000. It seems that increases in pre-operative diagnosis and shifts in imaging modalities did not impact the end surgical intervention, which disproves one of our initial hypotheses, however it would be hard to prove causality from our data set. A possible reason why the surgical treatment did not change even though the IA was diagnosed earlier may be because malignancy was the preliminary diagnosis in adult patients with known intussusception, and as such a more extended resection was required to avoid having to re-operate on the patient if the histological section showed cancer.

In summary, our analysis shows compelling evidence in favor of two out of our three initial hypotheses. First, IA is likely to be a chronic condition in adults. The reported cases show significant occurrence of chronic abdominal pain with intussusception of the appendix in middle age women, most commonly with endometriosis of the appendix. In this patient population, while still a rare entity, intussusception of the appendix should be considered in a chronic pain workup, especially if endometriosis is present. A chronic IA syndrome may be described in the future.

Second, IA is no longer an intra-operative diagnosis. Pre-operative diagnosis of intussusception of the appendix is increasingly common, and goes along with the use increasing use of diagnostic radiology in the workup of abdominal pain.

Similarly, the higher prevalence of colonoscopy in the adult population, as well as the use of colonoscopy as a tool in the workup of abdominal pain, allows endoscopic techniques to take a larger role in the pre-operative diagnosis and treatment of IA.

While once feared as a cause of potential peritonitis, the technology for removing the intussuscepted appendix by colonoscopy is being further developed and several case reports describe successes [16].

Lastly, while it may be possible to remove IA by endoscopy, the rates of appendectomy versus right hemi-colectomy have not significantly changed over the last 100 years. This is likely due to the fear of malignancy in adult patients with IA, and pre-operative diagnosis often does not point to histopathology or the lead point of the IA unless a large mass or metastasis is seen. Therefore, while we may improve our diagnostic capabilities, changes in surgical treatment particularly for benign causes of intussusception of the appendix may lag behind. Most importantly, an attempt for a minimal resection/appendectomy should be made in women with endometriosis, as this seems to be a common cause of IA in this population.

REFERENCES

1. Addiss DG, Shaffer N, Fowler BS, Tauxe RV. The epidemiology of appendicitis and appendectomy in the united states. *Am J Epidemiol.* 1990 Nov;132(5):910-25.
2. Gill BD, Jenkins JR. Cost-effective evaluation and management of the acute abdomen. *Surg Clin North Am.* 1996 Feb;76(1):71-82.
3. Sandler RS, Everhart JE, Donowitz M, Adams E, Cronin K, Goodman C, et al. The burden of selected digestive diseases in the United States. *Gastroenterology.* 2002 May;122(5):1500-11.
4. Kim YH, Blake MA, Harisinghani MG, Archer-Arroyo K, Hahn PF, Pitman MB, et al. Adult intestinal intussusception: CT appearances and identification of a causative lead point. *Radiographics.* 2006 May-Jun;26(3):733-44.
5. Collins DC. 71,000 human appendix specimens. A final report, summarizing forty years' study. *Am J Proctol.* 1963 Dec;14:265-81.
6. Fink VH, Santos AL, Goldberg SL. Intussusception of the appendix. Case reports and reviews of the literature. *Am J Gastroenterol.* 1964 Oct;42:431-41.
7. Jevon GP, Daya D, Qizilbash AH. Intussusception of the appendix. A report of four cases and review of the literature. *Arch Pathol Lab Med.* 1992 Sep;116(9):960-4.
8. Komine N, Yasunaga C, Nakamoto M, Shima I, Iso Y, Takeda Y, et al. Intussusception of the appendix that reduced spontaneously during follow-up in a patient on hemodialysis therapy. *Intern Med.* 2004 Jun;43(6):479-83.

9. Agha FP. Intussusception in adults. *AJR Am J Roentgenol.* 1986 Mar;146(3):527-31.
10. Sabiston DC, Townsend CM. *Sabiston textbook of surgery : The biological basis of modern surgical practice.* 18th ed. Philadelphia, PA: Saunders/Elsevier; 2008.
11. McCusker ME, Cote TR, Clegg LX, Sobin LH. Primary malignant neoplasms of the appendix: A population-based study from the surveillance, epidemiology and end-results program, 1973-1998. *Cancer.* 2002 Jun 15;94(12):3307-12.
12. Rutledge RH, Alexander JW. Primary appendiceal malignancies: Rare but important. *Surgery.* 1992 Mar;111(3):244-50.
13. Moradi P, Barakate M, Gill A, Farrow G. Intussusception of the vermiform appendix due to endometriosis presenting as acute appendicitis. *ANZ J Surg.* 2007 Sep;77(9): 758-60.
14. Bachman AL, Clemett AR. Roentgen aspects of primary appendiceal intussusception. *Radiology.* 1971 Dec;101(3):531-8.
15. Mann WJ, Fromowitz F, Saychek T, Madariaga JR, Chalas E. Endometriosis associated with appendiceal intussusception. A report of two cases. *J Reprod Med.* 1984 Aug;29(8):625-9.
16. de Hoyos A, Monroy MA, Gallegos C, Checa G. Intussusception of the appendix resected at colonoscopy. *Endoscopy.* 2006 Jul;38(7):763.

Appendix 1: References included in Comprehensive Review

1. Complete invagination of the appendix progressing to ileocecolic intussusception. *Gastroenterology*. 2002 Dec;123(6):2165.
2. Case records of the massachusetts general hospital. weekly clinicopathological exercises. case 13-2000. A 26-year-old woman with bouts of abdominal pain, vomiting, and diarrhea. *N Engl J Med*. 2000 Apr 27;342(17):1272-8.
3. Case records of the massachusetts general hospital. weekly clinicopathological exercises. case 38-1976. *N Engl J Med*. 1976 Sep 16;295(12):666-70.
4. Intussuscepting mucocele of the appendix. *J Mt Sinai Hosp N Y*. 1959 Mar-Apr;26(2):202-4.
5. Ackerman NB, Suresh K. Conservative operative management of intussusception of the appendix. *Arch Surg*. 1981 Dec;116(12):1597.
6. Adelman BP, Teplick JG. Intussusception of appendiceal mucoceles. *Am J Roentgenol Radium Ther Nucl Med*. 1955 Jun;73(6):966-70.
7. Akbayir N, Yildirim S, Sokmen HM, Kilic G, Erdem L, Alkim C. Intussusception of vermiform appendix with microscopic melanosis coli: A case report. *Turk J Gastroenterol*. 2006 Sep;17(3):233-5.
8. Allman DB, Ackerman M, Hoffman HS. Intussusception of the vermiform appendix; report of a case. *J Am Med Assoc*. 1952 Jul 19;149(12):1133-5.

9. Ardies P, Vanwambeke K, Hanssens M, Knockaert D, Penninckx F, Lauwereyns J, et al. Endometriosis of the cecum and appendix: Two case reports. *Gastrointest Radiol.* 1990 Summer;15(3):263-4.
10. Atkinson GO, Gay BB, Jr, Naffis D. Intussusception of the appendix in children. *AJR Am J Roentgenol.* 1976 Jun;126(6):1164-8.
11. Attard TM, Askin FB, Cuffari C. Appendiceal inversion as a lead point for ileocolic intussusception in a child with cystic fibrosis. *J Pediatr Gastroenterol Nutr.* 2000 Sep;31(3):300-2.
12. Bachman AL, Clemett AR. Roentgen aspects of primary appendiceal intussusception. *Radiology.* 1971 Dec;101(3):531-8.
13. Bailey DJ, Courington KR, Andres JM, Bagwell CE, Hitchcock CL. Cecal polyp and appendiceal intussusception in a child with recurrent abdominal pain: Diagnosis by colonoscopy. *J Pediatr Gastroenterol Nutr.* 1987 Sep-Oct;6(5):818-20.
14. Banerjee AK, Macpherson RI. A cecal mass in a five-year-old child. A case for diagnosis. *J Can Assoc Radiol.* 1971 Sep;22(3):187-90.
15. Beard DD. Intussusception of mucocele of the appendix. *Med J Aust.* 1955 Jan 8;1(2):43-4.
16. Bevan PG. Intussusception and acute appendicitis. *Br Med J.* 1957 Apr 20;1(5024):931-2.

17. Blondiaux E, Savoye-Collet C, Foulatier O, Lemoine F, Dacher JN.

Appendiceal intussusception caused by a mucocele of the appendix: Imaging findings.

Dig Liver Dis. 2007 Nov 3.

18. Brewer RJ, Wangenstein SL. Appendiceal intussusception: An unusual cause of painless rectal bleeding. *Am Surg.* 1974 May;40(5):319-20.

19. Bridger GP. Intussusception of a calcified mucocele of the appendix. *Br J Surg.* 1968 Feb;55(2):145-7.

20. Butte JM, Torres J, Henriquez IM, Pinedo G. Appendicular mucosal intussusception into the cecum secondary to an intramural mucinous cystadenoma of the appendix. *J Am Coll Surg.* 2007 Mar;204(3):510.

21. Campbell J, McCormick WF. Intussusception of the vermiform appendix presenting clinically as a cecal carcinoma. *Arch Surg.* 1959 Nov;79:825-6.

22. Casey RG, Ofori-Kuma F, Carroll K, Tait R, Farrell P. Intussusception of the appendix by a villous adenoma. *Eur J Surg.* 2001 Oct;167(10):789-91.

23. Casteels M, Eggermont E, Kerremans R, Ponnette E. Intussusception of the vermiform appendix: A preoperative diagnosis in an adolescent girl. *J Pediatr Gastroenterol Nutr.* 1986 Jan;5(1):159-62.

24. Chen YC, Chiang JM. Appendiceal intussusception with adenocarcinoma mimicking a cecal polyp. *Gastrointest Endosc.* 2000 Jul;52(1):130-1.

25. Chetty R, Daniel WJ. Mucinous cystadenoma of the appendix: An unusual cause of recurrent intussusception in an adult. *Aust NZ J Surg.* 1992 Aug;62(8):670-1.
26. Chijiwa Y, Kabemura T, Toyota T, Tanaka A, Misawa T. Endoscopic appearance of the intussuscepted appendix and accurate preoperative diagnosis. *Am J Gastroenterol.* 1988 Nov;83(11):1301-3.
27. Cois A, Pisanu A, Pilloni L, Uccheddu A. Intussusception of the appendix by mucinous cystadenoma. report of a case with an unusual clinical presentation. *Chir Ital.* 2006 Jan-Feb;58(1):101-4.
28. Conway ME. Intussusception of the appendix. *Ill Med J.* 1949 Jun;95(6):370.
29. Coulier B, Pestieau S, Hamels J, Lefebvre Y. US and CT diagnosis of complete cecocolic intussusception caused by an appendiceal mucocele. *Eur Radiol.* 2002 Feb;12(2):324-8.
30. Darby AJ, Doctor A. Villous papilloma of the appendix associated with mucocoele and intussusception. *Postgrad Med J.* 1974 Oct;50(588):650-4.
31. Day WA. Appendiceal intussusception simulating cecal tumor: Case report. *Dis Colon Rectum.* 1963 Mar-Apr;6:118-20.
32. de Hoyos A, Monroy MA, Gallegos C, Checa G. Intussusception of the appendix resected at colonoscopy. *Endoscopy.* 2006 Jul;38(7):763.

33. Deacon AL. Endometriosis and intussusception of the appendix. *J Obstet Gynaecol Br Emp.* 1949 Aug;56(4):586-90.
34. DeGerome JH, Rodriguez HP. Primary appendiceal intussusception. *Am J Dig Dis.* 1973 Aug;18(8):704-8.
35. Dewan PA. Intussusception of the appendix. *N Z Med J.* 1985 Dec 11;98(792):1058.
36. Dunavant D, Wilson H. Intussusception of the appendix, with complete inversion of the appendix and protrusion from the anus. *Ann Surg.* 1952 Feb;135(2):287-8.
37. Duncan JE, DeNobile JW, Sweeney WB. Colonoscopic diagnosis of appendiceal intussusception: Case report and review of the literature. *J Soc Laparoendosc Surg.* 2005 Oct-Dec;9(4):488-90.
38. Ekberg O, Ekelund G. Cecal tumor-inverted appendix. *Rofo.* 1978 Jul;129(1):137-8.
39. Elson MW. Cecal invagination by a mucocele of the appendix. *Radiology.* 1958 Jul;71(1):90-2.
40. Fazio RA, Wickremesinghe PC, Arsuru EL, Rando J. Endoscopic removal of an intussuscepted appendix mimicking a polyp--an endoscopic hazard. *Am J Gastroenterol.* 1982 Aug;77(8):556-8.

41. Fink VH, Santos AL, Goldberg SL. Intussusception of the appendix. Case reports and reviews of the literature. *Am J Gastroenterol.* 1964 Oct;42:431-41.
42. Flint R, Wright T. Intussusception of a normal appendix: How to avoid a right hemicolectomy. *N Z Med J.* 2003 Apr 17;116(1172):U403.
43. Forshall I. Intussusception of the vermiform appendix with a report of seven cases in children. *Br J Surg.* 1953 Jan;40(162):305-12.
44. Fullerton TE, Drabek GA, Lenz BT, Adams HP, Cavanaugh DJ. Appendiceal intussusception. *S D J Med.* 1985 Mar;38(3):29-31.
45. Garden OJ. Intussusception of the vermiform appendix. *Br J Clin Pract.* 1985 Oct;39(10):402-4.
46. Geerdson J, Axelsson C, Weile. Invagination of the vermiform appendix. A report of two cases associated with endometriosis. *Acta Chir Scand.* 1976;142(5):417-9.
47. Genell S. Intussusception of the appendix caused by an adenovillous papilloma. *Ann Chir Gynaecol.* 1976;65(3):187-90.
48. Gilpin D. Intussusception of the appendix. *Ulster Med J.* 1989 Oct;58(2):193-5.
49. Gorske K. Intussusception of the proximal appendix into the colon. *Radiology.* 1968 Oct;91(4):791.

50. Gupta P, Chwals W, Guandalini S. Intussusception of the appendix: Another poorly recognized cause of rectal bleeding. *J Pediatr Gastroenterol Nutr.* 2000 Mar;30(3):320-3.
51. Hartman E, Boerma EJ, te Velde J. Intracaecal prolapse of the appendix from endometriosis. *Neth J Surg.* 1988 Dec;40(6):166-7.
52. Heithold DL, Tucker JG, Lucas GW. Appendiceal intussusception as a manifestation of mucinous cystadenoma of the appendix: An interesting clinical entity. *Am Surg.* 1997 May;63(5):390-1.
53. Hill BJ, Schmidt KD, Economou SG. The "inside-out" appendix. *Radiology.* 1970 Jun;95(3):613-7.
54. Ho L, Rosenman LD. Complete invagination of the vermiform appendix with villous adenoma, intussuscepting to the splenic flexure of the colon. *Surgery.* 1975 Apr;77(4):505-6.
55. Hoeksema MA, Gusz JR. Appendiceal intussusception. *J Am Coll Surg.* 2001 Apr;192(4):538.
56. Holck S, Wolff M. Intussusception with incarceration of a cystadenoma of the appendix: Case report and review of the complications of appendiceal adenomas. *Dis Colon Rectum.* 1979 Mar;22(2):133-8.

57. Howard RJ, Ellis CM, Delaney JP. Intussusception of the appendix simulating carcinoma of the cecum. *Arch Surg.* 1970 Oct;101(4):520-2.
58. Itoh J, Soeno T, Koizumi R. Intussusception of the appendix with a calcified fecalith. *Jpn J Surg.* 1987 May;17(3):195-8.
59. Janos S, Imre S. Partial appendix invagination stimulating benign tumor of the cecum. *Orv Hetil.* 1973 Jul 1;114(26):1565-6.
60. Jevon GP, Daya D, Qizilbash AH. Intussusception of the appendix. A report of four cases and review of the literature. *Arch Pathol Lab Med.* 1992 Sep;116(9):960-4.
61. Jewett TC, Jr, Aterman K. Mucoviscidosis and intussusception of the appendix. *Surgery.* 1964 Dec;56:1143-6.
62. Jones CD, Eller DJ, Coates TL. Mucinous cystadenoma of the appendix causing intussusception in an adult. *Am J Gastroenterol.* 1997 May;92(5):898-9.
63. Juca W. Intussusception of the vermiform appendix. *Am J Surg.* 1960 Jan;99:106-7.
64. Kantarovsky A, Levy RD, Smit DP, Grayson W. Intussusception of appendix with carcinoid tumour. A case report. *S Afr J Surg.* 1993 Sep;31(3):104-6.

65. Karabulut R, Sonmez K, Turkyilmaz Z, Yilmaz Y, Akyurek N, Basaklar AC, et al. Mucosa-associated lymphoid tissue lymphoma in the appendix, a lead point for intussusception. *J Pediatr Surg.* 2005 May;40(5):872-4.
66. Kawamura YJ, Toyama N, Kasamatsu T, Ota M, Konishi F. Intussusception of appendiceal adenoma mimicking invasive carcinoma. *Endoscopy.* 2002 Sep;34(9):749.
67. Kegelaers B, Storms P, Eyckens A, Sebrechts R. Intussusception of vermiform appendix. A case report and review of the literature. *Acta Chir Belg.* 1996 Nov-Dec;96(6):287-90.
68. Kimura H, Konishi K, Yabushita K, Maeda K, Tsuji M, Miwa A. Intussusception of a mucocele of the appendix secondary to an obstruction by endometriosis: Report of a case. *Surg Today.* 1999;29(7):629-32.
69. Kleinman PK. Intussusception of the appendix: Hydrostatic reduction. *AJR Am J Roentgenol.* 1980 Jun;134(6):1268-70.
70. Kloppedal EA, Toledo-Pereyra LH. Case report. intussusception of the base of the appendix. *Minn Med.* 1972 Dec;55(12):1139-40.
71. Komine N, Yasunaga C, Nakamoto M, Shima I, Iso Y, Takeda Y, et al. Intussusception of the appendix that reduced spontaneously during follow-up in a patient on hemodialysis therapy. *Intern Med.* 2004 Jun;43(6):479-83.

72. Koumanidou C, Vakaki M, Theofanopoulou M, Nikas J, Pitsoulakis G, Kakavakis K. Appendiceal and appendiceal-ileocolic intussusception: Sonographic and radiographic evaluation. *Pediatr Radiol*. 2001 Mar;31(3):180-3.
73. Krasna IH, Beardmore HE. Appendicocecal intussusception: A case report. *Can J Surg*. 1969 Apr;12(2):229-32.
74. Langsam LB, Raj PK, Galang CF. Intussusception of the appendix. *Dis Colon Rectum*. 1984 Jun;27(6):387-92.
75. Larsen SG, Nilssen A, Helseth A, Bohler P, Giercksky KE. Invagination of the appendix with carcinoid tumour. *Eur J Surg*. 1999 Oct;165(10):993-7.
76. Lauwers GY, Prendergast NC, Wahl SJ, Bagchi S. Invagination of vermiform appendix. *Dig Dis Sci*. 1993 Mar;38(3):565-8.
77. Levine MS, Trenkner SW, Herlinger H, Mishkin JD, Reynolds JC. Coiled-spring sign of appendiceal intussusception. *Radiology*. 1985 Apr;155(1):41-4.
78. Luzier J, Verhey P, Dobos N. Preoperative CT diagnosis of appendiceal intussusception. *AJR Am J Roentgenol*. 2006 Sep;187(3):W325-6.
79. Maglinte DD, Fleischer AC, Chua GT, Kelvin FM. Sonography of appendiceal intussusception. *Gastrointest Radiol*. 1987;12(2):163-5.

80. Mann LS, Wolf A, Greenblatt M. Intussusception due to mucocele of the appendix. *Surgery*. 1964 May;55:672-5.
81. Mann WJ, Fromowitz F, Saychek T, Madariaga JR, Chalas E. Endometriosis associated with appendiceal intussusception. A report of two cases. *J Reprod Med*. 1984 Aug;29(8):625-9.
82. Martin LF, Tidman MK, Jamieson MA. Appendiceal intussusception and endometriosis. *J Can Assoc Radiol*. 1980 Dec;31(4):276-7.
83. Mathew J, Aldean IM, Ghafar FA, Haboubi NY. Appendicular intussusception into a polyp. *Tech Coloproctol*. 2004 Aug;8(2):113-5.
84. Mazaki T, Tomioka K, Takayama T. Image of the month. complete invagination of the appendix progressing to ileocecolic intussusception. *Gastroenterology*. 2002 Dec;123(6):1762, 2165.
85. McCormick WF. Intussusception of the vermiform appendix with a mucocele; review of literature with report of a case. *AMA Arch Pathol*. 1957 Dec;64(6):686-90.
86. McIntosh JC, Mroczek EC, Baldwin C, Mestre J. Intussusception of the appendix in a patient with cystic fibrosis. *J Pediatr Gastroenterol Nutr*. 1990 Nov;11(4):542-4.
87. Meyers MA, Abrams J. Intussusception of the appendix. *Br J Radiol*. 1970 Jul;43(511):485-7.

88. Miyahara M, Saito T, Etoh K, Shimoda K, Kitano S, Kobayashi M, et al.

Appendiceal intussusception due to an appendiceal malignant polyp--an association in a patient with peutz-jeghers syndrome: Report of a case. *Surg Today*. 1995;25(9):834-7.

89. Moradi P, Barakate M, Gill A, Farrow G. Intussusception of the veriform appendix due to endometriosis presenting as acute appendicitis. *ANZ J Surg*. 2007 Sep;77(9):758-60.

90. Morton PC, Oakmann CS. Primary intussusception of appendix with endometrial implants. *Am J Surg*. 1952 Dec;84(6):734-6.

91. Nycum LR, Moss H, Adams JQ, Macri CI. Asymptomatic intussusception of the appendix due to endometriosis. *South Med J*. 1999 May;92(5):524-5.

92. O'Beirn S. Intussusception of the appendix. *Ir J Med Sci*. 1949 Dec;8(288):875.

93. Offodile A,2nd, Hodgin JB, Arnell T. Asymptomatic intussusception of the appendix secondary to endometriosis. *Am Surg*. 2007 Mar;73(3):299-301.

94. Ohno M, Nakamura T, Hori H, Tabuchi Y, Kuroda Y. Appendiceal intussusception induced by tubulovillous adenoma with carcinoma in situ: Report of a case. *Surg Today*. 2000;30(5):441-4.

95. Ozuner G, Davidson P, Church J. Intussusception of the vermiform appendix: Preoperative colonoscopic diagnosis of two cases and review of the literature. *Int J Colorectal Dis.* 2000 Jun;15(3):185-7.
96. Panganiban W, Cornog JL. Endometriosis of the intestines and vermiform appendix. *Dis Colon Rectum.* 1972 Jul-Aug;15(4):253-60.
97. Panzer S, Pitt HA, Wallach EE, Thuluvath PJ. Intussusception of the appendix due to endometriosis. *Am J Gastroenterol.* 1995 Oct;90(10):1892-3.
98. Pardoll PM, Wilcoxon JK, Trudeau WL. Primary asymptomatic appendiceal intussusception: A colonoscopic view. *Gastrointest Endosc.* 1976 Aug;23(1):44.
99. Patton KR, Ferrera PC. Intussusception of a normal appendix. *Am J Emerg Med.* 2000 Jan;18(1):115-7.
100. Paul GJ, Ferraro LR. Intussusception of appendix. *N Y State J Med.* 1967 Oct 1;67(19):2625-9.
101. Pearlman DM, Srinivasan K. Malignant carcinoid of appendix. metastasis from small primary tumor which appeared as appendiceal intussusception. *N Y State J Med.* 1971 Jun 15;71(12):1529-31.
102. Pumberger W, Hormann M, Pomberger G, Hallwirth U. Sonographic diagnosis of intussusception of the appendix vermiformis. *J Clin Ultrasound.* 2000 Nov-Dec;28(9):492-6.

103. Ram AD, Peckham C, Akobeng AK, Thomas AG, David TJ, Patel L. Inverted appendix mistaken for a polyp during colonoscopy and leading to intussusception. *J Cyst Fibros*. 2005 Sep;4(3):203-4.

104. Reddy KM, Lamparelli MJ, Mudan SS, Leicester RJ, Knight MJ. A clear diagnosis of intussusception of the appendix. *Endoscopy*. 1998 Sep;30(7):S86.

105. Relan M, Das MM, Ray S. Intussusception of the appendix. *Postgrad Med J*. 1990 Feb;66(772):157.

106. Rodriguez MA, Wasdahl WA. Mucinous carcinoid and endometriosis in an inside-out appendix. *Am J Gastroenterol*. 1978 Feb;69(2):199-202.

107. Rudek B, von Herbay A, Schmidt J. Intussusception of the appendix secondary to mucinous cystadenoma. *Dig Surg*. 2001;18(5):422-6.

108. Ryu BY, Kim TH, Jeon JY, Kim HK, Choi YH, Baik GH. Colonoscopic diagnosis of appendiceal intussusception: A case report. *J Korean Med Sci*. 2005 Aug;20(4):680-2.

109. Sadahiro S, Ohmura T, Yamada Y, Saito T, Akatsuka S. A case of cecocolic intussusception with complete invagination and intussusception of the appendix with villous adenoma. *Dis Colon Rectum*. 1991 Jan;34(1):85-8.

110. Sakaguchi N, Ito M, Sano K, Baba T, Koyama M, Hotchi M. Intussusception of the appendix: A report of three cases with different clinical and pathologic features. *Pathol Int.* 1995 Oct;45(10):757-61.
111. Sale TA. Intussusception of the appendix. *Med J Malaya.* 1956 Jun;10(4):305-10.
112. Schmidt FR, McCarthy JD. Intussusception of the appendix with endometriosis presenting as a cecal tumor. *Arch Surg.* 1971 Oct;103(4):515-7.
113. Schmidt JS, Maier D, Raj P, Remine SG. Laparoscopic management of appendiceal intussusception associated with villous adenocarcinoma. *J Laparoendosc Surg.* 1994 Oct;4(5):369-73.
114. Schneider LA. Intussusception of the appendix. *J Abdom Surg.* 1962 Jul;4:103-6.
115. Seaman WB. The case of the appendiceal intussusception. *Hosp Pract.* 1978 Feb;13(2):150-1.
116. Shahade MG, Mehta RT. Recurrent appendicular intussusception. *J Indian Med Assoc.* 1965 Apr 16;44:440.
117. Skaane P, Eide TJ. Malignant appendiceal carcinoid with intussusception of the base manifesting as a cecal tumor: Report of a case. *Dis Colon Rectum.* 1977 Sep;20(6):511-4.

118. Sonnino RE, Ansari MR. Intussusception of the appendix and endometriosis. *Henry Ford Hosp Med J.* 1986;34(1):61-4.
119. Sriram PV, Seitz U, Soehendra N, Schroeder S. Endoscopic appendectomy in a case of appendicular intussusception due to endometriosis, mimicking a cecal polyp. *Am J Gastroenterol.* 2000 Jun;95(6):1594-6.
120. Swanger R, Davis S, McBride W, Rachlin S, Sonke PY, Brudnicki A. Multimodality imaging of an appendiceal intussusception. *Pediatr Radiol.* 2007 Sep;37(9):929-32.
121. Taban S, Dema A, Lazar D, Sporea I, Lazar E, Cornianu M. An unusual "tumor" of the cecum: The inverted appendiceal stump. *Rom J Morphol Embryol.* 2006;47(2):193-6.
122. Takahashi M, Sawada T, Fukuda T, Furugori T, Kuwano H. Complete appendiceal intussusception induced by primary appendiceal adenocarcinoma in tubular adenoma: A case report. *Jpn J Clin Oncol.* 2003 Aug;33(8):413-5.
123. Tao H, Dunbar JS. Intussusception of the appendix. *J Can Assoc Radiol.* 1971 Mar;22(1):33-5.
124. Tavakkoli H, Sadrkabar SM, Mahzouni P. Colonoscopic diagnosis of appendiceal intussusception in a patient with intermittent abdominal pain: A case report. *World J Gastroenterol.* 2007 Aug 21;13(31):4274-7.

125. Thomas RE, Maude K, Rotimi O. A case of an intussuscepted neuroendocrine carcinoma of the appendix. *World J Gastroenterol*. 2006 Feb 14;12(6):971-3.
126. Tonsekar KS, Cacdac R, Ashare R, Libcke JH. Villous adenoma of the vermiform appendix with cecal intussusception: A case report and review of literature. *Am Surg*. 1994 Dec;60(12):982-4.
127. Tseng PH, Lee YC, Chiu HM, Wu MS, Lin JT, Wang HP. Appendiceal intussusception diagnosed with endoscopic sonography. *J Clin Ultrasound*. 2006 Sep;34(7):348-51.
128. Tsunoda T, Eto T, Maeda H, Mochinaga N, Terada M, Matsuo S, et al. Intussusception of an appendiceal mucocele: Report of a case. *Surg Today*. 1992;22(5):470-3.
129. Varty K, Rance CH. Intussusception complicated by gangrene, demarcation and separation of the appendix. *Aust N Z J Surg*. 1993 Nov;63(11):913-4.
130. Velik MM. Intussusception of the appendix. *Med J Aust*. 1978 Jul 1;2(1):26.
131. Vogelaar FJ, Molenaar IQ, Adhin S, Steenvoorde P. Invagination of the appendix: Diagnostic laparoscopy? *Dig Dis Sci*. 2004 Feb;49(2):351-2.
132. Waseem T, Javaid-ur-Rehman, Sabir NU, Hussain S, Amir E, Arif S. Rare association: Ileocaeco-colic intussusception secondary to mucinous cystadenoma of the appendix in an adult. *ANZ J Surg*. 2007 Nov;77(11):1021-2.

133. Watkins GL. Ileocolic intussusceptions caused by mucoceles of the appendix. *Mo Med.* 1963 Oct;60:934-6.
134. Weiner JJ, Sala AM. Intussusception of the appendix. simulating a carcinoma of the caecum. *Am J Proctol.* 1962 Feb;13:40-5.
135. Weiner JJ, Sala AM. Intussusception of the appendix due to carcinoma. *Am J Surg.* 1957 Nov;94(5):820-4.
136. Welch JW, Hellwig CA, Koenke IA. Intussusception of the appendix with a mucocele. *J Abdom Surg.* 1962 Jan;4:27-30.
137. Wirtschafter SK, Kaufman H. Endoscopic appendectomy. *Gastrointest Endosc.* 1976 Feb;22(3):173-4.
138. Yates LN. Intussusception of the appendix. *Int Surg.* 1983 Jul-Sep;68(3):231-3.
139. Yoshikawa A, Kuramoto S, Mimura T, Kobayashi K, Shimoyama S, Yasuda H, et al. Peutz-jeghers syndrome manifesting complete intussusception of the appendix and associated with a focal cancer of the duodenum and a cystadenocarcinoma of the pancreas: Report of a case. *Dis Colon Rectum.* 1998 Apr;41(4):517-21.
140. Zeifer HD. Intussusception of the appendix; report of a case and review of the literature. *J Mt Sinai Hosp N Y.* 1951 Jul-Aug;18(2):125-30.