

5-15-2018

## Interleukin-1 Beta (IL-1 $\beta$ ) Gene Polymorphisms in Pre-Treatment Orthodontic Patients Exhibiting Short Root Anomaly (SRA)

Satyaprasad Nayak  
nayaks1@unlv.nevada.edu

Follow this and additional works at: <https://digitalscholarship.unlv.edu/thesesdissertations>



Part of the [Dentistry Commons](#)

---

### Repository Citation

Nayak, Satyaprasad, "Interleukin-1 Beta (IL-1 $\beta$ ) Gene Polymorphisms in Pre-Treatment Orthodontic Patients Exhibiting Short Root Anomaly (SRA)" (2018). *UNLV Theses, Dissertations, Professional Papers, and Capstones*. 3297.

<https://digitalscholarship.unlv.edu/thesesdissertations/3297>

This Thesis is protected by copyright and/or related rights. It has been brought to you by Digital Scholarship@UNLV with permission from the rights-holder(s). You are free to use this Thesis in any way that is permitted by the copyright and related rights legislation that applies to your use. For other uses you need to obtain permission from the rights-holder(s) directly, unless additional rights are indicated by a Creative Commons license in the record and/or on the work itself.

This Thesis has been accepted for inclusion in UNLV Theses, Dissertations, Professional Papers, and Capstones by an authorized administrator of Digital Scholarship@UNLV. For more information, please contact [digitalscholarship@unlv.edu](mailto:digitalscholarship@unlv.edu).

INTERLEUKIN-1 BETA (IL-1 $\beta$ ) GENE POLYMORPHISMS IN PRE-TREATMENT  
ORTHODONTIC PATIENTS EXHIBITING SHORT ROOT ANOMALY (SRA)

By

Satyaprasad C Nayak

Bachelor of Dental Surgery  
SDM College of Dental Sciences  
2005

Master of Science - Biomaterials  
SUNY at Buffalo  
2009

Doctor of Dental Medicine  
University of Pennsylvania  
2012

A thesis submitted in partial fulfillment  
of the requirements for the

Master of Science – Oral Biology

School of Dental Medicine  
Division of Health Sciences  
The Graduate College

University of Nevada, Las Vegas

May 2018

Copyright 2018 Satyaprasad C Nayak

All Rights Reserved



## Thesis Approval

The Graduate College  
The University of Nevada, Las Vegas

May 10, 2018

This thesis prepared by

Satyaprasad C Nayak

entitled

Interleukin-1 Beta (IL-1 $\beta$ ) Gene Polymorphisms in Pre-Treatment Orthodontic Patients Exhibiting Short Root Anomaly (Sra)

is approved in partial fulfillment of the requirements for the degree of

Master of Science – Oral Biology  
School of Dental Medicine

Dr. Brian Chrzan, Ph.D.  
*Examination Committee Chair*

Kathryn Hausbeck Korgan, Ph.D.  
*Graduate College Interim Dean*

Dr. Karl Kingsley, Ph.D.  
*Examination Committee Member*

Dr. Tanya Al-Talib, Ph.D.  
*Examination Committee Member*

Dr. Jennifer Pharr, Ph.D.  
*Graduate College Faculty Representative*

## Abstract

Root resorption is a frequent unwanted occurrence during orthodontic treatment. Biological factors include the quantity of specific inflammatory mediators, growth factors, and hormones as well as an individual's specific alleles for the genes encoding these mediators. Studies have shown an association between external apical root resorption (EARR) and the single nucleotide polymorphism (SNP) at +3954 of the IL-1 $\beta$  gene. Studies have also shown associations between chronic periodontitis and IL-1 $\beta$  gene polymorphisms in the region of +3954, -511 and -31. All previous studies to date, have evaluated genetic factors and root resorption in orthodontic patients in-treatment or post-orthodontic treatment. This study is novel in utilizing genomic DNA samples from buccal swabs of pre-treatment orthodontic patients to evaluate polymorphisms in the IL-1 $\beta$  gene at +3954, -511 and -31. Pre-treatment records were used specifically to determine if short roots (Short Root Anomaly) and selected IL-1 $\beta$  gene polymorphisms could be used to accurately assess a patient's risk of root resorption prior to orthodontic treatment. Subjects were categorized as exhibiting normal root length or with short roots based upon the root morphology evident on 3D CBCT pre-treatment scans. The sample size consisted of 52 subjects; 26 subjects exhibiting short root anomaly and 26 subjects exhibiting root length within normal limits. Samples for DNA analysis were collected by scraping the inside of the cheek with 10 strokes of a sterile nylon bristle brush. Genomic DNA was obtained from these samples using the Puregene method (Gentra Systems, Minneapolis, Minn). PCR amplification of regions encompassing the +3954, -31 and -511 sites was followed by restriction endonuclease digestion using enzymes recognizing the polymorphic sites. Agarose gel electrophoresis was used to separate and identify bands specific to each allele and

determine patient homozygosity and heterozygosity for each polymorphic site. In our study, Hispanic and female patients showed a higher prevalence of SRA. There was no association identified between the IL-1 $\beta$  polymorphisms at -511 or -31 with SRA or normal roots. All of the patients in the SRA group exhibited the CC genotype for the IL-1 $\beta$  polymorphism at +3954. The presence of the CC genotype was statistically significant in the patients of Hispanic origin. There was no statistically significant difference between the presence of any specific genotype among Caucasian patients. The IL-1 $\beta$  +3954 CC genotype has been reported to increase the risk of root resorption by decreasing the IL-1 $\beta$  expression and consequently, decreasing alveolar bone resorption. In contrast, the CT genotype has been reported to increase IL-1 $\beta$  expression, possibly leading to decreased risk of root resorption by increasing bone remodeling. These findings from this study suggest that there may be a genetic basis for Hispanic patients to be at a higher risk of root resorption compared to Caucasian patients. This study supports the idea that root resorption is multifactorial and multiple diagnostic measures (CBCT, DNA analysis) should be incorporated in the orthodontic records process to evaluate risk factors prior to starting any orthodontic treatment. Further studies can be designed to identify the patients who exhibit the IL-1 $\beta$  +3954 CC genotype and follow these patients with regular radiographs and CBCT scans to evaluate root resorption during the course of orthodontic treatment.

## **Acknowledgements**

The successful completion of this research project reflects the sum total of many individuals' efforts. I wish to thank many people without whose help this project would not have been possible.

In the first place, I would like to express my heartfelt thanks and gratitude to Dr. Brian Chrzan for his supervision, advice, and guidance from the very early stage of this research. Above all and the most needed, he provided me unflinching encouragement and support in various ways. I thank him for passing on his invaluable wealth of knowledge, experience, and expertise and also for his patience, which inspired and enriched my growth as a student and as a researcher.

I would also like to thank Dr. Karl Kingsley for his invaluable advice throughout the completion of this degree and research project.

I gratefully thank Dr. Tanya Al-Talib and Dr. Jennifer Pharr for their constructive input on this thesis. I am thankful that in the midst of all their activity, they were willing to be members of my committee.

I would also like to thank our clinical orthodontic faculty; Dr. James Mah, Dr. Bob Martin, Dr. Clifford Seran, Dr. Walter Babula, Dr. Kim Mai, Dr. Calvin Heinrich, Dr. Charles Hill and Dr. Randy Kunik for enriching my residency experience with your wisdom and making these past three years memorable.

I am also grateful to our staff; May, Julia, Andrew, Miguel, Noemi and Flora for their continued support.

Many thanks go in particular to Dr. Vince Kang, Dr. Anh Nguyen, Dr. Amy Tam, Dr. Suzanne Wen and Dr. Adam Whiteley for their advice, help, constant support and very much appreciated time.

My immense thanks to all of the residents at the UNLV Orthodontic program and my friends here in Las Vegas for their continued support and encouragement.

I would like to thank Will Collins, Jaclyn Richardson, Audrey Riegel, Paige Elsea and Caitlin Kemper for their help with this project.

I must express my very profound gratitude to my wife Nicole Fernandez for providing me with unfailing support and continuous encouragement throughout my years of study and through the process of writing this thesis. Nicole has been my best friend and a great companion, loved, supported, encouraged, entertained, and helped me get through this agonizing period in the most positive way. This accomplishment would not have been possible without her.

Words fail to express my appreciation to my parents, Chandrashekar Nayak and Vinoda Nayak, whose dedication, love and persistent confidence in me has enabled me to progress through life. They have been a constant source of encouragement and support over my entire life. Also to the rest of my family in India for their never-ending love and support.

I would like to express my gratitude to my parents-in-law Tony Fernandez and Darilyn Fernandez for their unfailing emotional support.

A very special gratitude goes out to the UNLV Orthodontic department and the Graduate & Professional Students Association grant for helping and providing funding for this work.

I would like to thank god for gracing me with his blessing.

Finally, I would like to thank everybody who was important to the successful realization of this thesis, as well as expressing my apology that I could not mention personally one by one.



## Table of Contents

ABSTRACT	III
ACKNOWLEDGEMENTS	V
TABLE OF CONTENTS	VII
LIST OF TABLES	IX
LIST OF FIGURES	X
CHAPTER 1, INTRODUCTION	1
1.1: PURPOSE OF THE WORK	3
CHAPTER 2, BACKGROUND AND LITERATURE REVIEW	6
2.1: ORTHODONTICALLY INDUCED INFLAMMATORY ROOT RESORPTION (OIIRR)/ EXTERNAL APICAL ROOT RESORPTION (EARR)	7
2.2 ROOT RESORPTION AND IMMUNE SYSTEM DISORDERS	9
2.3 SHORT ROOT ANOMALY	10
2.4 IL-1B:	12
2.5 IL-1B POLYMORPHISM +3954, -31, -511 AND PERIODONTITIS	13
2.6 IL-1B POLYMORPHISM +3954 AND ROOT RESORPTION	15
CHAPTER 3, MATERIALS AND METHODS:	18
3.1 STUDY DESIGN	18
3.2 SELECTION OF STUDY SUBJECTS	18
3.3 CLINICAL PROCEDURES	19
3.4 DNA PURIFICATION	20
3.5 PCR AMPLIFICATION AND DIGEST	21
3.6 AGAROSE GEL ELECTROPHORESIS	24
3.7 DNA SEQUENCING	24
3.8 STATISTICAL ANALYSIS:	25
CHAPTER 5, RESULTS:	26
5.1 ETHNIC AND SEXUAL DIVERSITY AMONG SRA AND CONTROL	26
5.2 IL-1B +3954 POLYMORPHISM	28
5.3 IL-1B -511 POLYMORPHISM	36
5.4 IL-1B -31 POLYMORPHISM	45
CHAPTER 6, DISCUSSION:	55
CHAPTER 7. CONCLUSIONS:	62
CHAPTER 8. FUTURE STUDIES	64
REFERENCES:	65



## List of Tables

Table 1. Primer Sequence .....	23
Table 2. Ethnic Diversity, n = 52.....	26
Table 3. Sexual Diversity, n = 52 .....	27
Table 4. IL-1 $\beta$ +3954 Genotype distribution in the total sample, n = 52 .....	31
Table 5. IL-1 $\beta$ +3954 Genotype distribution in the total male sample, n = 28.....	32
Table 6. IL-1 $\beta$ +3954 Genotype distribution in the total female sample, n = 24.....	33
Table 7. IL-1 $\beta$ +3954 Genotype distribution in the total Hispanic sample, n = 32 .....	34
Table 8. IL-1 $\beta$ +3954 Genotype distribution in the total Caucasian sample, n = 13 .....	35
Table 9. IL-1 $\beta$ +3954 Genotype distribution in the total Asian sample, n = 4 .....	36
Table 10. IL-1 $\beta$ +3954 Genotype distribution in the total African-American sample, n = 3 .....	36
Table 11. IL-1 $\beta$ -511 Genotype distribution in the total sample, n = 52 .....	39
Table 12. IL-1 $\beta$ -511 Genotype distribution in the total male sample, n = 28.....	40
Table 13. IL-1 $\beta$ +511 Genotype distribution in the total female sample, n = 24.....	41
Table 14. IL-1 $\beta$ -511 Genotype distribution in the total Hispanic sample, n = 32 .....	43
Table 15. IL-1 $\beta$ -511 Genotype distribution in the total Caucasian sample, n = 13 .....	44
Table 16. IL-1 $\beta$ -511 Genotype distribution in the total Asian sample, n = 4 .....	45
Table 17. IL-1 $\beta$ -511 Genotype distribution in the total African-American sample, n = 3 .....	45
Table 18. IL-1 $\beta$ -31 Genotype distribution in the total sample, n = 52.....	48
Table 19. IL-1 $\beta$ -31 Genotype distribution in the total male sample, n = 28.....	50
Table 20. IL-1 $\beta$ -31 Genotype distribution in the total female sample, n = 24.....	51
Table 21. IL-1 $\beta$ -31 Genotype distribution in the total Hispanic sample, n = 32 .....	52
Table 22. IL-1 $\beta$ -31 Genotype distribution in the total Caucasian sample, n = 13 .....	53
Table 23. IL-1 $\beta$ -31 Genotype distribution in the total Asian sample, n = 4 .....	54
Table 24. IL-1 $\beta$ -31 Genotype distribution in the total African-American sample, n = 3 .....	54

## List of Figures

Figure 1. 3D Volumetric analysis of patient #398 exhibiting short roots on central incisors and bicuspid	19
Figure 2- IL-1B single nucleotide polymorphisms and restriction endonuclease recognition sites	23
Figure. 3 Ethnic Diversity, SRA vs Control	27
Figure 4. Sexual Diversity, SRA vs Control	28
Figure 5. Band pattern for +3954, patients #237 and #634	29
Figure. 6 DNA sequence confirming CC genotype patient #237 (blue peak)	29
Figure. 7 DNA sequence confirming CT genotype patient #634 (blue and red peak)	30
Figure 8. +3954 Genotype comparison, SRA vs Control	31
Figure 9. +3954 Genotype distribution of male patients, SRA vs Control	32
Figure 10. +3954 Genotype distribution of all female patients, SRA vs Control	33
Figure 11. +3954 Genotype distribution of all Hispanic patients, SRA vs Control	34
Figure 12. +3954 distribution of all Caucasian patients, SRA vs Control	35
Figure 13. Band pattern for -511, patients #237, 634 and 686	37
Figure. 14 DNA sequence confirming TT genotype, patient #237 (red peak)	37
Figure. 15 DNA sequence confirming CC genotype, patient #634(blue peak)	38
Figure. 16 DNA sequence confirming CT genotype, patient #686 (red and blue peak)	38
Figure 17. Genotype Comparison, SRA vs Control	39
Figure 18. -511 Genotype distribution of all male patients, SRA vs Control	41
Figure 19. -511 Genotype distribution of all female patients, SRA vs Control	42
Figure 20. -511 Genotype distribution of all Hispanic patients, SRA vs Control	43
Figure 21. -511 Genotype distribution of all Caucasian patients, SRA vs Control	44
Figure 22. Band pattern for -31, patient #237, 634 and 686	46
Figure. 23 DNA sequence confirming CC genotype, patient #237(blue peak)	46
Figure. 24 DNA sequence confirming TT genotype, patient # 634(red peak)	47
Figure. 25 DNA sequence confirming CT genotype, patient #686 (red and blue peak)	47
Figure 26. -31 Genotype comparison, SRA vs Control	49
Figure. 27 -31 Genotype distribution of all male patients, SRA vs Control	50
Figure 28. -31 Genotype distribution of all female patients, SRA vs Control	51
Figure 29. -31 Genotype distribution of all Hispanic patients, SRA vs Control	52
Figure. 30 -31 Genotype distribution of all Caucasian patients, SRA vs Control	53

## Chapter 1, Introduction

Root resorption is a frequent undesired side effect during orthodontic treatment. Root resorption is characterized by a partial loss of root cementum and dentin, leading to shortening of the roots. The reduction in root length leads to an increased risk of mobility and may result in loss of the affected tooth. Mechanical or orthodontic treatment-related factors contributing to root resorption may include excessive tooth movement, excessive root torque, intrusive forces, excessive force magnitude, and extended treatment duration (Abuabara, 2007). Biological factors are far less characterized. Biological factors include the quantity of specific inflammatory mediators, growth factors and hormones, as well as an individual's specific alleles for the genes encoding these mediators. It is likely that there is a genetic basis for these individual variations.

External apical root resorption (EARR) may also occur in the absence of orthodontic treatment. To date, causes of EARR are poorly understood, and it is not possible to predict who will develop EARR or the extent of involvement (Harris, 1997). A genetic component of EARR was first hypothesized in 1997 following observations of possible inheritance in patients treated orthodontically (Harris, 1997). The first description of a potential genetic marker was established by examining linkage and association between several candidate gene polymorphisms and EARR in Caucasian American families (R. A. Al-Qawasmi, 2003). The association between EARR during orthodontic treatment and polymorphisms of the IL-1 $\beta$  (+3954) gene identified by these authors suggests a role for this cytokine in the pathogenesis of EARR (Bastos Lages, 2009). IL-1 $\beta$  has been frequently correlated with inflammatory events in bones and other connective tissues. Moreover, IL-1 $\beta$  has been characterized as a potent bone-resorptive cytokine and several studies have implicated IL-1 $\beta$  as a key component of the complex pathways leading to root resorption (Bastos Lages, 2009). Since IL-1 $\beta$  is a potent stimulator of bone resorption,

Al-Qawasmi has proposed that a low expression of this cytokine may result in less resorption of the cortical bone at the periodontal ligament (PDL) interface. This decrease in bone resorption would result in prolonged stresses concentrated on the root apices, resulting in hyalinization of the PDL and root resorption (R. A. Al-Qawasmi, 2003).

Previous studies have relied upon panoramic radiographs and lateral cephalograms to measure EARR. A more recent study utilized periapical radiographs to improve the accuracy in measuring and diagnosing EARR (Bastos Lages, 2009). However, the use of periapical radiographs has also been questioned for EARR measurements (Katona, 2006). It would be expected that the measurement and characterization of root resorption would be more accurate with the use of contemporary 3-dimensional imaging, such as Cone Beam Computed Tomography (CBCT).

All previous studies to date, have evaluated the genetic factors and root resorption in patients in-treatment or post-orthodontic treatment. These studies do not consider the type of treatment, the mechanics used, or the duration of treatment. Studies on individual genetic variation must effectively eliminate the variable aspects of orthodontic treatment if any data is to be evaluated for a genetic basis of root resorption. This would also suggest that the initial assessment of root resorption should occur prior to starting treatment. In clinical practice, orthodontists must make an initial assessment of the probability of root resorption prior to starting treatment. Pre-treatment radiographic evidence (the presence of short roots) is generally the only indication of a predisposition to resorption during orthodontic treatment. Volmer Lind in 1972 first identified a condition, which he called "Short Root Anomaly"(LIND, 1972). He defined SRA as 'abnormally short, plump roots always affecting the maxillary central incisors and rarely any other teeth'. There is evidence that this unusual root morphology before

orthodontic treatment can increase the risk of root resorption during treatment. A recent study has shown that SRA has a predilection for anterior teeth and occurs more frequently in individuals of Hispanic origin (Puranik, 2015).

At this time, there is no accurate method to determine a patient's risk of root resorption prior to starting orthodontic treatment. Ideally, a simple, non-invasive test could be performed to screen the genetic pre-disposition of a particular patient. This information at the start of treatment would allow the clinician to modify or shorten a treatment plan, or even elect not to treat. Advances in molecular biology, DNA sequencing and large-scale automation have simplified and reduced the once prohibitive cost of various genetic tests. However, the genetic basis for any pre-disposition to disease must be completely understood before considering the application of genetic testing. Unfortunately, current research has not successfully correlated any gene polymorphisms with a clear predisposition for EARR. One possible reason is the use of post-treatment records which may tend to over-estimate the number of patients with a genetic pre-disposition by including those that have root resorption solely due to mechanical, treatment related factors. The previously reported association between root resorption during orthodontic treatment and the IL-1 $\beta$  (+3954) polymorphism is a logical site for further study. However, homozygosity and heterozygosity for each allele at the multiple candidate IL-1 $\beta$  polymorphisms must be compared with radiographic evidence of pre-treatment short roots in order to describe any relationship between IL-1 $\beta$  and the presence of short roots (SRA) and the predisposition to treatment-related root resorption (EARR).

### **1.1: Purpose of the work**

Considering the following well-established observations: 1) short roots predispose an individual to further resorption, 2) abnormally short roots (SRA) occur more frequently in

Hispanic populations, 3) alleles of the polymorphic IL-1 $\beta$  gene at +3954 have been associated with differences in IL-1 $\beta$  expression and 4) alleles of the IL-1 $\beta$  gene at +3954, -511 and -31 have been associated with chronic periodontitis. At the UNLV SDM Orthodontic clinic, a significant percentage of the patient population is of Hispanic origin. A frequent observation among these patients is short incisor and mandibular premolar roots without any previous history of orthodontic treatment. This unique population is ideal for studying the genetic markers that may predispose patients with SRA to increased risk of root resorption during orthodontic treatment.

## **Research Questions and Hypotheses**

### **General Hypothesis**

Since IL-1 $\beta$  is a potent stimulator of bone resorption and aids in the recruitment of osteoclasts during orthodontic tooth movement, low IL-1 $\beta$  expression may result in less resorption of the bone at the interface with the PDL. This impaired alveolar bone resorption may result in prolonged stresses on the tooth root and subsequent loss of cementum and dentin. Any polymorphism that results in decreased IL-1 $\beta$  expression may also result in the appearance of short roots and EARR.

### **1. Do patients that exhibit short roots at the start of treatment carry the IL-1 $\beta$ (+3954) C allele?**

**H<sub>0</sub>** – Patients with normal roots carry the IL-1 $\beta$  (+3954) C allele.

**H<sub>A</sub>** – Patients that exhibit short roots carry the IL-1 $\beta$  (+3954) C allele.



**2. Do patients that exhibit short roots at the start of treatment carry the IL-1 $\beta$  (-31) T allele?**

**H<sub>0</sub>** – Patients with normal roots carry the IL-1 $\beta$  (-31) T allele.

**H<sub>A</sub>** – Patients that exhibit short roots carry the IL-1 $\beta$  (-31) T allele.

**3. Do patients that exhibit short roots at the start of treatment carry the IL-1 $\beta$  (-511) C allele?**

**H<sub>0</sub>** – Patients with normal roots carry the IL-1 $\beta$  (-511) C allele.

**H<sub>A</sub>** – Patients that exhibit short roots carry the IL-1 $\beta$  (-511) C allele.

## Chapter 2, Background and Literature Review

Root resorption is a condition that can result in the loss of dentin, cementum and/or bone. This process can be either physiologic or pathologic and it can be categorized based on: location, etiology (e.g. infection, trauma), site (e.g. apical, cervical) or a combination of the above. Common stimulants that can lead to root resorption include bleaching agents (internal bleaching), pulpal necrosis due to trauma or infection and orthodontic treatment. These stimulants can initiate root resorption by either acting alone or simultaneously (Bellamy & Malkhassain).

Root resorption can be classified as cervical root resorption, replacement resorption, internal resorption and external root resorption. Cervical root resorption is a type of external resorption affecting the cervical third of the root. Replacement resorption is a pathologic condition in which cementum, dentin and the periodontal ligament are replaced by bone. This condition can lead to ankylosis resulting from fusion of tooth and bone. Internal resorption is an inflammatory condition that can result in loss of dentin, and in severe cases can also affect cementum of the root. Internal resorption affects the internal aspect of the root following necrosis of pulp as a result of bacterial infection and /or chronic inflammation and is commonly found in the cervical region of the tooth. External root resorption involves the outer surface of the roots, and the most common type of external root resorption is external inflammatory root resorption. This may be caused by trauma, orthodontic tooth movement and pulpal or periodontal infections. (*American Association of Endodontics, "Glossary of endodontic terms,"* 2014; Kuo T-C, Cheng Y-A, 2005).

## **2.1 : Orthodontically Induced Inflammatory Root Resorption (OIIRR)/ External Apical Root Resorption (EARR)**

Orthodontically Induced Inflammatory Root Resorption (OIIRR) is often an unavoidable consequence of orthodontic tooth movement. Orthodontic tooth movement occurs by resorption of bone on the pressure side and deposition on the tension side. The response of the tooth under orthodontic force is related to the magnitude of the force applied. When light forces are applied to the tooth, remodeling of the bony socket occurs by a relatively painless process called “frontal resorption.” Application of heavy forces leads to rapidly developing pain, occlusion of the blood supply to the periodontal ligament and ligament hyalinization. Undermining resorption is the type of bone resorption occurring as a result of this sterile necrosis of the periodontal ligament on the pressure side. During orthodontic treatment, the objective is to produce tooth movement by frontal resorption recognizing that some areas of PDL hyalinization and undermining resorption will probably occur despite efforts to prevent this (Proffit, 2013).

There are three degrees of severity of OIIRR – cemental resorption with repair, dentinal resorption with repair and circumferential apical root resorption. Cemental or surface resorption with remodeling is a process in which the outer cemental layer is resorbed and later it is fully regenerated or remodeled. Dentinal resorption with repair is a process in which both cementum and the outer layers of dentin are resorbed and usually repaired with cementum alone. The final shape of the root after repair may not be identical to the original root form. In circumferential apical root resorption, shortening of the root occurs by full resorption of the cementum and dentin of the root apex. Regeneration is impaired due to the loss of apical material beneath the cementum (Brezniak & Wasserstein, 2009).

During tooth movement, osteoclasts attack cementum and bone, creating defects in the root surface. The defects are filled back in with cementum during the repair phase. Shortening of the root occurs when resorptive cavities fuse at the apex, so that peninsulas of root structure are cut off as islands. These islands resorb, and although the repair process places new cementum over the residual root surface, a net loss of root length occurs. This is why, although both the sides and the apex of the root experience resorption, roots become shorter but not thinner as a result of orthodontic tooth movement (Proffit, 2013).

OIRR can be further classified as moderate generalized resorption, severe generalized resorption and severe localized root resorption.

#### Moderate Generalized Resorption

Despite the potential for repair, root resorption is an unavoidable consequence of orthodontic treatment especially in patients with longer duration of treatment time. Compared to other teeth, maxillary incisors show somewhat greater shortening of root length. But all teeth included in the fixed orthodontic appliance therapy show slight average shortening (Proffit, 2013).

#### Severe Generalized Resorption

Severe generalized root resorption, fortunately, is rare. Severe generalized root resorption has been noticed in many individuals without any history of orthodontic treatment. The presence of severe generalized resorption before orthodontic treatment puts the patient at considerable risk of further resorption during orthodontic treatment, much more so than a patient with no pretreatment resorption. Although hormonal imbalances and other metabolic derangements have been suspected in these susceptible patients, little evidence supports these theories. It was reported in the 1940s that a deficiency of thyroid hormone could lead to generalized root

resorption. The etiology of severe generalized resorption is still considered entirely unknown. Various reports have suggested that the teeth exhibiting thin roots with pointed apices, distorted root form (dilaceration), or a history of trauma may present with above average root resorption during the orthodontic treatment. However, these characteristics can be considered as indicators for moderate resorption than as risk factors for severe root resorption (Proffit, 2013).

### Severe Localized Resorption

In some instances, orthodontic treatment may be the cause of severe localized root resorption. Use of heavy forces for a prolonged duration of time increases the amount of root resorption. It is increasingly apparent that some individuals are more susceptible to root resorption. It seems reasonable to presume that the large individual differences relate to genetic factors. There have been few studies linking genetic factors such as IL-1 $\beta$  gene polymorphisms to root resorption. Until now, the best way to identify the patients who are likely to experience large amounts of resorption is to take a panoramic radiograph every 6 to 9 months and evaluate the amount of resorption (Proffit, 2013). There is no diagnostic method using genetic testing to evaluate resorption risk prior to the orthodontic treatment.

## **2.2 Root resorption and Immune system disorders**

Activated leukocytes in the peripheral blood, indicative of pathology, suggest a possible association between pathological conditions affecting the immune system and orthodontic root resorption (Nishioka, 2006). Excessive OIRR has been noticed in patients who showed signs of psychological stress and incidence of asthma and allergies when compared to patients not suffering from any of these conditions.(Davidovitch Z, 2000). Similarly, McNab et al have reported increased incidence of EARR in an asthma study group. (McNab, 1999).

A retrospective study evaluated records of 60 orthodontic patients and 60 pair-matched controls in a Japanese population. Elevated levels of pro-inflammatory cytokines were reported in the serum of patients with active periodontal disease. However, no association was found between gingival inflammation and root resorption. The lack of association was most likely due to the use of intraoral photographs to detect the status of periodontal health. In addition, no significant association was found between root resorption and the extraction of permanent teeth. This study further supports the hypothesis that it is abnormal root morphology and possibly asthma and allergy that may be the most significant factors for excessive root resorption during the course of orthodontic treatment (Nishioka, 2006).

### **2.3 Short Root Anomaly**

Short-root anomaly (SRA) was first identified in a Swedish population by Volmer Lind in 1972. SRA can be defined as ‘abnormally short, plump roots mostly affecting both central incisors almost symmetrically (LIND, 1972). SRA is a rare condition, with a prevalence estimated at 1.3%. It is more common in female patients and principally affects the premolars and the maxillary incisors, the apexes of which are rounded rather than the usual pointed shape (Apajalahti, 2002; Apajalahti, 2003; Pazzini, 2010). Frequency of SRA is fairly low among the Caucasian population. SRA is fairly common among Japanese and Mongolian populations. Short rooted central incisors are also common among American-Indians (LIND, 1972). Lind suggested that SRA is an anomaly of genetic origin as he found that the maxillary central incisors are typically affected simultaneously and symmetrically, whereas mandibular central incisors are rarely involved. It has been reported that SRA is 3 times as common in girls as in it is in boys. The prevalence of the condition varies with race and possesses a familial pattern of inheritance

(LIND, 1972). An autosomal dominant inheritance pattern was documented in several individuals with SRA from eight families (Apajalahti, 1999).

A study by C. P. Puranik et al showed a predominantly autosomal dominant inheritance pattern in Hispanic individuals. They concluded that SRA has a predilection towards anterior teeth and in individuals of Hispanic descent. Due to the autosomal dominant inheritance pattern, they proposed the term 'hereditary idiopathic root malformation' or HIRM, as a more accurate name for the anomaly (Puranik, 2015).

Dental anomalies such as hypodontia, supernumerary teeth, invaginated teeth, microdontia, taurodontia, pulp stones and type I dentin dysplasia have been associated with SRA. It has also been associated with syndromes, such as Steven-Johnson syndrome and Down syndrome. SRA has also been associated with exogenous factors, including radiation of the head and neck or chemotherapy in children with malignant tumors during dental development (Pazzini, 2010).

The risk of root resorption increases when orthodontic forces are applied to teeth with short roots, possibly due to the lower root/crown ratio (Kjaer, 1995). Unusual root morphology present before orthodontic treatment has been associated with increased risk of root resorption (Weltman B, 2010). During the course of orthodontic treatment significant root shortening has been reported in patients who present with short roots without any prior history of orthodontic treatment. (Thongudomporn U, 1998). Root resorption and periodontal disease leading to the loss of alveolar bone can further compromise the prognosis in a patient who exhibits SRA.

SRA is not well documented, likely because it is poorly understood and the etiology still remains unknown. Care should be taken not to misdiagnose SRA as root resorption. Oyama et al

demonstrated that in a short root model, significant stress was concentrated at the apex of the roots, enough for the development of root resorption. Thus, orthodontic forces should be applied with considerable caution in patients exhibiting SRA (Oyama K, 2007). In extreme cases of SRA, orthodontic movement of teeth is contraindicated (Neto, 2013).

## **2.4 IL-1 $\beta$ :**

IL-1 $\beta$  is an important mediator of the inflammatory response and belongs to the interleukin-1 family of cytokines. This cytokine is primarily produced by macrophages as a proprotein, which is subsequently proteolytically cleaved into its final, active form by caspase 1 (CASP1/ICE). The IL-1 $\beta$  gene together with eight genes from the interleukin family form a cytokine gene cluster on chromosome 2. IL-1 $\beta$  is involved in a variety of cellular activities including cell proliferation, differentiation, apoptosis and most notably, inflammation. As a mediator of inflammation, IL-1 $\beta$  has been shown to induce cyclooxygenase-2 in the central nervous system (CNS), contributing to inflammatory pain hypersensitivity (“IL1B interleukin 1 beta [ Homo sapiens (human) ],” 2017).

It also plays a key role in both acute and chronic inflammation as well as autoimmune disorders (Ke Rena, 2011). IL-1 $\beta$  also contributes to homeostatic functions of the body including regulation of sleep, feeding and body temperature (Braddock M, 2004; Dinarello CA, 1996). However, an imbalance in IL-1 $\beta$  expression has been shown to elicit pathophysiological changes including rheumatoid arthritis, inflammatory bowel disease, neuropathic pain, osteoarthritis, multiple sclerosis, vascular disease and Alzheimer’s disease (Braddock M, 2004; CA, 2004; Dinarello CA, 1996). Numerous studies have reported that multiple auto-inflammatory diseases may, in fact, result from mutations within genes, resulting in an over production of IL-1 $\beta$  and



consequent disease states (Church LD, 2008; Ke Rena, 2011; Stojanov S, 2005). Not all inflammation is detrimental however as IL-1 $\beta$  has been shown to be beneficial in cases of sterile inflammation such as orthodontic tooth movement (OTM) and apoptosis.

The IL-1 $\beta$  gene is highly polymorphic and many studies have confirmed C and T base substitutions at the following positions: -511 (C-T), -31 (T-C) and +3954 (C-T). The -511 (C-T) and -31 (T-C) substitutions occur in the promoter region and demonstrate high linkage disequilibrium, which suggests that these mutations typically occur in unison (El-Omar EM, 2000; Machado JC, 2001; Xu, 2013). The -31 (T-C) substitution causes a disruption in the TATA box motif, which has been shown to affect the binding affinity of various transcription factors to the promoter, resulting in a change in IL-1 $\beta$  transcription (Chen H, 2006; El-Omar EM, 2000; Lind H, 2007). In contrast, the +3954 (C-T) substitution occurs within the IL-1 $\beta$  gene at exon 5 as a synonymous single nucleotide polymorphism (SNP). Within the literature, both the -511T and +3954T alleles have been shown to increase IL-1 $\beta$  secretion from lipopolysaccharide-induced protein secretions (Hall SK, 2004; Hernandez-Guerrero C, 2003; Pociot F, 1992; Xu, 2013). In children between the ages of 6-18 years old, increased allergic asthma risk has been associated with the +3954 polymorphisms. Serum levels of IL-1 $\beta$  was also increased in asthmatic children as compared to the healthy control (Sobkowiak, 2017).

## **2.5 IL-1 $\beta$ polymorphism +3954, -31, -511 and Periodontitis**

Periodontal disease is usually a chronic inflammation triggered by pathogens such as *Actinobacillus actinomycetemcomitans* and *Porphyromonas gingivalis*. Expression of proinflammatory cytokines such as IL-1 $\beta$  are triggered by the presence of periodontal pathogens. Due to its bone resorptive and proinflammatory properties, IL-1 $\beta$  has been associated with

increased tissue destruction. The severity of periodontal disease has been correlated with increased levels of IL-1 $\beta$  in the gingival crevicular fluid (Ferreira, 2008).

IL-1 $\alpha$  and IL-1 $\beta$  polymorphisms have been associated with increased periodontal disease and tooth loss as well as with type II diabetes and coronary heart disease (CHD). Compared to the wild-type IL-1 $\beta$ , diabetics with the IL-1 $\beta$  genotype CT or TT exhibited a more severe periodontal disease, which suggests that these genotypes may increase the inflammatory response. Another study reported a decrease in mean alveolar bone level in patients with CHD associated with these same genotypes, which further suggests the involvement of these polymorphisms in inflammation (Dinarello, 2011).

IL-1 $\beta$  is a key regulator of the host response and is a potent bone resorbing factor. It has been reported that single nucleotide polymorphisms (SNPs) in the IL-1 $\beta$  gene are associated with increased susceptibility to chronic periodontitis (Arora, 2017; Loos BG, 2015). Various ethnic populations are known to have varying susceptibility to chronic periodontitis owing to SNPs in the IL-1 $\beta$  gene (Wu X, 2015). It is estimated that approximately 30% of the Caucasian population has the IL-1 $\beta$  genotype polymorphism that is associated with increased susceptibility to chronic periodontitis (Arora, Shelly; 2017; Wu X, 2015).

Several studies have shown that an individual with allele C at IL-1 $\beta$  +3954 is associated with a high risk of developing aggressive periodontitis (Abhijeet Rajendra Shete, 2010; Diehl SR, 1999). The promoter sequence is a potential source for polymorphisms, which would result in altered gene expression. Several SNPs within the regulatory region of cytokine genes are associated with altered gene expression. The haplotype consisting of the C allele at -31 and the T allele at -511 has been associated with a 2 to 3-fold increase in lipopolysaccharide-induced IL-1 $\beta$  protein secretion. Thus, a haplotype study for the IL-1 $\beta$  gene is crucial as the -511 and -31

polymorphisms may influence the susceptibility and prognosis of disease through the IL-1 $\beta$  mediated inflammatory response (Abhijeet Rajendra Shete, 2010; Hall SK, 2004). A more recent study identified a strong association between the CT genotype at IL-1 $\beta$  +3954 and the TT genotype at IL-1 $\beta$  -511 with chronic periodontitis. However, no significant association with the disease was noted at the -31 polymorphism (Amirisetty, 2015).

## **2.6 IL-1 $\beta$ polymorphism +3954 and root resorption**

Several studies have reported an increased level of IL-1 $\beta$  in both the gingival tissue and the gingival crevicular fluid of patients undergoing orthodontic treatment. This cytokine has also been associated with bone resorption accompanying orthodontic tooth movement. (R. A. Al-Qawasmi, 2003; Alhashimi N, 2001; Grieve WG, 1994; Lehky L, 1988; Lynch PR, 1988; Sharp LB, 1991). Patients undergoing orthodontic treatment exhibited variations in the level of IL-1 $\beta$  and these variations were correlated with individual differences in the amount of tooth movement (Iwasaki LR, 2001; Rossi M, Whitcomb S, 1996). This may contribute to EARR susceptibility depending on the level of IL-1 $\beta$  expression (Davidovitch Z, 1991). These differences in expression may be attributed, in part, to the alleles at IL-1 $\beta$  gene polymorphisms. For example, the T allele at +3954 has been associated with a 4-fold increase in IL-1 $\beta$  production (Al-Qawasmi, 2003; Pociot F, 1992).

The first study to describe the association between IL-1 $\beta$  gene polymorphisms and EARR during orthodontic treatment was carried out by Al-Qawasmi et al. (2003). Among all teeth studied, maxillary central incisors exhibited the highest heritability for EARR. Consequently, these teeth are usually the most severely affected by root resorption during orthodontic treatment (R. A. Al-Qawasmi, 2003; Harris, 1997). The transmission of haplotypes, including the C allele

at +3954, was also demonstrated to increase the risk of EARR. On the contrary, transmission of haplotypes which included the T allele at +3954 decreased susceptibility to EARR, which further emphasizes the role of genetic susceptibility to EARR (R. A. Al-Qawasmi, 2003). From Al-Qawasmi's study (2003), it can be noted that there is a correlation between *in vitro* IL-1 $\beta$  expression and the IL-1 $\beta$  polymorphisms associated with EARR in orthodontic patients. Specifically, allele C of the IL-1 $\beta$  polymorphism at +3954 is associated with a relatively low expression of IL-1  $\beta$  (Endres S,1989; Pociot F, 1992). A 4-fold increase in IL-1 $\beta$  expression has been noted in cell from patients who are homozygous for the IL-1 $\beta$  +3954 T allele. Heterozygous CT cells produce 2-fold more IL-1 $\beta$  as compared to the cells from those homozygous for allele T (di Giovine FS, 1995; Pociot F, 1992).

Since IL-1  $\beta$  is a potent stimulator of bone resorption and aids in the recruitment of osteoclasts during orthodontic tooth movement, low IL-1  $\beta$  expression in the case of the C allele at +3954 may result in less resorption of the bone at the cortical bone interface with the PDL (R. A. Al-Qawasmi, 2003; Alhashimi N, 2001; Sharp LB, 1991). Al-Qawasmi et al (2003) suggested that excessive root resorption associated with the C allele of IL-1 $\beta$  at +3954 may be due to impaired alveolar bone resorption resulting in prolonged stresses on the adjacent tooth root and subsequent loss of cementum and dentin (R. A. Al-Qawasmi, 2003; WE, 2000). Research conducted with IL-1 $\beta$  knockout mice showed that root resorption associated with orthodontic tooth movement may, in fact, be mediated through a decreased rate of alveolar bone resorption, adding further evidence to support the hypothesis that a sufficient level of IL-1 $\beta$  expression is required to support bone resorption while maintaining root cementum (R. A. Al-Qawasmi, 2003; R. a Al-Qawasmi, 2004). These findings contradict the original hypothesis that

increased severity of EARR after orthodontic treatment may be related to an increased expression of IL-1  $\beta$  leading to increased resorption of alveolar bone (Engstrom C, 1988).

## **Chapter 3, Materials and Methods:**

### **3.1 Study Design**

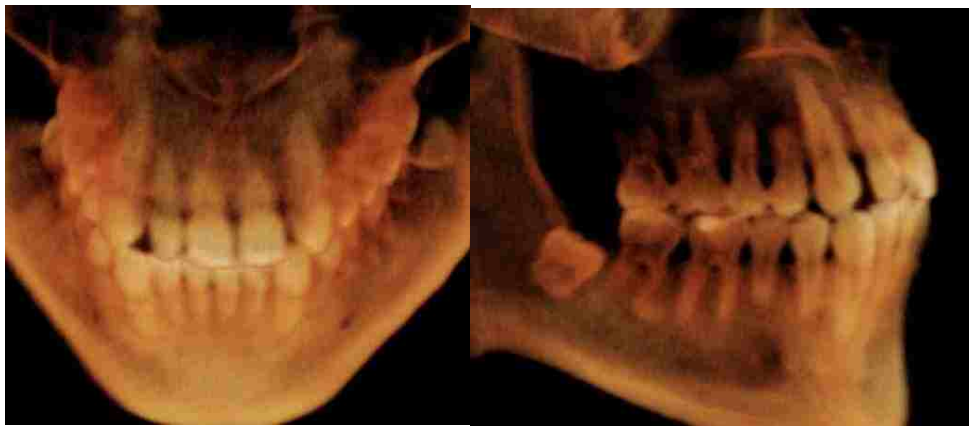
This case control study was conducted from March of 2016 to November of 2017 and sampled patients of record from the UNLV Orthodontic Clinic. The study was carried out with written informed consent from the subjects and their parents. The protocol was approved by the Biomedical Sciences IRB at the University of Nevada Las Vegas Office of Research Integrity (protocol number – 944227). A total of 52 patients were included in the study. Twenty-six patients were included in the SRA group with 2 or more teeth exhibiting short roots. The mean age in the short root group was 16.7 years (age range 12 – 37 years) with 15 female patients and 11 male patients. The control group included 26 subjects exhibiting normal root length. The mean age in the control group was 16.8 years (age range 13-30 years) with 9 female patients and 17 male patients. In the SRA group, 23 patients were Hispanic, 1 was Asian and 2 were Caucasian. The Control group consisted of 9 Hispanic, 3 Asian, 3 African American and 11 Caucasian patients.

### **3.2 Selection of Study Subjects**

Patients were selected for the study using the following criteria:

- 1) No previous history of orthodontic treatment
- 2) All or most of the permanent teeth erupted and root formation completed except for 2<sup>nd</sup> and 3<sup>rd</sup> molars
- 3) SRA group – Patients exhibited 2 or more teeth with short roots
- 4) Control group – All teeth exhibited normal root length
- 5) No history of trauma to the teeth exhibiting short roots

Panoramic radiographs and CBCT scans are obtained as a standard procedure for orthodontic diagnostic records at the UNLV SDM orthodontic clinic. Panoramic radiographs were used as an initial screening tool to identify patients with short roots. The presence of short roots was confirmed using volumetric analysis from the Cone Beam Computed Tomography (CBCT) (Fig.1). Roots were considered short if they were visually short and plump (LIND, 1972). All patients were randomly selected for the control group with no bias for age, sex or ethnicity. Once root morphology was confirmed, all patients and their x-rays were de-identified and assigned a random number using a random number generator application (Pretty Random for Apple iPhone).



***Figure 1. 3D Volumetric analysis of patient #398 exhibiting short roots on central incisors and bicuspids.***

### **3.3 Clinical Procedures**

The subjects providing the sample had not consumed any food or drink in the 60 min prior to sample collection. To collect the buccal cells, the buccal mucosa was scraped 10 times on both sides of the cheek in a rolling motion using a buccal collection brush (Gentra Puregene Buccal Cell Kit, #158845). Cell lysis solution (300  $\mu$ l) was dispensed into a 1.5 ml microcentrifuge tube to begin lysis. The collection brush was removed from its handle using

sterile scissors, and the detached head was placed in the tube. All of the samples were processed within 48 hours after collection.

### **3.4 DNA Purification**

The Gentra Puregene Buccal Cell Kit (#158845) was used to isolate genomic DNA from all buccal cell samples. All steps followed the manufacturer's instructions and are described in detail below.

- 1) To achieve maximum yield, 1.5  $\mu$ l of Puregene Proteinase K was added to the 1.5 ml microcentrifuge tube containing the collection brush, mixed by inverting 25 times, and then incubated at 55°C overnight.
- 2) The collection brush head was removed from the Cell Lysis Solution, scraping it on the sides of the tube to recover as much liquid as possible.
- 3) As RNA-free DNA was required, 1.5  $\mu$ l of RNase A Solution was added and vortexed. Samples were incubated for 45 min at 37°C.
- 4) Samples were then incubated for 1 min on ice to quickly cool the samples.
- 5) 100  $\mu$ l of Protein Precipitation Solution was added and vortexed vigorously for 30 s at high speed.
- 6) Samples were incubated for 10 min on ice.
- 7) Samples were centrifuged for 5 min at 16,000 x g. The precipitated proteins formed a tight pellet. If the protein pellet was not tight, samples were incubated on ice for an additional 5 min and centrifugation repeated.
- 8) 300  $\mu$ l isopropanol and 0.5  $\mu$ l Glycogen solution were pipetted into a clean 1.5 ml centrifuge tube, and the supernatant was added from the previous step.



- 9) Samples were mixed by inverting gently 50 times.
- 10) Samples were centrifuged for 5 min at 16,000 x g.
- 11) The supernatant was carefully discarded, and the tube was drained by inverting on a clean piece of absorbent paper, taking care that the pellet remained in the tube.
- 12) 70% (300  $\mu$ l) ethanol was added to each tube and inverted several times to wash the DNA pellet.
- 13) The samples were centrifuged for 5 min at 16,000 x g.
- 14) The supernatant was carefully discarded. The tube was drained on a clean piece of absorbent paper, taking care that the pellet remained in the tube. Samples were allowed to air dry for 5 min.
- 15) DNA Hydration Solution (100  $\mu$ l) was added to each tube and vortexed for 5 s at medium speed to mix.
- 16) Samples were incubated at 65°C for 1 h to dissolve the DNA.
- 17) Samples were then centrifuged briefly and stored in the freezer at -20°C.
- 18) DNA yield was determined using a spectrophotometer. Dilution of 1:80 was used for the determination. 790  $\mu$ l of Deionized Ultra-Filtered Water (D.I.U.F) was mixed with 10  $\mu$ l of purified genomic patient DNA. Optical density (O.D) at 260 nm and 280 nm was recorded for all of the samples. The ratio of the absorbance maximum at 260 nm to the absorbance at 280 nm was used to calculate concentration and purity.

### **3.5 PCR amplification and Digest**

Each patient's genomic DNA sample was diluted to the concentration of 50  $\eta$ g/ $\mu$ l. A separate PCR reaction for amplification of a region encompassing each site (IL-1 $\beta$  +3954, -31, -511) was prepared by adding 4  $\mu$ l patient DNA (50  $\eta$ g/ $\mu$ l), 25  $\mu$ l of Promega GoTaQ<sup>®</sup> master

mix (M7132), 2.5  $\mu$ l of forward primer (10  $\mu$ M) and 2.5  $\mu$ l of reverse primer (10 $\mu$ M) for IL-1 $\beta$  +3954, -31, and - 511 (Table 1) with nuclease free H<sub>2</sub>O (16  $\mu$ l) to a total volume of 50  $\mu$ l.

PCR thermocycling conditions for the +3954 and -511 amplifications consisted of the following steps: Initial denaturation at 95°C for 3 minutes followed by 39 cycles of 95°C for 1 minute, 57°C for 1 minute, and 72°C at 1 minute. A final extension was performed at 72°C for 8 minutes. Reactions were held at 4°C until freezing at -20°C.

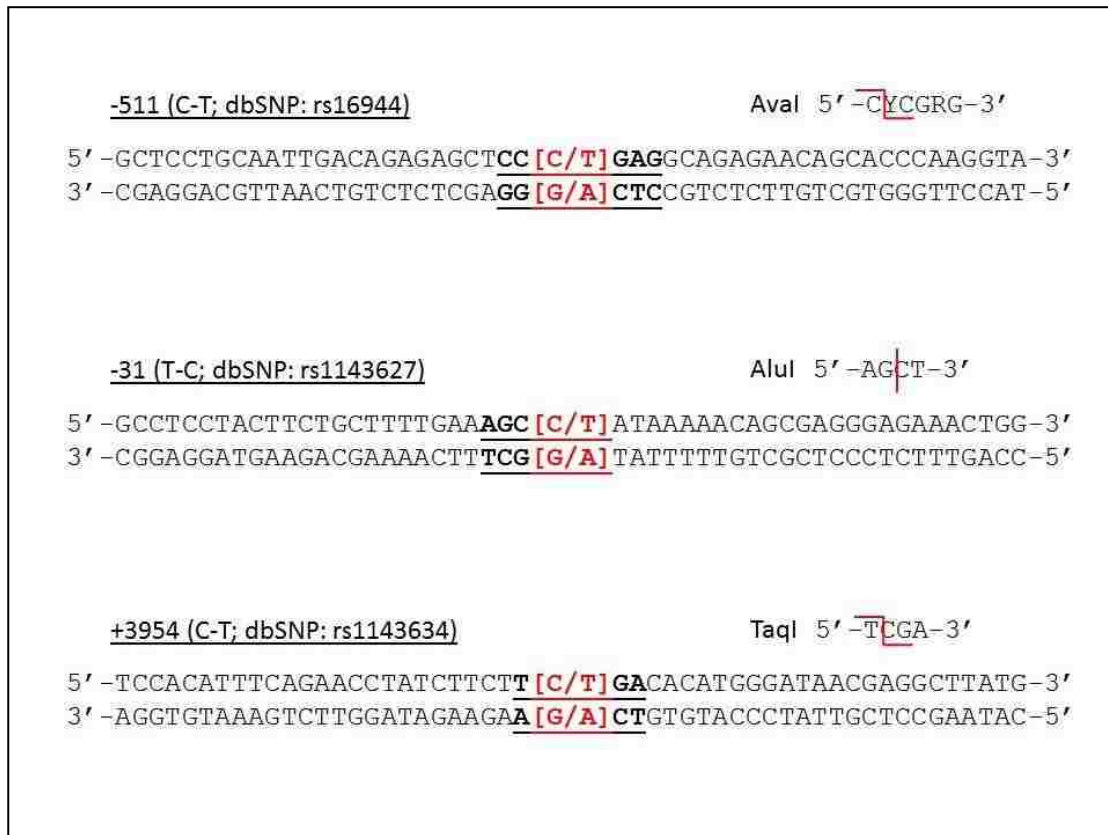PCR thermocycling conditions for the -31 amplifications consisted of the following steps: Initial denaturation at 95°C for 3 minutes followed by 39 cycles of 95°C for 1 minute, 51°C for 1 minute, and 72°C at 1 minute. A final extension was performed at 72°C for 8 minutes. Reactions were held at 4°C until freezing at -20°C.

The amplified products were 194 bp for the region encompassing the +3954 site, 155 bp for the -511 site and 239 bp for the -31 site. The +3954 amplified products were digested overnight with TaqI at 37°C. The -511 product was digested overnight with AvaI at 37°C. The -31 products were digested overnight with AluI at 37°C. Following the overnight digest, products were stored at -20°C.

**Table 1. Primer Sequence**

IL-1 $\beta$ +3954	Forward primer: 5'-CTCAGGTGTCCTCGAAGAAATCAA-3'
	Reverse primer: 5'- GCTTTTTTGCTGTGAGTCCCG-3'
IL-1 $\beta$ -511	Forward primer: 5'-GCCTGAACCCTGCATACCGT-3'
	Reverse primer: 5'-GCCAATAGCCCTCCCTGTCT-3'
IL-1 $\beta$ -31	Forward primer: 5'-AGAAGCTTCCACCAATACTC-3'
	Reverse primer: 5'-AGCACCTAGTTGTAAGGAAG-3'

**Figure 2- IL-1B single nucleotide polymorphisms and restriction endonuclease recognition sites**



### **3.6 Agarose gel electrophoresis**

Full-length PCR products and digests for each subject were resolved with agarose gel electrophoresis. All agarose gels were prepared at 2.5% containing ethidium bromide at a concentration of 500 ng/ml. A 100 bp molecular weight standard was included on all gels. Visualization of the gels was performed under UV light and images of the gels were captured using a Kodak Gel Logic 100 Imaging System (Rochester, NY). Bands representative of full length amplified PCR products and digested fragments were identified and noted based on the relative size of the bands compared to the 100 bp standard.

The TaqI digest of amplified +3954 site products yielded a 182 bp band when a T allele was present, since the TaqI site was not present. When a C allele was present at +3954, the cleavage at the preserved TaqI site resulted in bands of 85bp and 97bp. In both cases, a 12bp band was produced that was designed in the primers as a control site, although this was rarely visible on any agarose gel.

The AluI digest of amplified -31 site products yielded a single 239 bp band when a C allele was present, since the AluI site was not present. When a T allele was present at -31, the cleavage at the preserved AluI site resulted in a band of 137 bp and 102 bp.

The AvaI digest of amplified -511 site products yielded a single 155 bp band when a T allele was present, since a suitable AvaI site was not present. When a C allele was present at -511, the cleavage at the AvaI site resulted in bands of 92 bp and 63 bp.

### **3.7 DNA sequencing**

A sample of amplified full length amplified products from patients representing each genotype for all 3 sites +3954, -31 and -511 were randomly selected for DNA sequencing to verify the accuracy of sites identified by restriction endonuclease digests. PCR products were

sequenced by Functional Biosciences, Inc. (Madison, WI). The data files were viewed using CodonCode Aligner 7.1.2 for Mac OS X. At the time of sequencing, no patients with the TT genotype at the +3954 site were identified.

### **3.8 Statistical Analysis:**

The Chi-square test was used to investigate the distribution of the genotype and the allelic frequency in the short root and control groups for each IL-1 $\beta$  gene polymorphism. The Odds ratio (OR) was used to calculate the risk of patients presenting with SRA with each of the genotypes. Significance level was set at 5% and all chi-square tests were performed using Microsoft Excel (version 15.40) and the odds ratio was calculated using a web based calculator ([www.graphpad.com](http://www.graphpad.com)).

## Chapter 4, Results:

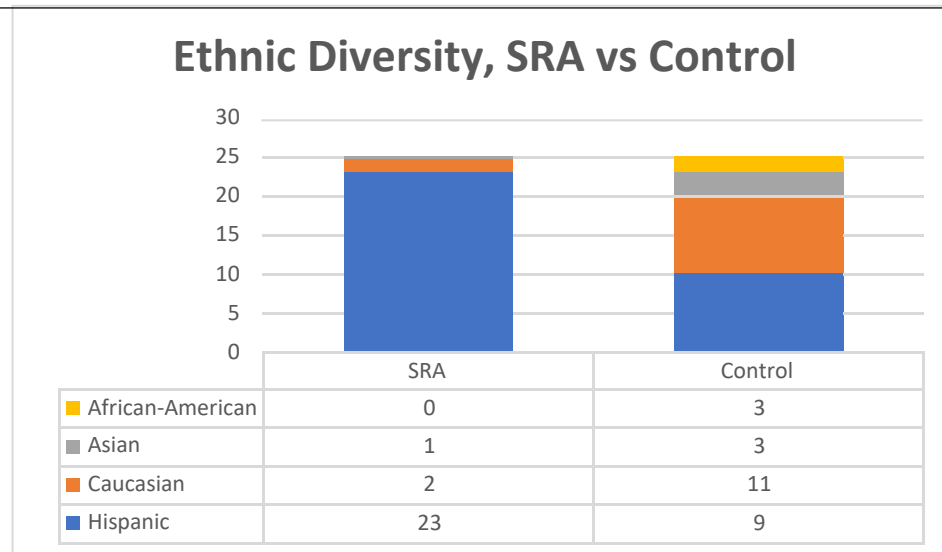
A total of 52 patients were evaluated for the IL-1 $\beta$  polymorphism at +3954, -511 and -31. Twenty-six patients exhibited short roots on two or more teeth and were categorized as SRA. An additional 26 patients were selected randomly and categorized as control if they exhibited roots within normal length.

### 5.1 Ethnic and sexual diversity among SRA and control

Samples were randomly collected from patients at the UNLV Orthodontic Clinic after confirming the presence of short roots or normal roots with panoramic radiographs and Cone Beam Computed Tomography (CBCT). The total sample (n=52) included 32 patients of Hispanic origin (61%), 13 patients of Caucasian origin (25%), 4 patients of Asian origin (8%) and 3 patients of African-American (6%) origin (Table 2). In the SRA group, 23 patients were Hispanic (88%), 2 were Caucasian (8%) and 1 was Asian (4%) (n=26) (Fig.3). In the control group 9 patients were Hispanic (33%), 11 were Caucasian (41%), 3 were Asian (11%) and 3 were African-American (15%) (n=26) (Fig.3).

**Table 2. Ethnic Diversity, n = 52**

Hispanic	32
Caucasian	13
Asian	4
African-American	3

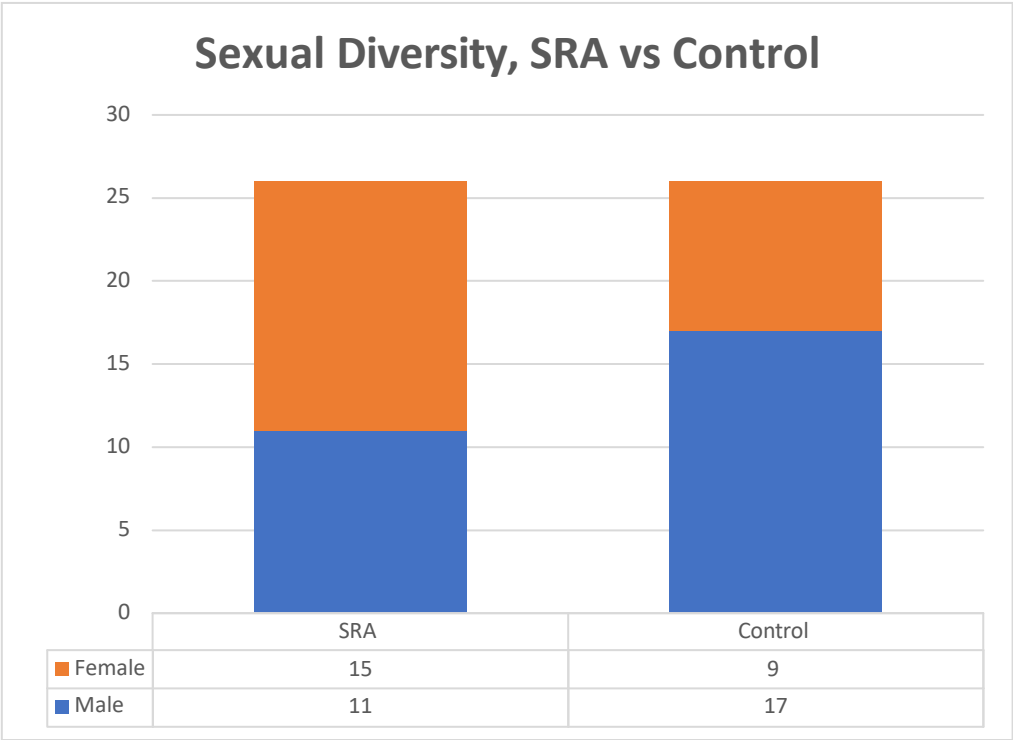


**Figure. 3 Ethnic Diversity, SRA vs Control**

Twenty-eight patients were males (54%) and 24 were females in the total sample (46%) (n=52) (Table 3). 11 patients were male (42%) and 15 were female (58%) in the SRA group, while 17 patients were male (65%) and 9 (35%) were female in the control group (Fig. 4).

**Table 3. Sexual Diversity, n = 52**

Male	28
Female	24

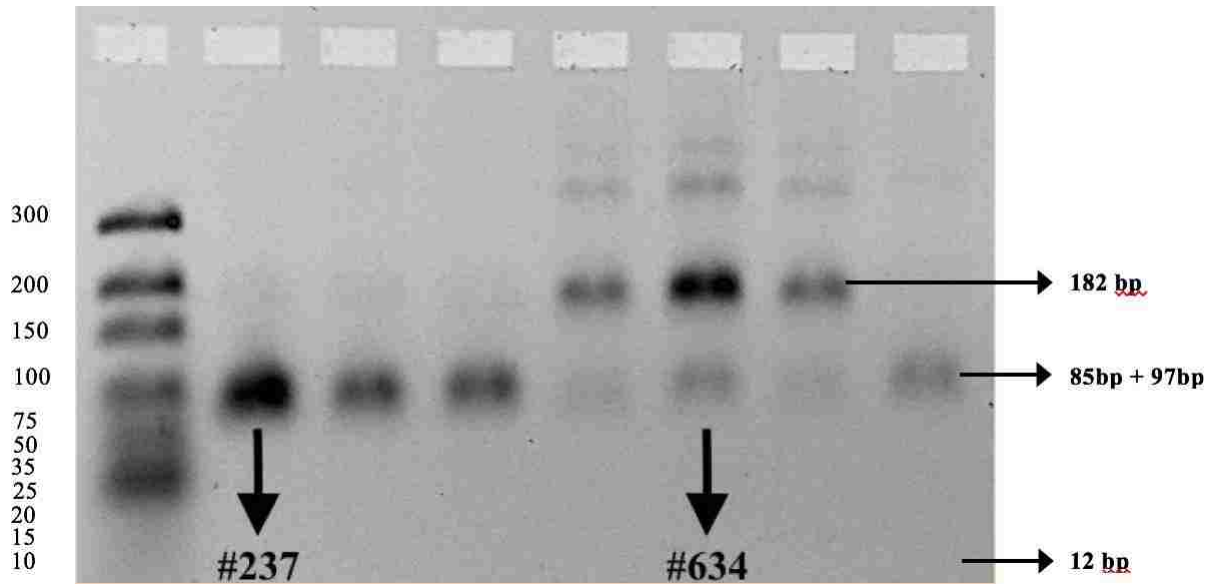


**Figure 4. Sexual Diversity, SRA vs Control**

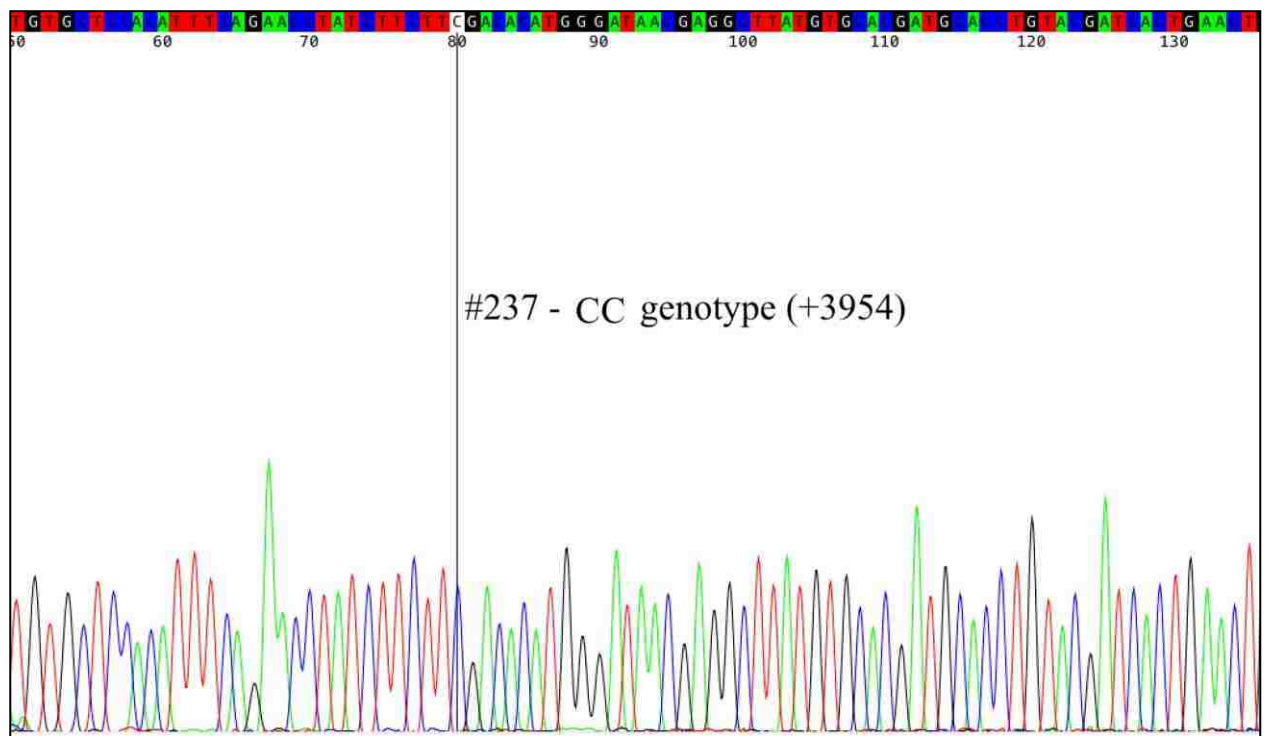
**5.2 IL-1 $\beta$  +3954 Polymorphism**

The results from the DNA sequencing were 100% concordant with our analysis using restriction digest and agarose gel electrophoresis for the +3954 polymorphism. Representative patient #237 exhibited the CC genotype and patient #634 exhibited the CT genotype (Fig. 5). These findings were confirmed with DNA sequencing (Fig 6 & 7).





*Figure 5. Band pattern for +3954, patients #237 and #634*

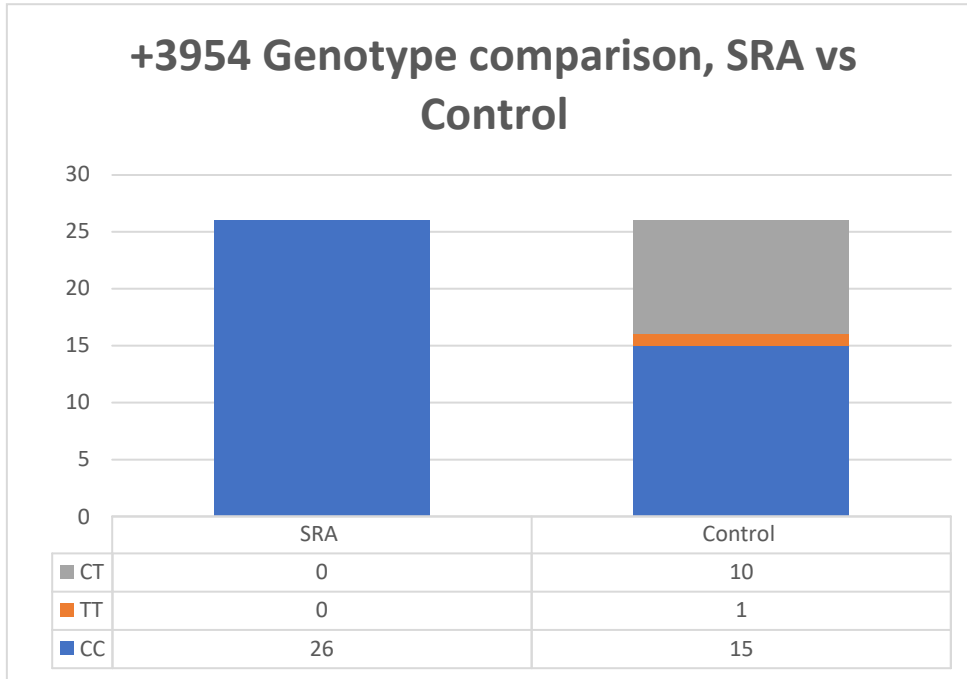


*Figure. 6 DNA sequence confirming CC genotype patient #237 (blue peak)*



**Table 4. IL-1 $\beta$  +3954 Genotype distribution in the total sample, n = 52**

CC	41
TT	1
CT	10

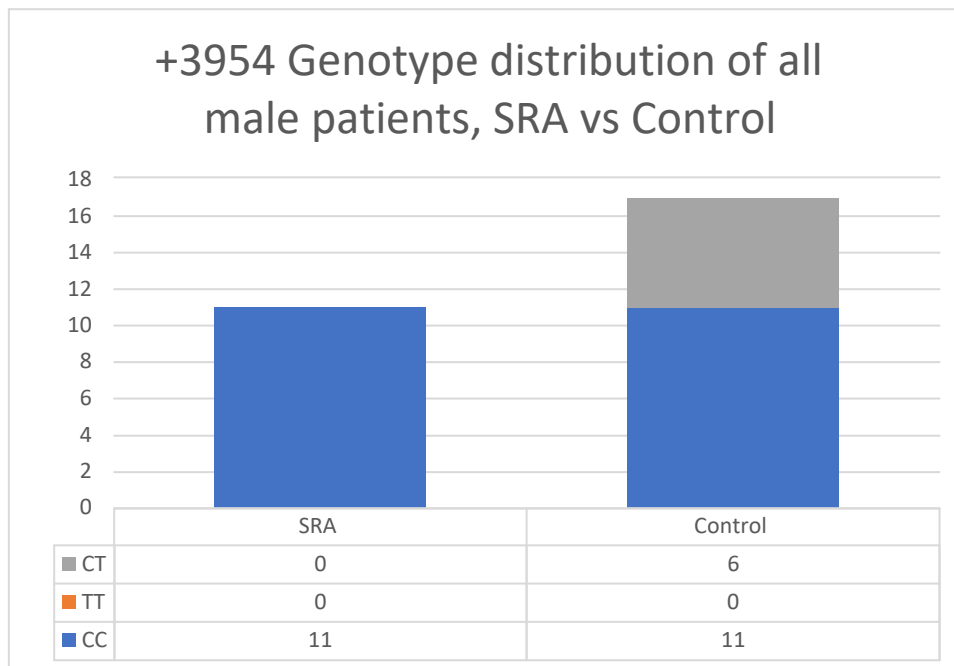


**Figure 8. +3954 Genotype comparison, SRA vs Control**

The CC genotype at +3954 was the most prevalent among all males (82%). All other males were the CT genotype at +3954 (Table 5). The presence of the CC genotype was statistically significant when compared to the TT and CT genotype (n=28) (p = 0.013). In the SRA group, 100% of the male patients exhibited the CC genotype and this difference was statistically significant (n=11) (p = 0.0001) (Fig. 9). In the control group, 71% of males exhibited the CC genotype while 29% exhibited the CT genotype (Fig. 9). This difference was statistically significant (n=17) (p =0.0001).

**Table 5. IL-1 $\beta$  +3954 Genotype distribution in the total male sample, n = 28**

CC	23
TT	0
CT	5



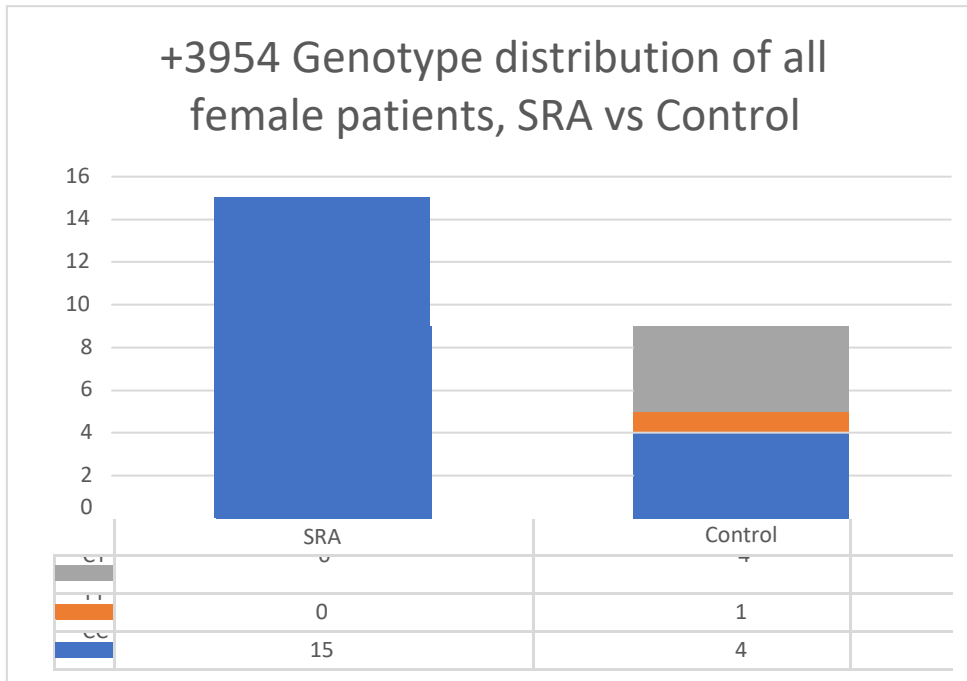
**Figure 9. +3954 Genotype distribution of male patients, SRA vs Control**

The CC genotype at +3954 was the most prevalent among all female patients (74%) while 4% of female patients exhibited the TT genotype and 22% exhibited the CT genotype (Table 6). The presence of the CC genotype was statistically significant as compared to the TT or the CT genotype (n=24) ( $p = 0.003$ ). In the SRA group 100% of females exhibited the CC genotype (Fig. 10). This difference was statistically significant (n=15) ( $p = 0.0001$ ). In the control group, 44% of the females exhibited the CC genotype, 45% exhibited the CT genotype,

while 11% exhibited the TT genotype (Fig. 10). This difference was not statistically significant (n=9) (p = 0.3)

**Table 6. IL-1 $\beta$  +3954 Genotype distribution in the total female sample, n = 24**

CC	19
TT	1
CT	4



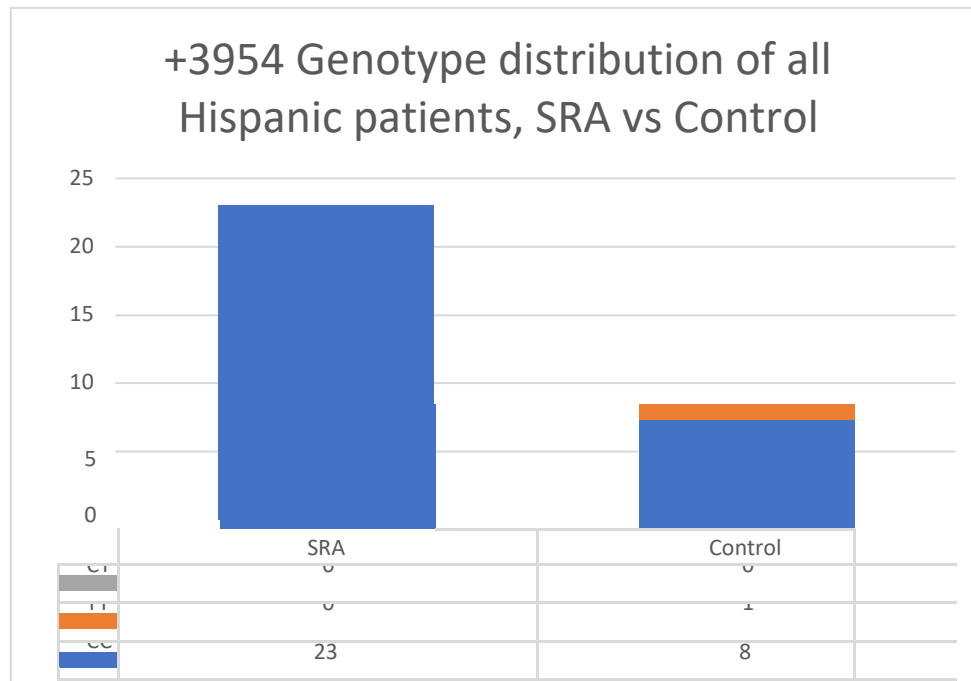
**Figure 10. +3954 Genotype distribution of all female patients, SRA vs Control**

97% of the patients of all Hispanic origin exhibited a CC genotype at +3954 and 3% of the Hispanic patients exhibited a CT genotype (Table 7). The presence of the CC genotype was statistically significant as compared to the other genotypes (n=32) (p = 0.0001). 100% of the

patients of Hispanic origin in the SRA group exhibited a CC genotype (Fig. 11). This difference was statistically significant (n=23) (p = 0.0001). 89% of the patients of Hispanic origin in the control group exhibited the CC genotype while 11% had the TT genotype (Fig. 11). This difference was statistically significant (n=9) (p = 0.0001).

**Table 7. *IL-1β* +3954 Genotype distribution in the total Hispanic sample, n = 32**

CC	31
TT	1
CT	0



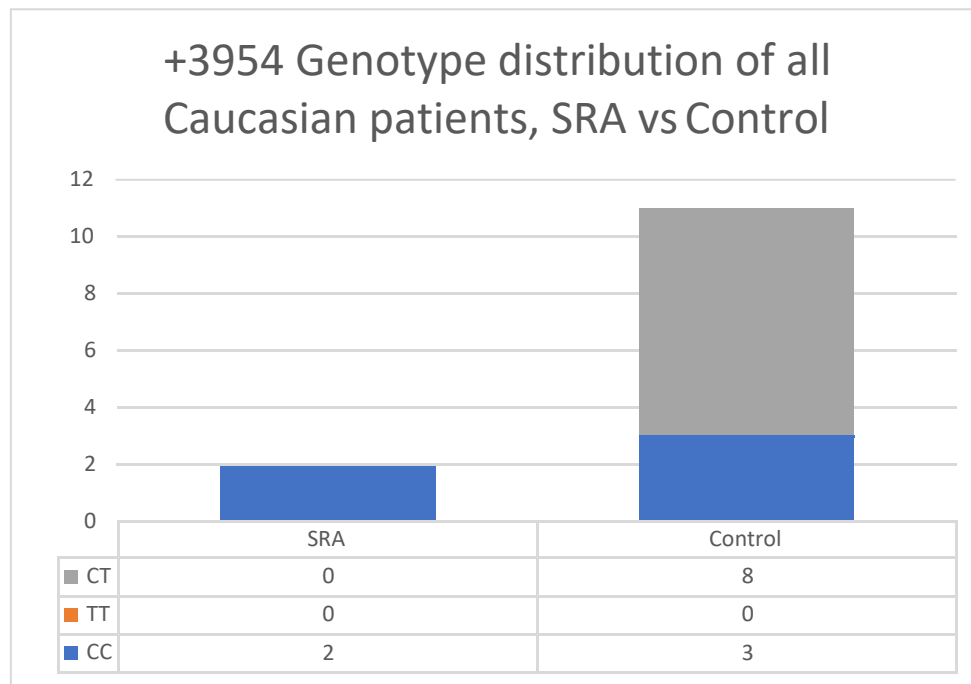
**Figure 11. +3954 Genotype distribution of all Hispanic patients, SRA vs Control**

38% of the patients of all Caucasian origin exhibited the CC genotype at +3954 and 62% of the Caucasian patients exhibited the CT genotype (Table 8). The presence of the CC genotype was not statistically significant when compared to the CT genotype (n=13) (p = 0.4). 100% of

the patients of Caucasian origin in the SRA group exhibited the CC genotype (Fig. 12). This difference was statistically significant (n=2) (p = 0.04). 73% of the patients of Caucasian origin in the control group exhibited the CT genotype and 27% exhibited the CC genotype (Fig. 12). This difference was not statistically significant (n=11) (p = 0.1).

**Table 8. *IL-1β +3954 Genotype distribution in the total Caucasian sample, n = 13***

CC	5
TT	0
CT	8



**Figure 12. *+3954 distribution of all Caucasian patients, SRA vs Control***

The CC genotype at +3954 was the most prevalent among all of the patients of Asian (100%) origin, showing a statistically significant difference (n=4) (p =0.0001) (Table 9). 67% of the patients exhibited the CC genotype and 33% exhibited the CT genotype among patients of

African-American origin, however this difference was not statistically significant (n=3) (p = 0.2) (Table 10).

**Table 9. IL-1 $\beta$  +3954 Genotype distribution in the total Asian sample, n = 4**

CC	4
TT	0
CT	0

**Table 10. IL-1 $\beta$  +3954 Genotype distribution in the total African-American sample, n = 3**

CC	2
TT	0
CT	1

From the Odds ratio calculation, patients with the CC genotype at +3954 had 12 times more chance of presenting with SRA as compared to patients with the TT genotype (OR = 12).

### **5.3 IL-1 $\beta$ -511 Polymorphism**

The results from the DNA sequencing were 100% concordant with our analysis using restriction digest and agarose gel electrophoresis for the -511 site. Representative patient #237 exhibited the TT genotype, patient #634 exhibited the CC genotype and patient #686 exhibited the CT genotype (Fig. 13). These findings were confirmed with DNA sequencing (Fig. 14, 15 and 16).



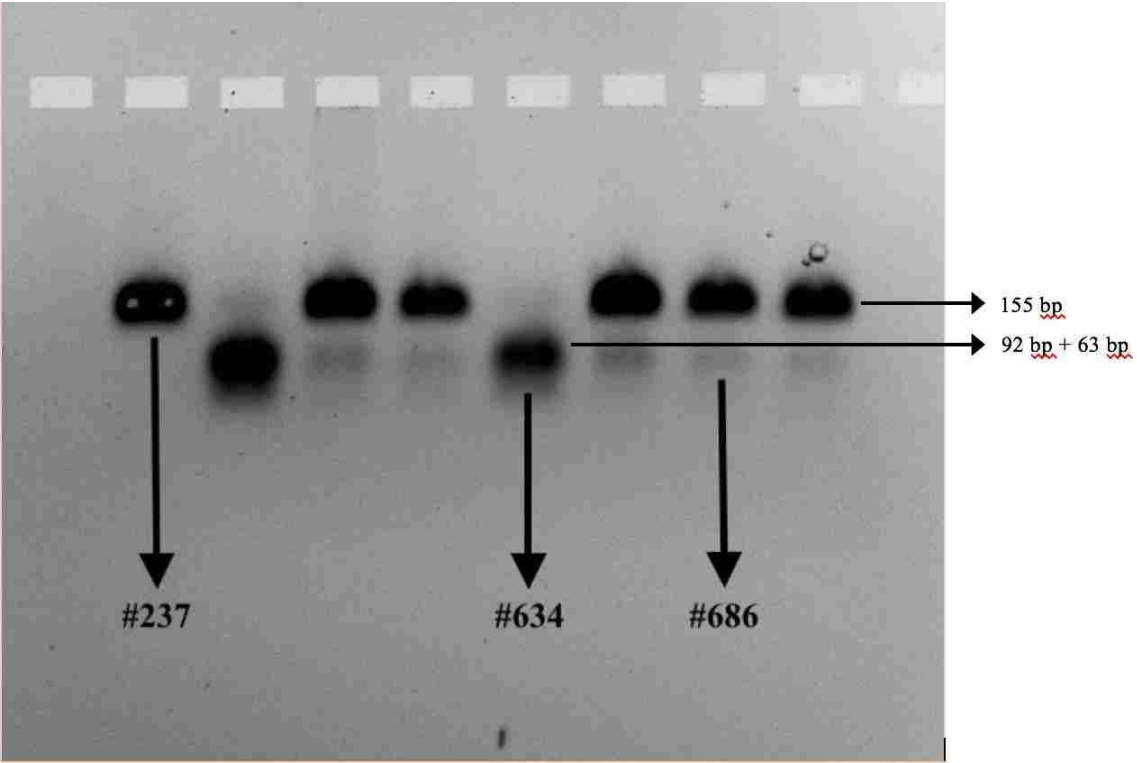


Figure 13. Band pattern for -511, patients #237, 634 and 686

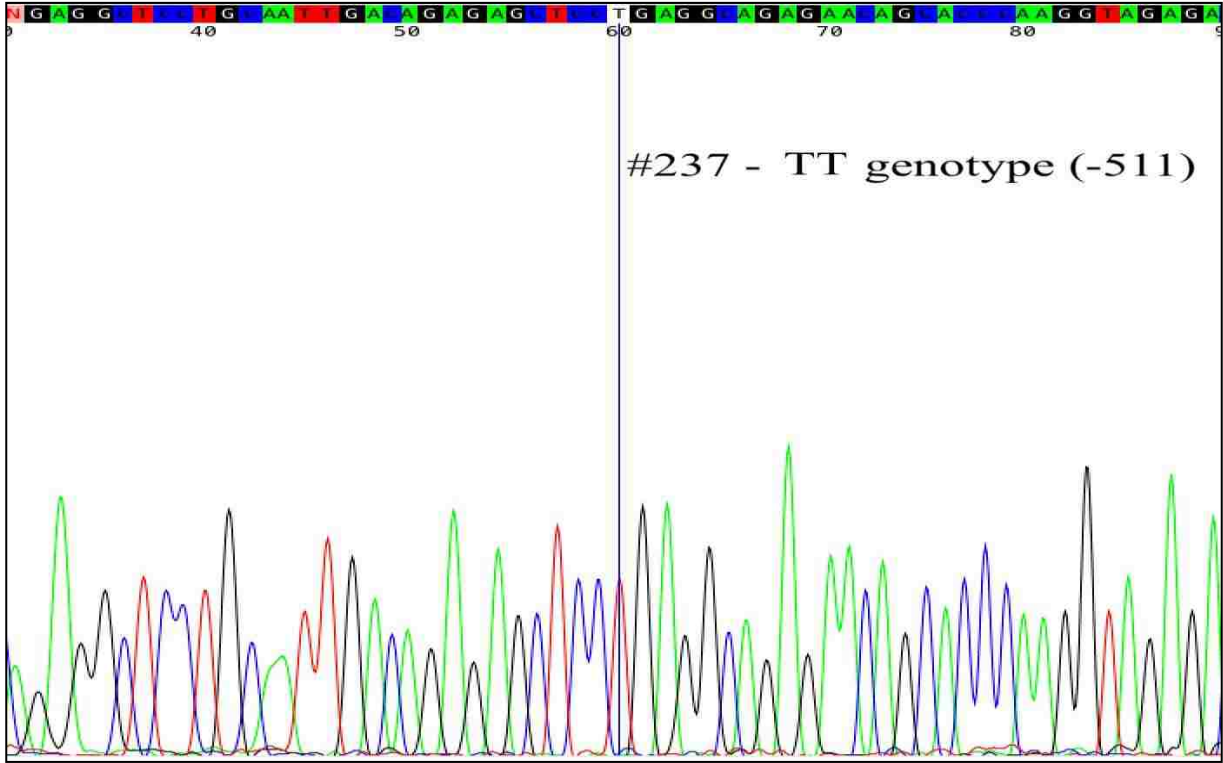
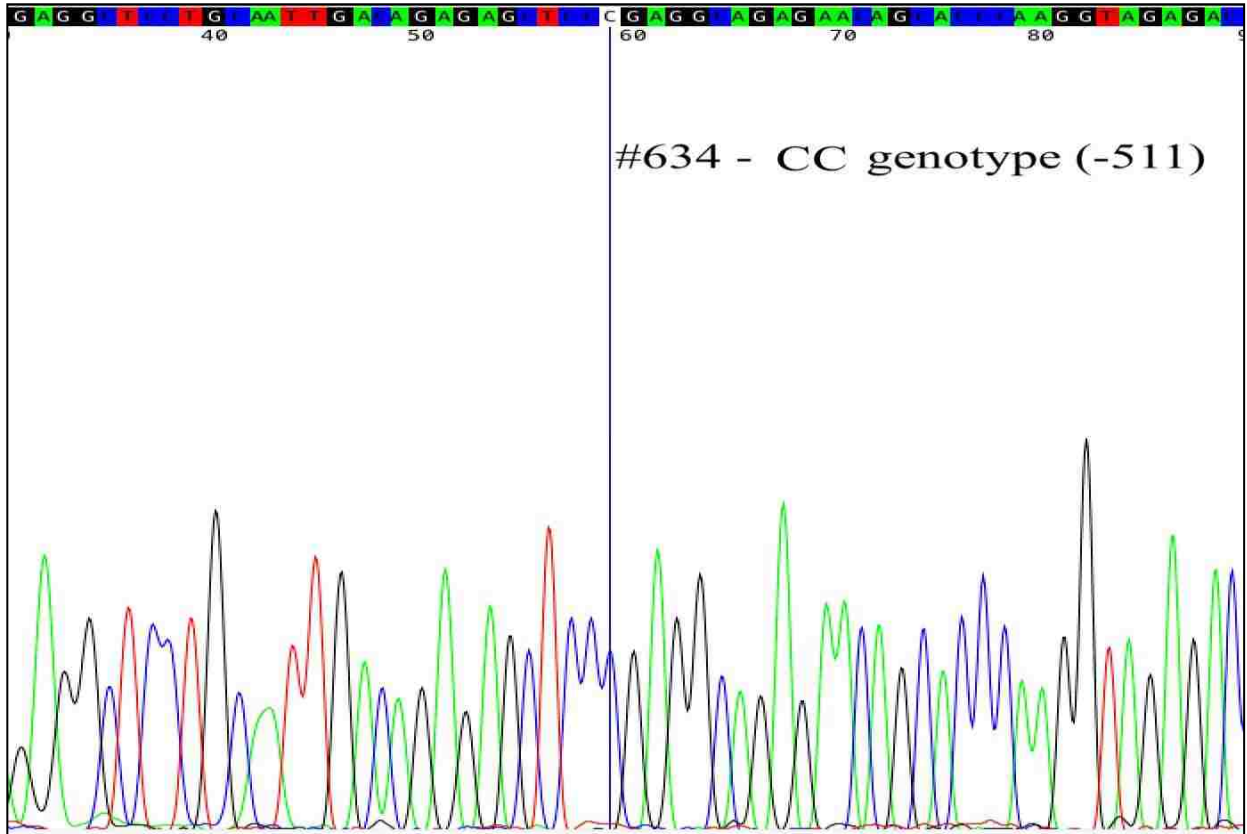
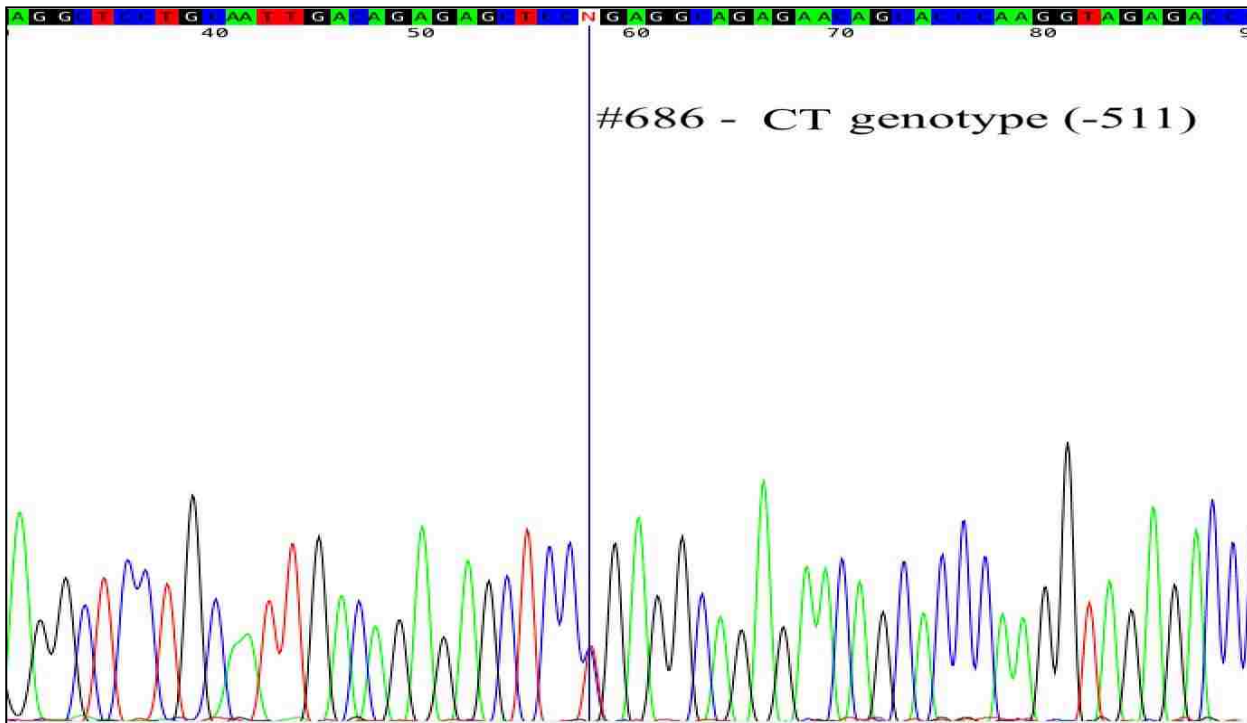


Figure 14 DNA sequence confirming TT genotype, patient #237 (red peak)



*Figure. 15 DNA sequence confirming CC genotype, patient #634(blue peak)*

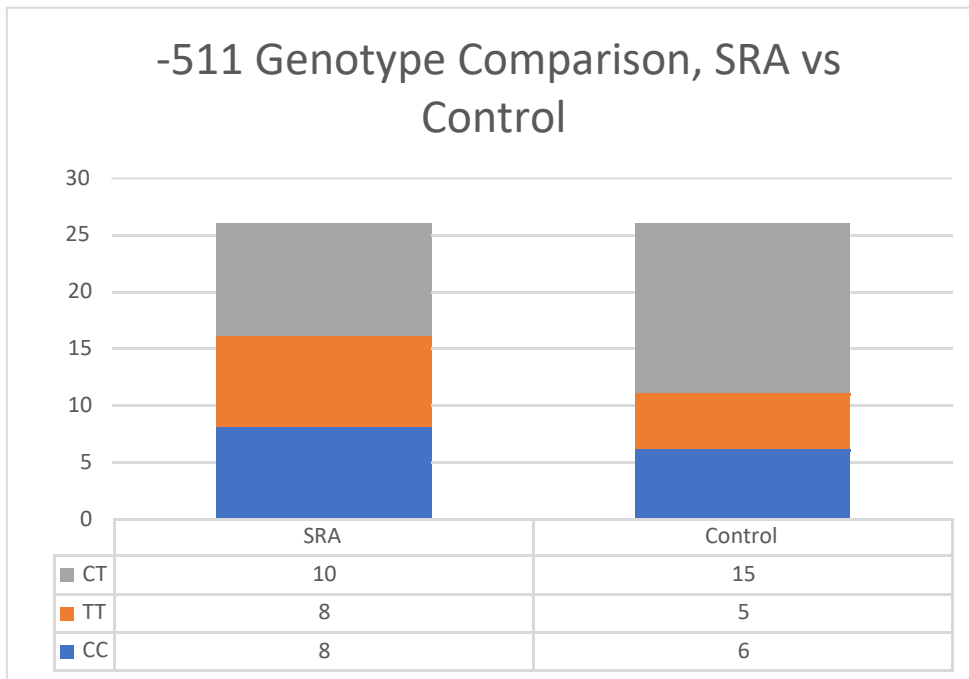


*Figure. 16 DNA sequence confirming CT genotype, patient #686 (red and blue peak)*

27% of the total patients exhibited the CC genotype at -511, 25% of the patients exhibited the TT genotype and 48% patients exhibited the CT genotype (Table 11). This difference was not statistically significant (n = 52) (p = 0.9). In the SRA group, 31% of the patients exhibited the CC genotype at -511, 31% of the patients exhibited the TT genotype and 38% of the patients exhibited the CT genotype (Fig. 17). There was no statistical significance between the genotypes in the SRA group (n=26) (p = 0.5). In the control group 23% of the patients exhibited the CC genotype, 19% of the patients exhibited the TT genotype and 58% of the patients exhibited the CT genotype (Fig. 17). This difference was not statistically significant (n=26) (p = 0.7).

**Table 11. IL-1 $\beta$  -511 Genotype distribution in the total sample, n = 52**

CC	14
TT	13
CT	25

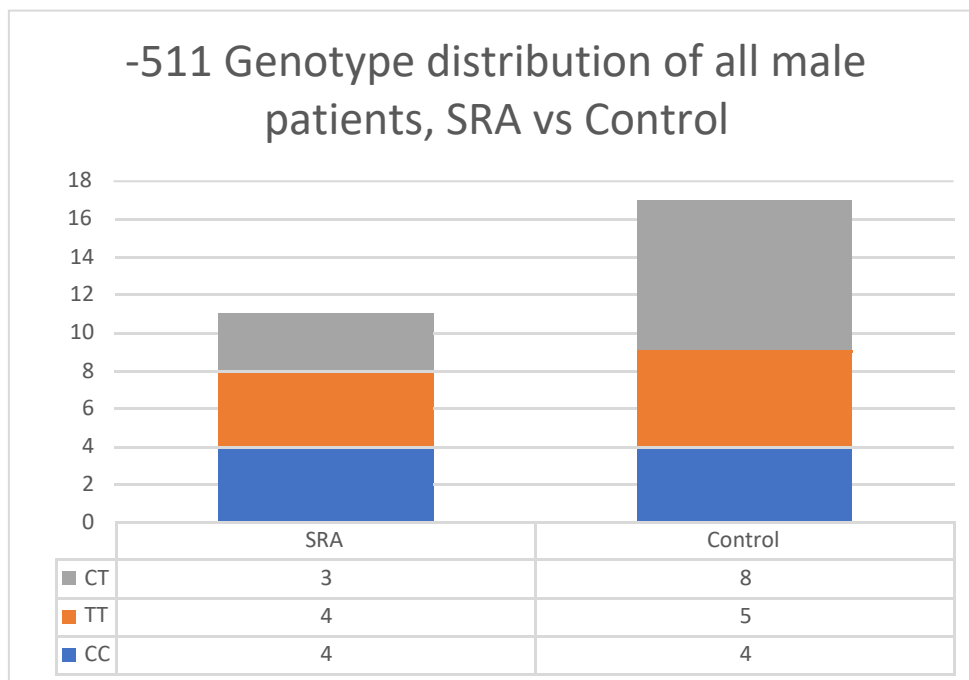


**Figure 17. Genotype Comparison, SRA vs Control**

Among all of the male patients in the study, 29% exhibited the CC genotype at -511, 32% exhibited the TT genotype and 39% exhibited the CT genotype (Table 12). This difference was not statistically significant (n=28) (p = 0.5). In the SRA group, 37% of males exhibited the CC genotype at -511, 36% exhibited the TT genotype and 27% exhibited the CT genotype (Fig. 18). This difference was not statistically significant (n=11) (p = 0.3). In the control group, 24% of the male patients exhibited the CC genotype at -511, 29% exhibited the TT genotype and 47% of the patients exhibited the CT genotype (Fig. 18). This difference was not statistically significant (n=17) (p=0.9).

**Table 12. *IL-1 $\beta$  -511 Genotype distribution in the total male sample, n = 28***

IL-1 $\beta$ -511 Genotype in total male sample, n = 28	
CC	8
TT	9
CT	11

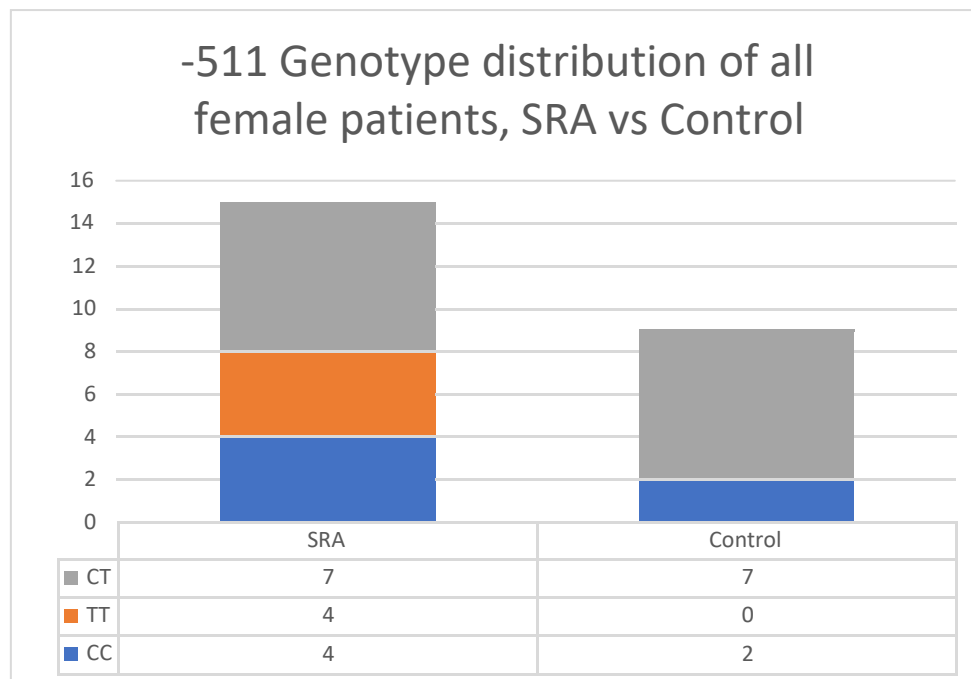


**Figure 18. -511 Genotype distribution of all male patients, SRA vs Control**

Among all of the female patients in the study, 25% exhibited the CC genotype at -511, 17% exhibited the TT genotype and 58% exhibited the CT genotype (Table 13). This difference was not statistically significant (n=24) (p = 0.6). In the SRA group, 27% of the females exhibited the CC genotype at -511, 27% exhibited the TT genotype and 46% exhibited the CT genotype (Fig. 19). There was no statistically significant difference in this group (n=15) (p =0.9). In the control group, 22% of the female patients exhibited the CC genotype and 78% exhibited the CT genotype (Fig. 19). This difference was not statistically significant (n=9) (p = 0.1).

**Table 13. IL-1 $\beta$  +511 Genotype distribution in the total female sample, n = 24**

CC	6
TT	4
CT	14

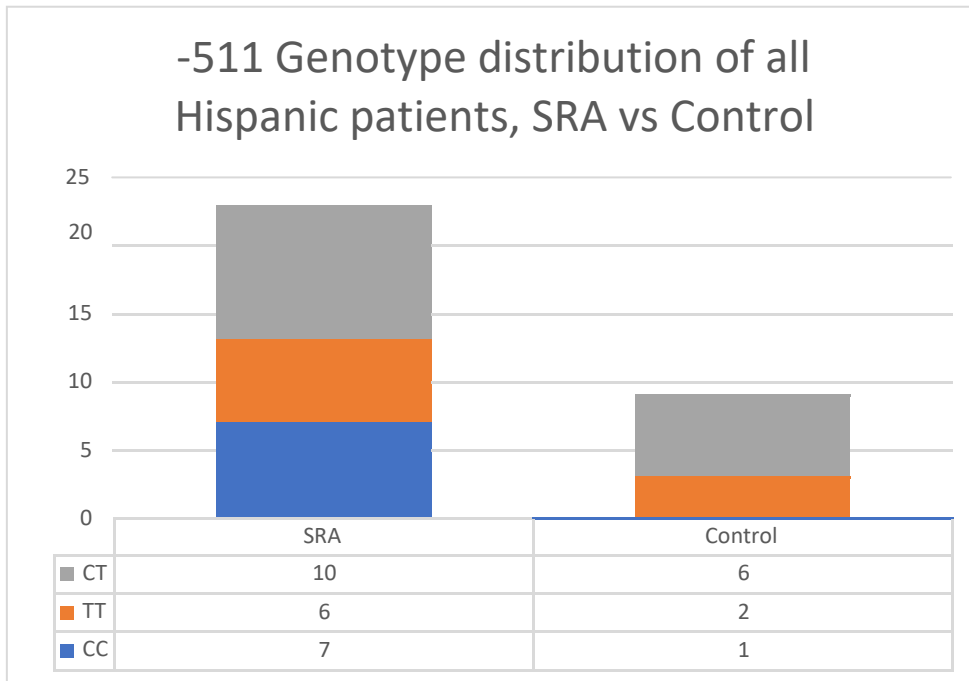


**Figure 19. -511 Genotype distribution of all female patients, SRA vs Control**

For the -511 site, there was no statistical difference found among the total patients of Hispanic origin ( $p = 0.9$ ). 25% of the patients exhibited the CC genotype, 25% exhibited the TT genotype and 50% the CT genotype ( $n=32$ ) (Table 14). 26% of Hispanic patients in the SRA group exhibited the CC genotype, 30% of the patients exhibited the TT genotype and 44% of patients exhibited the CT genotype (Fig. 20). This difference was not statistically significant ( $n=23$ ) ( $p=0.7$ ). 11% of the Hispanic patients in the control group exhibited the CC genotype, 22% exhibited the TT genotype and 67% exhibited the CT genotype (Fig. 20). This difference was not statistically significant ( $n=9$ ) ( $p = 0.5$ )

**Table 14. IL-1 $\beta$  -511 Genotype distribution in the total Hispanic sample, n = 32**

CC	8
TT	8
CT	16



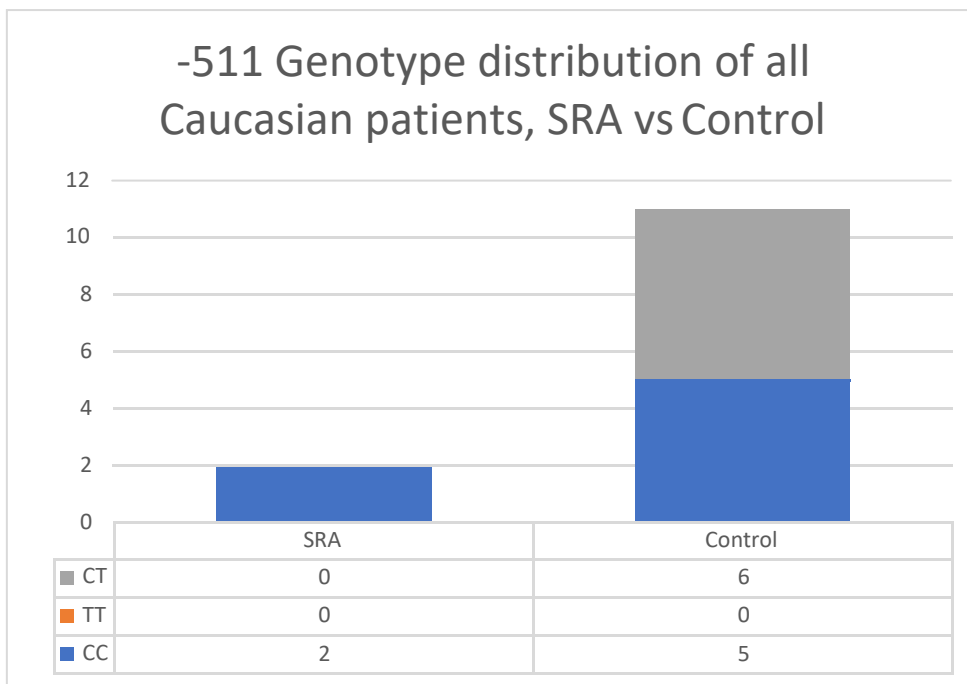
**Figure 20. -511 Genotype distribution of all Hispanic patients, SRA vs Control**

Among all of the Caucasian patients, 54% exhibited the CC genotype at the -511 site, 46% exhibited the CT genotype and none showed the presence of the TT genotype (Table 15). This difference was statistically significant (n=13) (p = 0.02). Within the SRA group, 100% of the Caucasian patients exhibited the CC genotype (Fig. 21). This difference was statistically significant (n=2) (p = 0.04). In the control group, 45% of the Caucasian patients exhibited the

CC genotype and 55% exhibited the CT genotype (Fig. 21). This difference was not statistically significant (n=13) (p=0.09).

**Table 15. IL-1 $\beta$  -511 Genotype distribution in the total Caucasian sample, n = 13**

CC	7
TT	0
CT	6



**Figure 21. -511 Genotype distribution of all Caucasian patients, SRA vs Control**

75% of all of the Asian patients exhibited the TT genotype at -511, while 25% exhibited the CT genotype. This difference was not statistically significant (n=4) (p = 0.06) (Table 16).

67% of all the African-American patients exhibited the CT genotype and 33% exhibited the TT genotype. This difference was not statistically significant (n=3) (p = 0.6) (Table 17).



**Table 16. IL-1 $\beta$  -511 Genotype distribution in the total Asian sample, n = 4**

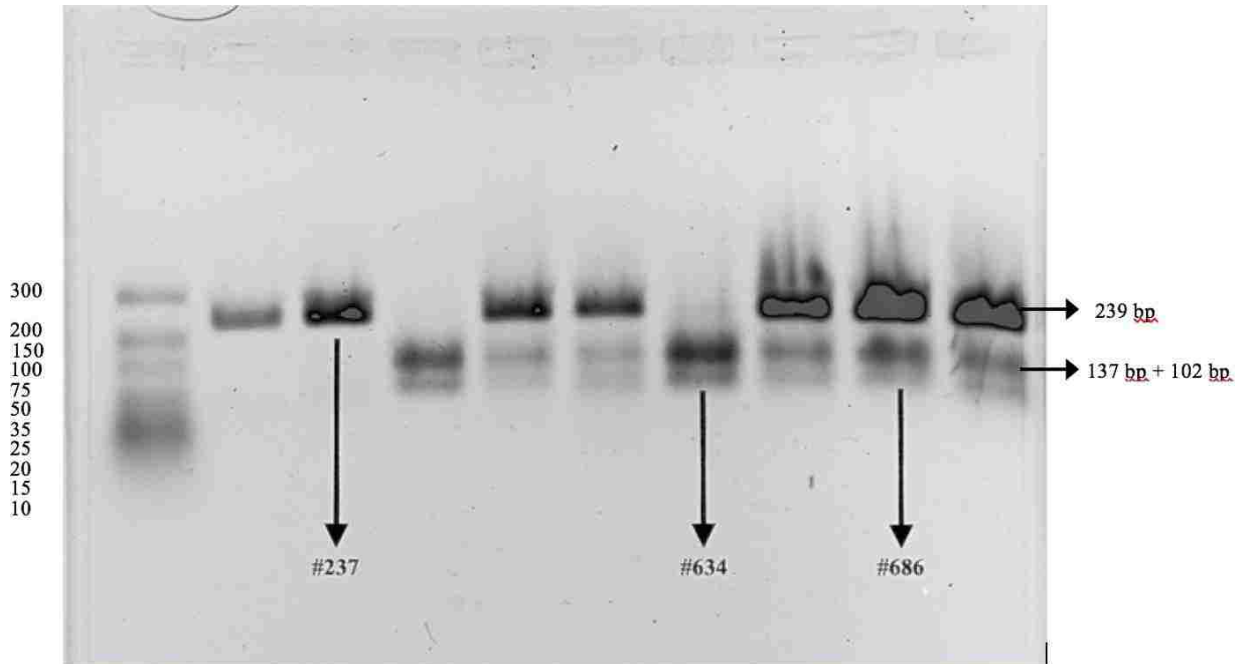
IL-1 $\beta$ -511 Genotype in total Asian sample, n = 4	
CC	0
TT	3
CT	1

**Table 17. IL-1 $\beta$  -511 Genotype distribution in the total African-American sample, n = 3**

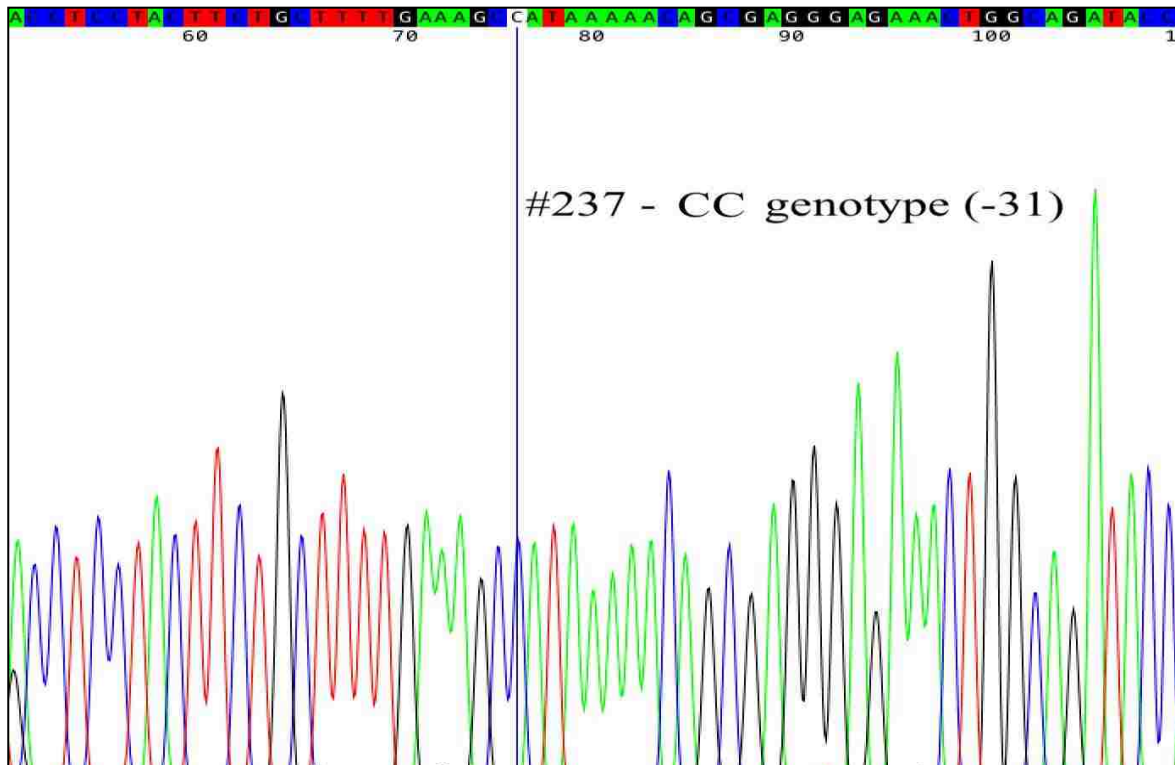
IL-1 $\beta$ -511 Genotype in total African-American sample, n = 3	
CC	0
TT	1
CT	2

#### **5.4 IL-1 $\beta$ -31 Polymorphism**

The results from the DNA sequencing were 100% concordant with our analysis using restriction digest and agarose gel electrophoresis for the -31 polymorphism. Patient #237 exhibited the CC genotype, patient #634 exhibited TT genotype and patient #686 exhibited CT genotype (Fig. 22). These findings were confirmed with DNA sequencing (Fig. 23, 24 and 25).



**Figure 22. Band pattern for -31, patient #237, 634 and 686**



**Figure. 23 DNA sequence confirming CC genotype, patient #237(blue peak)**

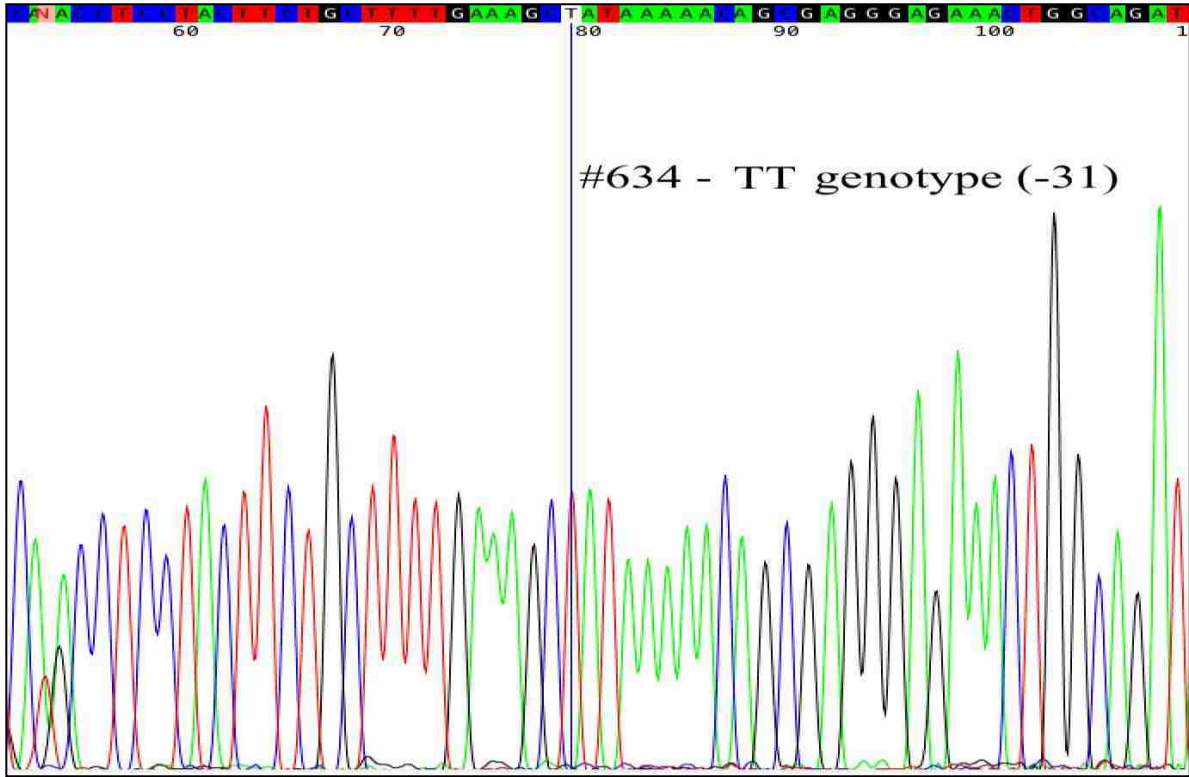


Figure. 24 DNA sequence confirming TT genotype, patient # 634(red peak)

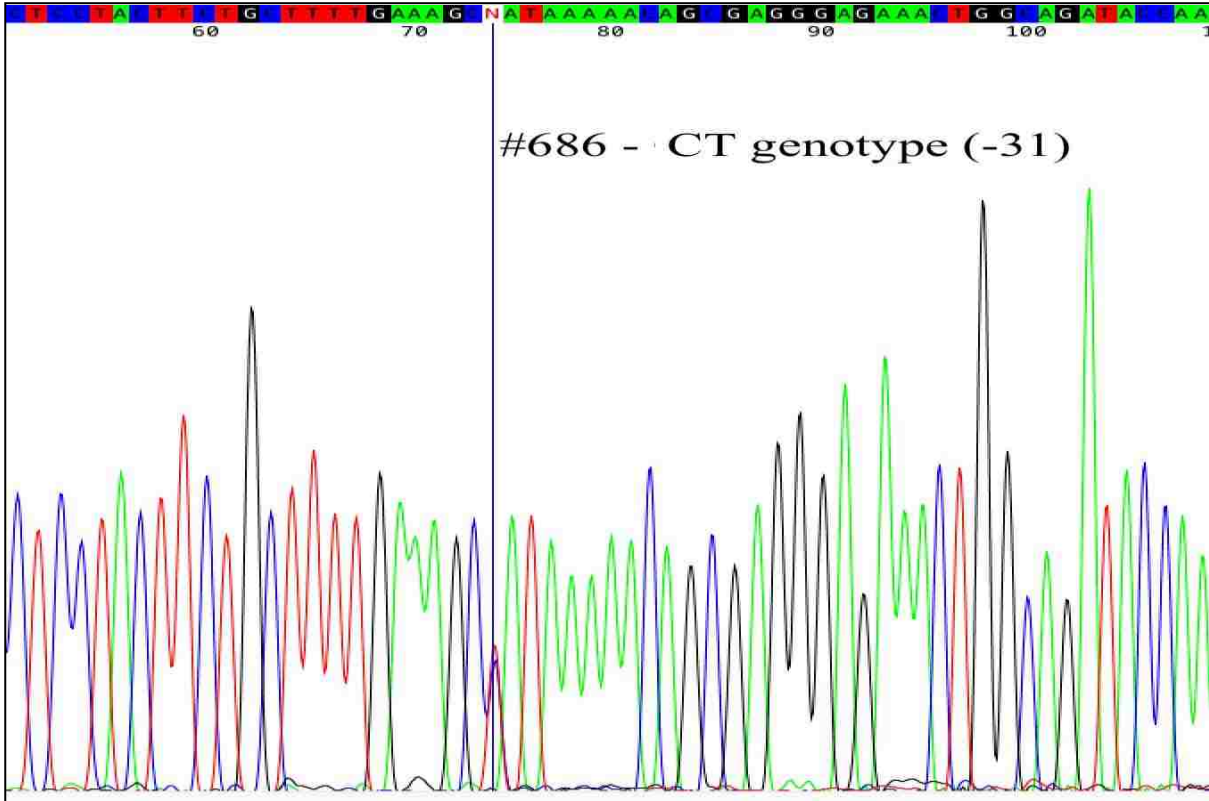
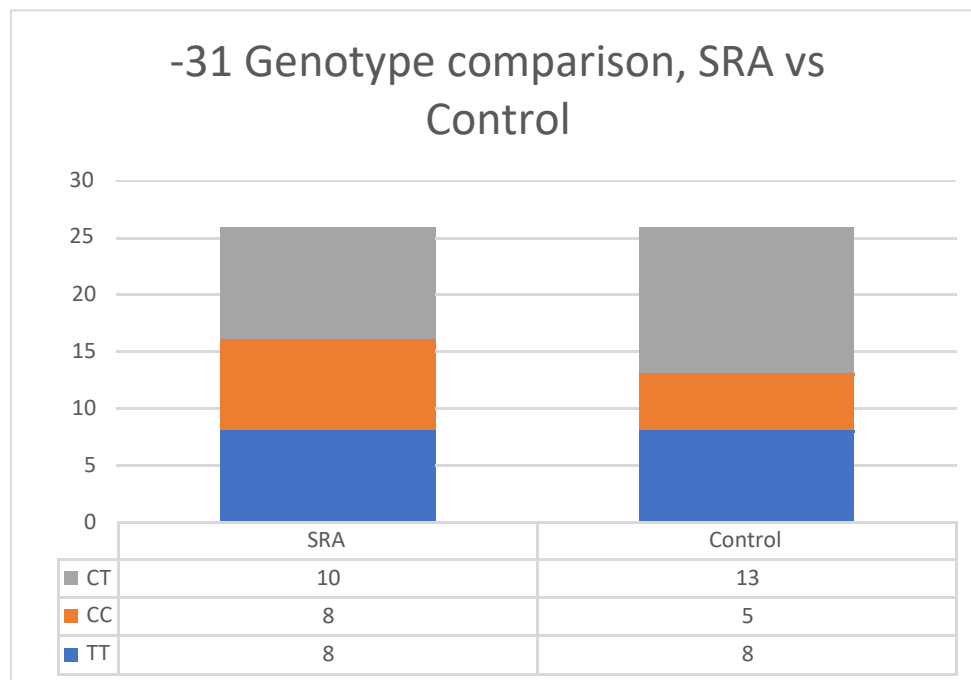


Figure. 25 DNA sequence confirming CT genotype, patient #686 (red and blue peak)

Following analysis of the -31 polymorphism, 31% of the total patients in the study exhibited the TT genotype, 25% of all patients exhibited the CC genotype and 44% of the total patients in the study exhibited the CT genotype (Table 18). This difference was not statistically significant (n=52) (p = 0.5). In the SRA group, 31% of the patients exhibited the TT genotype, 31% exhibited the CC genotype and 38% exhibited the CT genotype at the -31 site (Fig. 26). There was no statistical significant difference between the genotypes in the SRA group (n=26) (p = 0.5). In the control group, 31% of the patients exhibited the TT genotype, 19% exhibited the CC genotype, while 50% of patients exhibited the CT genotype at the -31 site (Fig. 26). This difference was not statistically significant (n=26) (p = 0.7).

**Table 18. *IL-1 $\beta$  -31 Genotype distribution in the total sample, n = 52***

TT	16
CC	13
CT	23

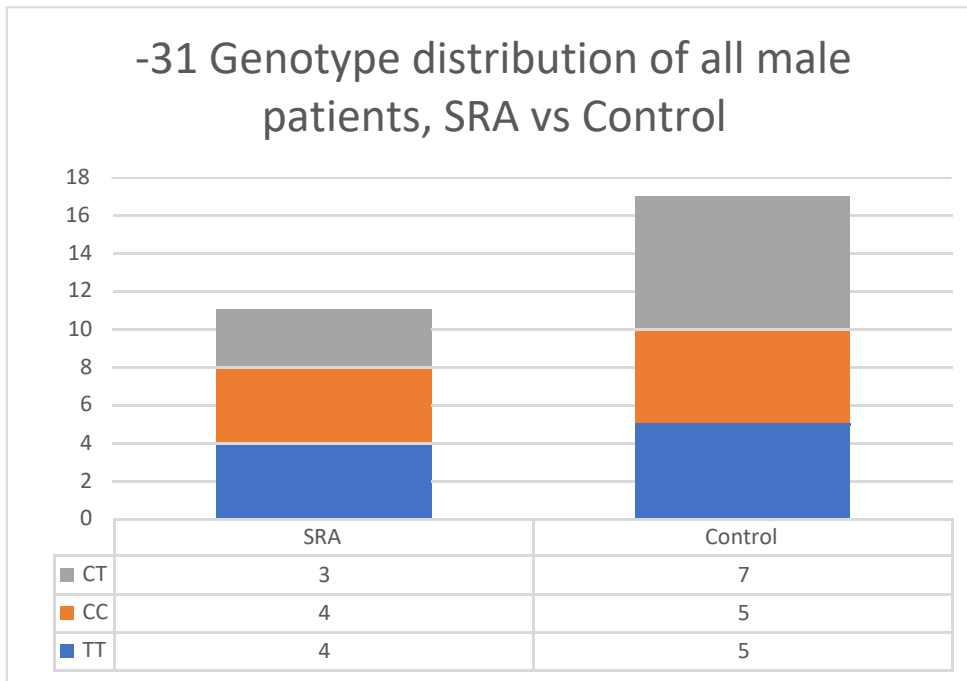


**Figure 26. -31 Genotype comparison, SRA vs Control**

Among all of the male patients in the study, 32% exhibited the TT genotype, 32% exhibited the CC genotype and 36% of the patients exhibited the CT genotype at the -31 site (Table. 19). This difference was not statistically significant (n=28) (p = 0.3). In the SRA group, 37% of the males exhibited the TT genotype, 36% exhibited the CC genotype and 27% exhibited the CT genotype at the -31 site (Fig. 26). This difference was not statistically significant (n=11) (p = 0.3). In the control group, 30% of males exhibited the TT genotype, 29% exhibited the CC genotype and 41% exhibited the CT genotype at the -31 site (Fig. 26). This difference was not statistically significant (n=11) (p = 0.7).

**Table 19. IL-1 $\beta$  -31 Genotype distribution in the total male sample, n = 28**

TT	9
CC	9
CT	11



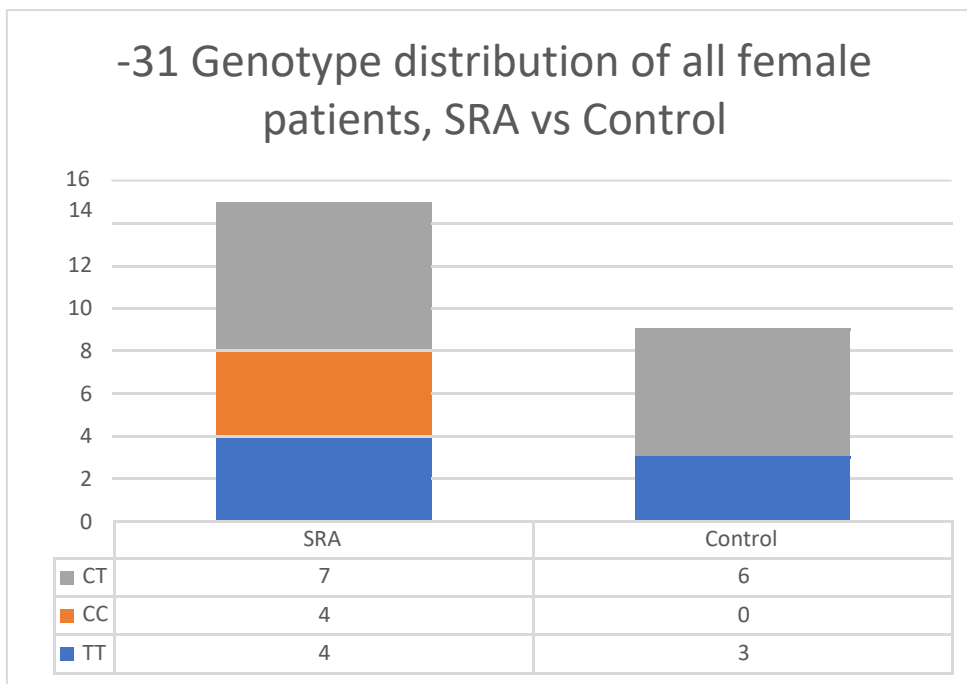
**Figure. 27 -31 Genotype distribution of all male patients, SRA vs Control**

Among all of the female patients in the study, 29% exhibited the TT genotype, 17% exhibited the CC genotype and 54% exhibited the CT genotype (Table. 20). This difference was not statistically significant (n=24) (p = 0.6). In the SRA group, 27% of females exhibited the TT genotype, 27% exhibited the CC genotype and 46% exhibited the CT genotype (Fig. 28). There was no statistically significant difference noted in this group (n=15) (p =0.9). In the control

group, 33% of females exhibited the TT genotype and 67% exhibited the CT genotype at the -31 site (Fig. 28). This difference was not statistically significant (n=9) (p = 0.2).

**Table 20. IL-1 $\beta$  -31 Genotype distribution in the total female sample, n = 24**

TT	7
CC	4
CT	13



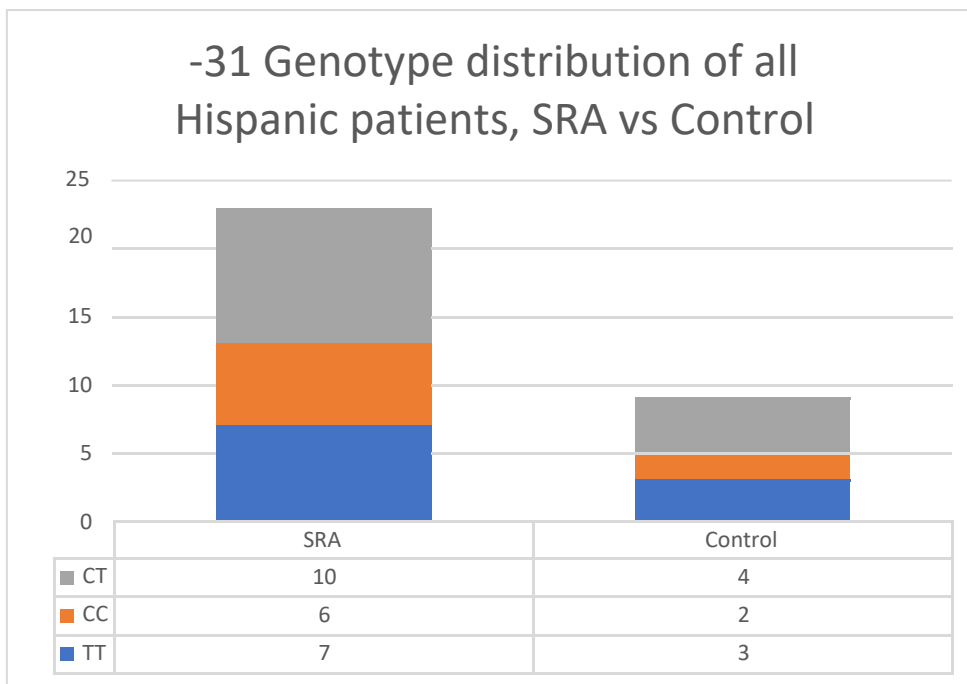
**Figure 28. -31 Genotype distribution of all female patients, SRA vs Control**

Among all of the Hispanic patients, there was no statistical significance (p = 0.6) with 30% of the total Hispanic patients exhibiting the TT genotype, 27% exhibiting the CC genotype and 43% exhibiting the CT genotype (n=32) (Table 21). In the SRA group, 26% of the Hispanic patients exhibited the TT genotype, 30% exhibited the CC genotype and 44% of the patients exhibited the CT genotype at the -31 site (Fig. 29). This difference was not statistically significant (n=23) (p=0.7). In the control group, 33% of the Hispanic patients exhibited the TT

genotype, 22% exhibited the CC genotype and 45% exhibited the CT genotype at the -31 site (Fig. 29). This difference was not statistically significant (n=9) (p = 0.8)

**Table 21. IL-1 $\beta$  -31 Genotype distribution in the total Hispanic sample, n = 32**

TT	10
CC	8
CT	14



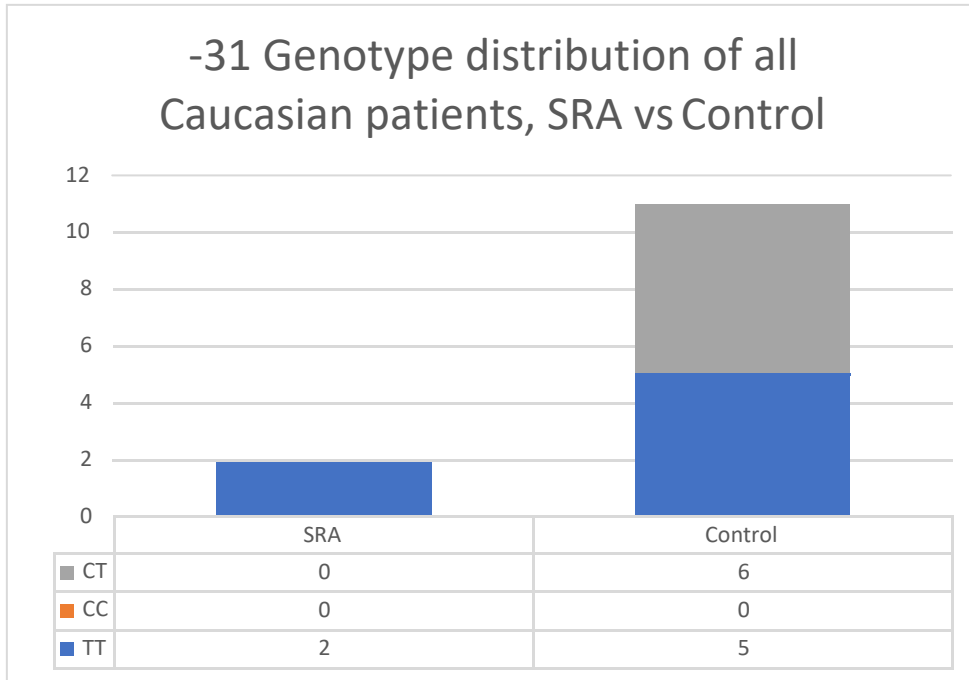
**Figure 29. -31 Genotype distribution of all Hispanic patients, SRA vs Control**

Among all Caucasian patients in the study, 54% exhibited the TT genotype and 46% exhibited the CT genotype at the -31 site (Table 22). This difference was statistically significant (n=13) (p = 0.02). In the SRA group, 100% of the Caucasian patients exhibited the TT genotype (Fig. 30). This difference was statistically significant (n=2) (p = 0.04). In the control group, 45% of the Caucasian patients exhibited the TT genotype and 55% exhibited the CT genotype (Fig. 30). This difference was not statistically significant (n=9) (p=0.09).



**Table 22. IL-1 $\beta$  -31 Genotype distribution in the total Caucasian sample, n = 13**

TT	7
CC	0
CT	6



**Figure. 30 -31 Genotype distribution of all Caucasian patients, SRA vs Control**

Among all Asian patients in the study, 75% exhibited the CC genotype and 25% exhibited the CT genotype at the -31 site (Table 23). This difference was not statistically significant (n=4) (p = 0.06). Among all of the African-American patients, 67% exhibited the CT genotype and 33% exhibited the TT genotype. This difference was not statistically significant (n=3) (p = 0.6) (Table 24).

**Table 23. *IL-1 $\beta$ -31* Genotype distribution in the total Asian sample, n = 4**

IL-1 $\beta$ -31 Genotype in total Asian sample, n = 4	
TT	0
CC	3
CT	1

**Table 24. *IL-1 $\beta$ -31* Genotype distribution in the total African-American sample, n = 3**

IL-1 $\beta$ -31 Genotype in total African-American sample, n = 3	
CC	0
TT	1
CT	2

## Chapter 5, Discussion:

Root resorption is often an unavoidable consequence of orthodontic treatment. Research has suggested that heavy forces and prolonged duration of treatment can lead to orthodontically induced root resorption. Abnormal root morphology can also lead to external root resorption after orthodontic treatment (Sameshima G T, 2004). Short root anomaly was first described by Lind in 1972. He described SRA as plump roots that are abnormally short and usually affecting maxillary central incisors, maxillary premolars and mandibular premolars (LIND, 1972). SRA can go unidentified because there are no clinical symptoms of this condition and since the frequency of SRA is low in Caucasian populations, this condition may not be prevalent in Caucasian dominated regions. Finite element analysis investigating the stress distribution at the root in different root shapes has shown increased stress loading in short and bent root models (Oyama K, 2007). From Oyama's finite element model analysis, it can be concluded that patients with SRA may be more prone to root resorption during orthodontic treatment as compared to patients who exhibit normal root length (Oyama K, 2007).

Al-Qawasmi was the first to identify an association between I IL-1 $\beta$  polymorphisms and root resorption during orthodontic treatment. They specifically described the CC genotype of the IL-1 $\beta$  polymorphism at +3954 and its association with decreased IL-1 $\beta$  production. They hypothesized that decreased IL-1 $\beta$  production leads to impaired alveolar bone remodeling resulting in prolonged stress on the root surface. This in turn leads to increased risk of root resorption during orthodontic treatment. This theory contradicts other hypotheses that state that increased root resorption can be associated with increased IL-1 $\beta$  expression, which is also associated with an increase in alveolar bone remodeling (R. A. Al-Qawasmi, 2003; R. a Al-Qawasmi, 2004). From the above-mentioned studies, it can be noted that a patient presenting

with SRA and exhibiting the IL-1 $\beta$  CC genotype at +3954 would be at higher risk for root resorption during orthodontic treatment (R. A. Al-Qawasmi, 2003; Oyama K, 2007).

IL-1 $\beta$  polymorphisms at -511 and -31 have also been associated with periodontal disease and several other chronic inflammatory diseases (Amirisetty, 2015). Some studies have reported an increase in the lipopolysaccharide induced IL-1 $\beta$  expression associated with the IL-1 $\beta$  polymorphisms at -511 and -31 (Hall SK, 2004).

This study was the first of its kind to explore the relationship between SRA and IL-1 $\beta$  polymorphisms at 3 distinct sites +3954, -511 and -31. Also, this was one of the first studies to explore the genetic factors that may lead to root resorption during orthodontic treatment among different ethnicities.

Compared to the previous studies conducted on short root anomaly using peri-apical radiographs or panoramic radiographs, this study incorporated the use of CBCT. CBCT was helpful in establishing a more accurate diagnosis of SRA. Proclined incisors can often be misdiagnosed as having short roots on panoramic radiographs. In our study, during initial patient selection we noticed that some of the patients who exhibited short roots in panoramic radiographs presented with no root abnormalities upon CBCT review. Cephalometric analysis often revealed proclination of these teeth. This indicates that CBCT is an important tool to accurately diagnose the presence of SRA.

Al-Qawasmi used panoramic radiographs to evaluate root resorption, Lages utilized peri-apical radiographs in their study (R. A. Al-Qawasmi, 2003; Bastos Lages, 2009). Panoramic radiographs, lateral cephalometric and peri-apical radiographs provide us with a 2-D image of a 3-D structure. There are limitations with these modalities to accurately diagnose the presence of short roots. Cephalometric radiographs may not be able to detect the presence of short roots

accurately due to overlap. In peri-apical radiographs the root length can be elongated or shortened depending on the angulation of the X-ray and panoramic radiographs may show distortion depending on where the structure falls in relation to the focal trough. Anterior teeth can also appear to have short roots in panoramic radiographs depending on their angulation in the alveolar housing. Our study utilized CBCT to evaluate the presence of short roots, the roots can be visualized in 3-D and any abnormal root morphology can be visualized accurately.

Lind wrote that the teeth primarily affected by SRA are maxillary incisors, maxillary premolars and mandibular premolars and rarely other teeth. In our study, we also found that only maxillary incisors, maxillary premolars and mandibular premolars were affected by SRA. This finding was similar to the one mentioned in the studies by Lind and Puranik (LIND, 1972; Puranik, 2015). As described by Puranik, SRA occurs frequently in individuals of Hispanic origin (Puranik, 2015). In our study 88% of patients in the SRA group were of Hispanic origin while only 33% of patients in the control group were of Hispanic origin. The frequency of SRA is generally low in the Caucasian population. Only 8% of patients in the SRA group were of Caucasian origin and 41% of patients in normal roots were of Caucasian origin. All the patients in the control group were randomly selected to avoid any ethnic bias. These finding confirms that SRA is not a common finding in individuals of Caucasian origin but occurs frequently in Hispanic populations. SRA has been reported to be 3 times more common in females as compared to males (LIND, 1972). Although the prevalence was not the same as reported by Lind, 58% of the patients in the SRA group were females as compared to 35% in the control group. These findings suggest a higher prevalence of SRA in females as compared to males.

No significant differences were seen in the different genotypes at the -511 and -31 sites between the SRA and control groups. Neither males nor females exhibited any increased

incidence of any genotype at -511 and -31 sites. No difference was noted among patients of Hispanic, Asian or African-American origin at both the -511 and -31 sites. No difference was noted between these ethnicities among SRA and the control group. Caucasian patients showed a significantly higher TT genotype compared to the CC or CT genotype for IL-1 $\beta$  at -31 and a higher CC genotype at -511 in the SRA group. In the control group, there was no significant difference between the genotypes for both the -511 and -31 sites. This data may not be the most meaningful since the sample size of Caucasian patients in the SRA group was very low (n=2).

No association was seen with the IL-1 $\beta$  -511 and -31 polymorphisms and the presence of SRA. Both -511 and -31 are located in the promoter region and show high linkage disequilibrium. In our study we noticed a similar finding, with polymorphisms at -511 and -31 almost always exhibiting linkage disequilibrium. The T allele at -511 and the C allele at -31 have been associated with increases in IL-1 $\beta$  production. In our study, we did not find any significant difference in the presence of different genotypes at the -511 and -31 sites.

In the SRA group, all patients exhibited the CC genotype at +3954. Reports have suggested that Hispanic patients may be at higher risk for root resorption during orthodontic treatment (Sameshima GT, 2001). This study found a significant occurrence of the CC genotype in patients of Hispanic origin. The CC genotype was prevalent in both the SRA and the control group which may suggest the predisposition of individuals of Hispanic origin towards orthodontically induced root resorption. It can be concluded from this study that a patient of Hispanic origin exhibiting SRA and exhibiting the CC genotype (IL-1 $\beta$  +3954 polymorphism) may present a higher risk of root resorption during orthodontic treatment and care should be taken during treatment planning.

100% of the Caucasian patients in the SRA group exhibited the CC genotype (IL-1 $\beta$  +3954) (n=2). Caucasian patients did not exhibit any significant presence of any genotype, suggesting that Caucasian patients may be at lower risk to root resorption as compared to Hispanic patients

All the patients of Asian origin also showed presence of CC genotype though no significant difference was found in the SRA group. There was no African-American patient in the SRA group. African-American patients in the control group did not show any significant difference in the genotype present. The sample size of Asian and African-American patients was too low to derive any conclusion.

If Hispanic patients do exhibit increased prevalence of the CC genotype at IL-1 $\beta$  +3954, this might explain the increased presence of the CC genotype in the control group in our study and the higher number of the CC genotype in the total sample, since 61% of patients were of Hispanic origin. This study was the first to evaluate the presence of a genetic marker that may be a risk factor for orthodontically induced root resorption among different ethnicities.

IL-1 $\beta$  (+3954) is located within exon 5 and this exon is in the coding region of the gene. Although the polymorphism does not result in a missense mutation, it might influence nuclear RNA stability, mRNA splicing or levels of mRNA expression.

It has been reported that there is 4-fold more IL-1 $\beta$  production in individuals who are homozygous for IL-1 $\beta$  +3954 TT genotype and 2-fold increase in heterozygous CT individuals (Pociot F, 1992). Al-Qawasmi had suggested that the IL-1 $\beta$  polymorphism at +3954, especially the CC genotype, may lead to decreased production of IL-1 $\beta$ . A study of IL-1 $\beta$  knockout mice does support the theory that a decreased level of IL-1 $\beta$  results in increased root resorption (R. A. Al-Qawasmi, 2003; R. a Al-Qawasmi, 2004). Orthodontic tooth movement happens by

resorption of bone on the pressure side and deposition of bone on tension side. IL-1 $\beta$  is responsible for recruitment of osteoclasts and bone resorption. It is plausible that low levels of IL-1 $\beta$  may lead to decreased remodeling of the bone, leading to prolonged stress concentration on the roots during orthodontic treatment. This prolonged stress can lead to increased root resorption under dynamic forces applied during orthodontic treatment (R. A. Al-Qawasmi, 2003; R. a Al-Qawasmi, 2004).

This study suggests that SRA may have a racial predilection, with Hispanic groups more prone to SRA. Also, it indicates that the +3954 CC IL-1 $\beta$  genotype may be a risk factor for root resorption during orthodontic treatment. This allelic variation may be more prevalent in Hispanic groups. Patients of Hispanic origin with a radiographic indication of SRA and the presence of the IL-1 $\beta$  (+3954) CC genotype may be at higher risk than individuals exhibiting SRA with the TT or CT genotype. These findings support the multifactorial nature of root resorption; a patient may present with one of the risk factors and yet not exhibit resorption of roots during orthodontic treatment. Long duration of treatment, extractions to close a large overjet or excessive torque of incisors can put a predisposed patient at risk for significant root resorption. These treatment mechanics combined with other factors like a unique genetic polymorphism or indications of SRA will put the patient at higher risk for root resorption. Diagnosing these risk factors, including single nucleotide polymorphisms, before the start of treatment is important when treatment planning for these patients.

Evaluating genetic risk factors for root resorption prior to orthodontic treatment could serve as an important diagnostic tool. Buccal swabs or even saliva samples can be taken chair side prior to the start of the treatment. DNA can be isolated and analyzed for any genetic marker, including the IL-1 $\beta$  gene polymorphism at +3954, that may lead to increase susceptibility to root



resorption during treatment. Diagnostic aids like CBCT and genetic analysis using a simple buccal swab and laboratory procedure may be able to help identify the patients at high risk for root resorption and these patients could be informed about their increased risk and treatment altered accordingly.

## Chapter 6, Conclusions:

- 1) All of the patients in the SRA group exhibited the CC genotype for the IL-1 $\beta$  gene polymorphism at +3954. This genotype has been implicated in causing increased root resorption by possibly decreasing IL-1 $\beta$  production and increasing the stress on root apices during orthodontic tooth movement.
- 2) In our study, Hispanic and Female patients showed more radiographic evidence of SRA.
- 3) Hispanic patients showed a higher prevalence of the CC genotype at +3954. This observation combined with the observation of a higher prevalence of Hispanic patients presenting with SRA suggests that Hispanic patients may be at a higher risk for orthodontically induced root resorption due to this genotype.
- 4) Caucasian patients did not show any significant difference between the different IL-1 $\beta$  +3954 genotypes. This suggests that Caucasian patients may be less prone to root resorption as compared to patients of Hispanic origin.
- 5) All of the Asian patients exhibited the CC genotype at IL-1 $\beta$  +3954 but the sample size was too small to derive any statistically significant conclusion.
- 6) No African-American patients were identified that exhibited SRA during the period of patient recruitment.
- 7) There was no correlation evident between the IL-1 $\beta$  gene polymorphisms at -511 or -31 with SRA or normal roots.
- 8) This study shows that orthodontically induced root resorption is multifactorial and the presence of one risk factor does not mean that a patient will experience root resorption during orthodontic treatment.

- 9) Multiple diagnostic measures are needed to evaluate the risk factors prior to orthodontic treatment.
- 10) CBCT can help diagnose the presence of abnormal root morphology accurately.
- 11) DNA analysis using cheek swabs may serve as a valuable diagnostic aid to evaluate a patient's genetic predisposition towards root resorption. This type of analysis should be a part of normal orthodontic records to evaluate a patient's risk factors and aid in formulation of a treatment plan accordingly.

## Chapter 7, Future studies

- 1) A larger sample size of patients with SRA and normal roots may be helpful in providing more conclusive data.
- 2) This study can be expanded to evaluate the prevalence of polymorphisms between different ethnicities. This would require equal distribution of patients from different ethnicities.
- 3) In our study, we chose to de-identify all patients after collecting their DNA. Future studies can be designed to identify patients who exhibit the IL-1 $\beta$  +3954 polymorphism at the start of treatment. These patients can then be followed with regular radiographs and CBCT scans to evaluate root resorption during the course of orthodontic treatment. This would be especially valuable for patients exhibiting CC genotype.

## References:

- 1) Maria, R. M. V. K. S. (2010). Internal resorption: A review & case report. *Endodontology*, 22(1), 100–108.
- 2) *American Association of Endodontics*, “Glossary of endodontic terms.” (2014).
- 3) Kuo T-C, Cheng Y-A, L. C.-P. (2005). Clinical management of severe external root resorption. *Chin Dent J*, 24(1), 59–64.
- 4) Proffit, W. R. F. H. W. S. D. M. (2013). Contemporary Orthodontics. In *Contemporary Orthodontics* (5th ed., p. 7,8).
- 5) Brezniak, N., & Wasserstein, A. (2009). Orthodontically Induced Inflammatory Root Resorption. Part I: The Basic Science Aspects. Retrieved from <http://www.angle.org/doi/full/10.1043/0003-3219%25282002%2529072%253C0175%253A0IIRRP%253E2.0.CO%253B2>
- 6) Ando, S., Kiyokawa, K., Nakashima, T., Shinbo, K., Sanka, Y., Oshima, S. & Aizawa, K.: Studies on the consecutive survey of succedaneous and permanent dentition in the Japanese children. Part 4. Behavior of short rooted teeth in the upper bilateral central incisors. *J. Nikon, Univ. Sch. Dent.* 1967: 9: 67-80
- 7) HRDLICKA, A.: Contribution to the anthropology of Central and Smith Sound Eskimos. *Anthropology. Pap. Amer. Mus. Nat. Hist.* 1910: 5, Part 2: 177-285
- 8) Pedersen, P. O.: The East Greenland Eskimo dentition. *Meddelelser om Gronland* 142; Copenhagen 1949.
- 9) Tratman, E. K.: A comparison of the teeth of people of Indo-European racial stock with the mongoloid racial stock. *Dent. Rec.* 1950: 70: 31-53 and 63-88.
- 10) Pazzini, C. A., Marques, L. S., Generoso, R., & Gerais, M. (2010). Short-root anomaly in an orthodontic patient. *American Journal of Orthodontics and Dentofacial Orthopedics*, 138(3), 346–348. <http://doi.org/10.1016/j.ajodo.2008.08.037>
- 11) Weltman B, Vig KWL, Fields HW, Shanker S, K. E. (2010). Root resorption associated with orthodontic tooth movement: a systematic review. *Am J Orthod Dentofacial Orthop*, 137, 462–476.
- 12) Sci, E. J. O., Apajalahti, S., Arte, S., & Pirinen, S. (1999). Short root anomaly in families and its association with other dental anomalies. *European Journal of Oral Sciences*, 107, 97–101.
- 13) Apajalahti, S., Hölttä, P., Turtola, L., Pirinen, S., & Apajalahti, S. (2002). Prevalence of short-root anomaly in healthy young adults. *Acta Odontologica Scandinavica*, 6357(July), 56–59. <http://doi.org/10.1080/000163502753472014>
- 14) Neto, J. V. J. R., Neto, J. V. J. R., Paiva, J. B. De, Valladares Neto, J., Rino Neto, J., & de Paiva, J. B. (2013). Orthodontic movement of teeth with short root anomaly: Should it be avoided, faced or ignored? *Dental Press J Orthod*, 18(6), 72–85. <http://doi.org/10.1590/S2176-94512013000600012>
- 15) Davidovitch Z, Lee YJ, Counts AL, Park YG, Bursac Z, J. M. (2000). The immune system possibly modulates orthodontic root resorption. In *Biological Mechanisms of Tooth Movement and Craniofacial Adaptation* (pp. 207–217).
- 16) McNab, S., Battistutta, D., Taverne, A., & Symons, A. L. (1999). External apical root resorption of posterior teeth in asthmatics after orthodontic treatment. *American Journal of Orthodontics and Dentofacial Orthopedics: Official Publication of the American*

- Association of Orthodontists, Its Constituent Societies, and the American Board of Orthodontics*, 116(5), 545–551. [http://doi.org/10.1016/S0889-5406\(99\)70187-3](http://doi.org/10.1016/S0889-5406(99)70187-3)
- 17) Nishioka, M., Ioi, H., Nakata, S., Nakasima, A., & Counts, A. (2006). Root Resorption and Immune System Factors in the Japanese. *Angle Orthodontist*, 76(1).
  - 18) IL1B interleukin 1 beta [ Homo sapiens (human) ]. (2017). Retrieved from <https://www.ncbi.nlm.nih.gov/gene?Db=gene&Cmd=ShowDetailView&TermToSearch=3553#summary>
  - 19) Dinarello CA. (1996). Biological basis for Interleukin-1 in disease. *Blood*, 87(6), 2095–2147.
  - 20) Xu, J., Yin, Z., Cao, S., Gao, W., Liu, L., Yin, Y., & Liu, P. (2013). Systematic Review and Meta-Analysis on the Association between IL-1B Polymorphisms and Cancer Risk. *PLoS ONE*, 8(5), 1–10. <http://doi.org/10.1371/journal.pone.0063654>
  - 21) El-Omar EM, Carrington M, Chow WH, McColl KE, B. J. (2000). Interleukin-1 polymorphisms associated with increased risk of gastric cancer. *Nature*, 404, 398–402.
  - 22) Machado JC, Pharoah P, Sousa S, Carvalho R, O. C. (2001). Interleukin 1B and interleukin 1RN polymorphisms are associated with increased risk of gastric carcinoma. *Gastroenterology*, 121, 823–829.
  - 23) Chen H, Wilkins LM, Aziz N, Cannings C, W. D. (2006). Single nucleotide polymorphisms in the human interleukin-1B gene affect transcription according to haplotype context. *Hum Mol Genet*, 15, 519–529.
  - 24) Lind H, Haugen A, Z. S. (2007). Differential binding of proteins to the IL1B -31 T/C polymorphism in lung epithelial cells. *Cytokine*, 38, 43–48.
  - 25) Hall SK, Perregaux DG, Gabel CA, Woodworth T, D. L. (2004). Correlation of polymorphic variation in the promoter region of the interleukin- 1 beta gene with secretion of interleukin-1 beta protein. *Arthritis Rheum*, 50, 1976–1983.
  - 26) Pociot F, Molvig J, Wogensen L, Worsaae H, N. J. (1992). A TaqI polymorphism in the human interleukin-1 beta (IL-1 beta) gene correlates with IL-1 beta secretion in vitro. *Eur J Clin Invest*, (22), 396–402.
  - 27) Hernandez-Guerrero C, Monzon-Bordonaba F, Jimenez-Zamudio L, Ahued- Ahued R, A.-V. F. (2003). In-vitro secretion of proinflammatory cytokines by human amniochorion carrying hyper-responsive gene polymorphisms of tumour necrosis factor-alpha and interleukin-1beta. *Mol Hum Reprod*, (9), 625–629.
  - 28) Sobkowiak, P., Wojsyk-banaszak, I., Kowalewska, M., & Wasilewska, E. (2017). Interleukin 1  $\beta$  polymorphism and serum level are associated with pediatric asthma. *Pediatric Pulmonology*, (March), 1–7. <http://doi.org/10.1002/ppul.23893>
  - 29) Ferreira, S. B., Trombone, A. P. F., Repeke, C. E., Cardoso, C. R., Martins, W., Santos, C. F., (2008). An Interleukin-1  $\beta$  ( IL-1  $\beta$  ) Single-Nucleotide Polymorphism at Position 3954 and Red Complex Periodontopathogens Independently and Additively Modulate the Levels of IL-1  $\beta$  in Diseased Periodontal Tissues. *INFECTION AND IMMUNITY*, 76(8), 3725–3734. <http://doi.org/10.1128/IAI.00546-08>
  - 30) Ke Rena and Richard Torresb. (2011). Role of interleukin-1 $\beta$  during pain and inflammation. *Brain Res Rev.*, 60(1), 57–64. <http://doi.org/10.1016/j.brainresrev.2008.12.020>.Role
  - 31) Dinarello, C. A. (2011). Interleukin-1 in the pathogenesis and treatment of inflammatory diseases. *Blood*, 117(14), 3720–3732.

- 32) Loos BG, Papantonopoulos G, Jepsen S, L. M. (2015). What is the contribution of genetics to periodontal risk? *Dent Clin North Am*, 59, 761–780.
- 33) Wu X, Offenbacher S, López NJ, Chen D, Wang HY, R. J. (2015). Association of interleukin-1 gene variations with moderate to severe chronic periodontitis in multiple ethnicities. *J Periodontal Res*, 50, 52–61.
- 34) Abhijeet Rajendra Shete, Rosamma Joseph, Neetha N. Vijayan, Lekshmy Srinivas, and M. B. (2010). Association of Single Nucleotide Gene Polymorphism at Interleukin-1b +3954, -511, and -31 in Chronic Periodontitis and Aggressive Periodontitis in Dravidian Ethnicity. *Journal of Periodontology* , (81), 62–69.  
<http://doi.org/10.1902/jop.2009.090256>
- 35) Diehl SR, Wang Y, B. C. (1999). Linkage disequilibrium of interleukin-1 genetic polymorphisms with early-onset periodontitis. *J Periodontol*, 70, 418–430.
- 36) Amirisetty, R., Patel, R. P., Das, S., Saraf, J., & Munshi, A. (2015). polymorphism in chronic periodontitis patients from North India. *Acta Odontologica Scandinavica ISSN:*, 73(5), 343–347. <http://doi.org/10.3109/00016357.2014.961958>
- 37) Arora, Shelly; Sulugodu, Srinivas Ramachandra; Abdullah, Fawzia; Gundavarapu, K. C. G. (2017). Interleukin 1 $\beta$  (+3954; -511) Genotype Polymorphism and its Association with Severe Chronic Generalized Periodontitis in the Malaysian Population. *Contemp Clin Dent.*, 8(1), 102–105.
- 38) Gore EA, Sanders JJ, Pandey JP, Palesch Y, G. G. (1998). Interleukin-1B +3953 allele 2: association with disease status in adult periodontitis. *J Clin Periodontol*, 25, 781–785.
- 39) McDevitt MJ, Wang H-Y, K. C. (2007). Interleukin-1 genetic association with periodontitis in clinical practice. *J Periodontol 2000; 71:15663*, 71, 156–163.
- 40) Kornman KS, Crane A, W. H.-Y. (1997). The interleukin-1 genotype as a severity factor in adult periodontal disease. *J Clin Periodon*, 24, 72–77.
- 41) Al-Qawasmi, R. A., Hartsfield, J. K., Everett, E. T., Flury, L., Liu, L., Foroud, T. M., ... Roberts, W. E. (2003). Genetic predisposition to external apical root resorption. *American Journal of Orthodontics and Dentofacial Orthopedics*, 123(3), 242–252.  
<http://doi.org/10.1067/mod.2003.42>
- 42) Grieve WG, Johnson GK, Moore RN, Reinhardt RA, D. L. P. (1994). Prostaglandin E (PGE) and interleukin-1  $\beta$  (IL-1  $\beta$ ) levels in gingival crevicular fluid during human orthodontic tooth movement. *Am J Orthod Dentofacial Orthop*, 105, 369–374.
- 43) Lynch PR, Davidovitch Z, S. J. (1988). Interleukin-1B at bone resorption sites: Localization during tooth movement in vivo. *J Dent Res*, 67, 297.
- 44) Lehky L, Davidovitch Z, S. J. (1988). Interleukin-1A localization in resorption and apposition sites, during tooth movement in vivo. *J Dent Res*, 67, 297.
- 45) Alhashimi N, Frithiof L, Brudvik P, B. M. O. (2001). Orthodontic tooth movement and de novo synthesis of proinflammatory cytokines. *Am J Orthod Dentofacial Orthop*, 119, 307–12.
- 46) Sharp LB, Anderson SA, Sammon PJ, Klemenz LG, Cohen DA, D. D. (1991). Local and systemic effects of IL-1 on interradicular alveolar bone. *J Dent Res*, (70), 596.
- 47) Iwasaki LR, Haack JE, Nickel JC, Reinhardt RA, P. T. (2001). Human interleukin-1 beta and interleukin-1 receptor antagonist secretion and velocity of tooth movement. *Arch Oral Biol*, (46), 185–189.

- 48) Rossi M, Whitcomb S, L. R. (1996). Interleukin-1  $\beta$  and tumor necrosis factor-alpha production by human monocytes cultured with L-thyroxine and thyrocalcitonin: relation to severe root shortening. *Am J Orthod Dentofacial Orthop*, 110, 399–404.
- 49) Davidovitch Z. (1991). Tooth movement. *Crit Rev Oral Biol Med*, 2, 411–450.
- 50) Pociot F, Molvig J, Wogensen L, Worsaae H, N. J. (1992). A TaqI polymorphism in the human interleukin-1B gene correlate with IL-1B secretion in vitro. *Eur J Clin Invest*, 22, 396–402.
- 51) Harris, E. F., Kineret, S. E., & Tolley, E. a. (1997). A heritable component for external apical root resorption in patients treated orthodontically. *American Journal of Orthodontics and Dentofacial Orthopedics : Official Publication of the American Association of Orthodontists, Its Constituent Societies, and the American Board of Orthodontics*, 111(3), 301–309. [http://doi.org/10.1016/S0889-5406\(97\)70189-6](http://doi.org/10.1016/S0889-5406(97)70189-6)
- 52) Endres S, Cannon JG, Ghorbani R, Dempsey RA, Sisson SD, L. G. (1989). In vitro production of IL-1B, IL-1A, TNF and IL-2 in healthy subjects: distribution, effect of cyclooxygenase inhibition and evidence of independent gene regulation. *Eur J Immunol* 1989;19:2327-33., 19, 2327–2333.
- 53) WE, Roberts. (2000). Bone physiology, metabolism, and biomechanics in orthodontic practice. In *Graber TM, Vanarsdall RL, editors. Orthodontics: current principles and techniques* (pp. 193–257).
- 54) Engstrom C, Granstrom G, T. B. E. (1988). Effect of orthodontic force on periodontal tissue metabolism. A histologic and biochemical study in normal and hypocalcemic young rats. *Am J Orthod Dentofacial Orthop*, 93, 486–495.
- 55) Al-Qawasmi, R. a, Hartsfield, J. K., Hartsfield, J. K., Everett, E. T., Weaver, M. R., Foroud, T. M., & Roberts, W. E. (2004). Root resorption associated with orthodontic force in IL-1B eta knockout mouse. *Journal of Musculoskeletal & Neuronal Interactions*, 4(4), 383–385.
- 56) Sameshima G T, S. P. M. (2004). Characteristics of patients with severe root resorption. *Orthodontics and Craniofacial Research. Orthodontics and Craniofacial Research*, 7, 108–114.
- 57) Oyama K, Motoyoshi M, Hirabayashi M, Hosoi K, S. N. (2007). Effects of root morphology on stress distribution at the root apex. *Eur J Orthod*, 29, 113–117.
- 58) Abhijeet Rajendra Shete, Rosamma Joseph, Neetha N. Vijayan, Lekshmy Srinivas, and M. B. (2010). Association of Single Nucleotide Gene Polymorphism at Interleukin-1b +3954, -511, and -31 in Chronic Periodontitis and Aggressive Periodontitis in Dravidian Ethnicity. *Journal of Periodontology* ·, (81), 62–69. <http://doi.org/10.1902/jop.2009.090256>
- 59) Abuabara, A. (2007). Biomechanical aspects of external root resorption in orthodontic therapy. *Med Oral Patol Oral Cir Bucal*, 12(8), 610–613.



## Curriculum Vitae

### **Satyaprasad C Nayak**

Email – satya.cnayak@gmail.com

#### Education

Master of Science: Oral Biology Certificate: Orthodontics and Dentofacial Orthopedics University of Nevada, Las Vegas, NV	Expected, May 2018
Doctor of Dental Medicine University of Pennsylvania, Philadelphia, PA	May 2012
Master of Science: Biomaterials SUNY at Buffalo, Buffalo, NY	December 2009
Bachelor of Dental Surgery SDM College of Dental Sciences and Hospital, India	May 2005

#### Experience

Associate Dentist, Comfort Care Dental Las Vegas, NV	07/2015-11/2018
Associate Dentist, Brookline Dental Associates Havertown, PA	07/2014-06/2015
Associate Dentist, Dental Dreams Philadelphia, PA	07/2012-06/2014

#### Awards/Honors

Clinical Honors, University of Pennsylvania	05/2012
James English Research Award SUNY at Buffalo	03/2009
Graduate Research Award 2 <sup>nd</sup> place winner, UNLV	02/2017

#### Research/Professional Publications/ Presentations

Enhancement of Endodontic Root Canal Imaging Master's Thesis, SUNY at Buffalo	09/2007-11/2009
--	-----------------

In-vitro tissue-on-tissue friction model differentiates performance of dry mouth product  
Co-author, IADR, Toronto, Canada

07/2008

Leadership Position

President of the PASS Class 2012  
Program for Advanced Standing Students

05/2010-05/2012

Professional Memberships

American Association of Orthodontics  
Pacific Coast Society of Orthodontics  
Southern Nevada Dental Society  
American Dental Association