

AN *IN-VITRO* COMPARISON OF BACTERIAL MICROLEAKAGE OF  
GUTTA-PERCHA AND THE GUTTACORE CROSS-LINKED  
GUTTA-PERCHA CORE OBTURATOR

by

Abigail C. Edds

Submitted to the Graduate Faculty of the School of Dentistry in  
Partial Fulfillment of the Requirements for the Degree of Master of  
Science in Dentistry, Indiana University School of Dentistry, 2013.

Thesis accepted by the faculty of the Department of Endodontics, Indiana University School of Dentistry, in partial fulfillment of the requirements for the degree of Master of Science in Dentistry.

---

Mychel M. Vail

---

Joseph Legan

---

Ygal Ehrlich

---

Richard L. Gregory

---

Susan Zunt

---

Kenneth J. Spolnik  
Chairman of the Research  
Committee and Program Director

---

Date

ACKNOWLEDGMENTS

I would like to thank the entire endodontic faculty and staff for all their knowledge and support. Thank you, Dr. Spolnik, for your professional and personal guidance over the last two years. I will always be grateful to have you as my mentor. You take a personal stake in your resident's wellbeing, which is truly appreciated. I want to thank Dr. Vail for her support, and for her ability to help keep everything in perspective. You have helped to shape me into the endodontic clinician I am today.

I want to thank Dr. Legan for exemplifying the qualities of a true teacher: dedication, kindness, and patience. Thank you, Dr. Ehrlich, for your efforts with my thesis study. Your enthusiasm was greatly appreciated. Special thanks to Dr. Gregory for all your assistance. Your direction and knowledge allowed me to learn and appreciate the importance of microbiology. I want to acknowledge your personal commitment to my study. You always had time to answer questions, despite your busy schedule.

I want to let Drs. Baker and Griglione know that I will always cherish your friendship and humor throughout this residency. I believe that events happen for a reason, and I am so glad that we were chosen to be in the same residency class. It has been a pleasure spending time and getting to know you. You each have added immensely to this journey, and I wish you both great success and happiness.

Lastly, I would like to express love and gratitude to my husband, Eric. I want to thank you for your sacrifice, encouragement, and steadfast support over the years. Your hard work and dedication to our family are immeasurable.

TABLE OF CONTENTS

Introduction.....	1
Review of Literature.....	4
Methods and Materials.....	27
Results.....	35
Tables and Figures.....	37
Discussion.....	69
Summary and Conclusions.....	75
References.....	77
Abstract.....	87
Curriculum Vitae	

LIST OF ILLUSTRATIONS

FIGURE 1	Summary of experimental design, Part 1 .....	38
FIGURE 2	Summary of experimental design, Part 2 .....	39
FIGURE 3	Access of premolar tooth .....	40
FIGURE 4	Working length determination .....	41
FIGURE 5	Instrumentation with Profile to a size 40.04 taper .....	42
FIGURE 6	Irrigation with sodium hypochlorite .....	43
FIGURE 7	EndoActivator used for activating irrigation solutions .....	44
FIGURE 8	GuttaCore obturators.....	45
FIGURE 9	Conventional gutta-percha .....	46
FIGURE 10	From top to bottom, GuttaCore size 40 size verifier, GuttaCore size 40 obturator, and conventional size 40 gutta-percha, respectively .....	47
FIGURE 11	AH Plus sealer used with both GuttaCore and gutta-percha groups.....	48
FIGURE 12	GuttaCore oven used with the GuttaCore obturator group .....	49
FIGURE 13	System B and Hot Shot used to obturate the gutta-percha warm vertical condensation group .....	50
FIGURE 14	Radiograph of teeth obturated with GuttaCore .....	51
FIGURE 15	Radiograph of teeth obturated with warm vertical condensation of gutta-percha.....	52
FIGURE 16	Microleakage models including the original apparatus by Torabinejad 1990 (top) and the modified Torabinejad apparatus (bottom) .....	53



FIGURE 17	Microleakage apparatus used for all samples .....	54
FIGURE 18	SEM photomicrograph of <i>E. faecalis</i> (image courtesy of en.m.wikipedia.org/wiki/Enterococcus_faecalis) .....	55
FIGURE 19	Smear of <i>E. faecalis</i> green fluorescent protein (GFP) construct .....	56
FIGURE 20	Blood agar plate (BAP) showing <i>E. faecalis</i> and <i>E. faecalis</i> GFP indicating green fluorescent sheen .....	57
FIGURE 21	Placement of <i>E. faecalis</i> GFP into sterile brain heart infusion broth with yeast extract and tetracycline by Bunsen burner.....	58
FIGURE 22	One day after broth inoculated with <i>E. faecalis</i> GFP. Sterile BHI-YE broth with tetracycline and turbid broth displaying growth of <i>E. faecalis</i> GFP .....	59
FIGURE 23	Apparatus samples prepared for study .....	60
FIGURE 24	Apparatus samples in CO <sub>2</sub> incubator .....	61
FIGURE 25	Turbidity of lower chamber broth in GuttaCore sample and GuttaCore sample that has not leaked .....	62
FIGURE 26	Confirmation of <i>E. faecalis</i> in lower chamber broth with culturing on BAP indicating green fluorescent sheen: GuttaCore sample and stock <i>E. faecalis</i> GFP .....	63
FIGURE 27	Sectioned GuttaCore obturated tooth in plastic block and gutta-percha positive control sectioned 100- $\mu$ m thick.....	64
FIGURE 28	Radiograph of teeth after 40-day microleakage study: GuttaCore sample that displayed turbidity; note root surface defect and gutta-percha positive control that displayed turbidity .....	65
FIGURE 29	Fluorescent microscopy from pilot study showing <i>E. faecalis</i> GFP in dentinal tubules indicated by green fluorescent aggregates and no <i>E. faecalis</i> GFP present in dentinal tubules .....	66

FIGURE 30 Fluorescent microscopy of GuttaCore sample with turbidity showing no *E. faecalis* GFP present in dentinal tubules in either coronal (top) or apical (bottom) section .....67

TABLE I Microleakage for the experimental and control groups over time .....68

## INTRODUCTION

Root canal therapy requires three important steps accomplished in concert to achieve long-term success. These include canal shaping, disinfection, and obturation. Shaping of the canal involves instrumentation to extirpate or debride the pulpal tissue and remove dentin to prepare for the subsequent steps of canal irrigation and obturation.<sup>1</sup> Canal disinfection is achieved by utilization of various irrigation solutions to reduce the microbial load. Sodium hypochlorite<sup>2</sup> is antimicrobial, and ethylenediamine tetra-acetic acid (EDTA) chelates calcium and removes the smear layer, which can contain necrotic debris.<sup>3</sup> After disinfection, the root canal system is filled with sealer and a core material to prevent reinfection through inward movement of tissue fluid and outward movement of bacteria and their toxins.<sup>4</sup>

Traditionally, gutta-percha has been used with sealer in a cold lateral condensation technique to obturate root canals.<sup>5</sup> Schilder<sup>4</sup> introduced the concept of warm vertical compaction of gutta-percha in 1967 to attempt to obturate more canal irregularities. Johnson<sup>6</sup> presented the use of stainless steel files with thermally plasticized gutta-percha in 1978. Subsequently, in 1991 the metal carrier was changed to plastic and named Thermafil. Thermafil has shortcomings in that it does not always fulfill Grossman's obturation material properties, such as apical extent of the material (extrusion of gutta-percha beyond the apex)<sup>7</sup> and ease of retreatment (plastic carriers remain inside the canal).<sup>8</sup> AH Plus sealer has shown long-term sealing ability.<sup>9</sup>

A new obturation material by Dentsply (Tulsa, OK), GuttaCore cross-linked gutta-percha core obturator, has been introduced that replaces the plastic core with a

cross-linked gutta-percha core. The obturator is marketed to be fast and efficient, as well as safe and biocompatible. A heated GuttaCore obturator utilizes hydraulic forces to centrally compact the warm, flowable gutta-percha into the three-dimensional canal system laterally and apically. The manufacturer states removal of the obturation material and core is fast and easy. To date, no microleakage studies have been done to test this newer obturation material.

#### PURPOSE

The purpose of this investigation is to evaluate and compare microleakage of the prepared root canal system when it is obturated using warm vertical gutta-percha or GuttaCore obturator. Both methods will use AH Plus sealer. The goal is to determine whether there is a significant difference in microbial microleakage between these two groups.

#### HYPOTHESES

Null Hypothesis: There is no significant difference in microleakage between AH Plus/gutta-percha and AH Plus/GuttaCore obturator.

Alternative Hypothesis: There is a significant decrease in microleakage of AH Plus/GuttaCore obturator versus AH Plus/gutta-percha.

REVIEW OF LITERATURE

## CLASSIC HISTORY OF ENDODONTICS

Although descriptions of endodontic therapies date back to ancient times, a comprehensive review of historical endodontics begins in the late 17<sup>th</sup> century. Charles Allen wrote the first book on dentistry in English in 1687, but did not describe pulpal treatment in detail. The “tooth worm” theory, in which a worm was thought to invade the interior of the tooth and cause pain, was rebuked by the findings of Anton von Leeuwenhoek, the father of modern microscopy.” In 1728 Pierre Fauchard advocated the use of a pin to remove the pulp, allowing the tooth to be left open for drainage and later filled with lead foil. Robert Woofendale documented the first endodontic therapy in 1766 when he described relieving pain by “cauterizing the pulp with a hot instrument.” He also wrote about using oil of cinnamon or cloves or turpentine on exposed pulp to aid with pain and “destroy the nerve.”<sup>10</sup>

Many techniques and materials have been introduced to obturate the prepared root canal space. Edward Hudson is often credited with being the first to use root canal fillings by placing gold foil in the canals in 1809. In 1839 Baker wrote the first published description in the *American Journal of Dental Science* of a complete root canal therapy, which involved removal of the pulp tissue and cleaning and filling of the root canal. It is speculated that leakage occurred because neither gutta-percha nor cements were used at this time. “Hill’s stopping” was used as the first gutta-percha filling material in 1847, which consisted of bleached gutta-percha and carbonate of lime and quartz.<sup>11</sup> When combined with chloroform, Hill’s stopping was used as cement with wooden plugs. In

the 1860s, E.L. Clarke and others would heat gutta-percha and use hot instruments to place it into canals. Use of gutta-percha alone as a root canal filling is attributed to G.A. Bowman.<sup>10</sup>

Joseph Lister reported the use of antiseptics to the medical community in 1867. The same year *Leptothrix buccalis* was identified as a “parasite” on teeth and in carious lesions, which led to the conclusion that caries could lead to pulpal changes. These findings spawned the use of antiseptic materials, such as phenol, to “sterilize” the pulp.<sup>10</sup> A change in etiology of pulpal pathology was occurring, as thinking changed from lack of vitality of the pulp causing disease to a theory revolving around bacteria. W.D. Miller further advocated the septic theory by correlating the development of a dental abscess from a pulpal infection.<sup>12</sup>

Improvements were made to adequately fill root canals. By the end of the 19<sup>th</sup> century, chloropercha, a combination of chloroform and gutta-percha, was widely used with gutta-percha cones during obturation. C.T. Gramm initially used copper points to fill canals, but ultimately plated them with gold to reduce oxidation. The use of caustic medicaments was gaining popularity and would remain in use for the next 50 years. The most widely used was formocresol, a mixture of tricresol and Formalin.<sup>12</sup>

Major developments to medicine and dentistry were occurring at the turn of the century, which included the discovery of X-rays by William C. Roentgen in 1917, and the development of procaine (Novocaine) by Einhorn in 1905. This allowed for pulpal treatment with anesthesia and evaluation of canal length and obturation with use of wires and X-rays. Many different root canal cleaning agents were being used, such as sodium dioxide, metallic sodium and potassium, and 20-percent to 40-percent sulphuric acid.



The concept of electromedication, later called ionization, to sterilize the canal was becoming popular in an attempt to use less caustic materials. Hermann Prinz recommended the use of 1.0-percent sodium chloride during this procedure.<sup>12</sup>

The concept of focal infection was introduced by E.C. Rosenow by demonstrating that bacteria, namely streptococci, present in one area of the body could spread via the bloodstream and cause disease at a different location. William Hunter later gave a dramatic speech on the topic of focal infection at McGill University in 1910. He discussed the role of sepsis in medicine and was very critical of dentistry as the source of the problem. When referring to gold crowns, he described them as “mausoleums of gold over a mass of sepsis.” This theory was adopted by many physicians and dentists who carried the thinking on for 25 years.<sup>13</sup>

The focal infection era particularly affected treatment of pulpless teeth, which were being extracted in place of receiving root canal therapy. Rhein made an attempt in 1912 to persuade dentists to use better techniques when performing root canal therapy, such as incorporating the rubber dam for asepsis. The continuing debate about the appropriate length of filling used to obturate the canal was argued between proponents of filling past the apical foramen versus those who cautioned against any extrusion. Sterilization and filling materials used to date were highly irritating, so a change in dental research to study materials based on “biologic principles” was championed.<sup>13</sup>

In 1920 Hermann used calcium hydroxide for filling canals in an attempt to use something other than phenolic or formol compounds, which he considered foreign and cytotoxic. Ten years later, Calyxyl, would be used for pulp capping, pulpotomies and infected canals. Hermann displayed calcium hydroxides use in secondary dentin bridge

formation. Pulp capping, although not widely performed in America, was popular in Europe due to histologic research showing pulp tissue to contain reparative cells using microscopy. In 1925 Rickert suggested using a sealer or “cementing medium” in conjunction with gutta-percha cones to seal laterally and apically. Standardization of root canal instruments and filling materials was suggested, although it would take many years to become accepted and incorporated by dental supply manufacturers.<sup>13</sup>

Twenty years after Hunter’s speech and indiscriminate extraction of diseased teeth, an article was published in the *Dental Cosmos* (1930) that asked clinicians to use better judgment. The editorial stated that extraction of pulpless teeth was not the answer, and recommended no longer choosing a “destructive policy.” Retaining teeth to provide for better overall patient welfare was discussed. These changes would take 10 years before conservative therapy would be accepted among the dental community and incorporated into dental schools.<sup>13</sup>

The shift to the “scientific era” took place at the end of the 1930s. Important work by Logan revealed that when microorganisms were present, that there was not necessarily infection present. Antibiotics as part of root canal therapy became commonplace in the 1940s and 1950s with the use of sulfanilamides and penicillin. Sommer and Crowley investigated periapical lesions and found no correlation between radiographic appearance of lesions and the bacteriologic status of the pulp. Wais further demonstrated that there is also no correlation between radiographic findings and histologic status of the pulp.<sup>13</sup>

The concept of instrumentation combined with medication to decrease microorganisms prior to filling the root canal was proposed by Auerback in 1953. A few

years later, Sargenti and Richter developed N2, a medicament and sealer that contained paraformaldehyde. Controversy over the use spread with concern of associated irritating properties. Proponents championed the ability of N2 to neutralize pulp to allow for root canal therapy in one appointment.<sup>13</sup>

The American Association of Endodontists was formed in 1943 by a group of 20 men who met in Chicago to create a group for organized endodontics. Harry B. Johnson created the term “endodontist” by combining two Greek words “endon,” meaning within, and “ho dontas,” meaning a tooth. The *Journal of Endodontia* was first published in 1946 and Balint Orban was the first editor. The American Board of Endodontics was founded in 1956 as a specialty board by the American Dental Association’s Council on Dental Education. Endodontics was finally recognized as a specialty in 1963, and the first certification of Diplomates was in 1965.<sup>13</sup>

## ROOT CANAL ANATOMY

Hess first noted the vast anatomical network of the root canal system in 1925,<sup>14</sup> and more current research by Peters<sup>15</sup> has confirmed the true canal complexity through use of microcomputed tomography. In Cleghorn’s<sup>16</sup> evaluation of over 6700 mandibular first premolars, 98 percent were found to be single-rooted with 75.8 percent having a type I canal system. In a study of over 7700 mandibular second premolars, 99.6 percent had a single root with 91 percent having a single canal.<sup>17</sup> Differences in root and canal number are found according to variations in gender and ethnicity that requires careful evaluation during root canal therapy.<sup>17</sup> Krasner and Rankow<sup>18</sup> described coronal anatomy in concise laws to aid in location of the pulp chamber and root canal orifices. These include:

1. Law of Centricity: pulpal floor is located in the tooth center at the cemento-enamel junction (CEJ) level.
2. Law of Concentricity: walls of the pulp chamber are concentric to external surface.
3. Law of CEJ: pulp chamber is located at this level.
4. Law of Symmetry: orifices are equidistant and perpendicular from a line drawn mesial-distal through the center of the pulpal floor (with exception of maxillary molars).
5. Law of Color Change: pulpal floor is darker than the chamber walls.
6. Law of Orifice Location: orifices are located at the junction of the chamber floor and walls.

Pineda and Kuttler<sup>19</sup> found that the distance from the major to the minor diameter of the apical constriction can range from 0.525 mm in 18-to-25-year-olds to 0.659 mm in older individuals. The increase in this length is due to the deposition of cementum at the apex with aging. A systematic review and meta-analysis of the literature by Schaeffer, Walton and White<sup>20</sup> in 2005 found a 28.8-percent better success rate when the root canal is obturated 0 mm to 1 mm from the apex rather than past the apex. The average apical foramen size of mandibular premolars varies from 35 mm to 40 mm,<sup>21</sup> and VandeVisse and Brilliant<sup>22</sup> recommends an apical foramen size of at least 30 to allow for better canal irrigation.

## ROOT CANAL PREPARATION

Preparation of root canals involves the removal of pulpal tissue, as well as the progressive enlargement of each canal to remove bacteria within root dentinal tubules and

create a space adequate for obturation. Access of mandibular premolars includes an oval preparation to facilitate location of the pulpal chamber, while utilizing the previously described laws from Krasner and Rankow<sup>18</sup> concerning chamber and canal location. This will ensure complete removal of the roof of the pulpal chamber and location of canal orifices. Next, rotary orifice shapers are used to preflare the coronal third of the canal to facilitate more consistent readings with the electronic apex locator by allowing more access to the apical foramen.<sup>23</sup> Preflaring also lessens the likelihood of .04 taper nickel-titanium instrument separation.<sup>24</sup>

Hand files are used to create and maintain a patent glide path that decreases the incidence of fracture of rotary (ProTaper) instruments.<sup>25</sup> The most widely used hand instruments are stainless steel K-files and Hedstrom files. K-type files are made from a preshaped blank (triangle or square) that is then twisted. Hedstrom files are machined from a circular blank by cutting sharp angles, which makes them more efficient and less likely to pack debris at the apex.<sup>26</sup> Maintaining apical patency with a #10 hand file improves the delivery and access of sodium hypochlorite to the apical third of the canal when using passive ultrasonic irrigation.<sup>27</sup>

After a glide path is created, rotary instruments are used as an efficient method to clean and shape and remain better centered in the canal space than stainless steel hand files.<sup>28</sup> Nickel-titanium (NiTi) files are composed of 55.0-percent nickel and 45.0-percent titanium and exist in two phases, called austenite and martensite. The continual cycling between the two phases allows for the files to exhibit superelasticity and shape memory, allowing for increased flexibility.<sup>29</sup> Despite the efficiency of NiTi rotary

instruments, all leave at least 35 percent of the internal canal surface area unmodified,<sup>30</sup> thus relying on irrigation solutions to aid in reduction of bacterial load.

## IRRIGATION

Irrigation solutions are utilized during cleaning and shaping of the root canal in conjunction with hand and rotary instruments to facilitate removal of bacteria. This is referred to as chemo-mechanical preparation. As previously mentioned, 100 percent of canal walls are not cleaned and shaped with instruments alone. Siquiera et al.<sup>31</sup> found that the use of antibacterial irrigation solutions is important in the process of chemo-mechanical preparation, regardless of instruments or solutions used. Ideal properties of irrigation solutions include:

1. Washing action.
2. Reduction of instrument friction during preparation.
3. Facilitation of dentin removal.
4. Dissolution of inorganic tissue.
5. Dissolution of organic matter (dentin collagen, pulp tissue, biofilm).
6. Killing of bacteria and yeasts.
7. Nonirritating and nontoxic.
8. Do not weaken tooth structure<sup>32</sup> (yet no solution has been found to fulfill all functions).

### Sodium Hypochlorite (NaOCl)

One very useful solution is sodium hypochlorite (NaOCl), a basic irrigation solution, which has been used in endodontics in concentrations from 0.5 percent to 6

percent with a buffered pH of 11.<sup>32</sup> The first use of NaOCl in medicine was recommended by Dr. Richard Dakin in 1915 during World War I to clean soldiers' injuries. It was termed Dakin solution and consisted of 0.5-percent sodium hypochlorite.<sup>33</sup> Sodium hypochlorite has a broad antimicrobial spectrum and is effective against bacteria<sup>32</sup> and fungi.<sup>34</sup> The active component of NaOCl is hypochlorous acid, which alters vital cell functions, resulting in cell death.<sup>32</sup>

Sodium hypochlorite dissolves organic tissue associated with the root canal, including vital and necrotic pulp and collagen within dentin.<sup>32</sup> Sodium hypochlorite has the ability to dissolve necrotic tissue best when used at 5.25 percent, full strength solution.<sup>35, 36</sup> Inhibitory effects versus *Enterococcus faecalis* were dependent on the concentration of sodium hypochlorite and were more effective with 5.25 percent than 1 percent.<sup>37</sup> The effectiveness of sodium hypochlorite is also related to time and microbial susceptibility,<sup>38</sup> as well as use of large volume and continual replenishment.<sup>37</sup> Careful use of NaOCl is warranted as unintentional injection of sodium hypochlorite beyond the apex of a tooth can result in pain, edema and necrosis of surrounding soft tissue due to its cytotoxic effects.<sup>39</sup>

#### Ethylenediamine Tetra-Acetic Acid (EDTA)

The smear layer was first described by McComb and Smith in 1975,<sup>40</sup> and is made up of organic and inorganic debris, including dentin, pulp tissue, odontoblast process remnants and bacteria.<sup>41</sup> A controversy exists about whether to remove the smear layer. Proponents of removal argue that leaving the smear layer will affect the adhesion of the sealer, whereas others claim that the presence of smear layer is a barrier to microbial invasion.<sup>41</sup>

Sodium hypochlorite, as mentioned, removes only the organic portion of the smear layer, leaving the inorganic components intact. EDTA is a chelating agent that sequesters calcium ions from canal dentin thereby removing inorganic debris. EDTA demineralizes dentin by dissolving hydroxyapatite and is most commonly used as a 17-percent concentration with a pH of 7.<sup>32</sup> Calt and Serper<sup>3</sup> found that a one-minute rinse with 17-percent EDTA is adequate to remove the smear layer, but that 10 minutes of EDTA caused extreme dentinal tubular destruction. A systematic review and meta-analysis by Sharavan et al.<sup>42</sup> in 2007 determined that smear layer removal does increase the “fluid tight seal,” regardless of obturation technique or sealer type used.

Irrigation solutions have been traditionally used via a syringe and needle delivery system. Adjuncts to delivery of solutions include ultrasonic, sonic and apical negative pressure systems. Ultrasonic activation is applied at a frequency between 25 kHz to 40 kHz and has been shown to significantly reduce colony forming units (CFU) of microorganisms when used for 1 minute.<sup>43</sup> Sonic activation via use of an EndoActivator uses a frequency of 1 kHz to 8 kHz and can improve the action of disinfection on biofilm bacteria.<sup>44</sup> EndoVac, an apical negative pressure device, draws irrigation solutions delivered at the orifice down to the depth of the cannula, thereby decreasing apical extrusion of irrigation solutions.<sup>45</sup> The EndoVac also effectively disinfects isthmuses and removes the smear layer and debris.<sup>46</sup>

#### MICROBIOLOGY AND IMMUNOLOGY OF ENDODONTIC INFECTIONS

Root canal therapy involves cleaning and shaping to remove microorganisms and their byproducts, as well as sealing the root with filling material and the crown with a



restoration to prevent recontamination of the canal space. The success of endodontics is dependent upon the eradication of bacteria to allow the body's immune system to heal and repair any periapical pathology that has been caused as a result of the microbial contamination of the pulp. The classic study by Kakehashi, Stanley and Fitzgerald<sup>47</sup> in 1965 illustrated the cause of periapical lesions to be the result of microflora. They utilized germ-free rats and conventional rats and exposed the pulp of the molars in each group. The rats that had microbial contamination developed pulpal necrosis with chronic inflammation and abscess formation in the bone apical to the exposed molars. The germ-free rats, despite having exposed pulps, did not develop abscess formation. The pulps in the rats that were free of bacteria remained vital and had dentin bridge formation.<sup>47</sup> Moeller<sup>48</sup> later confirmed that development of periapical lesions occurred only as a result of infection of devitalized pulps in monkeys. Sundqvist<sup>49</sup> further demonstrated the causative role of bacteria in endodontic periapical pathology in humans.

Once the bacterial etiology had been determined, studies tried to identify whether a particular species was associated with patient symptoms. Black pigmented bacteria were found to be associated with acute apical abscesses or purulent drainage.<sup>50,51</sup> *Bacteroides melaninogenicus* was found associated with presence of pain, sinus tracts and foul odor.<sup>52</sup>

Infections from primary root canal infections are polymicrobial and primarily belong to the genera *Fusobacterium*, *Prevotella*, *Porphyromonas*, *Eubacterium*, *Peptostreptococcus*, *Propionibacterium*, *Actinomyces*, and *Streptococcus*. Among them, *Porphyromonas endodontalis* has been frequently found associated with symptomatic primary infections.<sup>53</sup> The number of obligate anaerobes increases with time<sup>54</sup> and within

the apical 5 mm of the root canal.<sup>55</sup> Previously treated root canal infections have less diversity of species and are generally gram-positive (+) facultative cocci, including *E. faecalis*.<sup>56</sup> Other microorganisms have been found in endodontic infections such as yeasts,<sup>57</sup> particularly *Candida albicans*.<sup>58,59</sup>

Controversy exists over the presence of bacteria within periapical lesions. Tronstad found anaerobes in periapical tissues of refractory endodontic infections,<sup>60</sup> yet Nair questions contamination as he discusses the host immune response to microbial invaders from the root canal.<sup>61</sup> A number of viruses, including human herpes viruses (HHV), varicella zoster virus (VZV), and human papilloma virus (HPV) have also been isolated from acute apical abscesses, although their role in the pathogenesis has yet to be determined.<sup>62</sup>

*E. faecalis* is a non-motile gram-positive facultative coccal anaerobe (see Figure 18). *E. faecalis* is detected in asymptomatic, persistent endodontic infections.<sup>63</sup> Root canal-treated teeth are almost nine times more likely to contain *E. faecalis* than primarily infected teeth.<sup>56</sup> Virulence factors of *E. faecalis* in failed endodontically treated teeth are related to its capability to invade dentinal tubules, attach to collagen and survive.<sup>64</sup> *E. faecalis* produces gelatinase, hyaluronidase, and aggregation substance that allows for the spread and the adhesion of bacteria. *E. faecalis* secretes heat-shock proteins whose primary role is to allow the bacteria to survive under high stress conditions.<sup>56</sup>

Lipoteichoic acid (LTA), a component of the gram-positive bacterial cell wall, is another virulence factor of *E. faecalis*. LTA is recognized by toll-like receptors (TLR-2) on host cells, inducing activation of macrophages and the complement system. This in turn triggers a series of inflammatory events, including release of pro-inflammatory

cytokines, such as IL-1 and TNF- $\alpha$ . The principle function of the early innate immune response is to eradicate invading endodontic bacteria, but this response also results in local tissue destruction.<sup>56</sup>

If the innate response cannot destroy the microbial invaders, the host responds by activating the adaptive immune response. The two types of adaptive immunity, humoral and cell-mediated, are involved in chronic inflammation. The humoral response relies on B lymphocytes that become activated in response to an antigen and ultimately give rise to antibodies. Cell-mediated immunity is mediated by T lymphocytes, which are specific to a particular antigen.<sup>56</sup>

Bacterial invasion of the coronal pulp leads to inflammation and host immune reaction ultimately causing necrosis of the pulp. The infection spreads in an apical direction leading to apical periodontitis and possible acute abscess formation. Chronic apical periodontitis results as a consequence of inflammation and immune response. Cytokines induce osteoblasts to produce RANKL, which stimulates osteoclastogenesis, leading to periapical bone resorption.<sup>56</sup>

Many of the studies concerning endodontic microorganisms have been performed using conventional bacteriological methods, primarily culturing techniques. Problems result when a microbe is oxygen sensitive and therefore cannot be cultured in an aerobic environment. Prevalence of many organisms may have been underestimated utilizing this method.<sup>53</sup>

Molecular methods have been used to detect microorganisms that are difficult to culture. One method, the polymerase chain reaction (PCR), has the highest sensitivity of any microbiological method for the detection of microbiota. PCR is an *in-vitro* method

for the replication of specific sequences of DNA. PCR amplifies a very small quantity of microbial DNA a billion-fold and allows for detection by electrophoresis. PCR has the property to detect uncultivable microorganisms and is therefore useful in endodontic diagnosis and research.<sup>53</sup>

Green fluorescent protein (GFP) from the jellyfish *Aequorea victoria* is useful as a bacterial label because the fluorescent marker can be exhibited in the bacterial host without having to use stains, cofactors, or substrates.<sup>65</sup> A plasmid that encodes for a copy of the green fluorescent variant gene is transferred into the *E. faecalis*. An autocatalytic reaction occurs creating a fluorophore by oxidation. The marker fluoresces green with use of a standard fluorescence microscope (see Figure 19). The fluorescence is stable, species independent and can be monitored non-invasively in living cells. Expression of GFP action has been successfully accomplished for numerous organisms, including *Streptococcus mutans* and *E. faecalis*.<sup>66</sup>

## OBTURATION

The purposes of placing an obturating material after cleaning and shaping are to prevent the passage of fluids and bacterial elements from the root canal into the surrounding periapical tissues and to prevent periradicular tissue fluids from gaining access into the canal space.<sup>67</sup> The inadequate sealing of the apical foramen can perpetuate the growth of bacteria due to a continued nutrient supply, which allows them the ability to survive, proliferate and cause persistent disease.<sup>68</sup> Grossman illustrated the properties of an acceptable obturation material that include the following: 1) ease of introduction; 2) becomes solid; 3) seals apically and laterally; 4) does not shrink; 5) is impervious to moisture; 6) is bacteriostatic; 7) is non-staining, non-irritating, and easily

removable; 8) is sterile or sterilizable, and 9) is radiopaque.<sup>69</sup> The importance of biocompatibility, insolubility, ease of manipulation, and adaptation to canal irregularities was documented by McElroy.<sup>70</sup>

Many techniques and materials have been introduced to obturate the prepared root canal space. "Hill's stopping" was used as the first gutta-percha filling material in 1847, which consisted of bleached gutta-percha and carbonate of lime and quartz.<sup>11</sup> Contemporary gutta-percha is composed of gutta-percha (20%), zinc oxide (65%), radiopacifiers (10%) and plasticizers (5%).<sup>71</sup> Gutta-percha transitions from a beta phase to an alpha phase when heated to about 115°F, changes to an amorphous phase between 130°F to 140°F, and then returns to the beta phase upon cooling.<sup>72</sup> Senia et al.<sup>73</sup> determined that a one-minute immersion in 5.25.0-percent NaOCl should be done to disinfect the gutta-percha prior to use.

Traditionally, gutta-percha has been used with sealer in a cold lateral condensation technique,<sup>5</sup> yet Schilder<sup>4</sup> introduced the concept of warm vertical compaction of gutta-percha in 1967 to attempt to obturate more canal irregularities. No significant differences were found in a systematic review between the use of cold lateral compaction and warm vertical condensation with regard to obturation quality, postoperative pain prevalence or long-term outcome.<sup>74</sup> Warm gutta-percha condensation obturation did result in a higher rate of overextension than the cold lateral technique.<sup>74</sup> Extrusion of gutta-percha beyond the apex can be associated with increased incidence and degree of post-operative pain in teeth with no periapical radiolucency.<sup>75</sup>

Johnson<sup>6</sup> presented the use of stainless steel files with thermally plasticized gutta-percha in 1978. Subsequently, in 1991 the metal carrier was changed to plastic and

named Thermafil. Thermafil has shortcomings in that it does not always fulfill Grossman's obturation material properties, such as apical extent of the material (extrusion of gutta-percha beyond the apex)<sup>7</sup> and ease of retreatment (plastic carriers remain inside the canal).<sup>8</sup> When compared with traditional gutta-percha condensation techniques, Thermafil obturated premolars displayed the most leakage attributed to partial gutta-percha stripping off the carrier during placement, or space created during handle removal.<sup>76</sup>

A new obturation material by Dentsply (Tulsa, OK), GuttaCore cross-linked gutta-percha core obturator, has been recently introduced that replaces the plastic core with a cross-linked gutta-percha core. The obturator is marketed to be fast and efficient, as well as safe and biocompatible. A heated GuttaCore obturator utilizes hydraulic forces to centrally compact the warm, flowable gutta-percha into the three-dimensional canal system laterally and apically. The manufacturer states removal of the obturation material and core is fast and easy and can be accomplished with twisting the handle.

## ENDODONTIC MICROLEAKAGE STUDIES

Methods used to study microleakage have included the use of dyes, radioisotopes, fluid transport, electrochemicals, glucose and microorganisms. These models follow the penetration of the different tracers along the root canal.<sup>77</sup> The most utilized method was identification and measurement of dye or radioisotope penetration along a root filling. The same methods were being used to test obturation materials, but the results were highly variable, which raised concerns about the reliability of the findings.<sup>78</sup> Debate exists over the validity of these methods in applying *in-vitro* microleakage endodontic research findings to clinical applications.<sup>77</sup>

### Dye and Radioisotope Studies

Wu and Wesselink<sup>78</sup> reported that 82 percent of the endodontic leakage studies published utilized dye or radioisotope penetration. A certain degree of leakage was found in all of these studies. These are based on the concept of capillary action and diffusion. There are many variables associated with tracer penetration methods that may contribute to discrepancy in results. These include operator experience, variability in tracers used (size, pH, chemical reactivity), presence or absence of a smear layer, and thermal cycling during the experiment. Methylene blue dye, for example, is acidic and may demineralize the dentin, causing an increased amount of leakage.<sup>78</sup>

There are other factors that are difficult to control. Gaps between the root filling and the canal wall may contain entrapped air and/or liquid. The tracer may either penetrate or be prevented into these areas. The unpredictability of the entrapped air/liquid leads to further shortcomings associated with the tracer methodology.<sup>78</sup>

### Fluid Transport and Glucose Studies

In an effort to reduce the variability associated with the formation of entrapped air, the concept of applying reduced pressure was incorporated into the model. Pashley et al.<sup>79</sup> developed a system in 1987 for identifying leakage around coronal restorations using convective fluid transport under positive pressure. Fluid transport can be quantifiably measured by the movement of an air bubble in a fluid-filled capillary tube attached to the inlet side of the test specimen.<sup>80</sup>

A newer method for quantitatively assessing endodontic leakage was described by Xu et al.<sup>81</sup> in 2005. The model used glucose under hydrostatic pressure and measured leakage of the concentrated glucose in the apical reservoir. The device was found to be

sensitive. It did not require destruction of the tooth, and the results were clinically relevant. Glucose has a low molecular weight and can be used to simulate toxins that would move through the root canal.<sup>81</sup>

Shemesh et al.<sup>82</sup> compared leakage of root fillings using both the fluid transport and the glucose penetration models. Both models measure fluid passage along root fillings under constant pressure, but the glucose model was suggested to be more sensitive. The glucose method allowed for measurement of diffusion and might allow for detection of smaller voids due to prolonged length of time the model is subjected to pressure.<sup>82</sup> It was also found that experimental materials did not alter the concentration of the glucose over time.<sup>77</sup>

#### Bacterial Leakage Studies

Mortensen et al.<sup>83</sup> was the first to describe a model for testing bacterial penetration around coronal restorations in 1965. The device used a tubing assembly whereby bacterial leakage was visualized by turbidity of the broth apical to the tooth and presence of a red pigment that confirmed leakage was of the test microorganism.<sup>83</sup> By 1980, this bacterial leakage model was being used in endodontic research.<sup>84</sup> The most common device is the use of a two-chamber system, which seals a tooth between the upper and lower chambers. Turbidity or a change of color of the broth in the lower chamber is indicative of leakage of bacteria. Groups are compared according to the number that leaked and the time to leakage.<sup>85</sup>

Given that endodontic infections and apical periodontitis are caused by microorganisms, potentially through a coronal leakage source, the model can use bacteria as the marker to study different filling materials.<sup>85</sup> Despite the prevalent use of the



bacterial leakage model, questions regarding the validity and clinical application have been asked. The Editorial Board of the *Journal of Endodontics* made a statement that studies using this model would no longer be published in 2007.<sup>85</sup>

A review of published literature regarding microbial leakage through the root canal discussed concerns about the model including the inability to quantify the leakage. Once microorganisms are in the broth, they begin to multiply and turbidity results. Also, the dispute as to whether the microleakage is actually through the root canal or through the outer root surface cannot be determined. Some studies included in the review did not use media to prevent contamination; no histological methods were used to trace the route of leakage, and the articles did not mention sterilization of the teeth or the materials used in the model.<sup>85</sup>

## STERILIZATION METHODS

Extracted teeth used for endodontic research purposes require sterilization to eliminate microorganisms prior to initiation of the study. Appropriate sterilization techniques are imperative to assure no inherent contamination of the model components. Different methods used to sterilize teeth and materials in dental research have included chemicals to store teeth, steam autoclave, dry heat, ethylene oxide, and gamma/UV radiation.<sup>86</sup> These are employed in an attempt to prevent cross-contamination, as well as to prevent exposure of the researcher to potential infectious disease.<sup>86</sup> The Occupational Safety and Health Administration (OSHA) Bloodborne Pathogens Standard considers human teeth used for research and teaching purposes as a potential source of bloodborne pathogens. The following sterilization methods were utilized in this study:

## Thymol

Thymol is a phenolic compound used as storage media for extracted teeth. Studies indicate that for dentin adhesive research, stored teeth must be kept in a moist environment to prevent dehydration and should not be stored longer than 6 months.<sup>87,88</sup> Ethanol (70%), formalin (10%), distilled water, and distilled water with 0.02-percent thymol increased the permeability of dentin, but had no effect on bond strengths. Specimens stored in water and saline displayed the widest variations in permeability.<sup>89</sup> Thymol was not recommended as a storage solution in one study because it is a phenolic compound that investigators suspected to inhibit polymerization of methacrylates.<sup>90</sup> Haller et al.<sup>91</sup> found 0.1-percent thymol had no effect on microleakage and produced similar results when compared with freshly extracted teeth.

## Steam Autoclave

Sterilization is a process that kills microorganisms, including bacterial spores.<sup>92</sup> Use of the autoclave is the most frequently used means to sterilize instruments in dental schools and offices. The instruments are prepackaged in sleeves that typically have an indicator after treatment that the sterilization was effective. Steam is created under pressure at 121°C and 15 psi for 20 minutes, effectively killing all bacteria, spores and viruses.<sup>93</sup> The protein damage necessary for cell function ultimately kills bacteria, viruses and spores. Spore tests are routinely done to monitor the effectiveness of the autoclave unit, and are used as the indicator because of their known resistance to sterilization procedures. The spores of *Bacillus stearothermophilus* have been used to test steam autoclave sterilization.<sup>92</sup>

## Ethylene Oxide

Ethylene oxide is reported as the oldest sterilization method used to sterilize extracted teeth used in dental research. The process of sterilization using ethylene oxide is accomplished in three phases:<sup>94</sup>

1. First, a 16-h preconditioning using 50-percent to 80-percent relative humidity at 38°C.
2. Next, a 625-mg/L concentration of ethylene oxide cycles for three hours at 40°C to 50°C, effectively killing all microorganisms.
3. A degassing time of at least 72 hours at 40°C is necessary to minimize toxicity to human tissues.

Studies have demonstrated that the use of ethylene oxide gas does not interfere with dentin permeability or bond strength,<sup>95</sup> advocating for sterilization of teeth by this method for bacterial microleakage studies. However, controversy exists as to the effectiveness of ethylene oxide to kill bacterial spores. Hays and White reported that ethylene oxide rendered extracted teeth free of vegetative bacteria,<sup>96</sup> but later found ethylene oxide to be ineffective at sterilizing extracted human molars that had been injected with *Bacillus subtilis* endospores. This finding stressed the importance of evaluating sterilization methods using a biological standard.<sup>97</sup>

## Ultraviolet (UV) Radiation

Ultraviolet light is utilized to sterilize dental instruments and extracted teeth, and has been suggested for use in sterilization of dental implants.<sup>98</sup> UV light is part of the electromagnetic spectrum, and ranges from 150 nm to 400 nm, but has been found to have a maximal bactericidal dose at a wavelength of 254 nm.<sup>92</sup> Most believe that UV

rays cause cellular DNA mutations and cell death by altering genetic functions.

Limitation of traditional ultraviolet radiation to sterilize involves the low ability of the energy to penetrate surfaces not directly affected by the rays.<sup>92</sup> Both UV and  $\gamma$ -radiation kill endospores through alteration of cellular DNA mechanisms, but the suggestion of possible spore resistance factors has been raised.<sup>99</sup>

## MATERIALS AND METHODS

## SELECTION OF TEETH

Sixty-two human, single-rooted premolars extracted for periodontal considerations were used for this study. All teeth were collected from the Oral Health Research Institute under the IU IRB#NS0911-07. All teeth were stored in sealed containers using 0.1-percent thymol prior to the study. Radiographs were taken in a mesial-distal direction to confirm that a Type I root canal system was present. Teeth with abnormal canal anatomy, abnormal root morphology, extensive caries, or root fractures were excluded.

Once the teeth were selected, calculus and soft tissue debris were removed from the root surface using hand scaling instruments. Following debridement of the root surface, the teeth were immersed in 6.0-percent sodium hypochlorite (Clorox Co., Oakland, CA) for five minutes and mechanically debrided with a soft brush. The premolars were accessed and canal location determined (see Figure 3). A #10 K-type endodontic file (Kerr, Romulus, MI) was inserted into the root canal and advanced out the apical foramen of all teeth. All teeth with canals that could not be negotiated with #10 K-type endodontic files were excluded from the study.

## CANAL INSTRUMENTATION AND IRRIGATION

Working length determination was accomplished by passing a #10 K-type endodontic file into the root canal until the file was just visible at the apical foramen and subtracting 1 ml from this file length measurement (see Figure 4). The root canals were

cleaned and shaped using K-type endodontic hand files #10, #15, #20 (Kerr, Romulus, MI) to working length. Profile orifice shapers sequenced from 30/.06 to 50/.07 to 40/.06 were used to flare the coronal half of the canal. Instrumentation of all teeth were performed using a crown-up technique implementing Profile 0.04 tapered rotary files, sizes #20 to #40, with a master apical file (MAF) of 40/.04 (see Figure 5). Irrigation was performed using 1 ml of 6.0-percent NaOCl between each file with a 25-gauge needle tip irrigating syringe (see Figure 6). A #10 K-type file was used to maintain apical patency.

Once instrumentation was completed, the final working length was confirmed using a size verifier (40/.04), which reaches the apical constriction passively. This will ensure that the obturation material used matches the correct apical canal diameter. The size verifiers included by Dentsply are made of nickel titanium and are fluted, which makes them appropriate for minor apical shaping. If the size verifier is slightly short of the established working length, the size verifier can be used to enlarge the apical foramen diameter by rotating it in a clockwise direction with slight apical pressure until desired working length is reached with use of a rubber stopper. The size verifier should be able to rotate passively in the canal 180°.

After instrumentation, 2 ml of 6.0-percent NaOCl was flushed and activated using EndoActivator (Dentsply) (see Figure 7) for 1 minute, followed by a 1-min activated rinse of 2 ml of 17-percent EDTA solution to remove the smear layer. The root canals were then irrigated with a final rinse of 2 ml of sterile saline and then dried with sterile, coarse paper points. To prevent dehydration, all roots were handled using sterile water moistened gauze during resection and instrumentation.

## ASSIGNMENT OF TEETH

Specimens were randomly assigned to two groups of 27 teeth. The two groups were classified as Group I, warm vertical gutta-percha and Group II, GuttaCore. In addition, two groups containing four specimens each served as positive and negative controls, Group + and Group -, respectively. The positive and negative control groups are to ensure that the microleakage model is functioning properly.

## CANAL OBTURATION

Group I: After canal instrumentation and irrigation, Group I was obturated in an orthograde fashion with a #40/.04 gutta-percha cone (Brasseler, Savannah, GA) (see Figure 9) and AH Plus sealer (Dentsply/Caulk, Milford, DE)<sup>9</sup> using warm vertical condensation. This was accomplished by inserting the master gutta-percha cone coated with AH Plus sealer (see Figure 11) to working length. A System B heat source (Tulsa Dental, Tulsa, OK) plugger (see Figure 13) was advanced apically while activated to within 6 mm of the established working length. The heat activator was then released and apical pressure held for 10 seconds to allow the remaining gutta-percha to cool. Appropriately sized Schilder pluggers (Dentsply/Caulk, Milford, DE) were used to condense the apical portion of gutta-percha. The canal was next filled with warmed gutta-percha using a Hot Shot system (Discus Dental) (see Figure 13) to the canal orifice and further condensed with Schilder pluggers. Radiographs were taken to confirm successful length and density of the fill (see Figure 15). Cavit (3M, St. Paul, MN) was used to seal the chamber. The teeth were placed in a humidior at 37°C for a minimum of 8 hours to allow set of sealer prior to assembly of leakage apparatus.



Group II: A size 40 GuttaCore obturator (see Figure 8) was chosen and a rubber stopper set so that the top of the stopper coincided with the working length. The top of the rubber stopper also corresponded to the bottom of the calibration ring on the obturator. A #40/.04 sterile paper point was used to brush a very light coating of AH sealer (see Figure 11) on the canal walls, followed by an additional point to remove any excess sealer. The GuttaCore obturator was heated in the obturator oven (see Figure 12), then directly inserted into the canal until working length was reached. The GuttaCore obturator handle was removed by bending to separate and excess removed with a spoon excavator. Radiographs were taken to confirm successful length and density of the fill (see Figure 14). Cavit (3M, St. Paul, MN) was used to seal the chamber. The teeth were placed in a humidior at 37°C for a minimum of 8 hours to allow set of sealer prior to assembly of leakage apparatus.

Controls: Two groups containing four specimens each served as positive and negative controls, Group + and Group -, respectively. The positive and negative control groups are to ensure the bacterial microleakage apparatus is functioning properly. The positive controls consisted of four prepared teeth; two teeth obturated with only a single master cone of gutta-percha with no sealer and two obturated with a single GuttaCore obturator with no sealer. This allowed free communication of the bacteria from the upper chamber of the apparatus with the growth medium in the lower chamber. The negative control consisted of four teeth; two teeth obturated with AH Plus/gutta-percha and two teeth obturated with AH Plus/GuttaCore obturator. All four teeth in the negative control were coated with flowable composite resin to seal the apical opening and the dentinal tubules. The control teeth using sealer were placed in a humidior at 37°C for a minimum

of 8 hours to allow set of sealer prior to assembly of leakage apparatus. The negative control should exhibit no leakage. Obturated teeth in all groups were sterilized using ethylene oxide.

#### MICROBIAL LEAKAGE APPARATUS

A microbial leakage apparatus was constructed using a two-chamber method as described by Torabinejad et al.<sup>100,101</sup> (see Figure 16) and used by previous endodontic graduate students successfully.<sup>102</sup> The apparatus was constructed using a sterilized 5 ml scintillation vial in which the tooth was suspended and secured in a hole in the vial cap with wax, so that 3 mm of apical root structure projected down into the scintillation vial without contacting the floor of the vial (see Figure 17). A sectioned 10- $\mu$ l Eppendorf tube was seated in the coronal access and sealed using flowable composite resin to serve as a reservoir for the bacteria to be added.

The lower chamber of the apparatus, created by the space between the root tip and floor of the scintillation vial, was filled with 5 ml of autoclaved modified Brain Heart Infusion broth with Yeast Extract (BHI-YE) containing tetracycline at 15  $\mu$ g/ml. Assembly of the above model was completed by Bunsen burner flame and left under UV light for 24 hours. Tetracycline-resistant *E. faecalis* GFP construct was grown in 5 ml of the modified BHI-YE (see Figure 21) overnight at 37°C in a 5.0-percent CO<sub>2</sub> incubator for 24 h and cultured on blood agar plate (BAP) to confirm growth (see Figure 20, Figure 22). The *E. faecalis* GFP construct (strain designation OG1RF:pMV158GFP) was obtained from Dr. Lynn Hancock, Kansas State University. The tetracycline-resistant *E. faecalis* GFP strain was chosen to provide assurance of the data. For example, the presence of a tetracycline-resistant bacterium in the bottom chamber indicates that the

tetracycline-resistant *E. faecalis* GFP strain has passed through the canal and leaked into the lower chamber. Furthermore, the visualization of the GFP-labeled bacteria indicates that the fluorescent bacteria had to be from the inoculum. The upper chamber of the apparatus, that space above the canal orifice in the Eppendorf tube, was filled with 5  $\mu$ l of the fresh overnight culture of tetracycline-resistant *E. faecalis* in broth. The apparatus was then incubated in an anaerobic chamber at 37°C for 48 hours (see Figure 24). A fresh culture of *E. faecalis* GFP was grown every week as above in fresh modified BHI-YE medium, and *E. faecalis* was added (approximately 1  $\mu$ l to 5  $\mu$ l) to the upper chamber every 3 days to 4 days to ensure live bacteria were present during the entire investigation period. Replenishing of the upper chamber was accomplished using sterile technique.

Evidence of leakage was determined by bacterial turbidity of the growth medium in the lower chamber. This was determined by daily visual observation for 40 days and compared to a tube of uninoculated medium (see Figure 25). Samples of lower chamber medium were collected on BAP to verify the presence (after the vial was identified as leaking) or absence of *E. faecalis* by evaluating colonial morphology of the species (see Figure 26).

## BACTERIAL PENETRATION

Further direct confirmation of bacterial microleakage along the root canal was evaluated using a fluorescent microscope. After 40 days of the dual chamber bacterial microleakage study, two teeth were removed from the apparatus and submitted for histologic preparation (one GuttaCore and one positive control). The teeth were processed for hard tissue plastic histology and embedded in methyl methacrylate resin. These resin/plastic embedded teeth were sectioned to a thickness of 100  $\mu$ m the Leica

SP160 saw microtome (see Figure 27). These sections were glued to plastic glass slides and were further grinded down to 10  $\mu\text{m}$  with sequentially increasing grit of sandpaper on an Exakt grinding system. These final slides were observed for *E. faecalis* under a fluorescent microscope X100 oil immersion objective lens. Determination was made as to the presence of *E. faecalis* GFP construct into the depth of the root canal and classified into 3 sections (coronal, middle, and apical).

### STATISTICAL ANALYSIS

Presence of microleakage (turbidity), depth of microleakage, and time-to-leakage (in days) will be determined for each of the samples. The presence of microleakage will be compared between groups using Fisher's Exact tests and depth of microleakage will be compared using Mantel-Haenszel chi-square tests. Survival analysis will be used to compare the two groups for differences in time to microleakage, with a Kaplan-Meier plot to visualize the results and a nonparametric log-rank test for the group comparison.

### SAMPLE SIZE

With a sample size of 27 teeth in each of the two groups, the study will have 80-percent power to detect a difference in the proportion with no microleakage (40 percent versus 80 percent at 10 days based on a previous study) assuming a two-sided 5.0-percent significance level using a log-rank test.

## RESULTS

The microleakage evaluation was completed in 40 days. No microleakage was observed in the negative control groups. Microleakage was observed in both gutta-percha positive control groups and in one of two GuttaCore positive control groups. One of 27 GuttaCore samples displayed turbidity, which occurred at day 14. None of the 26 gutta-percha samples displayed turbidity at any point over the 40 days. The 95.0-percent confidence intervals (CI) for the percentage of samples with turbidity were 0.1 percent to 19 percent for GuttaCore and 0.0 percent to 13.2 percent for gutta-percha using a Fisher's Exact Test. The two groups did not have a significantly different percentage of samples with turbidity ( $p = 1.00$ ). No *E. faecalis* GFP was visualized under fluorescent microscopy in either the turbid GuttaCore sample or the gutta-percha positive control in the apical, middle, or coronal thirds. Both samples that demonstrated microleakage had confirmation that the lower chamber broth contained *E. faecalis* GFP when cultured on BAP.

TABLES AND FIGURES

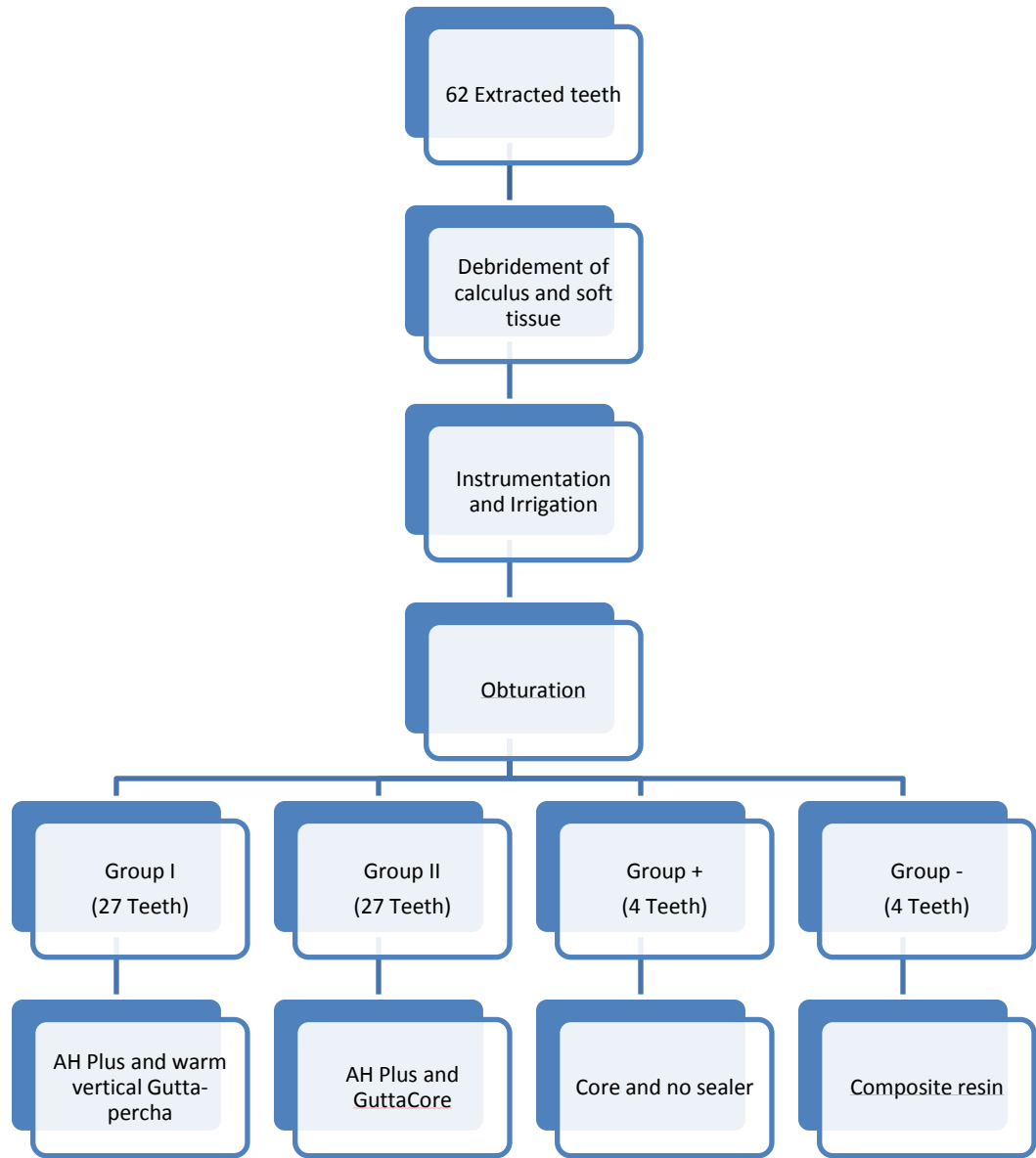


FIGURE 1. Summary of experimental design, Part 1.



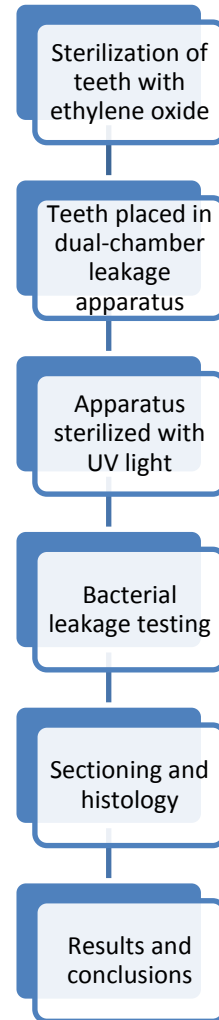


FIGURE 2. Summary of experimental design, Part 2.

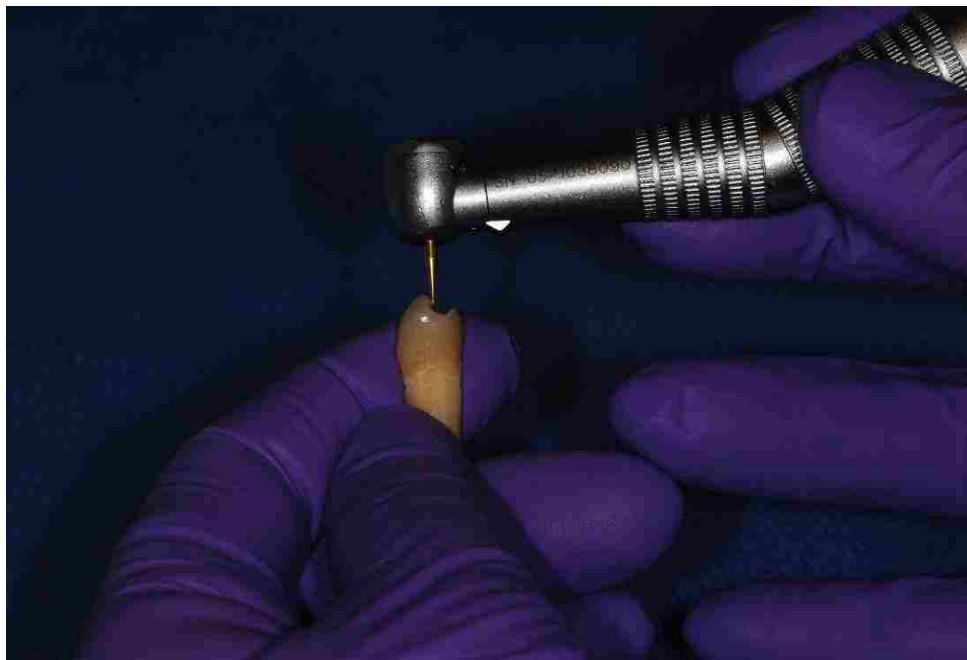

FIGURE 3. Access of premolar tooth.

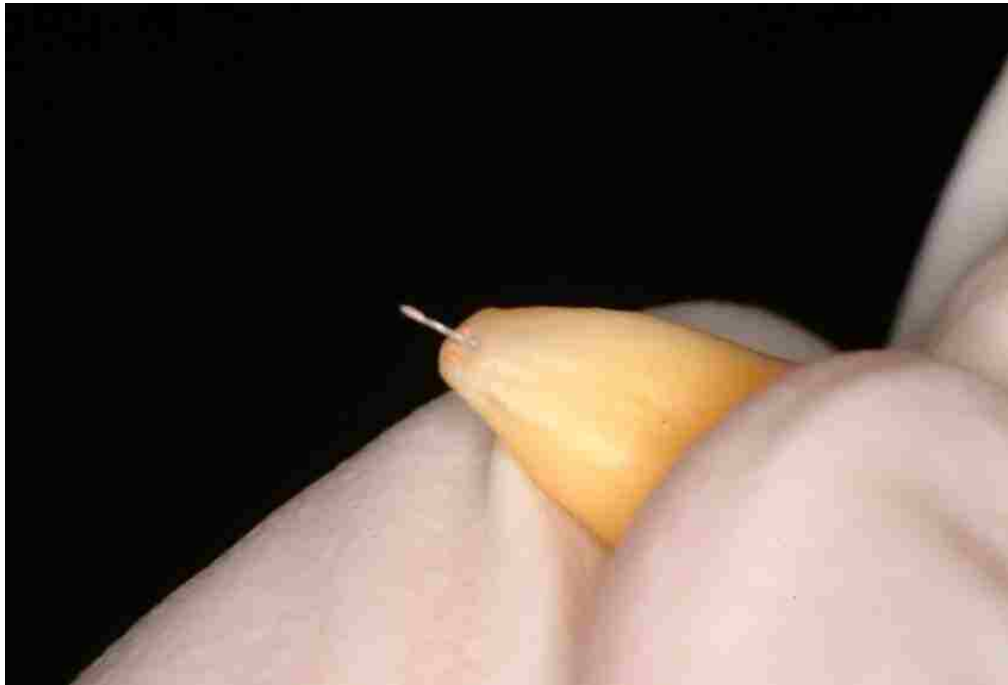


FIGURE 4. Working length determination.

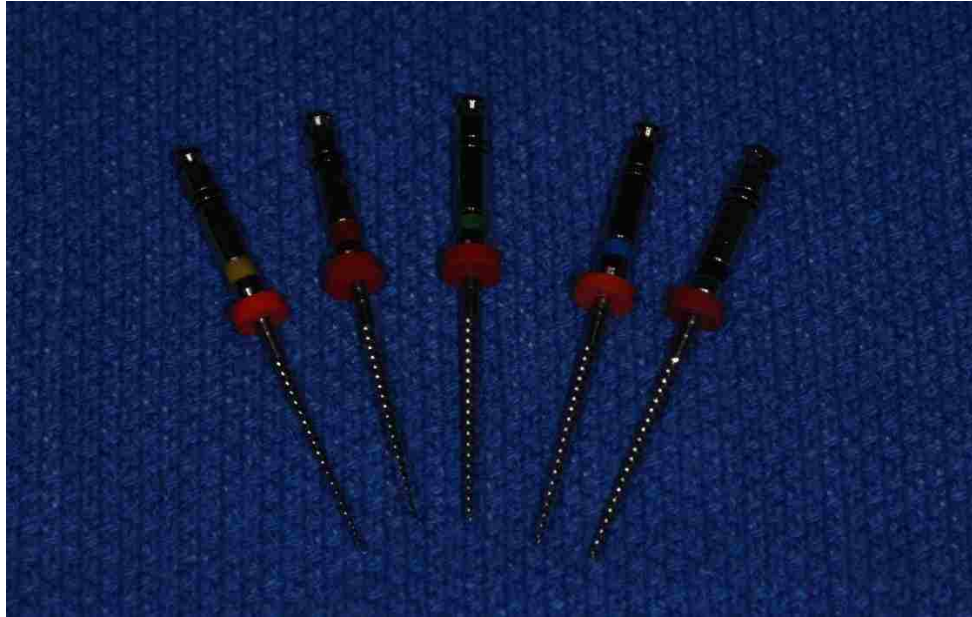

FIGURE 5. Instrumentation with Profile to a size 40.04 taper.

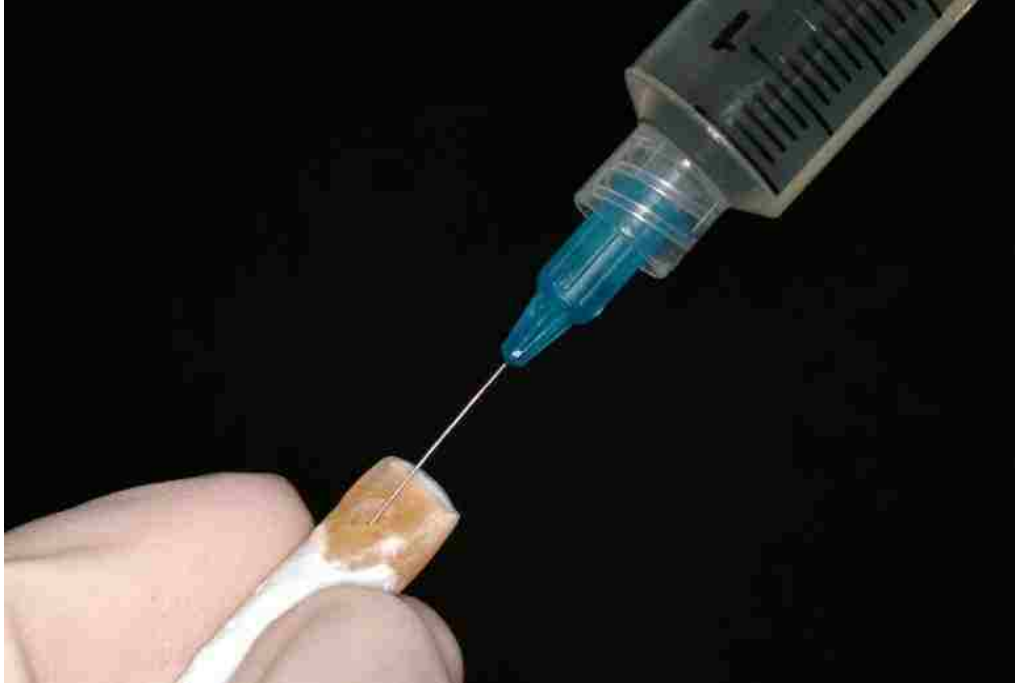

FIGURE 6. Irrigation with sodium hypochlorite.

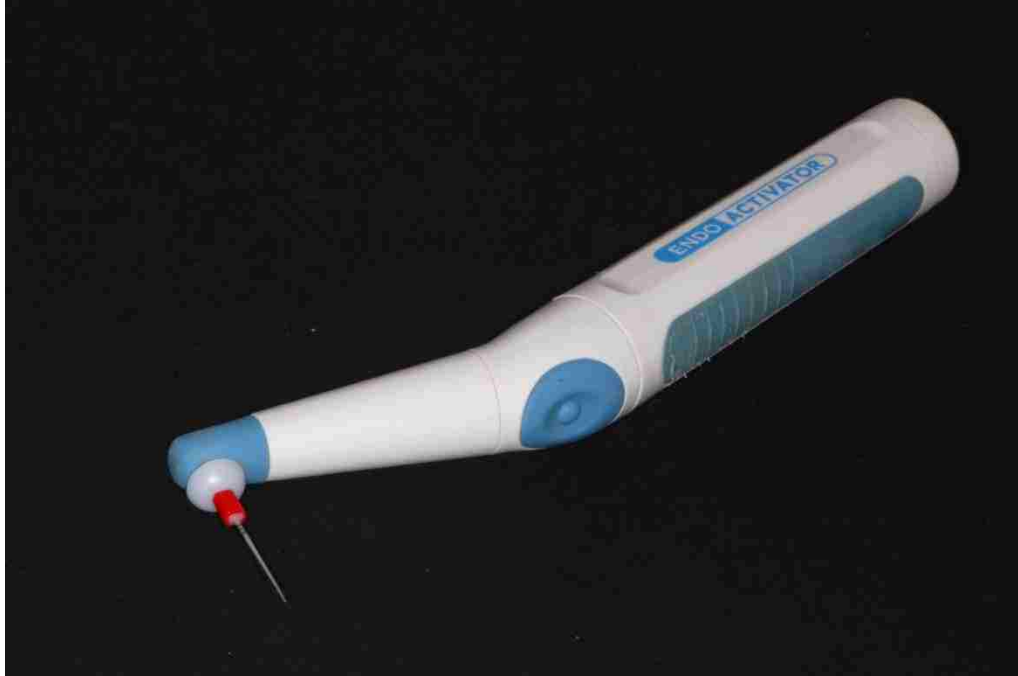


FIGURE 7. EndoActivator used for activating irrigation solutions.



FIGURE 8. GuttaCore obturators.



FIGURE 9. Conventional gutta-percha.



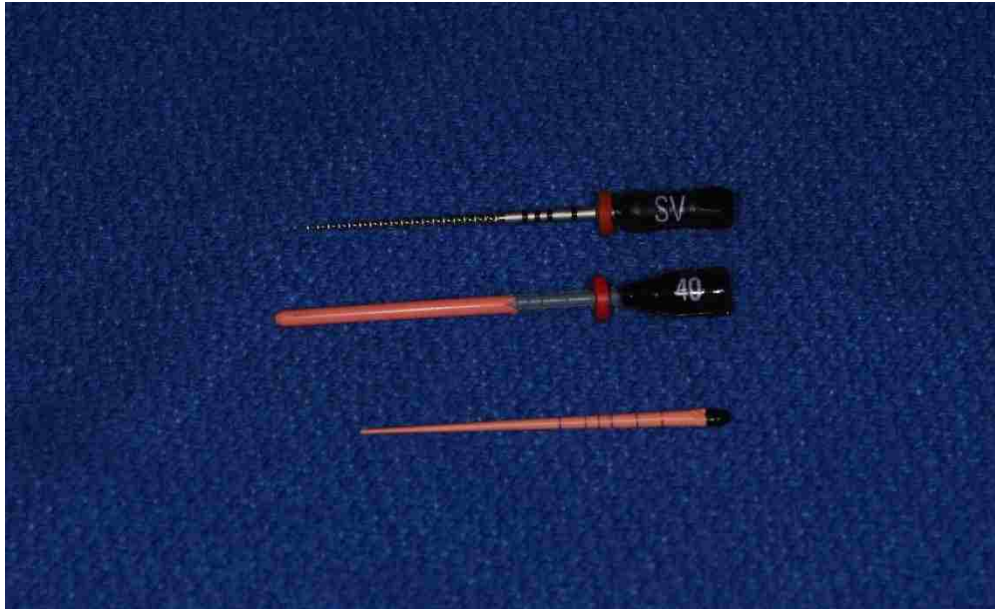

FIGURE 10. From top to bottom, GuttaCore size 40 size verifier, GuttaCore size 40 obturator, and conventional size 40 gutta-percha, respectively.

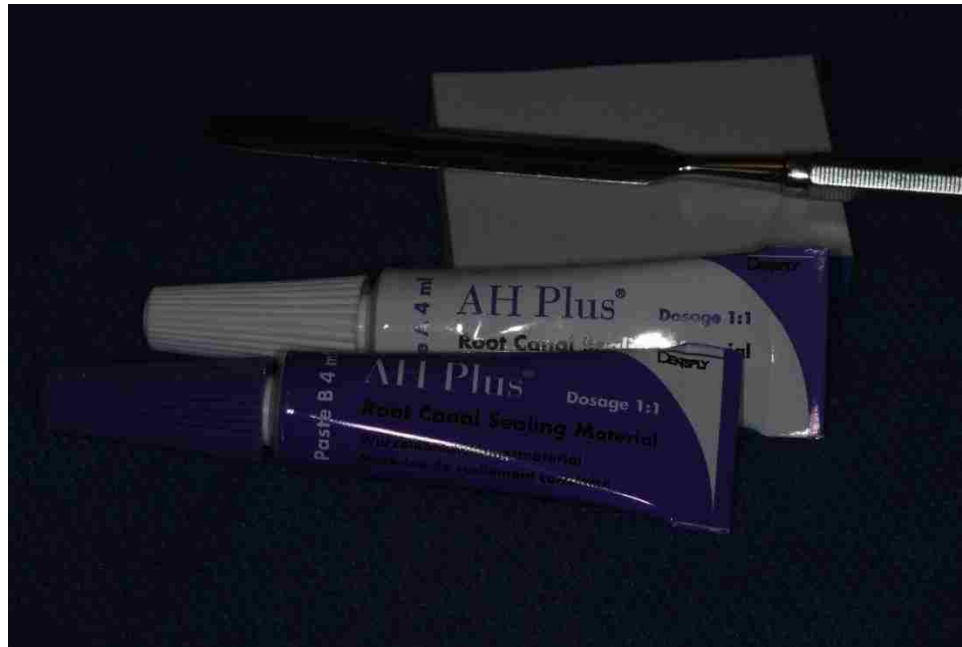

FIGURE 11. AH Plus sealer used with both GuttaCore and gutta-percha groups.



FIGURE 12. GuttaCore oven used with the GuttaCore obturator group.

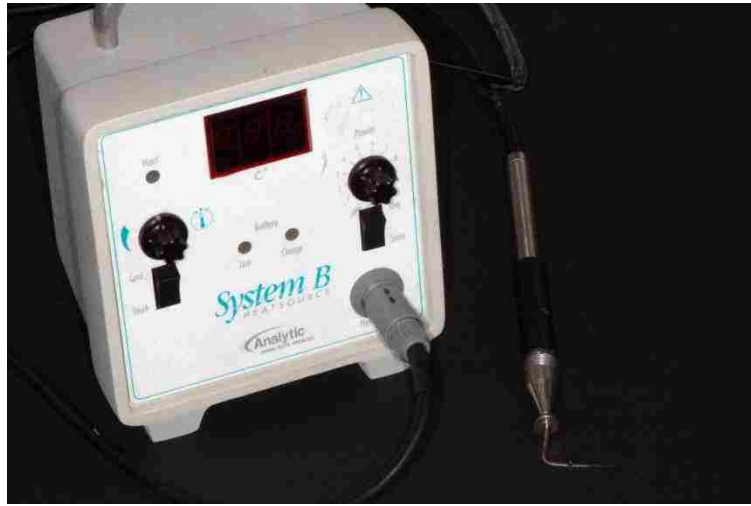

FIGURE 13. System B and Hot Shot used to obturate the gutta-percha warm vertical condensation group.

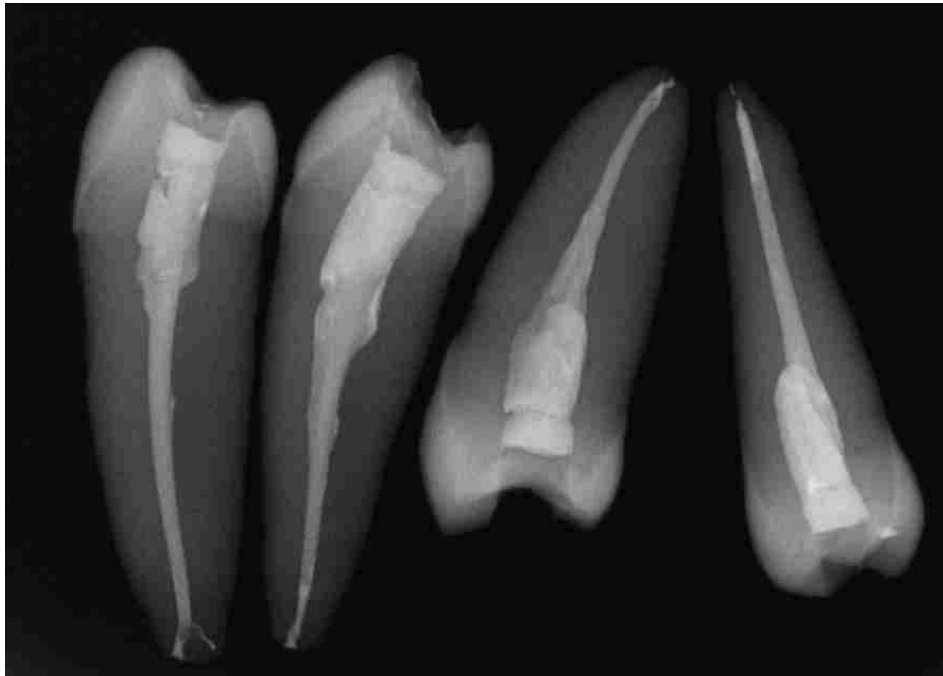


FIGURE 14. Radiograph of teeth obturated with GuttaCore.

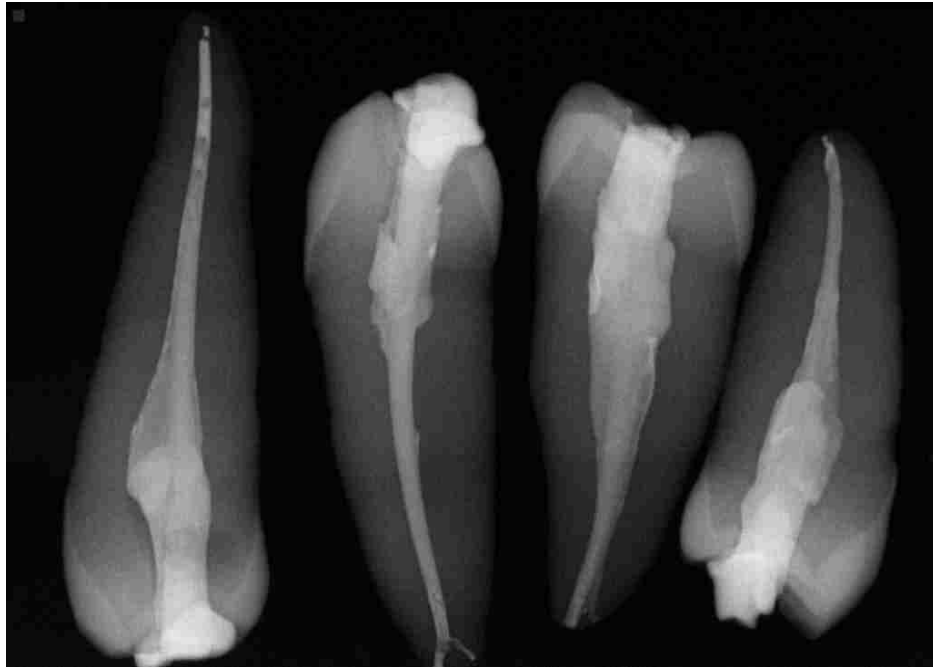


FIGURE 15. Radiograph of teeth obturated with warm vertical condensation of gutta- percha.

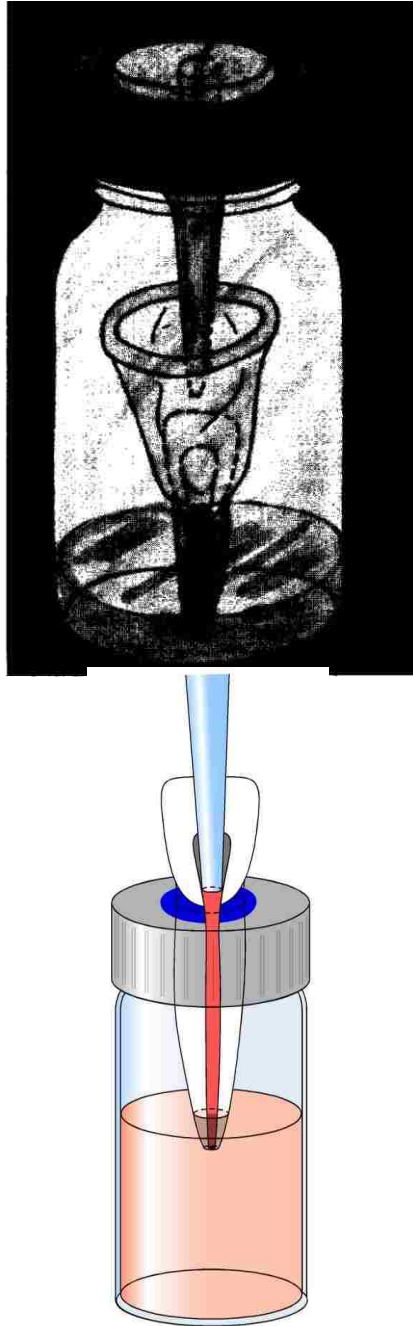


FIGURE 16. Microleakage models including the original apparatus by Torabinejad (1990) (top) and the modified Torabinejad apparatus (bottom).



FIGURE 17. Microleakage apparatus used for all samples.



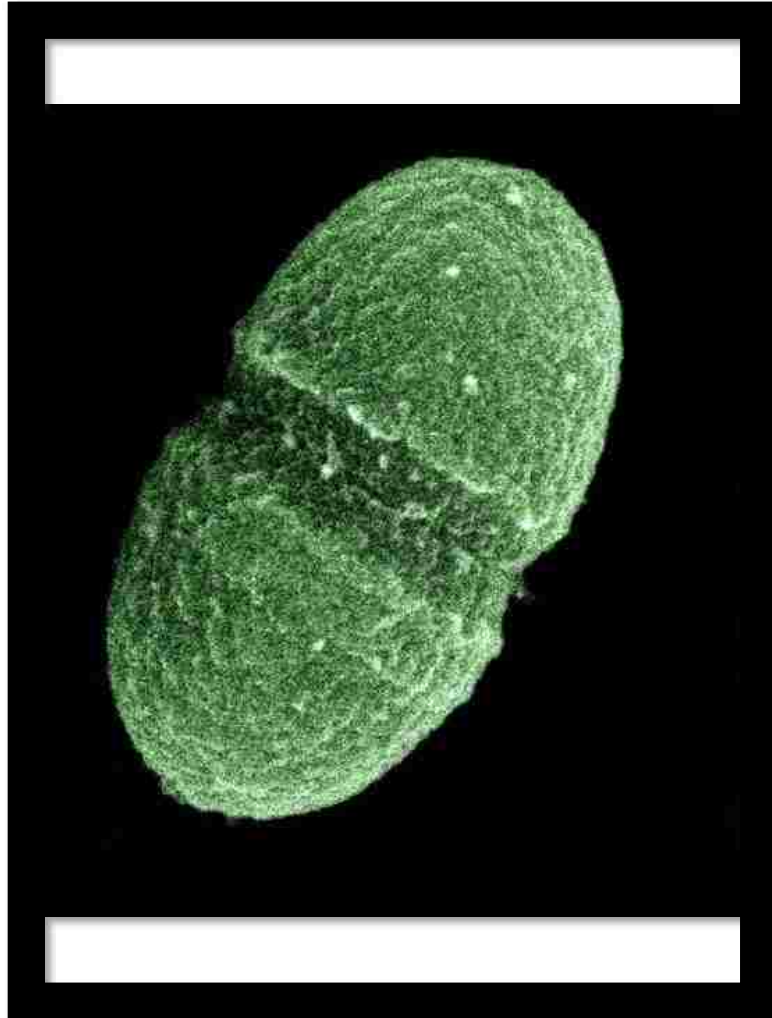


FIGURE 18. SEM photomicrograph of *E. faecalis* (image courtesy of [en.m.wikipedia.org/wiki/Enterococcus\\_faecalis](https://en.m.wikipedia.org/wiki/Enterococcus_faecalis)).

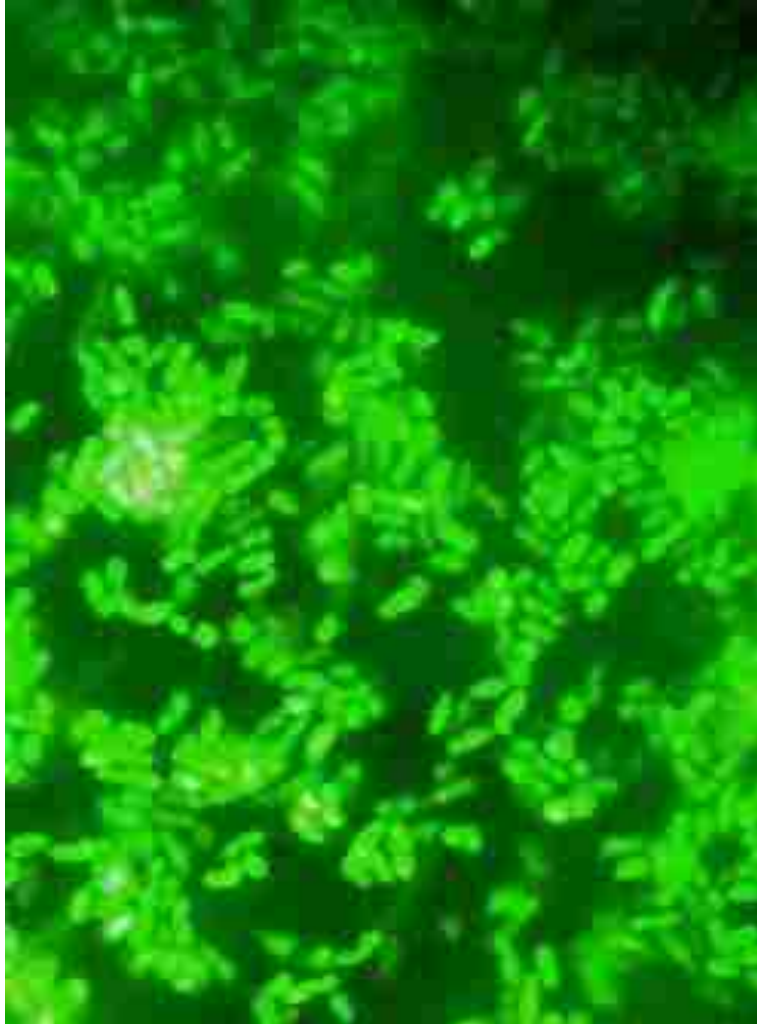


FIGURE 19. Smear of *E. faecalis* green fluorescent protein (GFP) construct (X100).



FIGURE 20. Blood agar plate (BAP) showing *E. faecalis* (left) and *E. faecalis* GFP (right) indicating green fluorescent sheen.




FIGURE 21. Placement of *E. faecalis* GFP into sterile brain heart infusion broth with yeast extract and tetracycline by Bunsen burner.



FIGURE 22. One day after broth inoculated with *E. faecalis* GFP. Sterile BHI-YE broth with tetracycline (left) and turbid broth displaying growth of *E. faecalis* GFP (right).



FIGURE 23. Apparatus samples prepared for study.



FIGURE 24. Apparatus samples in CO2 incubator.



FIGURE 25. Turbidity of lower chamber broth in GuttaCore sample (left) and GuttaCore sample that has not leaked (right).



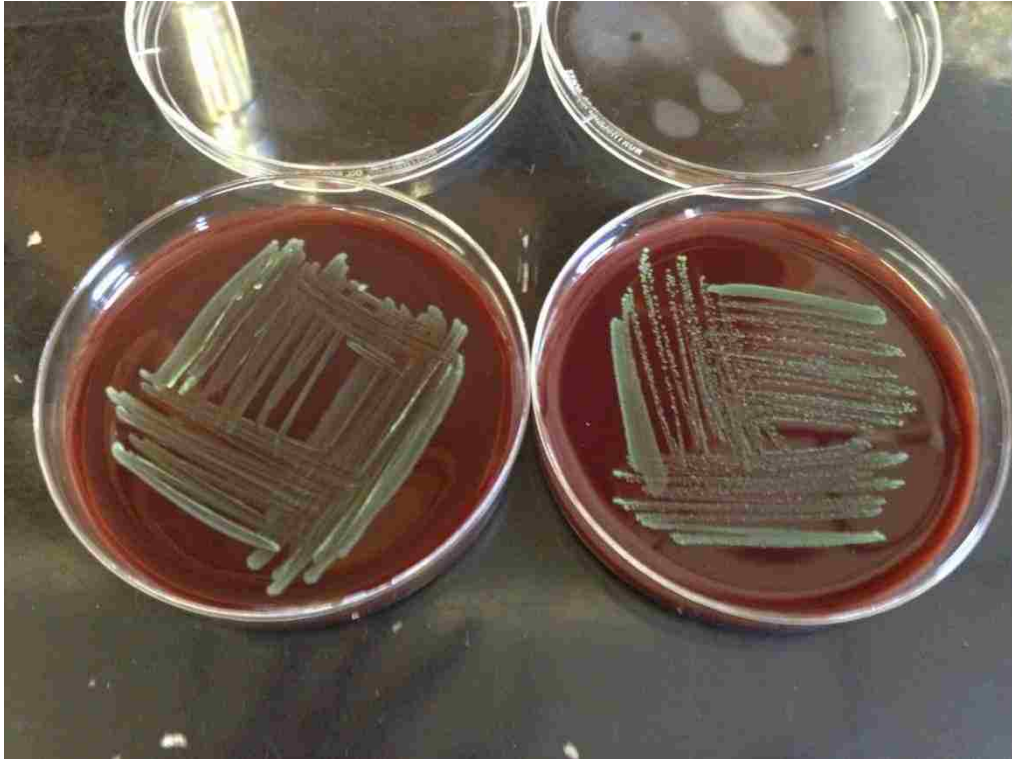


FIGURE 26. Confirmation of *E. faecalis* in lower chamber broth with culturing on BAP indicating green fluorescent sheen: GuttaCore sample (left) and stock *E. faecalis* GFP (right).

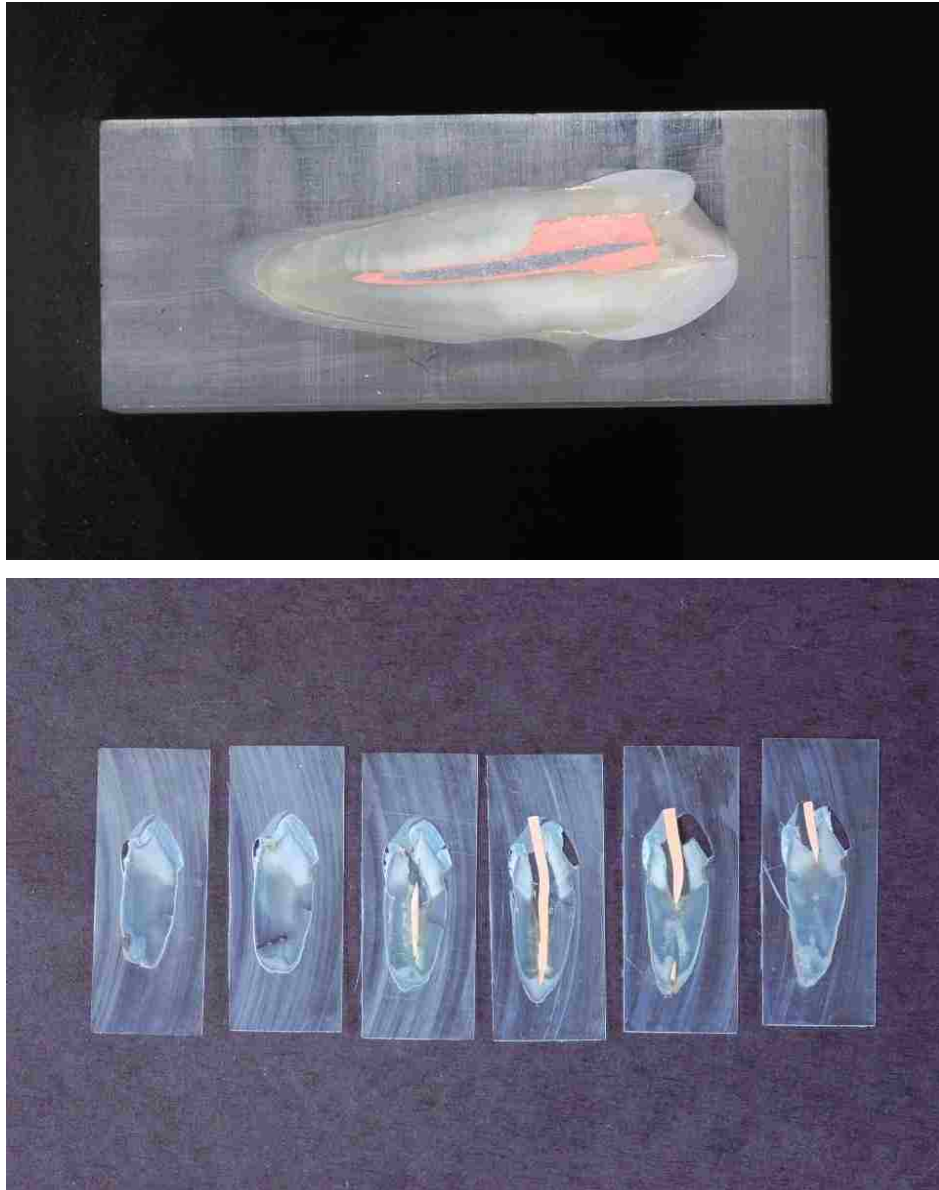


FIGURE 27. Sectioned GuttaCore obturated tooth in plastic block (top) and Gutta-percha positive control sectioned 100- $\mu\text{m}$  thick (bottom).

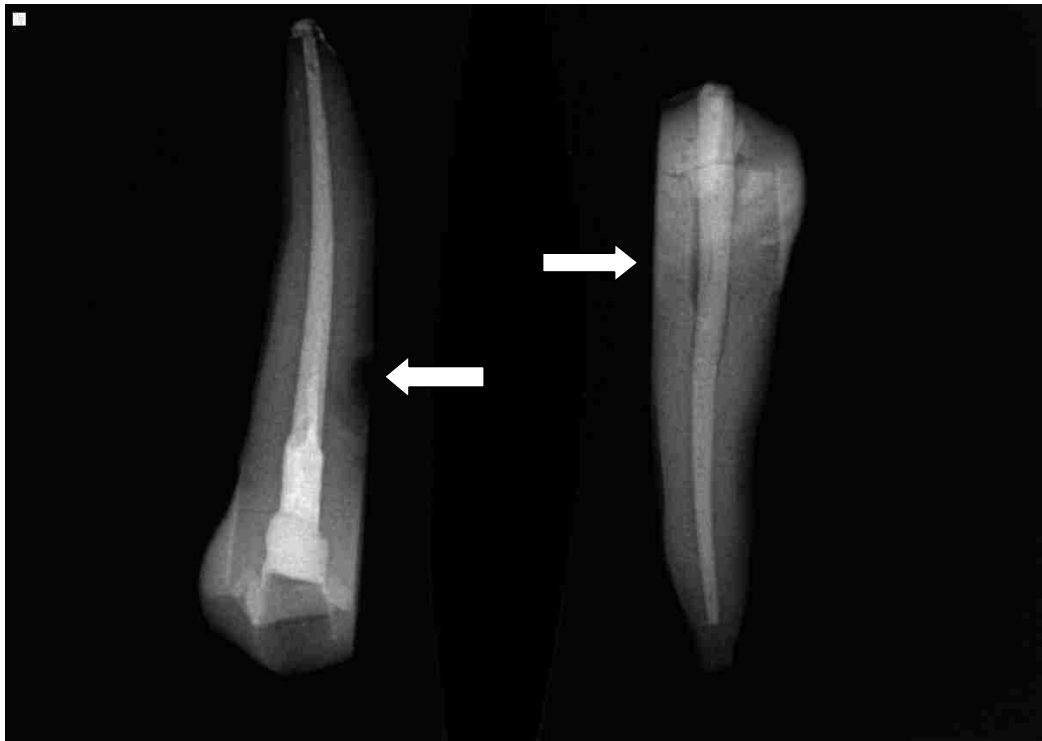

FIGURE 28. Radiograph of teeth after 40-day microleakage study: GuttaCore sample that displayed turbidity; note root surface defect (left arrow) and gutta-percha positive control that displayed turbidity (right arrow denotes path of leakage).




FIGURE 29. Fluorescent microscopy from pilot study showing *E. faecalis* GFP in dentinal tubules (top) indicated by green fluorescent aggregates and no *E. faecalis* GFP present in dentinal tubules (bottom) at X1000.




FIGURE 30. Fluorescent microscopy of GuttaCore sample with turbidity showing no *E. faecalis* GFP present in dental tubules in either coronal (top) or apical (bottom) section at X1000.

TABLE I

Microleakage for the experimental and control groups over time

Group	Microleakage, N (%)	Time to microleakage (days)
GuttaCore (n = 27)	1 (0.03%)	14
Gutta-percha ( n = 26)	0 (0%)	-
GuttaCore + controls (n = 2)	1 (50%)	38
Gutta-percha + controls (n = 2)	2 (100%)	18, 27
GuttaCore – controls (n = 2)	0 (0%)	-
Gutta-percha – controls (n = 2)	0 (0%)	-

Positive controls contained obturation material with no sealer, and negative controls were obturated with indicated core material with sealer and then coated with resin.

## DISCUSSION

The successful practice of endodontics is dependent on adequate filling and sealing of the root canal space to prevent bacterial contamination, which can lead to secondary disease or persistence of apical periodontitis. A systematic review and meta-analysis of the literature by Ng et al.<sup>103</sup> found the four factors that influenced success for primary root canal treatment included: absence of pre-operative periapical radiolucency, root canal filling with no voids, obturation of root filling to within 2 mm of the radiographic apex and an adequate coronal seal. In keeping with the theory of bacterial presence, Fabricius et al.<sup>104</sup> showed in a primate study that when no bacteria were present, healing occurred regardless of the quality of the obturation.

In a review of outcomes of endodontic treatment and retreatment, evaluation of radiographic success and failure found 58 percent of failures due to incomplete obturation.<sup>105</sup> However, Gutmann<sup>7</sup> comments that radiographic evaluation of quality of obturation does not correlate well with endodontic failure. Obturation is a reflection of cleaning and shaping and poorly obturated teeth are often poorly prepared. Consequently, after the Ingle<sup>105</sup> study, importance was placed on the development of improved obturation materials.

The radiographic evaluation of the GuttaCore and gutta-percha obturated teeth showed dense, homogenous fillings that appear to adapt to the canal walls and irregularities when viewed from a proximal perspective (see Figure 14, Figure 15). Several teeth filled with GuttaCore were excluded from the study initially due to the inability of the oven to heat the obturator appropriately to allow for proper placement to



working length. Once the heating element problem was identified and addressed, subsequent successful placement of the GuttaCore obturators was achieved.

Rechenberg et al.<sup>85</sup> reviewed published articles regarding microbial leakage through root canals and discussed the concerns inherent with leakage models and the clinical value of such studies. One major concern addresses whether bacterial leakage is through the root canal space or through other routes, including the external surface of the tooth or the interface between the upper and lower chamber seal. Rechenberg also points out the discrepancy between the leakage model filled with gutta-percha and sealer that will usually leak within weeks,<sup>106</sup> and the histological study model that finds few or no bacteria in the apical third of the roots that have been filled with gutta-percha and sealer and left open to the oral cavity for weeks.<sup>107</sup> Rechenberg questions whether this is because the leakage model is more sensitive than the histological model, or because the leakage model has inherent flaws. Only one microorganism is required to leak into the lower chamber and multiply to indicate leakage.<sup>85</sup>

Other concerns regarding microleakage studies include no mention of teeth or materials being sterilized, or the procedures did not include the use of selective media to prevent contamination. None of the studies reviewed had histologic methods that traced or confirmed the routes of leakage.<sup>85</sup> The most important concern, according to Rechenberg, was the inappropriate use of negative controls, which did not control for leakage between the two chambers. Many studies included the use of decoronized roots whose seals between the upper and lower chambers were inadequate.<sup>85</sup> Rechenberg proposed using teeth with intact crowns or leaving the apices of negative controls unsealed to assure leakage would be through the root canal.

Our two-chamber microleakage model was sterilized prior to assembly via steam autoclave (vials and caps) and ethylene oxide (obturator teeth), and after assembly via UV radiation. The selective media included tetracycline 15 µg/ml, which allowed for the growth of the tetracycline-resistant *E. faecalis* carrying a green fluorescent protein, and the use of this medium was an attempt to prevent contamination of other microbes. The sample teeth had intact crowns that allowed for complete separation of the upper and lower chambers with an adequate seal.

Wu and Wesselink's<sup>78</sup> review of endodontic leakage studies revealed an inherent problem of microbial leakage studies includes the inability to quantify the actual leakage.<sup>78</sup> When bacteria reach the lower chamber nutrient broth, they will immediately begin to multiply, complicating the ability to actually determine the amount of initial microleakage. The lack of power to detect statistical differences among the other reported disputes has led the Editorial Board of the *Journal of Endodontics* to exclude studies using microleakage models from being published.

The results of this study do show that GuttaCore obturators and warm vertical condensation of gutta-percha were equally effective. Our groups were large enough to conclude that both materials exhibited low microleakage with use of the two-chamber model. Although only three of the four positive controls revealed turbidity during the 40-day evaluation, it is the belief of the researchers that the final positive control would have leaked given additional time. The gutta-percha-filled positive controls leaked at days 18 and 27, whereas the GuttaCore positive control that did leak was on day 38, just two days prior to the conclusion of the study. The lower chamber broth from all the positive controls was confirmed to contain *E. faecalis* carrying GFP on blood agar. None of the

negative controls exhibited turbidity, which is what was expected with the teeth sealed both coronally and apically.

Of the 27 experimental gutta-percha samples, none exhibited turbidity, although one did have fungal contamination that was found in the top of the lower chamber above the nutrient media. This sample was excluded from statistical analysis, which left a sample size of 26 in the warm vertical condensation group. One out of 27 GuttaCore samples was found to have turbidity on day 14. The lower chamber broth from this GuttaCore sample was confirmed to contain *E. faecalis* carrying GFP on blood agar (see Figure 26). This was interesting to note because microleakage of the experimental model displayed microleakage before any of the positive controls. A radiograph of this GuttaCore sample was taken after the tooth was embedded in plastic and a root surface defect was found that likely contributed to the early leakage (see Figure 28).

The fact that little to no leakage occurred over the 40-day study, despite the conclusion that gutta-percha filled teeth usually leak within weeks,<sup>106</sup> is most likely a result of the pink Cavit that was used as a coronal seal. Cavit can be used to provide a temporary coronal seal, but different studies have shown varying leakage times. Barthel et al.<sup>108</sup> found 65 percent of samples demonstrated microleakage at 13 days with use of Cavit. Krakow et al.<sup>109</sup> showed Cavit could prevent bacterial contamination for up to three weeks. Longer sealing ability was found in a study that after 42 days, bacterial leakage was not found in 31 percent of samples.<sup>110</sup> Future studies using this model to test obturation materials would most likely benefit from not using a coronal filling to hasten leakage results. An adequate coronal restoration and seal is just as important as the root filling to help improve the long term prognosis of root canal therapy.<sup>111</sup> An additional

recommendation for future use of this model would be to place flowable composite along the external root surface, with the exception of the apical 3 mm, to prevent inadvertent leakage through the length of the root along the dentinal tubules.

A pilot study was conducted prior to the commencement of the thesis study to test different histologic preparation and sectioning techniques to assure the fluorescent bacteria would be visualized. This study alternatively involved complete immersion of the obturated sample tooth into culture media inoculated with *E. faecalis* GFP for one week. The results of the fluorescent microscopy showed *E. faecalis* GFP in dentinal tubules as indicated by green fluorescent aggregates in the positive control (see Figure 29). A similarly obturated tooth not subjected to *E. faecalis*-GFP-culture media showed no green fluorescent aggregates present in the dentinal tubules, which served as the negative control (see Figure 29). These findings indicated that our histologic preparation method was effective. The inability to locate *E. faecalis* GFP in either of the sectioned samples in this thesis study may be explained by Rechenberg's<sup>85</sup> previous suggestion that the leakage model is more sensitive than the histological study. Leakage into the lower chamber, as indicated by turbidity, could be due to a single microorganism that reaches the media and begins to multiply and therefore would not be able to be confirmed by histologic analysis.

SUMMARY AND CONCLUSIONS

Within the limitations of this study, there was no significant decrease in microleakage between the GuttaCore obturator and warm vertical condensation with gutta-percha. The results of this study do show that the GuttaCore obturator and warm vertical condensation of gutta-percha were equally effective. Our groups were large enough to conclude that both materials exhibited low microleakage with the use of the two-chamber microbial leakage model. Turbidity of the broth in samples that leaked was not associated with noticeable bacteria using fluorescent microscopy, which indicated that leakage may be the result of very few bacteria.

REFERENCES

1. Schilder H. Cleaning and shaping the root canal. *Dent Clin North Am* 1974;18(2):269-96.
2. Mentz TC. The use of sodium hypochlorite as a general endodontic medicament. *Int Endod J* 1982;15(3):132-6.
3. Calt S, Serper A. Time-dependent effects of EDTA on dentin structures. *J Endod* 2002;28(1):17-9.
4. Schilder H. Filling root canals in three dimensions. *Dent Clin North Am* 1967:723-44.
5. Cailleateau JG, Mullaney TP. Prevalence of teaching apical patency and various instrumentation and obturation techniques in United States dental schools. *J Endod* 1997;23(6):394-6.
6. Johnson WB. A new gutta-percha technique. *J Endod* 1978;4(6):184-8.
7. Gutmann JL, Saunders WP, Saunders EM, Nguyen L. An assessment of the plastic Thermafil obturation technique. *Int Endod J* 1993;26(3):173-8.
8. Ruddle CJ. Nonsurgical endodontic retreatment. *J Calif Dent Assoc* 2004;32(6):474-84.
9. da Silva Neto UX, de Moraes IG, Westphalen VP, Menezes R, Carneiro E, Fariniuk LF. Leakage of 4 resin-based root-canal sealers used with a single-cone technique. *Oral Surg Oral Med Oral Pathol Radiol Endod* 2007;104(2):e53-e57.
10. Cruse WP, Bellizzi R. A historic review of endodontics, 1689-1963 (Pt 1). *J Endod* 1980;6(3):495-9.
11. Johnson WT, Gutman JL. *Pathways of the pulp*. 9th ed. St. Louis, Mo.: Mosby Elsevier; 2006: 361.
12. Cruse WP, Bellizzi R. A historic review of endodontics, 1689-1963 (Pt 2). *J Endod* 1980;6(4):532-5.
13. Bellizzi R, Cruse WP. A historic review of endodontics, 1689-1963 (Pt 3). *J Endod* 1980;6(5):576-80.
14. Hess W. The anatomy of the root canals of the teeth of permanent dentition (Pt 1). New York: William Wood & Co.; 1925: 1-35.
15. Peters OA. Current challenges and concepts in the preparation of root canal systems: a review. *J Endod* 2004;30(8):559-67.



16. Cleghorn BM, Christie WH, Dong CCS. The root and root canal morphology of the human mandibular first premolar: a literature review. *J Endod* 2007;33(5):509-16.
17. Cleghorn BM, Christie WH, Dong CCS. The root and root canal morphology of the human mandibular second premolar: a literature review. *J Endod* 2007;33(9):1031-7.
18. Krasner P, Rankow HJ. Anatomy of the pulp-chamber floor. *J Endod* 2004;30(1):5-16.
19. Pineda F, Kuttler Y. Mesiodistal and buccolingual roentgenographic investigation of 7,275 root canals. *Oral Surg Oral Med Oral Pathol* 1972;33(1):101-10.
20. Schaeffer MA, White RR, Walton RE. Determining the optimal obturation length: a meta-analysis of literature. *J Endod* 2005;31(4):271-4.
21. Wu M-K, R'Oris A, Barkis D, Wesselink PR. Prevalence and extent of long oval canals in the apical third. *Oral Surg Oral Med Oral Pathol Radiol Endod* 2000;89(6):739-43.
22. VandeVisse JE, Brilliant JD. Effect of irrigation on the production of extruded material at the root apex during instrumentation. *J Endod* 1975;1(7):243-6.
23. Ibarrola JL, Chapman BL, Howard JH, Knowles KI, Ludlow MO. Effect of preflaring on Root ZX apex locators. *J Endod* 1999;25(9):625-6.
24. Roland DD, Andelin WE, Browning DF, Robert Hsu GH, Torabinejad M. The effect of preflaring on the rates of separation for 0.04 taper nickel titanium rotary instruments. *J Endod* 2002;28(7):543-5.
25. Peters OA, Peters CI, Schonenberger K, Barbakow F. Protaper rotary root canal preparation: assessment of torque and force in relation to canal anatomy. *Int Endod J* 2003;36:93-9.
26. Eldeeb ME, Boraas JC. The effect of different files on the preparation shape of severely curved canals. *Int Endod J* 1985;18(1):1-7.
27. Vera J, Arias A, Romero M. Effect of maintaining apical patency on irrigant penetration into the apical third of root canals when using passive ultrasonic irrigation: an in vivo study. *J Endod* 2011;37(9):1276-8.
28. Short JA, Morgan LA, Baumgartner JC. A comparison of canal centering ability of four instrumentation techniques. *J Endod* 1997;23(8):503-7.
29. Häikel Y, Serfaty R, Wilson P, Speisser JM, Allemann C. Mechanical properties of nickel-titanium endodontic instruments and the effect of sodium hypochlorite treatment. *J Endod* 1998;24(11):731-5.

30. Hülsmann M, Peters OA, Dummer PMH. Mechanical preparation of root canals: shaping goals, techniques and means. *Endodontic Topics* 2005;10(1):30-76.
31. Siqueira JF, Rôças IN, Santos SR, Lima KC, Magalhães FA, de Uzeda M. Efficacy of instrumentation techniques and irrigation regimens in reducing the bacterial population within root canals. *J Endod* 2002;28(3):181-4.
32. Haapasalo M, Shen Y, Qian W, Gao Y. Irrigation in endodontics. *Dent Clin North Am* 2010;54(2):291.
33. Zehnder M, Kosicki D, Luder H, Sener B, Waltimo T. Tissue-dissolving capacity and antibacterial effect of buffered and unbuffered hypochlorite solutions. *Oral Surg Oral Med Oral Pathol Radiol Endod* 2002;94(6):756-62.
34. Şen BH, Safavi KE, Spångberg LSW. Antifungal effects of sodium hypochlorite and chlorhexidine in root canals. *J Endod* 1999;25(4):235-8.
35. Hand RE, Smith ML, Harrison JW. Analysis of the effect of dilution on the necrotic tissue dissolution property of sodium hypochlorite. *J Endod* 1978;4(2):60-4.
36. Abou-Rass M, Oglesby SW. The effects of temperature, concentration, and tissue type on the solvent ability of sodium hypochlorite. *J Endod* 1981;7(8):376-7.
37. Siqueira JF, Rôças IN, Favieri A, Lima KC. Chemomechanical reduction of the bacterial population in the root canal after instrumentation and irrigation with 1%, 2.5%, and 5.25% sodium hypochlorite. *J Endod* 2000;26(6):331-4.
38. Vianna ME, Gomes BPF, Berber VB, Zaia AA, Ferraz CC, de Souza-Filho FJ. In vitro evaluation of the antimicrobial activity of chlorhexidine and sodium hypochlorite. *Oral Surg Oral Med Oral Pathol Radiol Endod* 2004;97(1):79-84.
39. Gatot A, Arbelle J, Leiberman A, Yanai-Inbar I. Effects of sodium hypochlorite on soft tissues after its inadvertent injection beyond the root apex. *J Endod* 1991;17(11):573-4.
40. McComb D, Smith DC. A preliminary scanning electron microscopic study of root canals after endodontic procedures. *J Endod* 1975;1(7):238-42.
41. Şen BH, Wesselink PR, Turkun M. The smear layer: a phenomenon in root canal therapy. *Int Endod J* 1995;28(3):141-8.
42. Shahravan A, Haghdoost A-A, Adl A, Rahimi H, Shadifar F. Effect of smear layer on sealing ability of canal obturation: a systematic review and meta-analysis. *J Endod* 2007;33(2):96-105.

43. Carver K, Nusstein J, Reader A, Beck M. In vivo antibacterial efficacy of ultrasound after hand and rotary instrumentation in human mandibular molars. *J Endod* 2007;33(9):1038-43.
44. Shen Y, Stojicic S, Qian W, Olsen I, Haapasalo M. The synergistic antimicrobial effect by mechanical agitation and two chlorhexidine preparations on biofilm bacteria. *J Endod* 2010;36(1):100-4.
45. Desai P, Himel V. Comparative safety of various intracanal irrigation systems. *J Endod* 2009;35(4):545-9.
46. Parente JM, Loushine RJ, Susin L, Gu L, Looney SW, Weller RN, et al. Root canal debridement using manual dynamic agitation or the Endovac for final irrigation in a closed system and an open system. *Int Endod J* 2010;43(11):1001-12.
47. Kakehashi S, Stanley HR, Fitzgerald RJ. The effects of surgical exposures of dental pulps in germ-free and conventional laboratory rats. *Oral Surg Oral Med Oral Pathol* 1965;20(3):340-9.
48. Moller A, Fabricius L, Dahlen G, Ohman A, Heyden G. Influence on periapical tissues of indigenous oral bacteria and necrotic pulp tissue in monkeys. *Eur J Oral Sci* 1981;89(6):475-84.
49. Sundqvist G. Associations between microbial species in dental root canal infections. *Oral Microbiol Immunol* 1992;7(5):257-62.
50. Sundqvist G, Johansson E, Sjögren U. Prevalence of black-pigmented *Bacteroides species* in root canal infections. *J Endod* 1989;15(1):13-9.
51. Baumgartner JC, Watkins BJ, Bae K-S, Xia T. Association of black-pigmented bacteria with endodontic infections. *J Endod* 1999;25(6):413-5.
52. Griffie MB, Patterson SS, Miller CH, Kafrawy AH, Newton CW. The relationship of *Bacteroides melaninogenicus* to symptoms associated with pulpal necrosis. *Oral Surg Oral Med Oral Pathol* 1980;50(5):457-61.
53. Machado de Oliveira JC, Siqueira JF, Alves GB, Hirata R, Andrade AF. Detection of *Porphyromonas endodontalis* in infected root canals by 16s rRNA gene-directed polymerase chain reaction. *J Endod* 2000;26(12):729-32.
54. Fabricius L, Dahlen G, Öhman AE, Moller AJ. Predominant indigenous oral bacteria isolated from infected root canals after varied times of closure. *Eur J Oral Sci* 1982;90(2):134-44.
55. Baumgartner JC, Falkler WA. Bacteria in the apical 5 mm of infected root canals. *J Endod* 1991;17(8):380-3.

56. Siqueira JF, ed. Treatment of endodontic infections. London: Quintessence; 2011.
57. Nair PN, Sjögren U, Krey G, Kahnberg K, Sundqvist G. Intraradicular bacteria and fungi in root-filled, asymptomatic human teeth with therapy-resistant periapical lesions: a long-term light and electron microscopic follow-up study. *J Endod* 1990;16(12):580-8.
58. Baumgartner JC, Watts CM, Xia T. Occurrence of *Candida albicans* in infections of endodontic origin. *J Endod* 2000;26(12):695-8.
59. Siqueira JF, Sen BH. Fungi in endodontic infections. *Oral Surg Oral Med Oral Pathol Radiol Endod* 2004;97(5):632-41.
60. Tronstad L, Barnett F, Riso K, Slots J. Extraradicular endodontic infections. *Dent Traumatol* 1987;3(2):86-90.
61. Nair PN. Apical periodontitis: A dynamic encounter between root canal infection and host response. *Periodontol* 2000 1997;13(1):121-48.
62. Ferreira DC, Paiva SSM, Carmo FL, et al. Identification of herpes viruses types 1 to 8 and human papillomavirus in acute apical abscesses. *J Endod* 2011;37(1):10-6.
63. Kaufman B, Spångberg L, Barry J, Fouad AF. Enterococcus spp. in endodontically treated teeth with and without periradicular lesions. *J Endod* 2005;31(12):851-6.
64. Siqueira JF, Jr. Treatment of endodontic infections. Quintessence Publishing; 2011.
65. Aymanns S, Mauerer S, van Zandbergen G, Wolz C, Spellerberg B. High-level fluorescence labeling of gram-positive pathogens. *PLoS ONE* 2011;6(6):e19822.
66. Pérez-Arellano I, Pérez-Martínez G. Optimization of the green fluorescent protein (gfp) expression from a lactose-inducible promoter in *Lactobacillus casei*. *FEMS Microbiol Lett* 2003;222(1):123-7.
67. Ørstavik D, Ford TP. Essential endodontology: prevention and treatment of apical periodontitis. Blackwell Munksgaard; 2008.
68. Siqueira JF. Aetiology of root canal treatment failure: why well-treated teeth can fail. *Int Endod J* 2001;34(1):1-10.
69. Grossman LI. Physical properties of root canal cements. *J Endod* 1976;2(6):166-75.
70. McElroy D. Physical properties of root canal filling materials. *J Am Dent Assoc* 1955;50(4):433-40.

71. Friedman CE, Sandrik JL, Heuer MA, Rapp GW. Composition and physical properties of gutta-percha endodontic filling materials. *J Endod* 1977;3(8):304-8.
72. Goodman A, Schilder H, Aldrich W. The thermomechanical properties of gutta-percha. (Pt 2). The history and molecular chemistry of gutta-percha. *Oral Surg Oral Med Oral Pathol* 1974;37(6):954-61.
73. Senia ES, Marraro RV, Mitchell JL, Lewis AG, Thomas L. Rapid sterilization of gutta-percha cones with 5.25% sodium hypochlorite. *J Endod* 1975;1(4):136-40.
74. Peng L, Ye L, Tan H, Zhou X. Outcome of root canal obturation by warm gutta-percha versus cold lateral condensation: a meta-analysis. *J Endod* 2007;33(2):106-9.
75. Harrison JW, Baumgartner JC, Svec TA. Incidence of pain associated with clinical factors during and after root canal therapy. (Pt 2). Postobturation pain. *J Endod* 1983;9(10):434-8.
76. Baumgardner K, Taylor J, Walton R. Canal adaptation and coronal leakage: lateral condensation compared to thermafil. *J Am Dent Assoc* 1995;126(3):351-6.
77. Shemesh H, Van Den Bos M, Wu MK, Wesselink PR. Glucose penetration and fluid transport through coronal root structure and filled root canals. *Int Endod J* 2007;40(11):866-72.
78. Wu MK, Wesselink PR. Endodontic leakage studies reconsidered. (Pt 1). Methodology, application and relevance. *Int Endod J* 1993;26(1):37-43.
79. Pashley DH, Andringa HJ, Derkson GD, Derkson ME, Kalathoor SR. Regional variability in the permeability of human dentine. *Arch Oral Biol* 1987;32(7):519-23.
80. Wu M, Gee A, Wesselink P, Moorer W. Fluid transport and bacterial penetration along root canal fillings. *Int Endod J* 1993;26(4):203-8.
81. Xu Q, Fan M-w, Fan B, Cheung GS, Hu H-l. A new quantitative method using glucose for analysis of endodontic leakage. *Oral Surg Oral Med Oral Pathol Radiol Endod* 2005;99(1):107-11.
82. Shemesh H, Wu MK, Wesselink P. Leakage along apical root fillings with and without smear layer using two different leakage models: a two-month longitudinal ex vivo study. *Int Endod J* 2006;39(12):968-76.
83. Mortensen DW, Boucher NE, Ryge G. A method of testing for marginal leakage of dental restorations with bacteria. *J Dent Res* 1965;44(1):58-63.

84. Goldman LB, Goldman M, Kronman JH, Letourneau JM. Adaptation and porosity of poly-hema in a model system using two microorganisms. *J Endod* 1980;6(8):683-6.
85. Rechenberg DK, De-Deus G, Zehnder M. Potential systematic error in laboratory experiments on microbial leakage through filled root canals: review of published articles. *Int Endod J* 2011;44(3):183-94.
86. DeWald JP. The use of extracted teeth for in vitro bonding studies: a review of infection control considerations. *Dent Mater* 1997;13(2):74-81.
87. Söderholm KJM. Correlation of in vivo and in vitro performance of adhesive restorative materials: a report of the ASC MD156 task group on test methods for the adhesion of restorative materials. *Dent Mater* 1991;7(2):74-83.
88. Rueggeberg FA. Substrate for adhesion testing to tooth structure -- review of the literature: a report of the ASC MD156 task group on test methods for the adhesion of restorative materials accredited standards committee MD156 for dental materials and devices. *Dent Mater* 1991;7(1):2-10.
89. Goodis HE, Marshall Jr GW, White JM, Gee L, Hornberger B, Marshall SJ. Storage effects on dentin permeability and shear bond strengths. *Dent Mater* 1993;9(2):79-84.
90. Fujisawa S, Kadoma Y. Effect of phenolic compounds on the polymerization of methyl methacrylate. *Dent Mater* 1992;8(5):324-6.
91. Haller B, Hofmann N, Klaiber B, Bloching U. Effect of storage media on microleakage of five dentin bonding agents. *Dent Mater* 1993;9(3):191-7.
92. Delgado AA, Schaaf NG. Dynamic ultraviolet sterilization of different implant types. *J Oral Maxil Implant* 1990;5:117-25.
93. Torabinejad M, Walton R. *Endodontics principles and practice*. 4th ed. St. Louis: Saunders Elsevier; 2009.
94. Thomas RZ, Ruben JL, ten Bosch JJ, Huysmans M. Effect of ethylene oxide sterilization on enamel and dentin demineralization in vitro. *J Dent* 2007;35(7):547-51.
95. Pashley EL, Tao L, Pashley DH. Sterilization of human teeth: its effect on permeability and bond strength. *Am J Dent* 1993;6(4):189-91.
96. Hays G, White R. Ethylene oxide sterilization/disinfection of teeth for education and research. In: *Transmissions*. 1994. p. 1.
97. White RR, Hays GL. Failure of ethylene oxide to sterilize extracted human teeth. *Dent Mater* 1995;11(4):231-3.

98. Stanford CM, Keller JC, Solursh M. Bone cell expression on titanium surfaces is altered by sterilization treatments. *J Dent Res* 1994;73(5):1061-71.
99. Setlow P. Spores of *Bacillus subtilis*: their resistance to and killing by radiation, heat and chemicals. *J Appl Microbiol* 2006;101(3):514-25.
100. Torabinejad M, Ung B, Kettering JD. In vitro bacterial penetration of coronally unsealed endodontically treated teeth. *J Endod* 1990;16(12):566-9.
101. Torabinejad M, Rastegar AF, Kettering JD, Pitt Ford TR. Bacterial leakage of mineral trioxide aggregate as a root-end filling material. *J Endod* 1995;21(3):109-12.
102. Nazzal JF. An in-vitro comparison of bacterial microleakage of zinc-oxide eugenol and Brasseler bioceramic sealer. [Thesis]. Indianapolis: Indiana University School of Dentistry; 2011.
103. Ng YL, Mann V, Rahbaran S, Lewsey J, Gulabivala K. Outcome of primary root canal treatment: systematic review of the literature. (Pt 2). Influence of clinical factors. *Int Endod J* 2008;41(1):6-31.
104. Fabricius L, Dahlén G, Sundqvist G, Happonen R-P, Möller ÅJ. Influence of residual bacteria on periapical tissue healing after chemomechanical treatment and root filling of experimentally infected monkey teeth. *Eur J Oral Sci* 2006;114(4):278-85.
105. Ingle JI, Simon JH, Machtou P, Bogaerts P. Outcome of endodontic treatment and retreatment. Philadelphia: Lea & Febiger; 2002.
106. Torabinejad M, Ung B, Kettering JD. In vitro bacterial penetration of coronally unsealed endodontically treated teeth. *J Endod* 1990;16(12):566-9.
107. Ricucci D, Bergenholtz G. Bacterial status in root-filled teeth exposed to the oral environment by loss of restoration and fracture or caries – a histobacteriological study of treated cases. *Int Endod J* 2003;36(11):787-802.
108. Barthel CR, Strobach A, Briedigkeit H, Göbel UB, Roulet J-F. Leakage in roots coronally sealed with different temporary fillings. *J Endod* 1999;25(11):731-4.
109. Krakow AA, deStoppelaar JD, Grøn P. In vivo study of temporary filling materials used in endodontics in anterior teeth. *Oral Surg Oral Med Oral Pathol* 1977;43(4):615-20.
110. Lamers AC, Simon M, van Mullem PJ. Microleakage of cavity temporary filling material in endodontic access cavities in monkey teeth. *Oral Surg Oral Med Oral Pathol* 1980;49(6):541-3.

111. Gillen BM, Looney SW, Gu L-S, et al. Impact of the quality of coronal restoration versus the quality of root canal fillings on success of root canal treatment: a systematic review and meta-analysis. *J Endod* 2011;37(7):895-902.



ABSTRACT

AN *IN-VITRO* COMPARISON OF BACTERIAL MICROLEAKAGE OF  
GUTTA-PERCHA AND THE GUTTACORE CROSS-LINKED  
GUTTA-PERCHA CORE OBTURATOR

by

Abigail C. Edds

Indiana University School of Dentistry  
Indianapolis, Indiana

Root canal therapy requires three important steps accomplished in concert to achieve long-term success: canal shaping, disinfection, and obturation. Traditionally gutta-percha has been used with sealer in a cold lateral condensation technique. Schilder introduced the concept of warm vertical compaction of gutta-percha in 1967 to attempt to obturate more canal irregularities. Johnson presented the use of stainless steel files with thermally plasticized gutta-percha in 1978, and later the metal carrier was changed to plastic and named Thermafil. Thermafil has shortcomings in that it does not always fulfill Grossman's obturation material properties, such as apical extent of the material (extrusion) and ease of retreatment.

A new obturation material by Dentsply Tulsa, the GuttaCore cross-linked gutta-percha core obturator, has been introduced that replaces the plastic core with a cross-linked gutta-percha core. The manufacturer states removal of the obturation material and

core is fast and easy. To date, no microleakage studies have been done to test this newer obturation material.

Methods used to study microleakage have included the use of dyes, radioisotopes, electrochemicals, fluid filtration, and microorganisms. A microbial leakage model has been constructed using a modified two-chamber apparatus as described by Torabinejad et al. and has been used successfully.

Green fluorescent protein (GFP) from the jellyfish *Aequorea victoria* is useful as a bacterial label because the fluorescent marker can be exhibited in the bacterial host without having to use stains. A plasmid that encodes for a copy of the green fluorescent variant gene was transferred into the *E. faecalis*. The marker glows green under a standard fluorescence microscope and has been used successfully to evaluate microleakage.

The purpose of this investigation was to evaluate the sealing ability of a new obturation material, GuttaCore, to determine if there will be a significant decrease in microleakage of AH Plus with GuttaCore obturator versus AH Plus with gutta-percha.

Sixty-two human, single-rooted premolars extracted for periodontal considerations were accessed and instrumented for non-surgical root canal therapy. Hand and rotary instrumentation was accomplished to MAF size 40.04, and irrigation was accomplished with 6.0-percent NaOCl and 17-percent EDTA with use of EndoActivator.

Teeth were randomly assigned to two experimental groups of 27 teeth each. Group I (conventional method) teeth were obturated with gutta-percha and AH Plus sealer using warm vertical condensation, and Group II (test method) teeth were obturated with GuttaCore and AH Plus sealer. Two control groups containing four teeth each

served as positive and negative controls. The positive and negative control groups ensured that the microleakage model was working correctly.

The teeth were evaluated for microbial microleakage of *E. faecalis* green fluorescent protein (GFP) construct using a dual chamber leakage model. If turbidity is observed in the lower chamber, it will indicate microleakage and an inadequate seal of the obturation method. The teeth were sectioned and viewed with a standard fluorescence microscope to determine the depth of microleakage utilizing the inherent fluorescence of the *E. faecalis* GFP construct.

No microleakage was observed in the negative control groups. Microleakage was observed in both gutta-percha positive control groups and in one of the two GuttaCore positive control groups. One of 27 GuttaCore samples displayed turbidity, which occurred at day 14. None of the 26 gutta-percha samples displayed turbidity at any point. The 95-percent confidence intervals (CI) for the percentage of samples with turbidity were 0.1 percent to 19 percent for GuttaCore and 0.0 percent to 13.2 percent for gutta-percha using a Fisher's Exact Test. The two groups did not have a significantly different percentage of samples with turbidity ( $p = 1.00$ ). No *E. faecalis* GFP was visualized under fluorescent microscopy in either the turbid GuttaCore sample or the gutta-percha positive control in the apical, middle or coronal thirds. Both samples that demonstrated microleakage had confirmation that the lower chamber broth contained *E. faecalis* GFP when cultured on blood agar plates.

Within the limitations of this study, there was no significant decrease in microleakage between the GuttaCore obturator and warm vertical condensation with gutta-percha. Turbidity of the broth in samples that leaked was not associated with

noticeable bacteria when using fluorescent microscopy, which indicated that leakage may be the result of very few bacteria.

## CURRICULUM VITAE

Abigail C. Edds

August 1993 to May 1997	BA, Sociology, University of Louisville, Louisville, KY
August 1999 to May 2003	DMD, University of Louisville School of Dentistry, Louisville, KY
July 2003 to June 2004	General Practice Residency (GPR), Indiana University School of Dentistry, Indianapolis, IN
July 2004 to June 2011	General Dentist, Indiana Family Dentistry, Brownsburg, IN
June 2011 to June 2013	MSD in Endodontics, Indiana University School of Dentistry, Indianapolis, IN

Professional Organizations

American Association of Endodontists (AAE)  
American Dental Association (ADA)  
Indiana Dental Association (ADA)