

ANTIBACTERIAL EFFICACY OF 0.12-PERCENT AND 2.0-PERCENT  
CHLORHEXIDINE GLUCONATE AT 37°C AND 46°C  
AGAINST *ENTEROCOCCUS FAECALIS*

by

Craig B.D. Thiessen

Submitted to the Graduate Faculty of the School of  
Dentistry in partial fulfillment of the requirements  
for the degree of Master of Science in Dentistry,  
Indiana University School of Dentistry, 2010.

Thesis accepted by the faculty of the Department of Endodontics, Indiana University School of Dentistry, in partial fulfillment of the requirements for the degree of Master of Science in Dentistry.

---

Joseph Legan

---

Richard Gregory

---

Susan Zunt

---

Mychel Vail

Chair of Research Committee

---

Kenneth Spolnik

Program Director

Date \_\_\_\_\_

ACKNOWLEDGMENTS

I would like to start off by thanking my family and friends for all their support and words of encouragement throughout this endeavor. I am grateful for my mentors, including both full-time and part-time faculty members who contributed tremendously towards my dental education. I would also like to thank everyone else who helped me obtain this defining moment in my career. An additional thanks goes to the members of my research committee, who have dedicated their valuable time and support. For my co-residents, a special thanks for all the help in all aspects of my dental career and life. I appreciate your friendship and support. Finally, I would like to thank the Graduate Endodontic staff for their hard work and for making the clinic an enjoyable place to treat patients.

TABLE OF CONTENTS

Introduction.....	1
Review of Literature .....	5
Materials and Methods.....	53
Results.....	59
Tables and Figures .....	61
Discussion.....	99
Summary and Conclusions .....	105
References.....	108
Abstract.....	121
Curriculum Vitae	

LIST OF ILLUSTRATIONS

FIGURE 1	Summary of experimental design .....	62
FIGURE 2	Initial sectioning of clinical crown with carborundum disk .....	63
FIGURE 3	Sectioning tooth to 5-mm sections in apparatus.....	64
FIGURE 4	Final section of 5-mm dentin disk section in apparatus .....	65
FIGURE 5	Measurement of dentin specimen in calipers .....	66
FIGURE 6	Close-up of 5-mm mark on calipers .....	67
FIGURE 7	Heavy duty drill press used to prepare lumens in dentin specimens.....	68
FIGURE 8	Close-up of ISO 025 bur in drill press and dentin specimen.....	69
FIGURE 9	Close-up of 2.5-mm diameter lumen prepared in dentin specimen.....	70
FIGURE 10	Ultrasonic unit used to aid in the removal of the smear layer .....	71
FIGURE 11	Specimens mounted in individual 22-mm diameter sterile tissue wells in 6 well plates.....	72
FIGURE 12	<i>Enterococcus faecalis</i> (ATCC 29212) used in this experiment .....	73
FIGURE 13	<i>E. faecalis</i> streak plate on BHI agar plate .....	74
FIGURE 14	Sterile BHI broth – clear.....	75
FIGURE 15	<i>E. faecalis</i> inoculated BHI broth – cloudy .....	76
FIGURE 16	Comparison of sterile (clear) and inoculated (cloudy) BHI broth.....	77
FIGURE 17	Inoculation of the dentin specimens with <i>E. faecalis</i> .....	78
FIGURE 18	Schematic drawing of specimen within the tissue well.....	79
FIGURE 19	Bunsen burner work station.....	80
FIGURE 20	Incubator settings at either 37°C or 46°C with 5-percent CO <sub>2</sub> .....	81
FIGURE 21	Saline, 0.12-percent CHX, and 2.0-percent CHX .....	82



FIGURE 22	Scale used to measure dentin specimens .....	83
FIGURE 23	Mortar and pestle used in conjunction with liquid nitrogen to pulverize the dentin specimens .....	84
FIGURE 24	Vortex used in at highest setting .....	85
FIGURE 25	Overall view of Sonicator used in this experiment .....	86
FIGURE 26	Spiral System used to spiral plate <i>E. faecalis</i> on the BHI agar plates.....	87
FIGURE 27	Spiral plate of <i>E. faecalis</i> at 1:100 dilution .....	88
FIGURE 28	Spiral plate of <i>E. faecalis</i> at 1:100 dilution .....	89
FIGURE 29	Spiral plate of <i>E. faecalis</i> at 1:1000 dilution .....	90
FIGURE 30	Spiral plate of <i>E. faecalis</i> at 1:1000 dilution .....	91
FIGURE 31	Overview of ProtoCol automated colony counter .....	92
FIGURE 32	Computer settings for ProtoCol automated colony counter .....	93
FIGURE 33	BHI agar spiral plate within ProtoCol automated colony counter .....	94
FIGURE 34	BHI agar spiral plate within ProtoCol automated colony counter being scored (green dots) four times to acquire mean for data analysis .....	95
TABLE I	Percentage loss of bacteria subjected to -70°C with subsequent treatment with liquid nitrogen.....	96
TABLE II	Summary of statistical data .....	97
TABLE III	Summary of statistical data in graph form .....	98

## INTRODUCTION

Successful endodontic therapy is dependent on the health status of the periradicular tissues. Studies by Kakehashi, Stanley, and Fitzgerald demonstrated the importance of bacteria in pulpal pathosis.<sup>1</sup> They demonstrated that pulpal and periapical pathosis does not occur in the absence of bacteria. Therefore, eliminating microorganisms from the root canal system through the use of biomechanical cleaning and shaping, various irrigation solutions, and intracanal medicaments is essential in eliminating endodontic infections.<sup>2-5</sup>

The anatomical complexity of the root canal system includes variations in canal length and curvatures, calcifications and pulp stones, isthmuses and fins, and lateral and accessory canals. Organic residues and bacteria located within the dentinal tubules cannot be sufficiently eliminated with hand and rotary instrumentation alone. Therefore, various irrigation solutions and intracanal medicaments are used during and after root canal preparation to reduce debris, necrotic pulp tissue, and microorganisms.<sup>6</sup> Sodium hypochlorite (NaOCl), chlorhexidine gluconate (CHX), and calcium hydroxide are widely used medicaments that have distinct characteristics including antimicrobial activity towards bacteria within infected root canal systems.<sup>7-10</sup>

While sodium hypochlorite is the most commonly used endodontic irrigation solution, other irrigation solutions such as CHX have proven to be effective during root canal therapy. There have been several studies stating the antibacterial properties of CHX as an endodontic irrigation solution.<sup>2, 6, 9</sup> This antibacterial efficacy is dependent on the concentration of the irrigation solution used. A 2.0-percent CHX solution was stated

to be more effective than a 0.12-percent CHX solution.<sup>11, 12</sup> A solution of 2.0-percent CHX has also been proven to be very effective in eliminating *E. faecalis*,<sup>13</sup> therefore, CHX may offer a clinically significant benefit during root canal therapy. A unique property of CHX is its substantivity effect, that at higher concentrations (2.0 percent) it demonstrates antimicrobial activity up to 72 hours after its removal from the root canal system.<sup>14</sup>

*Enterococcus faecalis* is a common microorganism in endodontic infections. Stuart et al.<sup>15</sup> stated that *E. faecalis* contains several virulence factors to compete with other microorganisms, invade dentinal tubules, and resist nutritional deprivation to cause periradicular disease. The use of proper aseptic technique, adequate apical preparation sizes, and copious amounts of 6 percent NaOCl and 2.0 percent CHX irrigation solutions are the most effective methods to eliminate *E. faecalis*. Therefore, continued research regarding *E. faecalis* and its elimination from the root canal system has clinical significance.

Several studies have reported that increasing the temperature of sodium hypochlorite can enhance its antimicrobial efficacy. Abou-Rass and Oglesby<sup>16</sup> stated that a higher concentration of NaOCl (5.25%) was more effective than a lower (2.6%) concentration, and that regardless of the concentration tested, heating the NaOCl was more effective at dissolving tissue. Evanov et al.<sup>17</sup> demonstrated that heat (46°C) enhanced the antimicrobial efficacy of both 10 percent calcium hydroxide and 0.12 percent CHX towards *E. faecalis* relative to saline (positive control) and to either experimental medication at 37°C. To date there have not been any published articles that

describe the heating of 2.0 percent CHX and its antimicrobial efficacy and clinical relevance towards *E. faecalis*, within dentinal tubules in root canal systems.

#### PURPOSE OF THE PRESENT STUDY

The purpose of this study was to investigate the antibacterial efficacy of 0.12-percent and 2.0-percent chlorhexidine gluconate (CHX) on eliminating *Enterococcus faecalis* from dentinal tubules, and whether this antibacterial effect was enhanced by heat.

#### HYPOTHESES

Null hypothesis: No statistically significant difference exists between the antibacterial efficacy of 0.12-percent CHX and 2.0-percent CHX on eliminating *E. faecalis* from dentinal tubules at ambient temperature (24°C).

Null hypothesis: No statistically significant difference exists between the antibacterial efficacy of 0.12-percent CHX and 2.0-percent CHX on eliminating *E. faecalis* from dentinal tubules at experimental temperature (46°C).

Alternative hypothesis: A statistically significant difference exists between the antibacterial efficacy of 0.12-percent CHX and 2.0-percent CHX on eliminating *E. faecalis* from dentinal tubules at ambient temperature (24°C).

Alternative hypothesis: A statistically significant difference exists between the antibacterial efficacy of 0.12-percent CHX and 2.0-percent CHX on eliminating *E. faecalis* from dentinal tubules at experimental temperature (46°C).

REVIEW OF LITERATURE

## HISTORY OF ENDODONTICS

The presence of odontogenic pain has occurred throughout the history of mankind. Fu His (2953 BC) is credited with one of the earliest surviving descriptions of several types of toothaches including pain caused by cold and mastication.<sup>18</sup>

Descriptions of remedies to cure toothaches have appeared on Egyptian tablets, Hebrew Bibles, and Greek, Roman, and Chinese medical writings.<sup>19</sup> The Chinese dating back to the 14<sup>th</sup> century BC theorized that dental disease was caused by tooth worms. This theory remained until it was disproved by the use of microscopes. In 1728 Pierre Fauchard, the founder of modern dentistry, wrote *The Surgeon Dentist*. This book provided accurate descriptions of pulp cavities and root canals. He refuted the notion of the tooth worm theory by describing a technique in which the pulp chamber is accessed to facilitate pulp extirpation and abscess drainage followed by lead fillings of the pulp chamber.<sup>20</sup> This then led to pulp-capping procedures by Phillip Pfaff in 1756. He cut out pieces of either gold or lead and placed them over exposed pulp tissue to prevent the metal restoration from contacting the exposed nerve. Bourdet in 1757 described a procedure for extracting carious teeth, filling the root canal with gold or lead, and replanting them.<sup>20</sup> It wasn't until Robert Woofendale in 1766 that the first endodontic procedure in this country was recorded, in which he cauterized the pulp with a hot instrument.

Several advances in the field of endodontics changed the way root canal therapy was performed. In 1838 Edwin Maynard took a watch spring and filed it down to make

the first broach to remove the pulp tissue from within the root canal.<sup>21</sup> In 1847 Edwin Truman introduced gutta-percha as a filling and denture base material, but it wasn't until G.A. Bowman in 1867 that gutta-percha points were utilized as root canal filling material.<sup>22</sup> Bowman was also credited with the rubber dam clamp after the invention of the rubber dam by S.C. Barnum in 1864. This advent of the rubber dam allowed for aseptic technique to control and prevent infection.<sup>18</sup>

The discovery of x-rays by Wilhelm Konrad Roentgen in 1895 drastically changed the accuracy of medical and dental diagnosis. Two weeks after his discovery, Otto Walkhoff took radiographs of his own teeth for diagnostic purposes. Edmund Kells used radiographs not only for diagnosis but during endodontic treatment as well. The very first radiograph he took was of a lead wire that he placed in a root canal to determine whether it fit the canal satisfactorily.<sup>22, 23</sup> The first dental x-ray machine did not make its appearance until 1913, however, and the first dental x-ray unit as we know it today was not introduced until 1917. Even as late as 1940, only 75 percent of dental offices utilized an x-ray machine.<sup>24</sup> Since then, several advances in technology have reduced the exposure times and increased the image quality exponentially.

Another epoch-making discovery was made in 1884, when Carl Koller was the first to use cocaine as a topical anesthetic. Within one year, William Halsted used a similar solution by performing a mandibular block injection. In 1890 Funk introduced pressure anesthesia for pulp removal using crystals of cocaine.<sup>22, 23</sup> All these forms of anesthetics had undesirable side effects such as sloughing and syncope, which limited their use in dentistry. The development of Novocaine in 1905 by Einhorn gave dentistry and especially endodontics a more effective and less toxic anesthetic compared with



cocaine. Currently, the use of ester anesthetics such as Novocaine and cocaine has limited applications today. Since the advent of amide local anesthetics, the majority of unwanted side effects have been eliminated.<sup>25</sup>

In the early 1900s endodontic therapy gained increased acceptance due to the advances in new technologies, materials, and techniques. This acceptance, however, was challenged by the focal infection theory advocated for and directly applied to dentistry in 1910 by William Hunter. His lecture entitled “The role of Sepsis and Antisepsis in Medicine,” accused dentists of creating a “veritable mausoleum of gold over a mass of sepsis” that led to multiple systemic diseases.<sup>25</sup> The focal infection theory was based on culture results from extracted teeth with little regard for the possibility the bacteria recovered may have been part of the normal flora of the oral cavity. This resulted in the needless extraction of millions of pulpless and healthy teeth to prevent focal infection and the discontinued teaching of endodontics in some dental schools.<sup>18, 23</sup>

The leaders of the dental profession challenged the focal infection theory and defended root canal treatment in the 1930s. Edward C. Kirk<sup>22</sup> wrote in the *Dental Cosmos*: “We are not now and never have been willing to acknowledge the implication that the root canal operation is a failure. To the contrary we have consistently maintained that the great majority of pulpless teeth could be saved by root canal surgery at the hands of the expert operator.” Likewise, C.N. Johnson began to speak out against the wholesale extractions of all pulpless teeth.<sup>25</sup> The work done by Logan in 1937 demonstrated that the presence of microorganisms did not necessarily imply the presence of infection, and that some bacterial presence is normal. This was one of the major contributions toward

placing the focal infection theory into proper perspective.<sup>26</sup> This proved the importance of laboratory research and clinical evidence and the start of evidence-based dentistry.

During the 1940s and 1950s root canal therapy again continued to gain acceptance within the dental and medical community. It was during this time that endodontists developed into a specialty. The term endodontics is from the Greek *en*, or within, and *odous*, or tooth.<sup>27</sup> This term was coined by Harry B. Johnson who created the first practice “limited to endodontics.” In 1943 a group of 20 dentists met in Chicago with the goal of creating an organization of endodontists. The result of their meeting was The American Association of Endodontists and its standards with four goals in mind:

1. To promote interchange of ideas on methods of pulp conservation and root canal treatment.
2. To stimulate research studies, both clinical and laboratory, among its members.
3. To assist in establishing local root canal study clubs.
4. To help maintain a high standard of root canal practice within the profession by disseminating information through lectures, clinics, and publications.<sup>23</sup>

In 1946 the first *Journal of Endodontics* was published, limited to the practice of endodontics. As the association grew, in 1956 the American Board of Endodontics was established, followed by the recognition of endodontics as a specialty in 1963 by the American Dental Association.

## ENDODONTIC THEORY

The specialty of endodontics is concerned with the morphology, physiology, and pathology of the dental pulp and periapical tissues.<sup>28</sup> The objective of endodontic therapy is to prevent and cure apical pathosis with the goal of restoring and retaining the tooth in a healthy state to allow for proper form and function in the masticatory apparatus.<sup>29</sup> Successful endodontic therapy is therefore dependent on the health status of the periradicular tissues from the adequate removal of bacteria from the root canal system.

Beginning in 1890 Miller<sup>30</sup> demonstrated the presence of different types of bacteria associated with pulpal disease in causing apical periodontitis. However, the true correlation between pulpal pathosis and bacteria was discovered in 1965 by Kakehashi et al.<sup>1</sup> This classic study proved that pulpal and periapical pathosis does not occur in the absence of bacteria. Therefore, eliminating microorganisms from the root canal system through the use of biomechanical cleaning and shaping, various irrigation solutions, and intracanal medicaments are essential in healing endodontic infections. Thorough attention should be given to these phases of treatment to acquire successful outcomes.

The importance of chemo-mechanical preparation was demonstrated in 1955 by Stewart.<sup>31</sup> He divided root canal therapy into three distinct phases: chemo-mechanical preparation, microbial control, and the complete obturation of the root canal system. Although his study concluded that the most important phase of endodontic treatment was primarily from the chemo-mechanical preparation, each phase is important for the proper healing of the periodontium. Enlarging the shape and taper of the canal, the removal of debris, and the reduction of the viable number of bacteria is enhanced by the efficient delivery of irrigation solutions and intracanal medicaments. In his study, Stewart

determined root canal success by obtaining a negative culture before obturation.

However, he stated that the ultimate criteria for success are determined by clinical responses, such as relief of pain and swelling, healing of a fistula, healthy supporting tissue, and radiographic healing of any periapical pathosis.

In 1967 Grossman<sup>32</sup> discussed 14 principles to be used as guidelines to attain maximum success with endodontic therapy. These include:

1. Aseptic technique should be followed.
2. Instrumentation should be confined within the root canal.
3. The root canal should be entered by a fine, smooth canal instrument, and never forced apically.
4. Biomechanical instrumentation is required to enlarge the canal space from its original size.
5. The canal should be continuously irrigated with an antiseptic solution during instrumentation to:
  - a. Serve as a lubricant.
  - b. Diminish the amount of microorganisms.
  - c. To facilitate the removal of dentinal shavings.
6. The antimicrobial irrigation solution should remain within the canal space and be non-irritating to the periapical tissue.
7. A fistula requires no special treatment as it will heal after the source of infection is removed.
8. A negative culture should be obtained before obturation.

9. A hermetic seal must be obtained during obturation at the cemento-dentinal junction.
10. Obturation material should be non-irritating to the periapical tissue.
11. Drainage must be established with an acute alveolar abscess.
12. Drainage may be via the root canal alone or by an incision into the soft tissue.
13. Avoid injections in the area of infection to prevent the spread of microorganisms into deeper tissue.
14. Not all pulpless teeth are amendable to non-surgical treatment; some may require root surgery to eliminate the inflammatory or cystic tissue.

These came to be known as Grossman's tenets and are still advocated today to evaluate new technologies.

Schilder<sup>33</sup> in 1967 stated that it is the adequate seal of the root canal system from the periodontium that protects the attachment apparatus from the breakdown of endodontic pathogens. The ultimate goal of endodontic therapy is to eliminate the root canal system as a source of infection and inflammation to the periapical tissues. This is achieved by thorough chemomechanical preparation of the root canal system followed by a complete three-dimensional obturation to the cemento-dentinal junction or 0.5 mm to 1 mm from the radiographic apex.

Pitt Ford<sup>34</sup> stated the importance of a well obturated root filling as having three objectives:

1. Diminish the space available to colonize bacteria.
2. Prevent bacterial contamination of the apex after extirpation of the pulp.
3. Prevent the movement of bacteria along the canal system.

In 1996 Weine<sup>29</sup> provided alterations to earlier guidelines on the principles of endodontic therapy. These include:

1. The objective of endodontic therapy is restoration of the tooth to its proper healthy form and function in the periodontium.
2. Three phases of therapy.
  - a. Diagnosis to treat the disease and develop a treatment plan.
  - b. Preparatory phase includes the chemomechanical preparation.
  - c. Obturation of the canal system as close as possible to the cemento-dentinal junction.
3. Importance of debridement to obtain successful results after obturation.
4. The mandatory use of a rubber dam to maintain an aseptic environment and to protect the patient from caustic irrigation solutions and aspirating instruments and debris.
5. Instrumentation and filling material should remain within the canal system, since it is the surrounding periodontium and their response that determines success or failure.
6. Proper restoration is an integral part of therapy to prevent fractures and crown-down leakage.
7. Post operative observation is necessary to evaluate the status of healing.
8. Proper case preparation is provided to the patient to explain endodontic procedures in an overall treatment plan.

Traditionally, a root canal filling of adequate quality provides the effective seal to obtain clinical success. This success, however, is compromised when an inadequate

coronal restoration is placed allowing crown-down leakage to occur. Ray and Trope<sup>35</sup> radiographically examined 1010 endodontically treated teeth with permanent restorations and concluded that the quality of the coronal restoration was significantly more important than the quality of the endodontic treatment in determining endodontic success.

## SUCCESS OF ENDODONTIC THERAPY

Numerous studies have been performed evaluating the success of initial endodontic therapy and nonsurgical retreatment based on clinical and radiographic evaluation. The major indicator of successful endodontic therapy is the absence of clinical symptoms and periapical lesions.

The classic study regarding success and failure of endodontic therapy was the Washington Study by Ingle.<sup>28</sup> He reported a 91.5-percent success rate determined radiographically on 1229 patients after a two-year recall.

In 1990 Sjogren et al.<sup>36</sup> evaluated the factors affecting the long-term results of endodontic therapy. He stated that the results of treatment were directly dependent on the preoperative status of the pulp and periapical tissue. Regardless of the pulp vitality, the presence of preoperative periapical radiolucency had a success rate of 86 percent compared with 96 percent success rate of cases without preoperative periapical radiolucency. The outcome of treatment was also dependent on the level of the obturation in relation to the root apex. A 94-percent success rate was demonstrated when the obturation was filled to within 0 mm to 2 mm of the root apex. When the root apex was obturated in excess, a success rate of 76 percent was noted compared with a 68

percent success rate when obturated more than 2 mm short of the root apex in cases with pulp necrosis and periapical radiolucency.

Walton<sup>37</sup> discusses the causes of failed root canal therapy and states that the presence of bacteria is the main cause. Overall, the most common causes of failed cases include:

1. Diagnosis and treatment planning errors.
2. Coronal leakage.
3. Lack of knowledge of pulp anatomy.
4. Inadequate debridement and/or disinfection of the root canal system.
5. Inadequate restorative protection.
6. Operative errors.
7. Deficiencies or errors in obturation.
8. Vertical root fractures.

The Toronto Study evaluated the outcome of initial endodontic therapy in a university graduate-clinic environment. A total of 405 endodontically treated teeth were examined after initial therapy over a period of four to six years. When examined both clinically and radiographically, a significant higher success rate of 92 percent was demonstrated for teeth treated without the presence of a periapical radiolucency compared with a success rate of 74 percent with teeth treated with a periapical radiolucency.<sup>38</sup>

When evaluating the treatment outcome performed by an endodontic specialist in regards to initial endodontic therapy and nonsurgical retreatment, Imura et al.<sup>39</sup> demonstrated a 91.45-percent overall success rate. Of the total 2000 teeth that were



examined clinically and radiographically, the initial endodontic treatment sample had a 94-percent success rate and the nonsurgical retreatment sample had an 85.9-percent success rate. Alley et al.<sup>40</sup> compared the success of endodontic therapy performed by specialists versus general dentists. They concluded that the success rate of endodontists at 98.1 percent was statistically significantly better than the success rate of 89.7 percent for general dentists.

Outcome assessment of endodontic therapy is essential for proper case selection and treatment planning. Epidemiological studies over a long follow-up period with a large sample size are valuable for proper clinical decision-making and tooth prognosis evaluation. Salehrabi and Rotstein<sup>41</sup> demonstrated a 97-percent success/survival rate of 1,462,936 teeth of 1,126,288 patients over a period of eight years after initial nonsurgical endodontic therapy.

Lazarski et al.<sup>42</sup> demonstrated that 94.44 percent of 110,766 nonsurgically treated teeth remained functional over an average of a 3.5-year follow-up. A subset of 44,613 cases had an incidence of extraction equal to 5.56 percent. Teeth that were not restored after endodontic therapy were significantly more likely to undergo extraction than restored teeth. As previously stated, Ray and Trope<sup>35</sup> concluded that the technical quality of the coronal restoration was significantly more important than the technical quality of the endodontic treatment for successful apical periodontal health.

These success rates are an important indication of the benefits of endodontic therapy towards the ability to maintain a functional dentition. The long-term prognosis of endodontically treated teeth is dependent on several factors, such as periodontal considerations, restorability, and the patient's motivation to preserve the tooth.

## ROOT CANAL ANATOMY

Root canal anatomy and the complex configuration of human pulpal systems provide the majority of challenges during endodontic therapy. For successful endodontic therapy, a thorough knowledge of tooth anatomy and root canal morphology is essential. Several anatomical and histological studies demonstrated the extreme complexity and highly variable anatomy of the root canal system.<sup>43, 44</sup> These included variations in the number, length, curvature, and diameter of root canals, along with the communications between the root canal system and the surrounding periodontium via accessory and lateral canals. In 1890 G.V. Black<sup>45</sup> was the first dentist to describe root canal anatomy by sectioning teeth in his book titled, *Descriptive Anatomy of the Human Teeth*.

It wasn't until the historic study by Hess<sup>46</sup> that the true description of the root canal system was demonstrated. Hess utilized vulcanized rubber that was injected into the pulp chambers of teeth to obtain an impression of the canal space. The teeth were then decalcified to illustrate the complex canal structure comprised of fins, isthmuses, and asymmetric cross-sectional forms instead of the cylindrical canals described by G.V. Black.

In 1969 Weine et al.<sup>47</sup> sectioned the mesiobuccal roots of maxillary first molars to provide the first clinical classification of root canal configurations. They concluded that the canal configurations fell into three categories:

Type I: A single canal from the pulp chamber to the apex.

Type II: A larger buccal canal that merges with a smaller lingual canal before the apex.

Type III: Two distinct canals with two distinct apical foramina.

Weine later classified another canal configuration in which a single canal further divides into two canals that exits with two distinct apical foramina.

In 1974 Vertucci et al.<sup>48</sup> published a classic study on root canal anatomy. The root canal system of extracted teeth was stained with hematoxylin dye to determine canal configurations. A more complex canal system was demonstrated compared with Weine's description. These canal types were classified as follows:

Type I: A single canal extending from the pulp chamber to the apex.

Type II: Two separate canals exiting the pulp chamber, which join to form one canal before the apex.

Type III: One canal exiting the pulp chamber that separates into two canals in the mid-root and rejoins to exit as one canal.

Type IV: Two separate canals from the pulp chamber to the apex.

Type V: One canal exiting the pulp chamber that separates into two canals, with two separate apical foramen.

Type VI: Two separate canals exiting the pulp chamber that join together and then exit as two separate canals.

Type VII: One canal exiting the pulp chamber that separates and rejoins and finally separates again into two distinct canals short of the apex.

Type VIII: Three separate canals extending from the pulp chamber to the apex.

These studies illustrate the complex nature of root canal systems that vary in size, number, and configurations.

The prevention of missed canals includes the understanding of the anatomy of the root canal system, but starts with good pre-operative radiographs. A minimum of two

diagnostic radiographs should be taken using the parallel and angled techniques to evaluate the root canal morphology. Radiographs may not always portray the correct morphology. They may be difficult for the clinician to diagnosis canal bifurcations, accessory canals, and apical deltas on a two-dimensional film. Pineda and Kuttler<sup>49</sup> examined 4183 extracted teeth by imaging them in a buccal-lingual and mesial-distal direction. They demonstrated that only 3.1 percent of canals evaluated were straight in both directions, and 30.6 percent of the teeth had ramifications of the main root canal. They concluded that radiographs are a poor representation of the root canal system because they are only two-dimensional.

An important step in locating and negotiating the orifices of the root canal is correct access into the pulp chamber. The pulp chamber floor and wall anatomy provide a guide to determine the location and number of root canals and their morphology. Krasner and Rankow<sup>50</sup> evaluated the anatomy of 500 pulp chambers and demonstrated the consistent patterns that exist between the anatomy of the pulp chamber and pulp chamber floor. These patterns were analyzed and laws proposed to assist practitioners in identifying the number and location of canals. These laws occurred in 95 percent of teeth examined and are as follows:

1. Law of Symmetry 1: The orifices of the canals are equidistant from a line in a mesiodistal direction through the floor, except for maxillary molars.
2. Law of Symmetry 2: The orifices of the canals are located on a line perpendicular to a line drawn in a mesiodistal direction across the center of the floor of the pulp chamber, except for maxillary molars.

3. Law of Color Change: The color of the pulp chamber floor is always darker than the walls.
4. Law of Orifices Location 1: The orifices at the canals are always located at the junction of the walls and the floor.
5. Law of Orifices Location 2: The orifices of the canals are located at the angles in the floor-wall junction.
6. Law of Orifices Location 3: The orifices of the canals are located at the terminus of the root developmental fusion lines.

The use of a dental operating microscope significantly increases the ability to both locate and negotiate canals. Stropko<sup>51</sup> examined 1732 conventionally treated maxillary molars to determine the percentage of a second mesiobuccal canal. The results of this study revealed that a second mesiobuccal canal was located in 73.2 percent of first molars, 50.7 percent of second molars, and 20 percent of thirds molars. A second mesiobuccal canal was located in 93 percent of first molars and 60.4 percent of second molars after utilization of an operating microscope. Kulild and Peters<sup>52</sup> located two canals in the mesiobuccal roots of both maxillary first and second molars 95.2 percent of the time utilizing a dental operating microscope. Baldassari-Cruz et al.<sup>53</sup> demonstrated an increase from 51 percent to 82 percent in locating a second mesiobuccal canal with the use of a dental operating microscope. These studies indicated that the use of a dental operating microscope significantly increases the opportunity to locate canal orifices.

Mandibular molars also present a challenge regarding root canal morphology. Skidmore and Bjorndal<sup>54</sup> examined the anatomy of extracted mandibular molars and concluded that 6.7 percent had two canals; 64.4 percent had three canals, and 28.9

percent had four canals. They also stated that of the teeth with two mesial canals, 59.5 percent remained divided, and the other 40.5 percent joined in the apical one third and exited through one foramen. If the teeth had two distal canals, they joined 61.5 percent of the time and separated the other 38.5 percent. This study significantly demonstrated a higher percentage of mandibular molar teeth with four canals at 28.9 percent, than that reported by Hess et al.<sup>46</sup> at 4.0 percent. Modifying the traditional access of a triangular outline to a rectangular outline allows better visualization to locate possible extra canals. Therefore, a thorough understanding of anatomical variations within a tooth is necessary to successfully perform endodontic therapy.

Accurate determination of the length of the root canal is important for proper instrumentation and obturation. Kuttler<sup>55,56</sup> microscopically examined the apical anatomy to determine the number and size of the apical foramen and the distance for the anatomic apex in two different studies. He concluded that the center of the foramen deviates away from the apical center as an individual ages, because of the thickening apical cementum. The distance of the cemento-dentinal junction to the anatomic apex was 0.507 mm for younger patients and 0.784 mm for older patients. Therefore, Kuttler recommended that the ideal working length of the root canal is measured 0.5 mm to the apical constriction.

A significant deviation can also be observed when comparing the apical foramen with the radiographic apex. Levy and Glatt<sup>57</sup> concluded that the apical foramen did not correlate with the radiographic apex 66.4 percent of the time. There was a greater deviation on the buccal or lingual dimension compared with the mesial distal dimension. Pineda and Kuttler<sup>49</sup> obtained similar results, with only 17 percent of the apical foramens

being located at the radiographic apex. As a result, they recommended obturating the root canal short of the radiographic apex.

## ROOT CANAL PREPARATION

Proper root canal preparation maintaining the original anatomy of the canal can be considered as one of the most important phases of endodontic therapy.<sup>29, 31, 58</sup> This preparation allows the access for irrigation solutions and medicaments to remove debris and disinfect the root canal system and therefore eliminate infection. However, a balance between removing sufficient tooth structure to adequately clean and shape the canal, while preserving as much radicular dentin for strength is imperative to prevent vertical fractures and for long-term success.

In 1957 Ingle<sup>59</sup> developed several principles for successful root canal preparation. First, the clinician must acquire the correct outline form to allow complete access for instrumentation throughout the root canal system. Next, establishing the proper convenience form to allow unobstructed access to the canal orifice, and then remove any remaining caries or defective restoration to eliminate residual bacteria. To complete the principle of preparation, adequate rinsing of the root canal system during instrumentation is recommended.

In 1974 Schilder<sup>58</sup> emphasized the importance of proper root canal preparation. He stated that proper cleaning and shaping facilitates sterilization and three-dimensional obturation of the canal system. He advocated several fundamental principles:

1. The root canal preparation should have a continuous taper from the cemento-enamel junction to the apex.

2. In cross-section, the diameter of the preparation should be narrower at every point apically and wider at every point coronally.
3. The root canal preparation should follow the original canal space.
4. The apical foramen should remain in its original position without transportation.
5. The apical opening should remain as small as possible.

Schilder also advocated several biological objectives of instrumentation:

1. Instruments should be confined to the root canal system.
2. Care should be taken not to force debris out of the apical foramen in necrotic cases.
3. Removal of organic debris is imperative for successful endodontic therapy.
4. Single canals should be cleaned and shaped in a single visit.
5. Adequate space must be created during root canal preparation for the delivery of irrigation solutions and intracanal medicaments.

In 1991 Buchanan<sup>60</sup> advocated a continuously tapered canal preparation to allow thorough debridement with smaller, more flexible files to negotiate the delicate apical portions of the root canal system. In addition, this would minimize canal transportation during preparation.

An assortment of instruments are available that assists in achieving the mechanical goals of endodontic therapy. These instruments can vary in length, taper, tip design, and type of metal used in fabrication. Hand instruments including files, broaches, reamers, and Hedstroms have been used for decades and still remain an indispensable component of root canal preparation. These hand instruments are manufactured by either



twisting square, triangular, or rectangular shafts of metal, usually stainless steel for K-type files, or ground from a round steel blank for Hedstrom files.

A major breakthrough occurred in 1988 when Walia et al.<sup>61</sup> demonstrated the bending and torsional properties of nitinol (nickel-titanium) root canal files. They compared traditional stainless steel hand files with these newly developed nickel-titanium hand files and concluded that the nitinol files had two to three times the elastic flexibility of stainless steel files as well as a superior resistance to fracture. The development of nickel-titanium instruments drastically changed the techniques of cleaning and shaping, through the development of new technologies and instrument design.

The use of rotary instrumentation was developed to enlarge curved canals or to produce wider tapers, to improve speed, and to reduce operator fatigue. Currently, several nickel-titanium rotary instruments are available in differing shape, cross-sectional patterns, and tip design. Esposito and Cunningham<sup>62</sup> evaluated whether stainless steel or nickel-titanium hand and rotary instruments would maintain the path of the original canal better. They concluded that small stainless steel file sizes (ISO 25 and 30) tended to straighten canals with increasing file sizes, compared with the nickel-titanium instruments, which maintained the original canal path.

Hand and rotary instrumentation are an invaluable adjunct in root canal preparation. However, in 2001 Spangberg<sup>63</sup> concluded that without superior knowledge of root canal anatomy and pathology, mechanical instrumentation will not enhance endodontic outcome. Mechanical instrumentation alone is effective in reducing the number of bacteria, but should be complimented with irrigation solutions and intracanal medicaments to further eradicate residual microorganisms.<sup>28</sup>

## ENDODONTIC MICROORGANISMS AND INFECTION

Microorganisms colonizing the root canal system are the major etiologic agent causing endodontic infections. In 1890 W.D. Miller,<sup>30, 64, 65</sup> the father of oral microbiology, was the first to associate microorganisms with pulpal and periapical disease. He discovered that gangrenous pulp tissue contained pathogenic organisms that were capable of producing an abscess. He also observed the variety of different microorganisms throughout the coronal, middle, and apical portions of the canal system. He concluded that if all the infected tissue were removed and antiseptically cleaned, no peri-cemental inflammation would occur.

The most influential evidence that bacteria are an important etiologic agent in pulpal and periapical disease comes from the classic study by Kakehashi, Stanley, and Fitzgerald.<sup>1</sup> In a study of gnotobiotic and conventional rats, they demonstrated that in the absence of microorganisms, inflammation of exposed, untreated pulps was minimal, and that healing readily occurred. However, in conventional animals, a comparable exposure led to progressive necrosis of the pulp, and abscess formation. They concluded that microorganisms are the major cause of pulp and periapical disease, and the major determinant in healing.

Another direct evidence of bacteria's etiological role in the development of apical periodontitis, is the result from Moller's<sup>66</sup> experimental study in monkeys. He demonstrated clinically and radiographically that infected pulp tissue displayed inflammatory reactions. He went a step further and identified the most frequently isolated bacteria as being facultatively anaerobic streptococci, coliform rods and obligately anaerobic strains.

The invasion of bacteria into an exposed pulp cavity will cause inflammation and necrosis and become infected. The types of microorganisms observed and the degree of contamination present is dependent on the different portals of entry into the pulp space. The major portals of pulp infection include caries, trauma, dental tubules, lateral canals, periodontal disease, and the anachoretic phenomenon.<sup>37, 67</sup> Anachoresis does occur, but does not contribute to pulpal infections. The most common portal of entry for bacteria and their by-products into the pulp space is via caries. A direct pulp exposure is not required for inflammatory reactions to occur adjacent to exposed dental tubules. However, the majority of pulps in these cases responds favorably and undergoes adequate healing and repair.<sup>68, 69</sup>

Once a portal of entry is available into the pulp cavity, bacterial infiltration through the dentinal tubules will result in pulpal necrosis. Microorganisms are able to invade into and become confined to the inner third of the dentinal tubules.<sup>70</sup> The number and types of bacterial species vary throughout an infected root canal. Once the pulp is necrotic, only a restricted subset of species can colonize it. The most common microorganisms in primary endodontic infections are predominantly gram-negative anaerobic rods. These genera include but are not limited to *Dialister*, *Treponema*, *Fusobacterium*, *Porphyromonas*, *Prevotella*, and *Tannerella*.<sup>37</sup> Other gram-negative bacteria frequently detected include but are not limited to *Pseudoramibacter*, *Micromonas*, *Peptostreptococcus*, *Streptococcus*, *Actinomyces*, *Olsenella*, and *Propionibacterium*.<sup>37</sup> However, virtually any microorganism found in the oral cavity, nasopharynx, or gastrointestinal tract may contaminate a root canal.<sup>71</sup>

Sundqvist<sup>72</sup> isolated bacteria associated with infected root canals. He discovered that *Fusobacterium nucleatum* was the most frequently isolated species and when taken together, the most common bacterial types were peptostreptococci. He concluded that the specific conditions within the root canal permit the growth of anaerobic bacteria that are capable of fermenting amino acids and peptides. This was in comparison with bacteria that obtain energy by fermenting carbohydrates because of their limitations in acquiring such nutrients. This conveys strong associations between certain species based on nutritional demands and relationships. Therefore, the pathogenicity of polymicrobial root canal flora is dependent on bacterial synergy.

The presence of microorganisms at the time of obturation is a vital factor influencing the outcome of endodontic therapy. Culture results can aid as an indicator for long-term prognosis. Sjogren et al.<sup>73</sup> investigated the role of bacteria on the prognosis of endodontic therapy. Complete periapical healing occurred in 94 percent of cases that yielded a negative culture. When the samples were positive prior to obturation, the success rate of treatment was only 68 percent. Other studies demonstrated similar findings that an infection at the time of obturation had a negative influence on treatment outcomes<sup>74</sup> by having a 10-percent to 15-percent lower success rate when teeth yield a positive culture before obturation.<sup>75</sup> These findings emphasized the importance of completely eliminating bacteria from the root canal system before obturation.

Ingle and Zeldow<sup>76</sup> evaluated the effects of instrumentation on the bacteriological culture status of infected teeth. After mechanical instrumentation and sterile water irrigation, only 20 percent of the teeth yielded a 48-hour negative culture. At follow-up appointments without intracanal medicaments, only 4.6 percent of the teeth yielded two

successive negative cultures, leaving 95.4 percent of teeth remaining infected. They calculated a 23-percent probability error of obtaining a negative culture after the first appointment, stating that a negative culture does not imply sterility of the root canal. They concluded that mechanical instrumentation with sterile water irrigation is an inefficient method of sterilizing a root canal system. Traditional culturing leading to inaccurate results according to Morse<sup>77-79</sup> is attributed to deficient saturation of the sampling point, the use of aerobic culturing techniques only, and limitations of the culture media. False positive culture results occur via contamination by leaky rubber dams, unsterile instruments and paper points, hand and air contamination, incomplete sterilization of the operating field, and an incomplete seal of the temporary restoration. False negative culture results are attributed to hidden and dormant microbes, remnants of intracanal medicaments, and the inability to determine growth because of insufficient numbers of microorganisms sampled.

Akpata<sup>80</sup> proposed a study to estimate the amount of viable microorganisms within an infected root canal after biomechanical preparation. He also evaluated the reliability of conventional culturing techniques as well. The outer surfaces of 20 teeth that yielded negative cultures after instrumentation and irrigation were sterilized by ultraviolet light. The teeth were then crushed, plated, incubated, and the number of viable microorganisms recorded. He concluded that viable microorganisms were either reduced to a low level or eliminated; signifying that negative cultures did not necessarily indicate sterility of the root canal. However, Akpata felt that after obturation, the remaining viable microorganisms would be too few to cause an infection that would influence the prognosis of endodontic therapy. Consequently endodontic success is more

dependent upon eliminating microorganisms from the root canal system through the use of biomechanical cleaning and shaping, various irrigation solutions, and intracanal medicaments instead of depending on culture results.

Microorganisms isolated from failing endodontic therapy have either resided within the root canal system from previous treatment or have infiltrated since treatment via caries or leakage. The composition of microflora of root canals varies between primary endodontic treatment and retreatment cases. Sundqvist et al.<sup>81</sup> discovered certain microorganisms were isolated in teeth after root canal treatment. Fifty-four previously treated teeth that were asymptomatic and had periapical radiolucency were selected for retreatment. The canals were sampled by advanced anaerobic culturing techniques. They concluded that the microbial flora in retreated teeth were significantly different from the polymicrobial flora in untreated teeth. The microbial flora of retreated teeth contained mainly single species of predominantly gram-positive bacteria, with the most common isolate being *Enterococcus faecalis*.

Siqueira and Rocas<sup>82</sup> used a polymerase chain reaction-based analysis to investigate the occurrence of microorganisms associated with failed endodontic therapy. Samples from 22 endodontically treated teeth with persistent periapical lesions were taken to analyze for 19 microbial taxa. All samples were positive for at least one target species. *E. faecalis* was the most common species isolated in 77 percent of the teeth. The other prevalent species were *Pseudoramibacter alactolyticus* (52 percent), *Propionibacterium propionicum* (52 percent), *Dialister pneumosintes* (48 percent), and *Filifactor alocis* (48 percent). *Candida albicans* was also isolated in nine percent of the

samples. It has been clearly established that enterococci are the dominant bacteria associated with failed endodontic therapy.

### *ENTEROCOCCUS FAECALIS*

The species that can adapt and tolerate the diverse ecological conditions of an endodontically treated tooth the best is *E. faecalis*. *E. faecalis* is a gram-positive, fermentative, facultatively anaerobic coccus that is non-spore forming. *E. faecalis* are ovoid in shape with a cell diameter between 0.5 µm to 1 µm. They are frequently elongated in the direction of the chain but can occur as single cells or in pairs. Most strains are non-hemolytic and non-motile. The oral cavity serves as a reservoir of *E. faecalis* for access to the root canal system. The different prevalence rates between 30 percent to 90 percent in the literature may be due to disparity in methods and timing of sampling and analysis.

When sampling is implemented before treatment in primary endodontic infections, *Enterococcus* spp. are not frequently isolated. Siqueira<sup>83</sup> evaluated the prevalence of *E. faecalis* in primary endodontic infections. The results using a molecular genetic method indicate that *E. faecalis* was isolated in only 7.5 percent of the cases. When they compared these results with asymptomatic lesions, *E. faecalis* was isolated in 11.5 percent of the cases, indicating that *E. faecalis* is isolated more often in asymptomatic teeth compared with teeth with acute symptoms.

Siren et al.<sup>84</sup> investigated the association between clinical factors and incidence of enterococci in endodontically failed teeth. The clinical history of 40 *Enterococcus*-positive and negative teeth were compared. They demonstrated that *E. faecalis*

significantly increased in prevalence in teeth between appointments after inadequate sealing. Their results emphasized the importance of controlled asepsis throughout endodontic treatment.

Several studies have demonstrated that *E. faecalis* is most commonly isolated in failed endodontic therapy. Pinheiro et al.<sup>85</sup> investigated the microbial flora within root canals of teeth with failed endodontic therapy and to determine the correlation between the different species and clinical features. Of the microorganisms recovered, 57.4 percent were facultative anaerobic species and 83.3 percent gram-positive microorganisms. *E. faecalis* was the most frequently isolated bacterial species. The other 42.6 percent of species recovered were obligate anaerobes with *Peptostreptococcus* being the most frequently isolated. These microorganisms were associated within canals of symptomatic teeth.

Rocas et al.<sup>86</sup> found similar results when determining associations between *E. faecalis* and different types of endodontic infections. They concluded that *E. faecalis* was more likely to be isolated in failed endodontic therapy compared with primary infections. They also stated that *E. faecalis* is significantly more associated with asymptomatic cases compared with symptomatic cases.

Chavez et al.<sup>87</sup> investigated the pattern of microflora that remains after chemo-mechanical treatment of root canals. They concluded that non-mutans streptococci, enterococci, and lactobacilli were the bacteria most frequently able to survive following failed endodontic therapy. The overall conclusions in these studies strongly agree that endodontic failures are of infectious etiology and that special attention should be given to



the development of proper antimicrobial strategies to help eliminate persistent root canal infections.

## IRRIGATION SOLUTIONS

The inability to eliminate all microorganisms and organic debris from the root canal system has prompted the use of different irrigation solutions during endodontic therapy. Mechanical instrumentation alone cannot achieve an adequately clean root canal. Mayer et al.<sup>88</sup> concluded that 35 percent of the root canal surface remained uninstrumented after the use of nickel-titanium rotary instrumentation. Therefore, emphasis on the combination of chemo-mechanical preparation to effectively clean the root canal system is essential. In addition to cleaning the canal system of debris, irrigation solutions increase the efficacy of hand and rotary instruments by acting as a lubricant and removing debris from the cutting flutes.<sup>89</sup> Several irrigation solutions have been advocated, such as saline, but the most popular and well documented includes sodium hypochlorite (NaOCl), chlorhexidine gluconate (CHX), ethylene-diamine tetra-acetic acid (EDTA), and BioPure MTAD.

In 1981 Bystrom and Sundqvist<sup>90</sup> demonstrated that bacteria persisted in root canals despite mechanical preparation and saline irrigation. Teeth with a high number of bacteria remained infected despite being treated five times. In conclusion, instrumentation with saline irrigation alone cannot predictably eliminate all bacteria from infected root canal systems. These results lead to the investigation of more effective irrigation solutions. Harrison<sup>91</sup> described the six desirable properties of irrigation solutions as:

1. Broad-spectrum antimicrobial activity with high efficacy against anaerobic and facultative microorganisms.
2. Dissolution of necrotic pulp tissue.
3. Inactivation of endotoxins.
4. Prevention of smear layer formation during instrumentation or once formed capable of dissolving the smear layer.
5. Systemically non-toxic
6. Minor potential to cause anaphylactic reactions.

In addition, when endodontic solutions come into contact with vital tissue, they should be non-caustic to the periodontal tissues. Currently, no irrigation solution meets all these requirements.

The most common endodontic irrigation solution is sodium hypochlorite (NaOCl) and is the gold standard. Therapeutic NaOCl solutions range in a variety of concentrations from, 0.5 percent to 6.0 percent and have a pH of 11 in unbuffered solution. NaOCl is ionized into  $\text{Na}^+$  and  $\text{OCl}^-$  in water. The hypochlorite ion,  $\text{OCl}^-$ , establishes an equilibrium with hypochlorous acid, HOCl, that is responsible for bacteria inactivation.<sup>92</sup> Hypochlorous acid has a profound effect on oxidative phosphorylation and other membrane-associated activities as well as DNA synthesis.<sup>93, 94</sup> The advantages of NaOCl include: mechanically flushing debris from the root canal system, dissolving both vital and necrotic tissue, creating antimicrobial action, and acting as a lubricant.

In 1983 Bystrom and Sundqvist<sup>95</sup> evaluated the effectiveness of 0.5-percent NaOCl and sterile saline as root canal irrigation solutions. They concluded that no bacteria could be recovered from 12 of 15 root canals irrigated with 0.5-percent NaOCl

compared with eight of 15 root canals when sterile saline was used. Siqueira et al.<sup>12</sup> demonstrated the superior antibacterial effects of NaOCl compared to sterile saline. They stated that mechanical instrumentation with 2.5-percent NaOCl eliminated *E. faecalis* better than mechanical instrumentation with sterile saline.

The action of NaOCl is related to the amount of free chlorine available. Higher volumes of a lower concentration of NaOCl are needed to achieve desired results. The alternative is to use a higher concentration of NaOCl. Hand et al.<sup>96</sup> evaluated varying concentrations of NaOCl and found that a full strength solution of 5.25 percent was significantly superior in dissolving pulp tissue remnants. In addition, Radcliffe et al.<sup>97</sup> investigated the antimicrobial activity of NaOCl of varying concentrations on endodontic microorganisms *Actinomyces israelii*, *A. naeslundii*, *Candida albicans*, and *E. faecalis*. All microorganisms were exposed to 0.5 percent, 1.0 percent, 2.5 percent, and 5.25 percent NaOCl for 0 seconds, 10 seconds, 20 seconds, 30 seconds, 60 seconds, and 120 seconds of contact time. The *E. faecalis* group were subjected to additional contact times of one, two, five, 10, and 30 minutes. Their results demonstrated that NaOCl lowered the colony-forming units below the limit of detection after 10 seconds. *E. faecalis*, however, required a longer contact time of 30 minutes for 0.5-percent, 10 minutes for 1.0-percent, five minutes for 2.5-percent, and two minutes for 5.25-percent NaOCl to reduce the colony-forming units to zero.

Many of the studies regarding NaOCl have conflicting results. In 1984 Harrison<sup>91</sup> published a review of NaOCl. In the review he stated, "If one examines the scientific evidence relating to the desirable properties for an endodontic irrigant, there can be little argument that a 5.25-percent NaOCl remains the irrigant of choice in modern endodontic

therapy.” He concluded by stating that any dilution of a 5.25-percent solution decreases its effectiveness. Full-strength NaOCl is now available in a 6.0-percent solution.

Regardless of the NaOCl concentration utilized, several studies have demonstrated that microorganisms can survive the effects of chemo-mechanical preparation.<sup>98-100</sup>

Although NaOCl is a potent antimicrobial agent and effective at dissolving pulpal remnants, it has undesirable effects. NaOCl has detrimental effects on healthy tissues even at lower concentrations in which it has been demonstrated to cause cytotoxicity and caustic effects. Pashley et al.<sup>101</sup> investigated the cytotoxicity of varying concentrations of NaOCl against red blood cells. They concluded that all concentrations of NaOCl are cytotoxic, causing complete hemolysis of red blood cells. Even a small amount injected past the foramen can cause immediate hemolysis, creating severe pain and hematomas.

Other weaknesses of NaOCl include unpleasant taste, inability to remove the smear layer, and resistance of microorganisms to its antimicrobial effects. Grawehr et al.<sup>102</sup> demonstrated the ineffectiveness of NaOCl when in contact with other irrigation solutions such as EDTA. These disadvantages have led to the search of alternative irrigation solutions, to enhance both the cleaning and antimicrobial properties for effective endodontic success.

## CHLORHEXIDINE

Chlorhexidine (CHX), developed in the late 1940s, is a widely used biocide in dentistry, and has been recommended as an alternative to NaOCl as an intracanal irrigation solution. CHX is a cationic bisbiguanide with excellent antimicrobial effects at a pH of 5.5 to 7.0. The most common preparation of CHX is with the digluconate salt

because of its stability and high water solubility.<sup>103</sup> CHX has a broad antimicrobial spectrum and is active against gram-positive and gram-negative bacteria, facultative anaerobic and aerobic bacteria, spores, viruses, and yeast.<sup>104</sup> At low concentrations, CHX is bacteriostatic, activating low molecular weight substances, i.e. phosphorus and potassium, to leak out without the cell being irreversibly damaged. CHX is bactericidal at higher concentrations not used during routine endodontic therapy, causing precipitation of the cytoplasm. CHX has become recognized as an effective oral antimicrobial agent in caries prevention, periodontal therapy, and treatment of oral infections. Endodontic applications of CHX as an irrigation solution have been limited to two concentrations, 0.12-percent and 2.0-percent chlorhexidine gluconate. At these concentrations, CHX has an extremely low level of tissue toxicity, both locally and systemically.<sup>105</sup>

*In vitro* studies have demonstrated the antibacterial efficacy of CHX. As with NaOCl, the antibacterial efficacy is dependent on the concentration of CHX utilized. Vahdaty et al.<sup>11</sup> tested the effectiveness of varying concentrations of CHX, NaOCl, and saline in disinfecting dentinal tubules. They demonstrated equal effectiveness of CHX and NaOCl at similar concentrations, in which a higher concentration was more effective than a lower concentration against *E. faecalis*. Ercan et al.<sup>106</sup> obtained similar results when comparing the antibacterial efficacy of 2.0-percent CHX and 5.25-percent NaOCl. They concluded that both irrigation solutions were significantly effective at reducing microorganisms in necrotic teeth. Jeansonne and White<sup>6</sup> also compared 2.0-percent CHX and 5.25-percent NaOCl, but demonstrated that 2.0-percent CHX was more effective in reducing the number of colony-forming units and positive cultures than 5.25 percent NaOCl. However, the differences were not statistically significant. Ohara et al.<sup>107</sup>

investigated the antibacterial effects of six irrigation solutions against anaerobic bacteria and reported that CHX was the most effective.

CHX has been shown to exhibit substantivity in root canal dentin. White et al.<sup>14</sup> investigated whether CHX irrigation exhibited substantive antimicrobial activity in instrumented root canals *in vitro*. Antimicrobial activity was present in all 2.0-percent CHX treated teeth throughout the 72-hour testing period. Irrigation with 0.12-percent CHX demonstrated substantivity in relatively lower concentrations for six to 24 hours after irrigation. Komorowski et al.<sup>108</sup> evaluated the antimicrobial substantivity of CHX-treated bovine dentin over a 21-day period. The specimens treated with CHX for seven days demonstrated significantly less dentin colonization by *E. faecalis* than other specimens. In 2004 Rosenthal et al.<sup>109</sup> evaluated the substantivity of CHX in bovine root canal dentin as well. To determine whether the CHX from the dentin samples remained antimicrobial, the extracts from both the control and experimental groups were mixed with cultures of *E. faecalis*. After one day, three weeks, six weeks, and 12 weeks of storage, the dentin extract contained approximately 0.0048 percent, 0.0023 percent, 0.0016 percent, and 0.0010 percent CHX, respectively. Therefore, the results of this study demonstrated that CHX is retained in the root canal dentin in antimicrobially effective amounts for up to 12 weeks.

Two-percent CHX in a gel formulation has been proposed for root canal disinfection as an alternative to 5.25-percent NaOCl solution. This gel formulation consists of 1.0-percent natrosol, 17-percent EDTA, and 2.0-percent CHX. Ferraz et al.<sup>110</sup> demonstrated that a 2.0-percent gel produced a cleaner root canal surface and had an antimicrobial ability comparable to 2.0-percent CHX solution and 5.25-percent NaOCl.

In a follow-up study, Wang et al.<sup>4</sup> results demonstrated that 2.0-percent CHX gel is an effective root canal disinfectant, and that additional intracanal dressings did not significantly improve the disinfection.

There are several advantages of using a CHX gel compared with a solution. Ferraz et al.<sup>110</sup> also demonstrated that almost all dentinal tubules were opened when treated with 2.0-percent CHX gel. The gel promoted better mechanical cleaning and removal of dentin debris and tissue, and the author found that the root canal system was more effectively cleaned because of the gel's viscosity. In addition to the mechanical properties, 2.0 percent CHX gel has good antimicrobial activity and acts as a lubricant during instrumentation. However, CHX in a gel formulation requires a longer time to eliminate microorganisms compared with the liquid form. Vianna et al.<sup>111</sup> evaluated the antimicrobial activity of CHX and varying concentrations of NaOCl. The timing required for 1.0-percent and 2.0-percent CHX liquid to eliminate all microorganisms was the same required for 5.25-percent NaOCl. However, CHX in a gel formulation required a longer time to eliminate *E. faecalis* than the corresponding concentration in a liquid form. They concluded by stating the antimicrobial action is related to type, concentration, and presentation form of the medicament as well as the microbial susceptibility.

Lenet et al.<sup>112</sup> compared the efficacy of two CHX delivery vehicles, a controlled-release device and a gel, to affect antimicrobial substantivity of bovine root dentin. The results demonstrated that a 2.0-percent CHX gel applied for seven days maintains antimicrobial properties for at least 21 days.

Similar to NaOCl, CHX has several disadvantages as an endodontic irrigating solution. CHX is dependent upon the pH, which is greatly reduced in the presence of organic matter, and lacks tissue solvency. Haapasalo et al.<sup>113</sup> concluded that the effects of CHX is reduced or delayed, by the presence of dentin. Portenier et al.<sup>114</sup> evaluated the antibacterial efficacy of CHX by dentin, hydroxyapatite, and bovine serum albumin. The results indicate CHX was strongly inhibited by bovine serum albumin and slowed down by dentin, thus reducing the inhibition of the antibacterial activity of CHX. Yamashita et al.<sup>115</sup> investigated the cleaning of root canal walls after irrigation with different solutions under a scanning electron microscope. Cleaning by CHX was inferior compared to NaOCl with and without EDTA. Okino et al.<sup>116</sup> compared the activity of various irrigation solutions on bovine pulp tissue. CHX did not dissolve the pulp tissue, whereas NaOCl efficiently dissolved the pulp tissue. Zamany et al.<sup>117</sup> discovered that when an additional rinse of 2.0-percent CHX is added with a 1.0-percent NaOCl rinse, cultivable bacteria were retrieved in one out of 12 cases. Therefore, it can be concluded that CHX is to be utilized as an adjunctive medicament to NaOCl rather than as a single irrigating solution.

For enhanced antimicrobial properties, a combination of NaOCl and CHX has been advocated for root canal irrigation. Kuruvilla and Kamath<sup>118</sup> demonstrated the use of NaOCl and CHX combined within the root canal system resulted in greater antimicrobial effects than when used separately. However, the combination of NaOCl and CHX produces an orange-brown precipitate. Bui et al.<sup>3</sup> concluded that this interaction between CHX and NaOCl significantly affected the patency of the dentinal



tubules, indicating a concern about any amount of precipitate with respect to leakage into the surrounding tissues and the seal of the root canal system.

Basrani et al.<sup>119</sup> investigated this interaction between NaOCl and CHX. Their results demonstrated an immediate reaction between 2.0-percent CHX and NaOCl, even at a low 0.023-percent concentration. An increase to 0.19-percent NaOCl concentration resulted in the formation of a precipitate. With increased concentration of NaOCl the color darkened and the precipitate thickened. An x-ray photon spectroscopy and time-of-flight secondary ion mass spectrometry was used to qualify and quantify the precipitate. These results revealed the presence of para-chloroaniline (PCA) in an amount directly related to the NaOCl concentration utilized.

Chhabra et al.<sup>120</sup> evaluated the carcinogenicity of PCA in rats and mice. They concluded that methemoglobin formation and accompanying haemolytic anaemia, extra-medullary haematopoiesis, and splenomegaly were indicative of regenerative anemia and erythrocyte toxicity. These toxicologic studies have demonstrated that the hematopoietic system is the major target for PCA, with the primary effect being the formation of methemoglobin. Since PCA has been reported as being carcinogenic in rats and mice, and short-term exposures in humans can manifest methemoglobin formation resulting in cyanosis, the incidental mixing of NaOCl and CHX should be avoided to minimize its formation.

#### ETHYLENEDIAMINE TETRAACETIC ACID

Throughout the cleaning and shaping procedure, both organic and inorganic debris accumulates on the radicular canal walls, producing an amorphous smear layer.

This smear layer may harbor microorganisms, prevent or delay the diffusion of irrigation solutions and intracanal medicaments into the dentinal tubules, and affect the seal of the root canal system during obturation. Acids and other chelating agents such as ethylenediamine tetraacetic acid (EDTA) can effectively remove this smear layer created during canal instrumentation. EDTA does so by chelating both calcium and phosphate.

In 1957 Nygaard-Ostby introduced EDTA to aid in enlarging narrow root canals. Stewart et al.<sup>121</sup> demonstrated that EDTA removes calcium from dentin and concretions in the pulp to allow endodontic instruments to more effectively clean and enlarge the canal. EDTA has limited antimicrobial and antiseptic activities. In 1963 Patterson<sup>122</sup> evaluated the endodontic implications of EDTA on dentin. A 10-percent EDTA solution inhibited bacterial growth of alpha hemolytic streptococcus and *Staphylococcus aureus* coagulase for 24 hours. He also determined that EDTA was not dependent on a high hydrogen ion concentration for adequate decalcification. Within 24 hours, the dentin nearest the pulp canal underwent decalcification. This decalcification was not self-limiting, but continued for five days; therefore, the need to thoroughly remove all remnants of residual chelated calcium and EDTA from within the canal system is imperative. In conclusion, Patterson stated that no deleterious effects were noted and that EDTA is a valuable adjunct to endodontic therapy.

Orstavik and Haapasalo<sup>123</sup> demonstrate that EDTA-facilitated smear layer removal improves the antimicrobial effect of various other irrigating solutions and medicaments in deeper layers of the dentin. Niu et al.<sup>124</sup> compared the effects of EDTA and EDTA with NaOCl irrigation on canal walls at the microscopic level. EDTA followed by NaOCl resulted in more debris removal than with EDTA alone.

Calt and Serper<sup>125</sup> evaluated the effects of EDTA on smear layer removal and on the structure of dentin, and recommended an exposure time of one to five minutes for effective removal. They also demonstrated that a 10-minute application of EDTA caused excessive peritubular and intertubular dentinal erosion, concluding that EDTA should not be prolonged greater than one minute during endodontic therapy. These results were confirmed when Crumpton et al.<sup>126</sup> investigated the effects on smear layer and debris removal with 17-percent EDTA after rotary instrumentation. They concluded that efficient smear layer removal was achieved by a final rinse of 1.0 ml of 17-percent EDTA for one minute, followed by 3.0 ml of 5.25-percent NaOCl.

During routine endodontic therapy, several irrigation solutions are utilized and interact as previously stated. The mixture between NaOCl and CHX is to be avoided. The combination of CHX and EDTA produces a white precipitate. Rasimick et al.<sup>127</sup> used reverse-phase high performance liquid chromatography with ultraviolet detection and discovered the white precipitate to be over 90-percent CHX and EDTA, with less than one percent (limit of detection) of the potential decomposition product, PCA. To help prevent this PCA formation, EDTA is advocated to flush out any residual NaOCl from within the canal before the application of CHX. The clinical significance of this white precipitate between CHX and EDTA is unknown, but may block dentinal tubules and possibly interfere with the seal of the root canal during obturation.

#### OTHER IRRIGATION SOLUTIONS

Hydrogen peroxide has also been advocated by some as an alternative irrigation solution. Hydrogen peroxide is a biocide used for disinfection and sterilization; however,

in endodontics, its use is not popular. Hydrogen peroxide is more effective against gram-positive than gram-negative bacteria and has antimicrobial properties toward viruses, bacteria, yeast, and spores. When used alternatively with NaOCl, an effervescence occurs that liberates oxygen from the tooth to aid in debris removal. Heuer<sup>128</sup> stated that all traces of hydrogen peroxide be removed with NaOCl to prevent the continued liberation of oxygen that can result in tissue emboli and severe cases of periapical periodontitis. Siqueira et al.<sup>98</sup> reported that a combination of NaOCl and hydrogen peroxide had no advantage over NaOCl alone against *E. faecalis*. Heling and Chandler<sup>129</sup> demonstrated a synergistic effect between hydrogen peroxide and CHX; however, this remains to be evaluated clinically. With only a minor contribution during endodontic therapy and because of its possible disadvantages of the use of hydrogen peroxide, it is preferable to use NaOCl alone.

In 2003, Torabinejad et al.<sup>130</sup> introduced a new irrigation solution called MTAD. MTAD consists of a mixture of tetracycline isomer (Doxycycline), an acid (citric acid), and a detergent (Tween-80). It has properties capable of disinfecting the dentin, removing the smear layer, opening the dentinal tubules, and allowing the antibacterial agents to penetrate the entire root canal system. Shabahang and Torabinejad<sup>131</sup> reported that a combination of 1.3-percent NaOCl and MTAD was significantly more effective against *E. faecalis* than other regimens such as 5.25-percent NaOCl and 17-percent EDTA. However, Johal et al.<sup>132</sup> demonstrated that a combination of 5.25-percent NaOCl and 15-percent EDTA allowed for no CFU of *E. faecalis* compared to CFU counts in nearly 50 percent of canals with 1.3-percent NaOCl and MTAD. The tissue dissolving

property of MTAD is not comparable to 5.25-percent NaOCl therefore, it is still necessary to utilize NaOCl throughout instrumentation.

## INTRACANAL MEDICAMENTS

Calcium hydroxide is an antimicrobial medicament, introduced in endodontic therapy by Hermann in 1920. Its use is recommended for different clinical situations such as root canal infections, root end closure, and root resorption. The antimicrobial action of calcium hydroxide is due in part to its high pH of 12.2, by the release of hydroxyl ions. This alters the integrity of the cytoplasmic membrane causing cellular destruction of bacterial cells. This requires an ideal time for effective destruction of microorganisms, acting directly or indirectly in contact with dentinal tubules.<sup>133</sup> The advantages of calcium hydroxide are its long-lasting effects, in which intracanal placement can be kept for several months. This is based on the stability and physical properties of the calcium hydroxide and due to the slow release of calcium and hydroxyl ions.

Sjogren et al.<sup>134</sup> demonstrated that a seven-day dressing of calcium hydroxide efficiently eliminated bacteria which survived the biomechanical instrumentation of the canal, whereas a 10-minute application of calcium hydroxide was ineffective. In 1985 Bystrom et al.<sup>135</sup> stated that the elimination of microorganisms in root canals can be achieved more reliably with calcium hydroxide than with other medicaments tested. However, these pioneer studies were later challenged. Kvist et al.<sup>136</sup> concluded that from a microbiological point of view, the treatment of teeth with apical periodontitis completed in two appointments with the use of calcium hydroxide medicament was no

more effective than the investigated one-visit appointment. Peters et al.<sup>137</sup> evaluated the fate of microorganisms in teeth of root canals subjected to calcium hydroxide. They concluded that calcium hydroxide limits but does not totally prevent the regrowth of endodontic microorganisms. Calcium hydroxide can be placed as a dry powder, or as a powder mixed with liquids such as local anesthetic solutions, saline, water, glycerin, or CHX to form a paste. These different vehicles have been added to calcium hydroxide to enhance its properties. Fava and Saunders<sup>138</sup> stated that for calcium hydroxide to be solubilized and resorbed at various rates by the periradicular tissue and from within the root canal system, the vehicle plays the principle role in the overall process because it determines the velocity of ion dissociation.

Although calcium hydroxide is the most common interappointment medicament utilized, concerns regarding its use are an issue. The proper placement of calcium hydroxide into the canal system is technique-sensitive. For maximum effectiveness, it is important to adequately place the calcium hydroxide completely throughout the root canal system with optimal density. The complete removal of calcium hydroxide is difficult as well. Lambrianidis et al.<sup>139</sup> reported that 20 percent to 45 percent residual calcium hydroxide remained on the root canal walls, even after copious irrigation with saline, NaOCl, or EDTA. This calcium hydroxide residue can interfere with the seal of the obturation material and possibly compromise the overall quality of the root canal treatment. Microbes such as *E. faecalis* and *C. albicans* have been demonstrated to be resistant to its effects.<sup>123, 135</sup> Therefore, it is advocated that calcium hydroxide be used in conjunction with other irrigation solutions such as NaOCl, EDTA, and CHX for more thorough debridement and disinfection of the root canal system.

## IRRIGATION REGIMENS

One alternative method to improve the effectiveness of irrigation solutions within the root canal system is to increase the temperature. Several studies have reported that increasing the temperature of irrigating solutions can enhance its antimicrobial efficacy. Abou-Rass and Oglesby<sup>16</sup> stated that a higher concentration of NaOCl (5.25 percent) was more effective than a lower (2.6 percent) concentration, and that regardless of the concentration tested, heating the NaOCl was more effective at dissolving tissue. Using endodontically appropriate tissues and microbiota, Sirtes et al.<sup>140</sup> stated that preheated NaOCl solutions had three desirable effects. These effects include clinical stability over a short period of time, improved tissue dissolving capacity, and increased antimicrobial efficacy against stationary phase *E. faecalis* cells.

Cunningham and Balekjian<sup>141</sup> reported that increasing the temperature of NaOCl from 22°C to 37°C significantly improved its tissue dissolving capacity. A follow-up study by Cunningham and Joseph<sup>142</sup> indicated that both the debriding and disinfection properties of a 2.6-percent NaOCl solution are enhanced with an increase in temperature. However, an *in vitro* investigation by Raphael et al.<sup>143</sup> determined the bactericidal efficiency of 5.25 percent NaOCl at various temperatures against different strains of bacteria and found that a direct correlation does not exist between the temperature of NaOCl and its bactericidal efficiency.

A more recent study by Evanov et al.<sup>17</sup> demonstrated that heat (46°C) enhanced the antimicrobial efficacy of both 10-percent calcium hydroxide and 0.12-percent CHX towards *E. faecalis* relative to saline (positive control) and to either experimental medication at 37°C. Although effective, CHX when exposed to heat can break down to

form PCA. Findings by Basrani et al.<sup>144</sup> demonstrated that heated CHX at 45°C displayed the possible formation of PCA; therefore, caution is advised until further studies and information is available.

Several different irrigation regimens have been proposed to maximize the effectiveness of irrigation solutions within the root canal system. Irrigation solutions supplemented with sonic, ultrasonic, or negative pressure irrigating devices demonstrates significantly better irrigation, debridement, and microbial control compared to traditional irrigation delivery systems.<sup>145-147</sup> These devices are to be used with caution since unwanted cutting of the canal system, apical extrusion of the irrigation solution, air contamination created by aerosols, and heating of irrigation solutions may occur.

#### *E. FAECALIS* SUSCEPTIBILITY TOWARDS IRRIGATION SOLUTIONS

Occasionally, treatment-resistant microorganisms, especially facultative anaerobe *Enterococcus faecalis*, can proliferate to become dominant and difficult to eliminate from the root canal system. The resistance of *E. faecalis* to endodontic medicaments increases dramatically in aging cultures. *E. faecalis* grown in rich media are more vulnerable to different types of stresses such as heat, hydrogen peroxide, acids, ethanol, and NaOCl compared to glucose-starved cells.<sup>148, 149</sup> Portenier et al.<sup>150</sup> compared the susceptibility of *E. faecalis* during exponential growth, stationary phase, and starvation phase to different irrigation solutions. They concluded that starvation may be one of the main factors that results in high resistance of *E. faecalis* to various irrigating solutions. This could then explain the differences between *in vitro* and *in vivo* studies. Therefore, they suggested



the use of cells in the starvation phase to adequately replicate *in vivo* conditions within the root canal system.

*E. faecalis* contains several virulence factors to compete with other microorganisms, invade dentinal tubules, and resist nutritional deprivation to cause periradicular disease.<sup>15</sup> These virulence factors include lytic enzymes, cytolysin, aggregation substance, pheromones, and lipoteichoic acid.<sup>86</sup> In addition, *E. faecalis* has been discovered to exhibit genetic polymorphism<sup>151</sup> along with serine protease, gelatinase, and collagen-binding protein (Ace) to assist with dentinal binding.<sup>152</sup> These are the several ways in which *E. faecalis* overcomes the challenges of survival within the root canal system.

Another main factor attributing to their survival is their ability to form distinct biofilms under complex growth conditions. This biofilm consisting of microbial communities of surface-attached cells embedded in a self-produced extracellular polymeric substance (EPS) helps to resist destruction, therefore enabling *E. faecalis* to become 1000 times more resistant to phagocytosis, antibodies, and antimicrobials compared with non-biofilm producing microorganisms.<sup>153</sup> Their elimination from the root canal system can be difficult. Lima et al.<sup>13</sup> evaluated the effectiveness of CHX- or antibiotic- based medications in eliminating *E. faecalis* biofilms. There were significant differences between the medications tested. The combination of Clindamycin with Metronidazole significantly reduced the amount of cells in one-day biofilms. However, only 2.0-percent CHX- containing medications were able to completely eliminate both one-day and three-day *E. faecalis* biofilms. Clegg et al.<sup>154</sup> assessed the effectiveness of different irrigation solutions on endodontic biofilms evaluated by SEM and culturing.

Their results indicated that 6.0-percent NaOCl was the only irrigation solution capable of both rendering bacteria nonviable and physically removing the biofilm. A 2.0-percent CHX solution was equally effective at bacterial killing, however having no effect on the biofilm structure. Therefore, this biofilm would possibly have the ability to express its antigenic potential in the future.

A recent study by Chavez de Paz et al.<sup>155</sup> analyzed the effects of antimicrobials on biofilms of *E. faecalis*, *L. paracasei*, *S. anginosus*, and *S. gordonii* isolated from root canals with persistent infections. These biofilms formed after 24 hours were then exposed to NaOCl, EDTA, and CHX. NaOCl removed most biofilm cells and affected the membrane integrity of all organisms. The exposure to EDTA also affected the membrane integrity in all the organisms but failed to disrupt only a few cells in biofilms of *E. faecalis*, *L. paracasei*, and *S. angiosus*. CHX had only a mild effect on the membrane integrity of *E. faecalis* and only removed 50-percent of its biofilm cells.

Adherence of bacteria to a host is an important step in the invasion and establishment of an infection. Kishen et al.<sup>5</sup> evaluated early *E. faecalis* biofilms and noted that bacterial adherence is significantly influenced by the last irrigation solution used. They stated that the least adherence was when NaOCl was used last.

Given that *E. faecalis* is the most resistant bacteria species to chemomechanical preparation, a variety of antimicrobial agents have been tested for their ability to eliminate *E. faecalis* from the root canal system. Heling and Chandler<sup>129</sup> investigated the effectiveness of several endodontic irrigation solutions against *E. faecalis*. Their results demonstrated that CHX and NaOCl were equally effective. As previously stated, at specific concentrations a synergistic effect was noted with a combination of CHX and

hydrogen peroxide. These results are supported by Vahdaty et al.,<sup>11</sup> who demonstrated no difference in the effectiveness of CHX or NaOCl in the eradication of *E. faecalis* from infected dentinal tubules. They also stated that *E. faecalis* was eliminated from the superficial layers of dentinal tubules up to 100 µm with a two-minute rinse of 2.0-percent CHX liquid.

When the antibacterial activity of NaOCl was tested against *E. faecalis*, Peciulience et al.<sup>156</sup> demonstrated that *E. faecalis* was not predictably eliminated from the root canal system after routine chemomechanical preparation with 5.25-percent NaOCl. Gomes et al.<sup>157</sup> demonstrated a significant difference between CHX and NaOCl in the elimination of *E. faecalis*. Only the highest concentration of 5.25-percent NaOCl killed *E. faecalis* rapidly in 30 seconds, while with a lower concentration of 0.5-percent NaOCl solution, five to 30 minutes were required for complete elimination. However, CHX eliminated *E. faecalis* cells within 30 seconds or less in 0.2-percent to 2.0-percent concentrations. These findings were later supported by Oncag et al.<sup>158</sup> and Vianna et al.,<sup>111</sup> who demonstrated *in vitro* CHX as being superior to NaOCl in eliminating *E. faecalis* and *Staphylococcus aureus*.

*E. faecalis* has been found to be resistant to calcium hydroxide because of its proton pump.<sup>159</sup> Therefore, studies have supported the mixture of calcium hydroxide with CHX. Zerella et al.<sup>160</sup> evaluated this combination of calcium hydroxide and CHX in retreatment cases. They discovered that all cases that initially harbored *E. faecalis* were successfully disinfected. In contrast, Schafer and Bossmann<sup>161</sup> concluded that CHX was significantly more effective against *E. faecalis* compared with calcium hydroxide paste or

a mixture of the two. They also stated that there was no increase in the efficiency of calcium hydroxide past when CHX was added.

Elimination of *E. faecalis* from the root canal system remains a challenge. It becomes evident that no single irrigation solution can fulfill all the ideal requirements. Therefore, a combination of irrigation solutions may be required to effectively meet these criteria. The irrigation regimen of full strength NaOCl, EDTA, and 2.0-percent CHX has resulted in the fewest number of adhering *E. faecalis* cells and the most effective methods of eliminating *E. faecalis* from the root canal system.<sup>5</sup>

#### OBTURATION AND LEAKAGE ON HEALING

Proper chemo-mechanical preparation is followed up by a compact three-dimensional obturation from the canal orifice to the apical foramen. The obturation of the root canal system is a vital step in the sealing of the canals to prevent contamination of the periodontal tissues and subsequent periapical pathosis.<sup>58</sup> Many endodontic filling materials and techniques have been advocated and explored over the last 100 years. The most commonly used obturation material currently is gutta-percha; however, a recently new obturation system named Resilon has been developed that takes advantage of the adhesive bonding within the root canal system.

Regardless of the obturation material utilized, obturated root canals may become recontaminated by various ways, including during a delay in placement of a permanent coronal restoration, a fracture of the tooth or coronal restoration, or during post preparation.<sup>162</sup> Therefore, a final permanent restoration placed in a timely manner is paramount to prevent recontamination and to ensure long-term endodontic success.

Periapical lesions that fail to heal regardless of adequate endodontic therapy may be due to the establishment of microorganisms outside the root canal in the periapical tissues.<sup>163</sup>

As a result, surgical treatment options are then advised to eliminate the bacteria that are inaccessible to conventional endodontic therapy.

## MATERIALS AND METHODS

## SELECTION OF TEETH

Modifications of the *in vitro* model for the preparation of dentin disk specimens originally described by Haapasalo and Orstavik<sup>164</sup> were utilized in the present study. Ninety-five human, extracted, single rooted, maxillary, central, lateral, and canine teeth were used for this study. All teeth were collected from the Oral Health Department under IUPUI/Clarian IRB #0306-64. All teeth were stored in a sealed container containing 0.1-percent thymol and stored at 4.0°C. Specific criteria were met for tooth selection. Radiographs of all teeth were taken in a mesial-distal direction to confirm a Type I root canal system was present. Teeth with atypical canal anatomy, atypical root morphology including obvious lateral canals, extensive caries<sup>164</sup> or root fractures were discarded.

A summary of the experimental design can be found in Figure 1. Once all 95 teeth had been selected, both calculus and any soft tissue were removed with hand scaling instruments. Following debridement of the root surface, the teeth were stored in 6.0-percent sodium hypochlorite (Clorox Co., Oakland, CA) overnight for surface disinfection, and placed back in sterile water to prevent dehydration. Cylindrical dentin disks (5.0 mm in thickness) were prepared by removing the crowns and the apical 5.0 mm of the teeth with a carborundum disk (Brasseler USA, Savannah, GA), at slow speed (<100 rpm) with water coolant (Figures 2-4). The disk thicknesses were measured with calipers (Mahr, 16ES, Esslingen, Germany) to ensure consistency (Figures 5 and 6). The pulpal lumens were standardized to 2.5 mm diameter with an ISO 025 bur (Brasseler

USA, Savannah, GA) in a MCS Heavy Duty Drill Press (Model 951220, Manhattan Supply Company, Central Islip, NY) (Figures 7-9).

#### DENTIN DISK SPECIMEN PREPARATION

Smear layer removal was accomplished using an ultrasonic bath with 17-percent EDTA for four minutes followed by another ultrasonic bath with 6.0-percent NaOCl for four minutes (Figure 10). The specimens were placed in glass containers with water and sterilized in a steam autoclave for 15 minutes at 121°C and 15 psi. Specimens were mounted into individual 22-mm diameter sterile tissue wells in six well plates (Fisher Scientific 08-772-1B) with covers, on a 5.0-mm base of sticky wax (Figure 11). A 10-ml brain heart infusion (BHI) broth was inoculated with 0.1 ml of an overnight culture of *E. faecalis* (ATCC 29212) (Figures 12-14) and incubated for 16 hours in 5.0-percent CO<sub>2</sub> at 37°C (Figure 15 and 16). The lumens of the dentin disks were completely filled with (approximately 24 µl) with BHI broth (Difco, Detroit, MI) containing approximately  $6.09 \times 10^8$  colony-forming units/ml (approximately  $1.49 \times 10^8$  colony-forming units/dentin disk) of *E. faecalis* (Figures 17). A 2.0-ml aliquot of sterile water was placed around the wax base, but not contacting the specimens, to maintain humidity (Figure 18). All specimen treatment was performed either under a Bunsen burner or under a laminar flow hood to avoid contamination (Figure 19). The specimens were incubated at 37°C in 5.0 percent CO<sub>2</sub> for 72 hours (Figure 20). Every 24 hours sterile BHI was added to the canals to compensate for evaporation. After 72 hours, the BHI broth was suctioned out and rinsed with a total of 2.0 ml of sterile saline per sample at ambient temperature (24°C).



Two temperatures were tested for each irrigation solution (saline, 0.12 percent CHX, and 2.0 percent CHX) (Figure 21): 24°C (ambient temperature) irrigation solution was placed in a 37°C (oral temperature) incubator to simulate clinical conditions, and the 46°C (experimental temperature) irrigation solution was placed in a 46°C incubator to maintain the experimental temperature.

#### ASSIGNMENT OF TEETH

Specimens were randomly assigned to six groups (15 teeth per group). The irrigation solution for groups 1 and 2 consisted of sterile saline at 37°C and 46°C, respectively. The irrigation solution for groups 3 and 4 consisted of 0.12-percent CHX at 37°C and 46°C, respectively. The irrigation solutions for groups 5 and 6 consisted of 2.0-percent CHX at 37°C and 46°C, respectively. The negative control group consisted of five teeth treated in the same method as the experimental teeth, except they were incubated with sterile, uninoculated BHI broth. Group 1 also served as the positive control to provide baseline data of bacterial growth over time.

All specimens in each group were filled with 2.0 ml of the test irrigation solution at the specified concentration and temperature and incubated at 37°C or 46°C, as appropriate, for 35 minutes. As demonstrated by Evanov et al.<sup>17</sup> in their preliminary study to determine the time needed for a dentin disk specimen to reach a specific temperature after being returned to the incubator, a time of five minutes was necessary for the specimens to return to the desired temperature after opening and closing the incubator doors. An additional 30 minutes was chosen to represent the approximate time of irrigation solution exposure during clinical instrumentation, for a total of 35 minutes of

irrigation solution exposure at the specified temperatures. The test irrigation solution was suctioned away and rinsed using 2.0 ml of 24°C sterile saline per sample. The specimens were frozen in a -70°C freezer, weighed to equal amounts (Figure 22), and pulverized in liquid nitrogen with a mortar and pestle (Figure 23). The specimens were mixed with 2.0 ml of phosphate-buffered saline and vortexed for 10 seconds and sonicated for 10 seconds on the highest setting (Figures 24 and 25).

A preliminary pilot study was performed to determine the percentage loss of bacteria subjected to -70°C with subsequent treatment with liquid nitrogen. The results in Table I demonstrated that there was an insignificant amount of bacteria loss when subjected to -70°C with subsequent liquid nitrogen treatment.

Another preliminary study was performed to determine the appropriate dilutions necessary for accurate data analysis. The results of this study concluded that 1:100 and 1:1000 dilutions were determined to be the most ideal for accurate data analysis. Serial dilutions of 1:100 and 1:1000 were prepared and 50- $\mu$ l aliquots of each dilution were spiral plated on BHI agar plates in duplicate and incubated in 5.0-percent CO<sub>2</sub> at 37°C (Figure 26). After 24 hours the bacterial colonies were counted using an automated colony counter for data analysis (Figures 27-34). Each specimen agar plate had the CFUs counted four times to determine each plate's mean. This mean value was recorded appropriately for each plate and group for statistical analysis.

## STATISTICAL METHODS

Comparisons of *E. faecalis* CFU were performed using two-way analysis of variance (ANOVA), with factors for solution (sterile saline, 0.12-percent CHX, and 2.0-

percent CHX), solution temperature (37°C and 46°C), and the solution-by-temperature interaction. Pair-wise comparisons between groups were examined for significance using the Fisher's Protected Least Significant Differences Method. A 5.0-percent significance level was used for each test. The *E. faecalis* CFU were log-transformed to satisfy the assumptions required for the ANOVA.

#### SAMPLE SIZE JUSTIFICATION

Based on the thesis by Evanov et al.<sup>17</sup> the within-group standard deviation for the *E. faecalis* log cfu/mg data is approximately 0.35. Calculations were performed assuming two-sided two-sample t-tests at a 5.0-percent significance level for each test. With a sample size of 15 specimens per group, the study will have 90-percent power to detect a difference of 0.43 log cfu/mg between any two groups.

## RESULTS

The alternative hypothesis of higher antibacterial efficacy could not be confirmed when heating a higher concentration of 2.0 percent CHX solution to 46°C against *E. faecalis*. The results demonstrated no statistically significant difference with the addition of heat to either test irrigation solution. There was a statistically significant difference in the antibacterial efficacy against *E. faecalis* in comparison with the concentration tested. A higher concentration of 2.0 percent CHX demonstrated a significantly higher antibacterial efficacy against *E. faecalis* compared with 0.12 percent CHX, and likewise with the saline control.

The interaction between solution and solution temperature was not significant ( $p = 0.66$ ), so that the solution comparisons can be generalized for any temperature and the temperature comparisons generalized for any solution. *E. faecalis* CFU differed by solution ( $p < 0.0001$ ): Saline had significantly higher *E. faecalis* CFU than 0.12 percent CHX ( $p = 0.00181$ ) and 2.0 percent CHX ( $p < 0.0001$ ), and 0.12 percent CHX had significantly higher *E. faecalis* CFU than 2.0 percent CHX ( $p = 0.0001$ ). Solution temperature did not have a significant effect on *E. faecalis* CFU ( $p = 0.44$ ). The results are represented in Tables II and III.

TABLES AND FIGURES

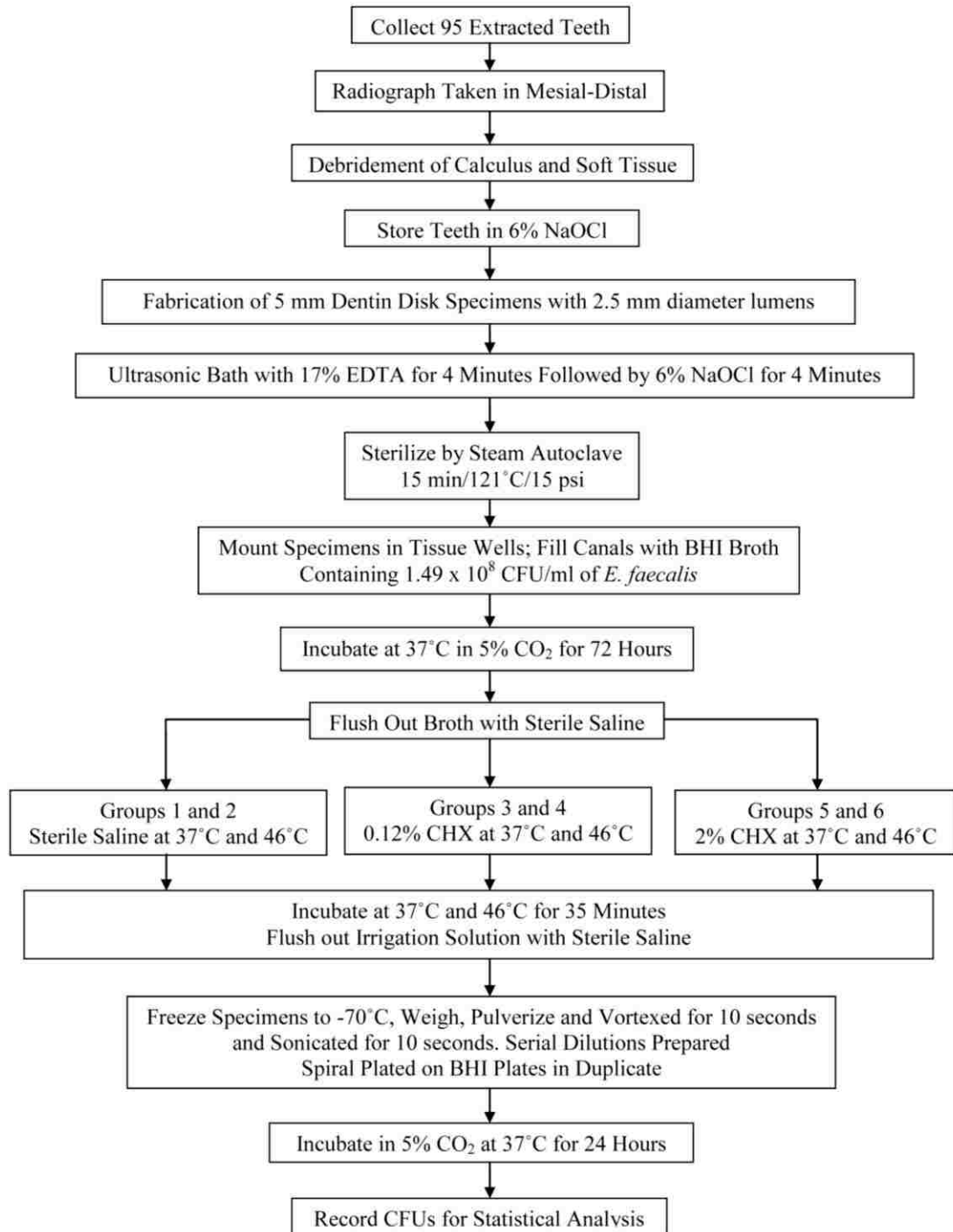


FIGURE 1. Summary of experimental design.

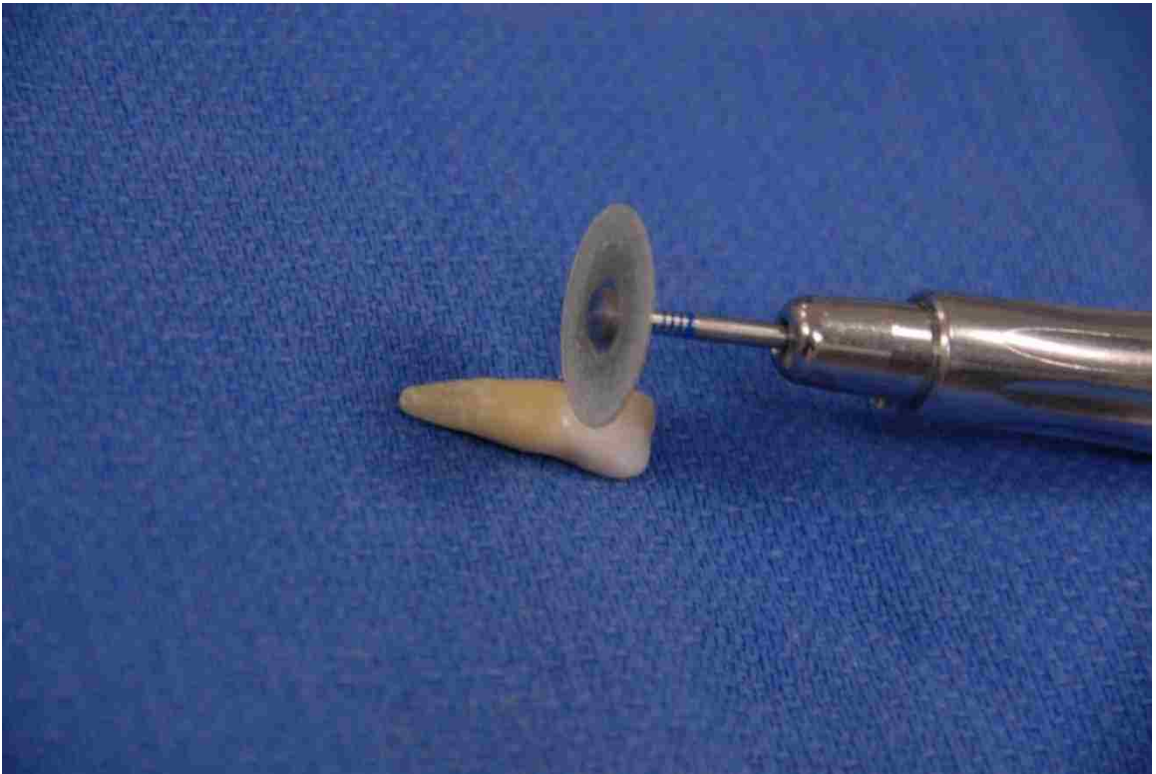

FIGURE 2. Initial sectioning of clinical crown with carborundum disk.






FIGURE 3. Sectioning tooth to 5-mm sections in apparatus.

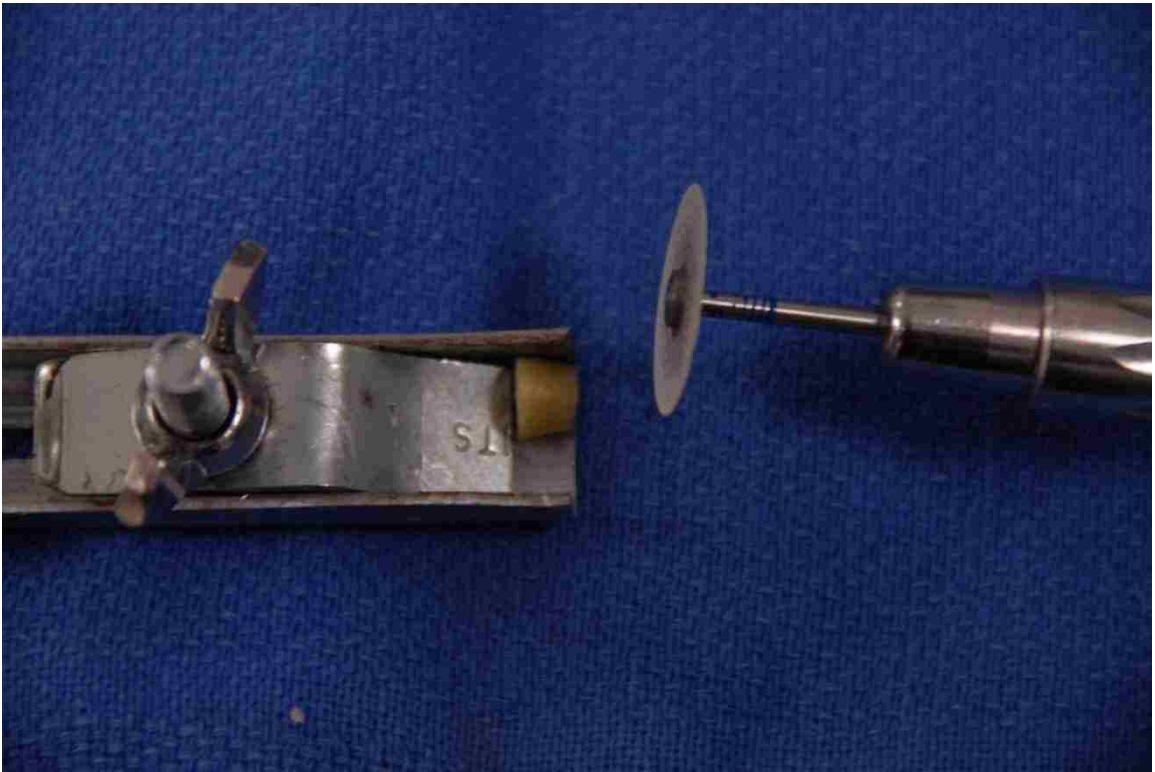


FIGURE 4. Final section of 5-mm dentin disk section in apparatus.

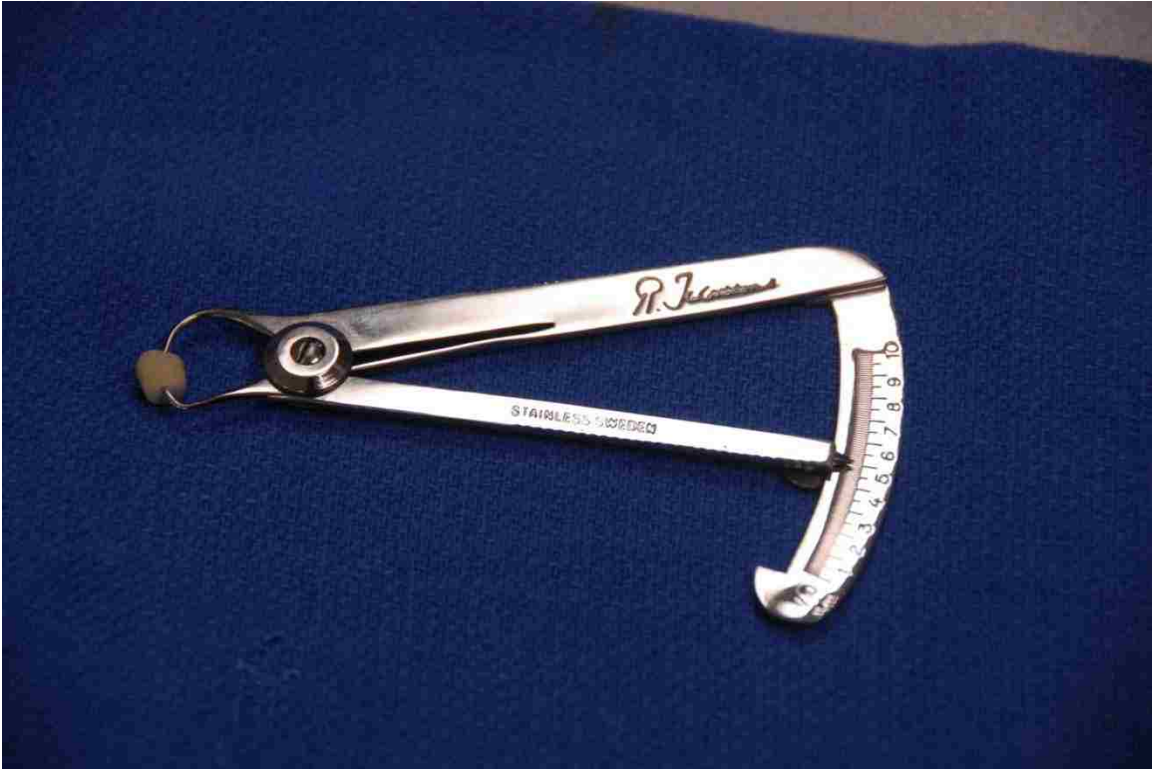

FIGURE 5. Measurement of dentin specimen in calipers.



FIGURE 6. Close-up of 5-mm mark on calipers.



FIGURE 7. Heavy duty drill press used to prepare lumens in dentin specimens.



FIGURE 8. Close-up of ISO 025 bur in drill press and dentin specimen.



FIGURE 9. Close-up of 2.5-mm diameter lumen prepared in dentin specimen.



FIGURE 10. Ultrasonic unit used to aid in the removal of the smear layer.



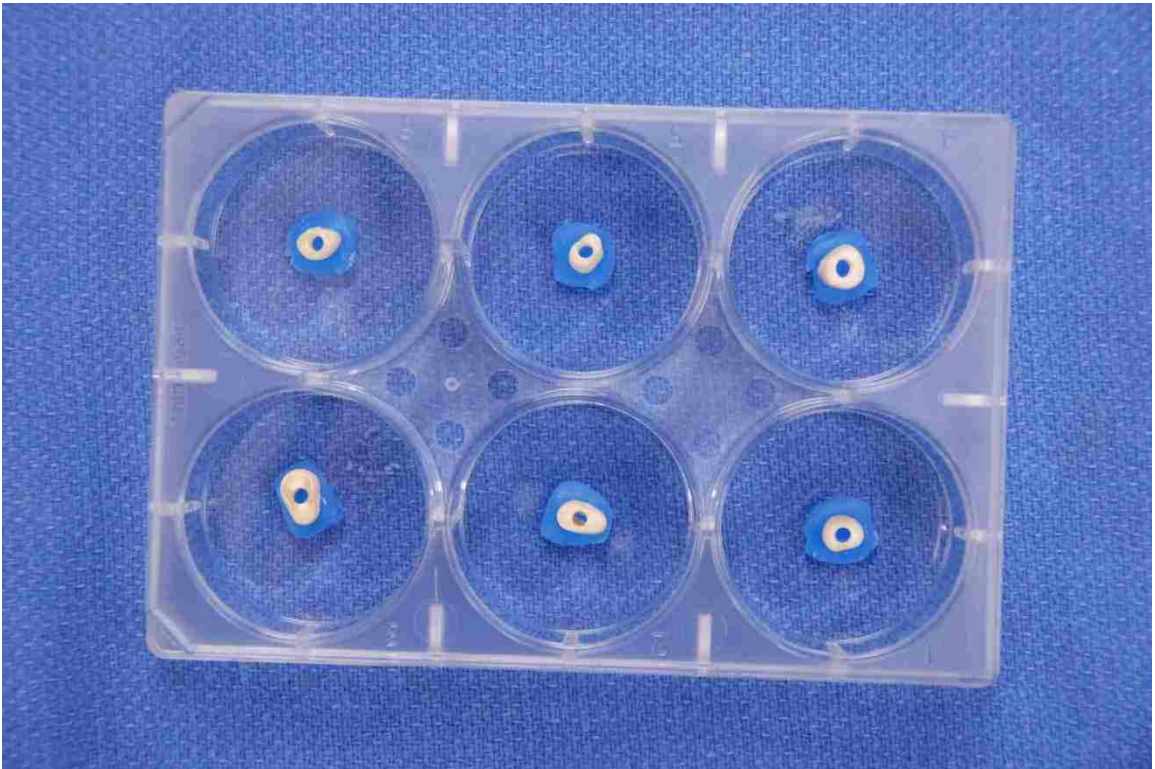


FIGURE 11. Specimens mounted in individual 22-mm diameter sterile tissue wells in six well plates.

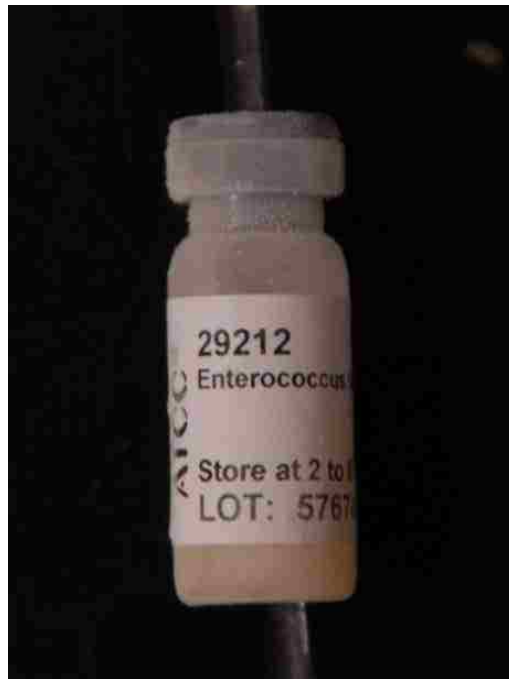


FIGURE 12. *Enterococcus faecalis* (ATCC 29212) used in this experiment.

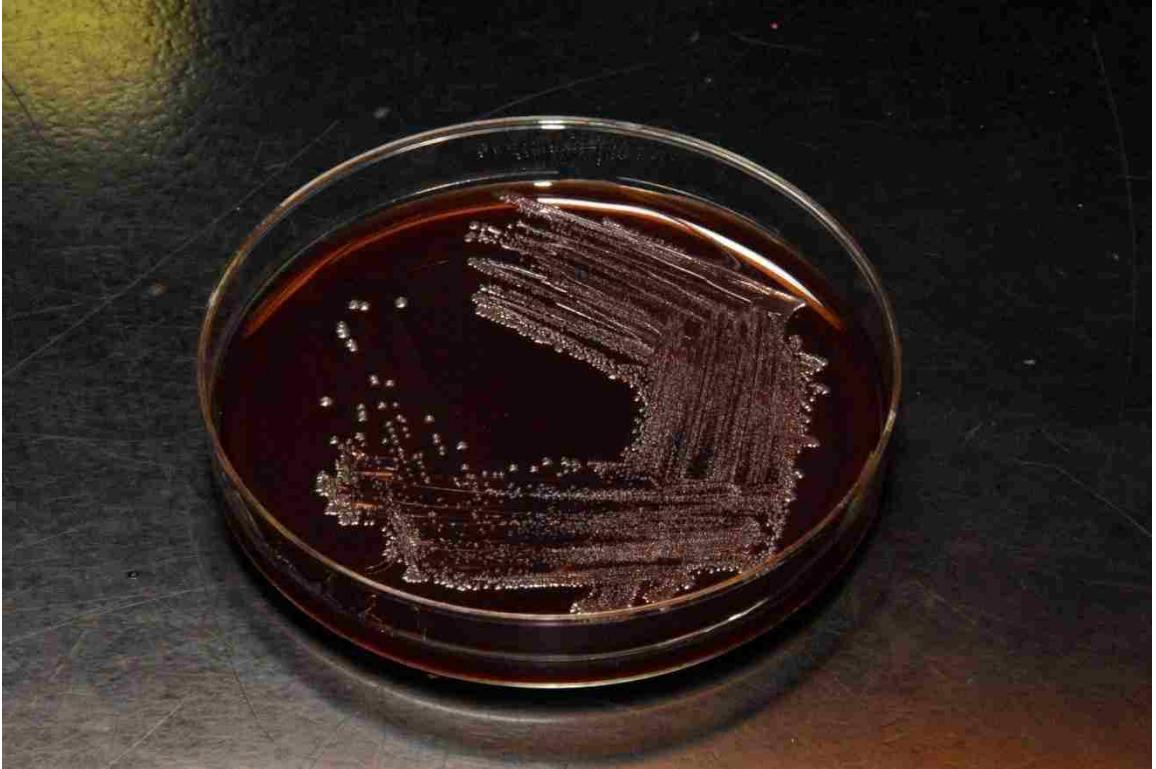

FIGURE 13. *E. faecalis* streak plate on BHI agar plate.

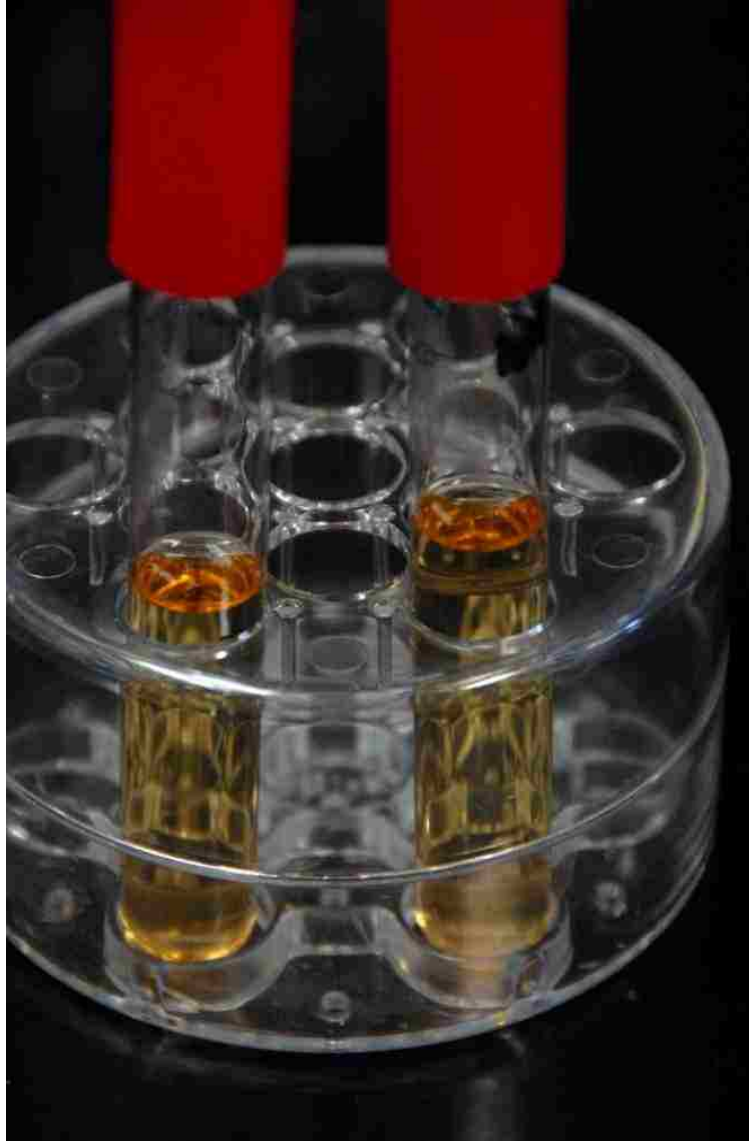


FIGURE 14. Sterile BHI broth – clear.

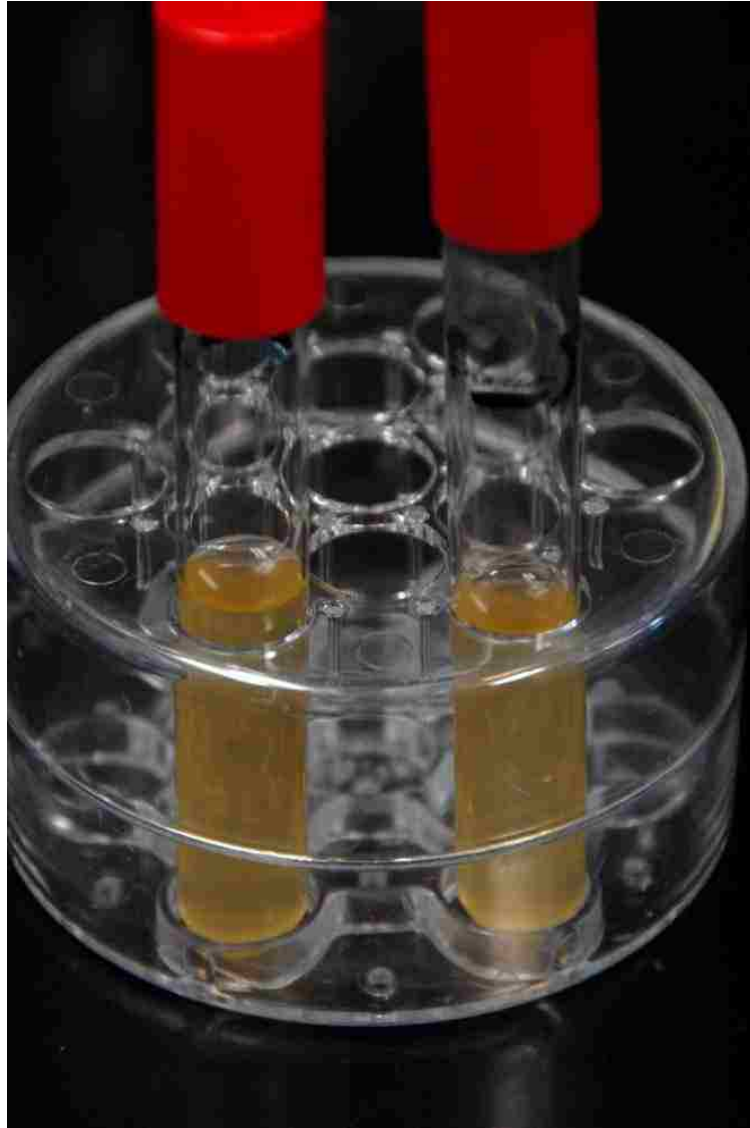


FIGURE 15. *E. faecalis* inoculated BHI broth – cloudy.



FIGURE 16. Comparison of sterile (clear) and inoculated (cloudy) BHI broth.

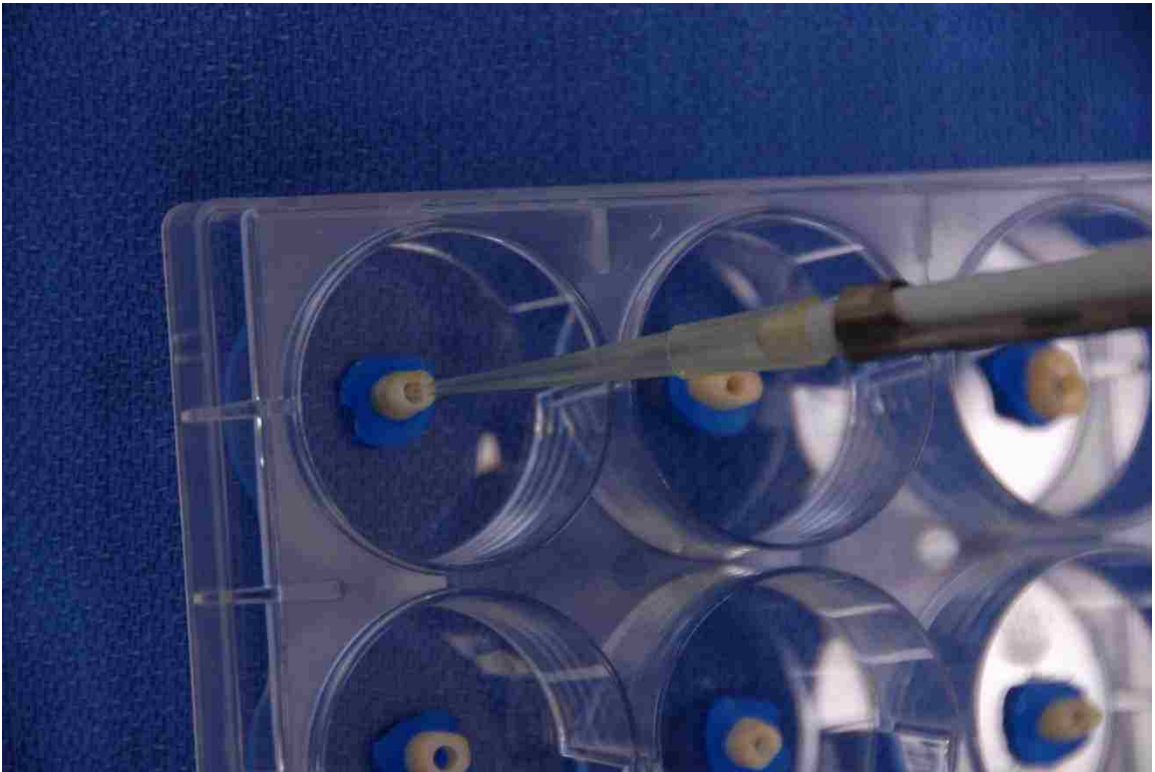

FIGURE 17. Inoculation of the dentin disk specimens with *E. faecalis*.

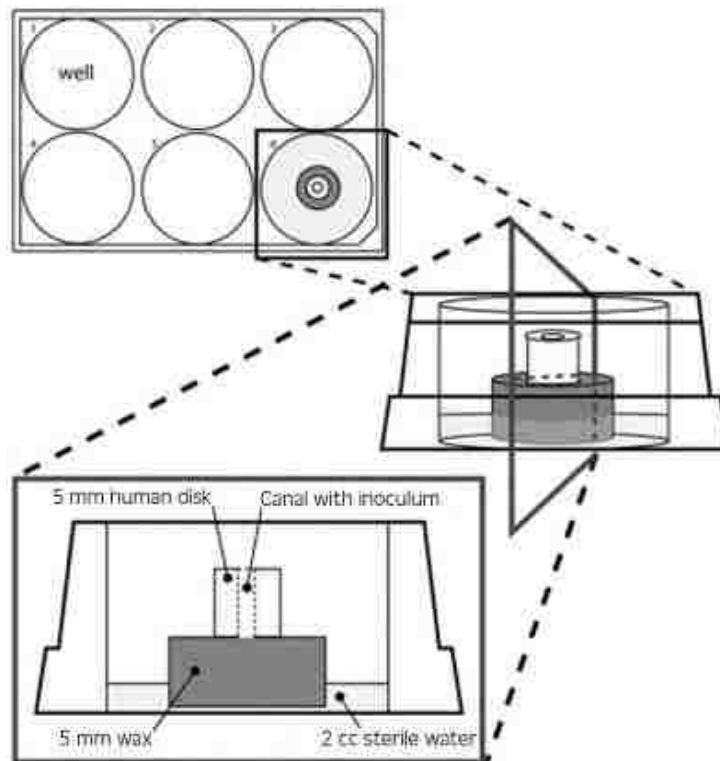


FIGURE 18. Schematic drawing of specimen within the tissue well.





FIGURE 19. Bunsen burner work station.



FIGURE 20. Incubator settings at either 37°C or 46°C with 5 percent CO<sub>2</sub>.

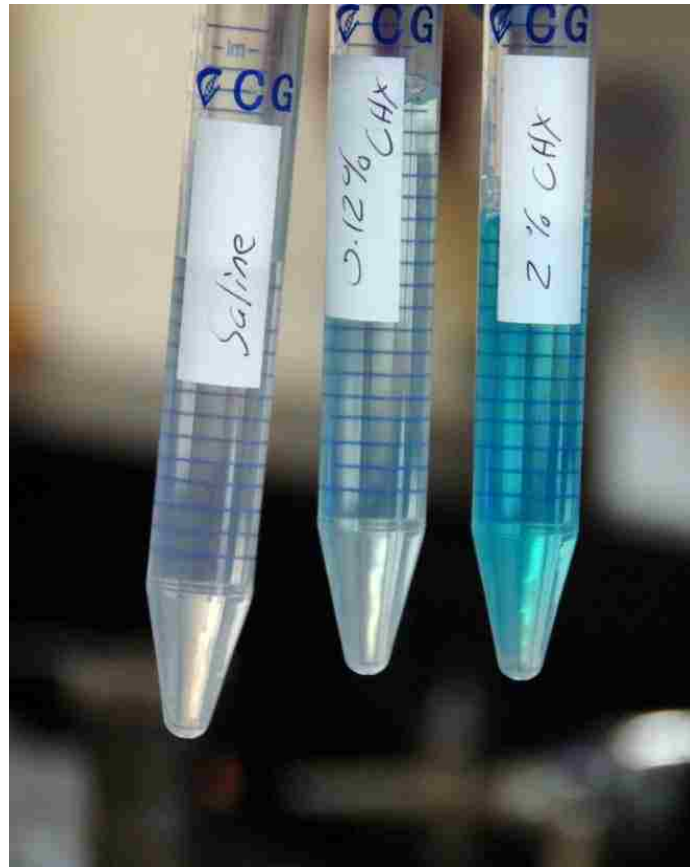

FIGURE 21. Saline, 0.12 percent CHX, and 2.0 percent CHX.



FIGURE 22. Scale used to measure dentin specimens.



FIGURE 23. Mortar and pestle used in conjunction with liquid nitrogen to pulverize the dentin specimens.



FIGURE 24. Vortex used at highest setting.



FIGURE 25. Overall view of Sonicator used in this experiment.



FIGURE 26. Spiral System used to spiral plate *E. faecalis* on the BHI agar plates.



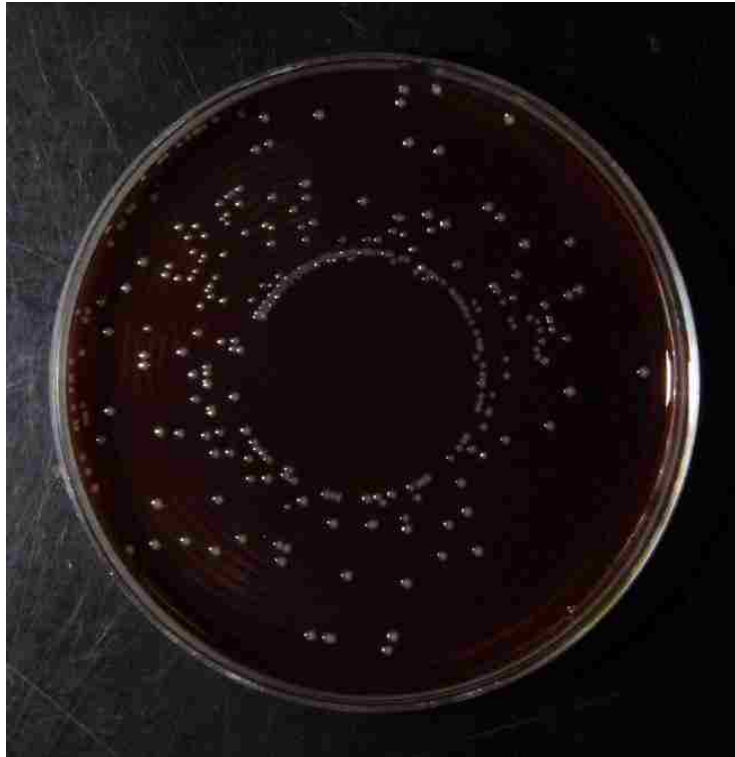

FIGURE 27. Spiral plate of *E. faecalis* at 1:100 dilution.

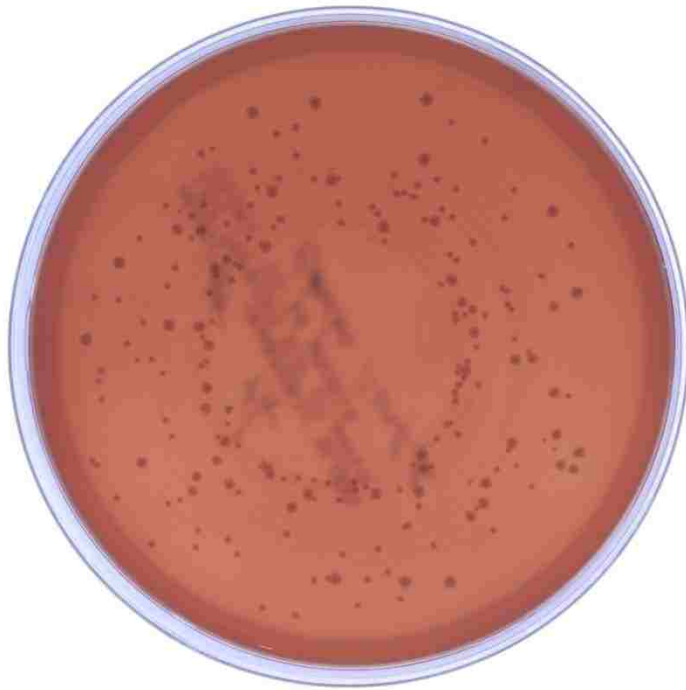


FIGURE 28. Spiral plate of *E. faecalis* at 1:100 dilution.

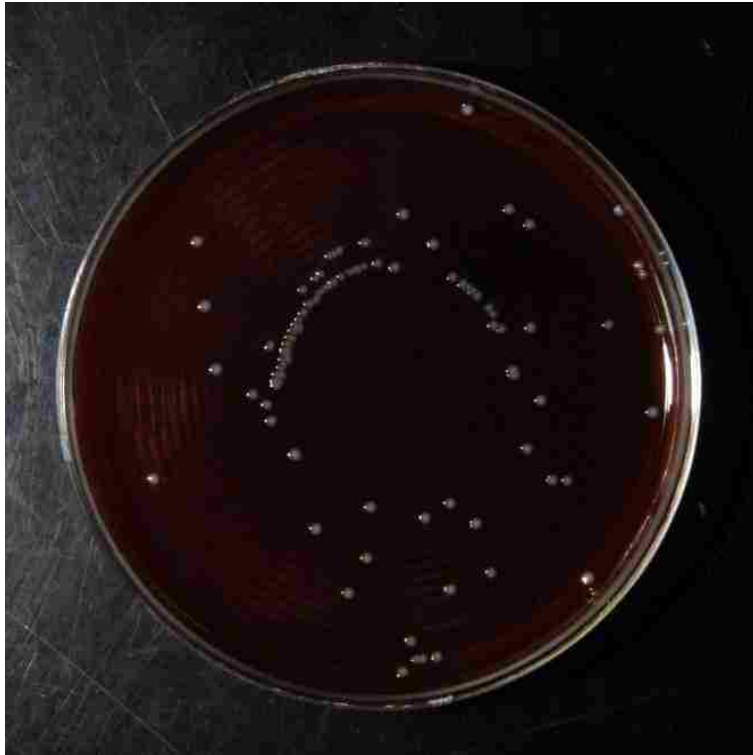

FIGURE 29. Spiral plate of *E. faecalis* at 1:1000 dilution.

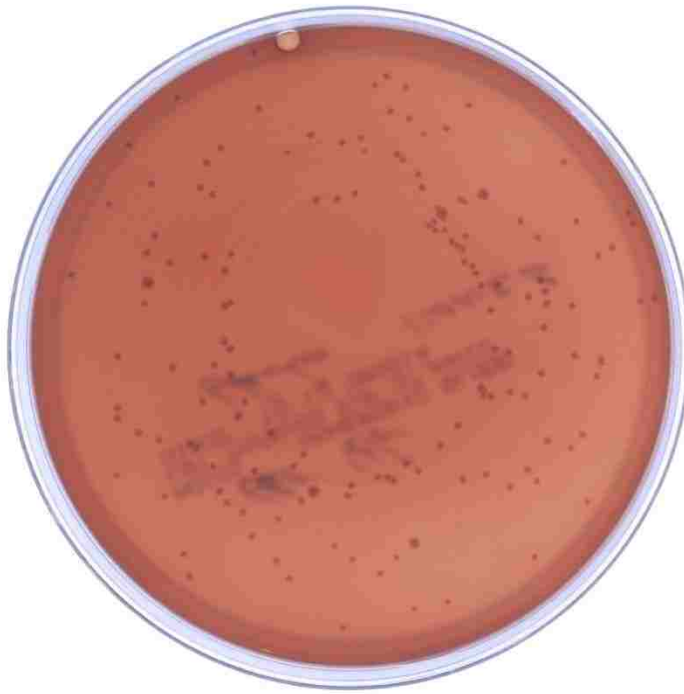

FIGURE 30. Spiral plate of *E. faecalis* at 1:1000 dilution.

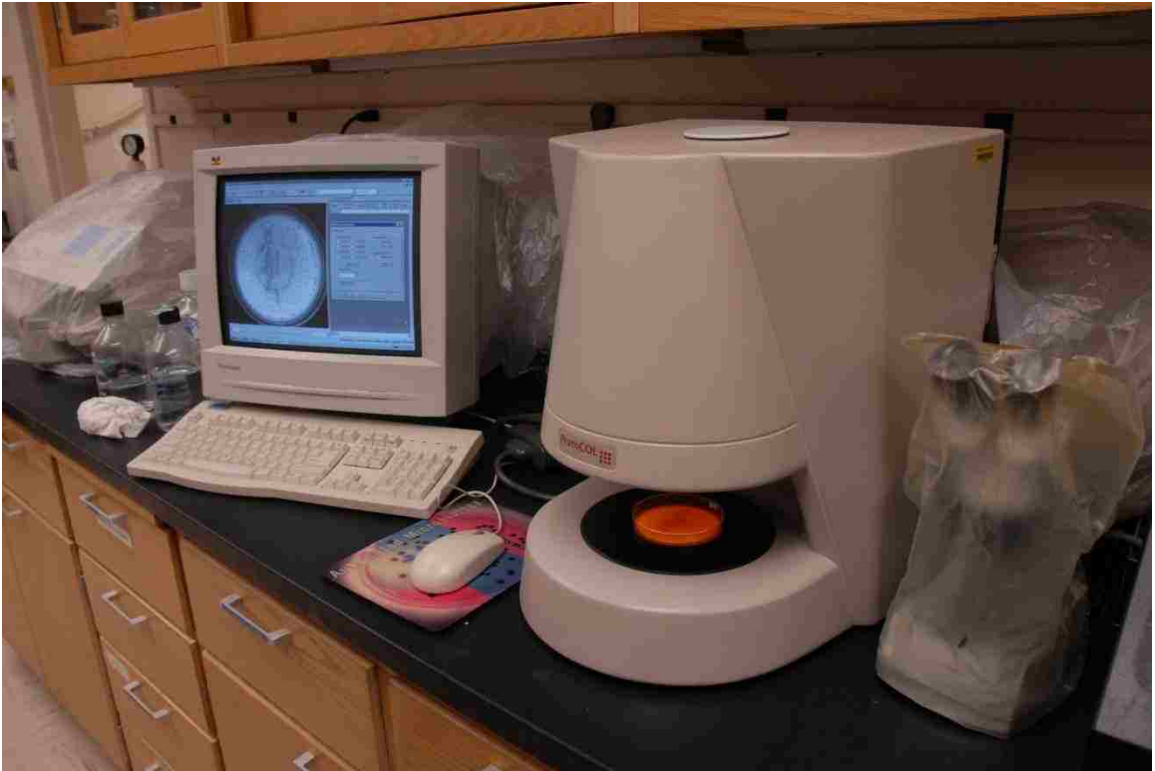

FIGURE 31. Overview of ProtoCOL automated colony counter.

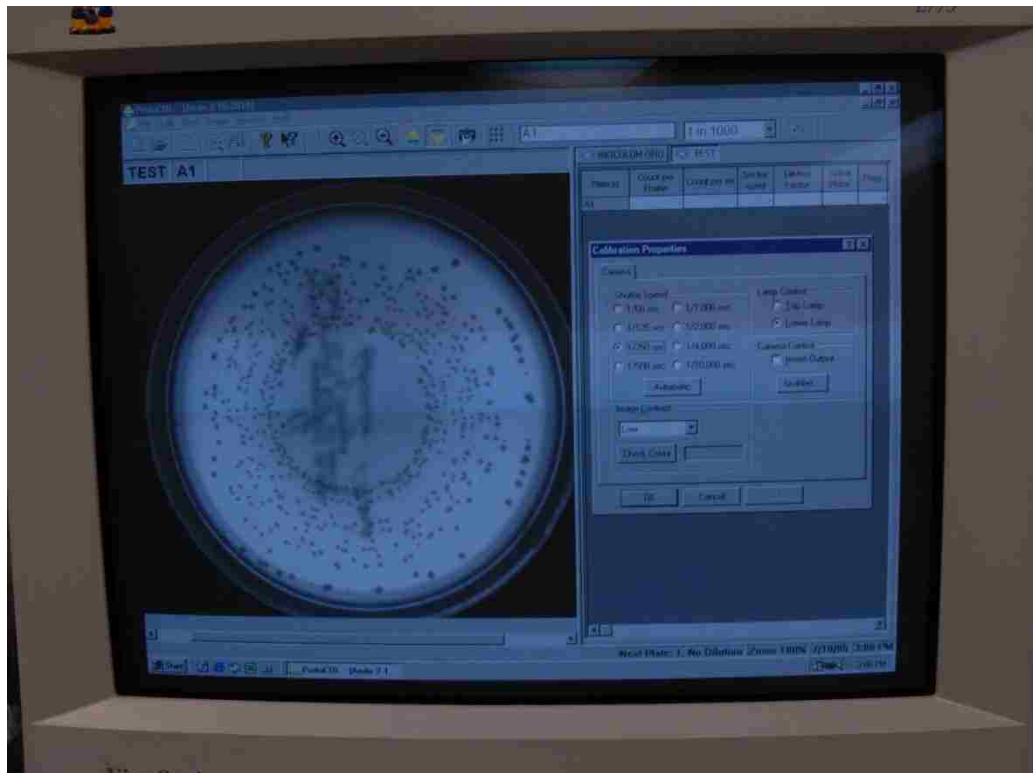


FIGURE 32. Computer settings for ProtoCOL automated colony counter.

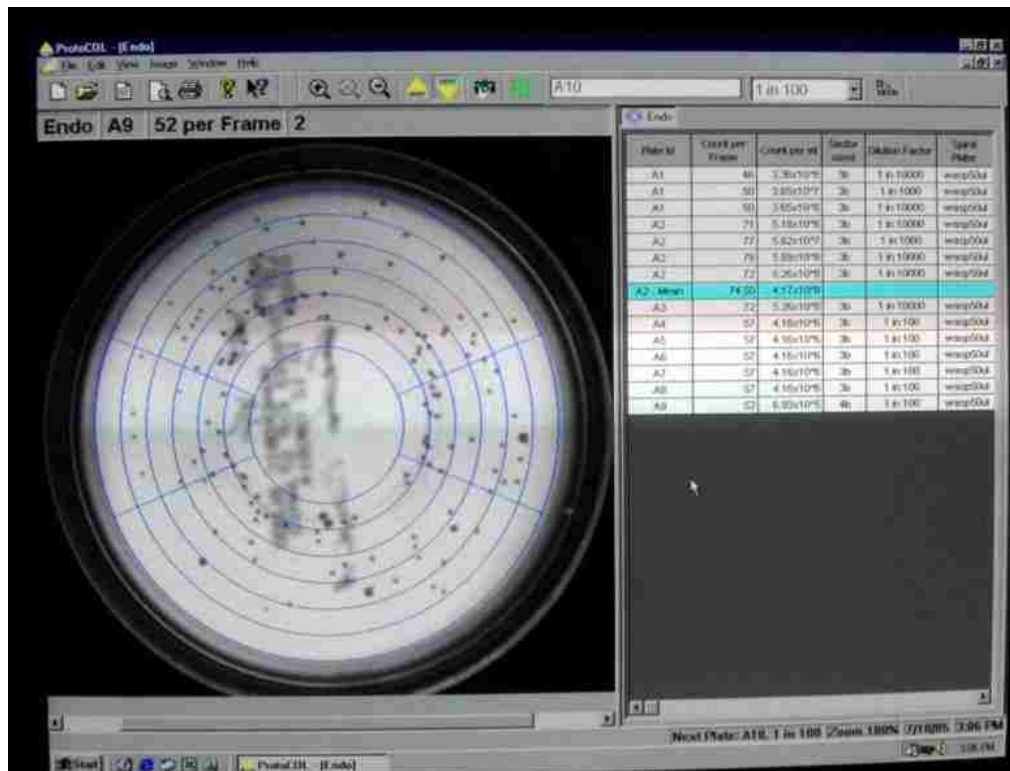


FIGURE 33. BHI agar spiral plate within ProtoCOL automated colony counter.

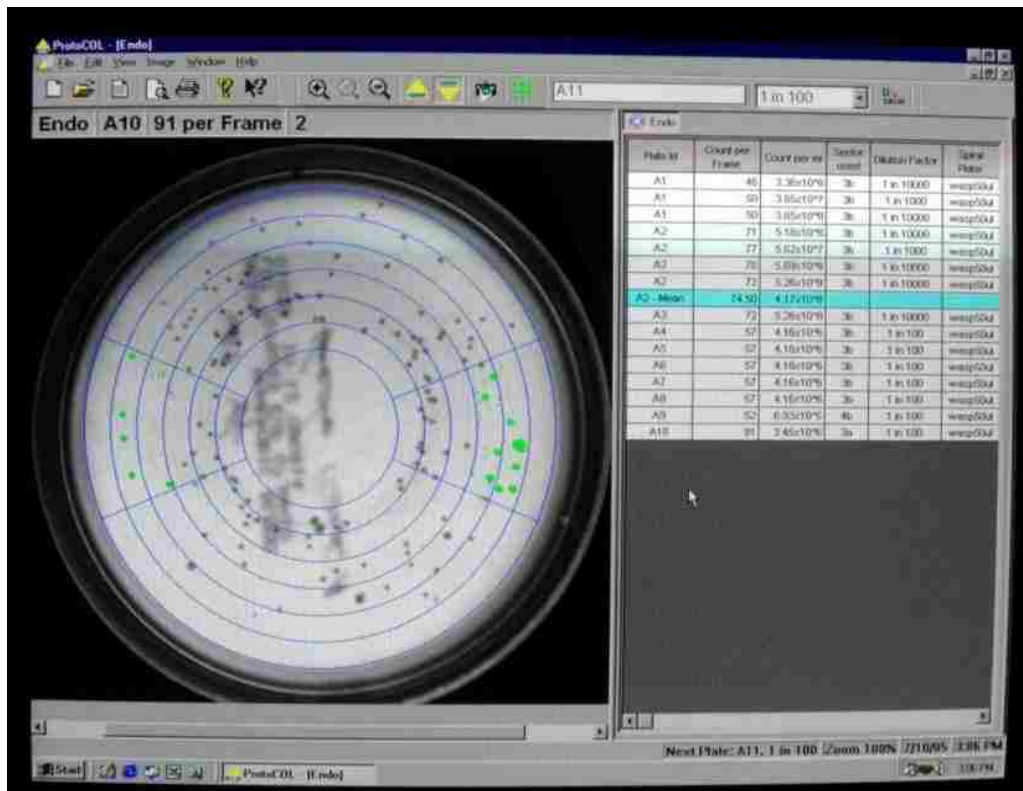


FIGURE 34. BHI agar spiral plate within ProtoCOL automated colony counter being scored (green dots) four times to acquire mean for data analysis.



TABLE I

Percentage loss of bacteria subjected to  $-70^{\circ}\text{C}$  with subsequent treatment with liquid nitrogen

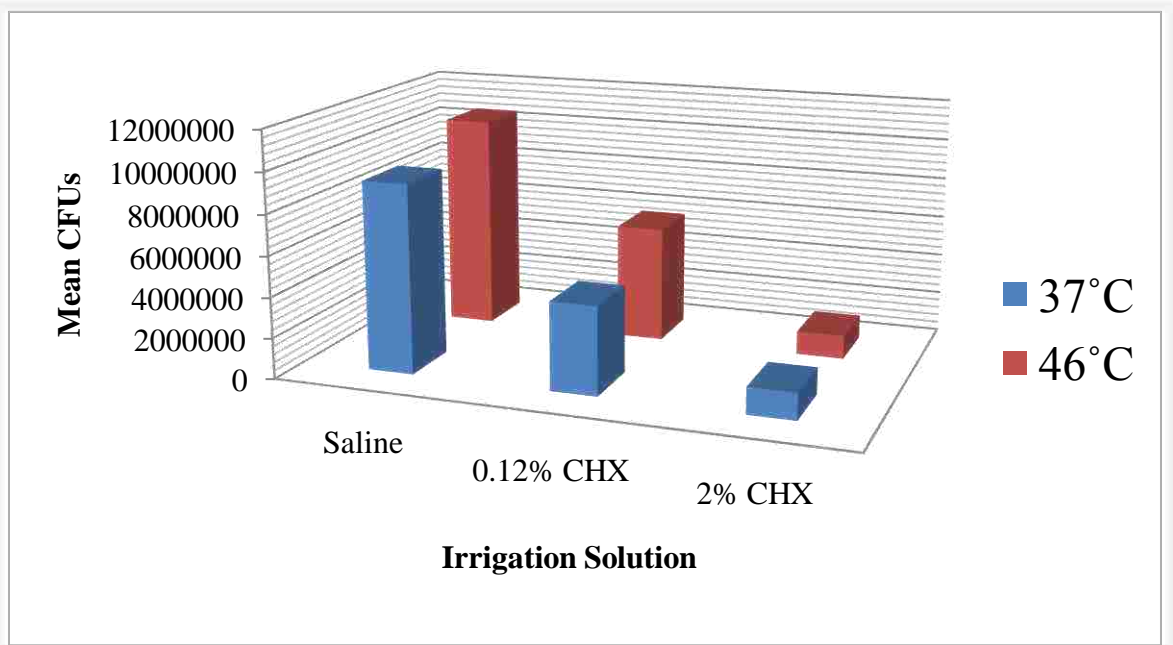
Non-Frozen Samples	CFU Counts
Plate 1	$5.18 \times 10^8$
Plate 2	$5.25 \times 10^8$
Frozen Samples	
Plate 1	$4.53 \times 10^8$
Plate 2	$4.68 \times 10^8$

TABLE II  
Summary of statistical data

Solution	Temperature	N	Mean	Std Dev.	Std Error	Min	Max
Saline	37°C	15	$9.28 \times 10^6$	$8.41 \times 10^6$	$2.17 \times 10^6$	$1.94 \times 10^6$	$3.43 \times 10^7$
Saline	46°C	15	$1.06 \times 10^7$	$1.01 \times 10^7$	$2.61 \times 10^6$	$1.87 \times 10^6$	$4.27 \times 10^7$
0.12% CHX	37°C	15	$4.33 \times 10^6$	$2.58 \times 10^6$	$7.53 \times 10^5$	$4.20 \times 10^5$	$9.69 \times 10^6$
0.12% CHX	46°C	15	$5.72 \times 10^6$	$2.9 \times 10^6$	$7.49 \times 10^5$	$8.52 \times 10^5$	$1.00 \times 10^7$
2% CHX	37°C	15	$1.32 \times 10^6$	$1.22 \times 10^6$	$3.15 \times 10^5$	$5.68 \times 10^4$	$4.19 \times 10^6$
2% CHX	46°C	15	$1.16 \times 10^6$	$1.24 \times 10^6$	$3.20 \times 10^5$	$1.72 \times 10^5$	$4.23 \times 10^6$

TABLE III

Summary of statistical data in graph form



## DISCUSSION

The causative role of microorganisms in the pathogenesis of pulp and periapical diseases has been well established and justifies the goal of elimination of bacteria as a critical step in root canal therapy.<sup>1</sup> Root canal asepsis is attempted by mechanical instrumentation, chemical irrigation, and intracanal medicaments. Despite these procedures, microorganisms such as *E. faecalis* may persist in small numbers, which might adversely affect the outcome of treatment. Pulp and periapical disease can also develop subsequent to treatment, due to bacterial contamination of the root canal system by coronal leakage. This confirms the importance of a coronal seal to the long-term success of endodontic therapy.

According to recent findings, bacteria in biofilms undergo a process of phenotypic diversification that decreases their susceptibility.<sup>165</sup> Multiple cell types in single-species biofilms may allow the survival against one particular antimicrobial agent. The chemical environment within the root canal system, including a complex mixture of inorganic and organic compounds, also aids in reducing the activity of various irrigation solutions. Therefore, using a combination of distinct antimicrobials against such biofilms and compounds is an effective strategy to eradicate the different cell types present.

To enhance the efficacy of irrigation solutions, their action on biofilms should involve the elimination of the EPS biofilm matrix as well as the bacteria itself, because this matrix could function as an additional source of nutrients and as a surface for future cell growth. CHX is a potent antimicrobial agent of proven substantivity, although it is

unable to effectively eradicate *E. faecalis* biofilms. Chavez de Paz et al.<sup>155</sup> demonstrated that NaOCl and EDTA were the most effective irrigation solutions affecting the cell membrane integrity of all organisms in biofilms. They also stated that cells in the upper layers of the biofilms were more affected by CHX compared with those in the deeper layers. Therefore, using a combination of several irrigation solutions to help disrupt the biofilm matrix will allow deeper penetration and elimination of residual cells throughout the biofilm and canal system.

*E. faecalis* was chosen as a test organism because it is facultative, nonfastidious, easy to grow and identify, and it efficiently and rapidly colonizes tubules.<sup>123</sup> It has been used extensively in endodontic research because it has been determined to be present in 38 percent to 63 percent of teeth with failed endodontic therapy.<sup>81, 166</sup> *E. faecalis* is considerably resistant to the common intracanal medication with calcium hydroxide compared with most other microbes.

The substantivity of CHX is dependent on the amount of CHX molecules available to interact with the dentin. Medicating the root canal system with a higher concentration of CHX will result in an increased resistance to microbial colonization. Komorowski et al.<sup>108</sup> demonstrated that in contrast with large bovine canals in which 0.2-percent CHX effectively imparts substantivity, in smaller human dentinal canals, a higher concentration of CHX was required to impart a comparable effect. Therefore, to make this study more clinically relevant, extracted human teeth were used instead of bovine teeth. Haapasalo and Orstavik<sup>164</sup> developed an *in-vitro* model that was modified in the present study to include quantitative analysis of *E. faecalis* within the dentinal tubules after the irrigation regimen of the test irrigation solutions. To eliminate the variable

effects of mechanical instrumentation and the antimicrobial effect of smear layer removal in reducing bacterial counts, both the lumen preparation and smear layer removal were accomplished before sterilization. The smear layer removal also allowed deeper penetration of both the microorganisms and the test irrigation solution.<sup>17</sup>

The susceptibility of *E. faecalis* differs between irrigation solutions during their exponential growth, stationary phase, and starvation phase growth cycle. To adequately replicate *in vivo* conditions within the root canal system, Portenier et al.<sup>150</sup> suggested the use of starvation phase cells. *E. faecalis* was assumed to be utilized in all three growth phases in this experiment. When *E. faecalis* was inoculated into the dentin specimens, they were either in the exponential growth or stationary phase. During this time their sterile BHI nutrient source was depleted and evaporated. The bacteria cells then went into the starvation phase until new sterile BHI broth was replenished. In future studies, more emphasis should be placed on the physiological status of the bacteria to better duplicate *in vivo* conditions, or test multiple microorganisms as in a biofilm.

Several studies have demonstrated the increased effectiveness of heated NaOCl<sup>16,</sup><sup>140-142</sup> with one study investigating heated 0.12-percent CHX.<sup>17</sup> To date there have not been any published articles that describe the heating of 2.0-percent CHX and its antimicrobial efficacy and clinical relevance towards *E. faecalis* within dentinal tubules in human root canal systems. Therefore, the intent of this study was to evaluate the antibacterial efficacy of 0.12-percent and 2.0-percent CHX on eliminating *E. faecalis* from the dentinal tubules, and whether this antimicrobial effect was enhanced by heat. The experimental 46°C temperature was used in this study to compare the results with Evanov et al.,<sup>17</sup> who determined that heat enhanced the antimicrobial action of both 10-

percent calcium hydroxide and 0.12-percent CHX relative to saline and to either experimental medication at 37°C towards *E. faecalis*. The other reason why 46°C experimental temperature was used was that Erikson and Albrektsson<sup>167</sup> discovered that the threshold temperature for bone survival was 47°C for one minute.

Considering that CHX can break down to form PCA by exposure to heat, caution is advised against heating CHX. Cameron<sup>168</sup> stated that even the use of ultrasonic activation to enhance the effectiveness of irrigation solutions can increase the temperature to at least 45°C. Basrani et al.<sup>144</sup> verified the presence of an aromatic amine similar to PCA in the precipitate formed between the interaction of 6.0-percent NaOCl and 2.0-percent CHX, and when 2.0-percent CHX is heated at 45°C. Therefore, they advised that CHX not be used in combination with NaOCl or with ultrasonic activation that raises the temperature above 37°C until more information is available. Future studies on the effects of sonic and ultrasonic activation on irrigation solutions are therefore warranted.

The results of this study demonstrated that solution temperature did not have a significant effect on *E. faecalis* CFU. To make a statistically significant difference between the 37°C and 46°C temperatures for the 0.12-percent CHX group, a sample size of 90 specimens would be indicated. For the 2.0-percent CHX group, a sample size of 11,388 specimens per temperature would be needed to find the observed difference between the 37°C and 46°C temperatures.

The results of this study demonstrate no significant difference between the two temperatures tested, at either concentration, along with the possibility of PCA formation with heated CHX, and therefore, it is strongly advised not to use heated CHX within the



root canal system during endodontic therapy until further studies and information are available. In regard to concentration, a higher concentration of 2.0-percent CHX significantly reduced the CFU compared with a lower 0.12-percent CHX solution, which significantly reduced the CFU compared with saline. Therefore, the use of 2.0-percent CHX is advised as a final irrigation solution after copious amounts of NaOCl and EDTA for effective antimicrobial efficacy and substantivity. Further investigations of the use of 2.0-percent CHX without heat to enhance the antibacterial efficacy against both *E. faecalis* and their associated biofilms are warranted. These future studies may involve the use of sonic or ultrasonic activation, with positive or negative pressure irrigation.

SUMMARY AND CONCLUSIONS

The purpose of this study was to investigate the antibacterial efficacy of 0.12-percent and 2.0-percent chlorhexidine gluconate (CHX) on eliminating *Enterococcus faecalis* from dentinal tubules, and whether this antibacterial effect was enhanced by heat. To date there have been no published articles that describe the heating of 2.0-percent CHX and its antimicrobial efficacy and clinical relevance regarding *E. faecalis*, within dentinal tubules in root canal systems.

Ninety-five human extracted, single rooted, maxillary, central, lateral, and canine teeth were used to prepare dentin disk specimens. After proper sterilization, a 2.5-mm ISO-sized diameter lumen was prepared, then these canals were filled with brain-heart infusion (BHI) broth and infected with *E. faecalis* and incubated for 72 hours to allow sufficient time for growth and adherence to the lumen wall. The BHI was removed and the specimens in equally divided groups were rinsed with sterile saline and filled with either saline, or 0.12 percent CHX, or 2.0 percent CHX at ambient temperature (24°C) or experimental temperature (46°C), and incubated at oral temperature (37°C) or the experimental temperature (46°C), respectively. The specimens were frozen to -70°C, pulverized in liquid nitrogen; serial dilutions of 1:100 and 1:1000 were prepared and spiral plated on BHI agar plates in duplicates and incubated. The number of bacterial colonies recorded 24 hours later for data analysis.

The results of this investigation demonstrated no statistically significant difference with the addition of heat to either test irrigation solution regarding the

elimination of *E. faecalis* from dentinal tubules within the root canal system. There was a statistically significant difference in the antibacterial efficacy of CHX against *E. faecalis* in comparison with the concentration tested. A higher concentration of 2.0-percent CHX demonstrated a significantly higher antibacterial efficacy against *E. faecalis* compared with 0.12-percent CHX, and likewise with the saline control. The clinical significance would indicate the use of a higher concentration of 2.0-percent CHX solution as an irrigation solution for enhanced antimicrobial efficacy in eliminating *E. faecalis* from the root canal system for improved endodontic success. Future investigations of the use of 2.0-percent CHX without heat to enhance the antibacterial efficacy against both *E. faecalis* and their associated biofilms are warranted.

REFERENCES

1. Kakehashi S, Stanley HR, Fitzgerald RJ. The effects of surgical exposures of dental pulps in germ-free and conventional laboratory rats. *Oral Surg Oral Med Oral Pathol* 1965;20:340-9.
2. Paquette L, Legner M, Fillery ED, Friedman S. Antibacterial efficacy of chlorhexidine gluconate intracanal medication in vivo. *J Endod* 2007;33(7):788-95.
3. Bui TB, Baumgartner JC, Mitchell JC. Evaluation of the interaction between sodium hypochlorite and chlorhexidine gluconate and its effect on root dentin. *J Endod* 2008;34(2):181-5.
4. Wang CS, Arnold RR, Trope M, Teixeira FB. Clinical efficiency of 2% chlorhexidine gel in reducing intracanal bacteria. *J Endod* 2007;33(11):1283-9.
5. Kishen A, Sum CP, Mathew S, Lim CT. Influence of irrigation regimens on the adherence of *Enterococcus faecalis* to root canal dentin. *J Endod* 2008;34(7):850-4.
6. Jeansonne MJ, White RR. A comparison of 2.0% chlorhexidine gluconate and 5.25% sodium hypochlorite as antimicrobial endodontic irrigants. *J Endod* 1994;20(6):276-8.
7. Estrela C, Pimenta FC, Ito IY, Bammann LL. Antimicrobial evaluation of calcium hydroxide in infected dentinal tubules. *J Endod* 1999;25(6):416-8.
8. Siqueira JF, Jr., Paiva SS, Rocas IN. Reduction in the cultivable bacterial populations in infected root canals by a chlorhexidine-based antimicrobial protocol. *J Endod* 2007;33(5):541-7.
9. Lee Y, Han SH, Hong SH, Lee JK, Ji H, Kum KY. Antimicrobial efficacy of a polymeric chlorhexidine release device using in vitro model of *Enterococcus faecalis* dentinal tubule infection. *J Endod* 2008;34(7):855-8.
10. Kontakiotis EG, Tsatsoulis IN, Papanakou SI, Tzanetakis GN. Effect of 2% chlorhexidine gel mixed with calcium hydroxide as an intracanal medication on sealing ability of permanent root canal filling: a 6-month follow-up. *J Endod* 2008;34(7):866-70.
11. Vahdaty A, Pitt Ford TR, Wilson RF. Efficacy of chlorhexidine in disinfecting dentinal tubules in vitro. *Endod Dent Traumatol* 1993;9(6):243-8.

12. Siqueira JF, Jr., Rocas IN, Santos SR, Lima KC, Magalhaes FA, de Uzeda M. Efficacy of instrumentation techniques and irrigation regimens in reducing the bacterial population within root canals. *J Endod* 2002;28(3):181-4.
13. Lima KC, Fava LR, Siqueira JF, Jr. Susceptibilities of *Enterococcus faecalis* biofilms to some antimicrobial medications. *J Endod* 2001;27(10):616-9.
14. White RR, Hays GL, Janer LR. Residual antimicrobial activity after canal irrigation with chlorhexidine. *J Endod* 1997;23(4):229-31.
15. Stuart CH, Schwartz SA, Beeson TJ, Owatz CB. *Enterococcus faecalis*: its role in root canal treatment failure and current concepts in retreatment. *J Endod* 2006;32(2):93-8.
16. Abou-Rass M, Oglesby SW. The effects of temperature, concentration, and tissue type on the solvent ability of sodium hypochlorite. *J Endod* 1981;7(8):376-7.
17. Evanov CDDS, Liewehr FDDSMS, Buxton TBP, Joyce APDDS. Antibacterial efficacy of calcium hydroxide and chlorhexidine gluconate irrigants at 37°C and 46°C. *J Endod* 2004;30(9):653-57.
18. Goodis H. Seltzer and Bender's dental pulp. Carol Stream, IL: Quintessence Books; 2002.
19. Gutmann JL. History of endodontics In: Ingle's Endodontics. Hamilton, Ontario: BC Decker; 2008.
20. Cruse WP, Bellizzi R. A historic review of endodontics, 1689-1963. (Pt 1). *J Endod* 1980;6(3):495-9.
21. Ostrander FD. The practice of endodontics: past, present, and future. *J Dent Educ* 1967;31(3):386-8.
22. Grossman LI. Endodontics 1776-1976: a bicentennial history against the background of general dentistry. *J Am Dent Assoc* 1976;93(1):78-87.
23. Grossman LI. Endodontics: then and now. *Oral Surg Oral Med Oral Pathol* 1971;32(2):254-9.
24. Jacobsohn PH, Fedran RJ. Making darkness visible: the discovery of x-ray and its introduction to dentistry. *J Am Dent Assoc* 1995;126(10):1359-67.
25. Grossman LI. Endodontics: a peep into the past and the future. *Oral Surg Oral Med Oral Pathol* 1974;37(4):599-608.
26. Bellizzi R, Cruse WP. A historic review of endodontics, 1689-1963. (Pt 3). *J Endod* 1980;6(5):576-80.
27. Cohen S, Burns RC. Pathways of the pulp. St. Louis: Mosby; 2002.

28. Ingle JI, Bakland LK, Baumgartner JC. Ingle's endodontics. Hamilton: Decker; 2008.
29. Weine FS. Endodontic therapy. St. Louis [Mo.]: Mosby; 1996.
30. Miller WD. An introduction to the study of the bacterio-pathology of the dental pulp. Dent Cosmos 1894;36:505-28.
31. Stewart GG. The importance of chemomechanical preparation of the root canal. Oral Surg Oral Med Oral Pathol 1955;8(9):993-7.
32. Grossman LI. Rationale of endodontic treatment. Dent Clin North Am 1967:483-90.
33. Schilder H. Filling root canals in three dimensions. Dent Clin North Am 1967:723-44.
34. Pitt Ford TR. Relation between seal of root fillings and tissue response. Oral Surg Oral Med Oral Pathol 1983;55(3):291-4.
35. Ray HA, Trope M. Periapical status of endodontically treated teeth in relation to the technical quality of the root filling and the coronal restoration. Int Endod J 1995;28(1):12-8.
36. Sjogren U, Hagglund B, Sundqvist G, Wing K. Factors affecting the long-term results of endodontic treatment. J Endod 1990;16(10):498-504.
37. Walton RE, Torabinejad M. Endodontics: principles and practice. St. Louis, Mo.: Saunders/Elsevier; 2009.
38. Friedman S, Abitbol S, Lawrence HP. Treatment outcome in endodontics: the Toronto Study. Phase 1: initial treatment. J Endod 2003;29(12):787-93.
39. Imura N, Pinheiro ET, Gomes BP, Zaia AA, Ferraz CC, Souza-Filho FJ. The outcome of endodontic treatment: a retrospective study of 2000 cases performed by a specialist. J Endod 2007;33(11):1278-82.
40. Alley BS, Kitchens GG, Alley LW, Eleazer PD. A comparison of survival of teeth following endodontic treatment performed by general dentists or by specialists. Oral Surg Oral Med Oral Pathol Oral Radiol Endod 2004;98(1):115-8.
41. Salehrabi R, Rotstein I. Endodontic treatment outcomes in a large patient population in the USA: an epidemiological study. J Endod 2004;30(12):846-50.
42. Lazarski MP, Walker WA, 3rd, Flores CM, Schindler WG, Hargreaves KM. Epidemiological evaluation of the outcomes of nonsurgical root canal treatment in a large cohort of insured dental patients. J Endod 2001;27(12):791-6.
43. Meyer W. Anatomy of root canals, demonstrated on microscopic reconstruction models. Dtsch Zahnarzt Z 1970;25(11):1064-77.



44. Cunningham CJ, Senia ES. A three-dimensional study of canal curvatures in the mesial roots of mandibular molars. *J Endod* 1992;18(6):294-300.
45. Black GV. Descriptive anatomy of the human teeth. Philadelphia: S.S. White manufacturing Co.; 1890.
46. Hess W, Zürcher E, Dolamore WH. The anatomy of the root-canals of the teeth of the permanent dentition. London: J. Bale, Sons & Danielsson; 1925.
47. Weine FS, Healey HJ, Gerstein H, Evanson L. Canal configuration in the mesiobuccal root of the maxillary first molar and its endodontic significance. *Oral Surg Oral Med Oral Pathol* 1969;28(3):419-25.
48. Vertucci F, Seelig A, Gillis R. Root canal morphology of the human maxillary second premolar. *Oral Surg Oral Med Oral Pathol* 1974;38(3):456-64.
49. Pineda F, Kuttler Y. Mesiodistal and buccolingual roentgenographic investigation of 7,275 root canals. *Oral Surg Oral Med Oral Pathol* 1972;33(1):101-10.
50. Krasner P, Rankow HJ. Anatomy of the pulp-chamber floor. *J Endod* 2004;30(1):5-16.
51. Stropko JJ. Canal morphology of maxillary molars: clinical observations of canal configurations. *J Endod* 1999;25(6):446-50.
52. Kulild JC, Peters DD. Incidence and configuration of canal systems in the mesiobuccal root of maxillary first and second molars. *J Endod* 1990;16(7):311-7.
53. Baldassari-Cruz LA, Lilly JP, Rivera EM. The influence of dental operating microscope in locating the mesiolingual canal orifice. *Oral Surg Oral Med Oral Pathol Oral Radiol Endod* 2002;93(2):190-4.
54. Skidmore AE, Bjorndal AM. Root canal morphology of the human mandibular first molar. *Oral Surg Oral Med Oral Pathol* 1971;32(5):778-84.
55. Kuttler Y. Microscopic investigation of root apexes. *J Am Dent Assoc* 1955;50(5):544-52.
56. Kuttler Y. A precision and biologic root canal filling technic. *J Am Dent Assoc* 1958;56(1):38-50.
57. Levy AB, Glatt L. Deviation of the apical foramen from the radiographic apex. *J N J State Dent Soc* 1970;41(8):12-3.
58. Schilder H. Cleaning and shaping the root canal. *Dent Clin North Am* 1974;18(2):269-96.
59. Ingle JJ. Endodontic instruments and instrumentation. *Dent Clin North Am* 1957:805-22.

60. Buchanan LS. Cleaning and shaping the root canal system. In: Cohen A, Burns R, eds. *Pathways of the pulp*. 5th ed. St. Louis: CV Mosby Co.; 1991, p. 166-92.
61. Walia HM, Brantley WA, Gerstein H. An initial investigation of the bending and torsional properties of Nitinol root canal files. *J Endod* 1988;14(7):346-51.
62. Esposito PT, Cunningham CJ. A comparison of canal preparation with nickel-titanium and stainless steel instruments. *J Endod* 1995;21(4):173-6.
63. Spangberg L. The wonderful world of rotary root canal preparation. *Oral Surg Oral Med Oral Pathol Oral Radiol Endod* 2001;92(5):479.
64. Miller WD. Gangrenous tooth-pulps as centers of infection. *Dent Cosmos* 1888;30:213.
65. Miller WD. The decomposition of the contents of the dentinal tubules as a disturbing factor in the treatment of pulpless teeth. *Dent Cosmos* 1890;32:349.
66. Moller AJ, Fabricius L, Dahlen G, Ohman AE, Heyden G. Influence on periapical tissues of indigenous oral bacteria and necrotic pulp tissue in monkeys. *Scand J Dent Res* 1981;89(6):475-84.
67. Gier RE, Mitchell DF. Anachoretic effect of pulpitis. *J Dent Res* 1968;47(4):564-70.
68. Bergenholtz G, Lindhe J. Effect of soluble plaque factors on inflammatory reactions in the dental pulp. *Scand J Dent Res* 1975;83(3):153-8.
69. Warfvinge J, Bergenholtz G. Healing capacity of human and monkey dental pulps following experimentally-induced pulpitis. *Endod Dent Traumatol* 1986;2(6):256-62.
70. Lin L, Langeland K. Light and electron microscopic study of teeth with carious pulp exposures. *Oral Surg Oral Med Oral Pathol* 1981;51(3):292-316.
71. Seltzer S. *Endodontology: biologic considerations of endodontic procedures*. New York: McGraw-Hill; 1971.
72. Sundqvist G. Taxonomy, ecology, and pathogenicity of the root canal flora. *Oral Surg Oral Med Oral Pathol* 1994;78(4):522-30.
73. Sjogren U, Figdor D, Persson S, Sundqvist G. Influence of infection at the time of root filling on the outcome of endodontic treatment of teeth with apical periodontitis. *Int Endod J* 1997;30(5):297-306.
74. Heling B, Shapira J. Roentgenologic and clinical evaluation of endodontically treated teeth, with or without negative culture. *Quintessence Int Dent Dig* 1978;9(11):79-84.
75. Oliet S, Sorin SM. Evaluation of clinical results based upon culturing root canals. *J British Endod Society* 1969;3:3-6.

76. Ingle JJ, Zeldow BJ. An evaluation of mechanical instrumentation and the negative culture in endodontic therapy. *J Am Dent Assoc* 1958;57(4):471-6.
77. Morse DR. The endodontic culture technique. Factors leading to false positive and negative results. *N Y State Dent J* 1971;37(2):88-94.
78. Morse DR. The endodontic culture technique: an impractical and unnecessary procedure. *Dent Clin North Am* 1971;15(4):793-806.
79. Morse DR. Does culturing contribute to endodontic success? *Trans Int Conf Endod* 1973;5(0):91-100.
80. Akpata ES. Effect of endodontic procedures on the population of viable microorganisms in the infected root canal. *J Endod* 1976;2(12):369-73.
81. Sundqvist G, Figdor D, Persson S, Sjogren U. Microbiologic analysis of teeth with failed endodontic treatment and the outcome of conservative re-treatment. *Oral Surg Oral Med Oral Pathol Oral Radiol Endod* 1998;85(1):86-93.
82. Siqueira JF, Jr., Rocas IN. Polymerase chain reaction-based analysis of microorganisms associated with failed endodontic treatment. *Oral Surg Oral Med Oral Pathol Oral Radiol Endod* 2004;97(1):85-94.
83. Siqueira JF, Jr., Rocas IN, Souto R, de Uzeda M, Colombo AP. Actinomyces species, streptococci, and Enterococcus faecalis in primary root canal infections. *J Endod* 2002;28(3):168-72.
84. Siren EK, Haapasalo MP, Ranta K, Salmi P, Kerosuo EN. Microbiological findings and clinical treatment procedures in endodontic cases selected for microbiological investigation. *Int Endod J* 1997;30(2):91-5.
85. Pinheiro ET, Gomes BP, Ferraz CC, Sousa EL, Teixeira FB, Souza-Filho FJ. Microorganisms from canals of root-filled teeth with periapical lesions. *Int Endod J* 2003;36(1):1-11.
86. Rocas IN, Siqueira JF, Jr., Santos KR. Association of Enterococcus faecalis with different forms of periradicular diseases. *J Endod* 2004;30(5):315-20.
87. Chavez De Paz LE, Dahlen G, Molander A, Moller A, Bergenholtz G. Bacteria recovered from teeth with apical periodontitis after antimicrobial endodontic treatment. *Int Endod J* 2003;36(7):500-8.
88. Mayer BE, Peters OA, Barbakow F. Effects of rotary instruments and ultrasonic irrigation on debris and smear layer scores: a scanning electron microscopic study. *Int Endod J* 2002;35(7):582-9.
89. Abou-Rass M, Piccinino MV. The effectiveness of four clinical irrigation methods on the removal of root canal debris. *Oral Surg Oral Med Oral Pathol* 1982;54(3):323-8.

90. Bystrom A, Sundqvist G. Bacteriologic evaluation of the efficacy of mechanical root canal instrumentation in endodontic therapy. *Scand J Dent Res* 1981;89(4):321-8.
91. Harrison JW. Irrigation of the root canal system. *Dent Clin North Am* 1984;28(4):797-808.
92. McDonnell G, Russell AD. Antiseptics and disinfectants: activity, action, and resistance. *Clin Microbiol Rev* 1999;12(1):147-79.
93. Barrette WC, Jr., Hannum DM, Wheeler WD, Hurst JK. General mechanism for the bacterial toxicity of hypochlorous acid: abolition of ATP production. *Biochemistry* 1989;28(23):9172-8.
94. McKenna SM, Davies KJ. The inhibition of bacterial growth by hypochlorous acid. Possible role in the bactericidal activity of phagocytes. *Biochem J* 1988;254(3):685-92.
95. Bystrom A, Sundqvist G. Bacteriologic evaluation of the effect of 0.5 percent sodium hypochlorite in endodontic therapy. *Oral Surg Oral Med Oral Pathol* 1983;55(3):307-12.
96. Hand RE, Smith ML, Harrison JW. Analysis of the effect of dilution on the necrotic tissue dissolution property of sodium hypochlorite. *J Endod* 1978;4(2):60-4.
97. Radcliffe CE, Potouridou L, Qureshi R, et al. Antimicrobial activity of varying concentrations of sodium hypochlorite on the endodontic microorganisms *Actinomyces israelii*, *A. naeslundii*, *Candida albicans* and *Enterococcus faecalis*. *Int Endod J* 2004;37(7):438-46.
98. Siqueira JF, Jr., Machado AG, Silveira RM, Lopes HP, de Uzeda M. Evaluation of the effectiveness of sodium hypochlorite used with three irrigation methods in the elimination of *Enterococcus faecalis* from the root canal, in vitro. *Int Endod J* 1997;30(4):279-82.
99. Siqueira JF, Jr., Rocas IN, Favieri A, Lima KC. Chemomechanical reduction of the bacterial population in the root canal after instrumentation and irrigation with 1%, 2.5%, and 5.25% sodium hypochlorite. *J Endod* 2000;26(6):331-4.
100. Cvek M, Nord CE, Hollender L. Antimicrobial effect of root canal debridement in teeth with immature root. A clinical and microbiologic study. *Odontol Revy* 1976;27(1):1-10.
101. Pashley EL, Birdsong NL, Bowman K, Pashley DH. Cytotoxic effects of NaOCl on vital tissue. *J Endod* 1985;11(12):525-8.
102. Grawehr M, Sener B, Waltimo T, Zehnder M. Interactions of ethylenediamine tetraacetic acid with sodium hypochlorite in aqueous solutions. *Int Endod J* 2003;36(6):411-7.

103. Greenstein G, Berman C, Jaffin R. Chlorhexidine. An adjunct to periodontal therapy. *J Periodontol* 1986;57(6):370-7.
104. Davies A. The mode of action of chlorhexidine. *J Periodontal Res Suppl* 1973;12:68-75.
105. Loe H, Schiott CR, Karring G, Karring T. Two years oral use of chlorhexidine in man. (Pt 1). General design and clinical effects. *J Periodontal Res* 1976;11(3):135-44.
106. Ercan E, Ozekinci T, Atakul F, Gul K. Antibacterial activity of 2% chlorhexidine gluconate and 5.25% sodium hypochlorite in infected root canal: in vivo study. *J Endod* 2004;30(2):84-7.
107. Ohara P, Torabinejad M, Kettering JD. Antibacterial effects of various endodontic irrigants on selected anaerobic bacteria. *Endod Dent Traumatol* 1993;9(3):95-100.
108. Komorowski R, Grad H, Wu XY, Friedman S. Antimicrobial substantivity of chlorhexidine-treated bovine root dentin. *J Endod* 2000;26(6):315-7.
109. Rosenthal S, Spangberg L, Safavi K. Chlorhexidine substantivity in root canal dentin. *Oral Surg Oral Med Oral Pathol Oral Radiol Endod* 2004;98(4):488-92.
110. Ferraz CC, Gomes BP, Zaia AA, Teixeira FB, Souza-Filho FJ. In vitro assessment of the antimicrobial action and the mechanical ability of chlorhexidine gel as an endodontic irrigant. *J Endod* 2001;27(7):452-5.
111. Vianna ME, Gomes BP, Berber VB, Zaia AA, Ferraz CC, de Souza-Filho FJ. In vitro evaluation of the antimicrobial activity of chlorhexidine and sodium hypochlorite. *Oral Surg Oral Med Oral Pathol Oral Radiol Endod* 2004;97(1):79-84.
112. Lenet BJ, Komorowski R, Wu XY, Huang J, Grad H, Lawrence HP, et al. Antimicrobial substantivity of bovine root dentin exposed to different chlorhexidine delivery vehicles. *J Endod* 2000;26(11):652-5.
113. Haapasalo HK, Siren EK, Waltimo TM, Orstavik D, Haapasalo MP. Inactivation of local root canal medicaments by dentine: an in vitro study. *Int Endod J* 2000;33(2):126-31.
114. Portenier I, Haapasalo H, Rye A, Waltimo T, Orstavik D, Haapasalo M. Inactivation of root canal medicaments by dentine, hydroxylapatite and bovine serum albumin. *Int Endod J* 2001;34(3):184-8.
115. Yamashita JC, Tanomaru Filho M, Leonardo MR, Rossi MA, Silva LA. Scanning electron microscopic study of the cleaning ability of chlorhexidine as a root-canal irrigant. *Int Endod J* 2003;36(6):391-4.

116. Okino LA, Siqueira EL, Santos M, Bombana AC, Figueiredo JA. Dissolution of pulp tissue by aqueous solution of chlorhexidine digluconate and chlorhexidine digluconate gel. *Int Endod J* 2004;37(1):38-41.
117. Zamany A, Safavi K, Spangberg LS. The effect of chlorhexidine as an endodontic disinfectant. *Oral Surg Oral Med Oral Pathol Oral Radiol Endod* 2003;96(5):578-81.
118. Kuruvilla JR, Kamath MP. Antimicrobial activity of 2.5% sodium hypochlorite and 0.2% chlorhexidine gluconate separately and combined, as endodontic irrigants. *J Endod* 1998;24(7):472-6.
119. Basrani BR, Manek S, Sodhi RN, Fillery E, Manzur A. Interaction between sodium hypochlorite and chlorhexidine gluconate. *J Endod* 2007;33(8):966-9.
120. Chhabra RS, Huff JE, Haseman JK, Elwell MR, Peters AC. Carcinogenicity of p-chloroaniline in rats and mice. *Food Chem Toxicol* 1991;29(2):119-24.
121. Stewart GG, Kapsimalas P, Rappaport H. EDTA and urea peroxide for root canal preparation. *J Am Dent Assoc* 1969;78(2):335-8.
122. Patterson SS. In vivo and in vitro studies of the effect of the disodium salt of ethylenediamine tetra-acetate on human dentine and its endodontic implications. *Oral Surg Oral Med Oral Pathol* 1963;16:83-103.
123. Orstavik D, Haapasalo M. Disinfection by endodontic irrigants and dressings of experimentally infected dentinal tubules. *Endod Dent Traumatol* 1990;6(4):142-9.
124. Niu W, Yoshioka T, Kobayashi C, Suda H. A scanning electron microscopic study of dentinal erosion by final irrigation with EDTA and NaOCl solutions. *Int Endod J* 2002;35(11):934-9.
125. Calt S, Serper A. Smear layer removal by EGTA. *J Endod* 2000;26(8):459-61.
126. Crumpton BJ, Goodell GG, McClanahan SB. Effects on smear layer and debris removal with varying volumes of 17% REDTA after rotary instrumentation. *J Endod* 2005;31(7):536-8.
127. Rasimick BJ, Nekich M, Hladek MM, Musikant BL, Deutsch AS. Interaction between chlorhexidine digluconate and EDTA. *J Endod* 2008;34(12):1521-3.
128. Heuer M. The biomechanics of endodontic therapy. *Dent Clin North Am* 1963:341.
129. Heling I, Chandler NP. Antimicrobial effect of irrigant combinations within dentinal tubules. *Int Endod J* 1998;31(1):8-14.
130. Torabinejad M, Khademi AA, Babagoli J, et al. A new solution for the removal of the smear layer. *J Endod* 2003;29(3):170-5.

131. Shabahang S, Torabinejad M. Effect of MTAD on *Enterococcus faecalis*-contaminated root canals of extracted human teeth. *J Endod* 2003;29(9):576-9.
132. Johal S, Baumgartner JC, Marshall JG. Comparison of the antimicrobial efficacy of 1.3% NaOCl/BioPure MTAD to 5.25% NaOCl/15% EDTA for root canal irrigation. *J Endod* 2007;33(1):48-51.
133. Estrela C, Pimenta FC, Ito IY, Bammann LL. In vitro determination of direct antimicrobial effect of calcium hydroxide. *J Endod* 1998;24(1):15-7.
134. Sjogren U, Figdor D, Spangberg L, Sundqvist G. The antimicrobial effect of calcium hydroxide as a short-term intracanal dressing. *Int Endod J* 1991;24(3):119-25.
135. Bystrom A, Claesson R, Sundqvist G. The antibacterial effect of camphorated paramonochlorophenol, camphorated phenol and calcium hydroxide in the treatment of infected root canals. *Endod Dent Traumatol* 1985;1(5):170-5.
136. Kvist T, Molander A, Dahlen G, Reit C. Microbiological evaluation of one- and two-visit endodontic treatment of teeth with apical periodontitis: a randomized, clinical trial. *J Endod* 2004;30(8):572-6.
137. Peters LB, van Winkelhoff AJ, Buijs JF, Wesselink PR. Effects of instrumentation, irrigation and dressing with calcium hydroxide on infection in pulpless teeth with periapical bone lesions. *Int Endod J* 2002;35(1):13-21.
138. Fava LR, Saunders WP. Calcium hydroxide pastes: classification and clinical indications. *Int Endod J* 1999;32(4):257-82.
139. Lambrianidis T, Margelos J, Beltes P. Removal efficiency of calcium hydroxide dressing from the root canal. *J Endod* 1999;25(2):85-8.
140. Sirtes G, Waltimo T, Schaetzle M, Zehnder M. The effects of temperature on sodium hypochlorite short-term stability, pulp dissolution capacity, and antimicrobial efficacy. *J Endod* 2005;31(9):669-71.
141. Cunningham WT, Balekjian AY. Effect of temperature on collagen-dissolving ability of sodium hypochlorite endodontic irrigant. *Oral Surg Oral Med Oral Pathol* 1980;49(2):175-7.
142. Cunningham WT, Joseph SW. Effect of temperature on the bactericidal action of sodium hypochlorite endodontic irrigant. *Oral Surg Oral Med Oral Pathol* 1980;50(6):569-71.
143. Raphael D, Wong TA, Moodnik R, Borden BG. The effect of temperature on the bactericidal efficiency of sodium hypochlorite. *J Endod* 1981;7(7):330-4.
144. Basrani BR, Manek S, Fillery E. Using diazotization to characterize the effect of heat or sodium hypochlorite on 2.0% chlorhexidine. *J Endod* 2009;35(9):1296-9.

145. Hockett JL, Dommisch JK, Johnson JD, Cohenca N. Antimicrobial efficacy of two irrigation techniques in tapered and nontapered canal preparations: an in vitro study. *J Endod* 2008;34(11):1374-7.
146. Gutarts R, Nusstein J, Reader A, Beck M. In vivo debridement efficacy of ultrasonic irrigation following hand-rotary instrumentation in human mandibular molars. *J Endod* 2005;31(3):166-70.
147. de Gregorio C, Estevez R, Cisneros R, Heilborn C, Cohenca N. Effect of EDTA, sonic, and ultrasonic activation on the penetration of sodium hypochlorite into simulated lateral canals: an in vitro study. *J Endod* 2009;35(6):891-5.
148. Laplace JM, Thuault M, Hartke A, Boutibonnes P, Auffray Y. Sodium hypochlorite stress in *Enterococcus faecalis*: influence of antecedent growth conditions and induced proteins. *Curr Microbiol* 1997;34(5):284-9.
149. Flahaut S, Hartke A, Giard JC, Auffray Y. Alkaline stress response in *Enterococcus faecalis*: adaptation, cross-protection, and changes in protein synthesis. *Appl Environ Microbiol* 1997;63(2):812-4.
150. Portenier I, Waltimo T, Orstavik D, Haapasalo M. The susceptibility of starved, stationary phase, and growing cells of *Enterococcus faecalis* to endodontic medicaments. *J Endod* 2005;31(5):380-6.
151. Sedgley CM, Lennan SL, Clewell DB. Prevalence, phenotype and genotype of oral enterococci. *Oral Microbiol Immunol* 2004;19(2):95-101.
152. Hubble TS, Hatton JF, Nallapareddy SR, Murray BE, Gillespie MJ. Influence of *Enterococcus faecalis* proteases and the collagen-binding protein, Ace, on adhesion to dentin. *Oral Microbiol Immunol* 2003;18(2):121-6.
153. Distel JW, Hatton JF, Gillespie MJ. Biofilm formation in medicated root canals. *J Endod* 2002;28(10):689-93.
154. Clegg MS, Vertucci FJ, Walker C, Belanger M, Britto LR. The effect of exposure to irrigant solutions on apical dentin biofilms in vitro. *J Endod* 2006;32(5):434-7.
155. Chavez de Paz LE, Bergenholtz G, Svensater G. The effects of antimicrobials on endodontic biofilm bacteria. *J Endod* 2010;36(1):70-7.
156. Peciuliene V, Reynaud AH, Balciuniene I, Haapasalo M. Isolation of yeasts and enteric bacteria in root-filled teeth with chronic apical periodontitis. *Int Endod J* 2001;34(6):429-34.
157. Gomes BP, Ferraz CC, Vianna ME, Berber VB, Teixeira FB, Souza-Filho FJ. In vitro antimicrobial activity of several concentrations of sodium hypochlorite and chlorhexidine gluconate in the elimination of *Enterococcus faecalis*. *Int Endod J* 2001;34(6):424-8.



158. Oncag O, Hosgor M, Hilmioglu S, Zekioglu O, Eronat C, Burhanoglu D. Comparison of antibacterial and toxic effects of various root canal irrigants. *Int Endod J* 2003;36(6):423-32.
159. Evans M, Davies JK, Sundqvist G, Figdor D. Mechanisms involved in the resistance of *Enterococcus faecalis* to calcium hydroxide. *Int Endod J* 2002;35(3):221-8.
160. Zerella JA, Fouad AF, Spangberg LS. Effectiveness of a calcium hydroxide and chlorhexidine digluconate mixture as disinfectant during retreatment of failed endodontic cases. *Oral Surg Oral Med Oral Pathol Oral Radiol Endod* 2005;100(6):756-61.
161. Schafer E, Bossmann K. Antimicrobial efficacy of chlorhexidine and two calcium hydroxide formulations against *Enterococcus faecalis*. *J Endod* 2005;31(1):53-6.
162. Saunders WP, Saunders EM. Coronal leakage as a cause of failure in root-canal therapy: a review. *Endod Dent Traumatol* 1994;10(3):105-8.
163. Bystrom A, Happonen RP, Sjogren U, Sundqvist G. Healing of periapical lesions of pulpless teeth after endodontic treatment with controlled asepsis. *Endod Dent Traumatol* 1987;3(2):58-63.
164. Haapasalo M, Orstavik D. In vitro infection and disinfection of dentinal tubules. *J Dent Res* 1987;66(8):1375-9.
165. Wilson M. Susceptibility of oral bacterial biofilms to antimicrobial agents. *J Med Microbiol* 1996;44(2):79-87.
166. Hancock HH, 3rd, Sigurdsson A, Trope M, Moiseiwitsch J. Bacteria isolated after unsuccessful endodontic treatment in a North American population. *Oral Surg Oral Med Oral Pathol Oral Radiol Endod* 2001;91(5):579-86.
167. Eriksson AR, Albrektsson T. Temperature threshold levels for heat-induced bone tissue injury: a vital-microscopic study in the rabbit. *J Prosthet Dent* 1983;50(1):101-7.
168. Cameron JA. The effect of ultrasonic endodontics on the temperature of the root canal wall. *J Endod* 1988;14(11):554-9.

ABSTRACT

ANTIBACTERIAL EFFICACY OF 0.12-PERCENT AND 2.0-PERCENT  
CHLORHEXIDINE GLUCONATE AT 37°C AND 46°C  
AGAINST *ENTEROCOCCUS FAECALIS*

by

Craig B.D. Thiessen

Indiana University School of Dentistry  
Indianapolis, Indiana

The purpose of this study was to investigate the antibacterial efficacy of 0.12-percent and 2.0-percent chlorhexidine gluconate (CHX) on eliminating *Enterococcus faecalis* from dentinal tubules, and whether this antibacterial effect was enhanced by heat. To date there have been no published articles that describe the heating of 2.0-percent CHX and its antimicrobial efficacy and clinical relevance towards *E. faecalis* within dentinal tubules in root canal systems.

Ninety-five human extracted, single rooted, maxillary, anterior teeth were used to prepare dentin disk specimens. After proper sterilization, a 2.5-mm ISO-sized diameter lumen was prepared, and then the canals were filled with brain-heart infusion (BHI) broth infected with *E. faecalis*. The BHI was removed and the specimens in equally divided groups were rinsed with sterile saline and filled with saline, or 0.12 percent CHX or 2.0 percent CHX at ambient temperature (24°C) or experimental temperature (46°C) and

incubated at oral temperature (37°C) or the experimental temperature (46°C), respectively. The specimens were frozen to -70°C and pulverized in liquid nitrogen. Serial dilutions were prepared of 1:100 and 1:1000 and spiral plated on BHI agar plates in duplicate. They were incubated, and the number of bacterial colonies was recorded 24 hours later for data analysis. A two-way analysis of variance (ANOVA), with factors for solution, solution temperature, and the solution-by-temperature interaction was used to determine antibacterial efficacy. Pair-wise comparisons between groups were examined for significance using the Fisher's Protected Least Significant Differences Method. The *E. faecalis* CFU were log-transformed to satisfy the assumptions required for the ANOVA.

The results of this investigation demonstrated no statistically significant difference with the addition of heat to either test irrigation solution regarding the elimination of *E. faecalis* from dentinal tubules within the root canal system. There was a statistically significant difference in the antibacterial efficacy of CHX against *E. faecalis* in comparison with the concentration tested. A higher concentration of 2.0-percent CHX demonstrated a significantly higher antibacterial efficacy against *E. faecalis* compared with 0.12-percent CHX, and likewise with the saline control. It can be concluded that the use of a higher concentration of 2.0-percent CHX is advantageous as a final irrigation solution after copious amounts of NaOCl and EDTA have been utilized for effective antimicrobial efficacy and substantivity.

## CURRICULUM VITAE

Craig B.D. Thiessen

February 17, 1978	Born in Portage, Wisconsin
August 1996 to May 2000	BS, St. Cloud State University Saint Cloud, Minnesota
June 2000 to June 2001	Wausau Hospital Catherization Laboratory Technician Wausau, Wisconsin
July 2001 to May 2005	DDS, Indiana University School of Dentistry, Indianapolis, Indiana
June 2005 to June 2008	General Dentistry – Private Practice Wausau, Wisconsin
July 2008 to June 2010	MSD Program, Endodontics, Indiana University School of Dentistry Indianapolis, Indiana

Professional Organizations

American Dental Association  
Wisconsin Dental Association  
American Association of Endodontists