

HOSTED BY




ELSEVIER

Available online at www.sciencedirect.com

ScienceDirect

journal homepage: <http://www.elsevier.com/locate/ijpam>



CASE REPORT

Hair tourniquet syndrome: Successful management with a painless technique



N. Alruwaili ^{a,b,*}, Hassan A. Alshehri ^c, Bachar Halimeh ^b

^a Emergency Department, King Faisal Specialist Hospital and Research Centre, Riyadh, Saudi Arabia

^b College of Medicine, Alfaisal University, Riyadh, Saudi Arabia

^c College of Medicine, Al-Imam University, Riyadh, Saudi Arabia

Received 3 December 2014; received in revised form 14 February 2015; accepted 19 February 2015

Available online 20 March 2015

KEYWORDS

Hair tourniquet syndrome;
Management of hair tourniquet syndrome;
Hair tourniquet removal

Abstract Hair tourniquet syndrome is a clinical phenomenon that involves hair or thread becoming so tightly wrapped around an appendage that pain, swelling and occasionally ischemia result. We report two cases of hair tourniquet syndrome that affected the digits and were treated with hair removal cream, which was an easy, effective and less invasive treatment method compared with standard managements such as incision or blunt probe cutting techniques.

Copyright © 2015, King Faisal Specialist Hospital & Research Centre (General Organization), Saudi Arabia. Production and hosting by Elsevier B.V. This is an open access article under the CC BY-NC-ND license (<http://creativecommons.org/licenses/by-nc-nd/4.0/>).

1. Introduction

The clinical entity known as hair tourniquet syndrome was described long ago and occurs when a piece of hair or thread is tightly wrapped around an appendage, such as the digits or genitalia [1,2]. This clinical scenario typically arises in the pediatric patient population [3,4]. The majority of cases involve infants that present early to the emergency department or primary health care center and exhibit a

good response after releasing the tourniquet [5]. Delays in presentation, diagnosis or management can lead to serious complications [6,7].

2. Case 1

A six-month-old boy presented to his local emergency department (ER) with a history of excessive crying for the past two days. This crying was not associated with any fever, decrease in activity, poor feeding or any other symptoms. There was no previous history of medical problems.

On examination, the boy appeared well and was vitally stable with no signs of toxicity or lethargy. Examination of the right foot revealed that the middle phalanx of the middle toe had a groove with mild swelling and edema

* Corresponding author. Emergency Department, King Faisal Specialist Hospital and Research Centre, Riyadh, Saudi Arabia. Tel.: +966 11442445.

Peer review under responsibility of King Faisal Specialist Hospital & Research Centre (General Organization), Saudi Arabia.

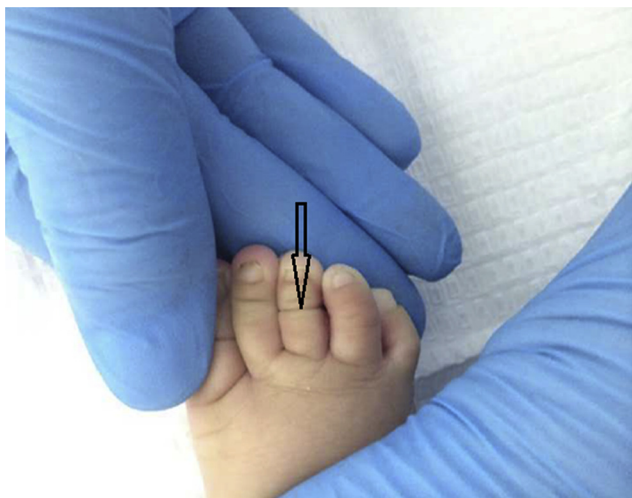


Figure 1 The constriction band causing mild swelling of the right middle toe due to a hair tourniquet (arrow).

(Fig. 1). The skin perfusion of the toe was normal at less than three seconds. There were no signs of erythema or abnormal discoloration that suggested ischemic changes. Examination of the other toes and the penis revealed no swelling or erythema. The other physical findings were unremarkable. Although no hair was observed during direct visualization of swelled toe, the cause of the pathology was suspected to be secondary to hair tourniquet syndrome. Therefore, a small amount of a depilatory agent (Nair) was applied over the region in which the hair tourniquet syndrome was suspected to be. The boy was then re-evaluated after ten minutes; on this evaluation, the normal appearance of the toe was restored (Fig. 2). Moreover, a tiny brown hair was observed in the side of the groove.

After washing the toe, the infant was discharged in an improved and stable condition. A follow-up call with the

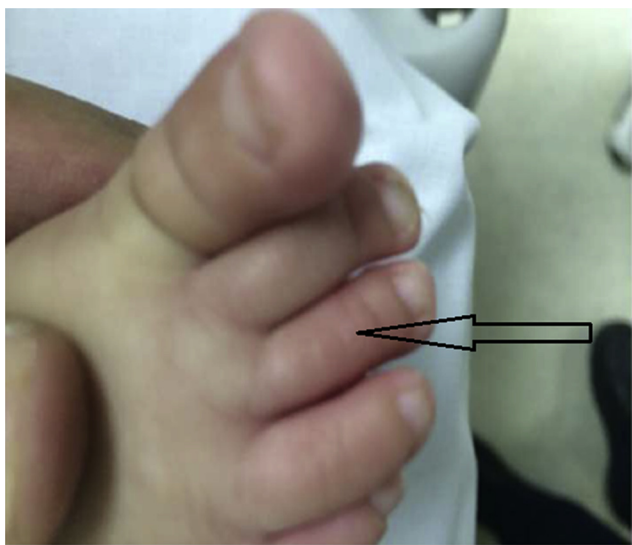


Figure 2 Normal appearance of the toe ten minutes after the removal of the hair tourniquet (arrow).

family revealed that the boy was doing significantly better and that his crying had significantly improved.

3. Case 2

A healthy 15-day-old baby boy was brought to the emergency department with a 5-h history of excessive crying, redness and swelling of the left ring finger. The parents denied any history of trauma to the affected site. His feeding and level of activity were optimal. He was afebrile with normal vital signs but appeared to be in pain and cried continuously. A local examination of the hand revealed a red, swollen and tender left ring finger with a circumferential groove in the area of the middle phalanx of the finger (Fig. 3). The capillary refill of the affected finger was normal at less than 3 seconds. The diagnosis of hair tourniquet was suspected, and on closer examination, a hair was observed at the base of the groove. We applied hair removal cream (the active ingredients of which were calcium hydroxide and sodium hydroxide) to the base of the groove for 10 min followed by subsequent rubbing and washing with warm water. Immediately after this treatment, the hair was removed, the swelling decreased dramatically, and the finger became less tender. The patient went home, and the parents were instructed to apply a triple-antibiotic ointment to the affected site. Outpatient follow-up 1 week later was recommended, but the patient did not show up for the appointment. The parents were contacted by phone, and they informed the hospital that the swelling has resolved and that the finger had become totally normal.

4. Discussion

Hair tourniquet syndrome is an uncommon acquired pediatric emergency that was recognized long ago. If not treated immediately, this condition can lead to serious complications, such as limb ischemia, amputation or bone erosion [6–8]. This syndrome commonly affects the fingers, toes, and penis [9,10] but might also affect other body parts, such as the clitoris, labia, ear lobes, umbilicus, nipple, tongue or uvula [6,11–15]. When a patient presents

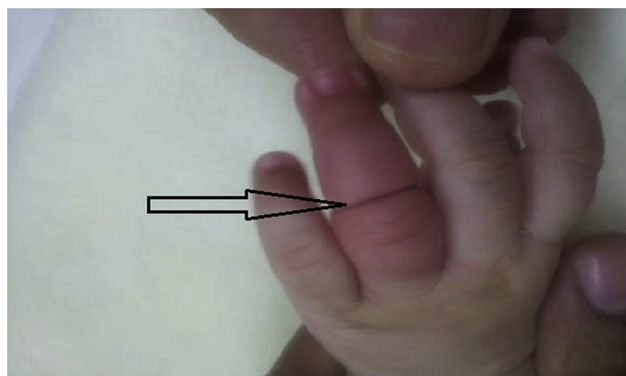

Figure 3 The circumferential groove in the area of the middle phalanx of the left ring finger causing redness and swelling due to a hair tourniquet (arrow).

with a local reaction or swelling, hair is commonly overlooked because it is very thin, which makes it difficult to identify. When wet, hair stretches out, and when dry, it constricts back to its normal size. Thus, if a hair is tightly wrapped around a toe or finger when wet, it can cause strangulation of the appendage when it dries [16].

The majority of cases occur in infants and young children with a median age of five months [4]. The median ages for finger, toe and external genitalia involvement have been found to be three weeks, four months and two years, respectively [3].

One of the predisposing factors is telogen effluvium; during the postpartum period, 90% mothers exhibit excessive hair loss secondary to hormonal changes that subsequently exposes their infants to the risk of hair tourniquet syndrome [17]. Although this condition is primarily the result of accidental injury, some cases have been reported to be caused by child abuse [3,18]. This condition can mimic other conditions, such as trauma, infection, congenital bands, insect bites and allergic reactions. The strangulation of tissue by hair or thread leads to obstructions of lymphatic drainage and venous return that subsequently result in swelling and edema of the affected body part. This condition can also lead to nerve injury and the impairment of arterial flow to the tissue, which can lead to tissue ischemia [19]. The diagnosis of such cases is challenging, particularly when the strangulating hair or thread had made a deep cut and is deeply embedded in the tissue or covered by skin epithelialization [7]. The most serious complications are found in cases in which the strangulation involves the genitalia; such cases can result in gangrene of the penis or urethral fistulas [3]. Presentation to the emergency room typically occurs early in the course of this syndrome. This syndrome typically presents with a history of excessive crying or discomfort over a few days along with mechanical signs of strangulation that include erythema, edema, and swelling of the affected appendage. Occasionally, the presentation can be delayed for years after the exposure. Hair tourniquet syndrome is a preventable and treatable condition when diagnosed early and managed appropriately.

The treatment of this condition primarily consists of decompression and complete release of the constrictors as early as possible after diagnosis. Many techniques have been described to remove the constrictors, but unfortunately, if significant edema or swelling is present, the process of release can be quite difficult. The choice of the technique primarily depends on how deep the constrictors are embedded into the body tissue. Surgical incision with exploration of the area and suitable anesthetic agents is the technique of choice for deeply imbedded constrictors. The incision should be made longitudinally with the blade placed perpendicularly to the skin at a 3-o'clock, 9-o'clock or 12-o'clock position on the digit. The incision should progress from proximal to distal, and its depth should reach the bone to ensure the complete release of the constrictor [2,3]. If minimal edema is present, and the thread can be observed, less invasive approaches can be attempted. For example, the unwinding of the thread or direct cutting of the thread with the aid of a blunt probe that is introduced between the skin and the constrictor to protect the skin and the body tissue during the direct cutting of constrictor using a pair of

scissors or a blade can be employed [6,7,11]. The use of a depilatory agent with a thioglycolate base can break constrictors composed of hair but not thread. This is one of the most effective and painless methods for non-deep hair tourniquets; however, this method should be avoided in cases involving broken skin. This technique involves the application of a small amount of the depilatory agent to the hair followed by a wait of approximately 3–10 min for the hair to break and release of the constriction. Subsequently, the area should be washed thoroughly. Following a reviewing of the literature regarding the use of depilatory agents for the treatment hair tourniquet syndrome, we found only one case report describing the use of technique in which O'Gorman et al described one baby with hair tourniquet syndrome who was successfully treated with a depilatory agent [20]. We reported these cases to encourage the use of this safe, painless and non-invasive method when allowed for by the conditions of the patient allows. Allergic reactions to depilatory creams and broken skin are relative contraindications for this technique and might be indications for the selection of different approaches.

5. Conclusions

Hair tourniquet syndrome should be considered in the differential diagnosis of swollen appendages. Depilatory agents should be utilized to release non-deep tourniquets because this procedure is painless and effective. Allergic reactions to depilatory creams and non-intact skin are relative contraindications for the use of this technique.

Ethical considerations

Written consent was obtained from the parents for the publication of these two cases and for the use of the accompanying pictures. This report was revised and approved for publication by the office of research affairs of the King Faisal Specialist Hospital and Research Centre, Riyadh, Saudi Arabia.

Conflict of Interest

None of the authors have any conflicts of interest associated with this manuscript.

Authors and co-authors agreement

We state that this manuscript has been approved by all authors for publication in the *International Journal of Pediatrics and Adolescent Medicine* and that the copyright should be transferred to the *International Journal of Pediatrics and Adolescent Medicine* if the manuscript is accepted.

References

- [1] Sivathanan N, Vijayarajan L. Hair-thread tourniquet syndrome: a case report and literature review. *Case Rep Med* 2012;171368.

- [2] Bacon JL, Burgis JT. Hair thread tourniquet syndrome in adolescents: a presentation and review of the literature. *J Pediatr Adolesc Gynecol* 2005;18(3):155–6.
- [3] Barton DJ, Sloan GM, Nichter LS, Reinisch JF. Hair-thread tourniquet syndrome. *Pediatrics* 1988;82:925–8.
- [4] Claudet I, Pasion N, Mařmchal C, Salanne S, Debusson C, Grouteau E. Hair-thread tourniquet syndrome. *Arch Pediatr* 2010;17:474–9.
- [5] Vázquez Rueda F, Núñez Núñez R, Gómez Meleno P, Blesa Sánchez E. The hair-thread tourniquet syndrome of the toes and penis. *An Esp Pediatr* 1996;44:17–20.
- [6] Mat Saad AZ, Purcell EM, McCann JJ. Hair-thread tourniquet syndrome in an infant with bony erosion: a case report, literature review, and metaanalysis. *Ann Plast Surg* 2006;57(4):447–52.
- [7] Garcia-Mata S, Hidalgo-Ovejero A. Hair tourniquet syndrome of the toe: report of 2 new cases. *J Pediatr Orthop* 2009;29(8):860–4.
- [8] Nicola Bizzotto, Andrea Sandri, Dario Regis, Guilherme Carpeggiani, Franco Lavini, Bruno Magnan. Serious delayed hair toe tourniquet syndrome with bone erosion and flexor tendon lesion. *Case Rep Pediatr* 2014:592323.
- [9] Golshevsky J, Chuen J, Tung PH. Hair-thread tourniquet syndrome. *J Paediatr Child Health* 2005;41(3):154–5.
- [10] Lohana P, Vashishta GN, Price N. Toe-tourniquet syndrome: a diagnostic dilemma! *Ann R Coll Surg Engl* 2006;88(4):W6-8.
- [11] Peckler B, Hsu CK. Tourniquet syndrome: a review of constricting band removal. *J Emerg Med* 2001;20(3):253–62.
- [12] Schneider K, Kennebeck S, Madden L, Campbell A. Hair tourniquet of the circumvallate papillae: a potentially “hairy” situation. *Pediatr Emerg Care* 2013;29(8):924–5.
- [13] Hickey BA, Gulati S, Maripuri SN. Hair toe tourniquet syndrome in a four-year-old boy. *J Emerg Med* 2013;44(2):39–58.
- [14] Dua A, Jamshidi R, Lal DR. Labial hair tourniquet: unusual complication of an unrepaired genital laceration. *Pediatr Emerg Care* 2013;29(7):829–30.
- [15] Alverson B. A genital hair tourniquet in a 9-year-old girl. *Pediatr Emerg Care* 2007;23(3):169–70.
- [16] Summers JL, Guira AC. Hair strangulation of the external genitalia: report of two cases. *Ohio State Med J* 1973;69(9):672–3.
- [17] Strahlman RS. Toe tourniquet syndrome in association with maternal hair loss. *Pediatrics* 2003;111(3):685–7.
- [18] Johnson CF. Constricting bands. Manifestations of possible child abuse. Case reports and a review. *Clin Pediatr (Phila)* 1988;27(9):439–44.
- [19] Kuo JH, Smith LM, Berkowitz CD. A hair tourniquet resulting in strangulation and amputation of the clitoris. *Obstet Gynecol* 2002;99(5 Pt 2):939–41.
- [20] O’Gorman A, Ratnapalan S. Hair tourniquet management. *Pediatr Emerg Care* 2011;27(3):203–4.