



1-1-2011

The role of parathyroid hormone in bone healing.

Padhraig F. O'Loughlin
Royal College of Surgeons in Ireland

Citation

O'Loughlin PF. The role of parathyroid hormone in bone healing [MD Thesis]. Dublin: Royal College of Surgeons in Ireland; 2011.

This Thesis is brought to you for free and open access by the Theses and Dissertations at e-publications@RCSI. It has been accepted for inclusion in MD theses by an authorized administrator of e-publications@RCSI. For more information, please contact epubs@rcsi.ie.



— Use Licence —

Creative Commons Licence:



This work is licensed under a [Creative Commons Attribution-Noncommercial-Share Alike 3.0 License](https://creativecommons.org/licenses/by-nc-sa/3.0/).



RCSI

ROYAL COLLEGE OF SURGEONS IN IRELAND
COLÁISTE RÍOGA NA MÁINLEÁ IN ÉIRINN



The Role of Parathyroid Hormone in Bone Healing

A Thesis Submitted to the Royal College of Surgeons in Ireland (RCSI)
for the Degree of Doctor of Medicine, M.D.

By

Padhraig F. O'Loughlin, BCh MB BAO MRCS

Department of Trauma and Orthopaedic Surgery
Royal College of Surgeons in Ireland (RCSI)

Research Supervisor:

Professor John M. O'Byrne, MCh, FRCSI, FRCS (Tr. & Ortho.), FFSEM, FFSEM(UK)
Abraham Colles Professor for Trauma & Orthopaedic Surgery

Department of Orthopaedic Surgery, Royal College of Surgeons in Ireland,
At Cappagh National Orthopaedic Hospital, Finglas, Dublin 11.

I declare that this thesis, which I submit to RCSI for examination in consideration of the award of a Degree of Doctor of Medicine (M.D.) is my own personal effort. Where any of the content presented is the result of input or data from a related collaborative research programme this is duly acknowledged in the text such that it is possible to ascertain how much of the work is my own. I have not already obtained a degree in RCSI or elsewhere on the basis of this work. Furthermore, I took reasonable care to ensure that the work is original, and, to the best of my knowledge, does not breach copyright law, and has not been taken from other sources except where such work has been cited and acknowledged within the text.

Signed _____

RCSI Student Number _____

Date _____

Contents

I. Selection and Development of Preclinical Models in Fracture Healing Research

Abstract

Introduction

Choosing an Animal Fracture Model

 Factors Affecting Fracture Healing

The Experimental Animal

 Rodents and Smaller Animals

 Higher Order Animals

The Experimental Fracture

Closed vs. Open.

 Fixation.

Gap.

Gene Therapy.

Summary

II. Osteotomy healing following Alendronate or Recombinant Human Parathyroid Hormone (rhPTH 1-34) in an osteoporotic rat model with and without pre-treatment with Alendronate

Introduction

Materials and Methods

 Surgery

 Veterinary Care

 Study Groups Post-Surgery

Radiographic evaluation

Micro Computed tomography (μCT)

Biomechanical testing

Histological Analysis

Paraffin embedded samples

Methacrylate embedding for calcified samples

Bone Formation Rate

Statistical analysis

Micro CT

Mechanical Testing

Results

Union rate

Abnormal callus formation

Biomechanical Testing

Micro CT

Histomorphology

TRAP Staining

Discussion

Bibliography

III. PTH (1-34) Augments Spinal Fusion, Fusion Mass Volume and Fusion Mass Quality in a Rabbit Spinal Fusion Model

Abstract

Mini Abstract/Précis

Introduction

Materials and Methods

Arthrodesis in Rabbits

Manual Palpation

Radiographic Analysis

Fusion mass volumetric analysis (CT)

Histologic Techniques

Statistical Methods

Results

Fusion Quantification: Manual Palpation and Faxitron

Assessments

Bone Production Quantification: Fusion Mass Volumetric

Analysis by CT

Bone Quality Assessment: Histomorphometric and Histological

Analysis

Discussion

Figure Legends

References

I. Selection and Development of Preclinical Models in Fracture Healing Research

Abstract

Animal fracture models have been extensively applied to pre-clinical research as a platform to identify and characterize normal and abnormal physiological processes and develop specific maneuvers that alter the biology and biomechanics being examined. The choice of animal model employed in a study bears a direct relationship to the specific intervention being analyzed. The animal models employed should be described clearly, control group data should be established and reproducibility should be defined from experiment to experiment and from institution to institution so that quantitative and qualitative outcomes can be reliably compared and contrasted to other related studies.

Introduction

Animal fracture models have been extensively applied to pre-clinical research as a platform to identify and characterize normal and abnormal physiological processes and develop specific maneuvers that alter the biology and biomechanics being examined. By facilitating the translation of in-vitro discovery into in-vivo testing, animal fracture models allow researchers to establish strategies to further understand the physiology of bone healing and to improve the rate, speed and quality of fracture healing.

The choice of animal model employed in a study bears a direct relationship to the specific intervention being analyzed. Thus, to allow accurate and reliable interpretation of pre-clinical animal studies, it is important that animal fracture models are well characterized. Animal models employed should be described clearly, control group data should be established, and reproducibility should be defined from experiment to experiment and from institution to institution so that quantitative and qualitative outcomes can be reliably compared and contrasted to other related studies.

The typical progression of animal experimentation, depending on the nature of the study, is an evolution from small animals (mice, rats, rabbits) to higher phylogenetic species (dog, sheep, pigs, goats) in an effort to mimic the human conditions as closely as possible. This path typically culminates in nonhuman primates and ultimately clinical studies.

The aim of this review is to discuss the different types of animal models used in fracture healing research in an attempt to characterize them in terms of their applicability for particular methods of analysis and provide guidance for animal model selection. To do so, the authors have reviewed all of the articles over the past ten years in a number of prominent orthopedic and musculoskeletal journals (Bone, Clinical Orthopedics and Related Research, The Journal of Bone and Mineral Research, The Journal of Bone and Joint Surgery (Am), The Journal of Orthopedic Research and The Journal of Orthopedic Trauma) and have identified 291 studies utilizing animal fracture models. The following review article describes and discusses the animal model data employed in these 291 studies. Reference details for these articles can be found in a supplementary reference list and corresponding table which guides the reader towards various types of animal fracture studies.

The Experimental Animal

Each animal model is best suited to answer a particular question. No predictable correction exists for size, weight or surface area across different species. A much larger BMP-2 dose was necessary in monkeys than would be suggested by merely correcting established canine dosages for surface area and weight.(11) Due to the species-specific and unpredictable nature of dosage, dose-finding studies may need to be performed directly in humans after animal research. In attempts to emulate human conditions, research commonly progresses incrementally from smaller to larger animals.

Bone-healing rate and speed varies between animals.(3-5, 12, 13) In the rat, normal fracture healing takes 4-5 weeks and is accomplished almost exclusively by the external periosteal callus with minimal medullary callus involvement.(14) Rabbits, dogs, and non-human primates heal with greater involvement of the medullary callus and thus take longer.

Age affects fracture repair rate and biology. Meyer et al. have studied the genetic changes with aging as they pertain to fracture healing extensively and have found that the delayed fracture healing in old rats is associated with reduced mRNA expression of genes forming the mitochondrial energy pathways.(15) Many other specific pathways are affected with age. This is an area of intense investigation.

In the initial design of any animal fracture model study appropriate power studies are imperative. With animal studies, hesitancy to calculate the appropriate number is common. Consequently, inadequate sample size leads to trends rather than true observations. In adjuvant testing, which can be directed at modes of administration, single doses, multiple dosing, delayed dosing, local versus systemic, duration, the carrier may be as critical as the material being tested.

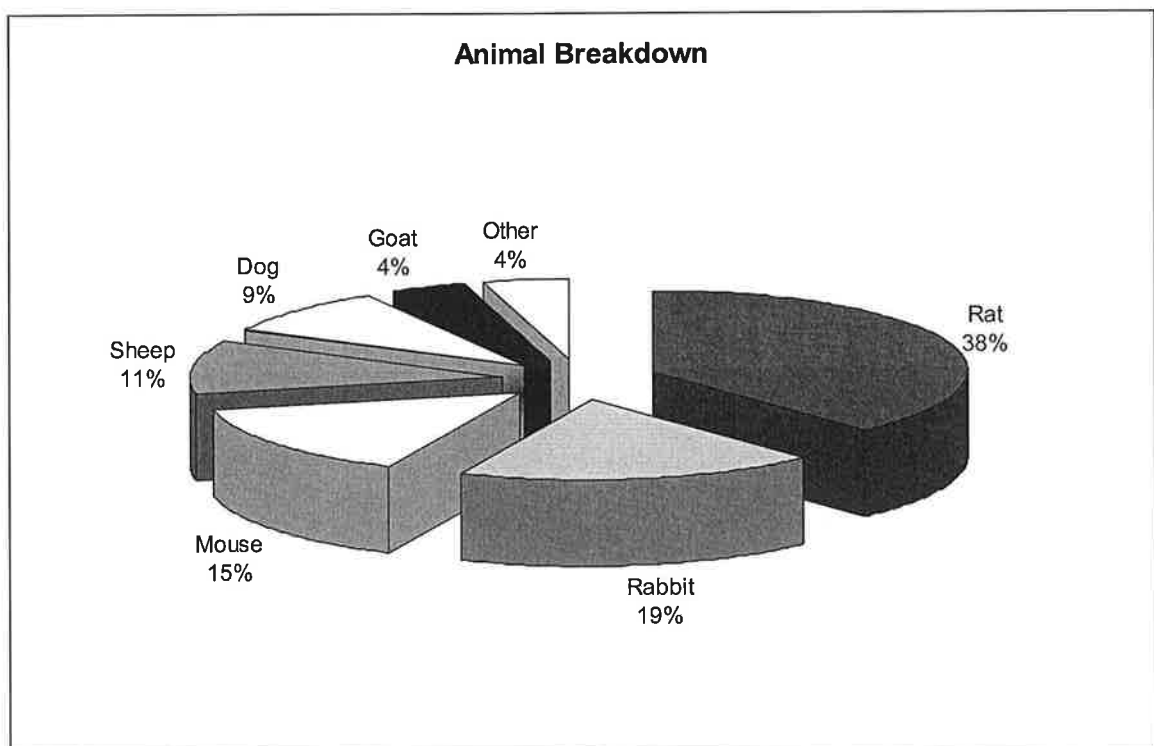


Figure 1. The use of various animal models in fracture healing

Rodents and Smaller Animals

Small rodent models, such as mice and rats, allow manipulation of molecular biology, incorporation of a greater number of animals and potentially quicker

healing rates. Furthermore, mice permit specific and conditional knockout studies. Athymic mice and rats can accept human cells, factors and tissues. Inbred mice and rats are preferred in non-time constrained tissue maneuvers. Mouse and rat calvarial defects have been utilized extensively for bone healing and are well-suited for specialized observation, for example, bone windows, continuous monitoring and tissue sampling.(16-24) Rodent critical sized defect models, currently a popular theme, allow experimentation with growth factors, local drugs and small peptides. The principal limitation with this model is the resultant membranous repair, which correlates poorly with the endochondral healing process. In the metaphysis and diaphysis, critical size defects will not heal. They are often unloaded and weakly correlate to fracture repair. They can be evaluated by radiography, micro-CT, histology, and various biomechanical tests. They have been used to test biologics (growth factors, small peptides), synthetics (allografts, ceramics) and osteogenic factors. One critical sized defect model, which has been used in studies such as the evaluation of BMP-2,(25) involves a 5mm defect in the rat femur stabilized by two pins proximally and distally through a polyethylene plate, which will not obscure radiographs.

Rodents can be manipulated and various diseases can be engineered to create challenges to bone healing. Examples include chemically-induced oophorectomy (produces osteoporosis within three months), chemically-

induced diabetes, nicotine exposure, smoking, chemotherapy, COX-2 inhibiting medication, knockout-animals and osteomyelitis.

Mouse. Murine models were used in 14% of the reviewed studies. Mice allow for the most sophisticated genetic manipulation, such as specific and conditional knockout studies. Nude mice are ideal when an immunologic response to implanted graft material is a concern. Its small size, however, makes surgical procedures more challenging and renders assessment of fixation mode and implant assessment impractical.

Rat. Of the reviewed studies, 38 % used a rat as their animal model making it the most commonly used animal. Athymic rats allow for implant studies.

Rabbit. The Lapine model was used in 19% of the reviewed articles. The New Zealand White Rabbit is the most commonly used rabbit model in fracture healing studies. Rabbits have been used in many biomechanical and cartilage studies, given their larger joints compared to rodents. Most lapine fracture studies utilized an open fracture model.

Higher Order Animals

Higher order mammals and non-human primates mimic the human more effectively than rodents, especially in terms of fixation methods and biomechanics. The relatively larger size facilitates easier surgery and biomechanical analysis. They have answered mechanical, osteoconductive and osteoinductive questions. They are used for confirmation of human dose

determination, but not as a screening tool. Biomechanical testing was far more common among larger animals than in smaller animals.

Dog. Canine models were used in 9% of the reviewed studies. Depending on the breed of dog used, they are easy to handle. Their use can vary worldwide depending on the societal acceptance of their role in research. Open fractures were generated in the majority of canine fracture studies. Depending on the breed of dog used, they are easy to handle. Of note, their use is often limited by lack of societal acceptance of their place in research.

Sheep and Goat. Ovine and Caprine models were used in 11% and 4% of the studies respectively. In the case of the ovine model, all were used in open fracture studies. A disadvantage may be higher cost compared to smaller animal models.

Of note, given that both of these animals are ruminants, there are special considerations to bear in mind when handling and with regard to housing given their size. Special attention should also be paid to anesthesia and positioning in ventral recumbency. Regurgitation of ruminal contents while under general anesthesia (regardless of positioning) should be avoided. Withholding all solid food for a minimum of 24 hours is necessary in all small ruminant anesthesia.

The Experimental Fracture

Closed vs. Open. Closed injury has less iatrogenic alteration and comminution. Einhorn et al. developed a guillotine-induced closed tissue model which makes endochondral ossification quite reproducible and which has been widely used in the rat femur and subsequently downsized to the mouse.(26) This model has been rigorously defined and characterized broadly in histology, biomechanics, radiology, and molecular patterns. Open fracture with an osteotomy causes local tissue damage with periosteal stimulation. It forms a bone within a bone, is not consistently reproducible, has a much lower rate of success in union, and provides a greater delta for augmentation of fracture healing.

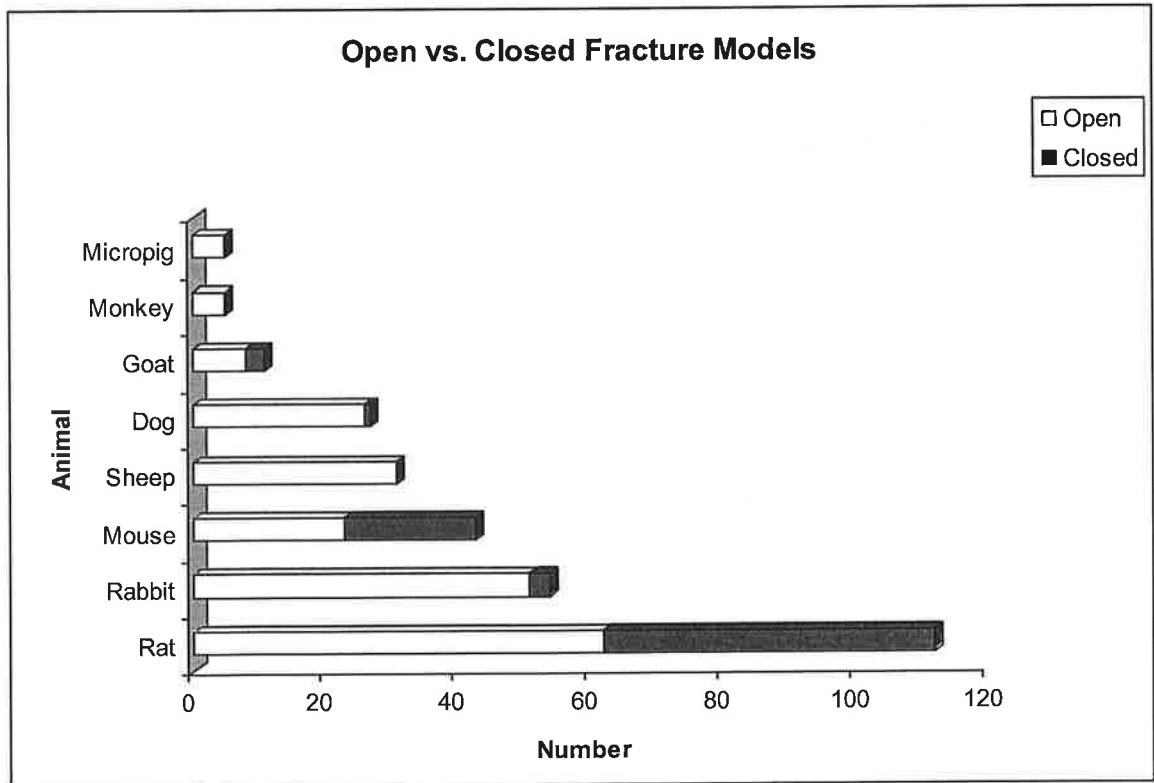


Figure 2. Closed vs. open fractures utilized in various animal models

Fixation. The mode of fracture fixation affects the repair process. Intramedullary fixation includes a pin (rigid or flexible), nail, wire or plate. Fixation can be metal or polyethylene. A fixator can cause distraction or variable stability. Fixation is not necessary in radial or ulnar defects. These have been extensively used and each one has a different mechanical environment providing either an excellent or a deleterious environment for repair.

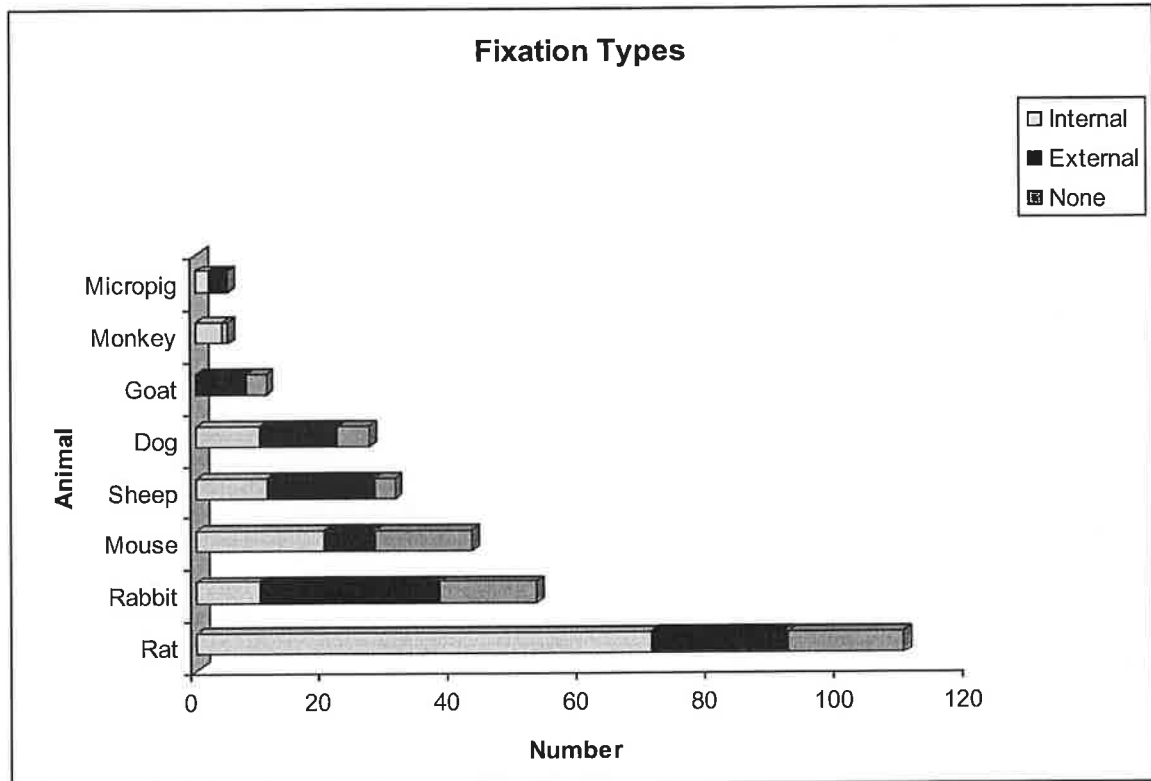


Figure 3. Fixation types as used in various animal models

Gap. A gap delays healing, and is desired for testing adjuvants. In the absence of a gap, with adequate contact and apposition, the fracture heals too rapidly to assess the influence of factors.

Gene Therapy. Gene therapy has recently entered the arena of fracture healing and studies involving in-vivo versus ex-vivo mode of transfection, duration, and the gene markers have evolved as testing modalities. These methods have often been used in defect models, but they require a carrier for presentation.

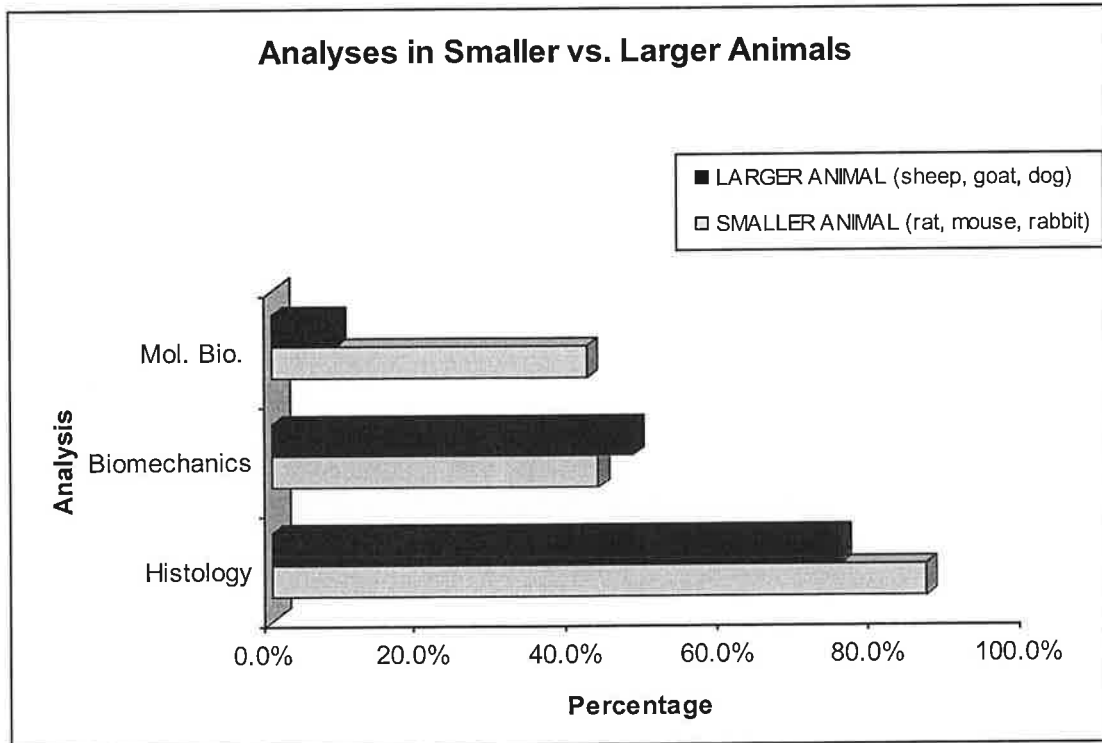


Figure 4. Modes of analysis

Summary

Preclinical fracture healing models play a very important role in understanding the physiology of bone healing and provide an efficient and effective means to assess various factors and their effects on the normal healing process. It is clear that there is a pattern of animal selection corresponding to the question being posed. The mouse is increasingly being used in studies involving genetic manipulations. The rat model is both effective and robust. Rabbits and the larger animals such as dogs and sheep, allow for more feasible biomechanical studies. With the progression to higher phylogenetic species, the primate offers the last step before a clinical trial.

In the current era of advanced pre-clinical research into fracture healing, there is a large array of sophisticated animal models available. By choosing an established model that has been well characterized in the literature, one can focus on the specific biological question being studied. Alternatively, one can attempt to develop a new, more specific animal model. However, this will require extensive characterization and testing prior to its application to the question at hand. Whether established or novel, the ability of the animal model selected to reliably and accurately represent the biological process being studied is paramount to the integrity of the study.

References

1. Sevitt A. Bone Repair and Fracture Healing in Man. 1981:35-51,64-107.
2. Rhinelander FW, Phillips RS, Steel WM, Beer JC. Microangiography in bone healing. II. Displaced closed fractures. J Bone Joint Surg Am 1968 Jun;50(4):643,62 passim.
3. Bostrom MP, Lane JM, Berberian WS, Missri AA, Tomin E, Weiland A, et al. Immunolocalization and expression of bone morphogenetic proteins 2 and 4 in fracture healing. J Orthop Res 1995 May;13(3):357-67.
4. Chakkalakal DA, Strates BS, Mashoof AA, Garvin KL, Novak JR, Fritz ED, et al. Repair of segmental bone defects in the rat: an experimental model of human fracture healing. Bone 1999 Sep;25(3):321-32.
5. Kawaguchi H, Kurokawa T, Hanada K, Hiyama Y, Tamura M, Ogata E, et al. Stimulation of fracture repair by recombinant human basic fibroblast growth factor in normal and streptozotocin-diabetic rats. Endocrinology 1994 Aug;135(2):774-81.
6. Bostrom K, Watson KE, Horn S, Wortham C, Herman IM, Demer LL. Bone morphogenetic protein expression in human atherosclerotic lesions. J Clin Invest 1993 Apr;91(4):1800-9.
7. Brighton CT, Krebs AG. Oxygen tension of nonunion of fractured femurs in the rabbit. Surg Gynecol Obstet 1972 Sep;135(3):379-85.

8. Brighton CT, Heppenstall RB. Oxygen tension in zones of the epiphyseal plate, the metaphysis and diaphysis. An in vitro and in vivo study in rats and rabbits. *J Bone Joint Surg Am* 1971 Jun;53(4):719-28.
9. Brighton CT, Krebs AG. Oxygen tension of healing fractures in the rabbit. *J Bone Joint Surg Am* 1972 Mar;54(2):323-32.
10. McKibbin B. The biology of fracture healing in long bones. *J Bone Joint Surg Br* 1978 May;60-B(2):150-62.
11. Martin GJ,Jr, Boden SD, Marone MA, Marone MA, Moskovitz PA. Posterolateral intertransverse process spinal arthrodesis with rhBMP-2 in a nonhuman primate: important lessons learned regarding dose, carrier, and safety. *J Spinal Disord* 13. 1999 Jun;12(3):179-86.
12. Nakamura T, Hara Y, Tagawa M, Tamura M, Yuge T, Fukuda H, et al. Recombinant human basic fibroblast growth factor accelerates fracture healing by enhancing callus remodeling in experimental dog tibial fracture. *J Bone Miner Res* 1998 Jun;13(6):942-9.
13. Shirley D, Marsh D, Jordan G, McQuaid S, Li G. Systemic recruitment of osteoblastic cells in fracture healing. *J Orthop Res* 2005 Sep;23(5):1013-21.
14. WRAY JB, LYNCH CJ. The vascular response to fracture of the tibia in the rat. *J Bone Joint Surg Am* 1959 Sep;41-A:1143-8.

15. Meyer MH, Meyer RA, Jr. Genes with greater up-regulation in the fracture callus of older rats with delayed healing. *J Orthop Res* 2007 Apr;25(4):488-94.
16. Aalami OO, Nacamuli RP, Lenton KA, Cowan CM, Fang TD, Fong KD, et al. Applications of a mouse model of calvarial healing: differences in regenerative abilities of juveniles and adults. *Plast Reconstr Surg* 2004 Sep 1;114(3):713-20.
17. Bosch C, Melsen B, Vargervik K. Importance of the critical-size bone defect in testing bone-regenerating materials. *J Craniofac Surg* 1998 Jul;9(4):310-6.
18. Zhang X, Kuroda S, Carpenter D, Nishimura I, Soo C, Moats R, et al. Craniosynostosis in transgenic mice overexpressing *Nell-1*. *J Clin Invest* 2002 Sep;110(6):861-70.
19. Schmitz JP, Hollinger JO. The critical size defect as an experimental model for craniomandibulofacial nonunions. *Clin Orthop Relat Res* 1986 Apr;(205)(205):299-308.
20. Schmitz JP, Schwartz Z, Hollinger JO, Boyan BD. Characterization of rat calvarial nonunion defects. *Acta Anat (Basel)* 1990;138(3):185-92.
21. Perlyn CA, Morriss-Kay G, Darvann T, Tenenbaum M, Ornitz DM. A model for the pharmacological treatment of crouzon syndrome. *Neurosurgery* 2006 Jul;59(1):210,5; discussion 210-5.

22. Kanou M, Ueno T, Kagawa T, Fujii T, Sakata Y, Ishida N, et al. Osteogenic potential of primed periosteum graft in the rat calvarial model. *Ann Plast Surg* 2005 Jan;54(1):71-8.
23. Hyun SJ, Han DK, Choi SH, Chai JK, Cho KS, Kim CK, et al. Effect of recombinant human bone morphogenetic protein-2, -4, and -7 on bone formation in rat calvarial defects. *J Periodontol* 2005 Oct;76(10):1667-74.
24. Develioglu H, Saraydin SU, Bolayir G, Dupoirieux L. Assessment of the effect of a biphasic ceramic on bone response in a rat calvarial defect model. *J Biomed Mater Res A* 2006 Jun 1;77(3):627-31.
25. Lane JM, Yasko AW, Tomin E, Cole BJ, Waller S, Browne M, et al. Bone marrow and recombinant human bone morphogenetic protein-2 in osseous repair. *Clin Orthop Relat Res* 1999 Apr;(361)(361):216-27.
26. Bonnarens F, Einhorn TA. Production of a standard closed fracture in laboratory animal bone. *J Orthop Res* 1984;2(1):97-101.

II. Osteotomy healing following Alendronate or Recombinant Human Parathyroid Hormone (rhPTH 1-34) in an osteoporotic rat model with and without pre-treatment with Alendronate

Introduction

Each year, over ten million people are diagnosed with osteoporosis and another 18 million with osteopenia in the United States,(1) Forty percent of women over the age of 50 years will sustain an osteoporosis-related fragility fracture during their lifetime.(2) Consequently, there has been a concerted effort by the medical community to increase diagnostic and therapeutic awareness of osteoporosis.(24) This has resulted in an increased level of screening and consequently treatment. Calcium and vitamin D supplements alone are insufficient to prevent or treat osteoporosis(3-5) and currently, bisphosphonates are the most widely prescribed medication for treatment of osteoporosis.(6) Bisphosphonates reduce bone resorption by inhibiting the formation and aggregation of calcium phosphate crystals with a consequent slow down in their dissolution also accompanied by a positive calcium balance with an increase in bone mineral content.(7, 8) The net effect on bone mineral density provided by bisphosphonates has been linked to a reduction in the risk of spine and hip fractures.(3, 9)

Recombinant human parathyroid hormone (rhPTH) may be used as an alternative or adjunctive agent to treat osteoporosis. Daily injections of PTH have proven efficacy in increasing bone mineral density based on the fact that physiological release of PTH occurs in a similar intermittent fashion. Animal studies in ovariectomized rats have demonstrated that rhPTH

increases both trabecular bone formation and bone strength with new bone formation especially significant at the end cortical surface and to a lesser extent on the periosteal surface.(10, 11) Pulsatile administration of rhPTH has been shown to increase bone mass in all four bony envelopes: cancellous, endocortical, intracortical, and periosteal. The anabolic action of rhPTH does not require prior stimulation of bone resorption as induced by ovariectomy.(12)

PTH has been shown to have both anabolic and catabolic effects on the skeleton.(15-18) Continuous administration of rhPTH or secretion of rhPTH associated with primary hyper-parathyroidism leads to an increase in both osteoclast cell number and activity. However, at low intermittent doses, rhPTH administration leads to increased bone formation in both rats and humans.(14-19)

Existing literature reports that Etidronate, a first-generation bisphosphonate, delays fracture healing, impairs callus mineralization and ultimately compromises the strength of fractured bone; whereas other bisphosphonates do not have these effects. Given this variation in response, each medication needs to be studied independently.(13) Li et al. have suggested that short term pre-treatment with bisphosphonates would not markedly disturb the fracture healing as long as the treatment is stopped when a fracture occurs.(20)

With an ever increasing older demographic in society, there has been a concomitant increase in the incidence of osteoporosis. Furthermore, a consequent increase in the number of fractures related to osteoporosis (pathologic/fragility fractures) is to be expected. Fracture treatment in a compromised host presents a difficult challenge for the orthopaedic surgeon. New treatment options are required in order to ensure bone healing in those patients with a metabolically compromised skeleton.

The ovariectomized (OVX) rat model exhibits predictable changes in bone that closely resembles the principle features of bone loss seen post-menopause. Therefore, it is generally accepted that OVX rats may be used as the animal model for testing new agents for osteoporosis therapy.(21, 25)

The administration of rhPTH in the setting of fracture healing in an OVX rat model has demonstrated increased bone strength as compared with either normal or sham operated rats that were treated with the vehicle alone. Biomechanical analysis demonstrated significant differences in ultimate load/absorbed energy and ultimate load/ultimate stress. An enhanced response to rhPTH compared with the bone response at non-fractured skeletal sites is evidenced by the corresponding increase in bone formation in the callus and surrounding periosteum.(22, 23)

The purpose of the current study was to compare the effect of rhPTH versus bisphosphonates during diaphyseal osteotomy healing in an osteoporotic rodent model with and without pretreatment with bisphosphonates. The current investigators are unaware of any previous studies examining whether pretreatment with bisphosphonates compromises diaphyseal fracture healing directly whether followed by further bisphosphonate or PTH treatment.

The hypothesis of this study was that rhPTH in comparison with bisphosphonates would provide superior mechanical results for osteotomy healing and would reverse the pre-osteotomy effects of bisphosphonate treatment, if such effects were indeed evident.

Materials and Methods

Approval was sought and obtained from the Institutional Animal Care and Use Committee (IACUC) at the current investigator's hospital. 126 ovariectomized Sprague Dawley rats (average weight 200 g) (Charles River Laboratories Inc., Wilmington, MA) were used for the study. The ovariectomy procedure was performed prior to their arrival at the investigators' institution and timed so that it was 8 weeks prior to the femoral osteotomy procedure.

The animals were randomly divided into two groups of equal size prior to surgical intervention (see Figure 1). Group 1 received pre-treatment with bisphosphonates for 8 weeks and Group 2 received no pre-treatment.

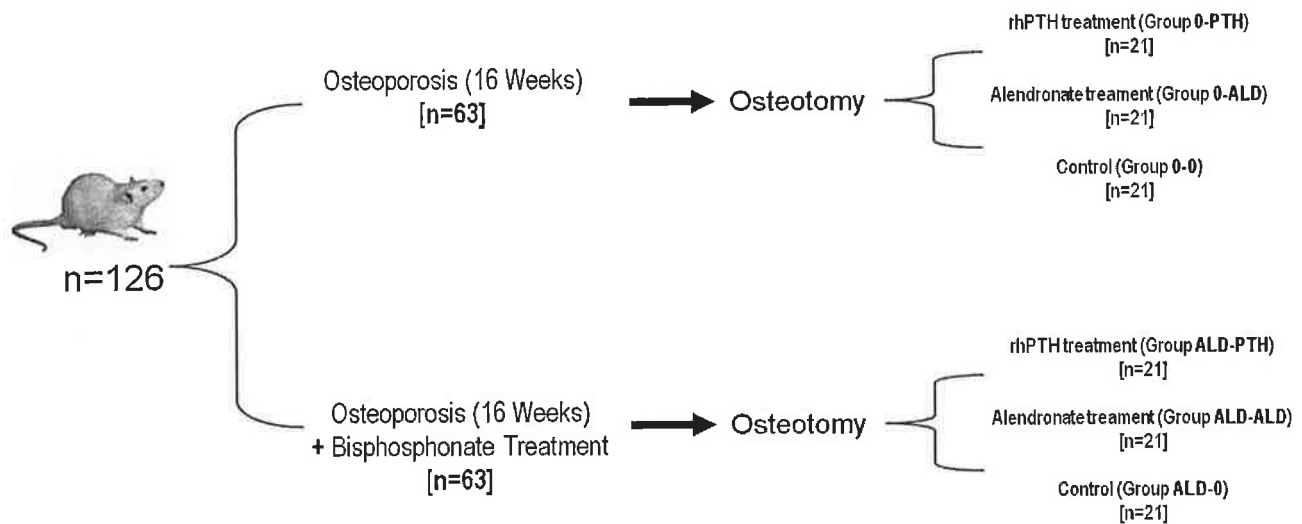


Figure 1. Study design flowchart

Surgery

Anesthetic induction was achieved by means of ketamine ('Ketaset' -- 100 mg/ml) 80 mg/kg, and xylazine ('Rompun' -- 20 mg/ml) 5 mg/kg which were mixed together in a single 1.0 cc TB syringe, and administered intraperitoneally, via a 5/8" 25 g needle into the right lower abdominal quadrant with the animal's anterior body tilted down. As necessary, anesthesia was prolonged for 10 minutes via intraperitoneal administration of an additional half dose of ketamine (i.e.: 40 mg/kg), once only.

The surgical site was prepared with wide margins (3 cm or more if possible) with removal of all hair in this area followed by two applications of Betadine soap and then wiping with 70% isopropyl alcohol. The surgeons in the O.R. performed the final scrub.

A standard femoral shaft osteotomy based on the Amanat technique with a 1 mm power saw through a sub-vastus 3 cm approach was performed.³⁰ A stainless steel smooth Kirschner wire (1.1 mm diameter) was inserted in a retrograde fashion up the femoral canal exiting through the greater trochanter and then advanced distal to the osteotomy site until resistance was found. This technique was chosen over other closed fracture techniques for two main reasons: (i) to ensure reproducibility so as to allow for meaningful comparison and (ii) to provide an adverse environment for osteotomy healing with an open procedure and injury to the periosteum.

Following the procedure the wound was irrigated with 20cc of saline solution and the subcutaneous tissue was closed with 3-0 Vicryl. The skin was closed with 3-0 nylon sutures.

Veterinary Care

All animals were housed in the center for laboratory animal services (CLAS) at the authors' institution. This facility is AAALAC-accredited. Animal Center personnel provided animal care and housing. Clinical veterinary care for all

laboratory animals was provided by the Center for Research Animal Resources (CRAR).

Postoperatively, rats were monitored by the veterinary staff under the supervision of a licensed veterinarian. None of the rodents required euthanasia due to complications of the surgical procedure.

Ability to ambulate was used as the main criteria to determine pain after the procedures. Ambulation signifies minimal discomfort. As these fractures were fixed with intramedullary rods, they were considered "stable" and generally did not cause overt signs of discomfort. Rats were able to full weight bear on the osteotomy side after surgery.

Study Groups Post-Surgery

After the surgical procedure, each group was further sub-divided randomly into three groups (see Figure 1):

No pre-treatment with Alendronate

Group 0-PTH: received a daily subcutaneous injection of 10ug rh rhPTH (1-34) kg/day.

Group 0-ALD: received Alendronate 10ug/kg/day as subcutaneous injection

Group 0-0: received a normal saline subcutaneous injection every day (control group)

Pre-treatment with Alendronate

Group ALD- PTH: received a daily subcutaneous injection of 10ug rh rhPTH (1-34) kg/day.

Group ALD-ALD: received Alendronate 10ug/kg/day as subcutaneous injection

Group ALD-0: received a normal saline subcutaneous injection every day (control group)

Following 6 weeks of pharmacological intervention rodents were euthanized under by means of carbon dioxide (CO₂) inhalation in a customized chamber. Animals were examined to confirm death with subsequent harvest of the tissues of interest. The intramedullary K-wire was removed from all femur specimens. Three femurs from each rat group were fixed and prepared for histological examination and 18 femora from the various groups were removed and cleaned of the surrounding soft tissue and frozen at -20 C for imaging, micro-computed tomography and mechanical testing.

Radiographic evaluation

High resolution faxitron radiographs were taken and three blinded observers assessed bone formation and remodeling, and perform an analysis on a standardized 5 point scale: 0=no new bone evident in defect, 1=0%to 25% fill defect by new bone, 2=26% to 50% fill of defect by new bone 3= 51% to 75% fill defect by new bone and 4= 76% to 100% fill defect by new bone.

Micro Computed tomography (μ CT)

Mineralized tissue was assessed by quantitative μ CT (MS-8 small animal scanner, GE Healthcare, Ontario, Canada). The femora were placed in a saline-filled scan tube and scanned at 80V and *0 μ A. Each scan contained air, saline and a SB-2 bone analogue (1.18 g/cc) for calibration of image via Hounsfield Units to tissue mineral density in mg/cm³. Reconstruction of the individual projections to CT volume data was accomplished with a modified Parker algorithm(26, 27) with an isotropic voxel resolution of 11.6 microns. In order to differentiate mineralized tissue from marrow, water and unmineralized callus, images were thresholded using 25% of the mineral attenuation value of the cortical bone for each specimen.

Regional analyses of the thresholded scans were performed using the system software (MicroView GE Healthcare Technologies Waukesha WI). To characterize calluses locally three volumes of attention (VOI) with a height of 1 mm were selected, at the level of the osteotomy, 2mm distal to the osteotomy site, and 2mm proximally. Within this (VOI) The total content of mineralized tissue [bone mineral content (BMC) in milligrams] and the mineral mass divided by the volume [bone mineral density (BMD) in milligrams per cubic centimeter]. These measurements were used to evaluate the quantity and quality of newly formed bone.

Biomechanical testing

Each femur was tested to failure a four-point bending technique with an ELF3200 high precision mechanical testing apparatus (EnduraTEC, Minnetonka, MN). The flat posterior surface of the femora was placed between the two inner points of the four point bending fixture. Bending stiffness, failure moment and failure deflection were determined. The upper load points were set 3.5mm apart, and load was applied until failure occurred. The bending moment to failure (N/mm) and bending stiffness (N/mm²) within the elastic range were calculated from the load deflection curves and the four point dimensions.

Histological Analysis

Paraffin embedded samples

Fracture sites were cleaned of muscle and preserved in 10% phosphate buffered formalin for 2 days at 4C. Following a 4 hour running water rinse, samples were decalcified in 5% nitric acid or 10% EDTA until bone was soft and flexible. An overnight running water rinse was followed by processing in a VIP tissue processor to paraffin. Embedded samples were sectioned at 5 microns thickness and subsequently stained with Alcian Blue for cartilage and Masson's Trichrome or H&E for standard morphometry and histology.

Methacrylate embedding for calcified samples

Following the 2 day formalin fixation, samples were washed overnight in running water, dehydrated through alcohols, cleared in xylene, and embedded in methyl methacrylate according to Erban (J.Histochem.Cytochem. v45, pp307-314, 1997). These calcified tissues were sectioned at 5-7 microns thickness with a tungsten carbide blade on Reichert-Jung Ultracut E microtome. These sections were stained with Alcian Blue to discriminate all the cartilage in the fracture site, with von Kossa to evaluate all the mineralized tissue in the site, and with Goldners Trichrome to evaluate the osteoid, or new unmineralized bone being deposited at bone forming sites.

Using the Bioquant morphometric system, we determine the percentage of cartilage present in the tissue site, the percentage of bone, the percentage of marrow, and the percentage of connective tissue, which makes up each fracture site. In addition, we determine the percentage of surfaces undergoing new bone formation, the percentage undergoing resorption, and the percentage of quiescent surface within each fracture site.

Bone Formation Rate

Two fluorescent labels were administered to each animal at 7 days and 3 days prior to sacrifice. The labels of choice are Tetracycline (5mgs/kg body wt) and Xlenol Orange (90 mgs/kg body wt) because they fluoresce green

and orange and are easily seen in calcified tissues. With Bioquant, we can measure the distance between the two labels and determine the rate of new bone formation, expressed in microns/day. These values can be statistically evaluated for variations between groups.

Statistical analysis

A power analysis was conducted at the planning stages of the experiment, with 18 rats per group, 80% power was established amongst groups with 1.2 times the pooled standard deviation.

Micro CT

The mean standard deviation was calculated for each group, two-way ANOVA followed by Bonferroni post-hoc tests were used to compare the means of each group to assess for statistical differences ($p < 0.05$).

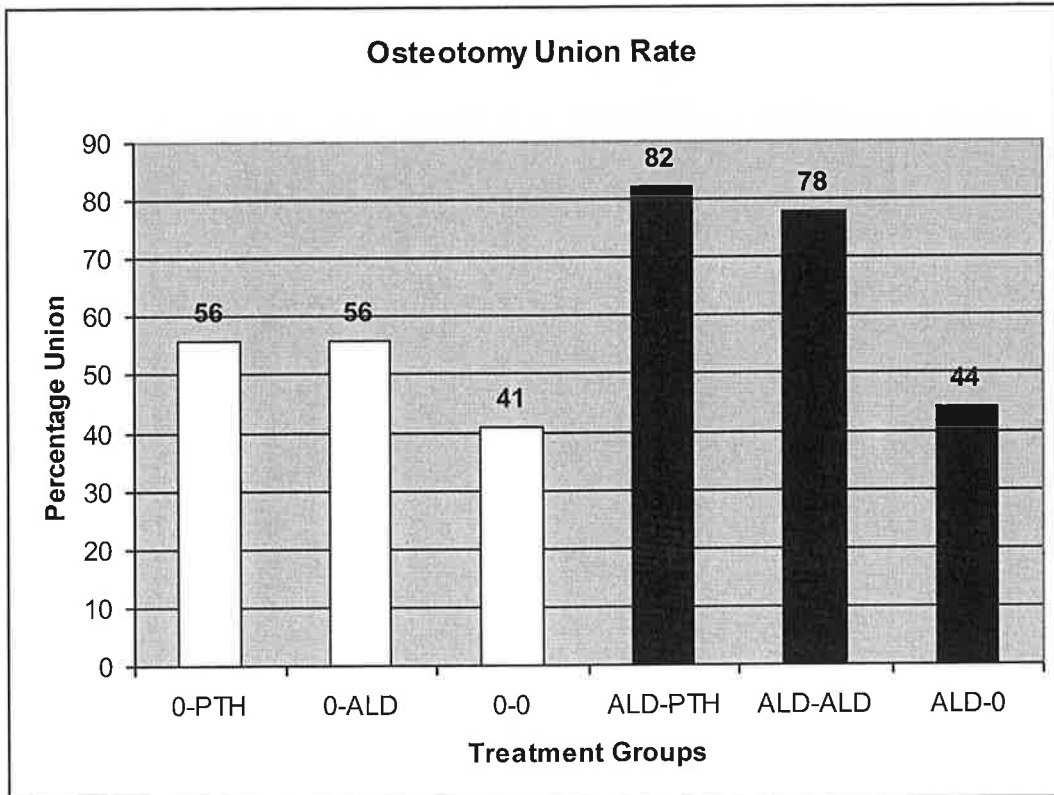
Mechanical Testing

Failure moment and bending stiffness were calculated for all specimens. The values from the intact femurs were used as baseline measurements. Values for the osteotomized specimens were subtracted from the values obtained from the contra-lateral limb (intact limb) to determine the change in failure moment and bending stiffness after treatment. A Mann-Whitney rank sum test was performed with pre-osteotomy treatment and post osteotomy treatment as the factors in one analysis and pharmacological intervention versus no intervention at all were analyzed as factors in a second analysis.

Results

Union rate

Focusing on the fracture callus, qualitative observations were made by a single observer for all samples. For each of the six subgroups the percentage of successful unions was determined (Figure 2).



It was decided that nonunions were those samples which were readily deformed by gravity when the sample was held at one end in the horizontal position and that did not demonstrate any biomechanical resistance when tested. The union rates for animals that did not receive pre-treatment with Alendronate and post-treated with either Alendronate or rhPTH (Groups 0-ALD and 0-PTH) were both 56% while those that did not receive post-op

pharmacological treatment i.e. 0-0, (control) had a union rate of 41%. The union rates for animals pre-treated with Alendronate and post-treated with Alendronate or rhPTH (Groups ALD-ALD and ALD-PTH), were 82% and 78% respectively. ($p=0.0021$), while those that received pre-treatment with Alendronate but did not receive post-op pharmacological treatment (Group ALD-O) had a union rate of 44%. Overall, animals that received Alendronate before osteotomy and were post-treated with Alendronate or rhPTH demonstrated a significantly higher union rate when compared to all the other groups

X-ray assessment, using the 5 point scale, for new bone formation demonstrated no statistical significance between groups using the Mann-Whitney Rank Sum test ($p = 0.71$).

Abnormal callus formation

X-ray analysis also revealed large callus formation extending proximally and distally from the osteotomy site covering the surface of the original diaphyseal cortex. These findings varied in frequency and character between different treatment groups. The ALD—0 group had a greater rate of such a radiological presentation with 13 samples of 18. Additionally, samples from this group seemed radiographically less dense when compared to other groups. In contrast, the 0-PTH group demonstrated more dense bone than the other groups.

Biomechanical Testing

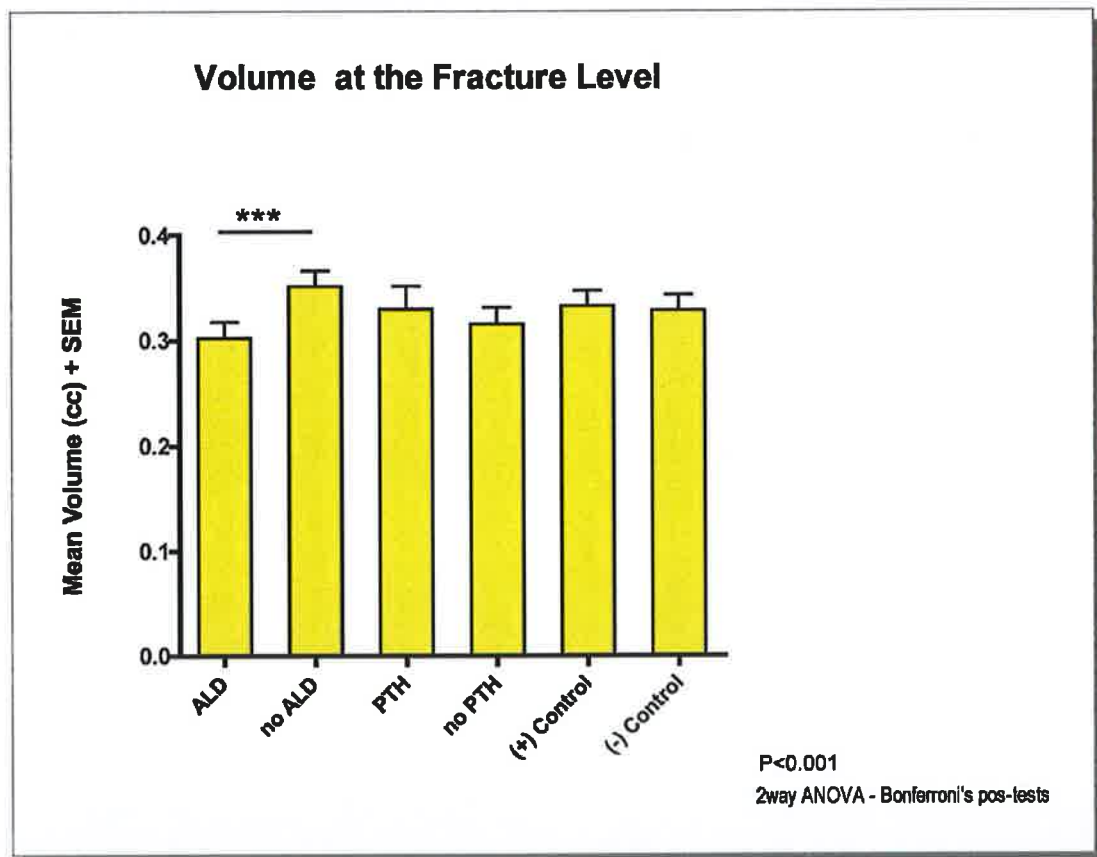
A statistically significant difference was not found in terms of improved failure moment or bending stiffness between sub-groups (Table 1).

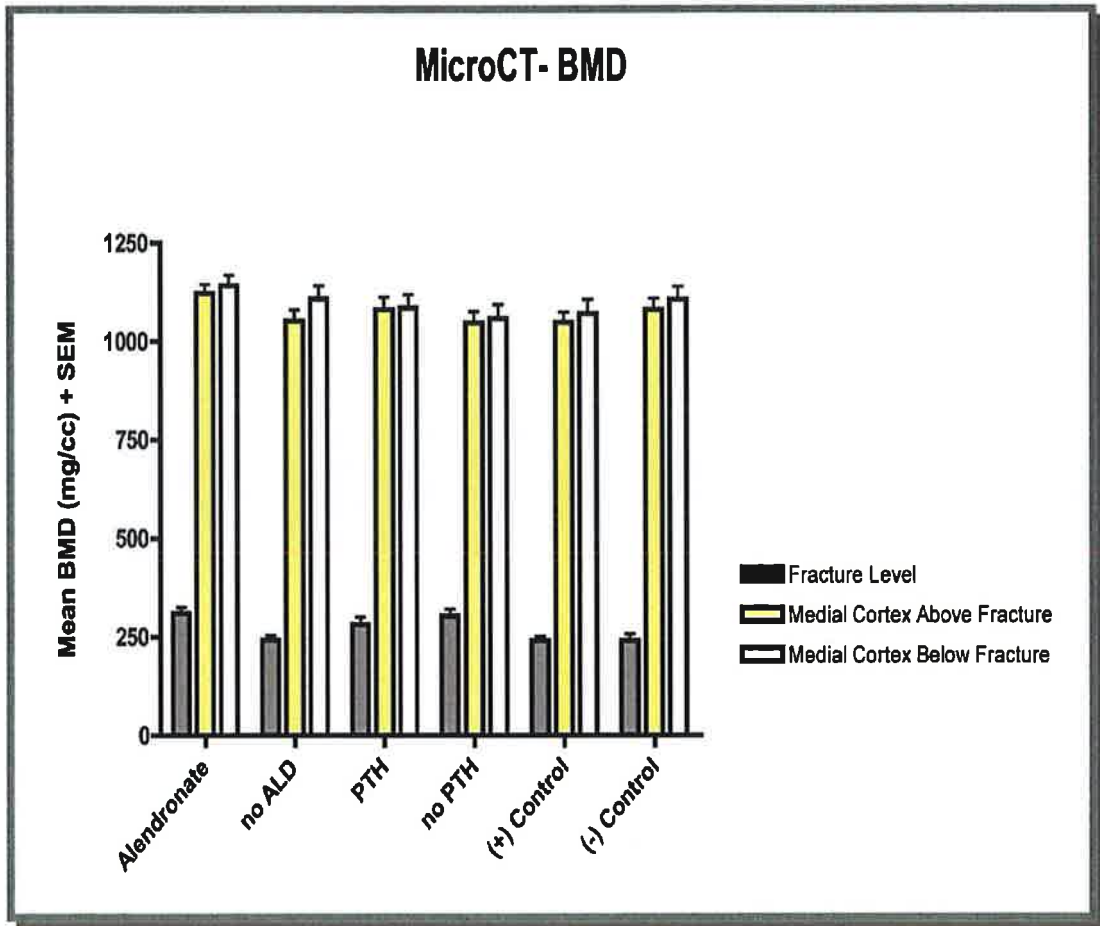
Biomechanical Testing						
	Failure Moment (Nm)		Bending Stiffness (Nm²)		Displacement at failure (mm)	
	<i>p</i> - value	Significant?	<i>p</i> - value	significant?	<i>p</i> - value	significant?
Pre-treatment vs. No pre- treatment	0.52	no	0.28	no	0.86	no
ALD vs PTH vs Control	0.07	no	0.07	no	0.08	no
Pre-fracture vs Post-fracture	0.68	no	0.58	no	0.79	no

When samples that had some pharmacological intervention were pooled and compared to those samples that did not receive medication at any time point there was a statistical significance for failure moment ($p=0.02$) and bending stiffness ($p<0.0001$)

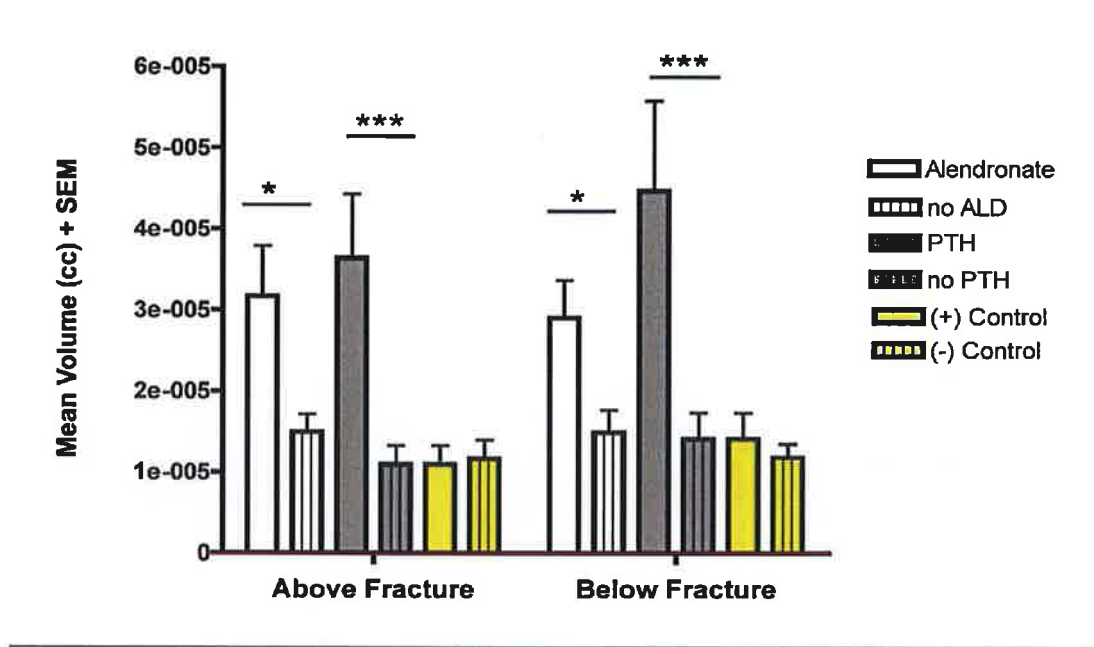
Micro CT

Despite an increased rate of bony union, no statistically significant difference or trend was demonstrated at the osteotomy site for callus bone volume (Figure 3), BMD (Figure 4) or BMC.





There was a trend in improved bone volume proximal and distal to the osteotomy site in those samples that had pharmacological intervention before and after surgery (Figure 5).



Histomorphology

Fluorescence in the control group was uniformly distributed throughout the whole bony surface with further enhancement at the osteotomy level. All of other samples exhibited a pattern of less fluorescence at the osteotomy site when compared to the control. There was no difference between those specimens which had had medication before or after osteotomy.

In all samples, the intramedullary canal was the most enhanced part of the bone. It was hypothesized but unclear as to whether this might be secondary to the mechanical stimulation of the intramedullary K-wire. Von Kossa stains revealed some callus formation at the osteotomy level with active cartilage at the osteotomy and no cortical callus union. Those animals who did not have pre-treatment with Alendronate demonstrated active cartilage and a large callus when compared to control samples. Cartilage islands were noted in

the intramedullary canal. Those 0-PTH group showed a greater amount of callus formation when compared to the control group and alendronate treated groups. Callus formation was also noted around the periosteum forming a new collar of cartilage around the bone. The ALD-0 group showed more cartilage formation and callus formation than the control group but no clear differentiation that could describe a specific pattern of ossification.

TRAP Staining

Osteoclast number distribution and morphology:

The 0-0 varied widely, with low activity at the distal aspect of the femur and at the osteotomy level. The 0-ALD group was biased by the abnormal callus appearance that showed high osteoclast numbers throughout the diaphysis with a possible increase in osteoclastic nuclei. The 0-PTH sample had a high number of osteoclasts at the cartilaginous callus arena with high activity at the distal aspect of the bone and seemingly normal numbers of nuclei. The ALD-O group displayed a high number of osteoclasts at the cartilaginous areas of the callus with low activity and a high number of nuclei at the osteotomy callus level. The ALD-ALD group demonstrated a high number of osteoclasts along the callus cartilage and the distal aspect of the bone with large osteoclasts with a high number of nuclei. The ALD-PTH group revealed many osteoclasts lining the cartilaginous osteotomy bridge and in the distal metaphyseal bone with normal nuclei number and cell morphology.

There was a lower amount of osteoclasts at the callus level when compared to the control-control group.

Histomorphometry was performed on the Von Kossa, Goldner's and fluorescent samples. Callus size, volume, diameter, width and bone proportions of trabecular, cortical or void space were examined using Von Kossa staining. None of the samples exhibited a specific pattern which could allow conclusions to be made.

When rate formation was analyzed after reviewing fluorescent samples no differences were obtained between samples. Callus composition and cell numbers were elucidated using Goldner's Trichrome staining. Fibrous tissue percentage, cartilaginous tissue percentage, osseous tissue percentage and void space percentage were not significantly different when comparing the various groups. Cell counts were performed at the osteotomy level to assess functional status of the different bone samples. No significant differences in osteoblast number or density were evident between the groups.

An increase in osteoclast cell number and density in those groups pre-treated with alendronate was observed. The osteoid surface area ratio was examined and while no statistical significance was observed, there was a trend towards increased osteoid in the 0-PTH and ALD-PTH animals, and a decrease in osteoid in the 0-ALD and ALD-ALD animals.

Discussion

Bisphosphonates have been used therapeutically for the last three decades to treat a variety of metabolic bone disorders. Alendronate is the most frequently prescribed bisphosphonate in the United States at present.

Treatment with parathyroid hormone once a day results in significant increase in the bone mineral density of the spine and proximal femur, without impairing bone quality. This will results in a decrease in the risk of both compression fractures of the spine and nonvertebral osteoporotic fractures of more than 50%. Both bisphosphonates and rhPTH have demonstrated a benefit in treating osteoporosis which is the primary risk factor for fractures in the elderly.

The present study intended to simulate an estrogen-deficient condition with the presence of a fracture and demonstrate beneficial or deleterious effects of Alendronate and rhPTH. The hypothesis of this study was that rhPTH in comparison with bisphosphonates would provide superior mechanical results for osteotomy healing and would reverse the presumed deleterious pre-osteotomy effects of bisphosphonate treatment, if such effects were indeed evident.

The current authors found that Alendronate did not inhibit osteotomy healing, and actually, more importantly, prevented the development of nonunion in

the estrogen deficient rat model when administered before and after osteotomy. They also found comparable union rates when rhPTH was administered after osteotomy in groups pretreated with Alendronate despite the fact that the pharmacological pathways are different.

Estrogen-deficient rats that received either rhPTH or Alendronate after osteotomy without pretreatment with Alendronate showed higher union rates when compared to controls i.e. the 0-0 group. However, the union rates were not equivalent to rats that received pre-treatment with Alendronate with subsequent post-treatment with PTH or Alendronate. In addition, no statistical significance in union rate was found when compared to the control group, indicating that Alendronate pre-treatment was the most important factor to increase the union rate.

Biomechanical tests results demonstrated a trend of improved failure moment and bending stiffness of the osteotomy callus following pretreatment with Alendronate and post-treatment with either Alendronate or rhPTH but this was not significantly different between the 6 different subgroups.

When all samples that received pharmacological treatment before osteotomy (Alendronate) and/or after (RhPTH or Alendronate) were pooled and compared to the control group (no treatment before or after the osteotomy) statistical significance was noted, indicating that pharmacological

intervention may have a role in improving osteotomy callus mechanical resistance in the estrogen-deficient rat model. The control group (0-0) had a union rate of 41 % indicating that the estrogen-deficient condition is a risk for the development of nonunion.

Micro CT analysis did not demonstrate statistically different values for bone volume, mineral content or bone mineral density following osteotomy. There was a trend of improved bone volume distal and proximal to the osteotomy site in samples that had been pretreated with Alendronate and post treated with Alendronate or rhPTH after surgery. The current authors believe that this phenomenon was secondary the early time point for animal sacrifice.

Histological analysis was intended to provide a qualitative description of the samples analyzed. No particular cell pattern activity or distribution that could be correlated to the other modes of analysis could be established. No statistical analysis was applied to the histological samples given the small group sizes. Of note, the control group did show evidence of decreased cellular activity that can be associated to decreased anabolism secondary to estrogen deficiency.

In summary, osteotomy healing was significantly enhanced by pre-operative pharmacological intervention with Alendronate followed by post-operative treatment with either Alendronate rhPTH post-osteotomy. The data also

suggests that pharmacological intervention in the form of either Alendronate or rhPTH may improve mechanical resistance for failure moment and bending whether these agents are administered both pre-osteotomy and post-osteotomy or post-osteotomy alone. Critically the current investigators did not find any correlation between delayed osteotomy healing and Alendronate use.

References

1. Osteoporosis prevention diagnosis and therapy. March 27-29, 2000.; .
2. Melton LJ,3rd, Chrischilles EA, Cooper C, Lane AW, Riggs BL. Perspective. How many women have osteoporosis? J Bone Miner Res 1992 Sep;7(9):1005-10.
3. Black DM, Cummings SR, Karpf DB, Cauley JA, Thompson DE, Nevitt MC, et al. Randomised trial of effect of alendronate on risk of fracture in women with existing vertebral fractures. Fracture Intervention Trial Research Group. Lancet 1996 Dec 7;348(9041):1535-41.
4. Cummings SR, Black DM, Thompson DE, Applegate WB, Barrett-Connor E, Musliner TA, et al. Effect of alendronate on risk of fracture in women with low bone density but without vertebral fractures: results from the Fracture Intervention Trial. JAMA 1998 Dec 23-30;280(24):2077-82.
5. Cummings SR, Black D, Barrett-Connor E, Scott J, Wallace RB. Alendronate and fracture prevention. JAMA 1999 Jul 28;282(4):324-5.
6. Chesnut CH,3rd, McClung MR, Ensrud KE, Bell NH, Genant HK, Harris ST, et al. Alendronate treatment of the postmenopausal osteoporotic woman: effect of multiple dosages on bone mass and bone remodeling. Am J Med 1995 Aug;99(2):144-52.
7. Fleisch H, Russell RG, Bisaz S, Casey PA, Muhlbauer RC. The influence of pyrophosphate analogues (diphosphonates) on the precipitation and dissolution. Calcif Tissue Res 1968:Suppl:10-10a.

8. Gasser AB, Morgan DB, Fleisch HA, Richelle LJ. The influence of two diphosphonates on calcium metabolism in the rat. *Clin Sci* 1972 Jul;43(1):31-45.
9. Black DM, Thompson DE, Bauer DC, Ensrud K, Musliner T, Hochberg MC, et al. Fracture risk reduction with alendronate in women with osteoporosis: the Fracture Intervention Trial. FIT Research Group. *J Clin Endocrinol Metab* 2000 Nov;85(11):4118-24.
10. Hock JM, Gera I, Fonseca J, Raisz LG. Human parathyroid hormone-(1-34) increases bone mass in ovariectomized and orchidectomized rats. *Endocrinology* 1988 Jun;122(6):2899-904.
11. Jahng JS, Kim HW. Effect of intermittent administration of parathyroid hormone on fracture healing in ovariectomized rats. *Orthopedics* 2000 Oct;23(10):1089-94.
12. Reeve J. PTH: a future role in the management of osteoporosis? *J Bone Miner Res* 1996 Apr;11(4):440-5.
13. Lehman RA, Jr, Kuklo TR, Freedman BA, Cowart JR, Mense MG, Riew KD. The effect of alendronate sodium on spinal fusion: a rabbit model. *Spine J* 2004 Jan-Feb;4(1):36-43.
14. Danielsen CC, Mosekilde L, Svenstrup B. Cortical bone mass, composition, and mechanical properties in female rats in relation to age, long-term ovariectomy, and estrogen substitution. *Calcif Tissue Int* 1993 Jan;52(1):26-33.

15. Dempster DW, Cosman F, Parisien M, Shen V, Lindsay R. Anabolic actions of parathyroid hormone on bone. *Endocr Rev* 1993 Dec;14(6):690-709.
16. Audran M, Basle MF, Defontaine A, Jallet P, Bidet MT, Ermias A, et al. Transient hypoparathyroidism induced by synthetic human parathyroid hormone-(1-34) treatment. *J Clin Endocrinol Metab* 1987 May;64(5):937-43.
17. Ejersted C, Andreassen TT, Oxlund H, Jorgensen PH, Bak B, Haggblad J, et al. Human parathyroid hormone (1-34) and (1-84) increase the mechanical strength and thickness of cortical bone in rats. *J Bone Miner Res* 1993 Sep;8(9):1097-101.
18. Reeve J, Hesp R, Williams D, Hulme P, Klenerman L, Zanelli JM, et al. Anabolic effect of low doses of a fragment of human parathyroid hormone on the skeleton in postmenopausal osteoporosis. *Lancet* 1976 May 15;1(7968):1035-8.
19. Whitfield JF, Morley P, Ross V, Isaacs RJ, Rixon RH. Restoration of severely depleted femoral trabecular bone in ovariectomized rats by parathyroid hormone-(1-34). *Calcif Tissue Int* 1995 Mar;56(3):227-31.
20. Li C, Mori S, Li J, Kaji Y, Akiyama T, Kawanishi J, et al. Long-term effect of incadronate disodium (YM-175) on fracture healing of femoral shaft in growing rats. *J Bone Miner Res* 2001 Mar;16(3):429-36.
21. Frost HM, Jee WS. On the rat model of human osteopenias and osteoporoses. *Bone Miner* 1992 Sep;18(3):227-36.

22. Holzer G, Majeska RJ, Lundy MW, Hartke JR, Einhorn TA. Parathyroid hormone enhances fracture healing. A preliminary report. Clin Orthop Relat Res 1999 Sep;(366)(366):258-63.
23. White AA,3rd, Panjabi MM, Southwick WO. Effects of compression and cyclical loading on fracture healing--a quantitative biomechanical study. J Biomech 1977;10(4):233-9.
24. Miller PD. Osteoporosis. In: Rakel BA, editor. Conn's Current Therapy. 54th ed. WB Saunders Company; 2002. p.586-98.
25. McCann RM, Colleary G, Geddis C, Clarke SA, Jordan GR, Dickson GR, et al. Effect of osteoporosis on bone mineral density and fracture repair in a rat femoral fracture model. J Orthop Res 2008 Mar;26(3):384-93.
26. Parker DL. Optimal short scan convolution reconstruction for fanbeam CT. Med Phys 1982 Mar-Apr;9(2):254-7.
27. Feldkamp LA, Goldstein SA, Parfitt AM, Jesion G, Kleerekoper M. The direct examination of three-dimensional bone architecture in vitro by computed tomography. J Bone Miner Res 1989 Feb;4(1):3-11.

III. PTH (1-34) Augments Spinal Fusion, Fusion Mass Volume and Fusion Mass Quality in a Rabbit Spinal Fusion Model

Abstract

Study Design

The posterolateral rabbit spinal fusion model was used to assess the effect of intermittent parathyroid hormone on spinal fusion outcomes.

Objective

To test the hypothesis that intermittent PTH improves spinal fusion outcomes in the rabbit posterolateral spinal fusion model.

Summary of Background Data

Spinal fusion is the definitive management for spinal deformity or instability, yet despite current technology, 5-40% of lumbar fusions result in pseudarthrosis. Animal studies have demonstrated enhanced fracture healing with the use of PTH but the effect of PTH on spinal fusion is poorly described.

Methods

44 male New Zealand white rabbits underwent bilateral posterolateral spine fusion (L5-L6 level). 22 rabbits received daily subcutaneous injections of PTH (1-34) (10mcg/kg) and 22 received an injection of saline fluid. All were sacrificed six weeks post-operatively. L5-L6 vertebral segments were removed and analyzed with manual bending, faxitron radiography, microCT and histomorphometry.

Results

Manual bending identified fusion in 30% (control) versus 81% (PTH) animals ($p < .001$). A radiographic scoring system ('0' = no bone formation, '5' = full fusion) resulted in an average score of 3.36 (control) versus 4.51 (PTH) ($p < .001$). MicroCT analysis demonstrated a median mass of 3.5cc (control) [range 2.25cc-5.40cc] versus 6.03cc (PTH) [range 4.34cc-10.58cc] ($p < .001$). Histology showed a median percentage bone area of 14.3% (control) (n=12) versus 29.9% (PTH) (n=15) ($p < .001$). The median percentage cartilage was 2.7% (control) (n=5) versus 26.6% (PTH) (n=5) ($p < .01$). Osteoclast quantification revealed median values of 140.5 (control) (n=6) and 345.0 (PTH) (n=8) ($p < .001$) respectively and the percentage of osteoblasts revealed a median value of 31.4% (control) (n=6) versus 64.4% (PTH) (n=8) ($p < .001$).

Conclusion

Intermittent PTH administration increased posterolateral fusion success in rabbits. Fusion bone mass and histological determinants were also improved with PTH treatment. PTH has promise for use as an adjunctive agent to improve spinal fusion in clinical medicine.

Key Words

Parathyroid hormone, posterolateral spinal fusion, rabbit model, adjunctive agent

Key Points

- Intermittent PTH administration has an anabolic effect
- Parathyroid hormone (PTH) (1-34) is the only FDA-approved anti-osteoporotic agent with an anabolic capacity.
- In a posterolateral spinal fusion rabbit model PTH increased fusion success
- Fusion bone mass and histological determinants (bone, cartilage, osteoblasts, osteoclasts) were all increased compared to the control
- PTH shows promise for use as an adjunctive agent to improve spinal fusion in a clinical setting

Mini Abstract/Précis

The rabbit posterolateral spinal fusion model was used to assess the effect of intermittent parathyroid hormone administration on spinal fusion outcomes. Intermittent PTH improved spinal fusion success and histological endpoints in the model.

Introduction

Spinal fusion is the surgical treatment of choice for multiple spinal disorders and abnormalities. Fusion definitively stabilizes the spinal column for disorders such as structural deformity, traumatic instability, degenerative instability, and post-resection iatrogenic instability. Fusion or arthrodesis is achieved by the formation of an osseous bridge between adjacent motion segments.

At low intermittent pulsatile doses, PTH administration leads to increased bone formation in rats and in humans.¹⁻³ Despite all of the studies conducted so far on the use of PTH, at the conception of this project, none had studied its effect on spinal fusion. Since this project's genesis, to the authors' knowledge, only one study has been published on this topic suggesting that PTH may enhance fusion in a rat model.⁴

We hypothesized that PTH administered in a pulsatile (daily injection) manner would result in a higher rate of successful fusion and an increase in fusion mass volume in a rabbit posterolateral single level spinal fusion model.

Materials and Methods

44 male New Zealand white rabbits (sourced from HRP Inc. (Denver, PA), age 6 months and average weight 4-6kgs) were analyzed in this study. The animals were divided into two groups of 22 animals. Both groups underwent a bilateral posterolateral spine fusion procedure.⁵ This involved implantation of a morselized iliac crest bone graft. Starting on post-operative day number 4, Group I received daily subcutaneous injections of saline solution, while Group II received a daily subcutaneous injection of recombinant parathyroid hormone (PTH) (1-34) at a dose of 10mcg/kg. This dose was based on preclinical rabbit data from Eli Lilly pharmaceuticals (Eli Lilly and Company, Indianapolis, IN)^{6, 7} The PTH used in this study was supplied by Eli Lilly pharmaceuticals. It was teriparatide (brand-name Forteo) prepared in a buffer containing 2% rabbit serum. The pharmacology of PTH (1-34) has been elucidated extensively in the literature.⁷⁻¹⁴

Arthrodesis in Rabbits

Using an IACUC approved protocol, bilateral posterolateral lumbar L5-6 spine fusions were performed as previously described.⁵ The only variation in the surgical technique involved volume of iliac crest graft utilized. In the original description of the model, 3 cc of graft were harvested and delivered to each side of the intended arthrodesis.⁵ In an effort to reduce the rate of arthrodesis from the 60-70% rate that has been described for the model^{5, 15}, we chose to use a smaller graft volume, which has been shown to decrease

fusion rates in the model.¹⁶⁻¹⁹ The graft volume used was 1 cc, which has been demonstrated to result in a successful fusion in 25% of animals.¹⁹ Iliac crest autograft was measured by placing the morselized bone graft in an open-ended syringe and applying compression with finger pressure until the 1cc level was reached. This graft volume was chosen to provide a large potential for PTH augmentation and to accentuate the postulated beneficial effect of PTH administration.

All animals were euthanized six weeks from the time of surgery by administration of a sedative (acetyl-promazine 1mg/kg intramuscularly) followed 20 minutes later by sodium pentobarbital (26% solution, 2cc intravenous).

Manual Palpation

The lumbar spinal segment L5-L6 was removed en-bloc from all of the animals and the majority of soft tissue was removed without disturbing the fusion mass. Each spine was assessed for fusion by manual palpation by three observers who were blinded to the type of treatment that the animal had received. Manual palpation has been reported to be the most sensitive and specific method of assessing fusion in this model.^{5, 16, 20} Specimens were assessed in both coronal and sagittal planes and were scored as having "motion" or "no motion" at the L5/L6 segment by each examiner. Specimens were graded as fused when at least two observers scored the

spine as having “no motion”. All remaining specimens were considered not fused.

Radiographic Analysis

Faxitron (Hewlett Packard, McMinnville, OR) high-resolution radiographic analysis was performed for each specimen L5-6 spinal segment, with images taken immediately post-op and at the time of sacrifice. Images were graded for fusion bone quantity and evidence of fusion using a numeric grading system (Table 1). Scoring was performed in a blinded manner by three independent observers; the average score for each fusion mass and standard deviations are reported.

Fusion mass volumetric analysis (CT)

The posterolateral fusion masses were quantified for volume of bone produced in each of the specimens. High resolution helical computed tomography (GE Light Speed Plus CT scanner, GE Medical Systems, Milwaukee, WI) was used to create axial images of the specimens in 0.63mm cuts. These axial images were reformatted into three dimensional reconstructions, and regions of interest (ROIs) were rendered around the fusion masses bilaterally to quantify the fusion bone volume (Voxtool Version 3.0.26e, GE Advantage Windows Workstation 4.0, General Electric, Milwaukee, WI). Fusion bone volume quantifications were performed by an independent observer blinded to the treatment groups. Right and left sides of

each specimen were considered together given the physical link between them and their interdependence for successful fusion. Fusion bone volume quantification for left and right were then summed to give a total fusion mass volume for each specimen; values are reported as group averages and standard deviations.

Histologic Techniques

Histological analysis was performed on all specimens.. All specimens were fixed in 4% paraformaldehyde after palpation assessment and faxitron images had been obtained. Fixed samples were then subjected to CT, with half of the specimens then being processed for decalcified and undecalcified processing. Decalcification was performed overnight in nitric acid. Samples were dehydrated by a series of ethanol solutions and finally embedded in paraffin. Undecalcified samples were dehydrated in a series of ethanol solutions, had lipids removed in an acetone wash, and were embedded in polymethylmethacrylate (PMMA) for sectioning. Serial coronal sections were cut from the center of the fusion mass of both preparations using a microtome (Reichert-Jung model 2030, Nussloch, Germany) (7 micron thick slices) for the paraffin-embedded samples and a Leica microtome (Leica Microsystems Inc., Bannockburn, IL) (5 micron thick slices) for the PMMA-embedded samples. Sections were mounted on plastic slides and stained in a systematic fashion to allow optimal comparisons between specimens and groups. Stains used were Van Kossa (calcified tissues),

Goldner's Trichrome (osteoid, bone), and Alcian Blue (cartilage). Immunostains were utilized for quantification of osteoclasts (Cathepsin-K) and osteoblasts (Procollagen-1).

Sections were studied under light microscopy (Nikon Microphot FXA, Nikon, Melville, Long Island, NY) and each image was digitized and analyzed using Bioquant software (Bioquant Image Analysis Corp., Nashville, TN). Image analysis was performed to estimate the percentage area of fibrous tissue, cartilage and bony tissue as well as to quantify both osteoblasts and osteoclasts. Bone area within samples was quantified from three randomly selected high power fields of samples prepared using the Von Kossa Reaction. Bone area is normalized as a fraction (percent) of total area, and is reported as average +/- standard deviation for each sample. Cartilage area within samples was determined by a similar technique, using Alcian Blue stained sections, and is reported as average +/- standard deviation for each sample. Osteoblasts were identified by immunostain for procollagen-1, and were quantified relative to their apposition to osteoid surfaces as a marker for active osteoblastic function. Osteoblast populations were quantified for length of their linear apposition along osteoid surfaces relative to total osteoid surface length for three randomly selected high power fields, and are reported as a fraction (percent) average +/- standard deviation for each sample. Osteoclasts were identified by immuno-stain for cathepsin-K, and were directly quantified in three randomly selected high power fields for

each sample; values reported are averages +/- standard deviation for each sample.

Statistical Methods

Scores from the manual palpation assessment and the radiographic analyses were compared statistically using the Chi-Square Test and the Fisher Exact Test, respectively. Cohen's Kappa Statistic was calculated to demonstrate inter-observer agreement. Kappa statistic was interpreted as: 1-0.9 excellent, 0.89-0.7 good, 0.69-0.5 moderate, 0.49 to 0.25 low, and 0.24-0.0 poor, as described previously. The Mann Whitney U test was used to compare histological differences between the treatment groups. The power analysis for the study was performed using manual palpation and radiographic assessment as the primary outcome variables.

Results

Fusion Quantification: Manual Palpation and Faxitron Assessments

Animals were euthanized at 6 weeks, and manual palpation testing of explanted spines identified fusion in 30% of the saline control group and 81% fusion in the PTH treatment group (Chi-squared test = 10.8, $p < 0.01$, Fisher exact test $p < 0.002$). High definition faxitron images of the samples were obtained and graded using a 0-5 radiographic scoring system (Table 1, Figure 1). The average fusion grade score for saline control animals was 3.36, while the average fusion grade score for PTH treated animals was

4.51. (Chi-squared test= 29.4, Fisher exact test $p < .001$, Cohen's Kappa statistic 0.76 with 83% agreement in inter-observer scoring).

Bone Production Quantification: Fusion Mass Volumetric Analysis by CT

Fine cut CT analysis and volume measurement demonstrated a 75% increase in bone formation in the PTH treated animals with an average combined (sum of left and right) mass of 3.5 +/- 0.81cc in control animals [range 2.25-5.40cc] and a combined value of 6.1 +/- 1.40cc with PTH treatment [range 4.34-10.58cc] ($p < 0.001$). Median bone mass formation was 3.44cc for control and 6.03cc for PTH treatment.

Bone Quality Assessment: Histomorphometric and Histological Analysis

Samples were processed for histology and histomorphometry using both undecalcified and decalcified methodologies. Endpoints evaluated were total bone area within a section normalized to total section area (percentage bone), percentage of cartilage by area, total osteoclast number, and relative quantification for active osteoblasts. Undecalcified specimens were processed using the Von Kossa reaction, and were quantified for total area of positive stain (bone area) relative to total specimen area using computer-assisted image analysis.(Figure 2) Control samples had a median percentage bone value of 14.3 +/- 10.3% (n=12), while PTH treated samples had significantly more bone area, with a median of 29.9 +/- 11.9% (n=15) ($p < 0.001$). (Figure 3) Decalcified samples were used for the remaining

histology and histomorphometry. Alcian Blue was used to identify cartilage-like tissue within the specimens, and positively staining areas were quantified relative to total sample area for each sample.(Figure 4) There was significantly less cartilage area present in the control samples with a median value of 2.7 +/- 3.5% (n=5) ($p < 0.01$) than the samples from PTH treated animals 26.6 +/- 2.7% (n=5) ($p < 0.01$). (Figure 5) Osteoclasts were identified with an immunostain for cathepsin-K and were digitally quantified.(Figure 6) Control samples had significantly lower median values for total osteoclast number per high powered field 140.5 +/- 20.87 (n=6) and than samples from PTH treated animals 345.0 +/- 42.02 (n=8) ($p < 0.001$). (Figure 7) Osteoblasts were identified with an immunostain for procollagen-1, and were quantified for their apposition to osteoid (suggesting active bone formation) as normalized to all visualized osteoid containing areas within 3 high powered fields.(Figure 8) The median percentage of osteoblasts in apposition to osteoid was significantly higher in the samples from the PTH treated animals 64.4 +/- 4.3% (n=8) than the control specimens 31.4 +/- 1.8% (n=6) ($p < .001$). (Figure 9)

Discussion

PTH, an amino acid polypeptide, is a major regulator of bone and calcium metabolism. It increases calcium in the extracellular fluid by binding to and activating osteoclasts, by increasing tubular reabsorption of calcium in the kidney and through promotion of intestinal absorption of calcium in the gut. The characteristic effects of PTH on the skeleton are produced by the amino terminal portion of the hormone (1-34 or 1-38).¹⁻³ Although a continuous infusion of PTH has been seen to elicit a net catabolic effect, intermittent administration is associated with a net anabolic effect on bone and cartilage.^{1, 2, 21-27} The anabolic effects of PTH (1-34) on fracture healing in animal models are well documented in the literature.^{4, 6, 7, 23, 28-40} Andreassen et al. showed an increase in callus formation and mechanical strength in a rat model compared to control specimens.^{28, 41}

In a rabbit model of posterolateral spinal fusion with autograft and without instrumentation, we assessed the effect of PTH (1-34) on spinal fusion success, radiographical and histological endpoints. PTH significantly enhanced posterolateral fusion success and augmented the quantity of the fusion bone produced. PTH also significantly increased osteoblast numbers in apposition to osteoid, total osteoclast populations and the percentage of cartilage within the specimens.

Despite the myriad of studies on the effects of parathyroid hormone on various aspects of bone formation, there are very limited descriptions of the effect of PTH on spinal fusions.(see Table 2 for a results comparison from relevant animal spinal fusion studies^{4, 42-44}) Two groups have reported on the small, but positive, effects obtained from daily PTH administration in the rat posterolateral lumbar arthrodesis model.^{4, 42} These studies reported trends toward improvement in fusion success at late time points and significant differences between groups for serum osteocalcin. Abe et al. also reported time course observations for gene expression, CT bone morphometry and histology in the specimens, and showed PTH-dependent significant changes in multiple gene regulations, early spine fusion success, CT assessed microstructure and histology (mineral apposition rate and osteoclast surface apposition).⁴² In the present study we extend the observation of augmented spinal fusion success with daily PTH administration to rabbit posterolateral fusions: a comparative surgical model that more closely replicates the spinal fusion procedure performed in humans as regards operative technique and fusion/pseudarthrosis outcome.^{5, 15, 45}

In addition, we deliberately used a smaller amount of autologous bone graft material in the model which enabled a larger difference in fusion success to be demonstrated between the groups; this difference was found to be statistically significant. Also reported are the significant PTH-mediated inductions of fusion bone volume assessed by faxitron and CT, bone and cartilage production assessed by histology, and osteoclast and active

osteoblast numbers as assessed by immuno-histology and histomorphometry. In both the rat and rabbit posterolateral spine fusion models, PTH appears to augment bone and cartilage biology at multiple levels (gene regulation, cellular activation, and tissue representation) to positively affect fusion success.

Limitations to the current study include that although prior work has demonstrated that the rabbit posterolateral spinal fusion model is similar to human spinal fusions, the kinetics of rabbit spine fusions are much more rapid, and in the present study we did not perform the analyses in time course and thus do not know the effects at earlier, or much later time points.⁴⁶⁻⁵⁰ Our findings are based on analysis of x-ray, microCT and histological data at one time point, and using one method of PTH treatment.. Recent studies have shown that the anabolic effect of PTH plateaus over time⁵¹⁻⁵⁵ and that cyclic modes of administration are as effective as daily regimens in mice.⁵⁶ It has been shown that a cyclical PTH regimen (daily PTH for 3 months followed by 3 months without PTH in repetition) improved vertebral bone mineral density (BMD) to the same extent as daily PTH in osteoporotic women.⁵⁷ Future studies could include multiple time points to examine the effects of PTH in time course, and altered administration of PTH to assess the effect of the dosing regimen. Another limitation in studies using comparative models is that results may not translate directly to humans, despite the apparent success discussed and reported here in each

of the rat and rabbit models, respectively. Further work in larger comparative models and in studies designed to assess human safety and effectiveness will be required prior to recommending the use of PTH to augment spinal fusions.

Another important factor worth considering with regard to dose and administration is the risk of toxicity or side effects. The dose in this study (10mcg/kg) was calculated in consultation with the Lilly corporation and reviewing the literature for the typical dose used in other animal models.^{58, 59} While it has clearly been demonstrated that PTH treatment can enhance bone repair, the dosages used in many of the animal studies published to date (60 to 200 mg/kg/day) far exceed far exceed the recommended equivalent human dosage for similar conditions.⁶⁰ Nakajima et al. in 2002, utilized a dose of 10mcg/kg/day of PTH 1-34 in 72 two-month-old rats and observed an increase in bone mineral content, bone mineral density and ultimate load to failure of the healing bone compared with saline-treated controls.⁶¹ Alkhiary et al., studied 270 male rats who underwent a standard closed femoral fracture and were divided into three groups that were administered daily subcutaneous injections of 5 mcg/kg or 30 mcg/kg of PTH (1-34) or saline solution.⁶² By day 35, both groups treated with PTH showed significant increases in bone mineral content, bone mineral density and total osseous tissue volume. These studies demonstrate that at lower dosages

consistent with those approved for clinical use, PTH enhances bone repair in animal models

A link has been established in the literature to the development of osteosarcoma with prolonged administration of PTH in animal models.^{27, 63} Near lifetime studies in 344 Fischer rats demonstrated the development of osteosarcoma at exposure multiples of 3-58 of the recommended human dose (20 mcg/day).⁶⁴ In the first of these studies, tumors were observed in all treatment groups,²⁷. In a subsequent dosing and treatment duration study that was stratified by animal age at initiation, no bone tumors were evident at 3-fold the human dose in rats treated for 20 months, a duration constituting approximately 80% of the animals' estimated lifespan..⁶⁵ Tumor development, however, is not unique to PTH (1-34) as evidenced by a study on osteosarcoma development in rats treated with human PTH (1-84).⁶⁶ This study characterized the effects of chronic near lifetime exposure to recombinant human PTH (1-84) on the rat skeleton. A dose of 10 mcg/kg/day for 24 months significantly increased bone mass but did not increase the incidence of osteosarcoma or induce other neoplastic or non-neoplastic proliferative changes. A dose-related increase in osteosarcoma was observed with 50 and 150 mcg/kg/day dose of PTH (1-84) which translates to 27 and 66 times the recommended dose in humans

Since its first commercial launch in December 2002, Lilly has maintained a worldwide teriparatide 20 mcg/day safety monitoring program and has recently identified one confirmed case of osteosarcoma in a patient treated with teriparatide ('Forteo').⁶⁷ The patient was a post-menopausal woman in her 70s with a medical history which included osteoporosis with vertebral fractures. The patient was treated with Forteo in a manner consistent with the label. During her second year of Forteo therapy, she was found to have metastatic cancer with no primary cancer site identified. The initial clinical impression was lung cancer with metastases. The case was referred to a pathology consultant, whose differential diagnosis included several tumor types, including an osteosarcoma variant. Lilly submitted the biopsy materials to another bone pathology expert who diagnosed osteosarcoma. Causality between Forteo and the osteosarcoma in this patient cannot be established, taking into account this was a single case of >250,000 patients in the United States and >300,000 patients worldwide treated with Forteo, the patient had a complex medical history, and the background incidence of osteosarcoma in the general population of men and women greater than 60 years of age is 1 in 250,000 per year. The identification of this case does not change the risk/benefit profile for Forteo. Given the known incidence in the general population, very rare cases of osteosarcoma can be expected, irrespective of treatment with Forteo.

PTH (1-34) use, as a precaution, is contraindicated in patients with Paget's disease of bone or unexplained elevations of alkaline phosphatase, patients with a prior history of radiation to the skeleton, children or young adults with open epiphyses, or in patients with bone metastasis as per FDA guidelines.

The authors performed histological studies at the end of the six week period but not before or during this time. The studies performed at the end however did not reveal any cellular atypia, evidence of dysplasia or evidence of increased mitosis. There was no evidence or suggestion of osteosarcoma, however, the current study was not designed to establish the safety of the use of PTH as regards the potential for iatrogenic dysplasia or neoplasia.

The original cohort of 1943 patients treated with PTH (1-34) was followed for a mean period of 5 years to determine whether cardiovascular disease, diminished renal function, renal calculi, or vertebral fractures occurred with greater frequency after cessation of PTH (1-34). No discernible increase in any of these pathologies was identified.

There are case reports of unintended overdose where the entire content of the PTH (1-34) pen (up to 800mcg) has been inadvertently administered.⁶⁸ Subsequent to receiving an overdose, transient events have been reported including nausea, weakness/lethargy, and hypotension. In other cases, no

adverse events occurred as a result of the overdose. No fatalities associated with overdose have been reported.

The spectrum of adverse events in the wider community of clinical practice is similar to those observed in the phase III clinical trial, with the most frequent being light-headedness and leg cramps. These events have tended to be transient, not symptomatic, and have been managed by adjusting either calcium or vitamin D intake.⁶⁸ For rare persistent or marked elevations of plasma calcium, cessation of use has been suggested.

For clinical application in spine fusion, pertinent questions include matters of dose, duration and cost of PTH treatment. It is postulated by the authors that PTH has its principal effect within the first three months of treatment, but it is difficult to predict dose-effectiveness and cost in the absence of appropriate clinical trials. If a more conservative period of six months of treatment was used, with PTH purchased at current average monthly wholesale values (\$600-1,000), the added cost to the spinal fusion would be approximately equal to the costs generated with the two currently used biological fusion augmentation agents (bone morphogenetic proteins 2 and 7). Furthermore, use of a cyclical dosing regimen as discussed previously, could further reduce the cost of PTH administration, provided that clinical trials prove effectiveness in this dosing method. In regard to relative effectiveness, Tsiridis et al compared the use of BMP-7 (OP-1) and PTH in an animal

fracture healing model and showed that more bone was formed in animals administered PTH than those receiving OP-1.⁶⁹ However, in spine fusion, BMP has been shown to eliminate the need for autologous bone grafting whereas it is more accurate to say from our data that PTH is a valuable adjunct to bone autografting.⁷⁰⁻⁷³ Interestingly, Kabasawa et al. studying BMP-induced bone formation in aged rats found that daily PTH treatment led to rescue of BMP-mediated alkaline phosphate activity and mineral deposition.⁷⁴ This suggests that there may be a synergy for osteoinduction between PTH and the BMPs in aged rats, that is similar to the induction of BMP mRNAs (BMP-2, 4, 7) by daily PTH administration in young rats.⁴² If spinal fusions could be rapidly and reliably augmented with PTH, the need for internal fixation could potentially be reduced, as could the risk for pseudarthrosis and requirement for revision surgery. In addition, PTH could play an important role in those cases where there is a higher risk of non-union such as patients on corticosteroids, smokers and patients suffering from diabetes.

Parathyroid hormone (PTH) (1-34) is the only FDA-approved anti-osteoporotic agent with an anabolic capacity. There is still a great deal to learn from the use of PTH as a means to augment spinal fusions, including identification of the target cells mediating the response and quantifying fusion kinetics in the rabbit model, and determining the optimal dosing and administration regimen for clinical application. Further studies are warranted

to establish whether there is a limited window of opportunity following injury or surgery to achieve optimal results, and the duration of treatment required to optimize effectiveness. In conclusion, we have shown that intermittent PTH administration augmented the success of spine fusion as well as the quantity and quality of bone formation in the rabbit posterolateral spine fusion model.

Figure Legends

- Figure 1 Radiographic Grading (note that left and right scores are combined given their interdependence. Maximum score is thus ten) [C= control, P = PTH-treated]
- Figure 2 Bone – Von Kossa Stain. Calcified tissue stained black. Appearance of less bony tissue seen on the control slide (left)
- Figure 3 Histomorphometric analysis of samples prepared using the Von Kossa reaction. Three randomly selected high power microscopic fields were digitally quantified for each sample using computer-assisted image analysis, and the percentage of total sample area comprised by Von Kossa staining regions was obtained. Average values for each sample are reported. Control samples are represented by white bars, and PTH treated samples are represented by black bars.
- Figure 4 Cartilage – Alcian Blue stain. Cartilaginous tissue stained blue with visibly less cartilage seen on the control slide (left)
- Figure 5 Histomorphometric analysis of samples prepared with the cartilage selective. Alcian Blue stain. Three randomly selected high power microscopic fields were digitally quantified for each sample using computer-assisted image analysis, and the percentage of total sample area comprised by Alcian Blue staining tissue was obtained. . Average values for each sample are reported. Control samples are represented by

white bars, and PTH-treated specimens are represented by black bars.

Figure 6 Osteoclasts – Cathepsin-K stain. Control sample seen on the left with less osteoclasts visualized

Figure 7 Histomorphometric analysis of samples immunostained for the osteoclast specific marker Cathepsin-K. Average values are shown for total counts of positively stained cells present in three randomly selected high power fields (automated counting performed as described in Materials and Methods). Control samples are represented by white bars, and PTH-treated are represented by the black bars.

Figure 8 Osteoblasts – Procollagen 1 stain. Control sample seen on the left with fewer osteoblasts seen on the bone forming fronts

Figure 9 Histomorphometric analysis of samples immunostained for the osteoblast specific marker Procollagen-1. Active osteoblasts (identified as those in contact with osteoid) were quantified by obtaining linear measurements of positively staining cells along the cumulative length of all bone-forming fronts in a three random microscopic fields, as a ratio of all lines of bone formation in the microscopic field. The relative activity for osteoblasts in the microscopic field was then expressed as a ratio of the bone forming fronts containing osteoblasts to the total number of bone forming fronts (% Osteoblast line).

Average values are reported from each sample. Control samples are represented by white bars, and PTH-treated are represented by black bars.

Figure 10 Results comparison table of animal spinal fusion studies using parathyroid hormone or bisphosphonates.

References

1. Kitazawa R, Imai Y, Fukase M, Fujita T. Effects of continuous infusion of parathyroid hormone and parathyroid hormone-related peptide on rat bone in vivo: Comparative study by histomorphometry. *Bone Miner.* 1991;12:157-166.
2. Dempster DW, Cosman F, Kurland ES, et al. Effects of daily treatment with parathyroid hormone on bone microarchitecture and turnover in patients with osteoporosis: A paired biopsy study. *J Bone Miner Res.* 2001;16:1846-1853.
3. Rosol TJ, Capen CC, Horst RL. Effects of infusion of human parathyroid hormone-related protein-(1-40) in nude mice: Histomorphometric and biochemical investigations. *J Bone Miner Res.* 1988;3:699-706.
4. Lawrence JP, Ennis F, White AP, et al. Effect of daily parathyroid hormone (1-34) on lumbar fusion in a rat model. *Spine J.* 2006;6:385-390.
5. Boden SD, Schimandle JH, Hutton WC. An experimental lumbar intertransverse process spinal fusion model. radiographic, histologic, and biomechanical healing characteristics. *Spine.* 1995;20:412-420.
6. Hirano T, Burr DB, Turner CH, Sato M, Cain RL, Hock JM. Anabolic effects of human biosynthetic parathyroid hormone fragment (1-34), LY333334, on remodeling and mechanical properties of cortical bone in rabbits. *J Bone Miner Res.* 1999;14:536-545.

7. Mashiba T, Burr DB, Turner CH, Sato M, Cain RL, Hock JM. Effects of human parathyroid hormone (1-34), LY333334, on bone mass, remodeling, and mechanical properties of cortical bone during the first remodeling cycle in rabbits. *Bone*. 2001;28:538-547.
8. Frolik CA, Black EC, Cain RL, et al. Anabolic and catabolic bone effects of human parathyroid hormone (1-34) are predicted by duration of hormone exposure. *Bone*. 2003;33:372-379.
9. Codrons V, Vanderbist F, Ucakar B, Preat V, Vanbever R. Impact of formulation and methods of pulmonary delivery on absorption of parathyroid hormone (1-34) from rat lungs. *J Pharm Sci*. 2004;93:1241-1252.
10. Hu Z, Niu H, Yang X, Li H, Sang G, Li B. Recombinant human parathyroid hormone 1-34: Pharmacokinetics, tissue distribution and excretion in rats. *Int J Pharm*. 2006;317:144-154.
11. Jones KO, Owusu-Ababio G, Vick AM, Khan MA. Pharmacokinetics and hepatic extraction of recombinant human parathyroid hormone, hPTH (1-34), in rat, dog, and monkey. *J Pharm Sci*. 2006;95:2499-2506.
12. Rubin MR, Bilezikian JP. Parathyroid hormone as an anabolic skeletal therapy. *Drugs*. 2005;65:2481-2498.
13. Eriksen EF, Robins DA. Teriparatide: A bone formation treatment for osteoporosis. *Drugs Today (Barc)*. 2004;40:935-948.

14. Fraher LJ, Klein K, Marier R, et al. Comparison of the pharmacokinetics of parenteral parathyroid hormone-(1-34) [PTH-(1-34)] and PTH-related peptide-(1-34) in healthy young humans. *J Clin Endocrinol Metab.* 1995;80:60-64.
15. Boden SD, Schimandle JH, Hutton WC. Lumbar intertransverse-process spinal arthrodesis with use of a bovine bone-derived osteoinductive protein. A preliminary report. *J Bone Joint Surg Am.* 1995;77:1404-1417.
16. Boden SD, Martin GJ,Jr, Morone M, Ugbo JL, Titus L, Hutton WC. The use of coralline hydroxyapatite with bone marrow, autogenous bone graft, or osteoinductive bone protein extract for posterolateral lumbar spine fusion. *Spine.* 1999;24:320-327.
17. Martin GJ,Jr, Boden SD, Titus L, Scarborough NL. New formulations of demineralized bone matrix as a more effective graft alternative in experimental posterolateral lumbar spine arthrodesis. *Spine.* 1999;24:637-645.
18. Morone MA, Boden SD. Experimental posterolateral lumbar spinal fusion with a demineralized bone matrix gel. *Spine.* 1998;23:159-167.
19. Curylo LJ, Johnstone B, Petersilge CA, Janicki JA, Yoo JU. Augmentation of spinal arthrodesis with autologous bone marrow in a rabbit posterolateral spine fusion model. *Spine.* 1999;24:434-8; discussion 438-9.

20. Yee AJ, Bae HW, Friess D, Robbin M, Johnstone B, Yoo JU. Accuracy and interobserver agreement for determinations of rabbit posterolateral spinal fusion. *Spine*. 2004;29:1308-1313.
21. Andreassen TT, Cacciafesta V. Intermittent parathyroid hormone treatment enhances guided bone regeneration in rat calvarial bone defects. *J Craniofac Surg*. 2004;15:424-7; discussion 428-9.
22. Andreassen TT, Ejersted C, Oxlund H. Intermittent parathyroid hormone (1-34) treatment increases callus formation and mechanical strength of healing rat fractures. *J Bone Miner Res*. 1999;14:960-968.
23. Hock JM, Gera I. Effects of continuous and intermittent administration and inhibition of resorption on the anabolic response of bone to parathyroid hormone. *J Bone Miner Res*. 1992;7:65-72.
24. Misof BM, Roschger P, Cosman F, et al. Effects of intermittent parathyroid hormone administration on bone mineralization density in iliac crest biopsies from patients with osteoporosis: A paired study before and after treatment. *J Clin Endocrinol Metab*. 2003;88:1150-1156.
25. Mitlak BH, Williams DC, Bryant HU, Paul DC, Neer RM. Intermittent administration of bovine PTH-(1-34) increases serum 1,25-dihydroxyvitamin D concentrations and spinal bone density in senile (23 month) rats. *J Bone Miner Res*. 1992;7:479-484.

26. Nakazawa T, Nakajima A, Shiomi K, Moriya H, Einhorn TA, Yamazaki M. Effects of low-dose, intermittent treatment with recombinant human parathyroid hormone (1-34) on chondrogenesis in a model of experimental fracture healing. *Bone*. 2005;37:711-719.
27. Vahle JL, Sato M, Long GG, et al. Skeletal changes in rats given daily subcutaneous injections of recombinant human parathyroid hormone (1-34) for 2 years and relevance to human safety. *Toxicol Pathol*. 2002;30:312-321.
28. Andreassen TT, Fledelius C, Ejersted C, Oxlund H. Increases in callus formation and mechanical strength of healing fractures in old rats treated with parathyroid hormone. *Acta Orthop Scand*. 2001;72:304-307.
29. Bilezikian JP, Rubin MR, Finkelstein JS. Parathyroid hormone as an anabolic therapy for women and men. *J Endocrinol Invest*. 2005;28:41-49.
30. Cranney A, Papaioannou A, Zytaruk N, et al. Parathyroid hormone for the treatment of osteoporosis: A systematic review. *CMAJ*. 2006;175:52-59.
31. Dempster DW, Cosman F, Parisien M, Shen V, Lindsay R. Anabolic actions of parathyroid hormone on bone. *Endocr Rev*. 1993;14:690-709.
32. Ejersted C, Andreassen TT, Hauge EM, Melsen F, Oxlund H. Parathyroid hormone (1-34) increases vertebral bone mass, compressive strength, and quality in old rats. *Bone*. 1995;17:507-511.

33. Holzer G, Majeska RJ, Lundy MW, Hartke JR, Einhorn TA. Parathyroid hormone enhances fracture healing. A preliminary report. *Clin Orthop Relat Res.* 1999;(366):258-263.
34. Jilka RL, Weinstein RS, Bellido T, Roberson P, Parfitt AM, Manolagas SC. Increased bone formation by prevention of osteoblast apoptosis with parathyroid hormone. *J Clin Invest.* 1999;104:439-446.
35. Miyakoshi N. Effects of parathyroid hormone on cancellous bone mass and structure in osteoporosis. *Curr Pharm Des.* 2004;10:2615-2627.
36. Oxlund H, Ejersted C, Andreassen TT, Topping O, Nilsson MH. Parathyroid hormone (1-34) and (1-84) stimulate cortical bone formation both from periosteum and endosteum. *Calcif Tissue Int.* 1993;53:394-399.
37. Rubin MR, Bilezikian JP. Parathyroid hormone as an anabolic skeletal therapy. *Drugs.* 2005;65:2481-2498.
38. Rubin MR, Bilezikian JP. New anabolic therapies in osteoporosis. *Endocrinol Metab Clin North Am.* 2003;32:285-307.
39. Rubin MR, Cosman F, Lindsay R, Bilezikian JP. The anabolic effects of parathyroid hormone. *Osteoporos Int.* 2002;13:267-277.
40. Skripitz R, Andreassen TT, Aspenberg P. Strong effect of PTH (1-34) on regenerating bone: A time sequence study in rats. *Acta Orthop Scand.* 2000;71:619-624.

41. Andreassen TT, Willick GE, Morley P, Whitfield JF. Treatment with parathyroid hormone hPTH(1-34), hPTH(1-31), and monocyclic hPTH(1-31) enhances fracture strength and callus amount after withdrawal fracture strength and callus mechanical quality continue to increase. *Calcif Tissue Int.* 2004;74:351-356.
42. Abe Y, Takahata M, Ito M, Irie K, Abumi K, Minami A. Enhancement of graft bone healing by intermittent administration of human parathyroid hormone (1-34) in a rat spinal arthrodesis model. *Bone.* 2007;41:775-785.
43. Huang RC, Khan SN, Sandhu HS, et al. Alendronate inhibits spine fusion in a rat model. *Spine.* 2005;30:2516-2522.
44. Sama AA, Khan SN, Myers ER, et al. High-dose alendronate uncouples osteoclast and osteoblast function: A study in a rat spine pseudarthrosis model. *Clin Orthop Relat Res.* 2004;(425):135-142.
45. Schimandle JH, Boden SD. Spine update. the use of animal models to study spinal fusion. *Spine.* 1994;19:1998-2006.
46. Wolf JW, Jr, White AA, 3rd, Panjabi MM, Southwick WO. Comparison of cyclic loading versus constant compression in the treatment of long-bone fractures in rabbits. *J Bone Joint Surg Am.* 1981;63:805-810.
47. Panjabi MM, White AA, 3rd, Wolf JW, Jr. A biomechanical comparison of the effects of constant and cyclic compression on fracture healing in rabbit long bones. *Acta Orthop Scand.* 1979;50:653-661.

48. Panjabi MM, White AA,3rd, Southwick WO. Temporal changes in the physical properties of healing fractures in rabbits. *J Biomech.* 1977;10:689-699.
49. FriedenberG ZB, Roberts PG,Jr, Didizian NH, Brighton CT. Stimulation of fracture healing by direct current in the rabbit fibula. *J Bone Joint Surg Am.* 1971;53:1400-1408.
50. Brighton CT, Krebs AG. Oxygen tension of healing fractures in the rabbit. *J Bone Joint Surg Am.* 1972;54:323-332.
51. Zhou H, lida-Klein A, Lu SS, et al. Anabolic action of parathyroid hormone on cortical and cancellous bone differs between axial and appendicular skeletal sites in mice. *Bone.* 2003;32:513-520.
52. lida-Klein A, Zhou H, Lu SS, et al. Anabolic action of parathyroid hormone is skeletal site specific at the tissue and cellular levels in mice. *J Bone Miner Res.* 2002;17:808-816.
53. Finkelstein JS, Hayes A, Hunzelman JL, Wyland JJ, Lee H, Neer RM. The effects of parathyroid hormone, alendronate, or both in men with osteoporosis. *N Engl J Med.* 2003;349:1216-1226.
54. Cosman F, Nieves J, Woelfert L, et al. Parathyroid hormone added to established hormone therapy: Effects on vertebral fracture and maintenance of bone mass after parathyroid hormone withdrawal. *J Bone Miner Res.* 2001;16:925-931.

55. Lindsay R, Nieves J, Formica C, et al. Randomised controlled study of effect of parathyroid hormone on vertebral-bone mass and fracture incidence among postmenopausal women on oestrogen with osteoporosis. *Lancet*. 1997;350:550-555.
56. Iida-Klein A, Lu SS, Cosman F, Lindsay R, Dempster DW. Effects of cyclic vs. daily treatment with human parathyroid hormone (1-34) on murine bone structure and cellular activity. *Bone*. 2007;40:391-398.
57. Cosman F, Nieves J, Zion M, Woelfert L, Luckey M, Lindsay R. Daily and cyclic parathyroid hormone in women receiving alendronate. *N Engl J Med*. 2005;353:566-575.
58. Skripitz R, Andreassen TT, Aspenberg P. Parathyroid hormone (1-34) increases the density of rat cancellous bone in a bone chamber. A dose-response study. *J Bone Joint Surg Br*. 2000;82:138-141.
59. Seebach C, Skripitz R, Andreassen TT, Aspenberg P. Intermittent parathyroid hormone (1-34) enhances mechanical strength and density of new bone after distraction osteogenesis in rats. *J Orthop Res*. 2004;22:472-478.
60. Barnes GL, Kakar S, Vora S, Morgan EF, Gerstenfeld LC, Einhorn TA. Stimulation of fracture-healing with systemic intermittent parathyroid hormone treatment. *J Bone Joint Surg Am*. 2008;90 Suppl 1:120-127.

61. Nakajima A, Shimoji N, Shiomi K, et al. Mechanisms for the enhancement of fracture healing in rats treated with intermittent low-dose human parathyroid hormone (1-34). *J Bone Miner Res.* 2002;17:2038-2047.
62. Alkhiary YM, Gerstenfeld LC, Krall E, et al. Enhancement of experimental fracture-healing by systemic administration of recombinant human parathyroid hormone (PTH 1-34). *J Bone Joint Surg Am.* 2005;87:731-741.
63. Sato M, Vahle J, Schmidt A, et al. Abnormal bone architecture and biomechanical properties with near-lifetime treatment of rats with PTH. *Endocrinology.* 2002;143:3230-3242.
64. Tashjian AH,Jr, Chabner BA. Commentary on clinical safety of recombinant human parathyroid hormone 1-34 in the treatment of osteoporosis in men and postmenopausal women. *J Bone Miner Res.* 2002;17:1151-1161.
65. Vahle JL, Long GG, Sandusky G, Westmore M, Ma YL, Sato M. Bone neoplasms in F344 rats given teriparatide [rhPTH(1-34)] are dependent on duration of treatment and dose. *Toxicol Pathol.* 2004;32:426-438.
66. Jolette J, Wilker CE, Smith SY, et al. Defining a noncarcinogenic dose of recombinant human parathyroid hormone 1-84 in a 2-year study in fischer 344 rats. *Toxicol Pathol.* 2006;34:929-940.

67. Harper KD, Krege JH, Marcus R, Mitlak BH. Osteosarcoma and teriparatide? *J Bone Miner Res.* 2007;22:334.
68. Tashjian AH, Jr, Gagel RF. Teriparatide [human PTH(1-34)]: 2.5 years of experience on the use and safety of the drug for the treatment of osteoporosis. *J Bone Miner Res.* 2006;21:354-365.
69. Tsiridis E, Morgan EF, Bancroft JM, et al. Effects of OP-1 and PTH in a new experimental model for the study of metaphyseal bone healing. *J Orthop Res.* 2007.
70. Vaccaro AR, Whang PG, Patel T, et al. The safety and efficacy of OP-1 (rhBMP-7) as a replacement for iliac crest autograft for posterolateral lumbar arthrodesis: Minimum 4-year follow-up of a pilot study. *Spine J.* 2007.
71. Dimar JR, Glassman SD, Burkus KJ, Carreon LY. Clinical outcomes and fusion success at 2 years of single-level instrumented posterolateral fusions with recombinant human bone morphogenetic protein-2/compression resistant matrix versus iliac crest bone graft. *Spine.* 2006;31:2534-9; discussion 2540.
72. Kanayama M, Hashimoto T, Shigenobu K, Yamane S, Bauer TW, Togawa D. A prospective randomized study of posterolateral lumbar fusion using osteogenic protein-1 (OP-1) versus local autograft with ceramic bone substitute: Emphasis of surgical exploration and histologic assessment. *Spine.* 2006;31:1067-1074.

73. Szpalski M, Gunzburg R. Recombinant human bone morphogenetic protein-2: A novel osteoinductive alternative to autogenous bone graft? *Acta Orthop Belg.* 2005;71:133-148.

74. Kabasawa Y, Asahina I, Gunji A, Omura K. Administration of parathyroid hormone, prostaglandin E2, or 1-alpha,25-dihydroxyvitamin D3 restores the bone inductive activity of rhBMP-2 in aged rats. *DNA Cell Biol.* 2003;22:541-546.

Radiographic Union Grading

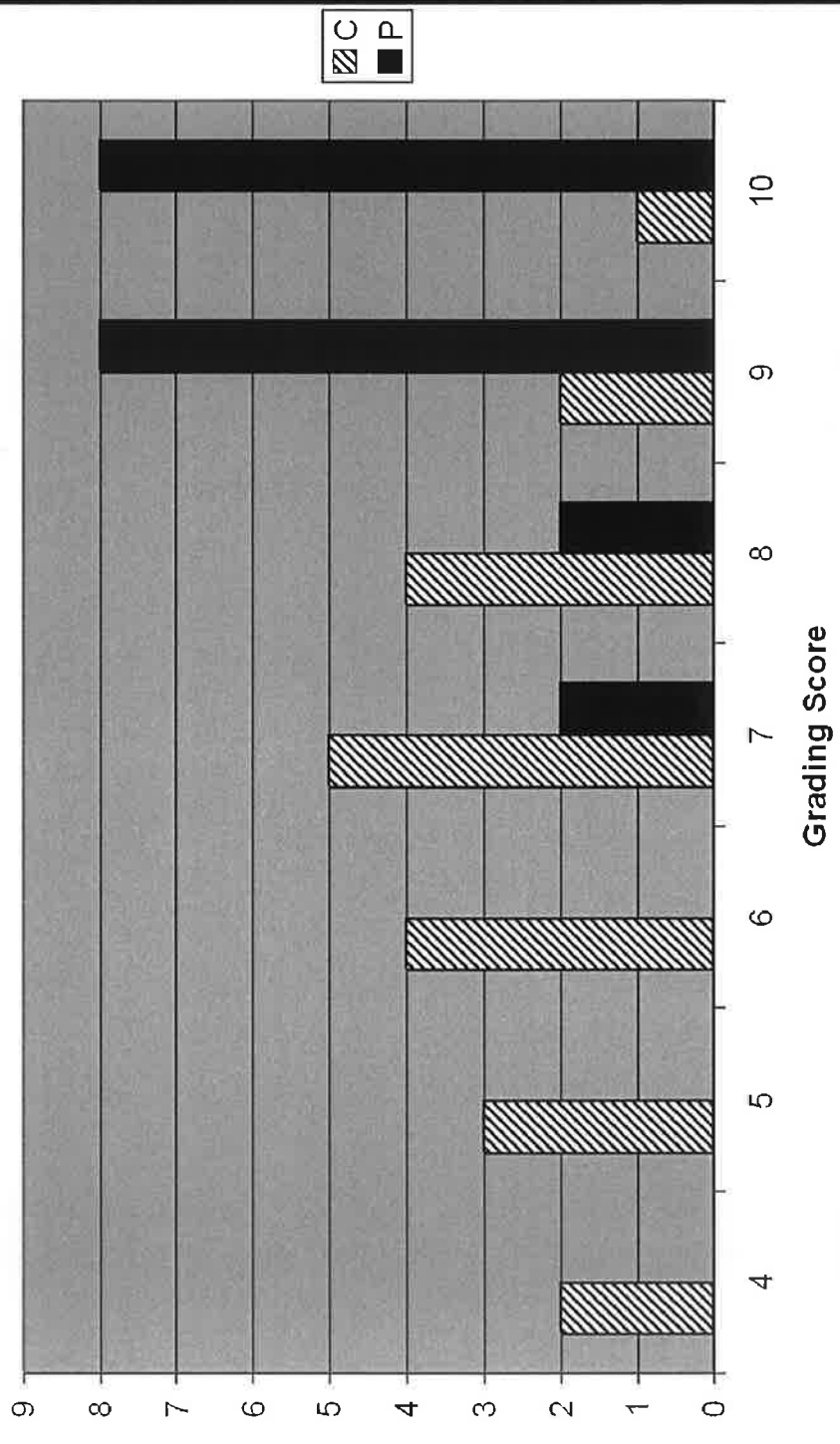


Figure 1

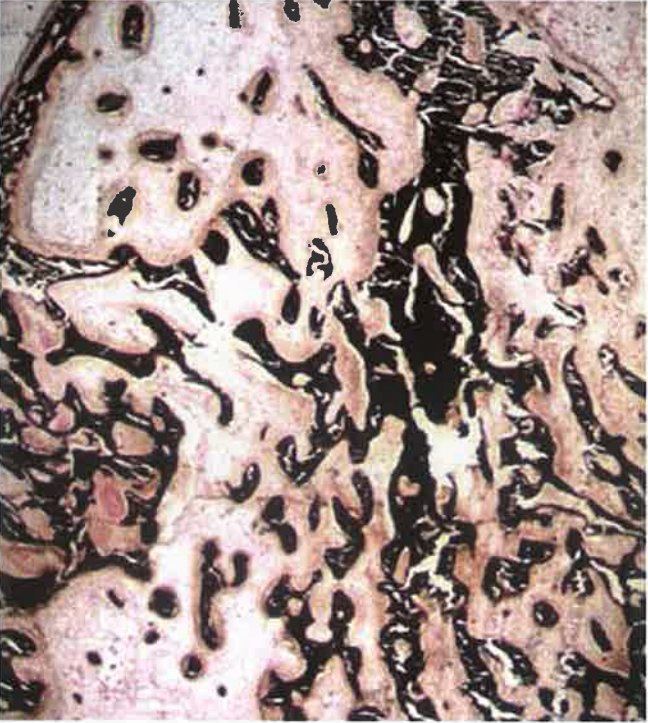

Figure 2

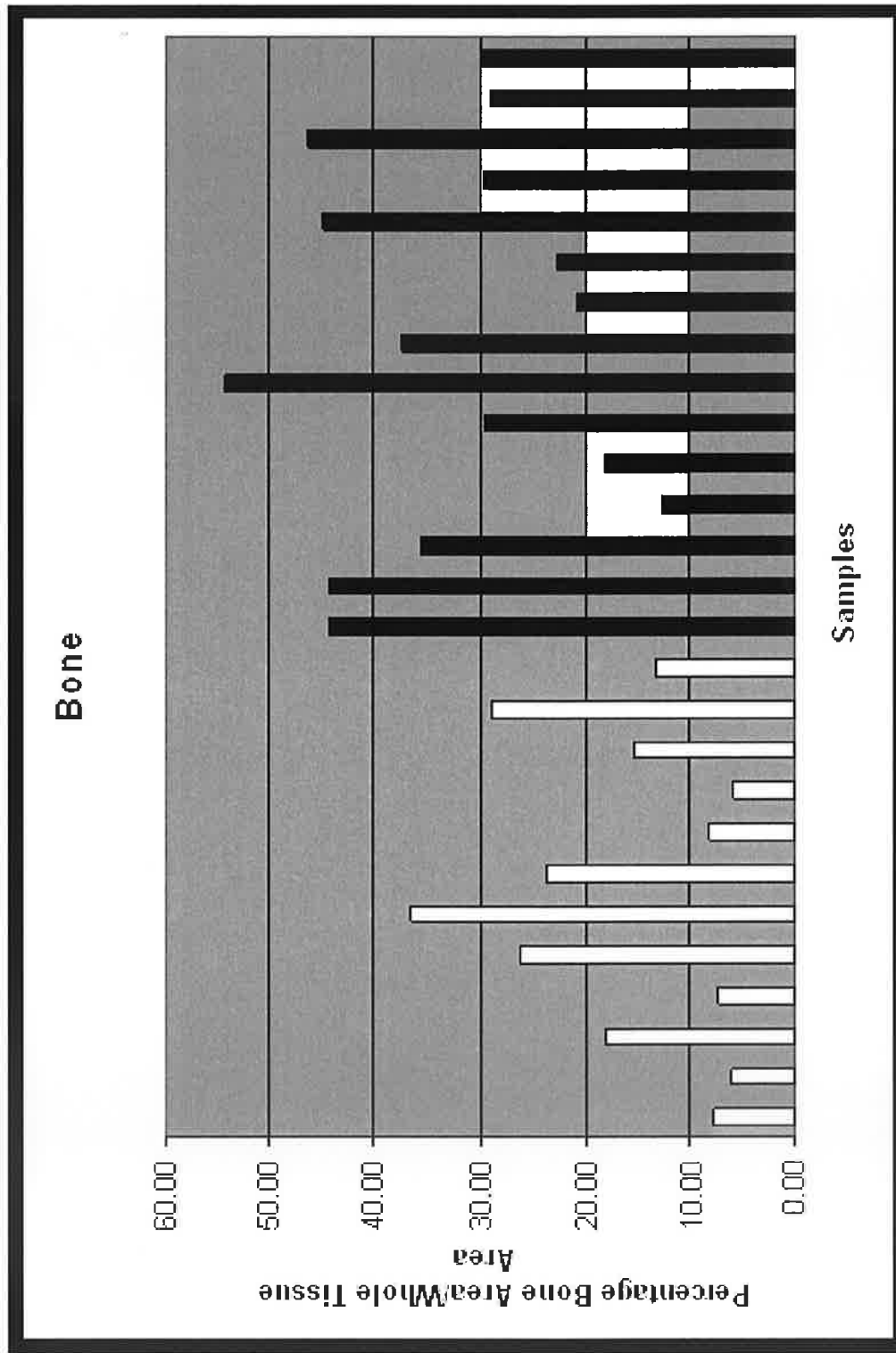


Figure 3

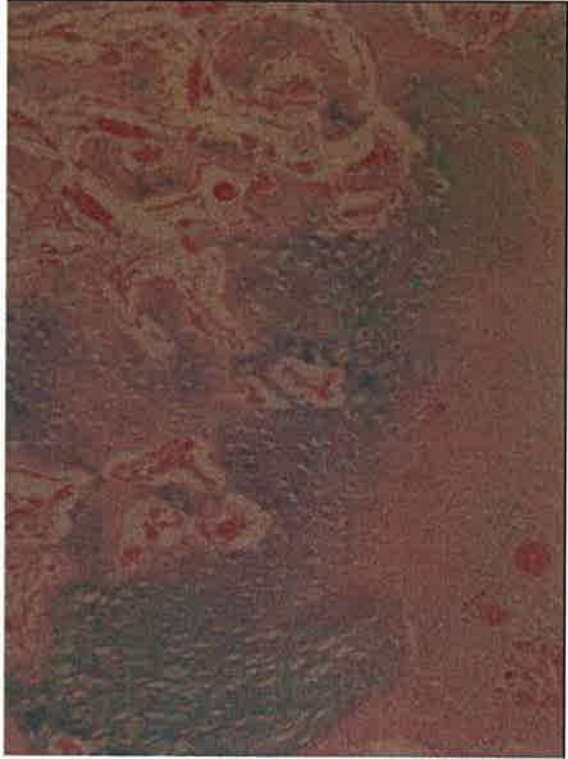


Figure 4

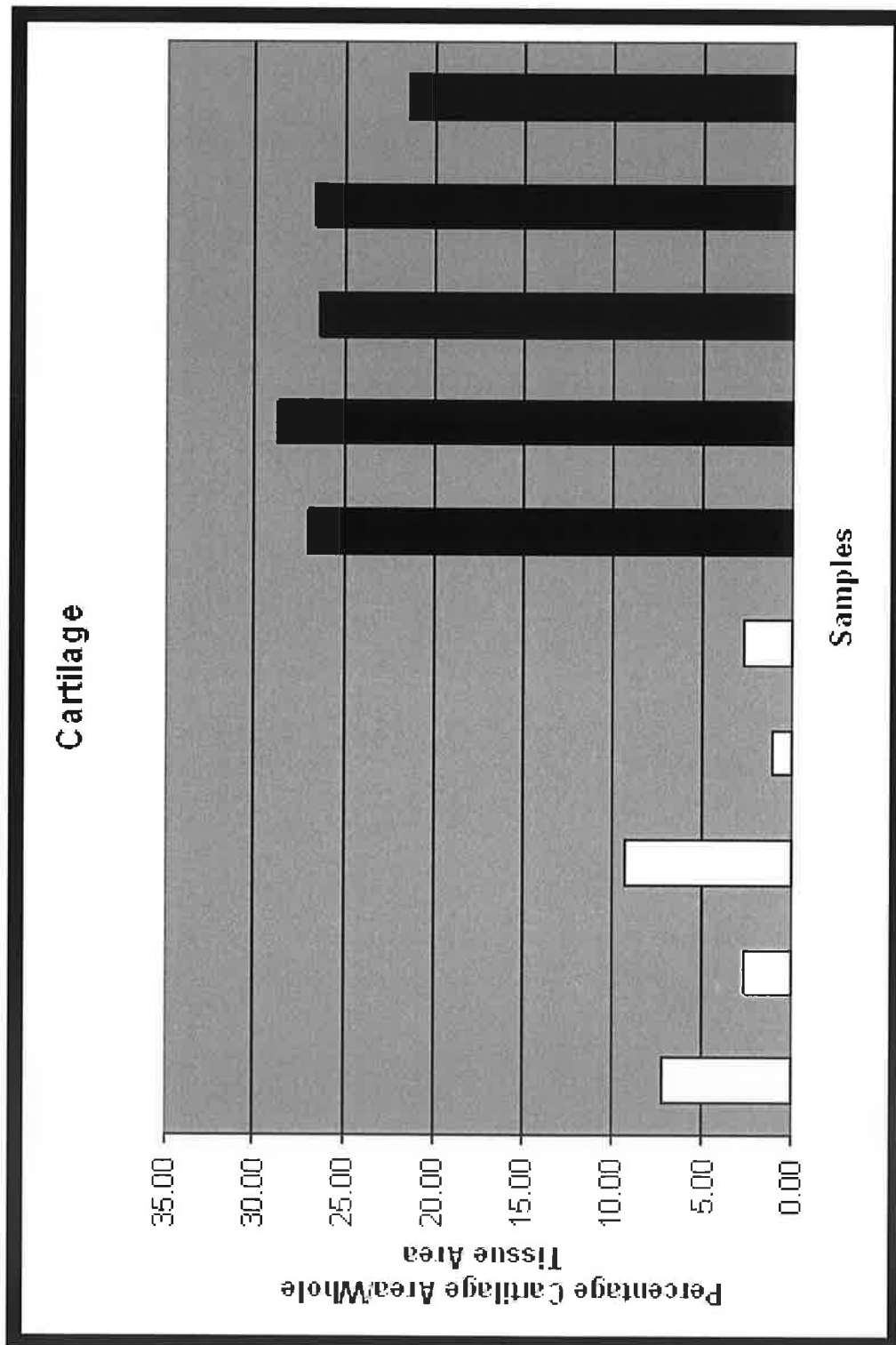


Figure 5

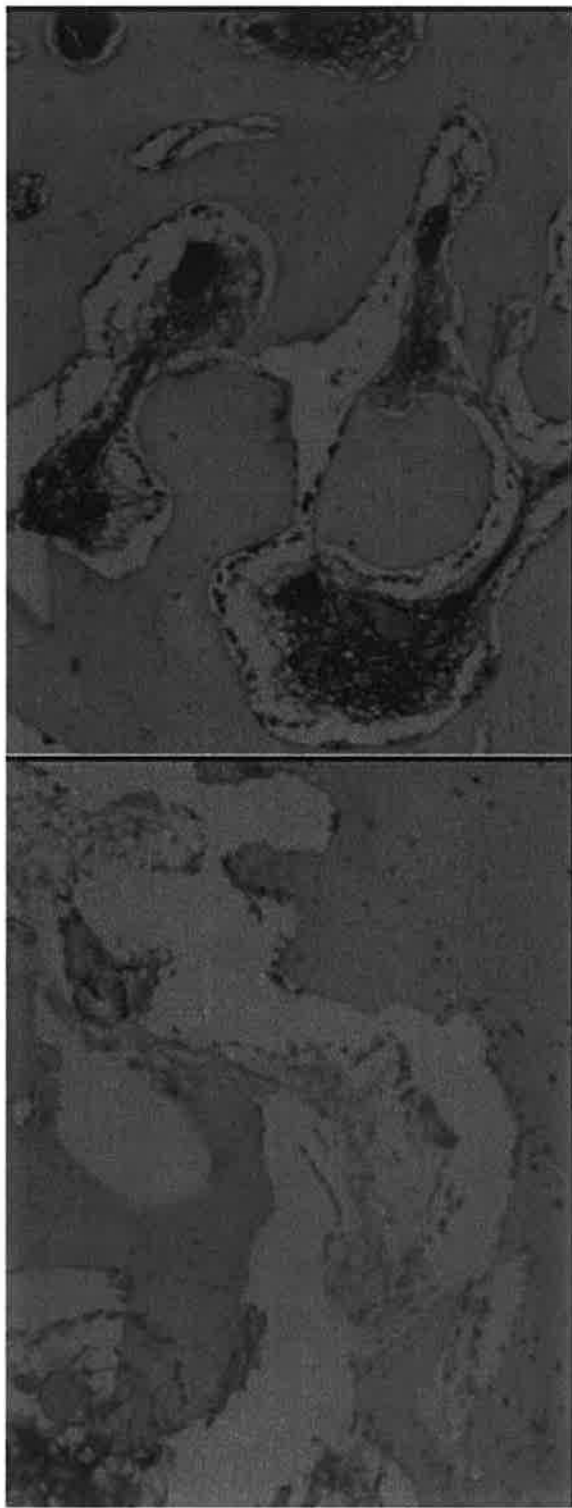


Figure 6

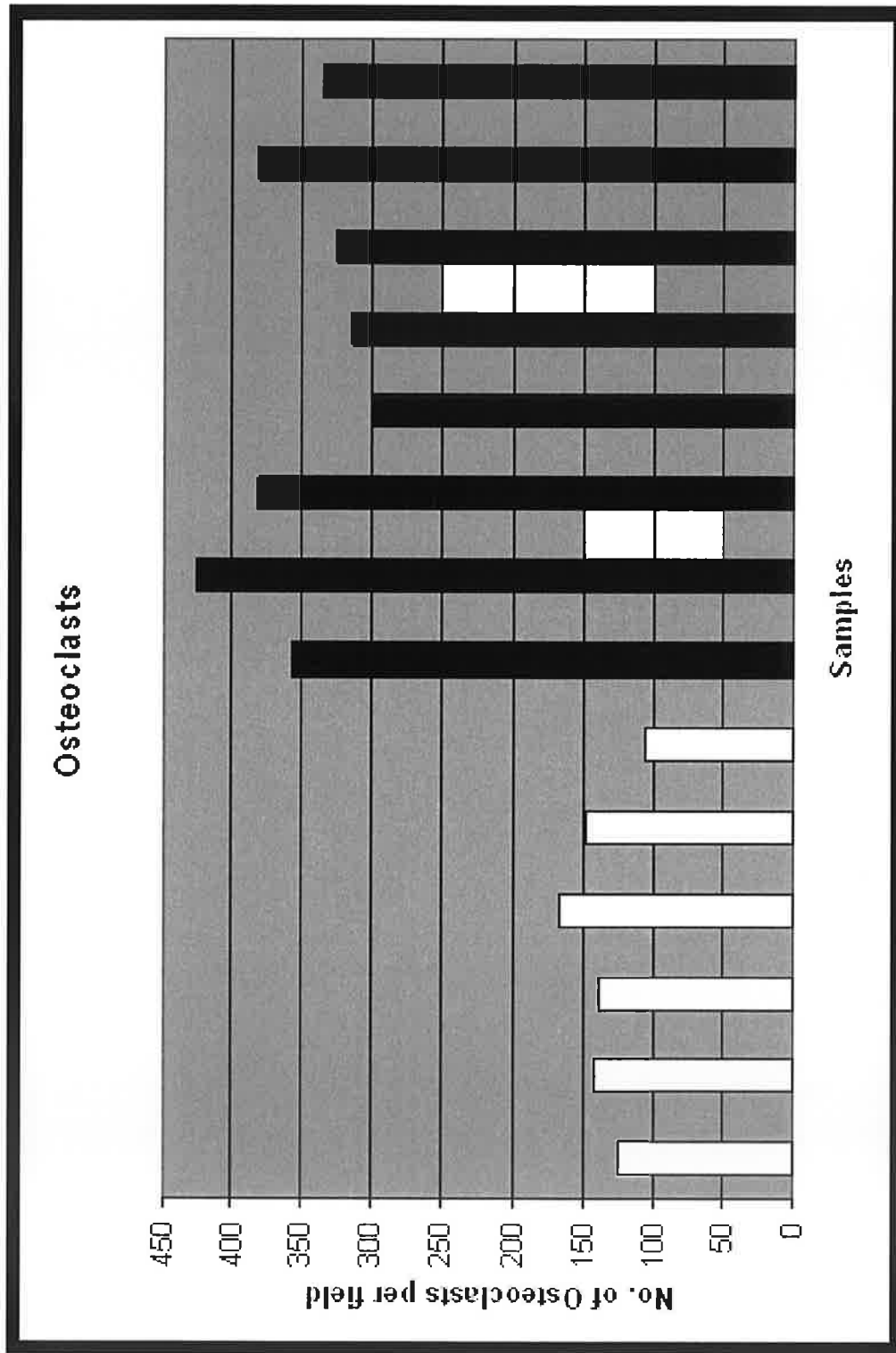


Figure 7

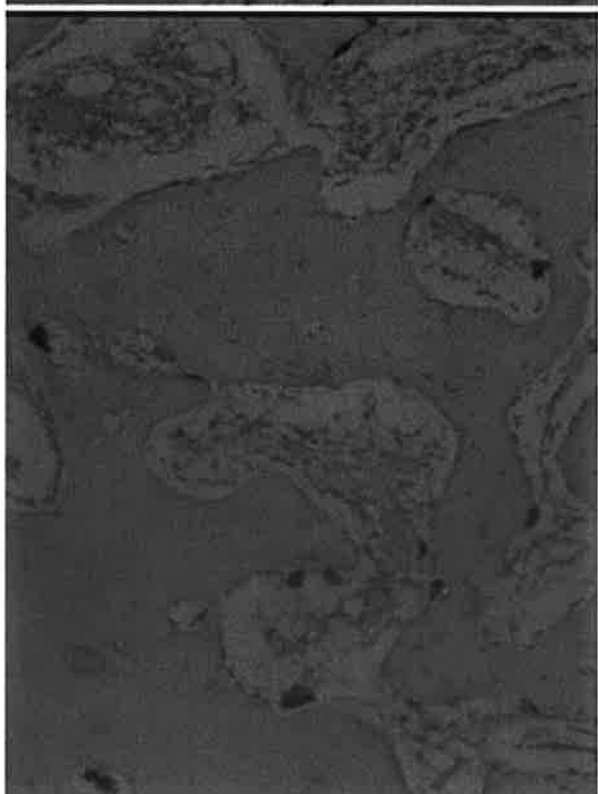
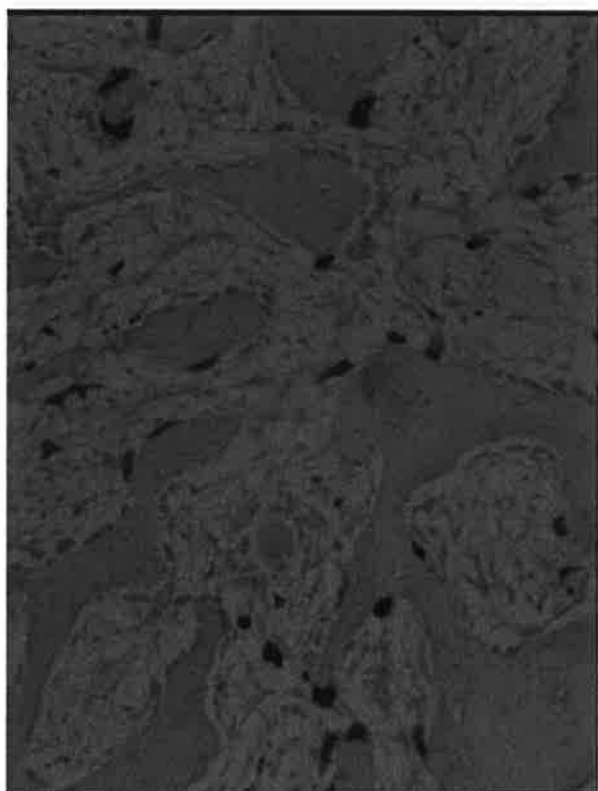


Figure 8

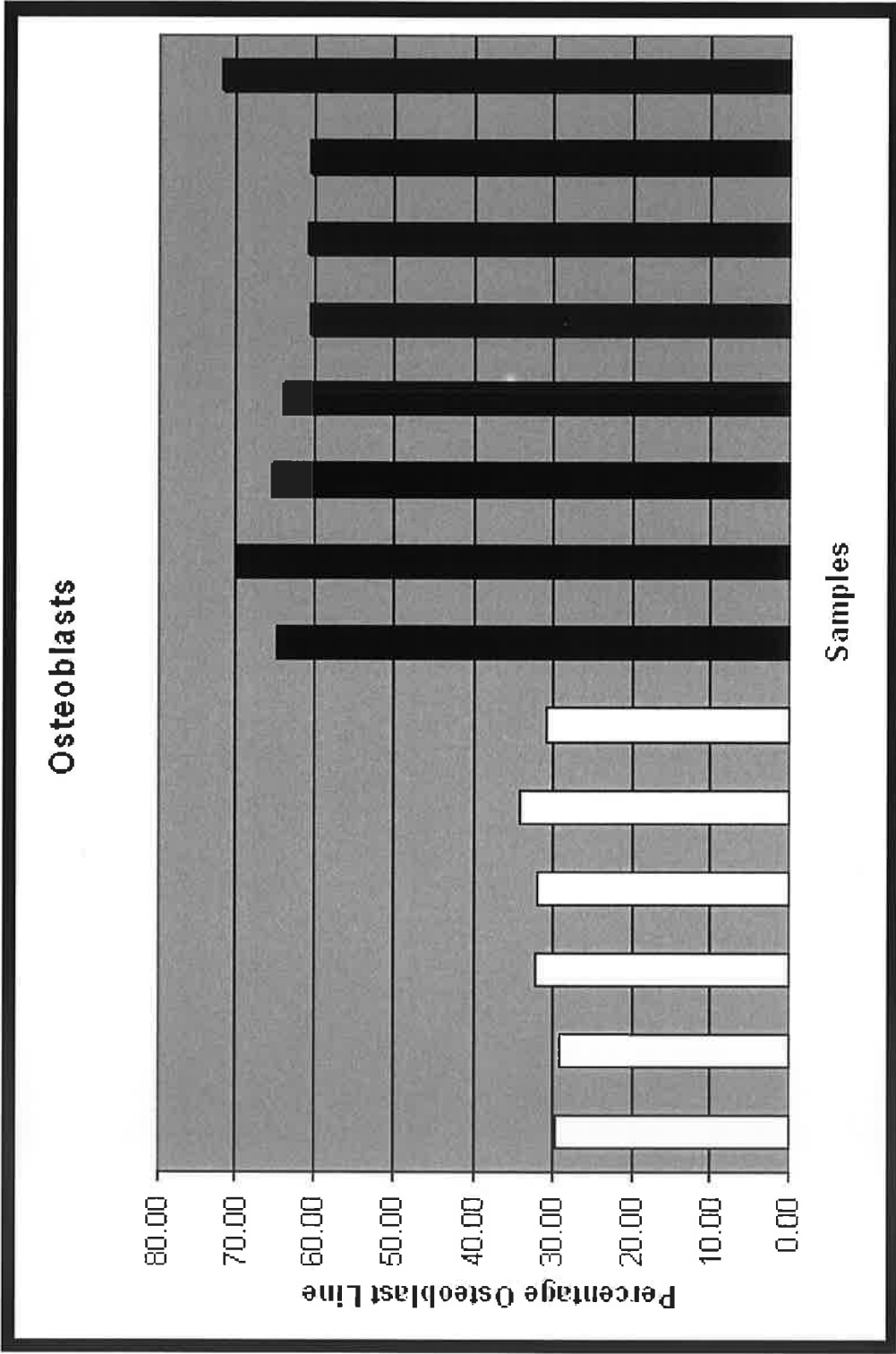


Figure 9

Study	Treatment	Spinal Fusion Rate		Fusion Mass		Histology	
		Control	Treated	Control	Treated	Control	Treated
Abe et al., 2007 ⁴² (Rat Model)	PTH (1-34)	14% @ 14 days 86% @ 28 days 86% @ 42 days	57% @ 14 days 100% @ 28 days 100% @ 42 days	Bone vol./ Tissue vol. 19.1 % (+/- 1.9)	Bone vol./ Tissue vol. 47.8 % (+/- 3.3)	Mineralized Surface/Bone Surface 54.6 % (+/- 1.7) @ 28 days 51.5 % (+/- 1.6) @ 42 days	Mineralized Surface/Bone Surface Day 28 64.4 % (+/- 0.8) @ 28 days Day 42 62.4 % (+/- 1.1) a
Lawrence et al., 2006 ⁴ (Rat Model)	PTH (1-34)	37% @ 42 days	52% @ 42 days			Serum Osteocalcin Levels 59.8 ng/L (+/- 12.4)	Serum Osteocalcin Levels 88.57 ng/L (+/- 17.27)
Huang et al., 2005 ⁴³ (Rat Model)	Alendronate	95% (19/20)	<u>Low dose</u> (5 mcg/kg/day) 50 % (12/24), <u>High dose</u> (50 mcg/kg/day) 40% (10/25)	Optical Density 100 (normalized value) Fusion Mass Area 100 (normalized value)	Optical Density <u>Low dose</u> (5 mcg/kg/day) 438 <u>High dose</u> (50 mcg/kg/day) 488 Fusion Mass Area <u>Low dose</u> (5 mcg/kg/day) 186 <u>High dose</u> (50 mcg/kg/day) 211	% Bone Element Area 48.8% % Marrow Element Area 13.3%	% Bone Element Area <u>Low dose</u> (5 mcg/kg/day) 50.9% <u>High dose</u> (50 mcg/kg/day) 8.6% % Marrow Element Area <u>Low dose</u> (5 mcg/kg/day) 54.5% <u>High dose</u> (50 mcg/kg/day) 6.8%
Sama et al., 2004 ⁴⁴ (Rat Model)	Alendronate	0% @ 14 days 50% @ 28 days 43% @ 42 days	<u>Low dose</u> (1mcg/kg/week) 29% @ 14 days 33% @ 28 days 43% @ 42 days <u>High dose</u> (10mcg/kg/week) 0% @ 14 days 0% @ 28 days 0% @ 42 days	% Bone Area* 76% @ 14 days 60% @ 28 days 55% @ 42 days	% Bone Area* <u>Low dose</u> (1mcg/kg/week) 78% @ 14 days 62% @ 28 days 63% @ 42 days <u>High dose</u> (10mcg/kg/week) @ 14 days @ 28 days @ 42 days	Osteoclasts Per Field* <u>Low dose</u> (1mcg/kg/week) 12 @ 14 days 4 @ 28 days Osteoblasts per Bone Surface* (%) <u>High dose</u> (10mcg/kg/week) 1.75 @ 14 days 2 @ 28 days 1.75 @ 42 days Osteoblasts per Bone Surface (%)* <u>Low dose</u> (1mcg/kg/week) 26% @ 14 days 38% @ 28 days 32% @ 42 days <u>High dose</u> (10mcg/kg/week) 14% @ 14 days 15% @ 28 days 12% @ 42 days	Osteoclasts Per Field* <u>Low dose</u> (1mcg/kg/week) 12 @ 14 days 4 @ 28 days 2.25 @ 42 days <u>High dose</u> (10mcg/kg/week) 1.75 @ 14 days 2 @ 28 days 1.75 @ 42 days Osteoblasts per Bone Surface (%)* <u>Low dose</u> (1mcg/kg/week) 26% @ 14 days 38% @ 28 days 32% @ 42 days <u>High dose</u> (10mcg/kg/week) 14% @ 14 days 15% @ 28 days 12% @ 42 days

Figure 10