



All Theses and Dissertations

---

2008-09-10

# The Claustrum in Autism and Typically Developing Male Children: A Quantitative MRI Study

Warren B. Davis

*Brigham Young University - Provo*

Follow this and additional works at: <https://scholarsarchive.byu.edu/etd>



Part of the [Psychology Commons](#)

---

## BYU ScholarsArchive Citation

Davis, Warren B., "The Claustrum in Autism and Typically Developing Male Children: A Quantitative MRI Study" (2008). *All Theses and Dissertations*. 1892.

<https://scholarsarchive.byu.edu/etd/1892>

This Thesis is brought to you for free and open access by BYU ScholarsArchive. It has been accepted for inclusion in All Theses and Dissertations by an authorized administrator of BYU ScholarsArchive. For more information, please contact [scholarsarchive@byu.edu](mailto:scholarsarchive@byu.edu), [ellen\\_amatangelo@byu.edu](mailto:ellen_amatangelo@byu.edu).

THE CLAUSTRUM IN AUTISM AND TYPICALLY DEVELOPING  
MALE CHILDREN: A QUANTITATIVE MRI STUDY

by

Warren B. Davis

A thesis submitted to the faculty of

Brigham Young University

Master of Science

Department of Psychology

Brigham Young University

December 2008

Copyright © 2008 Warren Davis

All Rights Reserved

BRIGHAM YOUNG UNIVERSITY

GRADUATE COMMITTEE APPROVAL

Warren B. Davis

This thesis has been read by each member of the following graduate committee and by majority vote has been found to be satisfactory.

---

Date

---

Erin D. Bieler, Chair

---

Date

---

Ross Flom

---

Date

---

Mark Allen

BRIGHAM YOUNG UNIVERSITY

As chair of the candidate's graduate committee, I have read the thesis of Warren Davis in its final form and have found that (1) its format, citations, and bibliographical style are consistent and acceptable and fulfill university and department style requirements; (2) its illustrative materials including figures, tables, and charts are in place; and (3) the final manuscript is satisfactory to the graduate committee and is ready for submission to the university library.

---

Date

---

Erin D. Bigler

Chair, Graduate Committee

Accepted for the Department

---

Date

---

Harold L. Miller, Jr

Graduate Coordinator, Psychology

Accepted for the College

---

Date

---

Susan Rugh

Associate Dean, College of Family, Home and  
Social Sciences

## ABSTRACT

### THE CLAUSTRUM IN AUTISM AND TYPICALLY DEVELOPING MALE CHILDREN: A QUANTITATIVE MRI STUDY

Warren B. Davis

Department of Psychology

Master of Science

The claustrum (Cl) is a subcortical gray-matter structure housed between the external capsule medially and the extreme capsule laterally. Due to its extensive reciprocal connections throughout the brain, it has been implicated in consciousness and other higher order functions including linking behavior and emotion. Such linkage may be important in understanding the neurobiology of autism since other cortical and subcortical regions including the spatially and ontologically related basal ganglia, as well as limbic structures, have been implicated in the disorder.

Participants were males with autism (n=16) and typically developing (TD; n=14) matched for head circumference and age. The Cl and other structures were

significant differences in the right claustrum ( $p=.014$ ), left claustrum ( $p = .041$ ), right total claustrum ( $p = .018$ ) and left total claustrum ( $p=.044$ ). Right CI volume was found to be significantly larger than left within each of the groups (Autism,  $p=.021$ ; TD,  $p=.033$ ).

These preliminary results demonstrate that the CI can be consistently identified in vivo using ROI tracing with apparent right-versus-left asymmetry documented. Smaller claustral volumes in autism support theories of a disconnect in long-range circuitry associated with autism.

## ACKNOWLEDGEMENTS

I would like to acknowledge: the advice, direction, encouragement and enthusiasm of my mentor Dr. Erin D. Bigler; Tracy Abildskov for his technical prowess and willingness to help even when bombarded with other tasks; Joanne Petrie for her general advice and help in formatting; Drs. Mark Ashley and Richard Helvie who first got me interested in neuroimaging, were role models of passionate, caring individuals, and gave me the opportunity as an inexperienced newbie to be a part of their team; Karen Christensen and others in the graduate office who put in extra time and effort to help me get everything done in time; Dr. Ross Flom for his advice, flexibility, and friendship; Jason Dorais for his help in tracing, positive attitude, and adventure seeking. I would also like to acknowledge the prayers and support of my parents, Brad and Ruth, as well as other family members: Cordell, Katie, Eve, Michael, Laura, and Clayton – who helped get everything finalized.



|  |    |
|--|----|
| INTRODUCTION .....   | 1  |
| NEUROANATOMY .....   | 4  |
| ONTOGENY .....   | 5  |
| CELL TYPES .....   | 6  |
| PHYSIOLOGICAL CONSIDERATIONS: LESION AND STIMULATION STUDIES ..... | 7  |
| CONNECTIONS BETWEEN THE CORTEX AND CLAUSTRUM.....                  | 9  |
| CLAUSTRAL FUNCTION.....  | 11 |
| AUTISM .....   | 12 |
| QUANTITATIVE NEUROIMAGING: ROI VOLUMETRIC METHODS .....            | 14 |
| PURPOSE AND RATIONALE OF STUDY .....                               | 15 |
| HYPOTHESIS .....   | 16 |
| METHODS.....   | 17 |
| PARTICIPANTS .....   | 17 |
| Autism diagnosis.....  | 17 |
| MAGNETIC RESONANCE IMAGING (MRI) .....                             | 18 |
| MRI acquisition.....   | 18 |
| IMAGE ANALYSIS .....   | 18 |
| ROI tracing.....   | 18 |
| Test-retest reproducibility .....                                  | 19 |
| STATISTICAL ANALYSIS.....  | 19 |
| Quantitative MRI .....   | 19 |
| RESULTS.....   | 21 |
| DISCUSSION .....   | 23 |
| UNDERCONNECTIVITY IN AUTISM .....                                  | 25 |
| SENSORY INTEGRATION.....   | 26 |
| DEVELOPMENTAL COURSE OF AUTISM AND THE CLAUSTRUM .....             | 28 |
| STUDY LIMITATIONS .....  | 29 |
| CONCLUSION .....   | 32 |
| REFERENCES .....   | 33 |
| APPENDIX A: CLAUSTRUM TRACING PROTOCOL.....                        | 47 |
| APPENDIX B: DATA AND STATISTICS.....                               | 59 |

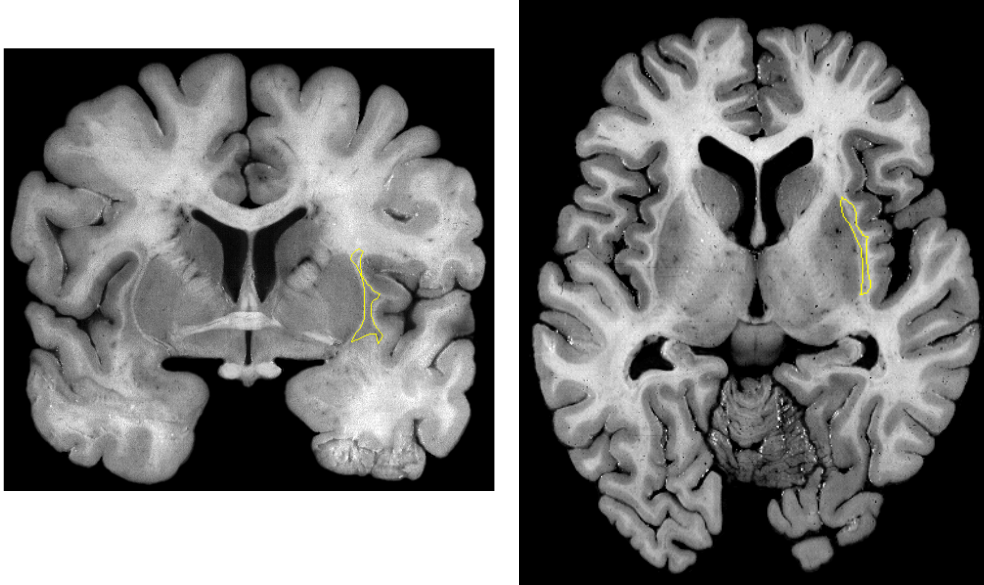
## Introduction

The claustrum has been an overlooked neuroanatomical structure. Although it has been defined by neuroanatomists for 190 years, (Edelstein & Denaro, 2004a, p. 951) only recently has its function been explored more fully (Crick & Koch, 2005). Part of its enigmatic nature could be due to its obscure shape and size; a thin ribbon-like gray matter structure just medial to the extreme capsule and lateral to the external capsule (see Figures 1 - 3). Indeed, its very name means “hidden away.”

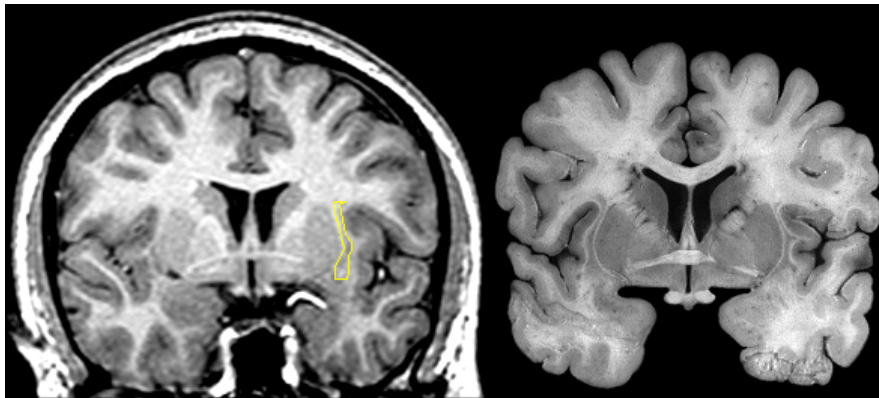
Interest in the claustrum has been rekindled as noted scientists have explored its underpinnings. On his deathbed, Nobel Prize laureate Dr. Francis Crick, was revising an article about the claustrum and its link to consciousness (Crick & Koch, 2005; Edelstein & Denaro, 2004b). After helping to unlock the mysterious structure of DNA, Dr. Crick turned his attention to neurobiology, applying the same genius to try and elucidate the neural correlates of consciousness (NCC). After decades of research surrounding the definition and circuitry of consciousness, Crick and his colleague, Christof Koch, proposed the claustrum as an ideal candidate for the ‘consciousness’ center, acting like a conductor in an orchestra to integrate information from all the varied modalities (2005). Their paper has spurred on the scientific world to further explore the function of the claustrum. Implicated functions that have precipitated from such studies include higher-order cognitive functions such as fear recognition (Stein, Simmons, Feinstein, & Paulus, 2007), experiential dread (Berns et al., 2006), memory storage (Morys, Bobinski, Wegiel, Wisniewski, & Narkiewicz, 1996), associative learning (Chachich & Powell, 2004), repetitive behaviors including addiction (Morys et al., 1996; Naqvi, Rudrauf, Damasio, & Bechara, 2007), multimodal processing in olfactory, auditory, visual, and tactile

information as well as emotional and behavioral responses (Bennett & Baird, 2006), cognitive impairment (Dubroff et al., 2008), suppression of natural urges (Lerner et al., 2008), and seizures (Zhang et al., 2001) and psychosis (Sperner, Sander, Lau, Krude, & Scheffner, 1996).

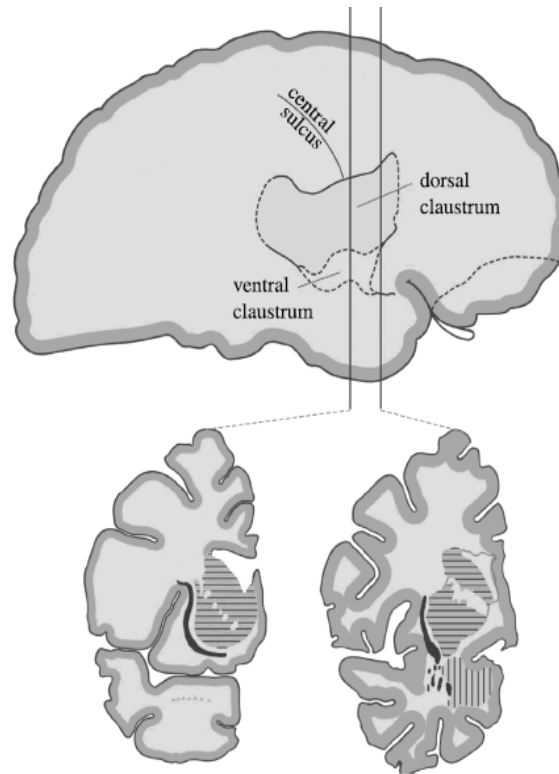
The putative behavioral features implicated to involve the claustrum have considerable relevance for understanding neuropsychiatric disorders where symptoms of anxiety, repetitive behaviors, and sensory integration may be key elements. For example, repetitive behaviors (see DSM-IV, American Psychiatric Association, 1994) heightened levels of underlying anxiety (Lecavalier, 2006) and disconnect in sensory integration (Iarocci & McDonald, 2006) are features of autism. As such, the disorder of autism presents an ideal population to study the relationship between brain structure and function. The current study will determine if there is a volumetric difference in claustral volume between individuals with autism compared to controls matched on age, performance IQ, and correcting for brain size. Such a difference could be a springboard into further investigation claustral function as well as the neural circuitry involved in autism.



*Figure 1:* Axial (left; level of the colliculi) and coronal (right, at the level of the anterior commissure) sections of the brain. The right claustrum is outlined in each image. Images used with permission from: Digital Anatomist Project at the University of Washington. Washington Brain Atlas: <http://www9.biostr.washington.edu/cgi-bin/DA/imageform>



*Figure 2:* Coronal section of the brain at the level of the colliculi in a T1 MRI (left) and post-mortem slice (right). The left claustrum is outlined in yellow on the T1 image. Images used with permission from: Digital Anatomist Project at the University of Washington.



*Figure 3:* The approximate location of the human claustrum beneath the insular cortex. Top image is a sagittal view and bottom images are coronal sections at the level of the vertical lines. On the coronal sections: dark band = claustrum; horizontal bands = caudate and putamen; vertical bands = amygdala. (Crick & Koch, 2005).

### *Neuroanatomy*

The claustrum has been defined for over 190 years (Edelstein & Denaro, 2004a) and is shown in Figures 1, 2 and 3. It is defined as a thin ribbon-like gray matter structure housed between the extreme capsule laterally and the external capsule medially in the general region of the insular cortex (Crick & Koch, 2005). On a coronal section it appears “worm-like” (Edelstein & Denaro, 2004a). Its presence in all animals has been debated when it comes to monotremes (i.e., egg-laying mammals such as the platypus, Ashwell, Hardman, & Paxinos, 2004), but all other species have been found to have a claustrum (Kowianski, Dziewiatkowski, Kowianska, & Morys, 1999).

The claustrum can be divided into two distinct regions, the dorsal and ventral claustrum (see Figure 2, Fernandez-Miranda, Rhoton, Kakizawa, Choi, & Alvarez-Linera, 2008; Kowianski et al., 1999; Morys et al., 1996). The distinctions between dorsal and ventral claustrum is based on cell number and density, connections, and calcium binding proteins wherein the dorsal claustrum has a greater number of cells as well as a greater cell density when compared to the ventral claustrum (Kowianski et al., 1999). Also, the dorsal claustrum is predominantly connected with the isocortex whereas the ventral claustrum connects with the entorhinal and prepiriform cortices (Morys et al., 1996; Morys, Narkiewicz, & Wisniewski, 1993; Pearson, Brodal, Gatter, & Powell, 1982). In a microsurgical fiber dissection, Fernandez-Miranda et al., (2008) reported a superior and inferior division of the ventral claustrum; the superior portion in the subputamen region and the inferior portion in the para-amygdalar region where it can be difficult to differentiate from the amygdala (Kowianski et al., 1999).

The claustrum is in close proximity to other basal ganglia structures as well as the amygdala and insular cortex (Fernandez-Miranda et al., 2008). Toward its rostral end it can be observed to be continuous with the putamen. Because of this proximity the claustrum has been considered to be a part of striatal-cortical circuitry in its relations to neuropsychiatric disorders, motivation and emotional circuitry (Bennett & Baird, 2006; Heimer, 2003).

### *Ontogeny*

Due to its proximity to insular cortex, basal ganglia, and amygdala, several hypotheses have been suggested for the ontogeny of the claustrum. In 1909 Brodmann contested that the claustrum is a “split-off” from insular cortex. Later, in 1972, Cajal

suggested the claustrum's origin to be more closely related to the basal ganglia (Kowianski et al., 1999). Perhaps the most accepted view of the claustrum is one put forth by Filimonoff (1966) which incorporates both the pallial and subpallial views suggesting that the claustrum is an intermediate formation of both the pallial matrix and bordering striatum.

More recently, Kowianski et al., (2008) suggested that the claustrum shares a common origin with the endopiriform nucleus and basolateral amygdala forming a "claustramygdaloid complex" from the lateral pallium and therefore implicating the claustrum's close association with the amygdala (Medina et al., 2004).

Ontogeny is important when considering possible claustral function and whether it is related to other ontologically similar structures such as basal ganglia, amygdala, or insula. However, regardless of its origin, the claustrum is a structure likely serving a mediating position between cortical and subcortical structures (Fernandez-Miranda et al., 2008) solely based on its anatomical location. As such, it could potentially serve as a conduit between higher cortical functions and more basic emotional functioning (Bennett & Baird, 2006; Crick & Koch, 2005).

### *Cell Types*

Surprisingly, there are only two cell types in the claustrum. Type 1 neurons are large, spiny and are reciprocally connected to various parts of the brain. The other type of neurons, classed as interneurons, is aspiny and has either a large or small soma (Edelstein & Denaro, 2004a; Spahn & Braak, 1985). This lack of neuron diversity led Crick and Koch to believe that the functionality of the claustrum is based on its inputs. They proposed that claustral neurons "could be especially sensitive to the timing of the inputs,

cementing the role of the claustrum in binding disparate events into a single percept, experienced at one point in time” (Crick & Koch, 2005, p. 1273). This intimation of events is at the heart of consciousness and other higher order functions such as processing social information.

The existence of dendritic spines in the claustrum allows it to act as an integrating center. Dendritic spines are found in places where inputs from diverse sources converge. One function of the spines is to allow a greater degree of connectivity in the same amount of space (Sorra & Harris, 2000), which helps to explain why the claustrum is able to receive, process, and integrate such a variety of inputs despite its relatively small size. Also, dendritic spines are more mobile than the underlying dendritic branch which makes them perfect targets for morphological plasticity (Matus, Brinkhaus, & Wagner, 2000).

#### *Physiological Considerations: Lesion and Stimulation Studies*

Useful lesion studies in humans and animals are limited. To date, there are not any known human diseases or genetic defects that lead to specific degradation of the claustrum although many have nonspecific claustral effects (for an example in Alzheimer's Disease see Morys et al., 1996). There is one report that showed reversible bilateral claustral lesions following general encephalopathy with seizures, psychotic symptoms and temporary loss of vision, speech and hearing (Sperner et al., 1996). Another case study of unilateral resection of the claustrum in 42 individuals with low-grade gliomas showed no post-operative sensorimotor or cognitive deficits (Duffau, Mandonnet, Gatignol, & Capelle, 2007), suggesting the claustrum's role as an accessory in global function rather than a primary player. This finding supports Crick and Koch's speculation that functional deficits would only be experienced after a biclaustral lesion



(Crick & Koch, 2005). Claustal edema has also been reported with intake of sugihiratake mushrooms, found in the mountainous regions of Japan and used as a delicacy in Japanese cuisine including miso soup and tempura. Following ingestion, asthenia in legs, shaking limbs, difficulty in ambulation and intractable status epilepticus were noted (Kuwabara, Arai, Honma, & Nishizawa, 2005; Nishizawa, 2005; Nomoto et al., 2007).

Because of its thin shape, internal location, and placement in a vascular watershed territory (Crick & Koch, 2005), the claustrum is hard to lesion and record from specifically without affecting neighboring areas. Nevertheless, in their extensive review on the subject, Edelstein and Denaro (2004a) suggest the claustral involvement in complex behaviors and functions, many being limbic in nature. Furthermore, they determine that “Physiologically, the CI [claustrum] appears to assume the role of sensory liaison between the somatic afferents . . . and the primary cortical sensory regions” (Edelstein & Denaro, 2004a, p. 682)

The lack of lesion studies and genetic defects specific to the claustrum makes it even more imperative to find populations where claustral function may be compromised. Castelli et al., (2002) reported significant reduced functional connectivity between extrastriate visual areas and the superior temporal sulcus of individuals with high functioning autism. This could implicate claustral involvement according to Edelstein and Denaro’s (2004a) proposed function of the claustrum mentioned above. McAlonan and colleagues (2005; 2002) have also found reduced gray matter volume in the basal ganglia and general temporal lobe in individuals with autism and Aspergers syndrome using voxel-based morphometry (VBM) techniques. This observation has also been supported by

Bigler et al. (in press), but VBM methods only permit a region of interest (ROI) analysis that identifies through stereotaxic coordinates the location of density changes in pixel values for white and gray matter and cerebral spinal fluid (CSF, see Ashburner & Friston, 2000). While these findings could lend support to a hypothesis of reduced claustral volume in individuals with autism, they do not represent a direct measure of the claustrum (for discussion of VBM see: Ashburner & Friston, 2001; Salmond et al., 2002; Testa et al., 2004).

### *Connections between the Cortex and Claustrum*

The most fascinating feature of the claustrum is not its anatomical shape but rather its extensive reciprocal connections to and from almost all brain areas (Fernandez-Miranda et al., 2008; Pearson et al., 1982). Indeed, these reciprocal connections underlie Crick and Koch's (2005) hypothesis concerning the claustrum as a consciousness center. Through numerous primate studies the claustrum has been shown to be interconnected with the frontal lobe—including motor cortex, prefrontal cortex and cingulate cortex—visual cortical regions in the occipital lobe, temporal and temporopolar cortices, parietooccipital and posterior parietal cortex, the frontoparietal operculum, somatosensory areas, prepiriform olfactory cortex and the entorhinal cortex. The claustrum also projects to the hippocampus (Amaral & Cowan, 1980), the amygdala (Amaral & Insausti, 1992) and to the caudate nucleus (Arikuni & Kubota, 1985; Crick & Koch, 2005).

This connection is mostly ipsilateral, but a small contralateral division also exists (Kievit & Kuypers, 1975). The information from the various brain regions is segmented topographically in the claustrum and in an overlapping manner; meaning the frontal lobes

project and receive the anterior claustrum, the parietal cortex is associated with the middle claustrum and the occipital and temporal cortices are associated with the posterior and inferior regions of the claustrum (Fernandez-Miranda et al., 2008; Morys et al., 1993; Pearson et al., 1982). Because of the interaction between these various groups of neurons (carrying information from specific modalities) the claustrum is in a prime position to integrate information from these varying sources (Crick & Koch, 2005).

Integration of information from various modalities may also occur prior to claustral synapses via spiny inverted neurons (also referred to as inverted pyramidal neurons) in cortical layers V and VI (Mendizabal-Zubiaga, Reblet, & Bueno-Lopez, 2007). These neurons make up a majority of the cortico-claustral projections from the primary visual cortex, and are also found in the auditory and sensory motor cortices and throughout the cortex. Because their dendritic arbor is spatially different from other pyramidal neurons in the same area, they allow two different streams of axonal output to be sent to the same destination carrying information from separate modalities.

The claustrum has often been compared to the thalamus because of its numerous reciprocal connections to primary sensory cortices and related diencephalic sensory relay nuclei. Edelstein and Denaro (2004) suggest that such apparent redundancy could be a means to ensure the cortex is in constant connection with the environmental sensorium. Despite their similarities, the claustrum and thalamus differ in two key aspects. The claustrum, unlike the thalamus, does not receive strong brainstem and spinal input (Edelstein & Denaro, 2004a). The claustrum also has the ability within itself via intra-claustral connections to “synchronize different perceptual, cognitive and motor modalities” whereas the thalamus does not “possess any obvious mechanism to directly

link its various constitutive nuclei.” (Crick & Koch, 2005).

### *Claustral Function*

Due to its ontogeny, proximity to basal ganglia, amygdala and insula, and reciprocal connections the claustrum has been implicated in many higher-order cognitive functions such as fear recognition (Stein et al., 2007), experiential dread (Berns et al., 2006), memory storage (Morys et al., 1996), associative learning (Chachich & Powell, 2004), and sensory integration (Naghavi, Eriksson, Larsson, & Nyberg, 2007). Crick and Koch (2005) have also recently suggested that the claustrum is an ideal structure to serve as a consciousness center for the brain, able to integrate information from all sensory modalities, including emotional content from limbic structures, to form a single event.

Edelstein and Denaro (2004) summarized their extensive review of the claustrum as such:

The CI can receive (it has many inputs from many areas), assimilate (inputs can result in change of the CI), integrate (multiple inputs result in a new signal) and channel (the redirecting of information) sensory information throughout the brain via the primary sensory cortices and diencephalic nuclei. In this way, the CI offers functionality of a higher order, enabling the organism to rapidly adapt to the subtleties and nuances of its ever-changing environment. In humans, a loss of any of these multisensory and heterotopic attributes may yet be demonstrated to be involved in some aspects of dementia, attention and other perturbation or disturbances of higher-order functions. It also can be seen why this structure could become a choice for the investigation of mind-brain relationships. (p. 688)

More recently, a detailed fiber dissection and diffusion tensor study, led Fernandez-Miranda et al., (2008) to conclude: “We suggest, as Crick did, that the information from, say, a visual cortical region, would be combined with information from the limbic system, or information from the somatosensory cortex would be integrated with the information from the motor cortex, by the corticoclaustral network” (p. 771).

The widespread reciprocal connections, particularly to brain regions involved in socio-emotional behavior such as the orbitofrontal cortex, middle temporal lobe (McAlonan et al., 2005), and amygdala (Schulkin, 2007), make autism (Baron-Cohen & Belmonte, 2005) a prime disorder to consider when investigating claustral dysfunction.

### *Autism*

Autism is a neuropsychiatric disorder where higher-order cognitive, emotional-fear reactions (Schulkin, 2007), and sensory integration (Iarocci & McDonald, 2006) are often impaired. Such symptoms directly implicate the claustrum as a player in autistic circuitry. Autism is diagnosed in the Diagnostic and Statistical Manual of Mental Disorders (DSM-IV, American Psychiatric Association, 1994, pp. 70-71) on the basis of a triad of characteristics, namely impaired social abilities, lack of language development, and repeated or ritualized behaviors. Autistic behavior was first characterized over 70 years ago (see Kanner, 1943) but it was not until 1978 that the symptoms were specifically outlined (Rutter, 1978). Although the disorder is still diagnosed based on behavioral findings and medical exclusion of other neuropsychiatric disorders, it is largely regarded as neurodevelopmental in nature with many brain areas showing a difference in connectivity (Herbert et al., 2003; Just, Cherkassky, Keller, & Minshew, 2004; Lewis & Elman, 2008), volume (Hollander et al., 2005; Langen, Durston, Staal, Palmen, & van Engeland, 2007; Tsatsanis et al., 2003; Voelbel, Bates, Buckman, Pandina, & Hendren, 2006), and white matter (Lainhart, Lazar, Bigler, & Alexander, 2000). Based on recent research it is now assumed that there is not a single locus of brain abnormality in autism (Fletcher et al., 1995; McAlonan et al., 2005); nor is there a single gene (Dawson et al., 2005; Pickles et al., 1995; Risch et al., 1999). Therefore, it is

unlikely that a structure like the claustrum would play a key role in the disorder, but rather an associative role in conjunction with multiple other neural systems and functional areas of the brain. If the claustrum's origin is basal ganglia (BG) in nature, then all of the BG neural circuitry that relates to repetitive behavior and emotional dysregulation in autism may be relevant to the claustrum (Chambers, Taylor, & Potenza, 2003). The amygdala has also been strongly suggested to be involved in autism (Schulkin, 2007) and the claustrum's close association to this structure (Fernandez-Miranda et al., 2008; Kowianski et al., 1999) would again implicate differences in claustral connectivity and volume.

Of particular importance to this study is the lack of development of the social brain in autism (Baron-Cohen & Belmonte, 2005; McAlonan et al., 2005). As noted previously, individuals with autism struggle with social interactions and have limited ability to interpret others' behavior, interact in social groups, and empathize (Baron-Cohen et al., 1999). Social brain neurocircuitry includes the orbito-frontal cortex, superior temporal gyrus and the amygdala (Brothers, Ring, & Kling, 1990), all of which project to and receive axons from the claustrum (Fernandez-Miranda et al., 2008). Indeed, these brain regions have been shown to be less activated in individuals with autism when performing social tasks (Baron-Cohen et al., 1999). Could it be that the claustrum plays an intermediary role between cortex and subcortical structures (Fernandez-Miranda et al., 2008; Morys et al., 1993) where a disconnect occurs between social processing and emotion?

Several behavioral abnormalities related to the basal ganglia are observed in individuals with autism including repetitive behavior and behaviors associated with

obsessive compulsive disorder and attention deficit hyperactive disorder (Bradley & Isaacs, 2006; Lecavalier, 2006). Although there have been discrepancies as to volumetric changes in basal ganglia volume (Hollander et al., 2005; Langen et al., 2007; Voelbel et al., 2006), such differences have been noted implying changes in circuitry. The claustrum is also closely associated with the basal ganglia both ontologically (Filimonoff, 1966) and spatially (Fernandez-Miranda et al., 2008; Kowianski et al., 1999), thus implicating the claustrum as functionally relevant to the basal ganglia.

#### *Quantitative Neuroimaging: ROI Volumetric Methods*

There are several ways that brain structures can be quantified. The methods used in this study, quantitative magnetic resonance imaging (qMRI), allow for analysis of minute differences unobservable to the unaided eye (E. D. Bigler, 2001).

Usually in qMRI, an initial classification of the MR image is performed to separate the three brain tissue constituents: white matter, gray matter, and CSF. After classification, the brain region or structure under study is then traced manually based on specific boundaries determined by the investigators. A region of interest (ROI) analysis is then applied, allowing a count of white matter, gray matter and CSF pixels within the specified region. Counts for each of the tissue types can then be summed over the slices and multiplied by the voxel dimension to obtain a volume (E. D. Bigler et al., 1997). However, because the claustrum is so thin, the software available at this time is not able to adequately distinguish the claustrum from the surrounding white matter and other closely related structures. Therefore, no initial classification of tissue types will be employed. Instead the claustrum will be traced, then a voxel count obtained, summed, and multiplied by the voxel dimensions to achieve the volume. It is also necessary to

correct for brain volume differences so that volumetric structural differences are based on the criteria determined and not attributable to general differences in brain size. Brain volume (total intracranial volume [TICV] will be measured) can be obtained in an automated fashion using FreeSurfer<sup>®</sup> v4.0.4 software (Athinoula A. Martinos Center for Biomedical Imaging, 2008) by methods previously described (Buckner et al., 2004; Dale, Fischl, & Sereno, 1999; Fischl, Sereno, & Dale, 1999). FreeSurfer<sup>®</sup> has been shown to be an accurate measure of overall brain volume (Klauschen, Goldman, Barra, Meyer-Lindenberg, & Lundervold, 2008).

The claustrum can be readily quantified by tracing its outer boundary at each level it can be clearly defined. An example of tracing of the claustrum is shown in Figure 1 (see also Appendix A). This type of tracing will be applied to each slice of the T1 Magnetic Resonance Image (MRI) where the claustrum can be identified. By knowing slice thickness and the gap between slices (in this study, there will be no gap), volumes can be calculated (E. D. Bigler et al., 1997).

#### *Purpose and Rationale of Study*

Although claustral volume has been studied and recorded previously (Kowianski et al., 1999), these studies were post mortem and not associated with autism or any other neuropsychological disorders. Therefore this study will be exploratory in nature; the first of its kind to estimate claustral volume en vivo and volumetric differences that may be associated with autism. The primary purpose of this study is to determine if the claustrum can be studied using current neuroimaging techniques such as ROI tracing. If the claustrum can be analyzed via the proposed methods it will undoubtedly lead to subsequent studies and insight into possible claustral function and pathways associated



with autism.

One early observation found in children with autism is increased head circumference corresponding to enlarged cerebral volume (Courchesne, Carper, & Akshoomoff, 2003). This early brain growth may be due to different local brain growth abnormalities. Recently, the thalamus of high-functioning individuals with autism was shown to be reduced in volume (Tsatsanis et al., 2003), probably due to lack of connections. Several volumetric studies of the basal ganglia in autism have shown increased caudate volumes (Hollander et al., 2005; Langen et al., 2007; Voelbel et al., 2006), while others have shown no difference in basal ganglia size (Hardan, Kilpatrick, Keshavan, & Minshew, 2003). Using VBM, McAlonan and colleagues (McAlonan et al., 2005) found a reduction in the gray matter of the fronto-striatal network. Since the claustrum may be more linked with the basal ganglia, and owing to the larger number of studies suggesting a relationship between psychopathology and larger basal ganglia volume, the current study anticipates that the claustrum will be larger in those with autism compared to controls. Because claustral size correlates highly with overall brain size (Kowianski et al., 1999), it is necessary to correct for brain size to ensure that claustral volume differences are not merely indicating brain size differences.

### *Hypothesis*

Subjects with autism will display a larger claustral volume when compared to non-autistic age-matched controls and when controlled for overall brain volume.

## Methods

### *Participants*

The autism group will consist of 16 high-functioning males (performance IQ > 85) that met criteria for autism disorder. Fourteen male control participants were selected based on age and performance IQ. The participants chosen for this study include a subgroup of a larger sample of autism spectrum disorder (autism, autism spectrum, pervasive developmental disorder-not otherwise specified, PDD-NOS) and control subjects whose corpus callosum and temporal DTI data has been previously reported (Alexander et al., 2007). In an effort to remove differences not associated with autism, this study focuses on high-functioning autistic males because gender and intellectual subnormality can affect brain morphometry (C. Frith, 2003).

All participants were recruited and scanned during a two year period (2003-2005) as part of an ongoing longitudinal study of autism at the University of Utah. All required Institutional Review Board approvals were obtained and all participants provided written informed consent/assent prior to participation.

*Autism diagnosis.* The diagnosis of autism was based on the Autism Diagnostic Interview-Revised (ADI-R, Lord, Rutter, & Le Couteur, 1994), Autism Diagnostic Observation Schedule-Generic (ADOS-G, Lord et al., 2000); DSM-IV (American Psychiatric Association, 1994), and International Classification of Diseases – Tenth Revision , (ICD-10, World Health Organization, 1995) criteria. Medical causes of autism were excluded based on participant history, Fragile-X gene testing, karyotype, and observation. The medical history also excluded medical conditions that could affect brain morphometry, including a history of severe head injury, hypoxia-ischemia, seizures, and

other neurologic disorders. Control participants underwent tests of IQ and language, had standardized psychiatric assessments (Leyfer et al., 2006) and were assessed with the ADOS-G (Lord et al., 2000) to confirm typical development. Controls were excluded if they had any history of developmental, learning, cognitive, neurological, or neuropsychiatric conditions.

### *Magnetic Resonance Imaging (MRI)*

*MRI acquisition.* Participants underwent MRI on a Siemens Trio 3.0 Tesla Scanner at the Center for Advanced Imaging Research at the University of Utah. Two young children with autism were sedated for scanning by an anesthesiologist (JL). They were continually monitored according to American Society of Anesthesiology standards. There were no complications. A wide range of pulse sequences and image contrasts were collected for both clinical review and quantitative analyses. An 8-channel, receive-only, RF head coil was used for the imaging experiments.

### *Image Analysis*

*ROI tracing.* The claustrum was first traced in the axial view then again in the coronal orientation following a predetermined protocol (see fig. 1 and Appendix A). A majority of the scans were traced by WD, while JD traced four of the scans. Both of these raters have been shown to be reliable on similar ROI tracing protocols (JD – whole brain, WD – temporal lobe (Bigler 1997)). Medial boundary of the claustrum will be the external capsule and the lateral boundary will be the extreme capsule. Ventrally, the claustrum will be traced as long as it is distinguishable from other basal ganglia. Total claustral volume will be determined by summing the gray matter pixels and then multiplying by the voxel dimension ( $0.125\text{mm}^3$ ). Head size correction using total

intracranial volume (TICV) will be done so that claustral volumes can be directly compared across subjects (E. D. Bigler et al., 1997). TICV will be obtained using FreeSurfer<sup>®</sup> (Buckner et al., 2004; Dale et al., 1999; Fischl et al., 1999).

*Test-retest reproducibility.* Even with clearly defined boundaries, tracing variability is inherent in any manual tracing protocol (Jack, Theodore, Cook, & McCarthy, 1995). With only one tracer it is necessary to have test-retest tracings to ensure validity of the tracings. Each scan was traced twice by the same rater, and then a percent error calculation was performed to make sure the two volumes were within 90% of each other. The average of the two tracings was used in the statistical analysis.

#### *Statistical Analysis*

*Quantitative MRI.* An independent samples two-tailed t-test will be performed to test if there is a difference in claustral volume of individuals with autism compared with the age matched controls. Although the hypothesis predicts a larger claustrum in individuals with autism, a two-tailed test will allow the testing of a difference in either direction and will also make the test more conservative.

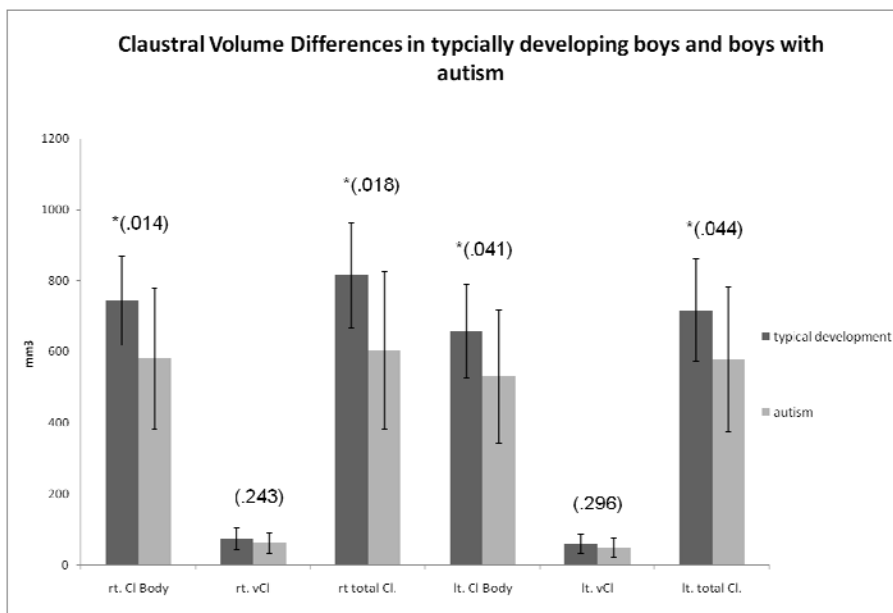
Data will be analyzed with and without correction for brain size. Because volume measurements of cerebral structures are highly interdependent and intercorrelated (Blatter et al., 1995) even in the claustrum (Kowianski et al., 1999), adjusting for brain size variation becomes important. By dividing each participant's claustral volume by the total intracranial volume (TICV) a ratio is created that controls for variability in brain size. However, because the claustrum is such a small structure, correcting for brain size reduces between-subject variability. Absolute size, regardless of head size, may be the critical measure and creating a TICV ratio may mask the structure-function relationships

(E. D. Bigler et al., 1996). Therefore, data will be reported with and without brain size corrections.

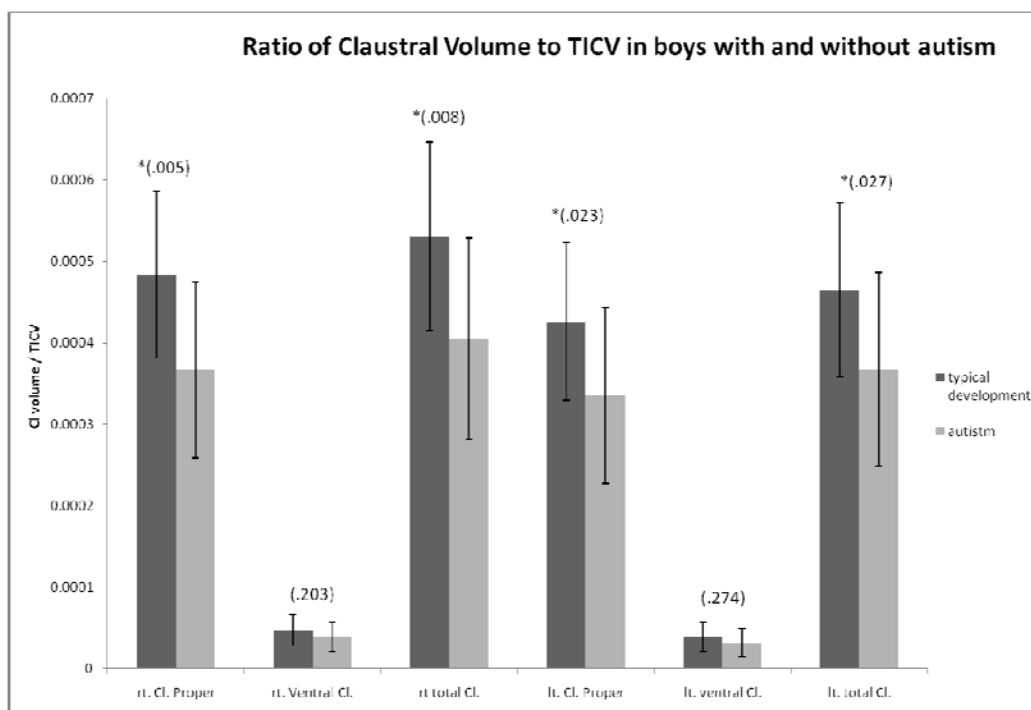
## Results

An independent samples, two-tailed t-test was used to determine if caudate volume in children with autism was different from typically developing children. Four different measures were found to be significantly different: right caudate ( $p = .014$ ), left caudate ( $p = .041$ ), right total caudate ( $p = .018$ ) and left total caudate ( $p = .044$ ). All other measures were not statistically significant (see Figure 4). Because subjects were already matched according to brain size, correcting for TICV did not yield any additional significant differences (see Figure 5).

Although not specifically alluded to in the hypothesis, caudate hemispheric differences were also tested using a paired samples t-test. The right caudate was found to be significantly larger than the left caudate in both the group with autism ( $p = .021$ ) and the typically developing group ( $p = .003$ ). Right and left caudate volume was also highly correlated in both the group with autism ( $r = .915$ ) and the typically developing group ( $r = .762$ ).



*Figure 4:* Differences in claustrum (Cl) volume between boys with autism and typically developing (TD) boys. Rt. = right; Lt. = left; vCl = ventral Cl. Error bars indicate standard deviations. *p* value in parenthesis; \* = significant finding.



*Figure 5:* Differences in TICV ratio (Cl volume/TICV) between boys with autism and typically developing boys. Rt. = right; Lt. = left; vCl = ventral Cl. Error bars indicate standard deviations. *p* value in parenthesis; \* = significant finding.

## Discussion

This study is the first of its kind to quantify the volume of the claustrum in vivo, sufficiently distinguishing it from the amygdala, putamen, insula, and other nearby structures. Contrary to the initial hypothesis, the volume of the claustrum was not found to be larger in individuals with autism compared to controls matched for age, brain size, and IQ. This initial hypothesis was based on the claustrum's close proximity and perhaps similar ontogeny to basal ganglia structures such as the caudate and putamen which have shown volume differences in individuals with autism, but these differences have not been reproducible (C. Frith, 2003), Voelbel et al. (2006), Langen et al. (2007) and Hollander et al. (2005) showed increased caudate volume in individuals with autism, and Herbert et al. (2003) showed larger globus-pallidus-putamen volume in 7-11 year old normal intelligence boys with autism. However, Hardan et al. (2003) showed no difference in basal ganglia (caudate and putamen) volume and McAlonan et al. (2002) showed decreased caudate volume in individuals with Asperger syndrome. Even studies of the amygdala have not been reproducible in regards to direction of volumetric differences (C. Frith, 2003). Tsatsanis (2003) showed a significant increase in thalamic volume when volumes were related to total brain volume. The discrepancies of these studies make it challenging to get a clear picture of volumetric differences of subcortical structures in autism. Some of these discrepancies may be a result of the subjects studied. Variations in IQ may lead to confounding factors (C. Frith, 2003) and the age of subjects is also important to consider because autism is a neurodevelopmental disorder and therefore may present with different morphometric findings at various stages of brain maturation (Hardan, Muddasani, Vemulapalli, Keshavan, & Minshew, 2006). Taken together, it



becomes difficult to predict which direction volumetric differences will occur in the claustrum in autism.

In this study there was a significantly smaller claustral volume in individuals with autism. Because the claustrum serves as an integrating center of all cortical modalities, this smaller claustral volume could be indicative of the underconnectivity found in autism as has been suggested by other investigators (Just, Cherkassky, Keller, Kana, & Minshew, 2007).

A post mortem volumetric study reported average human claustral volume to be  $580 \text{ mm}^3$  (Kowianski et al., 1999) which is considerably smaller than the average claustral volume reported here ( $701 \text{ mm}^3$  in typically developing boys and  $555 \text{ mm}^3$  in boys with autism). However, Kowianski et al. volumetrics did not correct for volumetric changes that occur when fixing the brains. Also, there were only five brains used in the Kowianski et al. study, with an average age of 62 years old. Accelerated loss in the area of the insula (Good et al., 2001), as well as the caudate and putamen (Gunning-Dixon, Head, McQuain, Acker, & Raz, 1998) have been shown to occur with old age. All of these reasons make it difficult to compare post-mortem volumetric data between Kowianski et al. and the current study. Even if volumes obtained via the ROI approach of the current investigation are not as accurate as postmortem studies, differences reported should still be reliable because the same error would be associated with both the control and autism groups.

There was a significant difference between right and left claustrum volume (right > left) in the control group, the autistic group, and between groups. Because this difference was seen in both groups, it would be more indicative of general hemispheric

differences rather than an association with a particular neuropathology. Other brain structures have also been shown to exhibit hemispheric differences such as the hippocampus (Li, Ga, Huo, Li, & Gao, 2007) and amygdala (Pedraza, Bowers, & Gilmore, 2004) with the right being larger than the left. Based on possible function of the claustrum (Crick & Koch, 2005) it is unclear why such a laterality would exist. But laterality of claustral involvement has been shown in other studies as well: Bonhila et al. (2008) reported increased left claustral volume in a VBM study of young males with autism; Naghavi, Eriksson, Larsson and Nyberg (2007) reported right claustrum and insula to be increasingly activated with modal sensory integration of conceptually related objects; Lerner et al. (2008) reported right more than left claustral activation associated with suppression of natural urges; Olson, Gatenby and Gore (2002) found left claustral activation in cross-modal integration of audio-visual stimuli; Banati, Goerres, Tjoa, Aggleton and Grasby (2000) found left claustral activation in response to visual-tactile integration, and Hadjikhani and Roland (1998) found right claustrum activation in visual-tactile cross modal transfer.

#### *Underconnectivity in Autism*

The claustrum is likely a key integrator of all cortical and subcortical modalities (Fernandez-Miranda et al., 2008; Morys et al., 1996). Recently a disconnection hypothesis for autism has been proposed to explain the neurobehavioral deficits seen in autism: “underconnectivity theory proposes that autism is a cognitive and neurobiological disorder associated with underfunctioning of integrative circuitry, resulting in a deficit in integration of information at the neural and cognitive levels” (Just et al., 2007, p. 951). Catani and Mesulam (2008) have also included autism in their discussions on

disconnection syndromes. As a player in cortical and subcortical connectivity, the claustrum would be expected to exhibit volumetric or other mal-developmental differences in neuropathologies where cortico-cortico and cortico-subcortico connections are disturbed. The smaller claustrum volume in autism subjects observed in the current study may reflect disturbed connections between this sub-cortical structure and other cortical and subcortical areas critical for emotional regulation and cognition.

Evidence of underconnectivity in autism is abundant. Just et al. (2007) used fMRI to analyze brain activation in high functioning individuals with autism and proposed underconnectivity on the basis of a lack of synchronization of brain areas activated in executive function tasks. Several other imaging studies have suggested to underconnectivity in autism based on white matter and gray matter differences (Bonilha et al., 2008), and lack of correlation between (McAlonan et al., 2005) and discrepancies in cortical thickness (Hardan et al., 2006). In a review article, Courchesne and Pierce (2005), suggested increased local and reduced long-distance reciprocal connectivity in the frontal cortex to be responsible for the deficits in higher order cognitive, language and social and emotional functions seen in autism.

### *Sensory Integration*

Dysfunction in sensory integration is a key element in autism (Iarocci & McDonald, 2006). When autism was first identified and characterized as a disorder, this dysfunction was noted (Kanner, 1943). Several clinical reports have confirmed this finding (Cesaroni & Garber, 1991) reporting both hyper and hypo-sensitivity, multichannel perceptions (where, for example, sounds may be seen as colors), sensory overload and difficulty processing more than one modality at a time (O'Neill & Jones,

1997). Again, the claustrum as a “sensory liaison between somatic afferent and primary cortical sensory regions” (Edelstein & Denaro, 2004a), would be strongly involved in these instances of dysfunctional sensory integration. Indeed the claustrum has been shown to be activated in sensory integration of audio-visual input (Olson et al., 2002), visual-tactile integration (Banati et al., 2000; Hadjikhani & Roland, 1998), and analysis and integration of audio-visual content (Naghavi et al., 2007). The ventral claustrum has also been implicated as an area where sensory-specific cortical systems are able to communicate with each other (Ettlinger & Wilson, 1990).

One specific circuit where proper sensory integration and attention is key in normal development, and dysfunctional in autism, is in social brain circuitry which is composed of the orbito-frontal cortex, superior temporal gyrus, and amygdala (Brothers et al., 1990); all of which project to and receive claustral connections (Fernandez-Miranda et al., 2008). The social brain and social intelligence is involved in the interpretation of social cues from faces, empathy, interacting in social groups, and general social judgment, all of which are deficient less in autism (Baron-Cohen & Belmonte, 2005). Social brain circuitry may also be responsible for language deficits seen in autism because proper language development has been shown to be best when in a social context (Dawson et al., 2005; Kuhl, Tsao, & Liu, 2003). Perhaps this same disconnect in social brain circuitry involving the claustrum allows for increased single modality functions seen in autism because there would be increased segmentation, rather than integration, of stimuli (Baron-Cohen & Belmonte, 2005; Jolliffe & Baron-Cohen, 1997).

Bennett and Baird (2006) imaged 19 college freshman who had moved more than

100 miles to attend school and scanned them six months apart (at the beginning and end of a semester) to see if there were neural changes that occurred as a result of the new experiences and maturation that precipitate with this stage in one's life. Using a VBM approach so differences across the entire cerebrum could be compared to controls, several areas of significant increased intensity were reported including the claustrum. This change in intensity was interpreted to be evidence of increased myelination, and therefore increased ability in information transfer. During the first year of life away from home new sociocognitive skills are developed to help one function in the new environment and therefore brain regions involved in emotional experience and behavioral regulation will be effected. The college transition is also marked by increased self-knowledge and the ability to apply this knowledge to the thoughts and feelings of others, an ability that is lacking in autism and often referred to as "mind-blindness" (U. Frith, 2001). Herein lays a direct link between the social brain and the claustrum.

#### *Developmental Course of Autism and the Claustrum*

One of the most consistent findings in autism is accelerated brain growth shortly after birth followed by arrest of growth and possible atrophy later in adolescence (Courchesne et al., 2003; C. Frith, 2003). Therefore the brain with autism is quite different if visualized early on compared with decades after onset; showing excessive growth and size early in development, and neuron loss, degeneration and inflammation decades later (Courchesne et al., 2007; Lainhart et al., 2000). This accelerated brain growth leads to underconnectivity in long range circuitry and hyperconnectivity in short range circuitry (Lewis & Elman, 2008). Usually, autism is not diagnosed until two years of age and sometimes evidence of autistic symptoms are not seen until shortly before this

time period. Areas of the brain that are in the process of developing during early childhood, such as the frontal cortex, are most at risk for aberrant growth or pruning whereas areas that develop previously, such as occipital cortex, develop more normally (Huttenlocher, 1990).

In the midst of all these developmental differences where does the claustrum come in? Anatomical changes in the claustrum even in early adulthood have been reported (Bennett & Baird, 2006). More studies would need to be conducted to analyze typical claustral development and possible developmental differences that occur with autism or other neurodevelopmental disorders where sensory integration and social processing is affected. If typical claustral development is most dynamic early in childhood (2-4 years old) when most individuals with autism also express developmental abnormalities, it would follow that structural or connectivity disorganization would also occur. Perhaps analysis of younger subjects would lead to more significant findings of claustral volume or activation differences. New imaging technologies such as near infrared spectroscopy (NIRS) allow the imaging of the infant brain without sedation and movement artifacts (Minagawa-Kawai, Mori, Hebden, & Dupoux, 2008). Such benefits will undoubtedly make this new technique pivotal in learning more about early neural development.

### *Study Limitations*

The current study is not without its limitations. Small sample size and a single rater limit the statistical power of the study. Using all male subjects make the results less transferable to females but the use of only males was done to eliminate sex differences that may occur because autism is more prevalent in males (Baron-Cohen, 2002) and

therefore the recruitment subjects is less problematic. This study focuses on non-mentally retarded individuals with autism because IQ is a significant factor in brain morphology (mental retardation has been shown to be associated with decreased cerebral volume) and can therefore be a compounding factor if one is trying to pinpoint differences specific to a certain neuropathology (C. Frith, 2003). There is a need to conduct similar studies in females and in individuals with autism with varying levels of IQ to determine the differences these factors create.

There are also drawbacks inherent to any ROI study such as this one including a priori determination of the area and ambiguous boundary definition (C. Frith, 2003; Jack et al., 1995), but due to its small size and difficult boundary definition, the claustrum cannot be appreciated using FreeSurfer<sup>®</sup> because this program is especially prone to segmentation errors in the insular region due to the thin nature of the extreme capsule (i.e., white matter) and therefore gray matter is often classified as continuous from cortex to basal ganglia thus not isolating the claustrum (Athinoula A. Martinos Center for Biomedical Imaging, 2008). Other automated techniques are prone to this same classification error. More ROI studies will need to be performed to confirm differences reported here. Precaution should be taken if trying to generalize these volumetric findings to use as standards. Such precautions should be used in all ROI studies considering discrepancies in anatomical boundaries, imaging techniques, software used, and general methodology between labs (Jack et al., 1995).

As mentioned previously, this is the first ROI study to volumetrically quantify the claustrum. Bonilha et al. (2008) did report increased gray matter in the left claustrum of twelve males with autism (avg. age = 12.4 years) using VBM. However, as discussed

earlier, VBM methods only permit a region of interest (ROI) analysis that identifies through stereotaxic coordinates the location of density changes in pixel values for white and gray matter and CSF (Ashburner & Friston, 2000). While these findings suggest reduced claustral volume in individuals with autism, they do not represent a direct measure of the claustrum. Lack of congruency between directional differences in volumetric studies is also reported in the caudate, amygdala and other areas inferred to be volumetrically affected in autism (C. Frith, 2003), and could be a result of differences in subject selection (i.e., IQ, age) and quantification methodology. There is need for standardized anatomical boundaries and quantification methodology to be adopted before results can be legitimately compared between researchers. In any event, both of these studies suggest claustral volumetric differences associated with autism.



## Conclusion

Whether the claustrum is referred to as a “conductor” (Crick & Koch, 2005), a “sensory liaison” (Edelstein & Denaro, 2004a), or a multimodal processing “clearinghouse” (Bennett & Baird, 2006), it is clearly involved in the coordination of cortical and sub-cortical pathways on a short and long-distance scale. It is relevant in the study of autism and schizophrenia and other disorders involving a disconnect in higher order psychological functions such as social, language and problem solving (Just et al., 2007). Further studies into its functional activation, cytoarchitecture, and connectivity will undoubtedly lead to a increased understanding of complex global neural systems and perhaps bring us one step closer to determining the center for consciousness (Crick & Koch, 2005).

## References

- Alexander, A. L., Lee, J. E., Lazar, M., Boudos, R., DuBray, M. B., Oakes, T. R., et al. (2007). Diffusion tensor imaging of the corpus callosum in Autism. *Neuroimage*, 34(1), 61-73.
- Amaral, D. G., & Cowan, W. M. (1980). Subcortical afferents to the hippocampal formation in the monkey. *Journal of Comparative Neurology*, 189(4), 573-591.
- Amaral, D. G., & Insausti, R. (1992). Retrograde transport of D-[3H]-aspartate injected into the monkey amygdaloid complex. *Experimental Brain Research*, 88(2), 375-388.
- American Psychiatric Association. (1994). *Diagnostic and Statistical Manual of Mental Disorders - Fourth Edition: DSM-IVTR* (Fourth ed.). Washington, D.C.: American Psychiatric Association.
- Arikuni, T., & Kubota, K. (1985). Claustral and amygdaloid afferents to the head of the caudate nucleus in macaque monkeys. *Neuroscience Research*, 2(4), 239-254.
- Ashburner, J., & Friston, K. J. (2000). Voxel-based morphometry--the methods. *Neuroimage*, 11(6 Pt 1), 805-821.
- Ashburner, J., & Friston, K. J. (2001). Why voxel-based morphometry should be used. *Neuroimage*, 14(6), 1238-1243.
- Ashwell, K. W., Hardman, C., & Paxinos, G. (2004). The claustrum is not missing from all monotreme brains. *Brain, Behavior and Evolution*, 64(4), 223-241.
- Athinoula A. Martinos Center for Biomedical Imaging. (2008, August 5). FreeSurfer Retrieved August 28, 2008, from <http://surfer.nmr.mgh.harvard.edu/fswiki>
- Banati, R. B., Goerres, G. W., Tjoa, C., Aggleton, J. P., & Grasby, P. (2000). The

- functional anatomy of visual-tactile integration in man: a study using positron emission tomography. *Neuropsychologia*, 38(2), 115-124.
- Baron-Cohen, S. (2002). The extreme male brain theory of autism. *Trends in Cognitive Science*, 6(6), 248-254.
- Baron-Cohen, S., & Belmonte, M. K. (2005). Autism: a window onto the development of the social and the analytic brain. *Annual Review of Neuroscience*, 28, 109-126.
- Baron-Cohen, S., Ring, H. A., Wheelwright, S., Bullmore, E. T., Brammer, M. J., Simmons, A., et al. (1999). Social intelligence in the normal and autistic brain: an fMRI study. *European Journal of Neuroscience*, 11(6), 1891-1898.
- Bennett, C. M., & Baird, A. A. (2006). Anatomical changes in the emerging adult brain: a voxel-based morphometry study. *Human Brain Mapping*, 27(9), 766-777.
- Berns, G. S., Chappelow, J., Cekic, M., Zink, C. F., Pagnoni, G., & Martin-Skurski, M. E. (2006). Neurobiological substrates of dread. *Science*, 312(5774), 754-758.
- Bigler, E. D. (2001). Quantitative magnetic resonance imaging in traumatic brain injury. *Journal of Head Trauma Rehabilitation*, 16(2), 117-134.
- Bigler, E. D., Abildskov, T. J., Petrie, J., Johnson, M., Lange, N., Chipman, J., et al. (in press). Volumetric and Voxel-Based Morphometry Findings in Autism Subjects With and Without Macrocephaly. *Developmental Neuropsychology*.
- Bigler, E. D., Blatter, D. D., Anderson, C. V., Johnson, S. C., Gale, S. D., & Hopkins, R. O. (1996). Traumatic Brain Injury and Memory: The Role of Hippocampal Atrophy. *Neuropsychology*, 10(3), 333-342.
- Bigler, E. D., Blatter, D. D., Anderson, C. V., Johnson, S. C., Gale, S. D., Hopkins, R. O., et al. (1997). Hippocampal volume in normal aging and traumatic brain injury.

*AJNR. American Journal of Neuroradiology, 18(1), 11-23.*

Blatter, D. D., Bigler, E. D., Gale, S. D., Johnson, S. C., Anderson, C. V., Burnett, B. M., et al. (1995). Quantitative volumetric analysis of brain MR: normative database spanning 5 decades of life. *AJNR. American Journal of Neuroradiology, 16(2), 241-251.*

Bonilha, L., Cendes, F., Rorden, C., Eckert, M., Dalgalarondo, P., Li, L. M., et al. (2008). Gray and white matter imbalance--typical structural abnormality underlying classic autism? *Brain and Development, 30(6), 396-401.*

Bradley, E. A., & Isaacs, B. J. (2006). Inattention, hyperactivity, and impulsivity in teenagers with intellectual disabilities, with and without autism. *Canadian Journal of Psychiatry. Revue Canadienne de Psychiatrie, 51(9), 598-606.*

Brothers, L., Ring, B., & Kling, A. (1990). Response of neurons in the macaque amygdala to complex social stimuli. *Behavioural Brain Research, 41(3), 199-213.*

Buckner, R. L., Head, D., Parker, J., Fotenos, A. F., Marcus, D., Morris, J. C., et al. (2004). A unified approach for morphometric and functional data analysis in young, old, and demented adults using automated atlas-based head size normalization: reliability and validation against manual measurement of total intracranial volume. *Neuroimage, 23(2), 724-738.*

Castelli, F., Frith, C., Happe, F., & Frith, U. (2002). Autism, Asperger syndrome and brain mechanisms for the attribution of mental states to animated shapes. *Brain, 125(Pt 8), 1839-1849.*

Catani, M., & Mesulam, M. (2008). What is a disconnection syndrome? *Cortex, 44(8), 911-913.*

- Cesaroni, L., & Garber, M. (1991). Exploring the experience of autism through firsthand accounts. *Journal of Autism and Developmental Disorders*, 21(3), 303-313.
- Chachich, M. E., & Powell, D. A. (2004). The role of claustrum in Pavlovian heart rate conditioning in the rabbit (*Oryctolagus cuniculus*): anatomical, electrophysiological, and lesion studies. *Behavioral Neuroscience*, 118(3), 514-525.
- Chambers, R. A., Taylor, J. R., & Potenza, M. N. (2003). Developmental neurocircuitry of motivation in adolescence: a critical period of addiction vulnerability. *American Journal of Psychiatry*, 160(6), 1041-1052.
- Courchesne, E., Carper, R., & Akshoomoff, N. (2003). Evidence of brain overgrowth in the first year of life in autism. *JAMA. Journal of the American Medical Association*, 290(3), 337-344.
- Courchesne, E., & Pierce, K. (2005). Why the frontal cortex in autism might be talking only to itself: local over-connectivity but long-distance disconnection. *Current Opinion in Neurobiology*, 15(2), 225-230.
- Courchesne, E., Pierce, K., Schumann, C. M., Redcay, E., Buckwalter, J. A., Kennedy, D. P., et al. (2007). Mapping early brain development in autism. *Neuron*, 56(2), 399-413.
- Crick, F. C., & Koch, C. (2005). What is the function of the claustrum? *Philosophical Transactions of the Royal Society of London. Series B: Biological Sciences*, 360(1458), 1271-1279.
- Dale, A. M., Fischl, B., & Sereno, M. I. (1999). Cortical surface-based analysis. I. Segmentation and surface reconstruction. *Neuroimage*, 9(2), 179-194.

- Dawson, G., Webb, S. J., Wijsman, E., Schellenberg, G., Estes, A., Munson, J., et al. (2005). Neurocognitive and electrophysiological evidence of altered face processing in parents of children with autism: implications for a model of abnormal development of social brain circuitry in autism. *Development and Psychopathology*, *17*(3), 679-697.
- Dubroff, J. G., Ficicioglu, C., Segal, S., Wintering, N. A., Alavi, A., & Newberg, A. B. (2008). FDG-PET findings in patients with galactosaemia. *Journal of Inherited Metabolic Disease*.
- Duffau, H., Mandonnet, E., Gatignol, P., & Capelle, L. (2007). Functional compensation of the claustrum: lessons from low-grade glioma surgery. *Journal of Neuro-Oncology*, *81*(3), 327-329.
- Edelstein, L. R., & Denaro, F. J. (2004a). The claustrum: a historical review of its anatomy, physiology, cytochemistry and functional significance. *Cellular and Molecular Biology (Noisy-le-grand)*, *50*(6), 675-702.
- Edelstein, L. R., & Denaro, F. J. (2004b). The neurobiology of consciousness and Sir Francis Crick. *Cellular and Molecular Biology (Noisy-le-grand)*, *50*(6), 671-673.
- Ettlinger, G., & Wilson, W. A. (1990). Cross-modal performance: behavioural processes, phylogenetic considerations and neural mechanisms. *Behavioural Brain Research*, *40*(3), 169-192.
- Fernandez-Miranda, J. C., Rhoton, A. L., Jr., Kakizawa, Y., Choi, C., & Alvarez-Linera, J. (2008). The claustrum and its projection system in the human brain: a microsurgical and tractographic anatomical study. *Journal of Neurosurgery*, *108*(4), 764-774.

- Filimonoff, I. N. (1966). The claustrum, its origin and development. *Journal fur Hirnforschung*, 8(5), 503-528.
- Fischl, B., Sereno, M. I., & Dale, A. M. (1999). Cortical surface-based analysis. II: Inflation, flattening, and a surface-based coordinate system. *Neuroimage*, 9(2), 195-207.
- Fletcher, P. C., Happe, F., Frith, U., Baker, S. C., Dolan, R. J., Frackowiak, R. S., et al. (1995). Other minds in the brain: a functional imaging study of "theory of mind" in story comprehension. *Cognition*, 57(2), 109-128.
- Frith, C. (2003). What do imaging studies tell us about the neural basis of autism? *Novartis Foundation Symposium*, 251, 149-166; discussion 166-176, 281-197.
- Frith, U. (2001). Mind blindness and the brain in autism. *Neuron*, 32(6), 969-979.
- Good, C. D., Johnsrude, I. S., Ashburner, J., Henson, R. N., Friston, K. J., & Frackowiak, R. S. (2001). A voxel-based morphometric study of ageing in 465 normal adult human brains. *Neuroimage*, 14(1 Pt 1), 21-36.
- Gunning-Dixon, F. M., Head, D., McQuain, J., Acker, J. D., & Raz, N. (1998). Differential aging of the human striatum: a prospective MR imaging study. *AJNR. American Journal of Neuroradiology*, 19(8), 1501-1507.
- Hadjikhani, N., & Roland, P. E. (1998). Cross-modal transfer of information between the tactile and the visual representations in the human brain: A positron emission tomographic study. *The Journal of Neuroscience*, 18(3), 1072-1084.
- Hardan, A. Y., Kilpatrick, M., Keshavan, M. S., & Minshew, N. J. (2003). Motor performance and anatomic magnetic resonance imaging (MRI) of the basal ganglia in autism. *Journal of Child Neurology*, 18(5), 317-324.

- Hardan, A. Y., Muddasani, S., Vemulapalli, M., Keshavan, M. S., & Minshew, N. J. (2006). An MRI study of increased cortical thickness in autism. *American Journal of Psychiatry, 163*(7), 1290-1292.
- Heimer, L. (2003). A new anatomical framework for neuropsychiatric disorders and drug abuse. *American Journal of Psychiatry, 160*(10), 1726-1739.
- Herbert, M. R., Ziegler, D. A., Deutsch, C. K., O'Brien, L. M., Lange, N., Bakardjiev, A., et al. (2003). Dissociations of cerebral cortex, subcortical and cerebral white matter volumes in autistic boys. *Brain, 126*(Pt 5), 1182-1192.
- Hollander, E., Anagnostou, E., Chaplin, W., Esposito, K., Haznedar, M. M., Licalzi, E., et al. (2005). Striatal volume on magnetic resonance imaging and repetitive behaviors in autism. *Biological Psychiatry, 58*(3), 226-232.
- Huttenlocher, P. R. (1990). Morphometric study of human cerebral cortex development. *Neuropsychologia, 28*(6), 517-527.
- Iarocci, G., & McDonald, J. (2006). Sensory integration and the perceptual experience of persons with autism. *Journal of Autism and Developmental Disorders, 36*(1), 77-90.
- Jack, C. R., Jr., Theodore, W. H., Cook, M., & McCarthy, G. (1995). MRI-based hippocampal volumetrics: data acquisition, normal ranges, and optimal protocol. *Magnetic Resonance Imaging, 13*(8), 1057-1064.
- Jolliffe, T., & Baron-Cohen, S. (1997). Are people with autism and Asperger syndrome faster than normal on the Embedded Figures Test? *Journal of Child Psychology and Psychiatry and Allied Disciplines, 38*(5), 527-534.
- Just, M. A., Cherkassky, V. L., Keller, T. A., Kana, R. K., & Minshew, N. J. (2007).



- Functional and anatomical cortical underconnectivity in autism: evidence from an fMRI study of an executive function task and corpus callosum morphometry. *Cerebral Cortex*, 17(4), 951-961.
- Just, M. A., Cherkassky, V. L., Keller, T. A., & Minshew, N. J. (2004). Cortical activation and synchronization during sentence comprehension in high-functioning autism: evidence of underconnectivity. *Brain*, 127(Pt 8), 1811-1821.
- Kanner, L. (1943). Autistic disturbances of affective contact. *Nervous Child*, 2, 217-250.
- Kievit, J., & Kuypers, H. G. (1975). Basal forebrain and hypothalamic connection to frontal and parietal cortex in the Rhesus monkey. *Science*, 187(4177), 660-662.
- Klauschen, F., Goldman, A., Barra, V., Meyer-Lindenberg, A., & Lundervold, A. (2008). Evaluation of automated brain MR image segmentation and volumetry methods. *Human Brain Mapping*.
- Kowianski, P., Dziewiatkowski, J., Kowianska, J., & Morys, J. (1999). Comparative anatomy of the claustrum in selected species: A morphometric analysis. *Brain, Behavior and Evolution*, 53(1), 44-54.
- Kowianski, P., Morys, J. M., Dziewiatkowski, J., Wojcik, S., Sidor-Kaczmarek, J., & Morys, J. (2008). NPY-, SOM- and VIP-containing interneurons in postnatal development of the rat claustrum. *Brain Research Bulletin*, 76(6), 565-571.
- Kuhl, P. K., Tsao, F. M., & Liu, H. M. (2003). Foreign-language experience in infancy: effects of short-term exposure and social interaction on phonetic learning. *Proceedings of the National Academy of Sciences of the United States of America*, 100(15), 9096-9101.
- Kuwabara, T., Arai, A., Honma, N., & Nishizawa, M. (2005). [Acute encephalopathy

among patients with renal dysfunction after ingestion of "sugihiratake", angel's wing mushroom--study on the incipient cases in the northern area of Niigata Prefecture]. *Rinsho Shinkeigaku. Clinical Neurology*, 45(3), 239-245.

Lainhart, J. E., Lazar, M., Bigler, E. D., & Alexander, A. (2000). The Brain During Life in Autism: Advances in Neuroimaging Research. In M. F. Casanova (Ed.), *Recent Developments in Autism Research* (pp. 55-90). Hauppauge, NY: Nova Biomedical Books.

Langen, M., Durston, S., Staal, W. G., Palmen, S. J., & van Engeland, H. (2007). Caudate nucleus is enlarged in high-functioning medication-naive subjects with autism. *Biological Psychiatry*, 62(3), 262-266.

Lecavalier, L. (2006). Behavioral and emotional problems in young people with pervasive developmental disorders: relative prevalence, effects of subject characteristics, and empirical classification. *Journal of Autism and Developmental Disorders*, 36(8), 1101-1114.

Lerner, A., Bagic, A., Hanakawa, T., Boudreau, E. A., Pagan, F., Mari, Z., et al. (2008). Involvement of Insula and Cingulate Cortices in Control and Suppression of Natural Urges. *Cerebral Cortex*.

Lewis, J. D., & Elman, J. L. (2008). Growth-related neural reorganization and the autism phenotype: a test of the hypothesis that altered brain growth leads to altered connectivity. *Dev Sci*, 11(1), 135-155.

Leyfer, O. T., Folstein, S. E., Bacalman, S., Davis, N. O., Dinh, E., Morgan, J., et al. (2006). Comorbid psychiatric disorders in children with autism: interview development and rates of disorders. *Journal of Autism and Developmental*

*Disorders*, 36(7), 849-861.

- Li, Y. J., Ga, S. N., Huo, Y., Li, S. Y., & Gao, X. G. (2007). Characteristics of hippocampal volumes in healthy Chinese from MRI. *Neurological Research*, 29(8), 803-806.
- Lord, C., Risi, S., Lambrecht, L., Cook, E. H., Jr., Leventhal, B. L., DiLavore, P. C., et al. (2000). The autism diagnostic observation schedule-generic: a standard measure of social and communication deficits associated with the spectrum of autism. *Journal of Autism and Developmental Disorders*, 30(3), 205-223.
- Lord, C., Rutter, M., & Le Couteur, A. (1994). Autism Diagnostic Interview-Revised: a revised version of a diagnostic interview for caregivers of individuals with possible pervasive developmental disorders. *Journal of Autism and Developmental Disorders*, 24(5), 659-685.
- Matus, A., Brinkhaus, H., & Wagner, U. (2000). Actin dynamics in dendritic spines: a form of regulated plasticity at excitatory synapses. *Hippocampus*, 10(5), 555-560.
- McAlonan, G. M., Cheung, V., Cheung, C., Suckling, J., Lam, G. Y., Tai, K. S., et al. (2005). Mapping the brain in autism. A voxel-based MRI study of volumetric differences and intercorrelations in autism. *Brain*, 128(Pt 2), 268-276.
- McAlonan, G. M., Daly, E., Kumari, V., Critchley, H. D., van Amelsvoort, T., Suckling, J., et al. (2002). Brain anatomy and sensorimotor gating in Asperger's syndrome. *Brain*, 125(Pt 7), 1594-1606.
- Medina, L., Legaz, I., Gonzalez, G., De Castro, F., Rubenstein, J. L., & Puelles, L. (2004). Expression of Dbx1, Neurogenin 2, Semaphorin 5A, Cadherin 8, and Emx1 distinguish ventral and lateral pallial histogenetic divisions in the

- developing mouse claustramygdaloid complex. *Journal of Comparative Neurology*, 474(4), 504-523.
- Mendizabal-Zubiaga, J. L., Reblet, C., & Bueno-Lopez, J. L. (2007). The underside of the cerebral cortex: layer V/VI spiny inverted neurons. *Journal of Anatomy*, 211(2), 223-236.
- Minagawa-Kawai, Y., Mori, K., Hebden, J. C., & Dupoux, E. (2008). Optical imaging of infants' neurocognitive development: recent advances and perspectives. *Developmental Neurobiology*, 68(6), 712-728.
- Morys, J., Bobinski, M., Wegiel, J., Wisniewski, H. M., & Narkiewicz, O. (1996). Alzheimer's disease severely affects areas of the claustrum connected with the entorhinal cortex. *Journal fur Hirnforschung*, 37(2), 173-180.
- Morys, J., Narkiewicz, O., & Wisniewski, H. M. (1993). Neuronal loss in the human claustrum following ulegyria. *Brain Research*, 616(1-2), 176-180.
- Naghavi, H. R., Eriksson, J., Larsson, A., & Nyberg, L. (2007). The claustrum/insula region integrates conceptually related sounds and pictures. *Neuroscience Letters*, 422(1), 77-80.
- Naqvi, N. H., Rudrauf, D., Damasio, H., & Bechara, A. (2007). Damage to the insula disrupts addiction to cigarette smoking. *Science*, 315(5811), 531-534.
- Nishizawa, M. (2005). [Acute encephalopathy after ingestion of "sugihiratake" mushroom]. *Rinsho Shinkeigaku. Clinical Neurology*, 45(11), 818-820.
- Nomoto, T., Seta, T., Nomura, K., Shikama, Y., Katagiri, T., Katsura, K., et al. (2007). A case of reversible encephalopathy accompanied by demyelination occurring after ingestion of Sugihiratake mushrooms. *Journal of Nippon Medical School*, 74(3),

261-264.

- O'Neill, M., & Jones, R. S. (1997). Sensory-perceptual abnormalities in autism: a case for more research? *Journal of Autism and Developmental Disorders*, 27(3), 283-293.
- Olson, I. R., Gatenby, J. C., & Gore, J. C. (2002). A comparison of bound and unbound audio-visual information processing in the human cerebral cortex. *Brain Research. Cognitive Brain Research*, 14(1), 129-138.
- Pearson, R. C., Brodal, P., Gatter, K. C., & Powell, T. P. (1982). The organization of the connections between the cortex and the claustrum in the monkey. *Brain Research*, 234(2), 435-441.
- Pedraza, O., Bowers, D., & Gilmore, R. (2004). Asymmetry of the hippocampus and amygdala in MRI volumetric measurements of normal adults. *Journal of the International Neuropsychological Society*, 10(5), 664-678.
- Pickles, A., Bolton, P., Macdonald, H., Bailey, A., Le Couteur, A., Sim, C. H., et al. (1995). Latent-class analysis of recurrence risks for complex phenotypes with selection and measurement error: a twin and family history study of autism. *American Journal of Human Genetics*, 57(3), 717-726.
- Risch, N., Spiker, D., Lotspeich, L., Nouri, N., Hinds, D., Hallmayer, J., et al. (1999). A genomic screen of autism: evidence for a multilocus etiology. *American Journal of Human Genetics*, 65(2), 493-507.
- Rutter, M. (1978). Diagnosis and definition of childhood autism. *Journal of Autism and Childhood Schizophrenia*, 8(2), 139-161.
- Salmond, C. H., Ashburner, J., Vargha-Khadem, F., Connelly, A., Gadian, D. G., & Friston, K. J. (2002). Distributional assumptions in voxel-based morphometry.

*Neuroimage*, 17(2), 1027-1030.

- Schulkin, J. (2007). Autism and the amygdala: an endocrine hypothesis. *Brain and Cognition*, 65(1), 87-99.
- Sorra, K. E., & Harris, K. M. (2000). Overview on the structure, composition, function, development, and plasticity of hippocampal dendritic spines. *Hippocampus*, 10(5), 501-511.
- Spahn, B., & Braak, H. (1985). Percentage of projection neurons and various types of interneurons in the human claustrum. *Acta Anatomica*, 122(4), 245-248.
- Sperner, J., Sander, B., Lau, S., Krude, H., & Scheffner, D. (1996). Severe transitory encephalopathy with reversible lesions of the claustrum. *Pediatric Radiology*, 26(11), 769-771.
- Stein, M. B., Simmons, A. N., Feinstein, J. S., & Paulus, M. P. (2007). Increased amygdala and insula activation during emotion processing in anxiety-prone subjects. *American Journal of Psychiatry*, 164(2), 318-327.
- Testa, C., Laakso, M. P., Sabbatoli, F., Rossi, R., Beltramello, A., Soininen, H., et al. (2004). A comparison between the accuracy of voxel-based morphometry and hippocampal volumetry in Alzheimer's disease. *Journal of Magnetic Resonance Imaging*, 19(3), 274-282.
- Tsatsanis, K. D. (2003). Outcome research in Asperger syndrome and autism. *Child and Adolescent Psychiatric Clinics of North America*, 12(1), 47-63, vi.
- Tsatsanis, K. D., Rourke, B. P., Klin, A., Volkmar, F. R., Cicchetti, D., & Schultz, R. T. (2003). Reduced thalamic volume in high-functioning individuals with autism. *Biological Psychiatry*, 53(2), 121-129.

- Voelbel, G. T., Bates, M. E., Buckman, J. F., Pandina, G., & Hendren, R. L. (2006). Caudate nucleus volume and cognitive performance: Are they related in childhood psychopathology? *Biological Psychiatry*, *60*(9), 942-950.
- World Health Organization. (1995). International Classification of Diseases, Tenth Revision. *Epidemiological Bulletin*, *16*(1), 14-16.
- Zhang, X., Hannesson, D. K., Saucier, D. M., Wallace, A. E., Howland, J., & Corcoran, M. E. (2001). Susceptibility to kindling and neuronal connections of the anterior claustrum. *Journal of Neuroscience*, *21*(10), 3674-3687.

## APPENDIX A

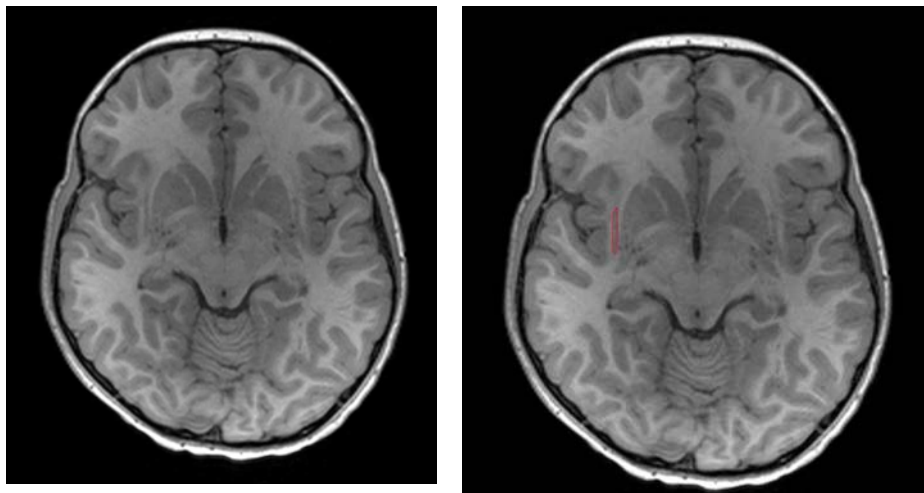
### Clastrum Tracing Protocol



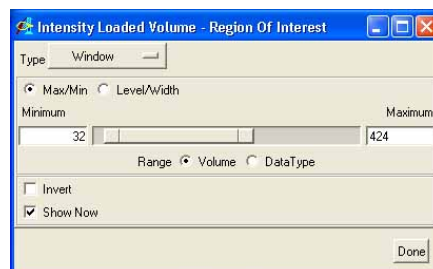
## Clastrum (CI) Protocol:

### Axial Tracing

- Open the 3d scan volume in the “Region of Interest” program in Analyze.
- Double the size of the image by going to view – size then clicking the “double” radio button.
- Start out in the axial view and find a good slice where the CI is continuous and easy to distinguish (usually around slice 315\*).



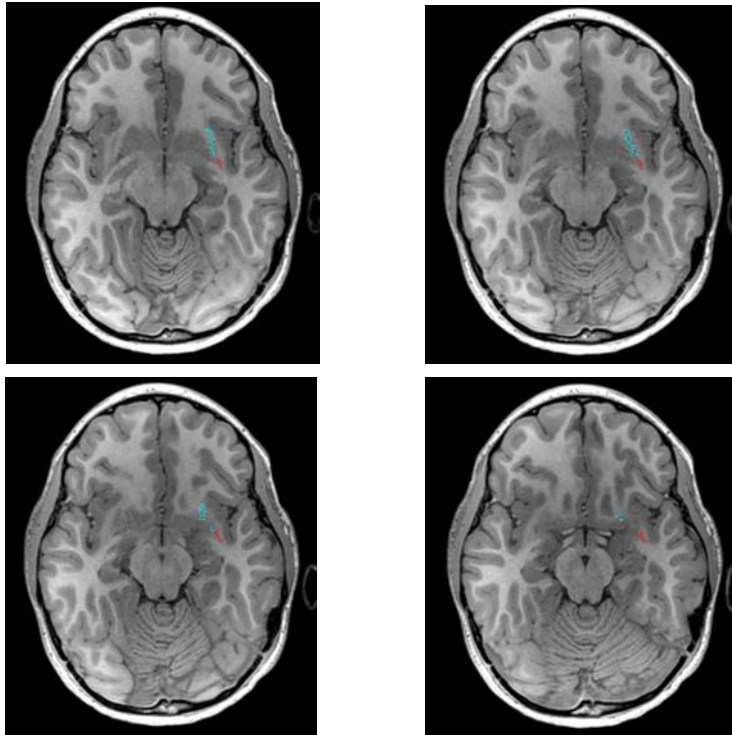
- Adjust the intensity (view – intensity). You want the CI to stand out as much as possible. You may adjust the intensity again to better visualize the CI as you move through the different slices and in different orientations but for the most part you can use the same intensity throughout the tracing. It may be a good idea to record the intensity you used in case you have to retrace the scans later.




---

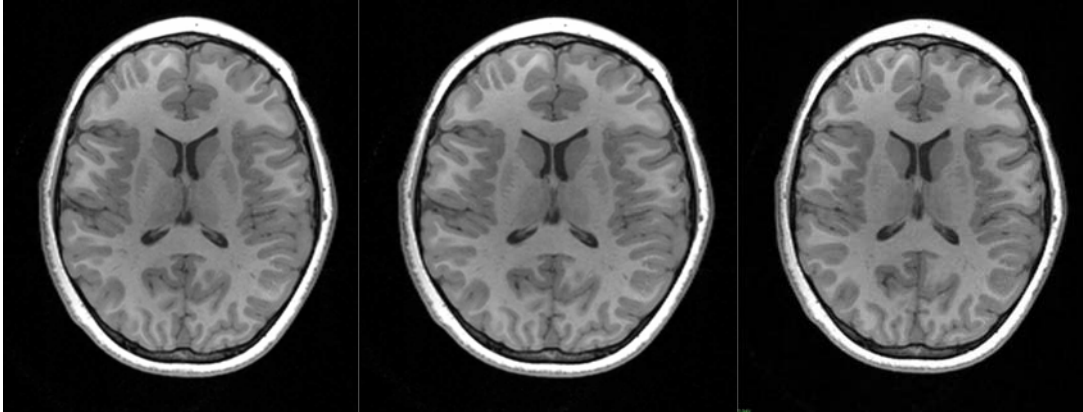
\* If images are too small you can view this document on the CD provided and enlarge the images in question. The training CD also has three example brains with object maps.

- Begin tracing the CI. You want to trace it as close to the borders as possible because the line itself is counted as “object” when you sample the images. (When you look at the tracing you shouldn’t see any non-CI within the tracing. For really thin CI sections you can trace up and back on the same line – meaning that the tracing is only one pixel wide. While you’re tracing, keep in mind that once the trace is complete it seems to expand a little.)
- Proceed to trace the CI ventrally (in the “-” or “back” direction) until it can no longer be distinguished. Sometimes the ventral CI (vCI) is distinguishable in the axial view, and sometimes it isn’t (see also the description of the ventral CI below).



Axial images: left to right and top to bottom (dorsal to ventral) showing the tracing of the CI (blue) and vCI (red). It’s advantageous to trace as much of the CI as you can positively identify in the axial view.

- Go back to your start point (around slice 315) and trace the CI as far dorsal as possible.
- The dorsal stopping point is the very last slice where the putamen still has a definite, continuous and distinct lateral boundary. The average number of slices in the axial view (after accounting for the coronal tracings) is about 63.



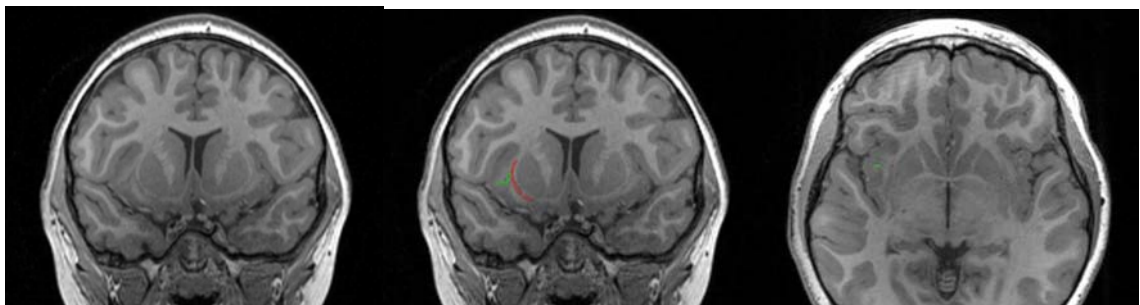
Axial images: left to right (ventral to dorsal) sequence showing the lateral boundary of the left putamen becoming less distinct and continuous. Stop point is the middle image.

#### Tips:



- If you set the “object to define” on “original” and the “intersections become part of:” to “defined” you can use the trace as an eraser to adjust your tracings.

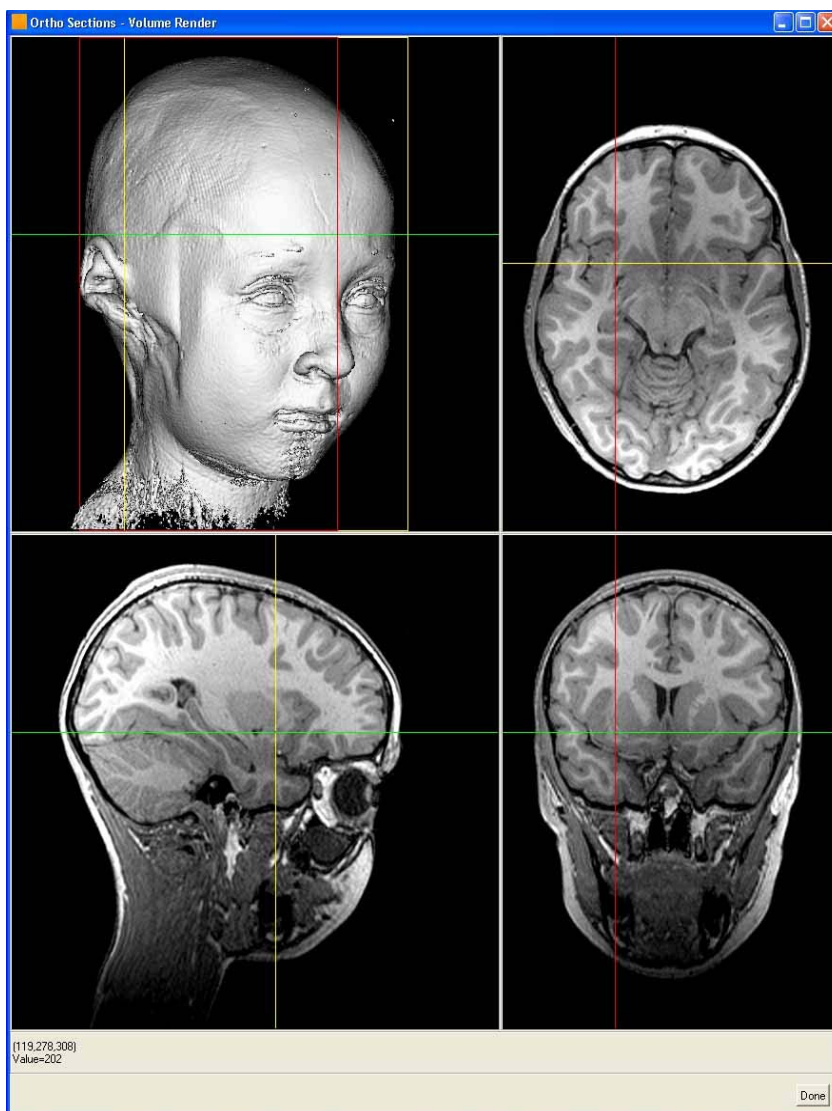


- Pressing “t” turns the traces off. It is usually a good idea to turn the tracings off any time you make an adjustment so the CI and other structures can be seen clearly.
- Pressing “l” turns the object labels off.
- Don’t trace any striations from the putamen or any parts of the CI that appear to be “fingers” or “wishbones”.

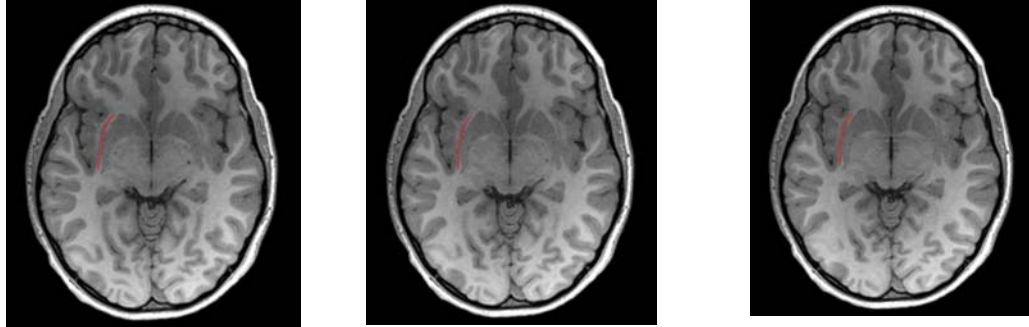


Images left to right: “wishbone” of right CI shown. The CI is traced in red and the questionable “wishbone” in green. Axial view showing why the green tracing is non-CI (insula).

- If you have definition questions you can load the volume into the “Volume Render” (Display – Volume Render; or  and then use the “Ortho Tool” (Tools – Display – Ortho sections; or ) to allow you to navigate the volume in each of the three planes. Using this tool you can also magnify just the coronal and axial views (use the right mouse button on the image). The three numbers on the bottom left of the window correspond to slice number in each of the three planes – usually (sagittal, coronal, axial).

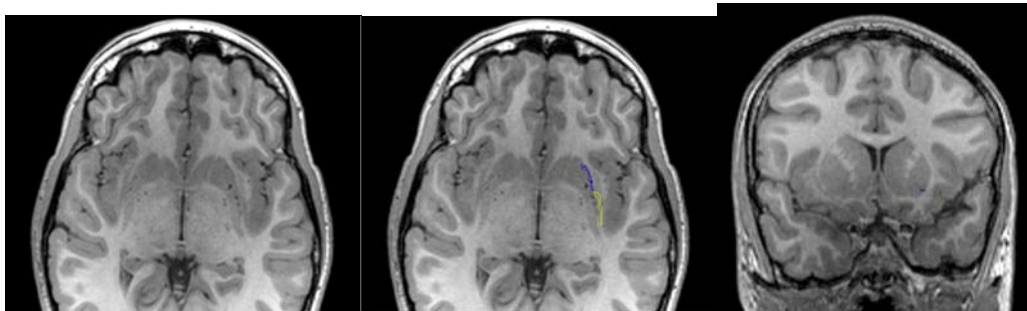


- When tracing the CI through a general area of equal intensity and you know there's definitely CI in there somewhere but that the CI is probably not the whole area just trace through the area keeping the CI about the same width as where the CI enters and exits the questionable area. It may show up better in the other orientation.



Axial Images: left to right (ventral to dorsal) showing proper tracing of CI.

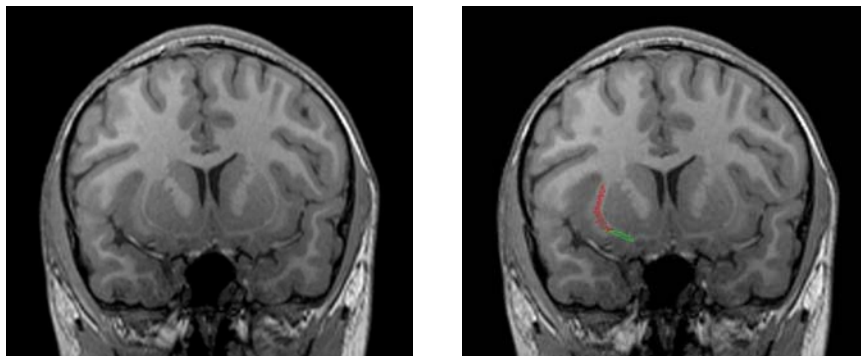
- If the CI appears to dip into or merge with the putamen do not define it as CI. The putamen boundary is a crescent shape that can easily be extended even when intensity differences are minor. The CI should not be defined anywhere within putamen boundaries.



Axial images showing the correct tracing when the CI appears to dip into the putamen. The correct CI is defined in yellow and the non-CI is blue (both images are the same slice). The coronal image on the far right confirms the blue tracing as putamen. Also note that these images do not show the full tracing of the CI, more CI is defined when the tracing is done in the coronal view.

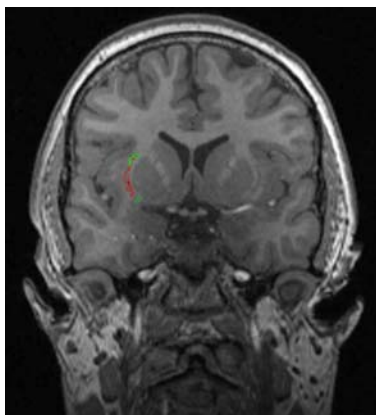
### Coronal Tracing

- After tracing the CI in the axial view, trace it in the coronal view. For the most part, the CI in the coronal view should be pretty much traced besides two main parts – the ventral CI (which is more caudal) and a part of the claustrum that extends under the putamen (towards the rostral end).
- Start towards the rostral end on a slice where the CI is pretty well defined and continuous (usually around slice 280)



Coronal Images: Same slice showing a good starting point for the coronal tracings. Right: the axial traces are in red and the new coronal tracing is in green. These images show the CI as it extends below the putamen.


- Trace the claustrum working your way rostrally (in the “+” direction). You shouldn’t have to worry about where to stop because the end points are usually better visualized in the axial view.
- Go back to your start point and now trace the CI towards the caudal end (in the “-” direction). Pay attention to the CI as it folds under the putamen. Also there may be places where you fill in the “gaps” from your axial tracing. Pay attention to the CI as it extends dorsally, usually these faint signals are best visualized in the coronal plane.



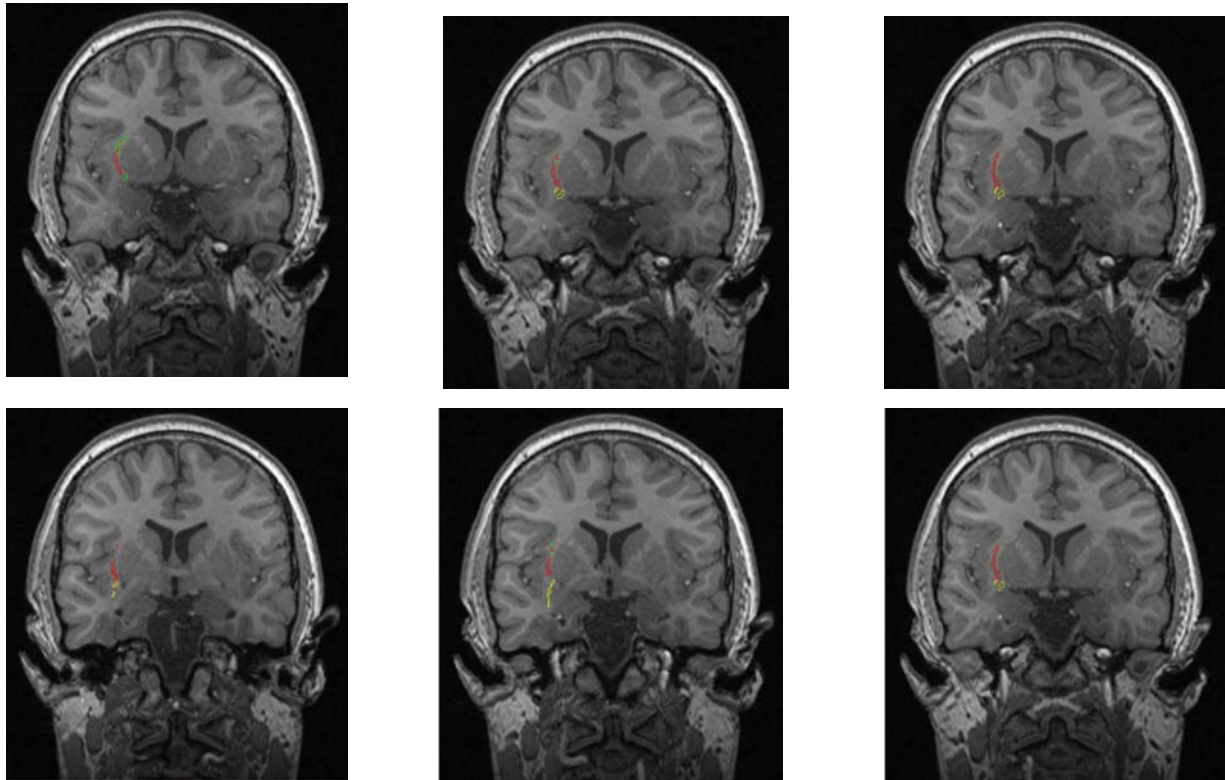
Coronal image showing the axial tracings in red and the coronal tracings in green. Notice the dorsal CI that was best identified in the coronal view.



### Ventral Claustrum (vCl)

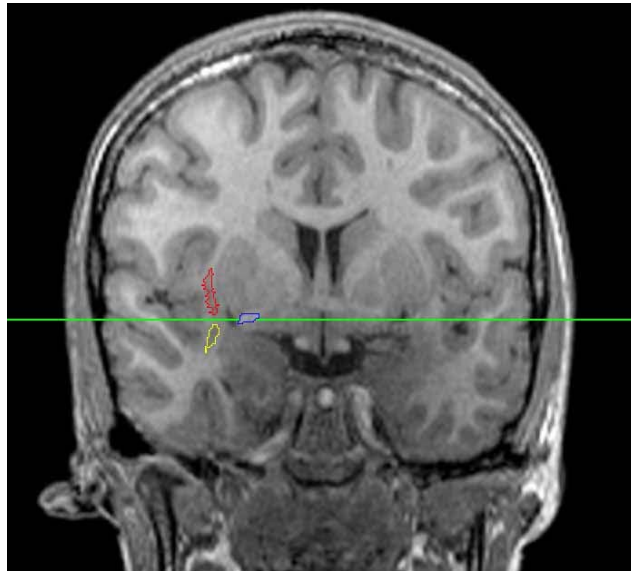
There are some keys to determining the vCl. You'll need to use a new "object" to trace the vCl. If you were able to trace parts of the vCl in the axial view you'll need to change the object to vCl. You can do this by using the "rename object" button -  - and then by adjusting then tracings. Unlike the other parts of the brain, you will need to adjust the tracings of the vCl from the axial tracings so that the trace is accurate according to the coronal view.

- The vCl is defined when the body of the Cl hooks back medially.



Coronal images: rostral to caudal (left to right top then left to right bottom) showing definition of the vCl (yellow). Notice how the vCl is first defined when it starts to hook back laterally in the opposite direction of the Cl body.


- Most of the vCl is seen when the temporal stem is also present.
- In most scans, the vCl is disconnected from the body of the Cl.
- The anterior commissure (AC) can also be used to help identify the vCl. As the AC heads laterally and is just over the amygdala (before it extends into the temporal stem) you can usually draw a straight line between the body of the Cl and the vCl.

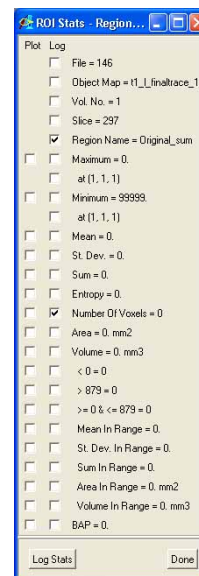
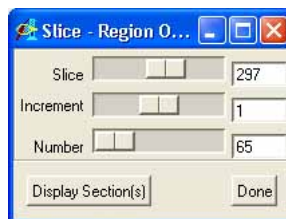
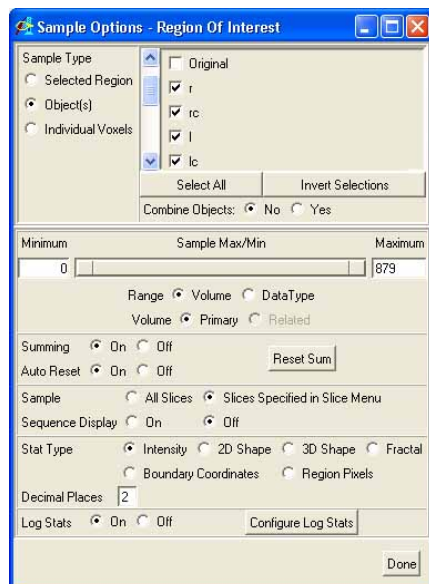


Coronal image showing the body of the Cl (red), vCl (yellow), AC (blue) and line through the AC showing the separation of the Cl body and vCl.

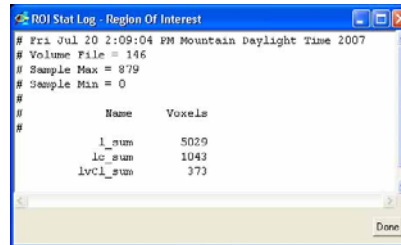


## Collecting Data

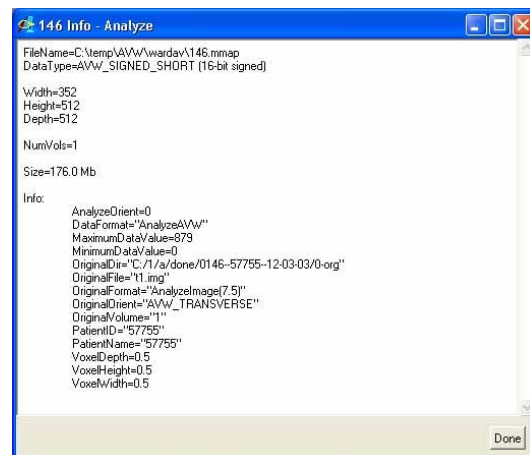
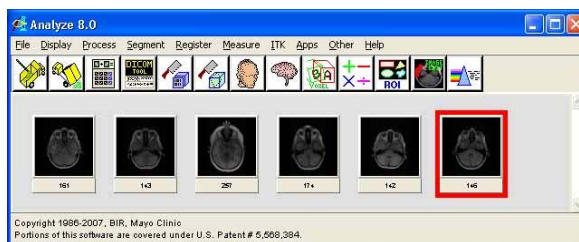
- In the ROI module, go to Sample Options (Generate – Sample Options; or ).
- Click on the “Objects” radio button in the “Sample Type” box.
- Select the Objects you created or click on “Select All”.
- Turn “Summing” to “On”
- “Slice specified in Slice menu” should be selected and the slice menu should have the correct number of slices to be sampled. To get the number of slices to be sampled go to the axial view in the ROI and find the first slice where the CI is defined. The stop point is determined by the indistinct lateral putamen boundary (see explanation and images above). Be sure that the viewer is in the axial view before sampling; if it’s in the coronal view the slices sampled will be wrong.
- It may be helpful to turn the “Sequence Display” to “off” so that the sampling is faster.
- Turn “Log Stats” to “On” and then click on “Configure Log Stats”
- Select the “Region Name” and “Number of Voxels” radio button on “Log Stats”



- Go back to the ROI screen and hit “Sample Images” on the left of the window.
- A typical printout out should look like this (I used two different objects for the left CI traced in the axial view (l) and the left CI traced in the coronal view (lc). This isn't necessary but if you also use two separate objects be sure to combine them when recording the voxel count for the CI body):



- The printout is a voxel count. In order to obtain a volume you need to multiply the number of voxels by the voxel dimensions. Voxel dimensions can be found by going to the main Analyze window and right clicking the volume then selecting “info”. At the bottom of the printout under “VoxelDepth”, “VoxelHeight”, and “VoxelWidth” are the voxel dimensions in mm. For this volume, the voxel volume would be  $(.5\text{mm})^3$  or  $.125\text{mm}^3$ .

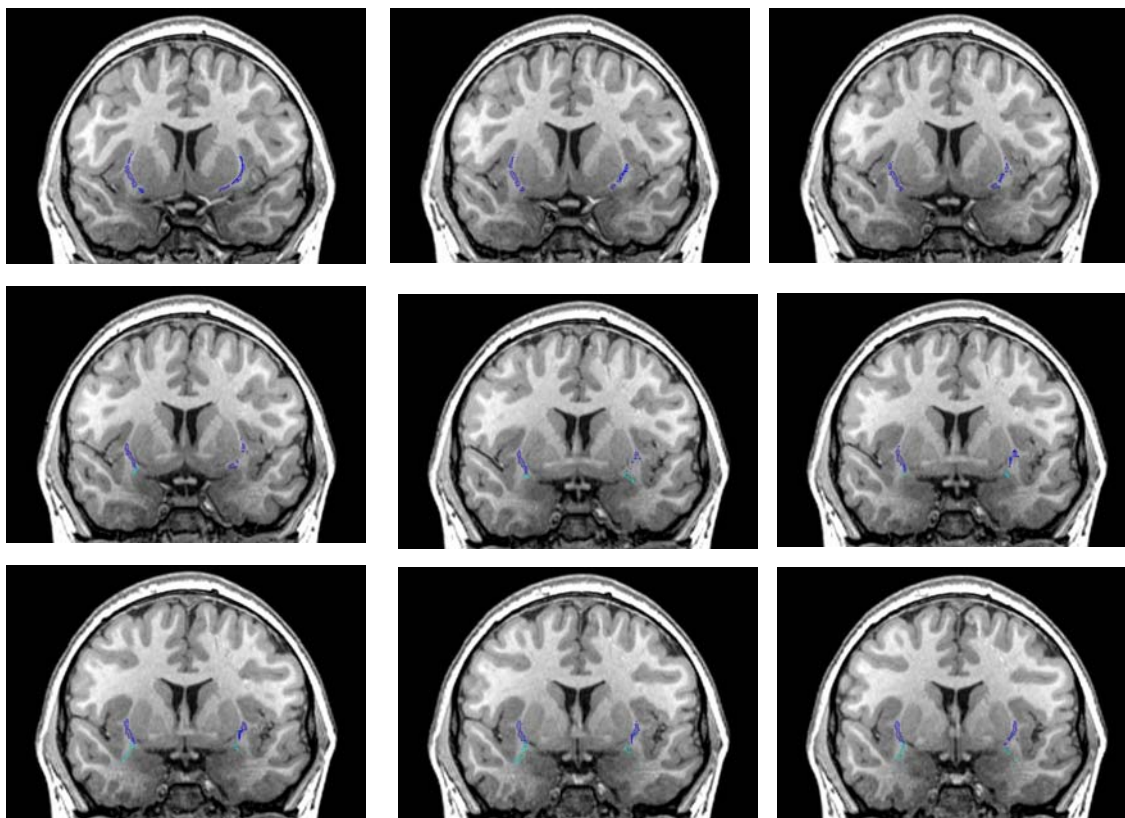


- Now you can multiply your voxel count by the voxel volume to obtain the volume of the right and left CI and vCI.

**Addendum A:**Ventral CI in the Extended Amygdala

In hindsight it appears that the vCI as it traverses through the extended amygdala was not properly identified in every brain. Therefore, the following addition to the protocol is necessary for future tracings of the vCI.

In the coronal view, there are usually five to eight slices where the CI transitions from lying ventral to the putamen to extending out into the temporal stem. The transition occurs as the CI merges with nearby gray matter (the extended amygdala), and then emerges in the white matter of the temporal stem. This transition is can be more difficult to distinguish in some brains. The same determinants used to identify the vCI from the CI body outlined previously still apply.



## APPENDIX B

### Data and Statistics

Clastrum Volumes (mm<sup>3</sup>)

| Brain | Dvlpmnt | rCl     | lCl      | RvCl   | lvCl   | r ttl Cl | l ttl Cl |
|-------|---------|---------|----------|--------|--------|----------|----------|
| 130   | 0       | 713.06  | 716.00   | 116.63 | 103.81 | 829.69   | 819.81   |
| 134   | 0       | 631.31  | 461.06   | 19.75  | 24.69  | 651.06   | 485.75   |
| 135   | 0       | 653.38  | 579.81   | 44.63  | 43.44  | 698.00   | 623.25   |
| 137   | 1       | 492.75  | 457.06   | 61.13  | 36.69  | 553.88   | 493.75   |
| 142   | 0       | 865.44  | 739.50   | 73.63  | 77.75  | 939.06   | 817.25   |
| 143   | 0       | 736.25  | 634.25   | 89.31  | 61.50  | 825.56   | 695.75   |
| 146   | 0       | 859.69  | 824.75   | 85.88  | 45.88  | 945.56   | 870.63   |
| 148   | 0       | 951.56  | 933.63   | 112.31 | 87.38  | 1063.88  | 1021.00  |
| 150   | 0       | 559.25  | 613.19   | 51.44  | 27.69  | 610.69   | 640.88   |
| 151   | 0       | 571.44  | 587.94   | 22.50  | 10.31  | 593.94   | 598.25   |
| 161   | 0       | 887.19  | 774.38   | 59.56  | 71.00  | 946.75   | 845.38   |
| 174   | 1       | 991.94  | 1035.75  | 99.50  | 94.31  | 1091.44  | 1130.06  |
| 183   | 1       | 488.63  | 545.25   | 29.81  | 37.50  | 518.44   | 582.75   |
| 200   | 1       | 720.63  | 641.31   | 71.38  | 69.75  | 792.00   | 711.06   |
| 201   | 1       | 790.81  | 650.63   | 68.75  | 42.44  | 859.56   | 693.06   |
| 204   | 0       | 879.19  | 669.06   | 112.88 | 66.31  | 992.06   | 735.38   |
| 214   | 1       | 246.13  | 257.75   | 29.38  | 41.94  | 275.50   | 299.69   |
| 217   | 1       | 793.25  | 668.88   | 71.38  | 58.44  | 864.63   | 727.31   |
| 218   | 1       | 825.25  | 635.94   | 107.50 | 42.44  | 932.75   | 678.38   |
| 221   | 1       | 628.44  | 576.06   | 95.38  | 100.31 | 723.81   | 676.38   |
| 229   | 0       | 719.94  | 474.50   | 82.69  | 49.94  | 802.63   | 524.44   |
| 230   | 1       | 467.69  | 560.69   | 51.75  | 28.06  | 519.44   | 588.75   |
| 231   | 1       | 594.38  | 441.06   | 52.13  | 69.56  | 646.50   | 510.63   |
| 233   | 1       | 408.625 | 313.88   | 19.375 | 20.00  | 428      | 333.88   |
| 241   | 1       | 387.625 | 394.3125 | 24.625 | 7.3125 | 412.25   | 401.625  |
| 244   | 0       | 645.50  | 608.25   | 69.25  | 69.56  | 714.75   | 677.81   |
| 250   | 0       | 737.19  | 590.56   | 79.31  | 95.88  | 816.50   | 686.44   |
| 251   | 1       | 472.50  | 394.50   | 66.44  | 55.38  | 538.94   | 449.88   |
| 257   | 1       | 587.06  | 565.81   | 81.81  | 65.88  | 668.88   | 631.69   |
| 259   | 1       | 403.88  | 335.88   | 30.00  | 16.69  | 433.88   | 352.56   |

Table 1: volumes (mm<sup>3</sup>) averaged from the two tracings. Dvlpmnt = development (0 = Typical Development; 1 = autism). rCl = right caudate body; lCl = left caudate body; rvCl = right ventral caudate; lvCl = left ventral caudate; r ttl Cl = right total caudate (caudate body + ventral caudate); l ttl Cl = left total caudate.

## Total Intracranial Volume

| Brain | ID | Age | TICV (mm <sup>3</sup> ) |
|-------|----|-----|-------------------------|
| 130   | 0  | 9   | 1678748.213             |
| 134   | 0  | 10  | 1580609.677             |
| 135   | 0  | 8   | 1461629.768             |
| 137   | 1  | 12  | 1563532.529             |
| 142   | 0  | 9   | 1493364.193             |
| 143   | 0  | 12  | 1275110.05              |
| 146   | 0  | 12  | 1527994.098             |
| 148   | 0  | 10  | 1614090.114             |
| 150   | 0  | 7   | 1457414.841             |
| 151   | 0  | 12  | 2014479.405             |
| 161   | 0  | 12  | 1350100.852             |
| 174   | 1  | 12  | 1733227.61              |
| 183   | 1  | 9   | 1399819.313             |
| 200   | 1  | 11  | 1665264.8               |
| 201   | 1  | 8   | 1868469.381             |
| 204   | 0  | 12  | 1934357.382             |
| 214   | 1  | 9   | 1386497.425             |
| 217   | 1  | 11  | 1740261.415             |
| 218   | 1  | 9   | 1598395.251             |
| 221   | 1  | 10  | 1337718.087             |
| 229   | 0  | 8   | 1353776.386             |
| 230   | 1  | 9   | 1383446.135             |
| 231   | 1  | 12  | 1675429.612             |
| 233   | 1  | 11  | 1504813.114             |
| 241   | 1  | 11  | 1709843.11              |
| 244   | 0  | 10  | 1553715.049             |
| 250   | 0  | 11  | 1612552.719             |
| 251   | 1  | 11  | 1417218.735             |
| 257   | 1  | 10  | 1507186.592             |
| 259   | 1  | 10  | 1674113.457             |

Table 2: Total Intracranial Volume obtained using Free Surfer Version3. Age in years. 0 = typical development; 1 = autism.

|                                | TD      | Autism  |
|--------------------------------|---------|---------|
| Average TICV(mm <sup>3</sup> ) | 1564.85 | 1572.83 |
| Average Age (years)            | 10.14   | 10.31   |

TD = typical development; TICV = total intracranial volume

**Volume Averages (mm<sup>3</sup>)**

|                            |       | <b>Cl body</b> | <b>vCl</b> | <b>ttl Cl</b> |
|----------------------------|-------|----------------|------------|---------------|
| <b>Typical Development</b> | Left  | 657.63         | 59.65      | 717.29        |
|                            | Right | 743.60         | 83.03      | 845.22        |
| <b>Autism</b>              | Left  | 529.67         | 49.17      | 578.84        |
|                            | Right | 581.22         | 60.02      | 641.24        |

**Standard Deviations**

|                            |       | <b>Cl body</b> | <b>vCl</b> | <b>ttl Cl</b> |
|----------------------------|-------|----------------|------------|---------------|
| <b>Typical Development</b> | Left  | 130.24         | 27.54      | 145.61        |
|                            | Right | 125.93         | 30.95      | 148.00        |
| <b>Autism</b>              | Left  | 187.3189       | 26.37521   | 204.5829      |
|                            | Right | 198.5135       | 27.93177   | 221.848       |

**Two-Tailed Independent Samples t-test**

|                 | <b>T</b> | <b>df</b> | <b>Sig.</b> |
|-----------------|----------|-----------|-------------|
| <b>rCl</b>      | -2.629   | 28        | 0.014       |
| <b>rvCl</b>     | -1.193   | 28        | .243        |
| <b>r ttl Cl</b> | -2.505   | 28        | 0.018       |
| <b>lCl</b>      | -2.141   | 28        | 0.041       |
| <b>lvCl</b>     | -1.064   | 28        | 0.296       |
| <b>l ttl Cl</b> | -2.106   | 28        | 0.044       |

Two-Tailed Independent Samples t-test showing differences between typical development and autism. r = right; l = left; v = ventral; Cl = claustrum; ttl = total.

**Hemispheric Differences (Paired samples t-test)**

|                            | <b>TD (<i>r</i>)</b> | <b>TD (<i>p</i>)</b> | <b>Autism (<i>r</i>)</b> | <b>Autism (<i>p</i>)</b> |
|----------------------------|----------------------|----------------------|--------------------------|--------------------------|
| <b>rCl - lCl</b>           | 0.762                | 0.003                | 0.915                    | 0.021                    |
| <b>rvCl - lvCl</b>         | 0.776                | 0.027                | 0.739                    | 0.043                    |
| <b>r ttl Cl - l ttl Cl</b> | 0.809                | 0.001                | 0.918                    | 0.012                    |

Two-Tailed Paired samples t-test showing correlations (*r*) and significance (*p*) of hemispheric differences between right and left claustral volumes. TD = typical development; r = right; l = left; v = ventral; Cl = claustrum; ttl = total