



All Theses and Dissertations

2016-03-01

Semantic and Syntactic Processing in a Patient with Left Temporal Lobe Damage Secondary to Traumatic Brain Injury: An fMRI Study

Caitlin Moizer

Brigham Young University - Provo

Follow this and additional works at: <https://scholarsarchive.byu.edu/etd>

 Part of the [Communication Sciences and Disorders Commons](#)

BYU ScholarsArchive Citation

Moizer, Caitlin, "Semantic and Syntactic Processing in a Patient with Left Temporal Lobe Damage Secondary to Traumatic Brain Injury: An fMRI Study" (2016). *All Theses and Dissertations*. 5802.

<https://scholarsarchive.byu.edu/etd/5802>

This Thesis is brought to you for free and open access by BYU ScholarsArchive. It has been accepted for inclusion in All Theses and Dissertations by an authorized administrator of BYU ScholarsArchive. For more information, please contact scholarsarchive@byu.edu, ellen_amatangelo@byu.edu.

Semantic and Syntactic Processing in a Patient with Left Temporal Lobe Damage Secondary
to Traumatic Brain Injury: An fMRI Study

Caitlin Moizer

A thesis submitted to the faculty of
Brigham Young University
in partial fulfillment of the requirements for the degree of

Master of Science

David McPherson, Chair
C. Brock Kirwan
Richard Harris

Department of Communication Disorders

Brigham Young University

March 2016

Copyright © 2016 Caitlin Moizer

All Rights Reserved

ABSTRACT

Semantic and Syntactic Processing in a Patient with Left Temporal Lobe Damage Secondary to Traumatic Brain Injury: An fMRI Study

Caitlin Moizer

Department of Communication Disorders, BYU
Master of Science

The ability of the brain to change and form new neuropathways after brain injury is remarkable. The current study investigates the brains ability to form new pathways for language processing following traumatic brain injury (TBI), specifically a left temporal lobectomy. Two subjects participated in this study; one participant with TBI and one age-matched control. Sentence stimuli consisted of four types: semantically correct, semantically incorrect, syntactically correct, and syntactically incorrect. Participants underwent a fMRI scan while the auditory stimuli were presented in four blocks. Participants were asked to record if the sentence was correct or incorrect by pressing the corresponding button. It was found that reaction times for both the participant with TBI and the control were longer for the incorrect conditions. The participant with TBI generally had longer reaction times compared to the control participant and had more errors. During the fMRI scans, patient movement occurred. The block design was not set up to account for movement. Due to this factor, imaging results are questionable. While there were differences between the participant with TBI and the control participant, these differences are expected to be much larger in someone with this degree of brain injury. It is recommended for further studies to be conducted in this area with a revised block design to account for patient movement.

Keywords: functional magnetic resonance imaging, neuroplasticity, semantic processing, syntactic processing, traumatic brain injury, reaction time

ACKNOWLEDGMENTS

I am grateful for the opportunity I have had to complete this thesis. It has been a long road, but ultimately a rewarding one. I could not have completed this thesis without the support of my family and friends. I am grateful for their constant support and encouragement. I would also like to thank my thesis committee for their patience, hard work, and guidance.

TABLE OF CONTENTS

LIST OF TABLES	vi
LIST OF FIGURES	vii
LIST OF APPENDICES	viii
DESCRIPTION OF STRUCTURE AND CONTENT	ix
Introduction	1
Functional Magnetic Resonance Imaging	1
Language Processing	1
Syntactic processing	1
Semantic processing	3
Neuroplasticity	4
Purpose	8
Method	8
Participants	8
Participant with traumatic brain injury	8
Details of the trauma	9
Language deficits, rehabilitation, and recovery	10
Current levels of functioning	12
Age-matched control participant	12
Stimuli	13
Instrumentation	14
Sentence recording instrumentation	14
Functional magnetic resonance imaging	14
Procedure	15
Stimuli preparation	15
Data presentation	15
Data Analysis	16
Results	17
Reaction time	17
Imaging	23
Discussion	23

References.....27

LIST OF TABLES

Table	Page
1. Descriptive Statistics for Reaction Time (ms) for the Control Participant	17
2. Descriptive Statistics for Reaction Time (ms) for the TB Participant	18
3. Computation of the Binaural Interaction, in ms, within and between the Two Participants.....	22

LIST OF FIGURES

Figure	Page
1. Initial neuroimaging of TB	9
2. Bar chart showing the standard deviation for RTs for each condition in both the control participant and the traumatic brain injured participant	19
3. Plot of RT for both the control participant and the traumatic brain injury patient as a function of condition	20
4. Scattergram of RT for all conditions	21
5. Bar chart of RT differences (TB – CP) for all conditions.....	22
6. Bar chart of errors for each participant and the difference between (CP-TB) the two participants	23

LIST OF APPENDICES

Appendix	Page
A. Sentence Stimuli	30
B. Informed Consent to Act as a Human Research Subject	36
C. BYU MRI Research Facility Screening Form	39
D. Annotated Bibliography.....	42

DESCRIPTION OF STRUCTURE AND CONTENT

The body of the thesis, *Semantic and Syntactic Processing in a Patient with Left Temporal Lobe Damage Secondary to Traumatic Brain Injury: An fMRI Study*, was written as a manuscript suitable for submission to a peer-reviewed journal in speech-language pathology. Appendix A includes the list of sentences used as stimuli during this study. Appendix B includes the consent form for the participants of this study. Appendix C includes a preliminary questionnaire filled out by the participants of the study. Appendix D includes an annotated bibliography. Level of evidence in the annotated bibliography was determined by the following guidelines; Level I: Evidence obtained from a systematic review of the majority (more than one) of relevant randomized control trials (meta-analysis). Level II: Evidence obtained from at least one well-designed randomized control trial. Level III (a): Evidence obtained from well-designed controlled trials without randomization. Level III (b): Evidence from well-designed cohort or case-controlled analytic studies, preferably from multiple clinical programs or research centers. Level III (c): Evidence from multiple time series, with or without intervention, showing dramatic results from uncontrolled research. Level IV: Opinions of respected authorities, based on clinical experience, descriptive studies or reports of expert committees.

Introduction

Language processing has been the topic of extensive research. Much research has used neuroimaging techniques, including functional magnetic resonance imaging (fMRI), to investigate the cortical regions involved in language processing and how language processing occurs. This study investigated the brain's ability to adapt and change following partial removal of the left temporal lobe following traumatic brain injury (TB). The participant with TB in the current study was able to recover remarkable amounts of language abilities over the course of five years. This study incorporates fMRI to describe the alternate pathways used by this individual to compensate for anatomical damage to language processing areas in the brain.

Functional Magnetic Resonance Imaging

In recent years, functional magnetic resonance imaging has become a widespread form of neuroimaging. Kim and Bandettini (2006) state, "Functional magnetic resonance imaging (fMRI) is a very powerful method to map brain functions with relatively high spatial and temporal resolution" (p. 4). In addition to high resolution, fMRI is noninvasive in its ability to observe brain activity. Brain activity is distinguished by depicting changes in blood oxygenation in the brain over time. As a result, fMRI has been used to map functions in specific brain regions (Huettel, Song, & McCarthy, 2009). The current study will use fMRI to examine brain regions activated when processing semantic and syntactic stimuli.

Language Processing

Syntactic processing. Syntactic processing is defined as the comprehension of sentences by understanding the grammatical structure, as well as the integration of lexical, semantic, and pragmatic information within the sentence structure. The brain has the capacity to store and retrieve received syntactic input with working, or short-term, memory (Marinis, 2009).

Studies have shown there are multiple brain regions involved in syntactic processing. For example, Broca's area, which is defined as the area located around the left inferior frontal gyrus (IFG) and is primarily responsible for speech production (Fedorenko, Nieto-Castanon, & Kanwisher, 2011). In a study conducted by Carramazza and Zurif (1976), they were able to show that individuals who suffered from Broca's aphasia had difficulty interpreting atypical noun structure. Fedorenko, Nieto-Castañón, and Kanwisher (2011) state that areas in or around the IFG respond more strongly to syntactically complex stimuli than other brain regions, which is indicative of the role Broca's area plays in syntactic processing (Fedorenko, et al., 2011).

In addition to Broca's area, regions of the left and right posterior temporal lobe have also been known to play a role in syntactic processing. Grodzinsky and Friederici (2006) found that these areas are critical in the integration of incoming linguistic and nonlinguistic stimuli to evolving syntactic structures.

Noppeney and Price (2004) conducted a study demonstrating the role of the left anterior temporal lobe (ATL) during syntactic processing, specifically syntactic priming, which is defined as processing that occurs when a sentence has the same syntactic form as a preceding sentence. They used fMRI as a physiological measure, in addition to behavioral measures to study syntactic priming during silent sentence reading. Both physiological and behavioral measures demonstrated that reading time and ATL activation were reduced when consecutive sentences were syntactically similar. Because ATL activation is reduced when processing syntactically similar sentences, ATL activation is increased during the comprehension of more complex sentence structure (Noppeney & Price).

The ATL also contributes to lexical and sentence level processing. Wilson et al. (2014) compared the activation of the ATL during sentence comprehension and word comprehension

using positron emission tomography (PET) and fMRI scans. Participants were asked to perform an auditory sentence-to-picture matching task while being scanned using fMRI. There were seven conditions which varied in complexity and length of sentence. Results suggested that activation rates of the ATL were much higher during the comprehension of sentences compared to just reading lists of words. The Wilson et al. study also demonstrated that ATL activation relates more to higher level syntactic processing than just basic syntactic structure building.

Semantic processing. Semantic processing is defined as the retrieval and understanding of word meanings and how the brain integrates those meanings into the context of a given sentence (Huang, Wang, Jia, Mo, & Chen, 2013). The two main operations of semantic processing are accessing the word meanings and the integration into the context of the sentence. These operations interact and overlap to increase message levels in sentences (Rommers, Dijkstra, & Bastiaansen, 2013).

Studies using PET and fMRI have demonstrated that the left posterior middle temporal gyrus is primarily responsible for the retrieval of word meanings. But, it is still unclear which regions of the brain are used in the integration of those word meanings into sentence context. However, additional studies have shown evidence of activation of the left inferior frontal gyrus and the left anterior temporal lobe in fMRI scans. Also, these activation patterns demonstrate great variability across studies due to the interaction of different semantic processes in the brain (Huang, et al., 2013). Huang et al. studied 15 participants that were placed in a sound booth and read a total of 500 sentences, which were a mixture of experimental and filler sentences. Participants were instructed to determine if a sentence was plausible by pressing the corresponding button on a response pad. Results demonstrated that activation patterns reflected the activation of the left inferior frontal gyrus and the left anterior temporal lobe. Further, the

results also demonstrated that lexical-semantic retrieval occurs before the integration of word meanings, which leads to sentence comprehension (Huang, et al., 2013).

Neuroplasticity

Plasticity is defined as an ongoing process within the nervous system. This process occurs when changes in input or stimuli to the brain, which is often the result of brain injury or damage, cause a cellular reorganization in the nervous system (Villamar, Portilla, Fregni, & Zafonte, 2012). The plasticity process occurs when there is redirection of neural pathways to complete brain functions damaged by brain injury. Evidence of neuroplasticity has been seen in individuals with brain damage caused by TB, stroke, or other causes. Neuroplasticity is viewed as the brain's mechanism to provide compensatory brain function due to injury.

Brain function recovery resulting from neuroplasticity has been known to occur in three stages. According to Villamar et al. (2012), the first stage to recover brain function activates cell repair, which reduces the swelling and inflammation in the brain. This stage generally occurs during the first three weeks after a brain injury. Common symptoms during this stage are brain edema and inflammation.

The second stage of neuroplasticity, or subacute stage, is where plasticity occurs. The brain modifies properties of previously existing neural networks and brain anatomy to create new connections and form new neural pathways. Villamar et al. (2012) describe studies identifying two processes that occur during the subacute stage of neural plasticity. The first of these processes is termed long-term potentiation (LTP). Following high frequency stimulation to elicit excitatory processes to the glutamatergic synapses of the motor cortex, LTP occurs when stimuli normally producing short-term effects produce long lasting strength to particular areas of the brain and synapses. Changes made to damaged sets of neurons are made without affecting other

functioning sets of synapses. The second process occurring in the subacute stage is long-term depression (LTD). This has the opposite effect of LTP, where stimuli meant to produce long-term effects bring about short-term effects to particular areas of the brain and synapses. Like LTP, changes made to damaged sets of neurons are also made without damaging preexisting functioning sets of synapses. Both LTP and LTD begin with modification of previous neural networks and are later complemented with anatomical changes. Together, LTP and LTD play important roles in attention, memory, and learning following brain injury (Villamar et al., 2012).

The third stage of neuroplasticity, or the acute stage, is most prominent during the first three months following brain injury. During the acute stage, plasticity and myelination are the most important factors in the reorganization of neural networks and pathways. The greatest brain recovery generally occurs during the subacute and acute stages (Villamar et al., 2012).

Grafman (2000) identifies four different types of neuroplasticity. The first type is called homologous area adaptation. This generally occurs during early stages of human brain development. Homologous area adaptation follows the idea that when damage occurs to a particular developing brain region, the brain functions performed in that region shift to another area of the brain that has not been affected by the damage. As a result of the function shift, this new brain area tends to become crowded with various brain functions. These crowded brain areas lead to a poor representation of shifting functions. In addition, when two functions from the same brain area occur simultaneously, there is a greater likelihood of dual-task interference. For example, Grafman conducted a study focusing on an adolescent who incurred a right parietal lobe injury. It was found that the left parietal lobe adopted function from the damaged right parietal lobe. The adolescent had intact visuospatial skills, but impaired arithmetic skills. Because of homologous area adaptation, the “spatial processes had claimed the left parietal

region before arithmetic instruction, making it much more difficult for the patient to learn and store arithmetic facts” (p. 346). Further, fMRI studies of the adolescent demonstrated activation of the left parietal lobe during mathematical processing even though visuospatial processing is the primary function of the left parietal lobe.

The next type of neuroplasticity identified by Grafman (2000) is called cross-modal reassignment, which involves introduction of new inputs into a representational brain region that has been deprived of its main inputs. For example, a study using fMRI and PET scans to examine brain activation areas in blind participants showed that those who have been blind since childhood have somatosensory input redirected to an area in the occipital lobe that was not activated in the control participant’s scans. Representations in the occipital lobe are viewed as an abstract form, where the actual functions are independent of the method of input. However, it is suspected there are limitations to the feasibility of cross modal reassignment as a type of neuroplasticity. For example, the occipital cortex is specialized for visual input so it would be unlikely to accept additional forms of input.

The third type of neuroplasticity is known as map expansion, which demonstrates the flexibility of brain regions devoted to a particular kind of knowledge or cognitive operation (Grafman, 2000). Recent work reveals that the size of cortical maps can expand or enlarge with practice or frequent exposure to stimuli. Two specific experiments conducted by Grafman found that implicit learning of a visuomotor sequence caused the cortical map to expand during the early stages of implicit learning. After the learning became explicit, map size decreased to baseline size. The meaning of map expansion as a form of neuroplasticity is still unclear. However, two possible implications exist. The first implication is that cortical regions specific to particular functions can expand into other brain regions responsible for other functions. The

second implication is that when the input process is unclear, the entire cortical network needs to be active. If the process is selected, less network energy is utilized (Grafman).

The fourth type of neuroplasticity identified by Grafman (2000) is called compensatory masquerade, which occurs when tasks that are dependent on impaired cognitive processes occur despite the damage. There are two ways the brain can process information: implicitly and explicitly. Implicit tasks, which are suggested without being directly established, are processed quite rapidly, while explicit tasks, which are clearly demonstrated, require more energy and are processed more slowly. When brain injury occurs, both implicit and explicit processes are affected but in many situations, one is spared. Patients with brain injury can use the spared process to develop pathways once used by the impaired processing over time. An additional study demonstrated that after traumatic brain injury, functional plasticity may be amplified by cognitive remediation, behavior modification, and some pharmacological approaches (Lu, Mahmood, & Chopp, 2003).

Magnetic resonance imaging (MRI) studies have also found evidence of plasticity in the brain following TBI. An MRI was used to monitor the changing processes during rehabilitation to treat the TBI. It was found that when participants were learning a new skill, grey matter volume increased in task-relevant areas of the brain. Also, in patients diagnosed with Broca's aphasia, it was found that white matter volume increased in the right arcuate fasciculus area after participating in speech rehabilitation. Ultimately, MRI studies could be used to look at the endpoint after brain injury rehabilitation is completed. These studies would focus on brain anatomy and body function level (Nordvik et al., 2014).

In conclusion, numerous studies have found evidence of neuroplasticity. These studies have used brain imaging techniques to demonstrate the brain's remarkable capabilities to adapt to change upon injury and damage.

Purpose

The aim of the present study was to describe the plasticity of the brain after traumatic brain injury when processing syntactic and semantic stimuli. Behavioral data collected included reaction time (RT) and error rates. Functional MRIs were used to identify the presence of functional differences in location and extent of brain activity in response to auditory processing of dichotic stimuli with varying levels of linguistic complexity.

Method

Participants

This study included two participants: one participant (TB) with a TBI resulting in a partially removed left temporal lobe, and one age-matched control participant (CP). Data collected from fMRI scans of each participant were compared. Differences in patterns of activation were noted.

Participant with traumatic brain injury. Participant TB is a 47-year-old male, native speaker of English who sustained a TBI at the age of 41. At 18 years old, he completed the extent of his education at 12th grade. Prior to the TBI, TB worked as a self-employed electrical contractor and electrician. There was no reported history of neurologic or language deficits. The TBI occurred during an assault, where TB received blows to both the left and right sides of his head. He sustained bilateral skull fractures, with the left fracture being depressed in the anterior temporal region and the right fracture being linear, starting in the posterior temporal region and extending to the posterior parietal region. TB's initial neuroimaging scans are depicted in Figure

1. Images include a computed tomography (CT) scan, which was performed on the day of trauma (left image) and an MRI performed six weeks posttrauma (right image). Both images are in radiologic view. The depressed skull fracture can be seen in the lower right quadrant of the CT scan. The dark spot on the lower right quadrant of the MRI scan is indicative of a partially removed left temporal lobe.

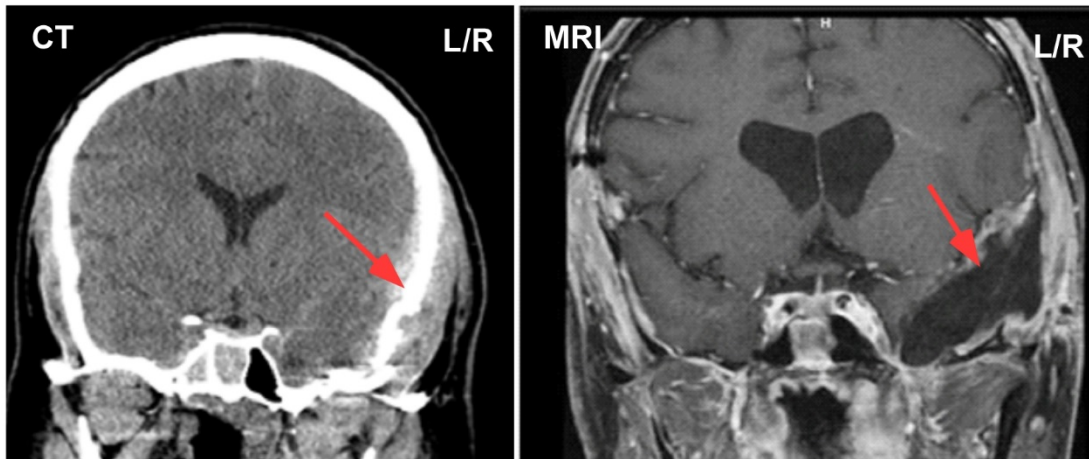


Figure 1. Initial neuroimaging of TB. Day of trauma CT scan (left image). The depressed skull fracture can be seen in the lower right quadrant of the CT scan. Six weeks posttrauma MRI (right image). The dark spot in the bottom left quadrant of the MRI is indicative of a partially removed left temporal lobe (image orientation is left to right, L/R).

Details of the trauma. When TB first arrived at the emergency room of a local hospital, his Glasgow Coma scale rating was 13. Multiple neurosurgical procedures were performed within the first few hours after injury. Original CT scans revealed serious intracranial hemorrhage, including an acute subdural hematoma on the left side and an acute epidural hematoma on the right side. The right side hematoma was the first to be treated due to its life threatening nature. However, when the right hematoma was evacuated, it caused the left side hematoma to continue to hemorrhage due to the release of pressure on the right side. The left side hematoma was then evacuated. Because of the depressed skull fracture on the left side, part of the left temporal lobe

was macerated so a partial temporal lobectomy was performed. The portion of the lobe that was removed included the temporal pole, but spared the medial temporal lobe and hippocampal area. The evacuation of both hematomas and the temporal lobectomy were performed within one day posttrauma. Two days posttrauma, a left orbitotomy was also performed, which included drainage of the hemorrhage and depression of the left medial wall. Sixteen days posttrauma, TB was admitted to the rehabilitation unit of the hospital and was discharged home 28 days posttrauma. TB received follow up CT and MRI scans two months posttrauma. These scans demonstrated cerebral atrophy, temporal lobe encephalomalacia, which is a localized softening of brain matter, and ventriculomegaly, which is dilation of the lateral ventricles. Also, it was noted that there was extensive damage to the white matter of his brain.

Language deficits, rehabilitation, and recovery. During his first visit with a speech language pathologist 16 days posttrauma, TB responded less than 30% of the time and was not in a state to be formally evaluated. He received informal assessment using specific questions from the Boston Diagnostic Aphasia Examination (BDAE; Goodglass, Kaplan, & Baressi, 2001). TB demonstrated severe receptive aphasia with a 0/5 severity rating, with no usable speech or comprehension. Three days following the original visit, the SLP reported no change. TB was then diagnosed with severe Wernicke's aphasia and continued to receive speech therapy during his stay at the hospital. Twenty-eight days posttrauma, TB was formally assessed with the Boston Diagnostic Aphasia Examination (BDAE).

During the administration of the BDAE, TB scored an overall severity rating of 1 on a 5 point scale. The speech pathology discharge summary reads as follows:

Patient is able to understand and ID a few pictures, does very well with numbers and letters and colors [sic]. Naming results in paraphasia and extended paraphasia with rare

accuracy even after cueing. Repetition is more intact, but not usually accurate on the first try. Reading is moderately impaired. Patient was able to demonstrate some comprehension of words and short sentences. He has prolific paraphasia and seems unaware of this. Patient does not respond to repetition [of paraphasias] by others, [nor does he respond to] trial recordings of himself [producing paraphasias].

After discharge from the rehabilitation unit of the hospital, TB continued to receive speech and language therapy at the hospital's outpatient clinic. He was seen three times a week for 50 minutes per session. In his first outpatient therapy session, it was noted that TB had made mild improvement since discharge. Notes from 35 days posttrauma stated

There have been small improvements in just the past six days, with improvement in sentence length in spontaneous utterances. Improvement in repetition is most pronounced. There is some mild improvement in comprehension, particularly of identification of nouns, but also with more complex yes/no questions. There is improvement in automatic speech. There are no overt changes in naming of nouns; however, the patient clearly names letters at this time, which he was unable to do prior. There are small improvements in reading ability, particularly word to picture matching, which improved dramatically, but also comprehension and oral reading have improved mildly.

During this initial outpatient session, TB was asked to describe the cookie theft picture as a part of the BDAE. A transcription of TB's verbal response when asked to describe the picture from the BDAE reads as follows:

Well she's got her // supelin ladys reaking all over the sandals/ the birds sleeping over the top and the evelins getting tigh into a play coveerse so they can get into a plesterin// condie. So it's just a big mess. That's it. She's doing one/ thing of sandiv super

// right in front of the / sendive slindos her/ tartblackfor. Little boy and a little girl are using that // ah/ tanor with the sando to get the crust n sand. She's erleventh; she can't see what's real and what's happening.

TB provided a description of the same picture six months posttrauma. It reads as follows:

Mother at kitchen sink and daughter and son at cookie jar on top of the crow and mother in water problem. She is washing dices [sic]. She can't see them. The boy is stealing the cook's. If he is not careful the stool will fall.

After discharge from the rehabilitation unit of the hospital, TB continued to receive outpatient therapy at the local hospital to treat his language and cognitive deficits. It was reported that TB stopped attending outpatient speech therapy sessions eight months posttrauma; however, a formal discharge from speech therapy was never reached (Bailey, 2014).

Current levels of functioning. At the time this study was conducted, 4.5 years posttrauma, TB was self-employed as an electrician, which was his pretrauma employment. Anecdotal evidence reports that TB continues to display executive functioning deficits, including organization and prioritization. He also reports difficulty with word finding and repetition of complex sentences. Paraphasias are no longer present and speech is fluent and coherent (Bailey, 2014).

Age-matched control participant. CP is a 51-year-old male, native speaker of English, with no prior history of neurological or language deficits. CP served as an age-matched control participant.

Prior to fMRI testing, each participant read and signed an informed consent document approved by the Institutional Review Board at Brigham Young University (Appendix B).

Stimuli

Stimuli conditions included four levels of linguistic complexity: syntactically correct sentences, syntactically incorrect sentences, semantically correct sentences, and semantically incorrect sentences. A total of 360 sentences were presented to both subjects. Four blocks, consisting of three groups of thirty sentences each were presented at a comfortable listening level to the participants. In each block, the groups of sentences (semantically correct, semantically incorrect, syntactically correct, and syntactically incorrect) were randomized and did not occur consecutively. Each group was also presented in three formats: left ear only, right ear only, and binaurally. In each group, the errors occurred in various parts of the sentence. Examples of the sentences are listed below (and the complete set in Appendix A):

No Syntactic Error

1. The dog ran down the street.
2. They painted both the books red.
3. The child laughed at the clown.
4. She returned the damaged computer.

Syntactic Error

1. The dog runned down the street.
2. They painting the book red.
3. The child laugh at the clown.
4. She return the damaged computer.

No Semantic Error

1. The green frog jumped.
2. The rough rock was coarse to the touch.

3. The soft fur felt like silk.
4. The museum was very interesting.

Semantic Error

1. The colorless green frog jumped.
2. The rough rock was smooth to the touch.
3. The soft fur felt like gravel.
4. The museum was very interested.

To isolate sentence pairs into individual WAV files with simultaneous onset times, the recording and editing software Audacity version 2.0.5 (Audacity, 2013) was used.

Instrumentation

Sentence recording instrumentation. Sentences were digitally recorded by an adult, female, native speaker of English. The signal was recorded in a sound treated room using a Larson Davis 1.27 cm model 2541 microphone attached to a Larson Davis model 900 microphone preamplifier. A 7.62 cm foam windscreen was used on the microphone at 0 degrees azimuth. The microphone preamplifier was attached to a Larson Davis model 2200 preamplifier power supply. The audio signal was digitized with 24-bit quantization and a 44.1 kHz sample rate using a Benchmark ADC1 analog-to-digital converter (Benchmark Media Systems). The digital output of the Benchmark ADC1 (Benchmark Media Systems) was routed to the digital input of a SADiE (Studio Audio & Video Limited, 2004) digital editing station using version 5.5.4 software. Files were then saved as 24-bit wav files.

Functional magnetic resonance imaging. Magnetic resonance imaging was performed with a Siemens TIM-TRIO 3.0T MRI scanner using a 12-channel head coil at the Brigham Young University MRI research facility. Before echo-planar image (EPI) acquisition, a T1-

weighted magnetization-prepared rapid gradient echo (MP-RAGE) sequence, (echo time = 2.08 ms, flip angle = 8°) was used to acquire an image formed from 176 slices (1.0 mm thick, matrix size = 224 x 256, field of view 219 x 250 mm, voxel size = .98 x .98 x 1 mm). Functional data were collected in 4 EPI scan runs that ranged from 446 s to 506 s (echo time = 28 ms, flip angle = 90°, repetition time = 2000 ms) with 39 slices (3 mm thick, 64 x 64 matrix size, field of view 192 x 192 mm, voxel size = 3 x 3 x 3 mm) (Hyatt, 2015).

Procedure

Stimuli preparation. Stimuli were presented in 12 pseudo-randomized blocks using e-prime (Schneider, Eschman, & Zuccolotto, 2012). Three blocks each of syntactically correct, syntactically incorrect, semantically correct, and semantically incorrect were pseudo-randomly presented. Each stimuli type were also presented in the left ear only, right ear only, and binaurally. Blocks of sentences consisted of 30 stimuli. Order of stimulus presentation in each block was pseudorandomized such that there was no repetition of a stimulus in the same block. There were a total of 360 sentence presentations.

Data presentation. On the day of the fMRI scanning, both participants completed an MRI safety screening form (see Appendix C) and reviewed their responses with a trained operator. Before beginning the test, they were read the following script:

You will hear a number of sentences and will determine whether or not the sentence makes sense or does not make sense. Press button 1 if the sentence makes sense and press button 2 if the sentence does not make sense.

Participants were then situated in the MRI scanner with headphones. They were given the participant alarm bulb, the response pad, and fitted with an array of mirrors to allow them to comfortably view a screen that allowed participants to view instructions and the response options

on a screen. Participants were instructed to hold the response pad in the right hand such that the index finger was placed on button one and the middle finger on button two. While the localization scan and structural scan were being completed, a practice block was presented to familiarize participants with the task. First a screen appeared that read as follows:

Welcome to the experiment. You will hear a number of sentences and will determine whether or not the sentence makes sense or does not make sense. Press button 1 if the sentence makes sense and press button 2 if the sentence does not make sense.

Before each block was presented, a screen was shown for ten seconds that informed the participant to wait for the next block. Baseline hemodynamic activation data were collected during this time. A run in the MRI scanner included four blocks followed by a screen that said *end of block*. After each run, the operator checked on the participant's comfort level and gave them an opportunity to relax.

Stimuli within sentence blocks were presented in a 2500 ms time window. A fixation cross was shown in the center of the screen during stimulus presentation. Response options were then presented for 1000 ms. Response options were pseudo-randomized so that button one would represent the stimulus correct in some blocks and stimulus incorrect in other blocks.

Data Analysis

Descriptive statistics were used for each condition (syntactically correct, syntactically incorrect, semantically correct, and semantically incorrect) and ear (left, right, and binaural).

Reaction time was recorded for all responses. The means, standard deviation, and range of RT to each condition were analyzed and plots constructed. Responses had to occur between the response window of 250 and 800 ms. Error rates were determined and reported for each condition.

Functional MRI data were analyzed using Analysis of Functional NeuroImages (Cox, 1996) and SPSS was used to generate statistical reports. Functional scans were slice time corrected to account for acquisition time differences between slices within a single repetition time (TR; the time between successive pulse sequences applied to the same slice). The TRs containing significant motion events were excluded from the analysis and movement across runs were accounted for. To achieve spatial normalization, the structural scans from all participants were fit to a standard brain mask using Advanced Neuroimaging Tools (ANTs). Single-subject regression analyses were conducted by creating six motion regressors (coding for three translations and three rotations) and 12 behavioral regressors coding for right ear, left ear, and binaural in each condition of semantic and syntactic condition (i.e., correct and incorrect).

Results

Reaction Time

Descriptive statistics for RT for the control participant (CP) are reported in Table 1. RTs were generally longer for incorrect conditions.

Table 1

Descriptive Statistics for Reaction Time (ms) for the Control Participant

Ear	Condition	<i>M</i>	<i>SD</i>	Minimum	Maximum
Left	Semantic Correct	419.05	114.04	258	577
Left	Semantic Incorrect	503.69	147.83	278	730
Left	Syntactic Correct	369.67	197.37	253	926
Left	Syntactic Incorrect	388.27	144.45	251	688
Right	Semantic Correct	472.57	152.50	263	630
Right	Semantic Incorrect	419.89	139.35	289	721
Right	Syntactic Correct	357.27	116.68	225	629
Right	Syntactic Incorrect	464.67	21.39	440	478
Binaural	Semantic Correct	433.88	114.43	260	689
Binaural	Semantic Incorrect	482.55	193.97	173	855
Binaural	Syntactic Correct	335.42	64.62	256	446
Binaural	Syntactic Incorrect	298.67	210.34	100	519

Descriptive statistics for RT for the participant with TBI (TB) are listed in Table 2. It was noted that RTs were generally longer for the incorrect conditions and is illustrated in Figure 2.

Table 2

Descriptive Statistics for Reaction Time (ms) for the TB Participant

Ear	Condition	<i>M</i>	<i>SD</i>	Minimum	Maximum
Left	Semantic Correct	515.63	172.43	380.00	779.00
Left	Semantic Incorrect	515.63	152.03	278.00	727.00
Left	Syntactic Correct	491.00	80.91	418.00	578.00
Left	Syntactic Incorrect	565.00	210.73	422.00	807.00
Right	Semantic Correct	536.17	171.23	311.00	733.00
Right	Semantic Incorrect	530.37	153.89	263.00	770.00
Right	Syntactic Correct	416.00	86.06	270.00	478.00
Right	Syntactic Incorrect	508.00	304.06	293.00	723.00
Binaural	Semantic Correct	406.63	144.76	295.00	707.00
Binaural	Semantic Incorrect	564.56	137.66	351.00	734.00
Binaural	Syntactic Correct	581.00	140.61	438.00	757.00
Binaural	Syntactic Incorrect	663.00	4.24	660.00	666.00

The bar chart (Figure 2) generally indicates that reactions times for participant TB are longer than for CP. This difference appears more pronounced in the binaural condition than in either left or right monaural condition. This is further evidenced in Figure 3 where all of the RT latencies for participant TB are prolonged.

Figure 4 is a scattergram of the RTs of participant TB x CP. Note the cluster embedded in the dashed circle. This cluster represents, from right to left, the RT of the binaurally presented incorrect syntactic sentences, the right presented correct semantic sentences, the right incorrect syntactic sentences, and the left semantic incorrect sentences. In addition, Figure 4 shows that the binaurally presented incorrect syntactic sentences were the slowest response (663 ms) for the participant TB.

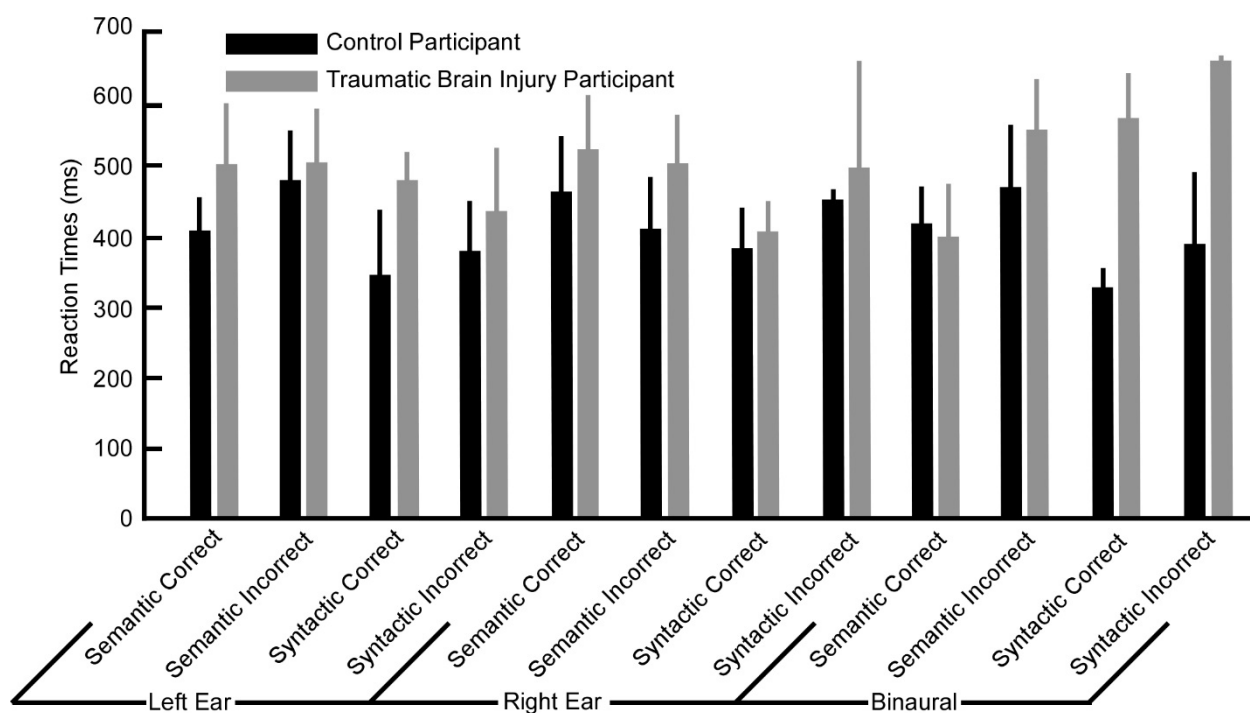


Figure 2. Bar chart showing the standard deviation for RTs for each condition in both the control participant and the traumatic brain injured participant.

An additional bar chart, Figure 5, shows the difference values between participants CP and TB (TB-CP). Of particular note is the greater RT differences for the binaurally presented syntactic sentences as well for the left ear presented correct syntactic sentences. This is also observed in Figures 2 and 3.

Table 3 shows the computation of the contribution of the binaural pathway. This was accomplished by taking the sum of the left and right ear responses in ms and subtracting them from the binaural response in ms (McPherson & Starr, 1993; McPherson, Tures & Starr, 1989). The results of the binaural interaction and percent binaural interaction may be considered a measure of bias subtended by right or left ear presentation of the sentences. As such, for participant TB, the syntactic incorrect sentences show a strong error bias towards right ear

presentation (69.64%). Likewise, for participant TB, processing of syntactic correct sentences show an error bias towards right ear presentation (64.06%). As can be seen in Table 3, processing of syntactic information require 19 to 23 ms more processing time in participant TB than in participant CP.

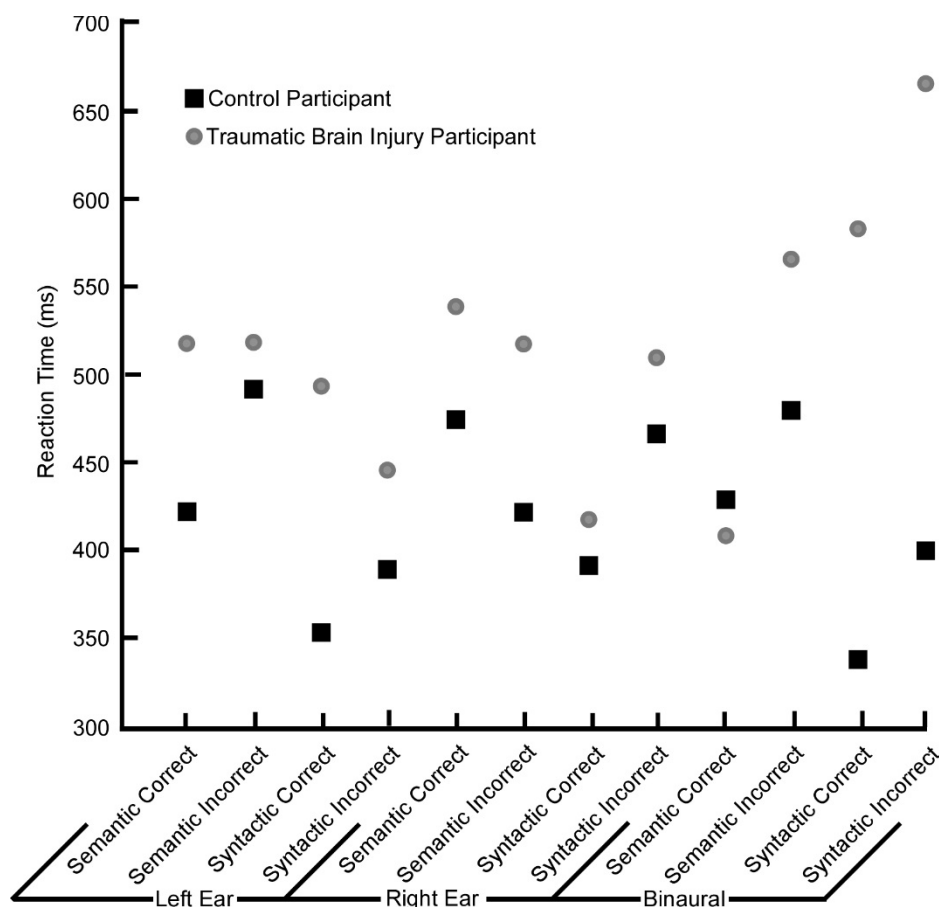


Figure 3. Plot of RT for both the control participant and the traumatic brain injury patient as a function of condition.

Figure 6 illustrates the error rates for each of the conditions in both participants, and the difference between the two participants. Participant TB consistently had the most errors. The largest errors for participant TB occurred for the syntactic sentences regardless of whether the sentence was correct or incorrect, with more errors occurring for right ear and binaural

presentation. More errors occurred for the incorrect syntactic sentences than for correct sentences. Overall it was noted that TB had 53.01% more errors than participant CP.

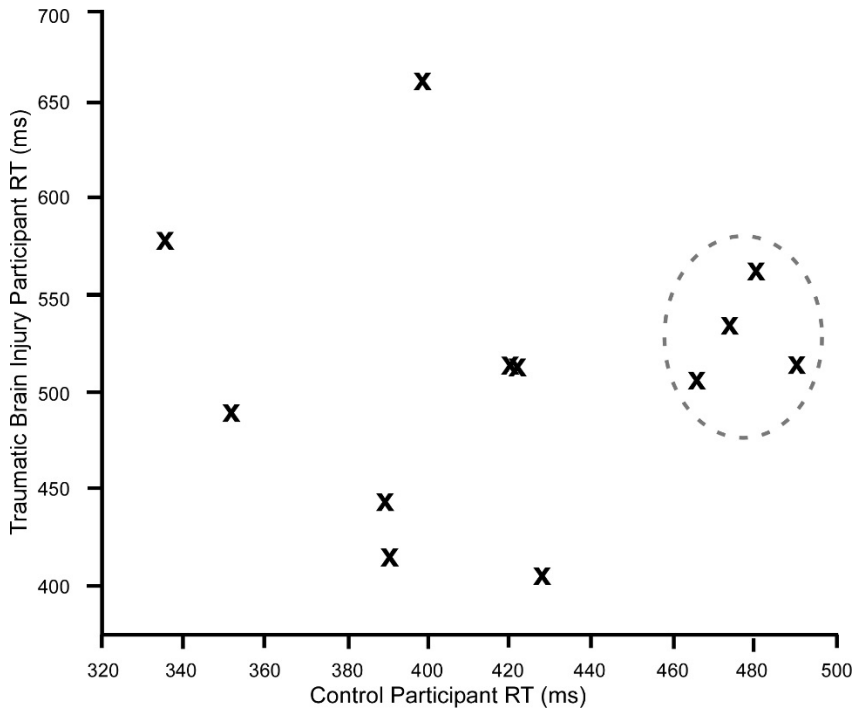


Figure 4. Scattergram of RT for all conditions. Clustering is seen within the dashed oval.

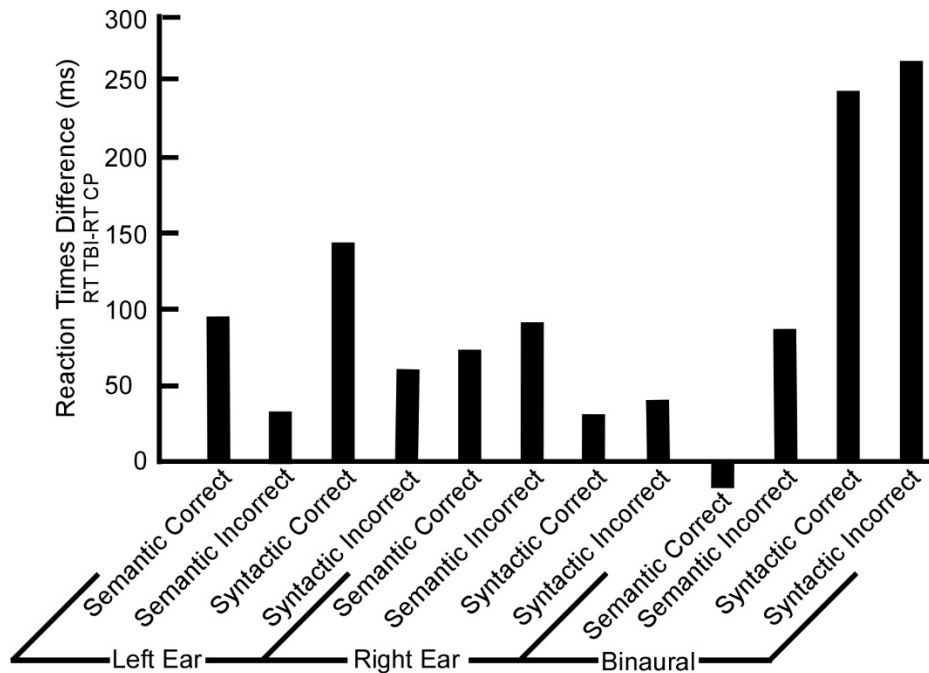


Figure 5. Bar chart of RT differences (TB – CP) for all conditions.

Table 3

Computation of the Binaural Interaction, in ms, within and between the Two Participants

Participant	Derivation Type	Semantic Correct	Semantic Incorrect	Syntactic Correct	Syntactic Incorrect
CP	BI	427.06	479.40	335.42	398.00
	BI%	47.90%	52.74%	45.25%	46.66%
TB	BI	406.63	564.56	581.00	663.00
	BI%	38.68%	54.76%	64.06%	69.64%
CP-TB	BID	20.44	-85.16	-245.58	-265.00
	BID%	9.22%	-2.02%	-18.81%	-22.98%

Note. A negative sign (-) represents the left ear response being greater than the right ear response (LE>RE); The procedures were adapted from McPherson et al. (1989) and McPherson & Starr (1993).

CP, control participant.

TB, participant with traumatic brain injury, left temporal lobe.

BI, Binaural interaction where: $BI = [(Right\ Ear + Left\ Ear) - Binaural]$ responses in ms.

BID, Binaural interaction difference is the difference in the BI between the two participants (CP-TB).

$BI\% = BI / (Right\ Ear + Left\ Ear)$.

$BID\%$, the percentage difference of the $BI\%$ between the CP minus TB participants.

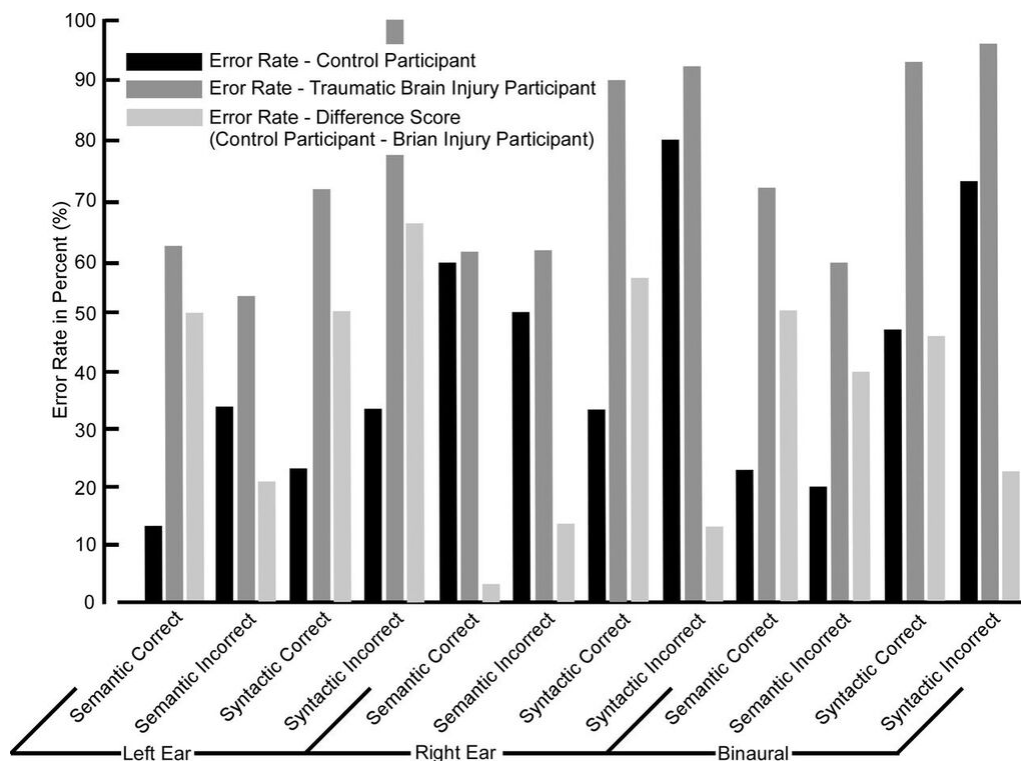


Figure 6. Bar chart of errors for each participant and the difference between (CP-TBI) the two participants.

Imaging

Functional magnetic resonance imaging results are questionable due to patient movement during scanning. Likewise, it was observed that the block design used did not sufficiently allow for patient movement. Consequently, the fMRI results are not discussed due to unforeseen technical problems.

Discussion

This study compared the syntactic and semantic processing of a participant who has a TBI and a neurotypical participant. Both participants were asked to perform a language task while undergoing a fMRI scan. During the scan, participants heard 360 total sentences with four levels of complexity (syntactically correct, syntactically incorrect, semantic correct, and semantically incorrect). Each sentence was presented in three ways (left ear only, right ear only,

and binaurally). Participants were asked to respond using a button push whether they perceived the sentence to be correct or incorrect. Results were recorded and are discussed below.

The RTs were generally longer for the incorrect conditions in both participants for both the syntactic and semantic sentences suggesting increased neural processing of the information in an attempt to place the sentences in the proper linguistic context. Participant TB showed slower reaction times for the syntactic incorrect sentences when binaurally presented in reference to either right or left ear monaural presentation. This can be interpreted as conflicting information within the integration of the auditory system and interference, or bias, from the damaged pathway. For example, the results showed between 64% and 70% error rates for right ear presentation of monaural syntactic sentences. This was not seen in presentation of the semantic sentences. In general, participant TB required increased processing time for syntactic information. Since language information is generally processed in the left temporal lobe, it is most likely that these delays are representative of an attempt to first process the information in the left temporal lobe and subsequently requiring it to be processed in the right temporal lobe; suggesting perhaps plasticity within the right temporal areas. This is consistent with the observation that TB currently displays some anecdotal evidence of difficulty in word finding in that the retrieval process may be delayed.

The RTs for participant TB are longer than for participant CP. This difference appears more pronounced in the binaural condition than in either the left or right monaural conditions. However, this suggests that in binaural condition there is a disruption of neural networks, which resulted in greater errors. Likewise, this is more pronounced in the syntactic binaural condition.

The finding that participant TB had greater syntactic errors than participant CP and greater overall errors (53%) is consistent with the current observation of difficulties with frontal lobe activities including organizational and prioritization.

The differences between the two participants are expected to be much larger when comparing a patient with a temporal lobectomy and a neurotypical control participant. Although these results demonstrate differences between the two participants, the results demonstrate that participant TB's brain has adapted to accommodate for the damage to his brain. New pathways have formed in his brain to restore the functions, such as semantic and syntactic processing, that were performed by the left temporal lobe prior to the TBI.

The block design used for the current study did not allow for the patient movement that occurred. This design ran each condition (semantic correct, semantic incorrect, syntactic correct and syntactic incorrect) in the same block. Because of this, the imaging for each condition was not sufficient to account for participant movement. In addition to an inadequate block design, there was poor training of the language processing task to the participants. Participants were instructed to use a button press to respond to the sentence stimuli. To respond, they were asked to press buttons corresponding to 'correct' and 'incorrect'. This procedure might not have been presented clearly to the participants. Misunderstanding of which button to press may have occurred for certain conditions. Also, there was minimal instruction to the participants regarding movement during scanning. Participants might not have understood the importance of staying still during the fMRI scan. More monitoring of movement from the instructor should have occurred as well. As movement was seen, reminders to stay still should have been given to the participants by the instructor.

For future studies, it is recommended that the block design be revised. Instead of placing all sentence stimuli for each condition in a single block, stimuli for each condition need to be spread out throughout each block to accommodate patient movement or other errors. This design would allow scans for each condition to be salvaged on the chance that errors occurred during scanning. It is also recommended to provide each participant with more in depth instructions of how to perform the language processing task. The instructor should make sure each participant has a clear understanding of instructions, including which button corresponds to ‘correct’ and ‘incorrect’ before beginning the fMRI scanning. Further, the instructor should use diligence in monitoring movement and provide consistent reminders to the participants during the study to remain still.

Additional research should be pursued in this area of study. Because the results of this case study were inconclusive, it is recommended to perform further studies using a revised block design for fMRI scanning. In addition, correct and incorrect responses should be collected as part of the design.

References

- Bailey, J. L. (2014). *Language pathways defined in a patient with left temporal lobe damage secondary to traumatic brain injury: A QEEG & MRI study* (Unpublished master's thesis). Brigham Young University, Provo, UT.
- Carramazza, A., & Zurif, E. (1976). Dissociations of algorithmic and heuristic processes in sentence comprehension: Evidence from aphasia. *Brain and Language*, 3, 572-582.
doi:10.1016/0093-934X(76)90048-1
- Cox, R. W. (1996). AFNI: Software for analysis and visualization of functional magnetic resonance neuroimages. *Computers and Biomedical Research*, 29, 162-173.
- Fedorenko, E., Nieto-Castañón, A., & Kanwisher, A. (2011). Syntactic processing in the human brain: What we know, what we don't know, and a suggestion for how to proceed. *Brain and Language*, 120(2012), 187-207. doi:10.1016/j.bandl.2011.01.001
- Goodglass, H., Kaplan, E., & Baressi, B. (2001). *Boston diagnostic aphasia examination: Short form record booklet* (3rd ed.). Boston, MA: Lippincott, Williams, & Wilkins.
- Grafman, J. (2000). Conceptualizing functional neuroplasticity. *Journal of Communication Disorders*, 33, 345-356. doi:10.1016/S0021-9924(00)00030-7
- Grodzinsky, Y., & Friederici, A. D. (2006). Neuroimaging of syntax and syntactic processing. *Current Opinion in Neurobiology*, 16(2), 240-246.
doi:10.1016/j.conb.2006.03.007
- Huang, J., Wang, S., Jia, S., Mo, D., & Chen, H. (2013). Cortical dynamics of semantic processing during sentence comprehension: Evidence from event-related optical signals. *PLOS One*, 8(8). doi:10.1371/journal.pone.0070671

- Huettel, S. A., Song, A. W., & McCarthy, G. (2009). *Functional magnetic resonance imaging*. Sunderland, MA: Sinauer Associates.
- Hyatt, E. (2015). *The right ear advantage in response to levels of linguistic complexity: A functional magnetic resonance imaging study* (Unpublished master's thesis). Brigham Young University, Provo, UT.
- Kim, S., & Bandettini, P. A. (2006). Principles of functional MRI. In S. H. Faro & F. B. Mohamed (Eds.), *Functional MRI: Basic principles and clinical applications* (pp. 3-23). New York, NY: Springer.
- Lu, D., Mahmood, A., & Chopp, M. (2003). Biologic transplantation and neurotrophin-induced neuroplasticity after traumatic brain injury. *The Journal of Head Trauma Rehabilitation*, *18*(4), 357-376. doi:10.1097/00001199-200307000-00006
- Marinis, T. (2009). Syntactic processing in development and acquired language disorders. In M. J. Ball, M. R. Perkins, N. Muller, & S. Howard (Eds.), *The handbook of clinical linguistics* (pp. 1-25). Oxford, UK: Blackwell Publishing, Ltd. doi:10.1002/9781444301007.ch12
- McPherson, D. L., Tures, C., & Starr, A. (1989). Binaural interaction of the auditory brain-stem potentials and middle latency auditory evoked potentials in infants and adults. *Electroencephalography and Clinical Neurophysiology*, *74*(2), 124-130. doi:10.1016/0168-5597(89)90017-8
- McPherson, D. L., & Starr, A. (1993). Binaural interaction in auditory evoked potentials: Brainstem, middle- and long-latency components. *Hearing Research*, *66*(1), 91-98. doi:10.1016/0378-5955(93)90263-Z
- Nordvik, J. E., Walle, K. M., Nyberg, C. K., Fjell, A. M., Walhovd, K. B., Westlye, L. T., & Tornas, S. (2014). Bridging the gap between clinical neuroscience and cognitive

rehabilitation: The role of cognitive training, models of neuroplasticity and advanced neuroimaging in future brain injury rehabilitation. *NeuroRehabilitation*, *34*, 81-85.

doi:10.3233/NRE-131017

Rommers, J., Dijkstra, T., & Bastiaansen, M. (2013). Context-dependent semantic processing in the human brain: Evidence from idiom comprehension. *Journal of Cognitive Neuroscience*, *25*(5), 762-776. doi:10.1162/jocn_a_00337

Schneider, W., Eschman, A., & Zuccolotto, A. (2012). *E-prime user's guide*. Pittsburgh: Psychology Software Tools, Inc.

Studio Audio & Video Limited. (2004). SADiE [Computer software]. Cambridgeshire, UK: Prism Sound Limited.

Villamar, M. F., Portilla, A. S., Fregni, F., & Zafonte, R. (2012). Noninvasive brain stimulation to modulate neuroplasticity in traumatic brain injury. *Neuromodulation*, *15*, 326-338. doi:10.1111/j.1525-1403.2012.00474.x

Wilson, S. M., DeMarco, A. T., Henry, M. L., Gesierich, B., Babiak, M., Mandelli, M. L., . . . Gorno-Tempini, M. L. (2014). What role does the anterior temporal lobe play in sentence-level processing? Neural correlates of syntactic processing in semantic variant primary progressive aphasia. *Journal of Cognitive Neuroscience*, *26*(5), 970-985. doi:10.1162/jocn_a_00550

Appendix A: Sentence Stimuli**Syntactically Correct**

1. The dog ran down the street.
2. They painted the book red.
3. The child laughed at the clown.
4. She returned the damaged computer.
5. She believed in fairy tales.
6. I really didn't like the play.
7. He got a cream pie smashed in his face
8. The bridge fell down.
9. A tornado hit the town.
10. He wants to eat dessert.
11. The boy watched the sun rise.
12. A rod is used to catch pink salmon.
13. The boy helped the woman.
14. The soft cushion broke the man's fall.
15. The girl gave no clear answer.
16. The cow slept in the grass.
17. The man left the grocery store.
18. The clock struck midnight.
19. The plate hit the floor with a crash.
20. The children slide into the pool.
21. I found a gold coin on the playground.

22. The girl wore her hair in two braids.
23. My mom drove me to school.
24. I fell in the mud.
25. My pen leaked ink on my dress.
26. The parents were eating donuts.
27. I got my hair cut today.
28. I lost my pet turtle.
29. My mom drives a jeep.
30. I got my finger stuck in the door.

Syntactically Incorrect

1. The dog runned down the street.
2. They painting the book red.
3. The child laugh at the clown.
4. She return the damaged computer.
5. She believing in fairy tales.
6. I really didn't liked the play.
7. He got a cream pie smashes in his face.
8. The bridge felled down.
9. A tornado hitted the town.
10. He wants to eating dessert.
11. The boy watched the sun rised.
12. A rod is uses to catch pink salmon
13. The boy is helps the woman.

14. The soft cushion broked the man's fall.
15. The girl gived no clear answer.
16. The cow sleep in the grass.
17. The man lefts the grocery store.
18. The clock strike midnight.
19. The plate hitting the floor with a crash.
20. The children slides into the pool.
21. I find a gold coin on the playground.
22. The girl wearing her hair in two braids.
23. My mom drived me to school.
24. I falling in the mud.
25. My pen is leaked ink on my dress.
26. The parents were eat donuts.
27. I got my hair cutted today.
28. I losted my pet turtle.
29. My mom droves a jeep.
30. I got my finger stick in the door.

Semantically Correct

1. The green frog jumped.
2. The rough rock was coarse to the touch
3. The soft fur felt like silk.
4. The museum was very interesting.
5. The woman was so happy she couldn't stop smiling.

6. The large desk seemed to fill the entire room.
7. The salt breeze came across from the sea.
8. The ship was broken on the sharp reef.
9. The sick boy didn't go to school for three weeks.
10. The ice cream melted in the hot sun.
11. The heavy coat kept the girl warm in the winter.
12. The crooked maze fooled the man.
13. The TV show was cancelled due to poor ratings.
14. A saw is a tool used for cutting pieces of wood.
15. The wagon moved easily on well-oiled wheels.
16. A cup of sugar makes baked goods sweet.
17. The woman was comfortable on the soft bed.
18. A tame squirrel makes a nice pet.
19. A pound of sugar costs more than eggs.
20. The old pipe began to rust.
21. I was so thirsty I needed a drink of water.
22. My bandaid wasn't sticky so it fell off.
23. The mouse was hungry so he looked for food.
24. Your mom is nice because she gave me a ride home.
25. This dinner is so delicious I can't stop eating.
26. The principal was mean and the kids were scared of him.
27. My dad is so funny that he tells us jokes.
28. The camping trip was fun and I didn't want to come home.

29. The dog was so tired he fell asleep.

30. I walked so far my feet got tired.

Semantically Incorrect

1. The colorless green frog jumped.

2. The rough rock was smooth to the touch.

3. The soft fur felt like gravel.

4. The museum was very interested.

5. The woman was so happy she couldn't stop frowning.

6. The small desk seemed to fill the entire room.

7. The salt breeze came across from the desert.

8. The ship was broken on the dull reef.

9. The healthy boy didn't go to school for three weeks.

10. The ice cream melted in the cold air.

11. The heavy coat kept the little girl cold in the summer.

12. The straight maze fooled the man.

13. The TV show was cancelled due to high ratings.

14. A saw is a tool used for putting pieces of wood together.

15. The wagon moved easily on poorly oiled wheels.

16. A cup of salt makes baked goods sweet.

17. The woman was comfortable on a hard bed.

18. A wild squirrel makes for a nice pet.

19. A pound of sugar costs less than eggs.

20. The new pipe began to rust.

21. I was so thirsty I didn't need a drink of water.
22. My bandaid was too sticky so it fell off.
23. The mouse was hungry so he didn't look for food.
24. You mom is mean because she gave me a ride home.
25. This dinner is delicious so I want to stop eating.
26. The principal was nice so the children were scared of him.
27. My dad is boring so he tells us jokes.
28. The camping trip was fun so I wanted to go home.
29. The dog was not tired and it fell asleep.
30. I walked so far my feet were energized.

Appendix B: Informed Consent to Act as a Human Research Subject

David L. McPherson, Ph.D.
Communication Science and Disorders
Brigham Young University
(801) 422-6458

Name of Participant: _____

Purpose of Study

This research is being conducted by Dr. David McPherson, Dr. Brock Kirwan, and Elizabeth Hyatt at Brigham Young University to identify differences in neural activation between the two sides of the brain in response to a variety of stimuli. This will be accomplished by measuring brain activity while listening to noise syllables, words, and sentences presented and reporting what information is heard best. Before you decide to participate in the study, it is important for you to understand why the research is being done and what it will involve. Please take time to read the following information carefully. Ask us if there is anything that is not clear or if you would like more information. Take time to decide whether you want to volunteer or take part in this study. You were invited to participate because you indicated your interest and that you are a good match for the group that we would like to study. We anticipate about 10 people will participate in this study.

Procedures

This study will involve one to three visits, which will last approximately an hour and 45 minutes to 3 hours in total. This will occur at the BYU MRI research facility and in the TLRB. If you agree to be in this study, the following will happen:

- You will fill out a magnetic resonance imaging (MRI) screening questionnaire, which will determine if it is safe for you to undergo MRI scanning.
- Next, an MRI will be done of your head. MRI detects the magnetic properties of fluids and tissues and allows researchers to obtain high resolution images of your brain. This will involve your lying quietly inside the center of a large doughnut-shaped magnet for up to an hour. Your head will be positioned with cushions to keep your head in the proper position within the scanner. While in the scanner, you will complete a computerized task during which you will be presented with sounds and words to both ears simultaneously. You will be asked to respond by pressing buttons on a hand-held response box to indicate which sound you hear best (first, more clearly).

Risks/Discomforts

Participation in this study may involve some additional risks or discomforts. There are no known adverse effects from exposure to magnetic fields (MRI). However, if you are pregnant or believe you may be pregnant, you should not take part in this research. The MRI may be harmful to an unborn baby. The scanner makes a loud banging noise while it is taking pictures. You will be given a set of earplugs to help with the noise. Some people undergoing this procedure become acutely anxious, or get claustrophobic. If this happens to you, you can tell us and we will stop the procedure immediately. You may experience some muscular aches and fatigue from lying still on your back in a confined space during the imaging. If you have any metal clips or plates in your body, or a pacemaker, you should tell the investigator about it immediately. MRI may not be appropriate under some of the following conditions: a cardiac pacemaker; metal fragments in eyes, skin, body; heart valve replacement; brain clips; venous umbrella; being a metal worker or welder; aneurysm surgery; intracranial bypass; renal or aortic clips; prosthetic devices such as middle ear, eye, joint, or penile implants; joint replacements; hearing aid; neuro-stimulator; insulin pump; IUD; shunts/stents; metal mesh/coil implants; metal plates, pins, screws, or wires or any other metal implant; permanent eye liner or eyebrows.

Benefits

There will be no direct benefits to you from these procedures. However, your participation may contribute to the scientific community's understanding on how language is processed in the brain which will be beneficial to professionals in the corresponding field.

Incidental Findings

The MRI scans being performed are for research purposes and are not of clinical quality. If the research team observes any abnormalities on your scans, they will be forwarded to be read by a qualified medical professional, who will contact you with any possible concerns. It will be your responsibility to arrange any clinical scans with your primary care physician.

Confidentiality

All information obtained from testing is confidential and is protected under the laws governing privacy. All identifying references will be removed and replaced by control numbers. Data collected in this study will be stored in a secured area accessible only to personnel associated with the study. Data will be reported without individual identifying information.

Compensation

You will be given \$20 compensation at the completion of this portion of the study. If you do not complete the study session because you ask to be let out of the scanner before the study is complete or because the researcher terminates the study, you will be compensated \$10 for your participation.

Participation

Participation in this research study is voluntary. You have the right to withdraw at any time or refuse to participate entirely without affecting your standing with the University.

Questions about the Research

If there are any further questions or concerns regarding this study, you may ask the investigator or contact David McPherson, Ph.D., Communication Science and Disorders, at (801) 422-6458; Taylor Building Room 129, Brigham Young University, Provo, Utah 84602; e-mail: david_mcpherson@byu.edu.

Questions about your Rights as a Research Participant

If you have questions regarding your rights as a research participant, you may contact the BYU IRB Administrator at (801) 422-1461; A-285 ASB, Brigham Young University, Provo, UT 84602; e-mail: irb@byu.edu.

Statement of consent

I have read and understand the above consent and desire of my own free will to participate in this study.

Printed Name: _____

Signature: _____

Date: _____

Appendix C: BYU MRI Research Facility Screening Form

BYU MRIRF Screening Form

All information is held in confidence and will not be part of any aspect of the study for which you are participating.

Brigham Young University
Magnetic Resonance Imaging Research Facility
Tel: (801) 422-9420

Name (first, middle, last): _____

Today's Date: ___ / ___ / ___ (mm/dd/yyyy)

Time: ___ : ___ (am) (pm)

Date of Birth: ___ / ___ / ___

Height (ft. in.): _____

Sex (circle one): Male Female

Weight (lbs.): _____

Are you fluent in English? Yes No

Can you lie still for an hour? Yes No

Are you pregnant or could you be pregnant? Yes No N/A

Are you currently breastfeeding? Yes No N/A

Have you ever had an MRI examination or participated in an MRI study? Yes No

 If so, did you have complications? Yes No

 If yes, please explain: _____

Have you ever been injured by a metal object or foreign body (e.g., bullet, BB, shrapnel)? Yes No

 If yes, please explain: _____

Have you ever worked with metal (e.g., welder, grinder, fabricator) or ever had an injury to the eye involving a metallic object (e.g., metallic slivers, shavings, foreign body)? Yes No

 If yes, please describe: _____

Have you ever had an allergic reaction to a contrast agent administered for imaging purposes? Yes No

 If yes, please state the contrast agent that was used and describe what happened:

Check if you have ANY of the following:

Please be honest: It is for your safety. All of your responses are confidential.

****IMPORTANT INSTRUCTIONS****

1) The objects below can be hazardous or interfere with the MRI exam. Please go through the list carefully and check any that apply to you.

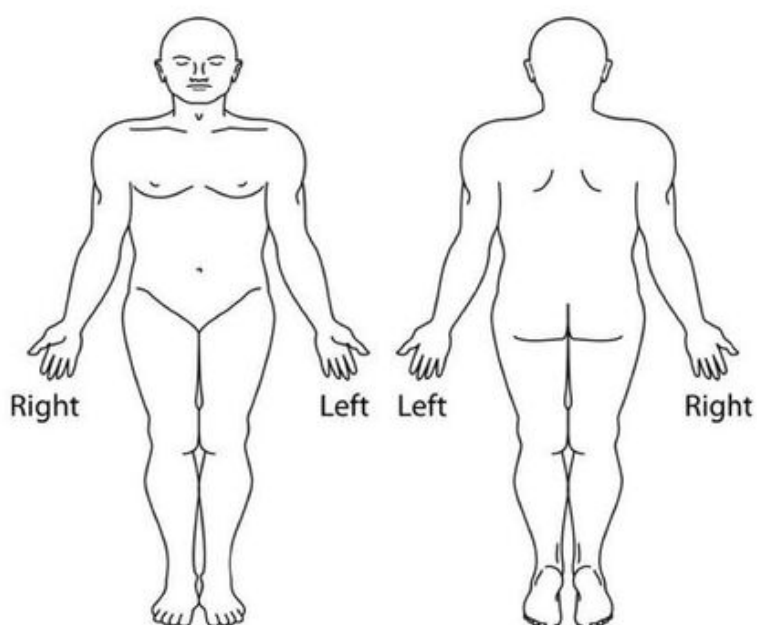
2) Before entering the scan room, remove any and all metallic objects and the following: hearing aids, dentures, false teeth, partial plates, keys, beepers, cell phones, pagers, eyeglasses, hair/bobby pins, barrettes/hair clips, jewelry, body piercing jewelry, watches, safety pins, paperclips, money clips, credits cards, bank cards, any magnetic strip cards, coins, pens, pocket knives, nail clippers, tools, clothing with metal fasteners and/ or zippers, and clothing with metallic threads.

- | | |
|---|--|
| <input type="checkbox"/> Yes <input type="checkbox"/> No Heart Pacemaker | <input type="checkbox"/> Yes <input type="checkbox"/> No Medication Patch (nicotine, nitroglycerine, Other: _____) |
| <input type="checkbox"/> Yes <input type="checkbox"/> No Implanted Cardiac Defibrillator (ICD) | <input type="checkbox"/> Yes <input type="checkbox"/> No Wire Mesh Implant |
| <input type="checkbox"/> Yes <input type="checkbox"/> No Aneurysm Clip | <input type="checkbox"/> Yes <input type="checkbox"/> No Removable (circle) Dentures / Retainers / Other: _____ |
| <input type="checkbox"/> Yes <input type="checkbox"/> No ANY Electronic, Mechanical, and/or Magnetic Implant and/or Biostimulator or Neurostimulator. Type: _____ | <input type="checkbox"/> Yes <input type="checkbox"/> No Permanent Retainers |
| <input type="checkbox"/> Yes <input type="checkbox"/> No Any Type of Ear Implant (e.g., cochlear, stapes, etc.) | <input type="checkbox"/> Yes <input type="checkbox"/> No Dental Bridge |
| <input type="checkbox"/> Yes <input type="checkbox"/> No Spinal Cord Stimulator | <input type="checkbox"/> Yes <input type="checkbox"/> No Bronzing / Tanning Lotions |
| <input type="checkbox"/> Yes <input type="checkbox"/> No Internal Electrodes or Wires | <input type="checkbox"/> Yes <input type="checkbox"/> No Body Piercing that Cannot Be Removed (<i>Removables must be removed before scan</i>) |
| <input type="checkbox"/> Yes <input type="checkbox"/> No Aortic or Carotid Artery Clips | <input type="checkbox"/> Yes <input type="checkbox"/> No Hair Pins or Hair Piece / Wig / "Weave" (<i>if there are ferromagnetic items involved, you will have to remove item before MRI scan room entry</i>) |
| <input type="checkbox"/> Yes <input type="checkbox"/> No Hearing Aid (<i>Remove before MRI scan room entry</i>) | <input type="checkbox"/> Yes <input type="checkbox"/> No Breast Expander / Markers / Implants / Other: _____ |
| <input type="checkbox"/> Yes <input type="checkbox"/> No Insulin or Other Implanted Infusion Pump | <input type="checkbox"/> Yes <input type="checkbox"/> No Acticoat Silver Wound Dressing |
| <input type="checkbox"/> Yes <input type="checkbox"/> No Swan-Gantz or Thermodilution Catheter | <input type="checkbox"/> Yes <input type="checkbox"/> No Any Other Implants (e.g., pill camera, etc.) Type: _____ |
| <input type="checkbox"/> Yes <input type="checkbox"/> No Antimicrobial Athletic Clothing | <input type="checkbox"/> Yes <input type="checkbox"/> No History of Kidney Problems (e.g., failure, removal, cancer, etc.) |
| <input type="checkbox"/> Yes <input type="checkbox"/> No Heart Valve or Stent | <input type="checkbox"/> Yes <input type="checkbox"/> No Any Other Type of Internal Coil, Filter, or Stent |
| <input type="checkbox"/> Yes <input type="checkbox"/> No Shunt (intraventricular or spinal) | <input type="checkbox"/> Yes <input type="checkbox"/> No Halo Vest |
| <input type="checkbox"/> Yes <input type="checkbox"/> No Vascular Coil, Umbrella (filter for clots), or Stent | <input type="checkbox"/> Yes <input type="checkbox"/> No Spinal Fixation Device |
| <input type="checkbox"/> Yes <input type="checkbox"/> No Vascular Access Port and/or Catheter | <input type="checkbox"/> Yes <input type="checkbox"/> No Spinal Fusion Procedure |
| <input type="checkbox"/> Yes <input type="checkbox"/> No Prosthesis (limbs, joints, or eye) | <input type="checkbox"/> Yes <input type="checkbox"/> No Any Type of Implant Held in Place by a Magnet; Type: _____ |
| <input type="checkbox"/> Yes <input type="checkbox"/> No Joint Replacement (hip, knee, etc.) | <input type="checkbox"/> Yes <input type="checkbox"/> No Any IV Access Port (e.g., broviac, port-a-cath, hickman, picc line, etc.) |
| <input type="checkbox"/> Yes <input type="checkbox"/> No Metal (circle) Rods / Plates / Screws / Nails / Pins / Clips / Other: _____ | <input type="checkbox"/> Yes <input type="checkbox"/> No Radiation Seeds (e.g., cancer treatment) |
| <input type="checkbox"/> Yes <input type="checkbox"/> No Surgical Staples, Clips, or Wire Sutures | <input type="checkbox"/> Yes <input type="checkbox"/> No Colored Contact Lenses |
| <input type="checkbox"/> Yes <input type="checkbox"/> No IUD, Diaphragm, Penile Implant | <input type="checkbox"/> Yes <input type="checkbox"/> No Claustrophobia |
| <input type="checkbox"/> Yes <input type="checkbox"/> No Shrapnel (metal fragments) / Gunshot Injury. Location: _____ | <input type="checkbox"/> Yes <input type="checkbox"/> No Tattoo and/or Permanent Make-up (e.g., lips, eyeliner, etc.) |
| <input type="checkbox"/> Yes <input type="checkbox"/> No Metal Fragments in Eye (history as a grinder or welder) | |
| <input type="checkbox"/> Yes <input type="checkbox"/> No Implanted Drug Infusion Device | |
| <input type="checkbox"/> Yes <input type="checkbox"/> No Eyelid Spring or Wire | |

Yes No Have you had any previous surgeries?

If so, list all prior surgery dates and details:

If you have had any implants or surgeries done, please indicate where on the body forms:



MRI Personnel Only

I, a certified Level 3 MRI Operator, have screened for hazardous materials and approved the subject for participation in this MRI research study.

This is valid *only* on the day it is completed. Returning subjects must fill out a new form.

Subject ID: _____

Name of MRI operator completing form
(print)

Signature

Date

Appendix D: Annotated Bibliography

Bailey, J. L. (2014). *Language pathways defined in a patient with left temporal lobe damage secondary to traumatic brain injury: A QEEG and MRI study* (Unpublished Master's Thesis). Brigham Young University, Provo, UT.

Objective: To compare language processing in the brain between a patient with TBI and a control patient. *Study Sample:* 1 participant with traumatic brain injury and an age matched control. *Methods:* Patients underwent quantitative electroencephalography (QEEG) testing. Participants listened to syntactically correct and incorrect sentences. They were asked to determine whether the sentences they heard were correct or incorrect. *Results:* The patient with TBI made more errors identifying syntactically incorrect sentences than the control participant. *Conclusions:* The patient with TBI exhibited more errors than the control participant, especially with syntactically incorrect sentences. This could be due to inaccurate pathways. However, this study demonstrates the brain's remarkable capabilities to adapt and change after injury. *Relevance to current work:* The current study is a follow up of this thesis. The same participant with TBI was analyzed in each thesis. *Level of evidence:* Level II

Carramazza, A., & Zurif, E. (1976). Dissociations of algorithmic and heuristic processes in sentence comprehension: Evidence from aphasia. *Brain and Language*, 3, 572-582. doi:10.1016/0093-934X(76)90048-1

Objective: To study how patients with varying types of aphasia process and comprehend language. *Study Sample:* Three groups of aphasic patients participated in the study. Each group was diagnosed with a different type of aphasia: Broca's, Conduction, and Wernicke's. A fourth group was a control group consisting of nonaphasic patients. *Methods:* Participants heard three different types of sentences while viewing two pictures. They were asked to determine which of the two pictures described the meaning of each sentence they heard. *Results:* Those with Broca's and Conduction aphasia scored most perfect when they could use semantic information. However, their performance dropped when they had to use syntactic information. *Conclusions:* Carramazza and Zurif conclude that neuropsychological dissociation of heuristic and algorithmic processing. They believe this is based on the processing of semantic and syntactic information. *Relevance to current work:* This study examined semantic and syntactic language processing in patients who have experienced brain damage, which is similar to the current study. *Level of evidence:* Level II

Fedorenko, E., Nieto-Castañón, A., & Kanwisher, A. (2011). Syntactic processing in the human brain: What we know, what we don't know, and a suggestion for how to proceed. *Brain and Language*, 120(2012), 187-207. doi:10.1016/j.bandl.2011.01.001

Objective: To examine different methods of syntactic processing in the brain to find a clearer picture of the neural basis. *Study Sample:* A dataset consisting of 25 participants was used. *Methods:* Participants were read lists of four different conditions: sentences, words, jabberwocky sentences, and pronounceable nonwords. This data was collected to form activation maps to determine subject specific functional regions of interest (fROIs). Researchers would take individual activation maps and overlay them on top of each other. This allowed researchers to

view and create “partitions” of common brain area activation during language processing.

Results: It was found that fROIs that were group-constrained and subject specific (GSS) were more selective than ROIs defined around activation peaks. Researchers also found that variability also exists in how selective the GSS fROIs are. GSS fROIs were also found to have larger effect sizes than anatomical fROIs. *Conclusions:* It is believed that it is possible that all language-sensitive brain regions support multiple aspects of language. Further studies should be done to further investigate this conclusion. *Relevance to current work:* This study provides insight to how the brain processes syntactic information, which was a key component of the current study.

Level of evidence: Level II

Grafman, J. (2000). Conceptualizing functional neuroplasticity. *Journal of Communication Disorders*, 33, 345-356. doi:10.1016/S0021-9924(00)00030-7

Objective: To examine for major types of neuroplasticity occurring during language recovery; homologous area adaptation, cross-modal reassignment, map expansion, and compensatory masquerade. *Study Sample:* Due to a multiple method analysis, multiple sample sizes were used. *Methods:* This was a multi-analysis study. Multiple methods were used to gather information. *Results:* Homologous area adaptation is defined as shifting specific brain operations to other undamaged areas in the brain. Cross-modal reassignment occurs when new inputs for damaged functions are introduced into represented brain regions. Map expansion can have two implications. The first occurs when cortical regions for specific functions expand into surrounding regions when damaged. The second requires the entire network to be active while selecting a unit of representation. After a unit is selected, the network relaxes and in turn uses less energy. Finally, compensatory masquerade occurs when tasks dependent on impaired processes occurs. *Conclusions:* Evidence of all four types of neuroplasticity has been found in various patients. *Relevance to current work:* This article identifies four different types of neuroplasticity. An understanding of neuroplasticity is critical to the current study. *Level of evidence:* Level IIIa

Grodzinsky, Y., & Friederici, A. D. (2006). Neuroimaging of syntax and syntactic processing. *Current Opinion in Neurobiology*, 16(2), 240–246. doi:10.1016/j.conb.2006.03.007

Objective: To explain brain mapping of language when processing syntactic information. *Study Sample:* This article is a review of literature. No study was conducted. *Methods:* This study used a review of literature to examine brain mapping of syntactic information. *Results:* There are two main approaches to localization of syntax: formal syntax map (FSM) and language processing map (LPM). It was found that Broca’s region plays a central role in syntactic analysis. Also, they demonstrate new areas in both hemispheres that are used for syntactic processing. *Conclusions:* This way of brain mapping is preliminary. However, it is beginning to emerge requiring further research. *Relevance to current work:* This study analyzed the areas of the brain and the processes used to analyze syntactic information, which is a key component of the current study. *Level of evidence:* Level I

Herrmann, B., Maess, B., Hahne, A., Schroger, E., & Friederici, A. D. (2011). Syntactic and auditory special processing in the human temporal cortex: An MEG study. *NeuroImage*, 57, 624-633. doi:10.1016/j.neuroimage.2011.04.034

Objective: To localize the cortical regions used during syntactic and perceptual processing. *Study Sample:* Twenty-four native German speakers participated in the present study. *Methods:* 384 sentences of four different conditions were presented to the participants in four randomized blocks using headphones. After each sentence was presented, participants were asked to use a response button to determine if the sentence was syntactically correct or incorrect. *Results:* When syntactically incorrect sentences were presented, activation was observed in the anterior superior temporal gyrus (STG). When there are double violations in sentences, the anterior and posterior STG were activated simultaneously. *Conclusions:* It was found that the anterior STG plays a role in speech related processing. *Relevance to current work:* The method of this study is similar to the current study. This article provides further insight to the syntactic processing of the brain. *Level of evidence:* Level II

Huang, J., Wang, S., Jia, S., Mo, D., & Chen, H. (2013). Cortical dynamics of semantic processing during sentence comprehension: Evidence from event-related optical signals. *PLOS One*, 8(8). doi:10.1371/journal.pone.0070671

Objective: To study the different dynamics of brain activation during sentence comprehension. The study used an event-related optical signal (EROS) technique. *Study Sample:* Fifteen native mandarin speakers participated in the study. *Methods:* Two stimulus lists were created. Participants were randomly assigned a list and were asked to read the various sentences. After reading the sentence, they were asked to determine if the sentence was plausible or not using a response button. *Results:* EROS results demonstrated activation of the left posterior middle temporal gyrus (LpMTG), followed by the left anterior inferior frontal gyrus (LaIFG) and the left middle frontal gyrus (LMFG), before the LpMTG was activated again. Expected words within the sentences elicited greater activation of these brain areas than unexpected words. *Conclusions:* This suggests that two different semantic integration processes, occurring in different brain areas, follow early lexical-semantic retrieval. These processes are a rapid and transient integration in the left anterior temporal lobe, and a slow, enduring integration in the LaIFT/LMFG and the LpMTG. *Relevance to current work:* This article provides insight to the semantic processing of the brain when comprehending sentences. *Level of evidence:* Level II

Hyatt, E. (2015). *The right ear advantage in response to levels of linguistic complexity: A functional magnetic resonance imaging study*. Unpublished Master's Thesis, Brigham Young University, Provo, UT.

Objective: To study the effect of linguistic complexity of the right ear advantage (REA) phenomenon using fMRI. *Study Sample:* Twenty right-handed individuals aged 18-29 participated in the study. *Methods:* During an fMRI scan, participants heard dichotic syllables, words, and sentences, with speech babble as a control. Participants were asked to report the stimulus they heard best using a response button. Reaction times, ear preference, and fMRI data were all recorded. *Results:* Words had the shortest reaction time and the greatest REA. Syllables and sentences had similar results. *Conclusions:* Words would best represent the REA

phenomenon in both clinical and experimental designs. *Relevance to current work:* The method of this study follows a similar pattern to the current study. *Level of evidence:* Level II

Lu, D., Mahmood, A., & Chopp, M. (2003). Biologic transplantation and neurotrophin-induced neuroplasticity after traumatic brain injury. *The Journal of Head Trauma Rehabilitation*, 18(4), 357-376. doi:10.1097/00001199-200307000-00006

Objective: To analyze the process in treatment of traumatic brain injury using various therapies to attempt to reduce neurologic deficits. The therapies include neurotrophins, growth factors, and cell and tissue neurotransplantation. *Study Sample:* This article is a review of literature. No study was conducted. *Methods:* This study used a review of literature to examine the results of these therapies to reduce neurologic deficits. *Results:* Each therapy type had different effects on the brain. *Conclusions:* It was found that cell therapy showed the most substantial promise of the therapies studied. *Relevance to current work:* Examining efforts of how the brain adapts to therapies helps to understand neuroplasticity, which was a key element of the current study. *Level of evidence:* Level I

Marinis, T. (2009). Syntactic processing in development and acquired language disorders. In M. J. Ball, M. R. Perkins, N. Muller, & S. Howard (Eds.), *The handbook of clinical linguistics* (pp. 1-25). Oxford, UK: Blackwell Publishing, Ltd. doi:10.1002/9781444301007.ch12

Objective: To determine if impaired language in developmental language disorders is caused by incomplete linguistic knowledge or by processing limitations. *Study Sample:* This article was a review of literature. No specific experiment or study sample was mentioned in the article. *Methods:* This paper used review of different literature to examine syntactic processing in typically developing children, developmental language disorders, such as Specific Language Impairment (SLI), and acquired disorders, such as aphasia. *Results:* Various studies demonstrate that language impaired children were slower than language controls in word detection, but are using syntactic and semantic and real-world information when processing sentences. This is similar to typically developing children. In acquired disorders, aphasic patients and controls took longer for processing more complex sentences. While both demonstrated difficulty, aphasics were less accurate than the controls. *Conclusions:* Those with language disorders demonstrate more difficulty when processing sentence structure. This review of literature shows that more studies need to be conducted to further prove this statement. *Relevance to current work:* This review of literature analyzes syntactic processing of the brain in those who have language disorders, such as TBI. This gain greater understanding to how the patient processes information in the current study. *Level of evidence:* Level IV

McPherson, D. L., Tures, C., & Starr, A. (1989). Binaural interaction of the auditory brain-stem potentials and middle latency auditory evoked potentials in infants and adults. *Electroencephalography and Clinical Neurophysiology*, 74(2), 124-130. doi:10.1016/0168-5597(89)90017-8

Binaural interactions in brain-stem auditory evoked potentials and in middle latency auditory evoked potentials were studied in 18 normal hearing adults and 10 normal term infants. Binaural interactions at the times of ABR waves V and VI were comparable in term infants and adults.

Binaural interaction during the time domain of the middle latency auditory evoked potentials was the greatest at N20 in term infants and at N40 in adults. Measurement of binaural interaction during maturation may be a useful tool in assessing neurologically affected infants.

McPherson, D. L. & Starr, A. (1993). Binaural interaction in auditory evoked potentials: Brainstem, middle- and long-latency components. *Hearing Research*, 66(1), 91-98. doi:10.1016/0378-5955(93)90263-Z

Binaural interaction occurs in the auditory evoked potentials when the sum of the monaural auditory evoked potentials are not equivalent to the binaural evoked auditory potentials. Binaural interaction of the early- (0-10 ms), middle- (10-50 ms) and long-latency (50-200 ms) auditory evoked potentials was studied in 17 normal young adults. For the early components, binaural interaction was maximal at 7.35 ms accounting for a reduction of 21% of the amplitude of the binaural evoked potentials. For the middle latency auditory evoked potentials, binaural interaction was maximal at 39.6 ms accounting for a reduction of 48% of the binaural evoked potential. For the long-latency auditory evoked potentials, binaural interaction was maximal at 145 ms accounting for a reduction of 38% of the binaural evoked potential. In all of the auditory evoked potentials binaural interaction was long lasting around the maxima. The binaural interaction component extends for several milliseconds in the brainstem to tens of milliseconds in the middle- and long-latency components. Binaural interaction takes the form of a reduction of amplitude of the binaural evoked potential relative to the sum of the monaural responses, suggests that inhibitory processes are represented in binaural interaction using evoked potentials. Binaural processing in the auditory pathway is maximal in the time domain of the middle-latency components reflecting activity in the thalamo-cortical portions of the auditory pathways.

Noppeny, U., & Price, C. J. (2004). An fMRI study of syntactic adaptation. *Journal of Cognitive Neuroscience*, 16, 702-713. doi:10.1162/089892904323057399

Objective: To study the effect of syntactic priming, which is the ease of comprehending sentences with similar syntactic structures, during reading comprehension. *Study Sample:* Twenty-five native English speakers participated in the current study. Twelve of these participated in the fMRI part of the experiment, while the other 13 participated in the behavioral part of the experiment. *Methods:* Participants silently read a total of 160 sentences consisting of four different syntactic forms. During the fMRI experiment, participant's eye movement was tracked to ensure they were attending to the words. In the behavioral experiment, participants were asked to press a response button when they read and understood the sentence. *Results:* The study demonstrated that the syntactic priming effect was reflected both behaviorally and physiologically. Behaviorally it was demonstrated in decreased reading times and physiologically it was demonstrated by attenuated responses in the brain's left temporal pole. *Conclusions:* It was found that if sequential sentences follow a similar syntactic structure, it is less taxing for the reader to comprehend the themes of the sentences. *Relevance to current work:* This study uses fMRI, which was also used in the current study, to analyze how the brain processes syntactic information at the sentence level. *Level of evidence:* Level II

Nordvik, J. E., Walle, K. M., Nyberg, C. K., Fjell, A. M., Walhovd, K. B., Westlye, L. T., & Tornas, S. (2014). Bridging the gap between clinical neuroscience and cognitive

rehabilitation: The role of cognitive training, models of neuroplasticity and advanced neuroimaging in future brain injury rehabilitation. *NeuroRehabilitation*, 34, 81-85. doi:10.3233/NRE-131017

Objective: To examine cognitive training while looking at brain structure change and reorganization. The purpose is to reveal mechanisms for neuroplasticity. *Study Sample:* The current paper took evidence and research from other studies to form their conclusions. No specific experiment was mentioned in the article. *Methods:* This paper uses cognitive rehabilitation techniques to discuss the relevance of these techniques to MRI research on brain plasticity. *Results:* Results show that cognitive training needs to be measured using the “body structure” and “body function” levels of the International Classification of Functioning, Disability and Health model. *Conclusions:* It was concluded that MRI could detect macro- and micro structural changes in the brain after intensive cognitive training. *Relevance to current work:* This study underwent MRI research to determine if the brain undergoes neuroplasticity during rehabilitation after injury. The current study examines how the brain adapts after TBI. *Level of evidence:* Level IV

Rommers, J., Dijkstra, T., & Bastiaansen, M. (2013). Context-dependent semantic processing in the human brain: Evidence from idiom comprehension. *Journal of Cognitive Neuroscience*, 25(5), 762-776. doi:10.1162/jocn_a_00337

Objective: To study the activation and integration of word meanings during language comprehension of idioms. *Study Sample:* In the first experiment, 24 students (17 female and 7 male), aged 18-26 years old, participated. These participants were native Dutch speakers. In the second experiment, 24 different students (21 female and 3 male), aged 18-30 years of age, participated. The participants were native Dutch speakers. *Methods:* Participants were given a list of 240 sentences, with 90 of them being experimental items. In experiment 1, participants were presented sentences with one word highlighted in red. Then they were asked to determine if the red word was Dutch or not. In experiment 2, EEGs were collected while participants read the sentences presented one word at a time. *Results:* In experiment 1, it was found that response times were faster for idiomatic conditions than the literal conditions. They were also faster for correct conditions. *Conclusions:* It was found that the activation and combination of word meanings depends widely on the contexts. *Relevance to current work:* This article provides further understanding of how the brain processes semantic information, which was investigated in the current study. *Level of evidence:* Level II

Ruschemeyer, S., Fiebach, C. J., Kempe, V., & Friederici, A. D. (2005). Processing lexical semantic and syntactic information in first and second language: fMRI evidence from German and Russian. *Human Brain Mapping*, 25, 266-286. doi:10.1002/hbm.20098

Objective: This article uses two different experiences to study the differences in semantic and syntactic processing in native and nonnative speakers of German and Russian. *Study Sample:* In the first experiment the study sample was composed of 18 native German speakers and 7 native Russian speakers. In the second experiment, the same 18 German speakers from experiment one participated. In addition, 14 nonnative German speakers, who were native Russian speakers, participated. *Methods:* In the first experiment, syntactically correct and incorrect sentences were

presented acoustically to the German speakers. Semantically incorrect sentences were also presented. Russian speakers were presented with similar sentences in Russian. Due to differences in languages, some variability was present. While the sentences were presented, fMRI slices were acquired every two seconds. In the second experiment, the same sentences from experiment one was presented acoustically to the native and nonnative German speakers. *Results:* Results show a similar pattern of increased activation for semantic errors than syntactic errors between native and non-native speakers. It was also found that non-native speakers used the inferior frontal gyrus (IFG), superior temporal gyrus and the basal ganglia differently than native speakers. *Conclusions:* This study found that the IFG is activated in language processing. It was also found that native and non-native speakers have similar patterns of activation when correcting errors. *Relevance to current work:* The method of this article is similar and formed part of the basis for the current study. *Level of evidence:* Level II

Thompson, C. K. (2000). Neuroplasticity: Evidence from aphasia. *Journal of Communication Disorders, 33*, 357-366.

Objective: To examine four forms of neuroplasticity and how they relate to language recovery in subjects with aphasia. *Study Sample:* This study is a review of literature. No specific study sample was recorded. *Methods:* Because this study was a review of literature, no specific experiment was conducted. *Results:* It has been observed that patients with aphasia recover language functions to due homologous area adaptation, particularly homologous right hemisphere areas and undamaged language centers in the left hemisphere. Map extension, which occurs when regions of cortical language are expanded in the left hemisphere, is also been seen in language recovery patients. Internal factors, such as blood flow levels and rate of neurotransmitter release, and external organism-specific factors, such as age, gender, and site of lesion, impact the extent of language recovery. *Conclusions:* Evidence for homologous area adaptation and map extension has been found in language recovery of aphasia patients. *Relevance to current work:* This information relates to current studies because it provides evidence of two forms of neuroplasticity, homologous area adaption and map extension existing in language recovery for patients with aphasia. This foundation can be used for further research studies to examine the depth of this phenomenon. *Level of evidence:* Level IV

Villamar, M. F., Portilla, A. S., Fregni, F., & Zafonte, R. (2012). Noninvasive brain stimulation to modulate neuroplasticity in traumatic brain injury. *Neuromodulation, 15*, 326-338. doi:10.1111/j.1525-1403.2012.00474.x

Objective: To study the use of noninvasive brain stimulation (NBS) as a tool to enhance neuroplasticity in traumatic brain injury patients. *Study Sample:* This paper uses a literature search to meet the articles objective. No current experiment was conducted for the purpose of this article. *Methods:* This paper uses a literature search to describe pathophysiological events following TBI. It also investigates the use of transcranial magnetic stimulation (TMS) and transcranial direct current stimulation (tDCS). *Results:* Pathophysiological mechanisms following TBI vary in time. TMS and tDCS have been found to decrease cortical hyperexcitability, modulate long-term plasticity and combined with physical and behavioral therapy. These three effects combine to help decrease disabling effects after TBI. *Conclusions:* Studies demonstrate the possible benefits of NBS to decrease extent of brain injury. It also has

potential to enhance plasticity changes, which facilitate learning and recover of function in damaged brain regions. This is all very theoretical and requires further studies to investigate further. *Relevance to current work:* This article analyzes techniques to enhance neuroplasticity in TBI patients. *Level of evidence:* Level IV

Vonberg, I., Ehlen, F., Fromm, O., & Klostermann, F. (2014). The absoluteness of semantic processing: Lessons from the analysis of temporal clusters in phonemic verbal fluency. *PLoS one*, 9(12):e115846. doi:10.1371/journal.pone.0115846.

Objective: To study the semantic information of words produced under certain phonemic task demands. *Study Sample:* 42 subjects participated in the study. *Methods:* Participants were asked to produce as many s-words as possible in 2 minutes. Temporal clusters were identified and the semantic and phonemic word relatedness between the clusters were assessed. *Results:* Phonemically and semantically were more related within clusters than between clusters. *Conclusions:* It was found that semantic information is spread. There is an interaction between content and sound-related information. *Relevance to current work:* This article investigates how the brain processes semantic information in a typically functioning brain. *Level of evidence:* Level II

Wilson, S. M., DeMarco, A. T., Henry, M. L., Gesierich, B., Babiak, M., Mandelli, M. L., . . . Gorno-Tempini, M. L. (2014). What role does the anterior temporal lobe play in sentence-level processing? Neural correlates of syntactic processing in semantic variant primary progressive aphasia. *Journal of Cognitive Neuroscience*, 26(5), 970--985. doi:10.1162/jocn_a_00550

Objective: To study the role of the anterior temporal lobe during processing of sentences. *Study Sample:* 20 patients with semantic primary progressive aphasia (PPA) and 24 age matched controls participated in the study. *Methods:* Participants underwent a fMRI scan while performing an auditory sentence-to-picture matching task. *Results:* The semantic PPA patients performed accurately on the sentence comprehension task, but less accurately than the controls. They demonstrated the most difficulty with the syntactically complex conditions. Overall, the semantic PPA patients responded more slowly than the controls. *Conclusions:* Syntactic processing in semantic PPA patients depends on the intact structure of the left frontal and left posterior temporal regions of the brain. The role of the anterior temporal lobe in sentence processing is more prominent in higher level processing, than in syntactic structure building. *Relevance to current work:* This study utilized a fMRI scan to demonstrate the role the anterior lobe plays in sentence level processing. The current study has a similar purpose. *Level of evidence:* Level II